

We are IntechOpen, the world's leading publisher of Open Access books Built by scientists, for scientists

6,900

Open access books available

185,000

International authors and editors

200M

Downloads

Our authors are among the

154

Countries delivered to

TOP 1%

most cited scientists

12.2%

Contributors from top 500 universities



WEB OF SCIENCE™

Selection of our books indexed in the Book Citation Index
in Web of Science™ Core Collection (BKCI)

Interested in publishing with us?
Contact book.department@intechopen.com

Numbers displayed above are based on latest data collected.
For more information visit www.intechopen.com



Tissue Engineering: Use of Growth Factors in Bone Regeneration

Carmen Mortellaro and Massimo Del Fabbro

Additional information is available at the end of the chapter

<http://dx.doi.org/10.5772/intechopen.69875>

Abstract

Tissue healing is a complex process involving a cascade of cellular and molecular events that are mostly shared by the different tissues of the body. Interestingly, the tissue repair process initiates immediately after a traumatic injury and is mediated and controlled by a wide range of cytokines, proteins, and growth factors released from platelets upon activation. Consequently, many growth factors have been considered as therapeutic molecules for the repair or regeneration of a wide range of tissues. Although their role has been only partially elucidated, the potential benefit of most growth factors has been demonstrated. In the last few years, the development of platelet-rich preparations has revolutionized the field of regenerative medicine, due to the repair capacities of the platelet-released growth factors that stimulate and accelerate both soft and hard tissue healing and regeneration. Today, autologous platelet concentrates (APCs) are used in a wide range of disciplines such as dentistry, oral surgery, orthopedics, sport medicine, dermatology, and plastic and reconstructive surgery. The purpose of this chapter is to describe the current evidence regarding the benefits of using autologous platelet concentrates in various oral surgery procedures, using a systematic review approach.

Keywords: platelet concentrates, growth factors, tissue regeneration, oral surgery

1. Introduction

Autologous platelet concentrates (APCs) have been widely used in many different clinical situations that require a rapid tissue healing and regeneration as it is especially the case in oral and maxillofacial surgery, orthopedics, sports medicine, ophthalmology, and in the treatment of skin ulcers. APCs are hemocomponents, obtained through centrifugation of patient's own blood, in order to collect the most active blood components: platelets, fibrin,

and in certain cases also leukocytes. The final product has a platelet concentration higher than the basal level, consequently has an increased number of platelet-derived growth factors [1]. The rationale of the clinical use of such platelet-rich preparations is based upon the concept of exploiting their contents enriched of numerous mitogenic platelet-derived growth factors (including platelet-derived growth factor (PDGF), transforming growth factor- β (TGF- β), endothelial growth factor (EGF), vascular endothelial growth factor (VEGF), insulin-like growth factor-1 (IGF-1), basic fibroblast growth factor (FGF), and hepatocyte growth factor (HGF)) as well as other key molecules in promoting tissue healing (as adhesive proteins, pro-coagulant factors, cytokines, chemokines, and anti-microbial proteins [2–5]) to stimulate many biological functions, such as chemotaxis, angiogenesis, proliferation, and differentiation (**Table 1**) in order to enhance hard and soft tissue healing.

Category	Term	Biological activities
Adhesive proteins	VWF + propeptide, Fg, Fn, Vn, TSP-1, and laminin-8	Cell contact interactions, clotting, and extracellular matrix composition
Clotting factors and associated proteins	F V/Va, F XI, Gas6, protein S, HMWK, AT, and TFPI	Thrombin production and regulation and angiogenesis
Fibrinolytic factors and associated proteins	Pgn, PAI-I, u-PAm, OSN, α 2-AP, HRGP, TAFI, and α 2-M	Plasmin production and vascular modeling
Proteases and antiproteases	TIMP-4, MMP-4, inhibitor of FIX, PN-II, C1-INH, and A1AT	Angiogenesis, vascular modeling, regulation of coagulation, and regulation of cellular behavior
Growth factors, cytokines, and chemokines	PDGF, TGF β -1 and -2, EGF, IGF-1, VEGF, bFGF, FGF-2, HGF, CCL5, IL-8, MIP-1 α , CXCL5, MCP-3, ANG-1, and IL-1 β , neutrophil chemotactic protein	Chemotaxis, cell proliferation and differentiation, and angiogenesis
Basic proteins and others	PF4, β -TG, PBP, CTAP III, NAP-2, and ES	Regulation of angiogenesis, vascular modeling, and cellular interactions
Antimicrobial proteins	TC	Bactericidal and fungicidal properties
Others	CS-4, AB, and Ig	Diverse
Membrane glycoproteins	α Ib β 3, α v β 3, GPIb, PECAM-1, most plasma membrane constituents, receptors for primary agonists, CD40L, TF, and P-selection	Platelet aggregation and adhesion, endocytosis of proteins, inflammation, thrombin generation, and platelet-leukocyte interactions

Extracted and readapted from Anitua et al. [2].

Table 1. Platelet α -granule contents and their functional categories.

2. Brief history of platelet concentrates

2.1. Fibrin adhesives

More than 40 years ago, these technologies were originally used as sealant-adhesive agents in the treatment of hemorrhage with the aim of blocking the blood leakage [6]. Subsequently, other molecules involved in the coagulation process were combined to such fibrin preparations to improve their adhesive properties. These preparations were referred as “platelet-fibrinogen-thrombin mixtures” and were successfully used in ophthalmology [7, 8], general surgery [9], and neurosurgery [10]. Other authors termed them as “gel foam” [11].

It is noteworthy that the application of these preparations was essentially related to their adhesive properties and the platelets were served only to reinforce the fibrin matrix architecture. A few years later, it was developed the concept that these preparations could have healing and regenerative properties. In the late 1980s, Knighton et al. [12–14] used the autologous “Platelet-Derived Wound Healing Factors (PDWHF),” which were prepared through two-step centrifugation process, in the treatment of chronic nonhealing cutaneous ulcers. In 1997, Whitman et al. used platelet concentrate referred as “platelet gel” in oral and maxillofacial surgery [15].

2.2. Platelet-rich plasma

The term “Platelet-Rich Plasma” (PRP) was, for the first time, introduced by Kingsley et al. to describe a thrombocyte concentrate [16] used for the treatment of severe thrombopenia. However, the use of PRP term really started with Marx in 1998 [1] when he published a comparative clinical study in which the PRP regenerative potential was demonstrated in a series of patients undergoing mandibular reconstruction. Afterward, the PRP product was associated with the concept of platelet growth factors and their potential contribution to the enhancement of tissue healing.

According to the PRP protocol, the blood is collected in tubes containing anticoagulants and processed by two centrifugation steps. **Figure 1** illustrates schematically the specific protocol [17]. The final PRP product can be applied to the surgical site with a syringe or be activated by thrombin and/or calcium chloride to trigger platelet activation and to stimulate the fibrin polymerization.

After blood collection into tubes with anticoagulant, the first centrifugation at low force (soft spin) allows the separation of blood into three distinct layers: red blood cells at the bottom, a cellular plasma (platelet-poor plasma (PPP)) in the upper portion, and a whitish layer called buffy coat located between them containing the highest concentration of platelets and leukocytes. For the production of Pure-PRP (P-PRP), PPP and the superficial buffy coat layer are transferred into another tube and centrifuged at high forces (hard spin), after which most of the PPP and leukocytes are discarded and the final P-PRP can be collected. For the production of PRP rich in leukocytes (L-PRP), PPP, the entire buffy coat layer and some residual red blood cells are collected and transferred in another tube to be hard spin centrifuged. To obtain

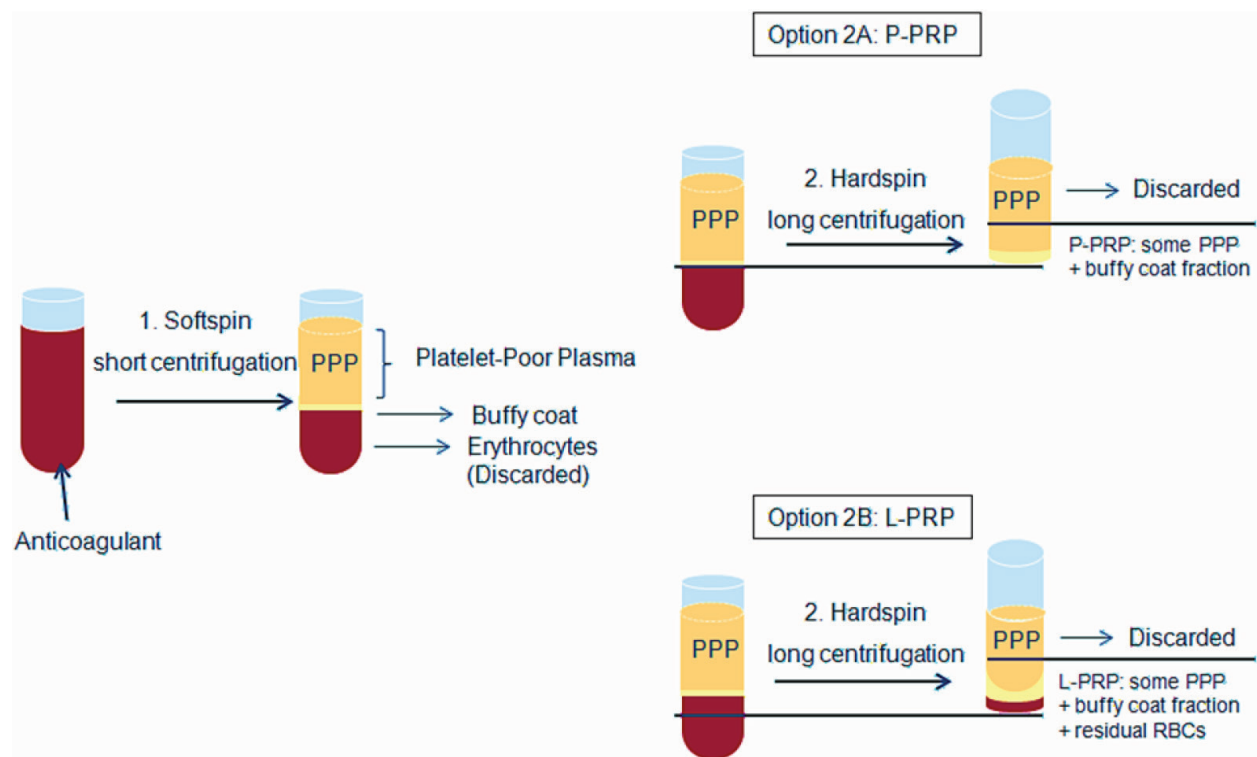


Figure 1. Protocol for PRP production.

the final L-PRP, PPP is discarded leading to an L-PRP that contains the buffy coat with most of the platelets and leukocytes, some residual red blood cells and PPP (adapted from Dohan Ehrenfest et al. [17]).

Currently, more than 20 different commercial systems for PRP preparation exist, which may lead to products with different features, especially regarding the composition and the cell concentration rate respect to baseline. On average, a 5–8× concentration is achieved though a ratio of up to 11× has been reported with PRP.

2.3. Platelet-rich fibrin

In 2001, Choukroun et al. developed a protocol for producing a hemocomponent named platelet-rich fibrin (PRF) [18]. Here, the blood is collected in tubes in the absence of anticoagulant and centrifuged with moderate forces (3000 rpm in a dedicated centrifuge) for 12 min. Afterward, three layers are formed: red blood cells and acellular plasma are located, respectively, at the bottom and at the top of the tube, and the fibrin clot, positioned between them, is PRF (**Figure 2**). Since the formation of the PRF clot naturally occurs within the tube, it has a strong fibrin matrix in which most of the platelets and leukocytes are embedded [19]. Since its introduction, PRF has undergone some development: the advanced PRF (a-PRF) was launched a few years ago, characterized by a reduced centrifugation speed and time (2700 rpm, 8–10 min), which allows a more even cell distribution within the clot [20]. Recently, the injectable PRF (i-PRF) has also been developed, which may be obtained with a further softer spin (1500 rpm, 3 min), consisting of a liquid form, very rich in white cells that can be used by infiltration into tissues and joints.

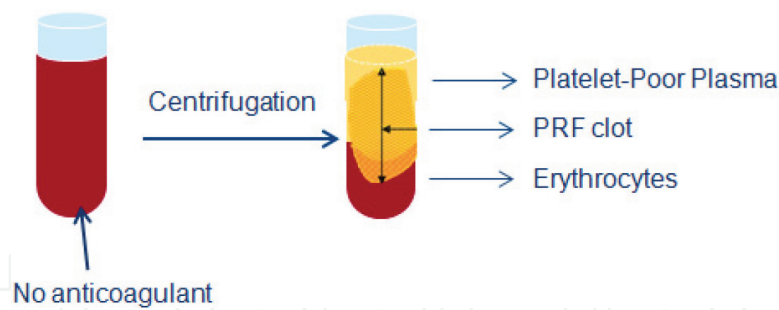


Figure 2. Protocol for PRF production. (Adapted from Dohan Ehrenfest et al. [19]).

2.4. Plasma rich in growth factors

In parallel to the introduction of PRP and PRF, Anitua in 1999 proposed another platelet concentrate protocol, denominated plasma rich in growth factors (PRGF) [21]. Briefly, blood is collected in tubes containing 0.2 ml of 3.8% trisodium citrate as anticoagulant. After a centrifugation at 580 g for 8 min, red blood cells and buffy coat layer are deposited at the bottom of the tube and the plasma component above. The latter is then manually separated into two fractions. The lower portion of about 2 ml, above the buffy coat, is the PRGF, whereas the upper portion is the plasma poor in growth factors (PPGF) (**Figure 3**). The final PRGF product may be applied as a liquid fraction to the target site or may be preactivated by adding 0.2 ml of 10% CaCl_2 to induce the clot formation [22].

2.5. Technical differences between PRGF, PRP, and PRF

PRGF differs from PRP for the following technical aspects:

1. Blood volume drawn is minimal (5–40 ml).
2. Requires a single centrifugation for the preparation.
3. Does not contain leukocytes.
4. Does not contain proinflammatory cytokines.
5. Platelet concentration is reduced (2–3 fold the baseline, respect to 5–8× for PRP).

In addition, PRGF also differs from PRF for these features:

1. Different products can be obtained (liquid, gel, membrane, and fibrin clot).
2. PRGF liquid can be combined with bone graft materials for bone regeneration procedure.

Differences between PRP and PRF are as follows:

1. PRP preparation requires two centrifugations.
2. Different products can be obtained (liquid and fibrin clot).
3. PRP liquid can be mixed with bone graft materials for bone regeneration procedures.

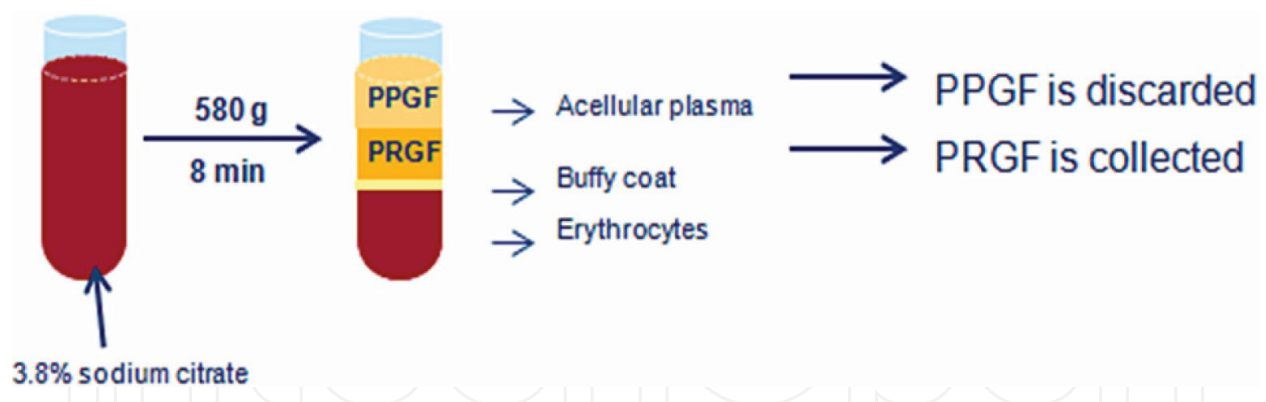


Figure 3. Process of PRGF production. Details are given in the text. (Adapted from Anitua [22]).

3. Clinical evidence of the efficacy of autologous platelet concentrates in oral regenerative surgical procedures

3.1. General aspects

In the last couple of decades, it has been observed a growing interest in the use of autologous platelet concentrates during oral regenerative surgical procedures as an adjunctive tool to enhance the hard and soft tissue healing. The following sections will summarize the recent evidence on the efficacy of autologous platelet concentrates in the dental field. The recent evidence has been obtained using a systematic review approach. The focused question was: “Does the adjunct of autologous platelet concentrate produce benefits to hard and soft tissue healing in oral surgery procedures in terms of tissue parameters, postoperative complications as well as patient’s postoperative quality of life?” In order to address the aim of this chapter, electronic searches were performed on the main scientific databases (MEDLINE, Scopus, and Cochrane Central Register of Controlled Trials). Proper search terms were used, combined by Boolean operators. Only controlled clinical trials, randomized clinical trials, and existing systematic reviews and meta-analyses of the literature were included. The outcomes were complications and adverse events, treatment success, discomfort/quality of life, bone healing and remodeling assessed by histological and radiographic techniques, and soft tissue healing. The surgical procedures taken into consideration were: tooth extraction, periodontal surgery, endodontic surgery and treatment of immature necrotic teeth, maxillary sinus augmentation, and implant treatment. When possible, a quantitative analysis was undertaken by meta-analysis approach, using the software RevMan (RevMan, Version 5.3, The Nordic Cochrane Center, The Cochrane Collaboration, Copenhagen, Denmark, 2014).

3.2. Alveolar postextraction healing

Several recent systematic reviews evaluated the efficacy of autologous platelet concentrates in enhancing alveolar socket healing after tooth extraction [23, 24]. Beneficial effects were generally reported in terms of better soft tissue healing, better clinical and histological epithelialization of wound margins, and a faster wound closure, although the heterogeneity of the data

could not allow sound meta-analyses. Regarding the bone formation, the qualitative synthesis of the histological analyses reported a better bone quality in biopsies retrieved from sites treated with platelet concentrate. Furthermore, the meta-analysis of the histomorphometric evaluation of the bone formation (including only few of the included studies) revealed that sites treated with platelet concentrate showed a statistically significant greater proportion of new bone than the controls, at 3 months of follow-up [23]. Even though the results of the meta-analysis suggest a beneficial effect of autologous platelet concentrates on bone formation, caution should be paid on interpreting such results, since the available evidence is scarce and of limited quality [23]. In spite of the relatively numerous randomized clinical studies assessing the value of APCs for enhancing postextraction socket healing, the main reason that prevents a wide meta-analysis is that the methods used for assessing bone regeneration and socket preservation are very different, providing different information that cannot be aggregated. In fact, different studies used different techniques like histological and immunohistological analysis, histomorphometric evaluation, scintigraphy, micro-TC, intraoral radiography, cone beam computed tomography, and clinical assessment, for the evaluation of different variables as percentage of new bone formation, osteoblasts activity, bone density, crestal bone level changes, ridge width and height, and soft tissues health status [23, 24]. All studies that evaluated postoperative symptoms like pain, swelling, trismus, and adverse events like dry socket, alveolitis, and acute inflammation concluded that APCs are effective in reducing symptoms and the incidence of adverse events, with an overall improvement of patients' quality of life [24]. The most recent systematic review on this topic concludes that APCs should be used in postextraction sites in order to improve clinical and radiographic outcomes such as bone density and soft tissue healing, as well as to reduce postoperative symptoms [24]. The actual benefit of APCs on decreasing of pain in extraction sockets, however, though consistently reported, is still not quantifiable [24]. In **Figure 4**, a brief sequence of pictures documenting a

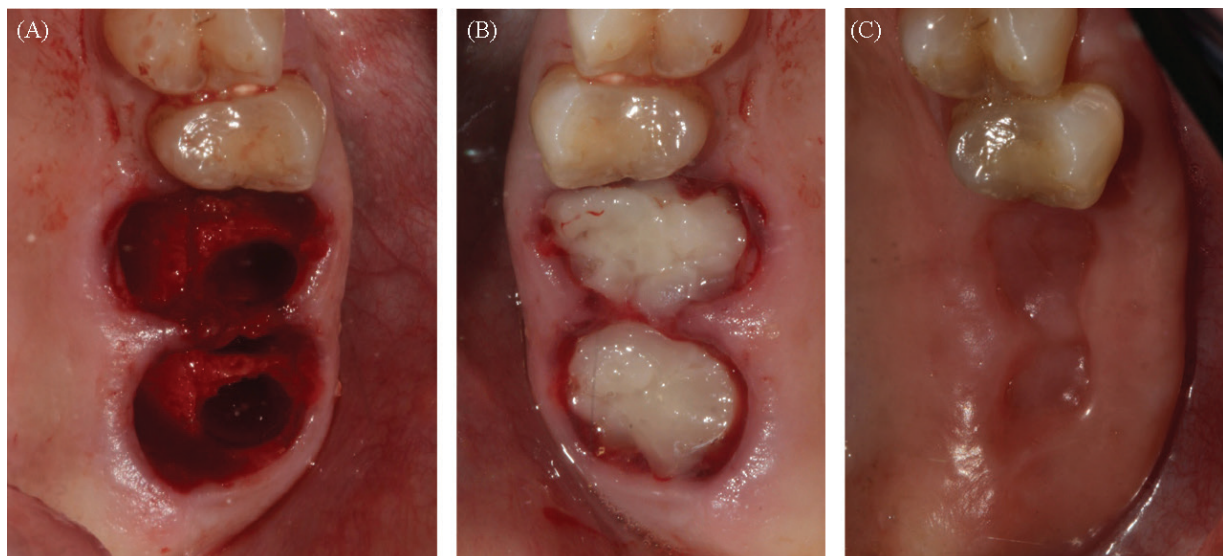


Figure 4. Double tooth extraction in the upper jaw and placement of PRGF in the extraction socket. (A) Fresh sockets after atraumatic extraction. (B) Sockets filled with PRGF clot; it can be sutured for a better stabilization. (C) 14 days after surgery: excellent healing of soft tissues is shown.

case of double extraction in the posterior upper jaw, subsequent positioning of platelet concentrate (PRGF) into extraction sockets, and the postsurgical clinical healing is shown.

3.3. Periodontal defects

Several systematic reviews and some meta-analyses evaluated the efficacy of autologous platelet concentrates in the treatment of periodontal defects, including intrabony defects, gingival recessions, and furcation defects [25–33]. Beneficial effects on clinical and radiographic outcomes in the treatment of intrabony defects were reported, although a high heterogeneity emerged among the clinical studies in terms of outcomes evaluated and bioactive agents/procedures combined with autologous platelet concentrates [25, 28, 30–32]. Furthermore, two meta-analyses [28, 30] concluded that PRP might exert positive adjunctive effects in the surgical treatment of such defects when combined with grafting materials, but no adjunctive effects were found in association with the guided tissue regeneration technique. Indeed, the latter is considered the gold standard for the treatment of periodontal intrabony defects and its use could probably mask the PRP effect. Regarding the autologous platelet concentrates' effect on gingival recessions, very few systematic reviews have been conducted, presumably due to the limited data about it. PRP or PRF did not show any clinical improvements in the treatment of gingival recessions or furcation defects [28, 33]. A Cochrane systematic review on this topic is still ongoing [34] and its results will certainly shed light on the actual evidence level regarding this topic, possibly confirming early indications of previous systematic reviews.

3.4. Endodontics and endodontic surgery

Platelet concentrates have been recently used in the clinical treatment of immature necrotic teeth, with the aim of regenerating the intracanal pulp and stimulating tooth development, as well as in the surgical treatment of teeth with apical periodontitis to enhance healing of periapical tissues. Clinical evidence on the benefits of the use of platelet concentrates in these pathologies exists but is still scarce. A recent systematic review concluded that periapical healing and apical closure were improved in those immature necrotic teeth treated with PRP compared with the control group without PRP, even though not statistically significant, and a significant better thickening of dentinal walls and root lengthening were also reported [35]. However, from the histological point of view, it seems that a true regeneration of necrotic pulp tissue of either mature or immature teeth was not achieved after using platelet concentrates. In fact, the neoformed intracanal tissues were mainly cemento-like, bone-like, and connective tissue. Root canals were repopulated with living tissue that only marginally resembled the original pulp. Despite this, the root maturation may be achieved and teeth function is not compromised [36].

Though the use of APCs in the management of periapical lesions could be considered a proper indication, very scarce studies are present regarding this topic. One randomized clinical study evaluated the postoperative quality of life in patients undergoing endodontic surgery [37]. The test group of 18 patients was treated with the adjunct of P-PRP and the control group was treated conventionally, without P-PRP. The test group showed significantly less pain and swelling, fewer analgesics taken, and improved functional activities as compared with

the control group [37]. This suggests that the adjunct of P-PRP to the endodontic surgery procedure may produce significant beneficial effect to patients' quality of life during the early postoperative period.

Another pilot clinical study on endodontic surgery compared a group of seven patients treated with the adjunct of PRF versus four control patients [38]. In addition to confirming the beneficial effects in the early postoperative period regarding significant reduction of pain and swelling, a significantly better healing of the lesion was observed after 2 and 3 months but not after 1-year follow-up [38]. This preliminary study had a very small sample size, so results should be interpreted cautiously. The latter two studies have been included in a recently published Cochrane systematic review on endodontic procedures for the retreatment of periapical defects, which concluded that there is evidence that adjunctive use of a gel of plasma rich in growth factors reduces postoperative pain compared with no grafting [39]. Regarding other possible beneficial effects of APCs in endodontic surgery, further evidence is needed.

3.5. Maxillary sinus augmentation

The use of platelet concentrates in association with grafting material during maxillary sinus augmentation procedure provided conflicting results in both preclinical and clinical studies [40, 41]. A recent meta-analysis documented that PRP combined to graft materials, in this type of surgical procedure, had no adjunctive effect on bone formation, on implant survival and implant stability as well as it did not show any statistically significant differences on marginal bone loss or alveolar bone height, compared to the bone graft alone [42]. Similar conclusions were also reported in other systematic reviews [43, 44]. However, another meta-analysis reported opposite conclusions concerning the bone formation supporting the use of PRP for sinus bone graft [45]. Furthermore, beneficial effects on soft tissue healing as well as reduction of postoperative discomfort were often reported [43]. Such variability in results could be ascribed to a number of factors. First of all, different techniques have been adopted for the preparation of platelet concentrates, leading to the products with different characteristics (final concentration of platelets and white cells, presence or absence of leukocytes, use of anticoagulants and activators, different mechanical consistence of the product, and association with different graft types) and, presumably, different biological activities. Secondly, different studies may also differ in experimental design, objectives, outcome variables, inclusion criteria, and follow-up duration. Furthermore, the sinus augmentation technique, though representing a very popular model for the assessment of bone substitutes for bone regeneration, suffers from a number of confounding factors that make standardization difficult, like patient age, residual bone quality and quantity, smoking habits, volume of graft used, porosity and general features of the graft material (e.g., intraoral or extraoral autografts, allografts, xenografts, and alloplasts), graft resorbability over time, graft healing time, and intra- and postsurgical complications like membrane perforation, infection, expertise of the clinician, techniques adopted for evaluating bone formation, including the position of the biopsy (crestal or lateral). Finally, if one aims at evaluating the effect of APCs on implant survival and success in the maxillary sinus augmentation, a number of additional factors concerning the implants and the prosthetic reconstruction must be considered, e.g., implant length

and width, shape, surface micro- and nano-geometry, type of implant-abutment connection, implant primary stability, and number and position of the implants. In fact, it is well known that implant survival in the augmented maxillary sinus is more variable than that of implants placed in the posterior maxilla.

A randomized clinical trial evaluating the effect of P-PRP adjunct on postoperative quality of life of patients undergoing maxillary sinus augmentation procedure, found a beneficial effect of P-PRP regarding pain, swelling, hematoma, and other postoperative symptoms, improving patient's acceptance of this often demanding procedure [46].

3.6. Implant dentistry

As it is claimed that platelet concentrates may promote bone regeneration, several animal studies have been conducted to assess the PRP effect on the osseointegration process, through histological and histomorphometrical evaluation, but controversial results have been reported. In fact, some studies did not demonstrate any advantages of PRP over non-PRP control groups at stimulating faster bone formation or higher bone-implant contact [47–49]. By contrast, histomorphometric analyses of the bone-implant interface in the early healing phase after implantation (6 or 8 weeks) revealed a significantly higher percentage of bone-implant contact in implants coated with liquid PRP formulation compared to those not PRP-bioactivated [50–52]. In addition to being time dependent, PRP effect is also site dependent since its effect has been reported to decrease with increasing distance from the site of application [52]. Similarly, liquid-PRP showed a tendency to increase the bone apposition to roughened titanium implants during early healing phase [53, 54].

Clinical studies reported a higher bone formation around the implants [55] and a good preservation of the alveolar crest around postextraction implants [56, 57] when APCs were used.

APCs have been also combined with several different types of grafting materials during regenerative procedures associated with implantoprosthesis rehabilitations, showing satisfying results and positive patient-related outcomes [58–61]. A long-term clinical study (10–12 years) on short implant placement in association with PRGF reported an implant survival rate of 98.9% and marginal bone loss inferior to 1 mm [62].

3.7. Systemically compromised patients

Patients affected by chronic systemic conditions like osteoporosis, cancer, diabetes type I or II, immunodeficiency, hematological/coagulation defects, and other conditions, often present difficulty in healing even after simple surgical procedures, like the extraction of a tooth. Therefore, the use of a safe tool that may enhance the healing process in a natural way may represent a remarkable benefit for these patients.

A few studies have been published on the use of platelet concentrates in systemically compromised patients, most of them are regarding postextraction healing. Some examples will be reported.

3.8. Diabetes

In a split-mouth study in 34 patients with diabetes mellitus candidate to bilateral tooth extraction of a total of 127 teeth, alveolar sockets on the test side were treated with P-PRP and on the control side they were left to heal in a natural way [63]. The P-PRP group showed a significantly better healing (evaluated through the Healing Index) and a faster closure of the alveolus (by evaluation of the residual socket volume) at 3 and 7 days after extraction, as compared to the control group [63]. The authors concluded that platelet growth factors stimulate a faster epithelialization, protecting the alveolus in early healing steps. Hence, it is avoided occurrence of alveolitis, very common in diabetic patients following tooth extraction.

3.9. Irradiated patients

In a split-mouth study on 20 patients that underwent radiotherapy for head and neck cancer, and candidate to bilateral tooth extraction, alveolar sockets on the directly irradiated side were treated with P-PRP (test group) and on the untreated side they were left to heal in a natural way (control group) [64]. Twenty-four bilateral extractions were performed in the mandible and 33 in the maxilla for a total of 114 extractions. The P-PRP group showed a significantly better healing, in terms of Healing Index and residual socket volume at each follow-up (7, 14, and 21 days), as compared to the control group. Patients were followed up to 24 months after surgery. In the control group, two cases with bone exposure were retreated with P-PRP and subsequently healed [64].

3.10. Osteoradionecrosis (ORN)

In a series of 10 patients who developed osteoradionecrosis, debridement of necrotic bone (performed with ultrasonic instruments) was associated with the adjunct of P-PRP. All patients successfully healed, with no intraoperative or postoperative complications up to 12 months of follow-up [65]. Tissue regeneration and closure was excellent, and postoperative pain, assessed through visual analogue score (VAS) scores, was low. In spite of the absence of a control group, this study suggested that P-PRP may be beneficial as an adjunct to surgical treatment of ORN, for predictable enhancement of tissue vascularization and epithelialization in patients with a history of head and neck radiotherapy.

3.11. Coagulation defects

A case-control study was performed on 66 patients affected by severe thrombocytopenia ($<50,000$ platelets/ μL) and in need for at least two tooth extraction each [66]. For these patients, postoperative bleeding represents an important issue. Teeth were extracted in two consecutive interventions. In one intervention, the patients received a platelet transfusion before extraction (systemic treatment) and in the other session, the postalveolar sockets were filled with P-PRP (local treatment). Patients were evaluated frequently in the first 7 days after extraction. The group treated locally with P-PRP showed a statistically significant reduction in postoperative bleeding, hematoma, and need for reintervention, as compared to the group receiving a systemic infusion of platelets [66]. Therefore, P-PRP in postalveolar sockets may strongly

reduce the risk of hemorrhage and related complications in thrombocytopenic patients, due to the ability of stimulating healing and its hemostatic properties.

3.12. Bisphosphonate-related osteonecrosis of the jaws

Recently renamed medication-related osteonecrosis of the jaw (MRONJ), it is an adverse drug reaction consisting of progressive bone destruction in the maxillofacial region of patients under current or previous treatment with a bisphosphonate or another antiresorptive or antiangiogenic drug. Since APCs demonstrated to enhance bone and soft tissue healing in oral surgery procedures, it is reasonable to believe that they might provide benefits to these patients. A recent systematic review included 18 studies, reporting on 362 patients undergoing oral surgery in combination with APCs [67]. The adjunct of APC in the surgical treatment of necrotic bone removal significantly reduced osteonecrosis recurrence as compared to control (**Figure 5**). APC was associated with a reduced, though not significant, incidence of BRONJ after tooth extraction. Heterogeneity among studies was found regarding bisphosphonate type, clinical indication, administration route, treatment duration, triggering factors, study design, follow-up duration, type of APC, and outcomes adopted to evaluate treatment success [67]. Though the results of this review must be cautiously interpreted, since they are based on low evidence level studies, with limited sample size, they are suggestive of possible beneficial effects of APC when associated with surgical procedures for treatment or prevention of BRONJ. To confirm such indication, prospective comparative studies with a large sample size are urgently needed. Another subsequent systematic review on the same topic substantially confirmed these results, highlighting the need for well-done evidence-based comparative studies [68].

3.13. Implants in patients assuming bisphosphonates

In a multicenter study on a cohort of 235 middle-aged osteoporotic women under bisphosphonates therapy, the outcome of a total of 1267 implants was evaluated after a minimum follow-up of 24 months [69]. The implants were always placed in combination with P-PRP, used as a coating over implant surface at insertion (**Figure 6**). The main outcomes (adverse

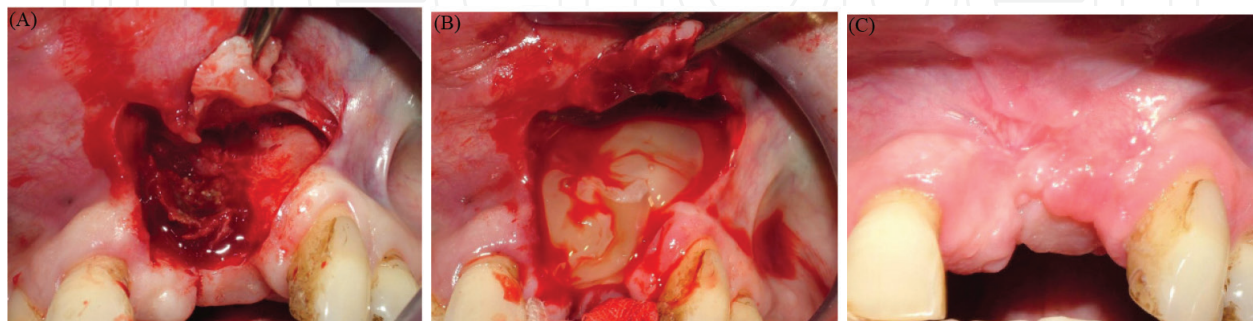


Figure 5. (A) A case of an oncologic patient under bisphosphonate affected by osteonecrosis of the upper jaw, undergoing respective surgery for removal of the necrotic bone. (B) PRGF is placed within the region involved from resection. (C) One year after surgery, the region is completely healed.

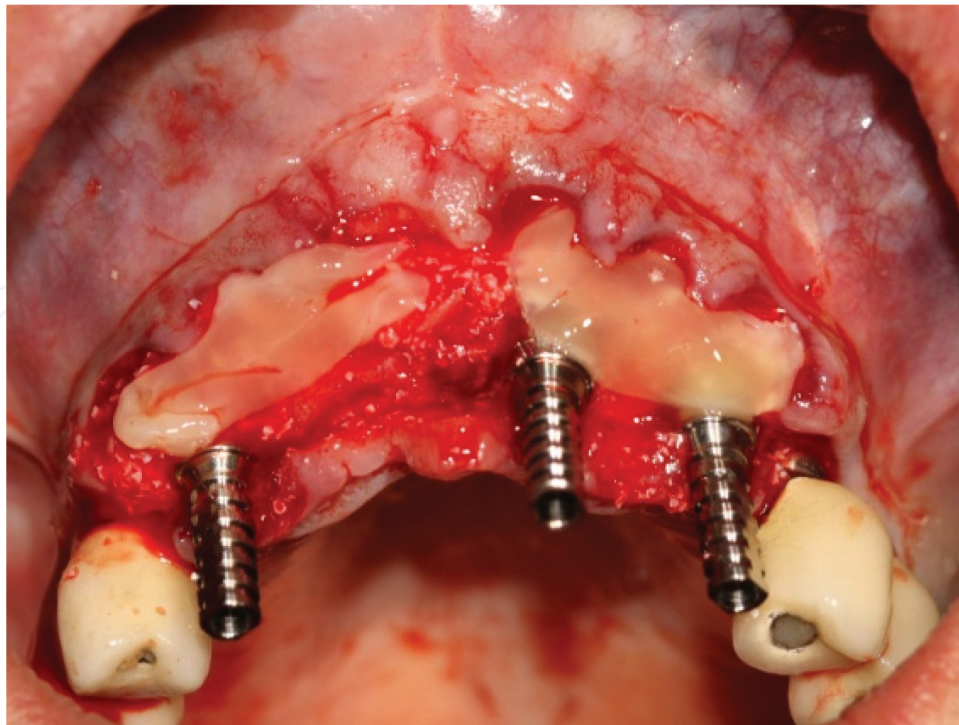


Figure 6. Multiple implant placements in an osteoporotic woman under bisphosphonates. PRGF membrane was used to cover the region involved from implant surgery.

events) were implant failure and incidence of osteonecrosis of the jaw (ONJ). Sixteen implants were lost in 16 patients up to 120 months after placement, representing a survival of 98.7% on an implant basis and 93.2% on a patient basis [69] No cases of ONJ occurred. The results are perfectly in line with those of healthy patients.

Overall, the above results suggest that the use of procedures aimed at enhancing tissue healing, such as autologous platelet concentrates, may produce relevant benefits in patients at risk due to their compromised systemic condition and should be recommended.

4. Conclusion

The use of autologous platelet concentrates generally produced beneficial effects, though the level of evidence differs among various surgical procedures. In postextraction sockets and periodontal intrabony defects, the advantage of using APCs, both alone and combined with bone substitutes, is well documented by a number of randomized clinical studies. In maxillary sinus augmentation, controversial outcomes exist, due to few published controlled studies. Also, in endodontic surgery and implant treatment, there is a paucity of evidence-based studies, even though all show beneficial effects of APC. The variability among protocols and outcomes in different studies often prevents the possibility of performing meta-analysis and is thought to be related to the controversial results sometimes observed. Better soft tissue healing, improved patients' quality of life and reduced incidence of adverse events and

complications are systematically reported when using APC. In conclusion, the use of such autologous products is recommended for improving predictability and patients' acceptance of treatment in oral surgery procedures.

Author details

Carmen Mortellaro^{1*} and Massimo Del Fabbro^{2,3}

*Address all correspondence to: carmen.mortellaro@med.uniupo.it

1 Department of Health Sciences, Avogadro University of Eastern Piedmont, Novara, Italy

2 Department of Biomedical, Surgical and Dental Sciences, Università degli Studi di Milano, Milano, Italy

3 IRCCS Istituto Ortopedico Galeazzi, Milano, Italy

References

- [1] Marx RE, Carlson ER, Eichstaedt RM, Schimmele SR, Strauss JE, Georgeff KR. Platelet-rich plasma: Growth factor enhancement for bone grafts. *Oral Surgery, Oral Medicine, Oral Pathology, Oral Radiology, and Endodontology*. 1998;**85**:638-646
- [2] Anitua E, Andia I, Ardanza B, et al. Autologous platelets as a source of proteins for healing and tissue regeneration. *Thrombosis and Haemostasis*. 2004;**91**:4-15
- [3] Alsousou J, Thompson M, Hulley P, et al. The biology of platelet-rich plasma and its application in trauma and orthopaedic surgery: A review of the literature. *Journal of Bone and Joint Surgery. British Volume*. 2009;**91**:987-996
- [4] Boswell SG, Cole BJ, Sundman EA, et al. Platelet-rich plasma: A milieu of bioactive factors. *Arthroscopy*. 2012;**28**:429-439
- [5] Pelletier MH, Malhotra A, Brighton T, et al. Platelet function and constituents of platelet rich plasma. *International Journal of Sports Medicine*. 2013;**34**:74-80
- [6] Matras H. Effect of various fibrin preparations on reimplantations in the rat skin. *Osterreichische Zeitschrift fur Stomatologie*. 1970;**67**:338-359
- [7] Rosenthal AR, Harbury C, Egbert PR, Rubenstein E. Use of a platelet-fibrinogen-thrombin mixture as a corneal adhesive: Experiments with sutureless lamellar keratoplasty in the rabbit. *Investigative Ophthalmology*. 1975;**14**:872-875
- [8] Rosenthal AR, Egbert PR, Harbury C, Hopkins JL, Rubenstein E. Use of platelet-fibrinogen-thrombin mixture to seal experimental penetrating corneal wounds. *Albrecht von Graefe's archive for clinical and experimental ophthalmology*. 1978;**207**:111-115

- [9] Pearl RM, Wustrack KO, Harbury C, Rubenstein E, Kaplan EN. Microvascular anastomosis using a blood product sealant-adhesive. *Surgery, Gynecology & Obstetrics*. 1977;**144**: 227-231
- [10] Silverberg GD, Harbury CB, Rubenstein E. A physiological sealant for cerebrospinal fluid leaks. *Journal of Neurosurgery*. 1977;**46**:215-219
- [11] Fischer H. A method of suture-free anastomosis of nerve transplantation is being reported, using facial nerve as the example (author's transl). *Laryngologie, Rhinologie, Otologie*. 1979;**58**:154-156
- [12] Knighton DR, Ciresi KF, Fiegel VD, Austin LL, Butler EL. Classification and treatment of chronic nonhealing wounds. Successful treatment with autologous platelet-derived wound healing factors (PDWHF). *Annals of Surgery*. 1986;**204**:322-330
- [13] Knighton DR, Doucette M, Fiegel VD, Ciresi K, Butler E, Austin L. The use of platelet derived wound healing formula in human clinical trials. *Progress in Clinical and Biological Research*. 1988;**266**:319-329
- [14] Knighton DR, Ciresi K, Fiegel VD, Schumerth S, Butler E, Cerra F. Stimulation of repair in chronic, nonhealing, cutaneous ulcers using platelet-derived wound healing formula. *Surgery, Gynecology & Obstetrics*. 1990;**170**:56-60
- [15] Whitman DH, Berry RL, Green DM. Platelet gel: An autologous alternative to fibrin glue with applications in oral and maxillofacial surgery. *Journal of Oral and Maxillofacial Surgery*. 1997;**55**:1294-1299
- [16] Kingsley CS. Blood coagulation; evidence of an antagonist to factor VI in platelet-rich human plasma. *Nature*. 1954;**173**:723-734
- [17] Dohan Ehrenfest DM, Rasmusson L, Albrektsson T. Classification of platelet concentrates: From pure platelet-rich plasma (P-PRP) to leucocyte- and platelet-rich fibrin (L-PRF). *Trends in Biotechnology*. 2009;**27**:158-167
- [18] Choukroun J, Adda F, Schoeffler C, Vervelle A. Une opportunité en paro-implantologie: Le PRF. *Implantodontie*. 2001;**42**:55-62
- [19] Dohan Ehrenfest DM, Del Corso M, Diss A, Mouhyi J, Charrier JB. Three-dimensional architecture and cell composition of a Choukroun's platelet-rich fibrin clot and membrane. *Journal of Periodontology*. 2010;**81**:546-555
- [20] Ghanaati S, Booms P, Orlowska A, Kubesch A, Lorenz J, Rutkowski J, Landes C, Sader R, Kirkpatrick CJ, Choukroun J. Advanced platelet-rich fibrin: A new concept for cell-based tissue engineering by means of inflammatory cells. *Journal of Oral Implantology*. 2014;**40**:679-689
- [21] Anitua E. Plasma rich in growth factors: Preliminary results of use in the preparation of sites for implants. *The International Journal of Oral & Maxillofacial Implants*. 1999;**14**:529-535

- [22] Anitua E. The use of plasma-rich growth factors (PRGF) in oral surgery. *Practical Procedures & Aesthetic Dentistry*. 2001;**13**:487-493
- [23] Del Fabbro M, Corbella S, Taschieri S, Francetti L, Weinstein R. Autologous platelet concentrate for post-extraction socket healing: A systematic review. *European Journal of Oral Implantology*. 2014;**7**:333-344
- [24] Del Fabbro M, Bucchi C, Lolato A, Corbella S, Testori T, Taschieri S. Healing of postextraction sockets preserved with autologous platelet concentrates. A systematic review and meta-analysis. *Journal of Oral and Maxillofacial Surgery*. 2017. <http://dx.doi.org/10.1016/j.joms.2017.02.009>
- [25] Plachokova AS, Nikolidakis D, Mulder J, Jansen JA, Creugers NH. Effect of platelet-rich plasma on bone regeneration in dentistry: A systematic review. *Clinical Oral Implants Research*. 2008;**19**:539-545
- [26] Martínez-Zapata MJ, Martí-Carvajal A, Solà I, Bolibar I, Angel Expósito J, Rodríguez L, García J. Efficacy and safety of the use of autologous plasma rich in platelets for tissue regeneration: A systematic review. *Transfusion*. 2009;**49**:44-56
- [27] Kotsovilis S, Markou N, Pepelassi E, Nikolidakis D. The adjunctive use of platelet-rich plasma in the therapy of periodontal intraosseous defects: A systematic review. *Journal of Periodontal Research*. 2010;**45**:428-443
- [28] Del Fabbro M, Bortolin M, Taschieri S, Weinstein R. Is platelet concentrate advantageous for the surgical treatment of periodontal diseases? A systematic review and meta-analysis. *Journal of Periodontology*. 2011;**82**:1100-1111
- [29] Del Fabbro M, Ceci C, Taschieri T. Systematic review on the effect of platelet concentrates for the surgical treatment of periodontal defects. *Dental Cadmos*. 2013;**81**:138-145
- [30] Panda S, Doraiswamy J, Malaiappan S, Varghese SS, Del Fabbro M. Additive effect of autologous platelet concentrates in treatment of intrabony defects: A systematic review and meta-analysis. *Journal of Investigative and Clinical Dentistry*. 2014;**5**:1-14
- [31] Shah M, Deshpande N, Bharwani A, Nadig P, Doshi V, Dave D. Effectiveness of autologous platelet-rich fibrin in the treatment of intra-bony defects: A systematic review and meta-analysis. *Journal of Indian Society of Periodontology*. 2014;**18**:698-704
- [32] Roselló-Camps À, Monje A, Lin GH, Khoshkam V, Chávez-Gatty M, Wang HL, Gargallo-Albiol J, Hernandez-Alfaro F. Platelet-rich plasma for periodontal regeneration in the treatment of intrabony defects: A meta-analysis on prospective clinical trials. *Oral Surgery, Oral Medicine, Oral Pathology and Oral Radiology*. 2015;**120**:562-574
- [33] Moraschini V, Barboza Edos S. Use of platelet-rich fibrin membrane in the treatment of gingival recession: A systematic review and meta-analysis. *Journal of Periodontology*. 2016;**87**:281-290
- [34] Del Fabbro M, Panda S, Jayakumar ND, Sankari M, Varghese S, Ramamoorthi S, Ceci C, Ceresoli V, Taschieri S. Autologous platelet concentrates for treatment of periodontal

defects (Protocol). Cochrane Database of Systematic Reviews. 2014;(12). Art.No.: CD011423. DOI: 10.1002/14651858.CD011423

- [35] Lolato A, Bucchi C, Taschieri S, Kabbaney AE, Fabbro MD. Platelet concentrates for revitalization of immature necrotic teeth: A systematic review of the literature of the clinical studies. *Platelets*. 2016;**27**:383-392
- [36] Del Fabbro M, Lolato A, Bucchi C, Taschieri S, Weinstein RL. Autologous platelet concentrates for pulp and dentin regeneration: A literature review of animal studies. *Journal of Endodontics*. 2016;**42**:250-257
- [37] Del Fabbro M, Ceresoli V, Lolato A, Taschieri S. Effect of platelet concentrate on quality of life after periradicular surgery: A randomized clinical study. *Journal of Endodontics*. 2012;**38**:733-739
- [38] Angerame D, De Biasi M, Kastrioti I, Franco V, Castaldo A, Maglione M. Application of platelet-rich fibrin in endodontic surgery: A pilot study. *Giornale Italiano di Endodonzia*. 2015;**29**:51-57
- [39] Del Fabbro M, Corbella S, Sequeira-Byron P, Tsisis I, Rosen E, Lolato A, Taschieri S. Endodontic procedures for retreatment of periapical lesions. Cochrane Database of Systematic Reviews. 2016;(10). Art. No.: CD005511. DOI: 10.1002/14651858.CD005511.pub3
- [40] Choi BH, Im CJ, Huh JY, Suh JJ, Lee SH. Effect of platelet-rich plasma on bone regeneration in autogenous bone graft. *International Journal of Oral and Maxillofacial Surgery*. 2004;**33**:56-59
- [41] Thor A, Franke-Stenport V, Johansson CB, Rasmusson L. Early bone formation in human bone grafts treated with platelet-rich plasma: Preliminary histomorphometric results. *International Journal of Oral and Maxillofacial Surgery*. 2007;**36**:1164-1171
- [42] Lemos CA, Mello CC, dos Santos DM, Verri FR, Goiato MC, Pellizzer EP. Effects of platelet-rich plasma in association with bone grafts in maxillary sinus augmentation: A systematic review and meta-analysis. *International Journal of Oral and Maxillofacial Surgery*. 2016;**45**:517-525
- [43] Del Fabbro M, Bortolin M, Taschieri S, Weinstein RL. Effect of autologous growth factors in maxillary sinus augmentation: A systematic review. *Clinical Implant Dentistry and Related Research*. 2013;**15**:205-216
- [44] Rickert D, Slater JJ, Meijer HJ, Vissink A, Raghoobar GM. Maxillary sinus lift with solely autogenous bone compared to a combination of autogenous bone and growth factors or (solely) bone substitutes. A systematic review. *International Journal of Oral and Maxillofacial Surgery*. 2012;**41**:160-167
- [45] Bae JH, Kim YK, Myung SK. Effects of platelet-rich plasma on sinus bone graft: Meta-analysis. *Journal of Periodontology*. 2011;**82**:660-667
- [46] Del Fabbro M, Corbella S, Ceresoli V, Ceci C, Taschieri S. Plasma rich in growth factors improves patients' postoperative quality of life in maxillary sinus floor augmentation:

- Preliminary results of a randomized clinical study. *Clinical Implant Dentistry and Related Research*. 2015;**17**:708-716
- [47] Streckbein P, Kleis W, Buch RS, Hansen T, Weibrich G. Bone healing with or without platelet-rich plasma around four different dental implant surfaces in beagle dogs. *Clinical Implant Dentistry and Related Research*. 2014;**16**:479-486
- [48] Thor AL, Hong J, Kjeller G, Sennerby L, Rasmusson L. Correlation of platelet growth factor release in jawbone defect repair-a study in the dog mandible. *Clinical Implant Dentistry and Related Research*. 2013;**15**:759-768
- [49] Weibrich G, Hansen T, Kleis W, Buch R, Hitzler WE. Effect of platelet concentration in platelet-rich plasma on peri-implant bone regeneration. *Bone*. 2004;**34**:665-671
- [50] Anitua EA. Enhancement of osseointegration by generating a dynamic implant surface. *Journal of Oral Implantology*. 2006;**32**:72-76
- [51] Anitua E, Orive G, Pla R, Roman P, Serrano V, Andía I. The effects of PRGF on bone regeneration and on titanium implant osseointegration in goats: A histologic and histomorphometric study. *Journal of Biomedical Materials Research Part A*. 2009;**91**:158-165
- [52] Zechner W, Tangl S, Tepper G, Fürst G, Bernhart T, Haas R, Mailath G, Watzek G. Influence of platelet-rich plasma on osseous healing of dental implants: A histologic and histomorphometric study in mini pigs. *The International Journal of Oral & Maxillofacial Implants*. 2003;**18**:15-22
- [53] Nikolidakis D, van den Dolder J, Wolke JG, Stoelinga PJ, Jansen JA. The effect of platelet-rich plasma on the bone healing around calcium phosphate-coated and non-coated oral implants in trabecular bone. *Tissue Engineering*. 2006;**12**:2555-2563
- [54] Nikolidakis D, van den Dolder J, Wolke JG, Jansen JA. Effect of platelet-rich plasma on the early bone formation around Ca-P-coated and non-coated oral implants in cortical bone. *Clinical Oral Implants Research*. 2008;**19**:207-213
- [55] Georgakopoulos I, Tsantis S, Georgakopoulos P, Korfiatis P, Fanti E, Martelli M, Costaridou L, Petsas T, Panayiotakis G, Martelli FS. The impact of platelet rich plasma (PRP) in osseointegration of oral implants in dental panoramic radiography: Texture based evaluation. *Clinical Cases in Mineral and Bone Metabolism*. 2014;**11**:59-66
- [56] Kutkut A, Andreana S, Monaco Jr E. Clinical and radiographic evaluation of single-tooth dental implants placed in grafted extraction sites: A one-year report. *Journal of the International Academy of Periodontology*. 2013;**15**:113-124
- [57] Rosano G, Taschieri S, Del Fabbro M. Immediate postextraction implant placement using plasma rich in growth factors technology in maxillary premolar region: A new strategy for soft tissue management. *Journal of Oral Implantology*. 2013;**39**:98-102
- [58] Anitua E, Alkhraisat MH, Miguel-Sánchez A, Orive G. Surgical correction of horizontal bone defect using the lateral maxillary wall: Outcomes of a retrospective study. *Journal of Oral and Maxillofacial Surgery*. 2014;**72**:683-693

- [59] Jeong SM, Lee CU, Son JS, Oh JH, Fang Y, Choi BH. Simultaneous sinus lift and implantation using platelet-rich fibrin as sole grafting material. *Journal of Cranio-Maxillofacial Surgery*. 2014;**42**:990-994
- [60] Tajima N, Ohba S, Sawase T, Asahina I. Evaluation of sinus floor augmentation with simultaneous implant placement using platelet-rich fibrin as sole grafting material. *Journal of Oral and Maxillofacial Surgery*. 2013;**28**:77-83
- [61] Taschieri S, Corbella S, Del Fabbro M. Mini-invasive osteotome sinus floor elevation in partially edentulous atrophic maxilla using reduced length dental implants: Interim results of a prospective study. *Clinical Implant Dentistry and Related Research*. 2014;**16**:185-193
- [62] Anitua E, Piñas L, Begoña L, Orive G. Long-term retrospective evaluation of short implants in the posterior areas: Clinical results after 10-12 years. *Journal of Clinical Periodontology*. 2014;**41**:404-411
- [63] Mozzati M, Gallesio G, di Romana S, Bergamasco L, Pol R. Efficacy of plasma-rich growth factor in the healing of postextraction sockets in patients affected by insulin-dependent diabetes mellitus. *Journal of Oral and Maxillofacial Surgery*. 2014;**72**:456-462
- [64] Mozzati M, Gallesio G, Gassino G, Palomba A, Bergamasco L. Can plasma rich in growth factors improve healing in patients who underwent radiotherapy for head and neck cancer? A split-mouth study. *Journal of Craniofacial Surgery*. 2014;**25**:938-943
- [65] Gallesio G, Del Fabbro M, Pol R, Mortellaro C, Mozzati M. Conservative treatment with plasma rich in growth factors-Endoret for osteoradionecrosis. *Journal of Craniofacial Surgery*. 2015;**26**:731-736
- [66] Cocero N, Mozzati M, Bergamasco L. Oral surgery in severe thrombocytopenia patients: A case-control comparison of platelet concentrate versus platelet transfusion. *Indian Journal of Dental Research*. 2012;**2**:27-32
- [67] Del Fabbro M, Gallesio G, Mozzati M. Autologous platelet concentrates for bisphosphonate-related osteonecrosis of the jaw treatment and prevention. A systematic review of the literature. *European Journal of Cancer*. 2015;**51**:62-74
- [68] Lopez-Jornet P, Sanchez-Perez A, Amaral Mendes R, Tobias A. Medication-related osteonecrosis of the jaw: Is autologous platelet concentrate application effective for prevention and treatment? A systematic review. *Journal of Cranio-Maxillofacial Surgery*. 2016;**44**:1067-1072
- [69] Mozzati M, Arata V, Giacomello M, Del Fabbro M, Gallesio G, Mortellaro C, Bergamasco L. Failure risk estimates after dental implants placement associated with plasma rich in growth factor-Endoret in osteoporotic women under bisphosphonate therapy. *Journal of Craniofacial Surgery*. 2015;**26**:749-755

