

We are IntechOpen, the world's leading publisher of Open Access books Built by scientists, for scientists

6,900

Open access books available

186,000

International authors and editors

200M

Downloads

Our authors are among the

154

Countries delivered to

TOP 1%

most cited scientists

12.2%

Contributors from top 500 universities



WEB OF SCIENCE™

Selection of our books indexed in the Book Citation Index
in Web of Science™ Core Collection (BKCI)

Interested in publishing with us?
Contact book.department@intechopen.com

Numbers displayed above are based on latest data collected.
For more information visit www.intechopen.com



Intratympanic Drug Delivery for Tinnitus Treatment

Monique Antunes De Souza Chelminski Barreto,
Alleluia Lima Losno Ledesma,
Marlene Escher Boger and
Carlos Augusto Costa Pires De Oliveira

Additional information is available at the end of the chapter

<http://dx.doi.org/10.5772/intechopen.69664>

Abstract

Objective: The aim of the study to evaluate the effectiveness of oral and injection intratympanic methylprednisolone to treat acute tinnitus associated with idiopathic sudden sensorineural hearing loss.

Study design: Analytical, prospective and longitudinal study.

Setting: Brasilia Institute of Otorhinolaryngology.

Subjects and methods: Twenty-three subjects with acute tinnitus and idiopathic sudden sensorineural hearing loss, 13 treated with oral steroids only (Group 1) and 10 treated with methylprednisolone intratympanic injection as rescue therapy (Group 2), and evaluated by audiometry, otoacoustic emission, tinnitus handicap inventory (THI) and visual analog scale (VAS) to assess the degree of tinnitus annoyance, before treatment and after 3 months.

Results: The annoyance due to tinnitus resulted in a mean VAS of 7.69 in the beginning of treatment and 5.15 3 months after treatment (Group 1), and 8.30 at the beginning and 6.00 3 months later (Group 2). In THI, average was 64.77 points at the beginning of treatment and 49.92 points 3 months later (Group 1) and 72.20 points at the beginning and 51.60 points after 3 months (Group 2). The results of audiometry and otoacoustic emissions showed significant improvement in both groups with significant differences intragroups before and after, but not between the groups.

Conclusion: The results suggest that both oral and injection intratympanic methylprednisolone are effective treatment for acute tinnitus associated with idiopathic sudden sensorineural hearing loss in these patients.

Keywords: tinnitus, idiopathic sudden sensorineural hearing loss, treatment, intratympanic, corticosteroids

1. Introduction

Tinnitus is a complex disorder and is presented as a hearing sensation, which is not associated with an external sound stimulus [1]. It probably arises initially in the cochlea and later reaches higher structures of the auditory system where it becomes sometimes very annoying (severe disabling tinnitus—SDT).

One study showed 10 patients with “predominantly cochlear tinnitus” treated using intratympanic dexamethasone injections and described 5 patients with tinnitus control for at least 1 year [2]. They did not use a control group.

The effectiveness of intratympanic dexamethasone injections as a treatment for SDT was studied [3]. A control group was treated with saline solution and a study group with dexamethasone solution, both using intratympanic injections. There was no statistic significant difference between saline and dexamethasone solution regarding tinnitus improvement measured with visual analog scale (VAS). They concluded that intratympanic injections of steroids are not effective for the treatment of chronic SDT.

For acute tinnitus, interventions such as intratympanic AM-101 (a cochlear N-methyl-D-aspartate receptor antagonist) were tested. However, there is insufficient evidence to support the safety and efficacy of this intervention [4]. A second phase study was carried out, randomized, and placebo controlled using AM-101 intratympanic injections and concluded that the duration of symptoms affected the cure rate of intratympanic therapy for acute subjective tinnitus [5].

The management of subjective tinnitus associated with idiopathic sudden sensorineural hearing loss (ISSHL) includes oral, intravenous, and/or intratympanic administration of corticosteroids as initial therapy [6]. Intratympanic corticosteroids were effective for the treatment of idiopathic sudden sensorineural hearing loss (ISSHL) in controlled trials when used as primary therapy [7] or as rescue therapy after failure of initial oral steroids therapy [6].

The sudden sensorineural hearing loss (SSHL) is a hearing loss of at least 30 dB at three consecutive frequencies occurring in the period of 3 days or less [8] may occur in frequencies and intensities varying from a mild hearing loss to a total loss of hearing [9, 10].

SSHL is often accompanied by tinnitus and there are few theories trying to explain its mechanism. One of them associates this symptom to a maladaptive attempt at cortical reorganization process due to peripheral deafferentation [7].

Many of these patients with tinnitus and SHL remain with residual buzz even if the treatment for SHL has been effective. The treatment of sudden sensorineural hearing loss is based on its etiology. In idiopathic sudden sensorineural hearing loss (ISSHL), the oral corticosteroids are widely used, although the supporting evidence is weak. Injection intratympanic dexamethasone has been tried in patients with idiopathic sudden sensorineural hearing loss because it provides a high concentration of steroids in the labyrinth in animal models [8]. In addition, there are several advantages to intratympanic treatment. The procedure is well tolerated, relatively easy to perform as outpatient. Most patients understand the concept of intratympanic treatment and easily accept this therapy [3].

The questions we try to ask in this paper are as follows:

1. Are steroids intratympanic injections effective in the treatment of acute tinnitus? (As in ISSHL).
2. If so, what explains the fact it is not effective to treat chronic SDT?

2. Methods

The study protocol and procedures were approved by the Research Ethics Committee (REC) University of Brasilia (Opinion number 132/2012). All patients received information about the risks and expectations of therapy and signed a free informed consent form (FICF) accepting their participation in the study.

This is an analytical, prospective and longitudinal study, and the data were analyzed between January (2014) and June (2015).

Patients with middle ear diseases; presence of air type tympanogram, Ad, Ar, B, or C; prior ear surgery; signs of acute or chronic otitis media; history of Meniere's syndrome or fluctuating hearing; and history of prior sensorineural hearing loss were excluded (**Figure 1**).

From the initial sample of 38 patients with acute tinnitus and idiopathic sudden hearing loss, 23 were enrolled, 13 in the oral steroid therapy group (Group 1/oral therapy) and 10 in the intratympanic corticosteroids group after failure of oral therapy (Group 2/rescue therapy).

Tinnitus handicap inventory (THI) [11] and visual analog scale (VAS) were used for evaluation of tinnitus annoyance. For audiological assessment, tonal and vocal audiometry were used. (Diagnostic audiometer Madson Itera II) and for distortion products otoacoustic emission (DPOAE) measurements OtoRead Portable Interacoustic device was used.

A detailed clinical history was taken, followed by an otoneurological examination and audiological assessment by tonal and vocal audiometry. DPOAE measurements and application of THI [11] and VAS were carried out before onset of therapy and 3 months later [6].

All patients underwent pure-tone audiometry (PTA) and speech audiometry carried out by the same audiologist before and after treatment. The mean was calculated based on pure-tone average at 500, 1000, 2000, and 4000 Hz [12].

For DPOAEs, primary tones f_1 and f_2 were presented at 55 and 65 dB SPL (sound pressure levels). The f_2/f_1 ratio was kept at approximately 1.2. The levels of the DPOAE at $2f_1-f_2$ were recorded in four different frequencies (ranging between 2000 and 5000 Hz), DP-gram showed DP1 level (dB) and DP1 signal-to-noise ratio (dB).

All patients were treated with systemic oral therapy according to the local protocol (1 mg/kg/day prednisolone for 10 days, followed by decreasing doses thereafter). Next, rescue therapy with intratympanic methylprednisolone was offered after systemic therapy failed and no improvements were demonstrated audiometrically in 10 patients (Group 2).

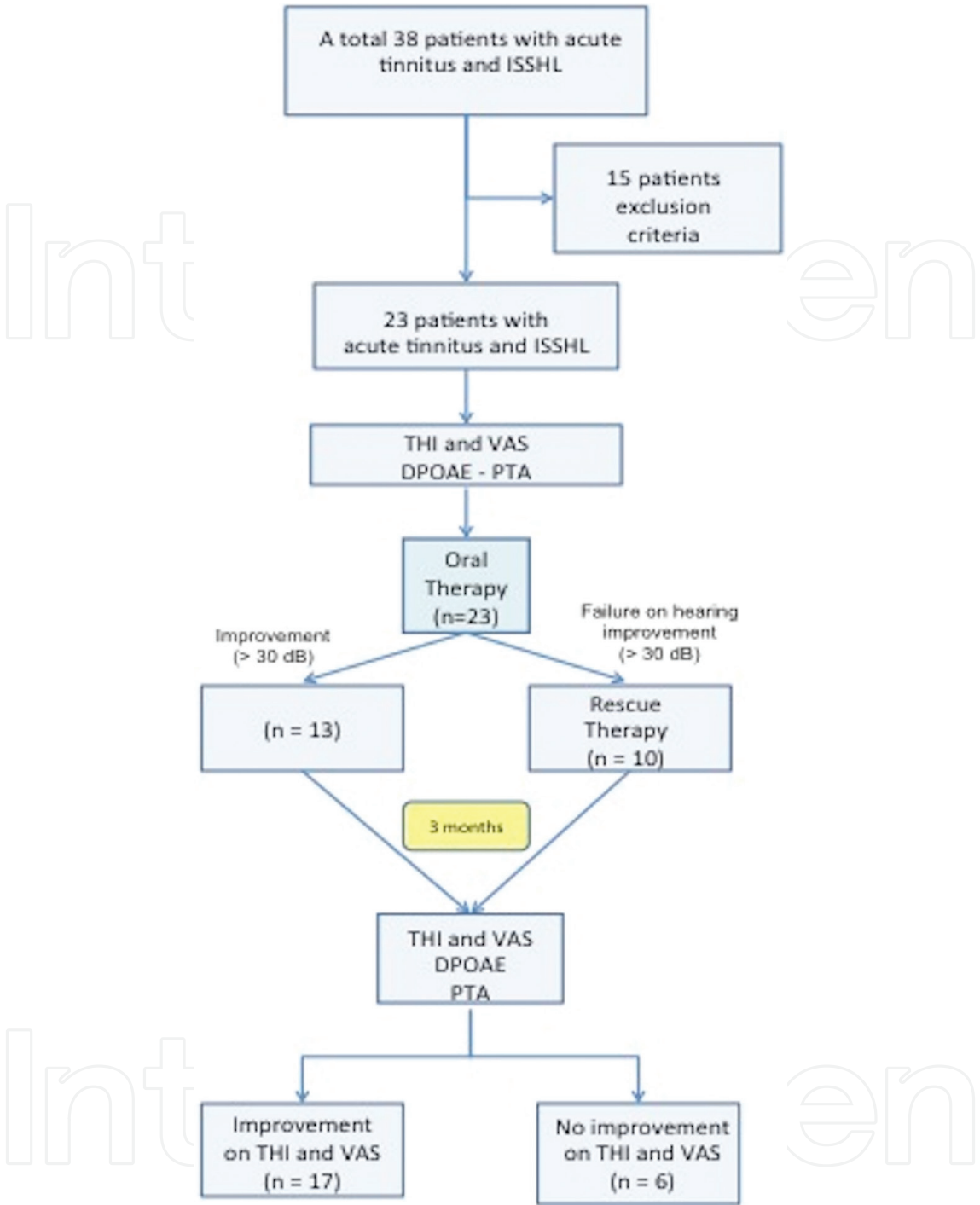


Figure 1. Schematic diagram.

Initially, EMLA cream was applied (AstraZeneca, Wilmington DE) for topical anesthesia in the external auditory canal and the tympanic membrane and left for 30–45 minutes. Then, the patient’s head was placed at 45° in the direction of the affected ear. A solution of 40 mg of methylprednisolone/ml was warmed to body temperature. About 0.3–0.5 ml of the solution was injected into the middle ear; two holes were made with the application of needle (Gelco N.22), one just below the umbo (where the drug was administered) and another in the upper

posterior region (vent). After intratympanic application of the steroid, the patient remained in the injection position with head turned 45° for 30 minutes to maximize exposure of the round window membrane to the solution and were applied three injections every 48 hours.

The criteria for defining successful recovery after therapy vary in the literature on intratympanic therapy. The hearing recovery was analyzed in three categories: (A) complete recovery when there was improvement ≥ 30 dBHL (hearing loss) in the affected frequencies; (B) partial recovery, when there was improvement ≥ 10 dBHL and ≤ 30 dBHL in the affected frequencies; (C) no recovery when there is an improvement of ≤ 9 dBHL [13]. Failure of oral prednisolone therapy was absence of improvement, as just described, after 14 days of treatment [14].

All patients answered the THI [11] and the VAS to assess quantitatively and qualitatively the therapeutic response in relation to tinnitus. In the VAS, score ranges from 1 to 10, where 10 represents the highest degree of tinnitus severity. Scores measured the intensity and discomfort of tinnitus. Two points in the VAS were considered significant change [3]. The THI questionnaire was considered improved when there was change of category of tinnitus severity in the following scale: Grade 1 negligible (0–16), Grade 2 light (18–36), Grade 3 moderate (38–56), Grade 4 severe (58–76), and Grade 5 catastrophic (78–100) [11].

The average posttreatment for some measures were compared between types of treatment (oral therapy and intratympanic corticosteroids after failure of oral therapy) using an analysis of covariance model (ANCOVA). In the ANCOVA model, the measurement obtained after treatment was considered the dependent variable, the type of treatment as the independent variable and the measures at baseline as the covariate. Mean comparisons were made with the intragroup test employing Student *t*-test for paired samples. Note that $p < 0.05$ was considered significant. The analysis was performed using SAS v 9.4 (SAS Institute, Inc., 2012).

3. Results

There were 23 subjects in the total, 13 subjects (6 female and 7 male, mean age = 38.30 years) in the oral steroid therapy (Group 1) and 10 subjects (7 female and 3 male, mean age = 47.40 years) in the intratympanic corticosteroids after failure of oral therapy (Group 2).

The average total score in THI before in Group 1 ($n = 13$) was 64.77 points, and after oral therapy, it was 45.90 points. The mean of the THI score before intratympanic corticosteroids after failure of oral therapy (Group 2) ($n = 10$) was 72.20 points and 47.73 points after (**Figure 2**). The mean VAS value in Group 1 was 7.69 points before and 5.30 points after therapy. The average value in VAS for the Group 2 was 8.30 points before and 5.81 points after therapy (**Figure 3**). THI and VAS averages showed a significant decrease when comparing the values before and after treatment intragroups ($p < 0.05$), whereas the analysis between groups was not statistically different.

In pure tone audiometry, we found the average of 74.23 dB (Group 1) before and 59.69 dB after therapy and 86.50 dB before and 51.91 dB after therapy (Group 2; **Figure 4**). A significant decrease in pure tone thresholds was found when comparing the values before and after treatment intragroups ($p < 0.05$), whereas the analysis between groups was not statistically different.

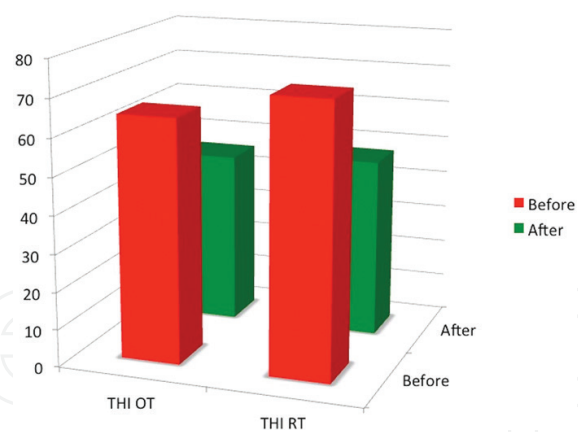


Figure 2. THI results before and after treatment.

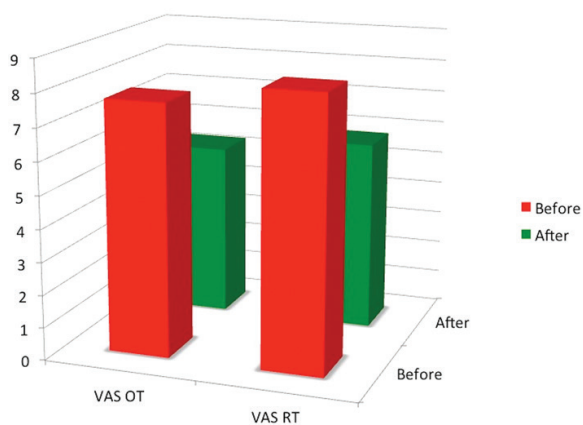


Figure 3. VAS results before and after treatment.

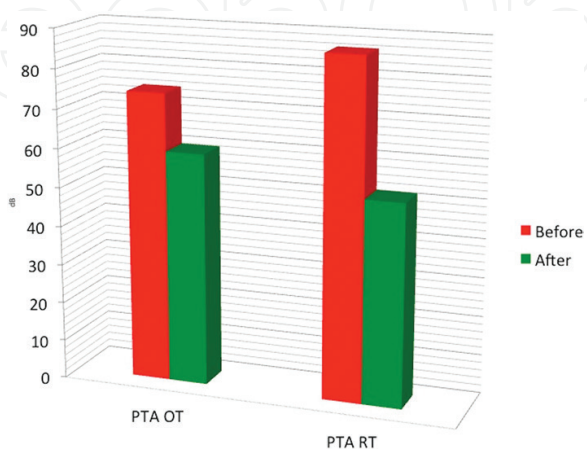


Figure 4. PTA results before and after treatment.

In the DPOAE test, we found in Group 1 the following amplitude values before and after therapy: for frequencies of 2 KHz: -10.08 and -1.69 dB; 3 KHz: -9.77 and -1.85 dB; 4 KHz: -10.92 and -5.08 dB; and 5 KHz: -10.69 and -2.85 dB. As for Group 2, the following amplitude values were obtained before and after treatment, respectively: 2 KHz: -12.30 and -3.90 dB; 3 KHz: -12.00 and -7.10 dB; 4 KHz: -11.30 and -6.10 dB, and 5 KHz: -12.60 and -4.40 dB (**Figure 5**).

As for the S/N ratio, the following values were obtained in Group 1 before and after therapy, for each frequency tested: 2 KHz: 2.77 and 8.38 dB; 3 KHz: 2.23 and 8.69; 4 KHz: 0.00 and 7.85 dB, and 5 KHz: 1.23 and 8.08 dB (**Figure 6**). We found a significant decrease when comparing the amplitude values before and after treatment intragroups ($p < 0.05$) in the four analyzed frequencies (2, 3, 4, and 5 KHz), while the analysis between groups did not show statistical difference.

The S/N ratios were as follows before and after treatment, respectively: 2 KHz: 0.00 and 7.10 dB; 3 KHz: 0.50 and 7.10 dB; 4 KHz: 1.00 and 4.30 dB, and 5 KHz: -0.70 and 4.50 dB (**Figure 6**). There was decrease when comparing signal/noise values before and after treatment intra-groups ($p < 0.05$) in four analyzed frequencies (2 and 5 KHz), while the analysis between groups was not statistically different.

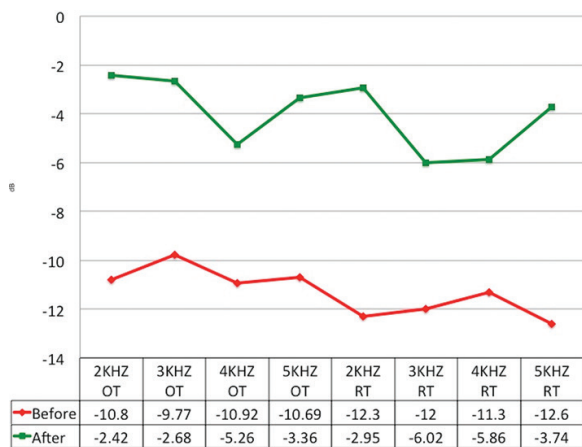


Figure 5. Amplitude results before and after treatment.

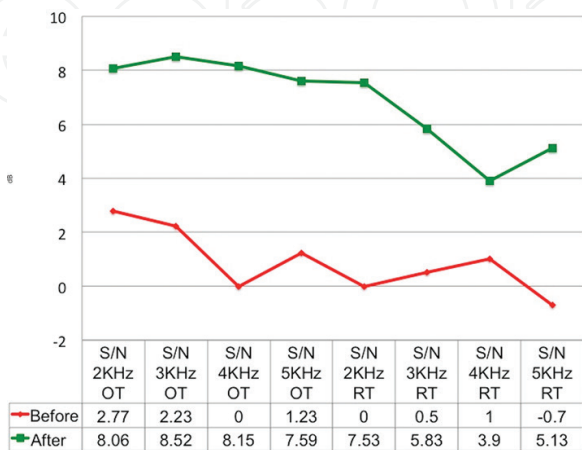


Figure 6. Signal/noise results before and after treatment.

4. Discussion

In this study, the treatment of sudden deafness and acute tinnitus with intratympanic corticosteroids after failure of oral therapy (rescue) was effective. The findings were consistent with the study in which the THI and VAS scores were significantly reduced after intratympanic steroids injections, and it was concluded that these scores were useful for assessing tinnitus patients, as well as it [15].

The intratympanic therapy is currently in use for ISSHL, Meniere's disease, tinnitus associated with these disorders and idiopathic tinnitus [15]. In previous studies, positive results of intratympanic steroids injections were reported for chronic subjective tinnitus [2, 16, 17], but they did not use the control group. Statistic significant difference between saline and dexamethasone solution when a control group was used regarding tinnitus improvement measured with visual analog scale (VAS).

A systematic review was conducted to determine the efficacy of intratympanic steroids treatment. It emphasized that this treatment should be considered as an adjuvant one in sudden deafness [18] consistent with the findings of this study.

The analysis of the characteristics of sudden deafness in 105 patients pointed out that there are individual differences in clinical characteristics between patients with tinnitus and ISSHL hindering a single treatment line [19]. We emphasize that both groups of this study were homogeneous, showing no statistical difference in age, sex, and affected ear.

By examining variables such as gender, age, and laterality in relation to changes in the level of tinnitus after the start of ISSHL, our results corroborate previous studies in which patients requiring rescue therapy were those in which oral therapy had not been sufficient to improve the hearing thresholds. Some patients improved hearing thresholds but remained with residual tinnitus [20].

Overall good results were reported in 77% of patients with tinnitus and various diseases immediately after the intratympanic dexamethasone treatment [21] and found that the best results of intratympanic therapy for tinnitus are obtained in patients with a shorter duration of tinnitus, especially when treatment was initiated within 3 months of symptom onset [17]. The effectiveness of intratympanic injection of prednisolone or dexamethasone to treat subjective tinnitus was reported to be 48.6 and 37.5%, respectively [22].

Similar results were found by other researchers that recommended intratympanic therapy as a possible option in the treatment of tinnitus to a certain group of patients [3, 23]. No difference in results was observed in patients between 3 and 6 months after treatment [23].

The shorter the period from onset of sudden deafness to the start of intratympanic treatment with dexamethasone, the greater the improvement in tinnitus that could be expected after treatment [24]. There is no significant difference after 3 months [6].

In this study, we chose to use intratympanic corticosteroid as rescue after failure of oral corticosteroids. We found that this association was particularly effective in relation to tinnitus. In Group 2, VAS and THI showed a significant reduction of tinnitus annoyance after intratympanic

steroids therapy. Probably, these results are due to the fact that the rescue treatment was initiated immediately after the oral treatment did not show the desired results.

It is significant the correlation between the degree of hearing recovery and subjective improvement of tinnitus after treatment. It was suggested that the hearing improvement may be a prognostic factor for tinnitus improvement, but the presence of tinnitus was not a prognostic factor for the recovery of hearing [25]. These findings are similar to those of the present study.

In this study, Group 2 had increase in the amplitude of DPOAE in all frequencies. There are studies in the literature that demonstrate a prognostic role for OAEs in the ISSHL [21, 26]. Other studies do not agree with this [27, 28].

The DPOAE is detectable in three of five patients whose hearing had significantly improved. It is suggested that the presence of DPOAE can be a useful prognostic factor that positively correlates with the recovery of the SHL [29].

It is reported a significant increase in the amplitude of DPOAE among patients who regained their hearing and also found significant correlations between improvement in DPOAE and improved hearing. It was stated that the presence of DPOAE predicted improvement in hearing [28, 30]. Our study is in agreement with these previous studies.

The detection of OAE during the first 15 days after starting treatment, even with no improvement in hearing, would suggest the high sensitivity of this test to detect improvement changes in the activity of outer hair cells [31].

The sudden deafness factors that predict a favorable prognosis are still controversial. Clinical recovery was estimated by the difference between the audiometric results on admission and the audiometric results 10 days later. Only two factors were significantly associated with improved hearing: tinnitus ($p < 0.04$) and the configuration of ascending audiometric curve at admission ($p < 0.045$) [32]. In this study, most subjects had flat audiometric curve.

Tinnitus was cured in 43 of 114 patients (37.7%) within 3 months. In our study, THI was significantly reduced after intratympanic dexamethasone, and this cure rate was significantly higher in patients with symptoms lasting 2 weeks or less. The authors concluded that the duration of symptoms affected the intratympanic dexamethasone cure rate for acute subjective tinnitus [33].

The feeling of ear fullness and tinnitus in ISSHL was compared in one study that found they were primarily associated with poorer hearing thresholds at high frequencies. They concluded that tinnitus is probably originated in the region where the hair cells are damaged [34]. Steroid intratympanic therapy for acute tinnitus was found effective. SSHL patients were excluded from that study. Our study is about ISSNHL patients with tinnitus that is necessarily acute.

Steroids were likewise effective for these patients. Probably, the short time from onset of tinnitus is the determinant factor to predict the effectiveness of steroids therapy.

Our study has some limitations that should be pointed out: we did not have a control group, as this group would be composed of patients who failed on oral therapy and were not treated

with rescue therapy, which would not be correct from the point of view ethics and the number of patients is small in preliminary studies. Therefore, to confirm our results, we should consider a larger number of patients in future studies.

5. Conclusions

Our results as well as other studies seem to point out to the effectiveness of steroids for the treatment of acute tinnitus. Both oral and intratympanic steroids were effective in our study. Intratympanic steroids improved tinnitus further in patients that did not respond well to oral steroids. The higher concentration of steroids in inner ear fluids after intratympanic injection probably explains this result.

Why steroids are effective to treat acute tinnitus and not to treat chronic tinnitus? We believe tinnitus start in the cochlea almost always. Later the cochlea lesion causes changes in central pathways that in some patients make the symptom permanent and extremely annoying-severe disabling tinnitus (SDT) [2]. If tinnitus is treated before it sets foot in the central pathways (acute tinnitus), steroid therapy is effective.

Author details

Monique Antunes De Souza Chelminski Barreto*, Alleluia Lima Losno Ledesma, Marlene Escher Boger and Carlos Augusto Costa Pires De Oliveira

*Address all correspondence to: nikebarr@hotmail.com

University of Brasilia, Brasília, Brazil

References

- [1] Eggermont JJ. Pathophysiology of tinnitus. *Progress in Brain Research*. 2007;**166**:19-36
- [2] Shulman A, Goldstein B. Intratympanic drug therapy with steroids for tinnitus control. *The International Tinnitus Journal*. 2000;**6**:10-20
- [3] Araujo MFS, Oliveira CA, Bahmad Jr F. Intratympanic dexamethasone injections as a treatment for severe, disabling tinnitus. Does it work? *Head and Neck Surgery*. 2005;**131**:113-117
- [4] Muehlmeir G, Biesinger E, Maier H. Safety of intratympanic injection of AM-101 in patients with acute inner ear tinnitus. *Audiology and Neurotology*. 2011;**16**:388-397
- [5] Heyning PV, Muehlmeir G, Cox T, Lisowska G, et al. Efficacy and safety of AM-101 in the treatment of acute inner ear tinnitus a double-blind, randomized, placebo-controlled phase II study. *Otology & Neurotology*. 2014;**35**:589-597

- [6] Stachler RJ, Chandrasekhar SS, Archer SM, Rosenfeld RM, et al. Clinical practice guideline: Sudden hearing loss. *Otolaryngology Head and Neck Surgery*. 2012;**146**:S1-S35
- [7] Rauch SD, Halpin CF, Antonielle PJ, Babu S, et al. Oral vs intratympanic corticosteroid therapy for idiopathic sudden sensorineural hearing loss. *The Journal of the American Medical Association*. 2011;**305**:2071-2079
- [8] Schreiber BE, Charlotte A, Dorian OH, Linda ML. Sudden sensorineural hearing loss. *The Lancet*. 2010;**375**:1203-1211
- [9] Maia RA, Cahali S. Surdez súbita. *Brazilian Journal of Otorhinolaryngology*. 2004;**70**: 238-248
- [10] Penido NO, Ramos HVL, Barros FA, Cruz OLM, et al. Clinical and etiological factors and evolution of hearing in sudden deafness. *Brazilian Journal of Otorhinolaryngology*. 2005;**71**:633-638
- [11] Ferreira PEA, Cunha F, Onishi ET, Branco-Barreiro FCA, et al. Tinnitus handicap inventory: Cultural adaptation to Brazilian. *Pró-Fono R Atual Cient*. 2005;**17**:303-310
- [12] Halpin CF, Shi H, Reda D, Antonelli PJ, et al. Audiology in the sudden hearing loss: Clinical trial. *Otology & Neurotology*. 2012;**33**(6):907-911
- [13] Nemati S, Naghavi SE, Kazemnejad E, Banan R. Otoacoustic emissions in sudden sensorineural hearing loss: Changes of measures with treatment. *Iranian Journal of Otorhinolaryngology*. 2011;**23**(1):37-44
- [14] Raymundo IT, Bahmad FJr, Barros Filho JB, Pinheiro TG, et al. Intratympanic methylprednisolone as rescue therapy in sudden sensorineural hearing loss. *Brazilian Journal of Otorhinolaryngology*. 2010;**76**:499-509
- [15] Tinnitus assessment by THI and VAS in patients with sudden sensorineural hearing loss Wang, P., et al., Lin chuang er bi yan hou tou jing wai ke za zhi = Journal of clinical otorhinolaryngology, head, and neck surgery, 2014;**28**(22): p. 1777-9
- [16] Dodson KM, Sismanis A. Intratympanic perfusion for the treatment of tinnitus. *Otolaryngologic Clinics of North America*. 2004;**37**:991-1000
- [17] Cesarani A, Capobianco S, Soi D, Giuliano DA, et al. Intratympanic dexamethasone treatment for control of subjective idiopathic tinnitus: Our clinical experience. *The International Tinnitus Journal*. 2002;**8**:111-113
- [18] Lavigne P, Lavigne F, Saliba I. Intratympanic corticosteroids injections: A systematic review of literature. *European Archives of Otorhinolaryngology*. 2015;**23**:1-8
- [19] The study of clinical characteristics of sudden sensorineural hearing loss patients with tinnitus Li, Q., et al., Lin chuang er bi yan hou tou jing wai ke za zhi = Journal of clinical otorhinolaryngology, head, and neck surgery, 2015;**29**(1): p. 57-60
- [20] Michiba T, Kitahara T, Hikita-Watanabe N, Fukushima M, et al. Residual tinnitus after the medical treatment of sudden deafness. *Auris Nasus Larynx*. 2013;**40**:162-166

- [21] Sakashita T, Minowa Y, Hachikawa K. Evoked otoacoustic emissions from ears with idiopathic sudden deafness. *Acta Otolaryngologica Supplementum*. 1991;**486**:66-72
- [22] She W, Dai Y, Du X, Chen F, et al. Treatment of subjective tinnitus: A comparative clinical study of intratympanic steroid injection vs. oral carbamazepine. *Medical Science Monitor*. 2009;**15**:35-39
- [23] Choi SJ, Lee JB, Lim HJ, In SM, et al. Intratympanic dexamethasone injection for refractory tinnitus: Prospective placebo-controlled study. *Laryngoscope*. 2013;**123**(11):2817-2822
- [24] Yoshida T, Teranishi M, Iwata T, Otake H, et al. Intratympanic injection of dexamethasone for treatment of tinnitus in patients with sudden sensorineural hearing loss. *Audiol Research*. 2012;**2**(1):4-7
- [25] Rah YC, Park KT, Yi YJ, Seok J, et al. Successful treatment of sudden sensorineural hearing loss assures improvement of accompanying tinnitus. *The Laryngoscope*. 2015;**125**:1433-1437
- [26] Ishida IM, Sugiura M, Teranishi M, Katayama M, et al. Otoacoustic emissions, ear fullness and tinnitus in the recovery course of sudden deafness. *Auris Nasus Larynx*. 2008;**35**:41-46
- [27] Canale A, Lacilla M, Giordano C, De Sanctis A, et al. The prognostic value of the otoacoustic emission test in low frequency sudden hearing loss. *European Archives of Otorhinolaryngology*. 2005;**262**:208-212
- [28] Hoth S. On a possible prognostic value of otoacoustic emissions: A study on patients with sudden hearing loss. *European Archives of Otorhinolaryngology*. 2006;**262**(3):217-224
- [29] Schweinfurth JM, Cacace AT, Parnes SM. Clinical applications of otoacoustic emissions in sudden hearing loss. *Laryngoscope*. 1997;**107**:1457-1463
- [30] Chao TK, Chen THH. Distortion product otoacoustic emissions as a prognostic factor for idiopathic sudden sensorineural hearing loss. *Audiology and Neurotology*. 2006;**11**:331-338
- [31] Shupak A, Zeidan R, Shemesh R. Otoacoustic emissions in the prediction of sudden sensorineural hearing loss outcome. *Otology & Neurotology*. 2014;**10**:1-7
- [32] Ben-David J, Luntz M, Magamsa I, Fradis M, et al. Tinnitus as a prognostic sign in idiopathic sudden sensorineural hearing loss. *The International Tinnitus Journal*. 2001;**7**(1):62-64
- [33] An YH, Kyu KK, Kwak MY, Yoon SW, et al. Prognostic factors for the outcomes of intratympanic dexamethasone in the treatment of acute subjective tinnitus. *Otology & Neurotology*. 2014;**35**:1330-1337
- [34] Sakata T, Esaki Y, Yamano T, Sueta N, et al. A comparison between the feeling of ear fullness and tinnitus in acute sensorineural hearing loss. *International Journal of Audiology*. 2008;**47**(3):134-140