

# We are IntechOpen, the world's leading publisher of Open Access books Built by scientists, for scientists

6,900

Open access books available

186,000

International authors and editors

200M

Downloads

Our authors are among the

154

Countries delivered to

TOP 1%

most cited scientists

12.2%

Contributors from top 500 universities



WEB OF SCIENCE™

Selection of our books indexed in the Book Citation Index  
in Web of Science™ Core Collection (BKCI)

Interested in publishing with us?  
Contact [book.department@intechopen.com](mailto:book.department@intechopen.com)

Numbers displayed above are based on latest data collected.  
For more information visit [www.intechopen.com](http://www.intechopen.com)



---

# Sagittal Alignment in Spinal Deformity: Implications for the Non-Operative Care Practitioner

---

Prachi Bakarania, Hagit Berdishevsky,  
Kelly Grimes and John Tunney

Additional information is available at the end of the chapter

<http://dx.doi.org/10.5772/intechopen.69455>

---

## Abstract

Sagittal alignment has become a hot topic in the world of orthopedics, particularly as it pertains to adults with spine deformities and coexisting pain, activity limitations, and health-related quality of life. It is reported that the prevalence of spinal deformity in the older adult will continue to increase. Clinicians across disciplines recognize the myriad of variation that exists in sagittal alignment, and that there is not one ideal norm to ascribe to. Relatively new to the spine deformity community has been the discovery of the relationship between the pelvis and the femur (pelvic incidence) in dictating lumbar lordosis and overall spinal alignment. While it is acknowledged that variation exists, there is now evidence that there is a limited range within which we can compensate for loss of sagittal alignment and still function well. When compensations run out, the quality of life becomes affected. These alignment variations, compensations, and in some cases, loss of alignment all together have clinical implications for the physiotherapist working with the older adult population. The purpose of this chapter is to describe the current state of evidence-informed knowledge around spinopelvic parameters as they relate to the adult with spine deformity and offer clinical implications for the conservative care practitioner.

**Keywords:** adult spinal deformity, scoliosis, sagittal alignment, pelvic incidence, lumbar lordosis, sagittal vertical axis

---

## Learning objectives

1. Explain why the sagittal profile is important from an evolutionary and biomechanical perspective.
2. Appreciate the historical evolution of our understanding of sagittal alignment.

3. Define key sagittal parameters.
4. Explain the correlations between the various parameters that are key in understanding the sagittal relationships.
5. Describe how spinal deformity may lead to compensatory changes in sagittal alignment.
6. State implications in terms of assessment strategies for the conservative care practitioner (physiotherapists/orthotists).

## 1. Introduction

Spinal Deformity may be defined as an abnormality in alignment, formation, or curvature of one or more portions of the spine [1]. Spine deformities can occur in one or a combination of the axial, coronal, and sagittal planes. Scoliosis is a spinal deformity defined by the Scoliosis Research Society (SRS) as a lateral curve measuring  $10^\circ$  or more on an anterior-posterior radiograph with the presence of vertebral rotation [2].

In recent years, attention to the role of sagittal plane alignment in the overall health and function of adults with spine deformity has increased [3]. The purpose of this chapter is to shed light on the body of literature surrounding sagittal alignment variations and hypothesize about clinical implications for the conservative care practitioner managing spinal deformity in clinical practice.

## 2. Main body

### 2.1. Definition of posture

Alignment and postural control have long been fundamental to the clinical decision-making process of the physiotherapist. The Guide to Physical Therapy Practice lists “Posture” as a key test and measure to be included in a physiotherapist’s objective examination [4]. Indeed, there exists no universal definition of posture and within postural control, alignment [5]. However, health-care practitioners from various backgrounds make similar statements when describing posture. Basmajian in 1965 understood posture to be the “upright, well-balanced stance of the human subject in a ‘normal’ position” [6]. The Posture Committee of the American Academy of Orthopedic Surgeons (AAOS) defines posture as “the state of muscular and skeletal balance which protects the supporting structures of the body against injury or progressive deformity, irrespective of the attitude in which the structures are working or resting. Under such conditions, the muscles will function most efficiently and the optimum positions are afforded for the thoracic and abdominal organs” [7].

### 2.2. Evolutionary perspective on upright posture

In evolutionary terms, it is upright stance and the ability of humans to achieve bipedalism that differentiates humans from the majority of the animal world. This ability was made

possible by the evolution of the structure of the pelvis and lumbar spine as well as their muscular attachments.

Several changes have been critical to this evaluation. First, the human lumbar spine is exceedingly longer and more mobile, which has allowed for lumbar lordosis (LL)/extension to align the trunk over the pelvis from a lateral view [8].

Second, the sacrum in humans is broader/wider. It contributes to the mobility of the lower lumbar segments to form lordosis, where the narrowness of the sacrum and length of the ilia in other primates “lock” the lower lumbar segments [9]. In addition to the sacrum being shorter in length and broader in width, the ilia are also broader in width and more flared anteriorly [9]. This adaptation brings the anterior gluteal muscles (gluteus medius and minimus) from their former roles as hip extensors and migrates them laterally and anteriorly to perform their current roles as hip abductors and stabilizers of the pelvis during the single limb stance phase of gait. In partnership with a longer femoral neck, the gluteals create a longer lever arm, allowing the hip abductors to function more effectively in stabilizing the pelvis during the stance phase of gait.

Other muscular changes include hypertrophy of the gluteus maximus in humans, particularly during running, where it serves to keep the trunk from falling forward during heel strike [9]. Additionally, the hamstrings, while they played a “power” function in quadrupedal locomotion, play more of a stabilizing/control role in human bipedal locomotion. Furthermore, humans have smaller erector spinae muscles most likely owing to the center of mass being at the second sacral vertebrae, which creates a shorter lever arm in which the erector spinae have to work [9]. Therefore, the muscles do not need to be under such constant activation.

A general understanding of the evolution of spinopelvic alignment and upright stance helps us understand how the loss of this congruent relationship is potentially problematic in individuals with spinal deformity.

### **2.3. Historical perspective on understanding of sagittal alignment**

The evolution of our understanding of sagittal alignment has been developing for over 150 years. It is von Meyer who is credited with the discovery of the weight center of the human body at the level of the second sacral vertebra [6]. Although highly variable, most clinicians and researchers reporting on alignment agree that the line of gravity should pass near the mastoid process of the temporal bone, just anterior to the second sacral vertebrae, just posterior to the hip joint, and just anterior to the knee and ankle joint [6, 7, 9, 10]. Thus, balanced about this line of gravity, man is able to remain upright with mild anterior/posterior sway and minimal energy expenditure.

The German orthopedist, Franz Staffell, in 1889, is credited with further sub-classification of ideal posture into categories (i.e., round, flat, lordotic) [11].

Statements such as that made by Schulthess in 1905 are indicative of the openness of clinicians to the variation in the sagittal plane versus the assumption of one ideal posture and all else faulty [12].

Kendall, Kendall, and Boynton in 1952 described an ideal postural type and three faulty postural types (kyphotic-lordotic, flat back, and swayback) [7]. Rex McMorris in 1961 described

what he termed faulty postural types in children [13]. Roussouly in 2005 identified lordotic types, which will be discussed in further detail later in this chapter [14]. Mac-Thiong in 2010 described six postural types [15].

Our evolution in understanding the relationship of the pelvis to the spine can be traced to the early 1960s. Joanne Bullock-Saxton, in her narrative review in 1988, cited work by Hollinshead in 1962 observing a relationship between the position of the pelvis and the amount of lumbar lordosis [16]. Indeed, others also discussed the interaction between pelvic obliquity or pelvic inclination and its role in determining the degree of lumbar lordosis. Additionally, the obliquity of the sacrum was determined to be related to the degree of lumbar lordosis [16]. During et al. explained the relationship between the position of the sacrum and the depth of lumbar lordosis as functional. The steeper the slope of the upper portion of the sacrum, the deeper the lumbar lordosis needs to be in order to maintain optimal position of the upper part of the body over the lower along the line of gravity [17].

The advent of instrumentation with spinal fusion in the surgical management of scoliosis and spinal deformity has led to a greater push to understand sagittal alignment. Although early surgical instrumentation was effective in addressing the frontal plane aspect of the scoliotic alignment, follow-up revealed often deleterious effects on the sagittal plane [18]. Doherty, in 1973, described what was later coined by Moe and Denis as “flatback syndrome,” characterized by a fixed forward inclination of the trunk due to the loss of normal lumbar lordosis [18]. The early instrumentation combined the use of a straight rod with distractive forces and, when intervention extended to lower lumbar levels, the combination of these forces led to a loss of lumbar lordosis [18]. Recognition of this postoperative outcome led to advancements in surgical technique, which is beyond the scope of this text, as well as the understanding of the need to not only preserve but also enhance lumbar lordosis in order to minimize the risk of postoperative flatback syndrome. The identification of pelvic incidence, a morphological parameter that describes the relationship of the sacrum to the femur, represented a turning point in the movement to better address the sagittal plane from an operative perspective [19]. These parameters and their clinical implications may also be useful, as we will see, for the physiotherapist working with the older adult with spine deformity, as it gives us parameters within which we can better prognosticate the type of client we may be able to work with successfully.

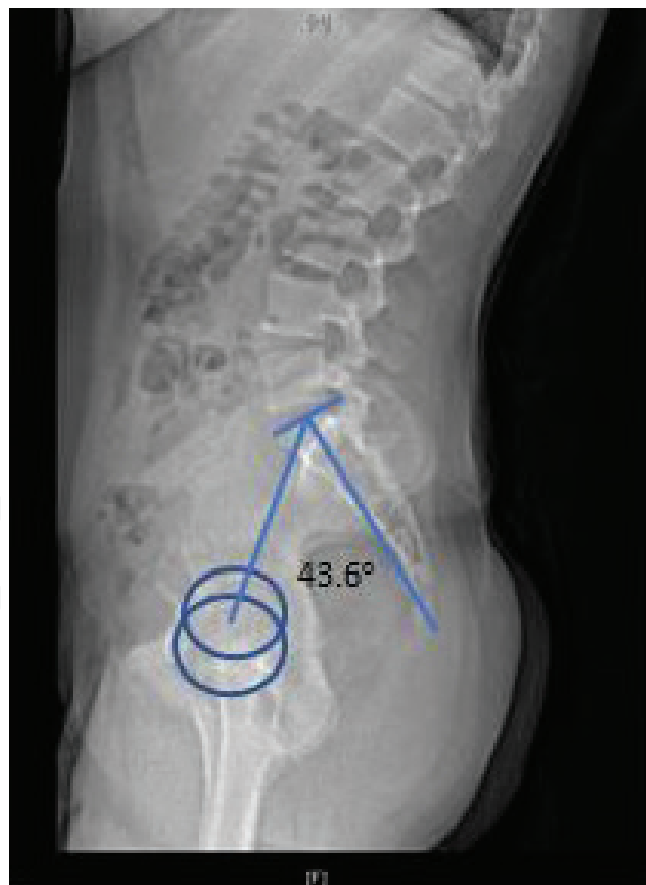## **2.4. Measuring spinopelvic alignment**

Assess a patient’s sagittal alignment allows the practitioner to objectively understand its potential role in contributing to a patient’s pain and dysfunction. In 2006, the Scoliosis Research Society published the first classification system to develop a common language around adult spinal deformity (ASD). This classification grew out of an understanding that the existing adolescent scoliosis classifications were not entirely applicable to the adult population when making clinical decisions around operative management. The most recent update on this classification emphasizes the importance the sagittal plane plays in maintaining healthy upright spinal postures. Their work is valuable for the conservative care practitioner to help make clinical predictions as to the contribution of alignment to pain in our patients with spinal deformity [20].

The first step of the classification is to identify the coronal curve type, depending on the location of the curve apices and convexities. The categories are thoracic, thoracolumbar/lumbar, or double curve. The second step is to assess for the presence of sagittal modifiers. These modifiers include pelvic incidence (PI), global alignment via sagittal vertical axis (SVA), pelvic tilt (PT), degree of lumbar lordosis (LL), as well as subluxation or listhesis in the frontal or sagittal plane [20].

#### 2.4.1. Pelvic incidence

Pelvic incidence is an anatomical or morphological measurement that is unique to each individual and is independent to the spatial orientation of the pelvis (**Figure 1**). It is specific to each individual and remains constant throughout the life span. The steps in measuring PI are as follows: (1) Draw a line across S1 superior end plate. (2) Find the midpoint from #1 and draw a downward perpendicular line. (3) Draw a line from the center of the femoral head line to the center of the center sacrum line. Often in the presence of pelvic obliquity you will need to find the midpoint of both femoral heads. (4) The angle between these lines is the pelvic incidence.



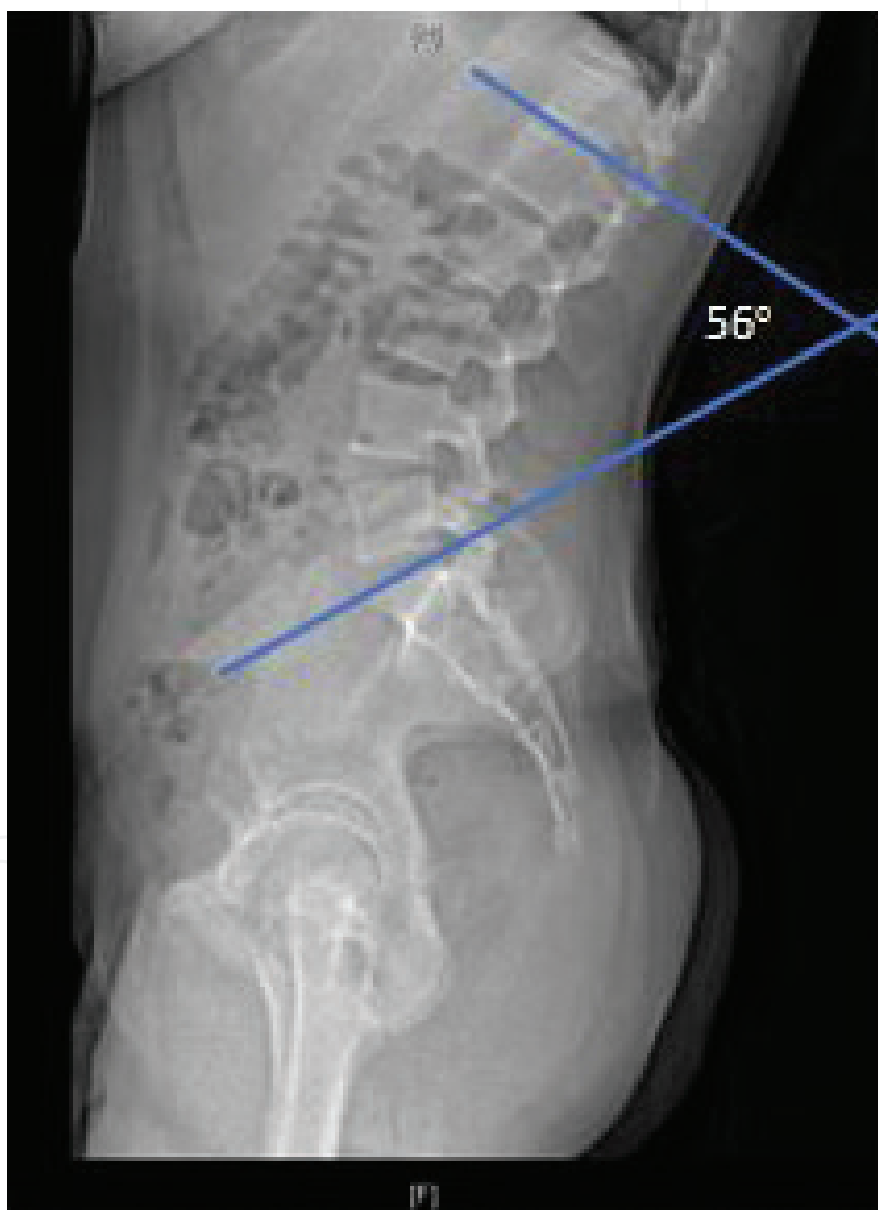**Figure 1.** Pelvic incidence measurement. (1) Draw a line across S1 superior end plate. (2) Find the midpoint from #1 and draw a downward perpendicular line. (3) Draw a line from the center of the femoral head line to the center of the center sacrum line.

### 2.4.2. Lumbar lordosis

Lumbar lordosis is measured by the angulation from the inferior angle of T12 and the superior end plate of S1 (**Figure 2**).

### 2.4.3. SVA

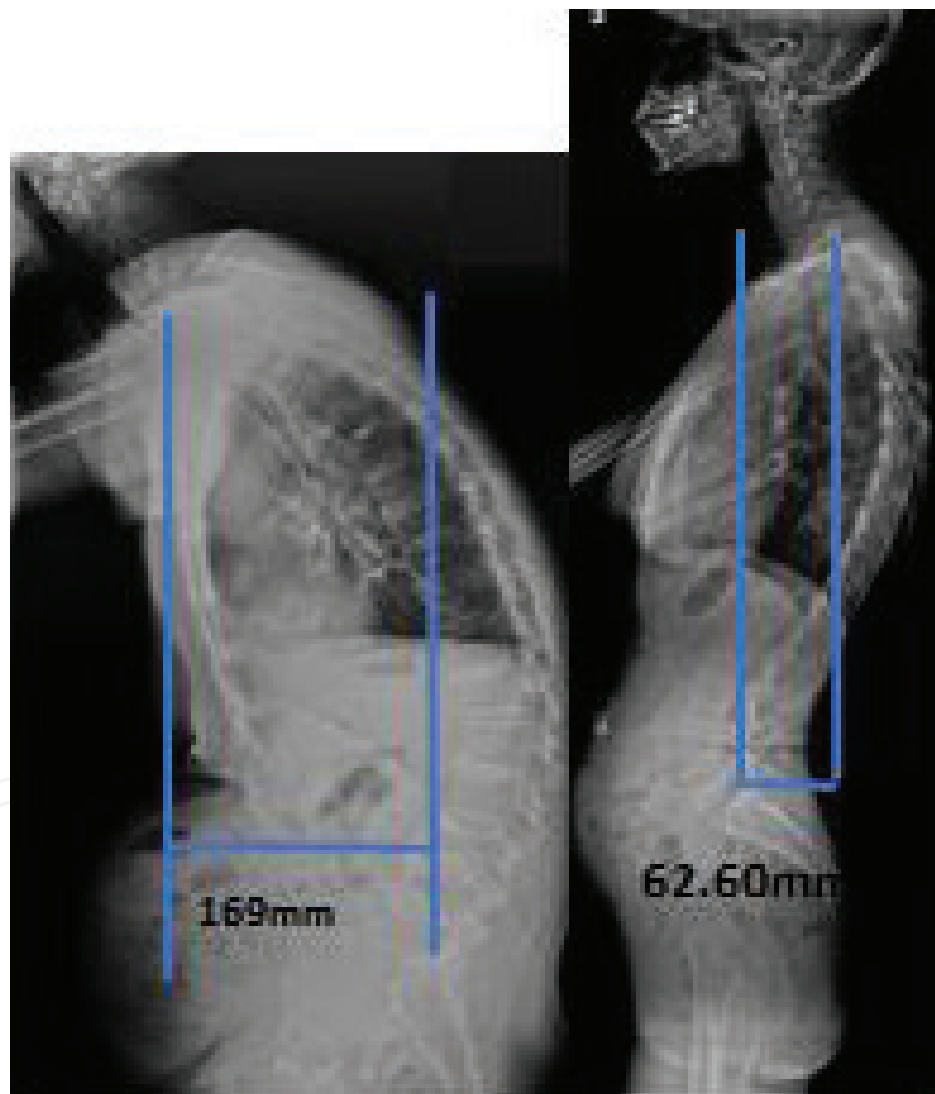
Sagittal vertical axis is used to measure the degree of forward or backward angulation of a patient's posture. SVA is one of the easiest radiological parameters to measure, since the



**Figure 2.** Lumbar lordosis measurement: From inferior end plate of T12 and superior end place of sacral. This patient has a lumbar lordosis of 56.2°.



femoral heads do not have to be visualized. For this reason, the authors have found it to be a clinically relevant and useful measure to incorporate into clinical practice. The steps to measure SVA on a standard lateral view radiograph are as follows: (1) Identify the center of C7—inferior end plate, and draw a line straight down perpendicular to the bottom of the film. (2) Draw a vertical line from the posterior-superior corner of the sacrum. (3) Measure the distance between lines 1 and 2 [21]. A positive number indicates that C7 is in front of sacrum. On a clinical examination, the patient's head is likely to be in front of the torso as well as his trunk in a more forward flexed position. A negative number indicates that a C7 is behind the sacrum. This type of posture is often called swayback. Clinically, the patient likely stands with their pelvis more in front than their head (**Figure 3A and B**).



**Figure 3.** SVA—Sagittal vertical axis: The steps to measure SVA are as follows: (1) Identify the center of C7—inferior end plate, and draw a line straight down perpendicular to the bottom of the film. (2) Draw a vertical line from the posterior-superior corner of the sacrum. (3) Measure the distance between lines 1 and 2. (A) This individual has a (+) SVA of 169.98 mm. (B) This individual has a (-) SVA of 62.6mm.



#### 2.4.4. Pelvic tilt

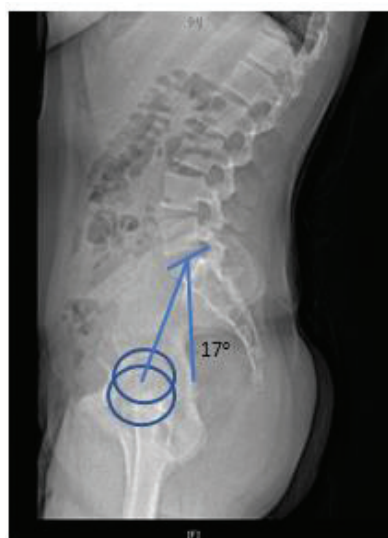Radiological pelvic tilt is a sagittal measurement that can be assessed on a lateral radiograph. Refer to **Figure 4** for specifics. The following are the measurement steps: (1) Draw a line from the midpoint of the sacral end plate running perpendicular down to the bottom of the X-ray. (2) Draw a line from the center of the femoral heads to the center of the sacrum. (3) The angle between these two lines is the pelvic tilt. Also, pelvic tilt + sacral slope (SS) = pelvic incidence (**Figure 4**) [21].

#### 2.4.5. Sacral slope

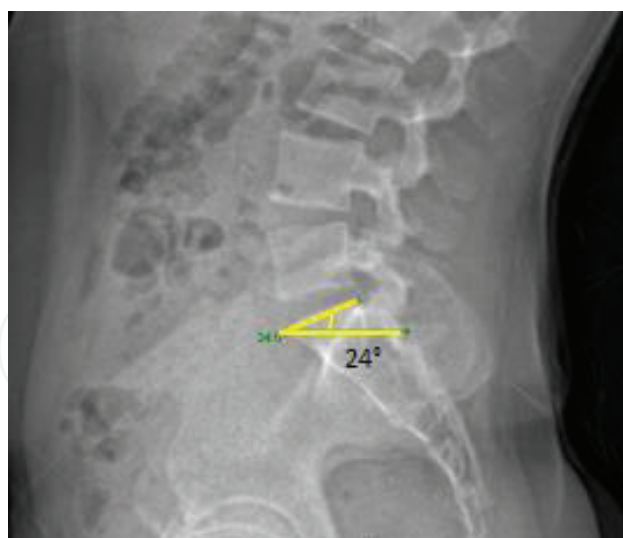
The last radiological measure discussed here is the least discussed as it is often difficult to measure. However, its importance is vital to understanding the relationship of the other parameters. Refer to **Figure 5** for specifics. The steps to measurement are as follows: (1) Draw a line along the superior sacral end plate. (2) Draw a line from the anterior superior edge parallel to the bottom of the X-ray. (3) This angle is the sacral slope. Pelvic incidence = sacral slope + pelvic tilt [22].

### 2.5. Inter-relationships between spinopelvic parameters

A significant chain of interdependence exists between pelvic and spinal parameters. Pelvic incidence, as previously stated, is an independent and anatomic parameter that determines pelvic orientation and the optimal size of lumbar lordosis [19]. In practice, the PI of an individual is correlated together with his or her sacral slope. In this section, both SS and PI will be described in relation to LL and sagittal balance as well as the consequences of mismatch between the pelvic parameters and LL for the adult individual with spinal deformity.



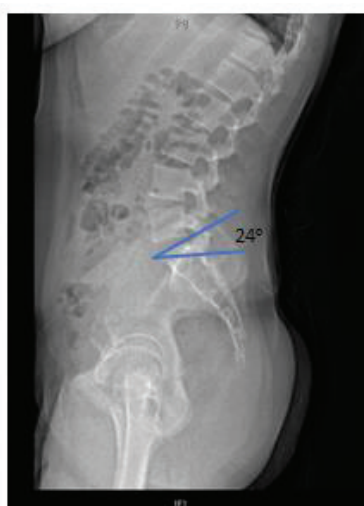**Figure 4.** Pelvic tilt. (1) Draw a line from the midpoint of the sacral end plate running perpendicular down to the bottom of the X-ray. (2) Draw a line from the center of the femoral heads to the center of the sacrum. (3) The angle between these two lines is the pelvic tilt. This individual's pelvic tilt measures 17°.



**Figure 5.** Sacral slope: (1) Draw a line along the superior sacral end plate. (2) Draw a line from the anterior superior edge parallel to the bottom of the X-ray. (3) This angle is the sacral slope. This individual's sacral slope measures 24°.

### 2.5.1. Influence of sacral slope on global sagittal alignment

In a well-balanced spine, the SS is between 35 and 45° and the LL has an apex at L3–L4 [23] (**Figure 6**). In an individual with a low SS angle (<35°), a regional hypolordotic lumbar deformity with a compensatory hypo-kyphosis or normal thoracic and lumbar apex at L5 may be observed [23]. *Regional deformity* is defined as sagittal kyphotic misalignment that affects a limited number of segments of the spine (i.e., the lumbar spine, the thoracic spine, the thoracolumbar junction (TLJ), or the lower lumbar spine). *Compensatory mechanisms* are changes in the sagittal alignment of spinal or non-spinal segments, different from those involved in regional deformity, to restore the

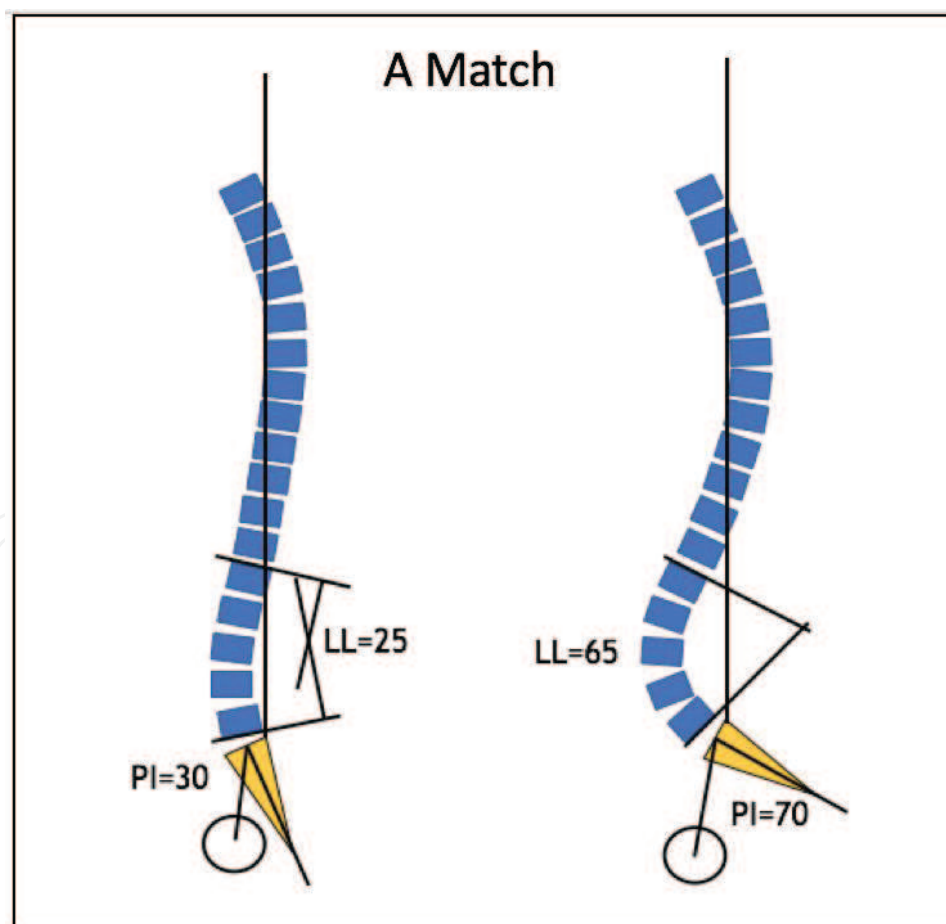


**Figure 6.** Drawings of sacral slope and sagittal spinal alignments. Left: Sacral slope (SS) < 35°, apex of lumbar lordosis (LL) at middle L5, the spine is hypolordotic and relatively normal kyphotic; middle: 35° < SS < 45°, apex of LL at middle L3–L4, the spine is well balanced; right: SS > 45°, apex of LL at base L3, the spine is hyperlordotic and hyper-kyphotic.

alignment of the gravity line or the horizontal gaze. Compensatory mechanisms need active muscle contraction by the subject [24, 25]. When the SS is high ( $>45^\circ$ ), a regional hyper-lordosis lumbar deformity along with compensatory thoracic hyper-kyphosis may commonly be observed [23].

### 2.5.2. Pelvic incidence and its relationship to LL and sagittal balance

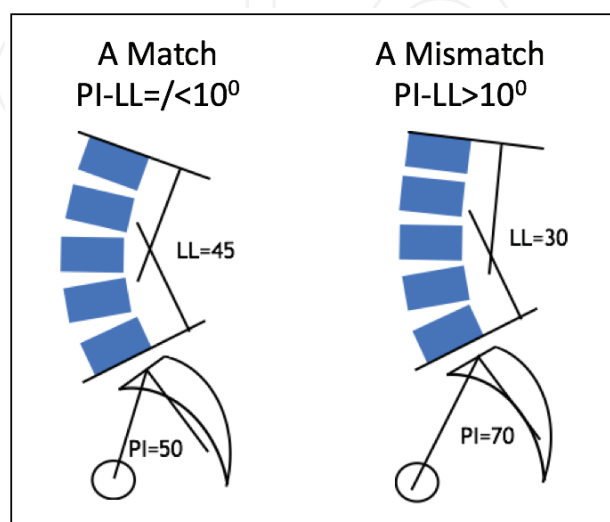
A mean value PI was documented in 2011 to be  $55 \pm 10^\circ$  [24], and a mean value of LL and thoracic kyphosis (TK) was documented in 1989 to be  $44$  and  $36^\circ$  [26]. These mean values do not imply ideal but simply a fixed angle providing anatomical characteristics of the pelvis and lumbar spine. Ranges of value are more appropriate for describing normal, but in this section, the mean values give an easier way of understanding the concept of match versus mismatch between the two. A  $\pm 10^\circ$  difference between PI and LL was documented as an ideal match for optimal maintenance of sagittal balance [27]. A *match* occurs when both PI and LL are within the margin of  $10^\circ$  difference (known as  $PI-LL = 10$  or  $PI - LL = 10$ ). PI and LL can be high or low in degrees and still be considered a match. For example, a PI of  $70^\circ$  and an LL of  $65^\circ$  would be considered a high degree. A PI of  $30^\circ$  and an LL of  $35^\circ$  would be considered a low degree. In both cases, the difference between them is  $5^\circ$  and thus considered a match and a harmonious sagittal plane alignment (**Figure 7**).



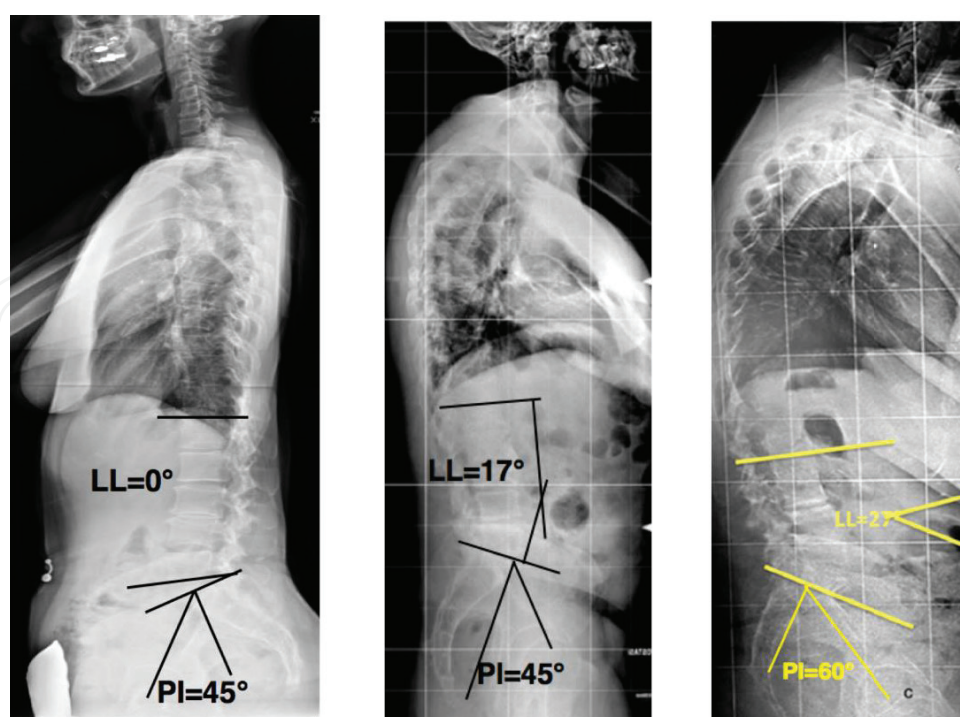
**Figure 7.** Representative drawing of harmonious spine in the sagittal plane: high PI and LL (left) and low PI and LL (right). Both are a match between PI and LL of two possible separate individuals.

A *mismatch* occurs when there is a greater than  $10^\circ$  difference between PI and LL and can lead to a disharmonious sagittal plane alignment. A mismatch can be presented by high PI and low LL ( $PI-LL >10$ ) or the opposite (**Figure 8**).

The most documented [24–26] types of mismatches in adolescent idiopathic scoliosis (AIS) and ASD include those with  $PI-LL >10^\circ$  where the PI is high and the LL is low (**Figure 9**).



**Figure 8.** Representative drawing of match (left) and mismatch (right) PI and LL.



**Figure 9.** Mismatch PI-LL in adolescent (left) and older adults (middle and right).

### 2.5.3. Clinical implications

Radiological parameters that most highly correlate with pain, disability, and low quality of life are sagittal vertical axis, pelvic tilt, and the PI-LL relationship and are thus key components of the SRS-Schwab ASD classification [20, 27–29].

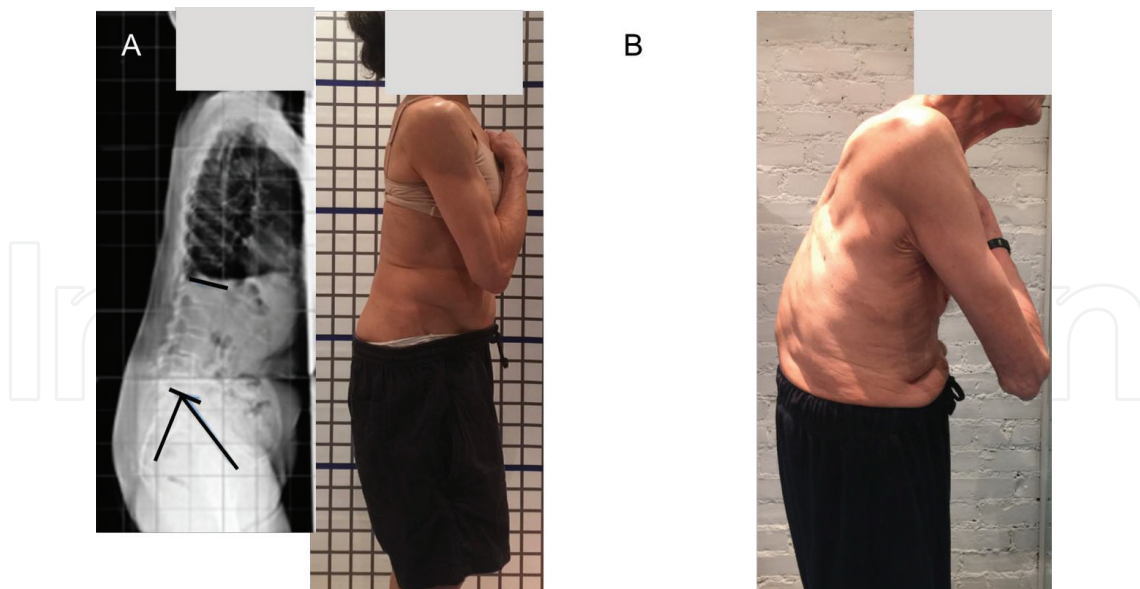
In a multi-center, prospective cohort trial in 2013 related radiological parameter thresholds to clinical findings as being predictive of worse clinical symptoms and poorer quality of life [28]. They proposed and concluded that a PI-LL of  $10^\circ$  or less, global alignment (positive SVA) of less than 4 cm, and PT of less than  $20^\circ$  were the ideal spinopelvic alignment for reducing operative intervention procedures and postoperative pain and disability [28].

Overall, literature demonstrates increased surgical complexity with increased severity of sagittal deformity modifiers. A significantly higher osteotomy rate was reported with increasing positive sagittal malalignment and a PI-LL mismatch [29–31]. Iliac fixation was more commonly used as global alignment became increasingly positive. Berjano and Aebi reported the value of the pedicle subtraction osteotomy (PSO), a procedure to restore lumbar lordosis in patients with lumbar/thoracolumbar scoliosis, concurrent loss of lumbar lordosis, and PI-LL mismatch [32]. This procedure has been demonstrated to restore sagittal alignment and improve patient self-reported pain and function.

The incorporation of spinopelvic parameters into surgical decision making has provided greater insight into the relationship between spine deformity and compensatory strategies to attempt to maintain upright alignment. It is theorized, for example, that a person with a low PI may adapt well to a situation if their lumbar lordosis is reduced (due to degenerative changes or scoliosis) because their sagittal alignment, based on the existence of low PI, may more readily “accept” changes that will cause hypolordosis in the lumbar spine and still maintain a match between PI and LL. Conversely, an individual with a high PI and low or loss of lumbar lordosis (secondary to lumbar degenerative changes or scoliosis or to compensate for a decreased thoracic kyphosis) will likely not adapt as well as the one described first. The high PI may not allow the individual to adapt well to the low lumbar lordosis, and after exhausting compensatory strategies at the pelvis (through pelvic tilt) and lower extremities, they may tend toward a positive sagittal balance (positive SVA) and potential compensations in the thoracic spine as well.

Lamartina and Berjano [24] describe a comprehensive classification of sagittal imbalance. In their classification, two compensatory mechanisms occur in response to reduced lumbar lordosis (i.e., lumbar kyphosis). First, local lumbar kyphosis may be compensated for by thoracic lordosis (**Figure 10**). In this situation, the thoracolumbar junction is normal or lordotic. Second, lumbar kyphosis may not be compensated by thoracic lordosis but by thoracic hyperkyphosis causing global kyphosis. In this case, the TLJ is in kyphosis, and the whole spine demonstrates an anterior loss of sagittal balance. In both situations, there will be additional compensations, including pelvic retroversion and knee flexion to maintain upright posture. The reason for the differences between the two is not yet understood but the most accepted theory is that the differences in compensation in the thoracic region are based on the preexisting alignment of the thoracic (being originally hypo-kyphotic vs. normal or hyper-kyphotic)





**Figure 10.** (A) Lumbar kyphosis with a compensatory thoracic lordosis, pelvic retroversion (increased pelvic tilt), and knee flexion. (B) global kyphosis—lumbar kyphosis is not compensated by thoracic lordosis. The TLJ is kyphotic. Compensatory pelvic tilt and flexed knees are present.

and the TLJ. Lumbar kyphosis differs from global kyphosis in that in *lumbar kyphosis*, there is a local kyphosis (at the lumbar region) with compensatory thoracic hypo-kyphosis (**Figure 10A**). In this alignment strategy, thoracic extensor muscles are active, and patients may benefit from remodeling of the lumbar lordosis conservatively or by selective lumbar osteotomy and fusion where the patient may regain a balance with reversal of the compensatory mechanism of the thoracic spine. In *global kyphosis*, the thoracic spine fails to compensate to the lumbar kyphosis and the whole trunk becomes kyphotic (**Figure 10B**).

#### 2.5.4. Summary

The literature review of this section demonstrates that the sagittal plane is vital to understanding pain and disability in patients with ASD, and that SVA, PT, and PI-LL mismatch are the main drivers that affect disability and decreased function [27–32]. Becoming proficient in defining radiographically the above parameters, values and limits, can help guide a better therapeutic decision-making process conservatively and operatively with the aim and focus on maintaining or creating the best sagittal alignment for the individual that will improve function, as well as decrease pain and disability.

### 2.6. Assessment of the patient with ASD

The objective examination should begin with the assessment of alignment using a posture grid. In this section, we only discuss the evaluation of the sagittal alignment. With the patient standing sideways to the posture grid, the examiner can obtain sagittal alignment in a variety of ways, utilizing tools such as an inclinometer, a flexi-ruler, or a plumbline. The amount of cervical lordosis, thoracic kyphosis, lumbar lordosis, thoracolumbar junction transitional

area, pelvic tilt, as well as description of hip and knee position can be measured. An increase in thoracic kyphosis (hyper-kyphosis), and loss of lordosis either in the cervical or in the lumbar/thoracolumbar region, may lead to alignment faults accompanied by muscle length/strength/activation changes that will need to be tested and addressed. See **Table 1** for a description of predicted implications of various alignment faults on mobility, muscle length, strength, and muscle performance. This is not an all-inclusive list and does not substitute for a careful evaluation of alignment and contributing factors to the clinical presentation of the client. See **Table 2** for take-home messages regarding radiological parameters as were discussed in this chapter.

Specific intervention strategies are beyond the scope of this chapter. The authors recommend that clinicians interested in working with this patient population pursue additional training in scoliosis education as most experts view it as a sub-specialty in physiotherapy practice [34].

Thoracic hyper-kyphosis	Loss of LL with TLJ in kyphosis	Loss of LL with TLJ normal or lordotic	PI and hip pathology
<b>Compensatory alignment faults</b> <ul style="list-style-type: none"><li>• excess cervical lordosis with forward head</li><li>• excess lumbar lordosis</li></ul> <b>Mobility deficits</b> <ul style="list-style-type: none"><li>• shoulder range of motion (ROM): flexion and external rotation</li><li>• thoracic mobility</li><li>• ribcage mobility</li></ul> <b>Muscle length deficits</b> <ul style="list-style-type: none"><li>• short/stiff pectorals</li><li>• short/stiff latissimus dorsi</li><li>• short/stiff rectus abdominus</li></ul> <b>Muscle performance deficits</b> <ul style="list-style-type: none"><li>• abdominals (imbalance of coordination/recruitment of abdominal musculature)</li><li>• scapular adductors</li><li>• thoracic extensors</li></ul>	<b>Compensatory alignment faults</b> <ul style="list-style-type: none"><li>• increased thoracic and global kyphosis</li><li>• increased pelvic tilt</li><li>• increased hip/knee flexion</li></ul> <b>Mobility deficits</b> <ul style="list-style-type: none"><li>• shoulder range of motion (ROM): flexion and external rotation</li><li>• thoracic mobility</li><li>• ribcage mobility</li></ul> <b>Muscle length deficits</b> <ul style="list-style-type: none"><li>• short/stiff pectorals</li><li>• short/stiff latissimus dorsi</li><li>• short/stiff rectus abdominus</li></ul> <b>Muscle performance deficits</b> <ul style="list-style-type: none"><li>• abdominals (imbalance of coordination/recruitment of abdominal musculature)</li><li>• scapular adductors</li><li>• global trunk extensors and hip extensors, knee extensors</li></ul>	<b>Compensatory alignment faults</b> <ul style="list-style-type: none"><li>• increased thoracic hypo-kyphosis (usually preexisting)</li></ul> <b>Mobility deficits</b> <ul style="list-style-type: none"><li>• thoracic mobility</li><li>• ribcage mobility</li></ul> <b>Muscle length deficits</b> <ul style="list-style-type: none"><li>• short/stiff or overactive thoracic extensors</li><li>• short/stiff rectus</li></ul> <b>Muscle performance deficits</b> <ul style="list-style-type: none"><li>• abdominals (imbalance of coordination/recruitment of abdominal musculature)</li><li>• scapular adductors</li><li>• global trunk extensors and hip extensors, knee extensors</li></ul>	Novel theory hypothesizing relationship between low PI and femoral acetabular impingement (FAI) [33] Low PI → anterior pelvic tilt with gait → artificial anterior acetabular over coverage and recurrent FAI that increases risk for CAM morphology

**Table 1.** Common sagittal alignment faults and predicted impairments.



Take-home messages on radiological measurements: [20–22, 27, 28]

1. Pelvic incidence = sacral slope + pelvic tilt—This is a radiological measurement
2. Lumbar lordosis should be within  $\pm 10^\circ$  of pelvic incidence (PI)
3. Pelvic tilt should be  $< 25^\circ$
4. SVA (sagittal vertical axis)- should be within 46mm
5. Frontal or sagittal plane listhesis, 0 cm

Table 2. Take-home messages on radiological measurements.

2.7. Implications of sagittal alignment and spinopelvic parameters for the orthotist managing adolescents with spine deformity

2.7.1. The evolution of orthoses for patients with spinal deformity

Spinal bracing has evolved significantly since the days of Dr. Sayre’s tripod device and Dr. Taylors “spinal assistant,” both notable historical reference points [35]. The ideas that they employed are still found in orthoses designed today. The concepts of spinal elongation, application of pressure to the prominence of the deformity, and “windows” to create areas of relief are still basic concepts of almost all bracing types still used today. This demonstrates to us that we are not starting a new form of treatment but merely using research to advance ideas started long ago. For further reference, please refer to the SRS bracing manual [36].

The pivotal *Bracing in Adolescent Idiopathic Scoliosis trial* (BrAIST) has altered the medical community’s recommendation on bracing in the AIS population. The study was originally designed as a randomized controlled study, but when enrollment goals were not being met, a preference arm was added. This meant that families who opted against randomization were able to choose which group they would like to enter [37]. The study used 44% of patients assigned to the randomized cohort to calculate their intention to treat analysis. They found that the Number Needed to Treat (NNT) in order to prevent one case of curve progression was 3.0 and reduction in relative risk with bracing was 56% [37]. This is no small matter as scoliosis fusion surgery was second only to appendicitis in terms of the total cost in children aged 10–17 years [37, 38]. The BrAIST study linked the success of the brace with more hours of wear time, an average of 17.7 h per day [37].

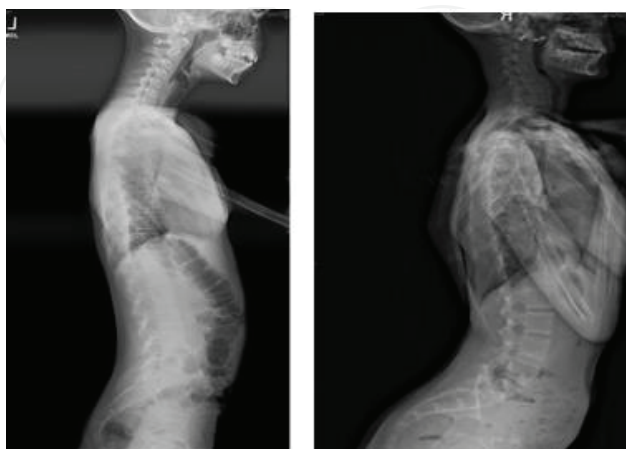
2.7.2. Role of the sagittal profile in scoliosis orthoses—our theory

It has long been known that scoliosis is a three-dimensional deformity, and even in the presence of spinal deformity, the body will try to regain balance. Historically, the focus of intervention has been on the control of the frontal and transverse plane. However, the sagittal plane may play a larger role in spinal deformity than previously suspected. The pelvic incidence parameter, described earlier in this chapter, may be a key factor in driving sagittal alignment and an important factor in brace design [19]. It is known that spinal loading occurs mainly via axial compression. However, vertebral bodies are also subjected to shear forces in an anterior

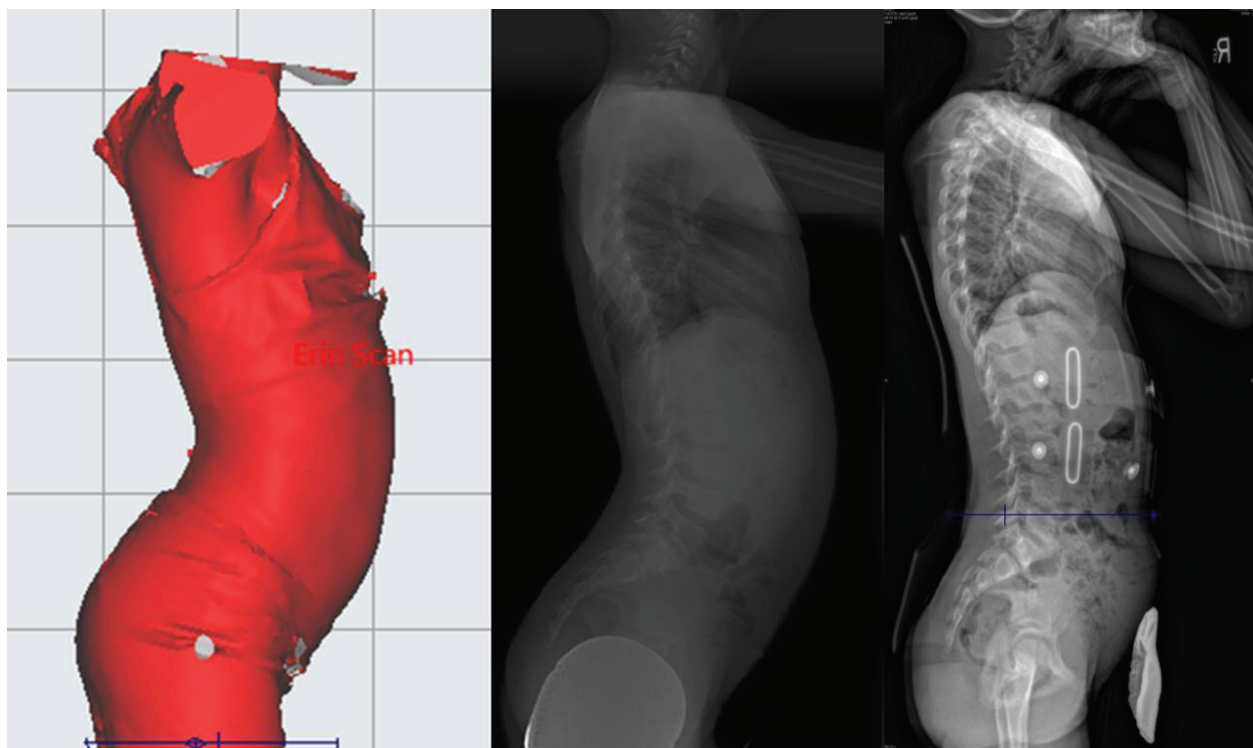
or posterior direction. The more posterior the shear force, the less stable the spine is in rotation [39]. It may be theorized that increased posteriorly directed shear forces increase the risk of scoliotic deformity. A study by Schlosser in 2015 noted that the spines of girls during the peak growth spurt are more posteriorly inclined [40]. If accounting for sagittal forces during the peak growth phase can reduce this rotational instability, it may lead to further efforts both clinically and research-wise to address scoliosis based on parameters in addition to the Cobb angle. It may be, according to the hypothesis of the authors, that an increase in Cobb angle is a reaction to the above-described imbalance and instability. Is it possible to predict at-risk patients based on parameters other than the Cobb angle and treat these patients proactively? These questions warrant more clinical research.

### 2.7.3. Brace construction

Up to now, the goal in orthoses fabrication has been to maintain “normal” lumbar lordosis and kyphosis values. However, there is a wide range of “normal” ranges in pediatrics. The original scoliosis TLSO used  $0^\circ$  of lordosis as its default value. It was noted that orthoses may achieve the same coronal correction with a lumbar lordosis of  $15^\circ$ , which led to increased patient comfort level. This point is referenced in the SRS bracing manual and in an editorial response in which research has proven the original Boston brace set at  $0^\circ$  of lordosis “produced significant curve correction of the spinal deformity in the frontal plane at the expense of a significant reduction of thoracic kyphosis in the sagittal plane” [36, 41] (**Figure 11**). With respect to the sagittal profile, the authors feel it is imperative to match a patient’s individual pelvic incidence to their ideal lumbar lordosis when constructing a brace. In a study using biomechanical modeling, we have the first opportunity to trial several braces on the same patient to observe outcomes based on 15 different design factors [42] (**Figure 12**). This study had some interesting conclusions which may help guide the future of brace treatment.



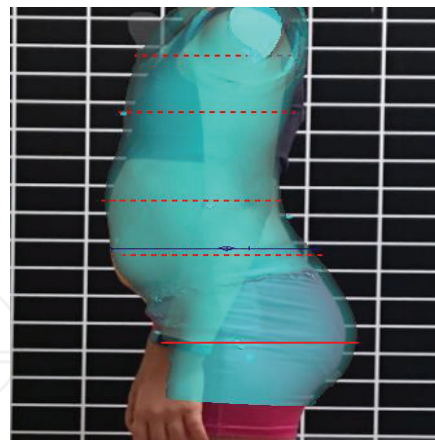
**Figure 11.** It would be difficult to treat both of these patients when using a “standard” amount of lumbar lordosis. Both of these patients require individualized parameters for treatment success.



**Figure 12.** Example of a brace correcting sagittal balance while maintaining thoracic kyphosis.

1. When a thoracic pad was placed in a more posterior position, it controlled axial rotation better but caused decreased kyphosis.
2. Placing pads below the curve apex was not optimal. In a questionnaire of the Society on Scoliosis Orthopaedic and Rehabilitation Treatment (SOSORT) members, 11 of the 21 surveyed said the pad should be at the level of the apex. Ten indicated pad placement below the apex [43].
3. No correlation was found between the reduction of the lordosis and the correction of the coronal curves (**Figure 13**).
4. The reduction of the lordotic profile of the brace only had a negative effect on sagittal curves (hypo-kyphosing and hypo-lordosing). This is actually the way that Schuermans kyphosis is treated with the brace to have the effect of reducing hyper-kyphosis.
5. An asymmetric rigid shell was more efficient in correcting the coronal curves than a symmetric one.
6. Strap position has a great effect on rotational control of the brace. Anterior opening seems to control rotation better.

All of these concepts need to be tested in the real world and on a much larger scale but they are great starting points for developments of new treatments. A global method to assess bracing



**Figure 13.** New digital imaging can be used to match clinical photos and digital X-rays to patient-specific morphology.

is the concept of overall balance summation, but this is only valid in the frontal plane [44]. The implications for sagittal plane malalignment that continues into adulthood have been well documented and discussed in this chapter; therefore, they should also play a part in brace design [27].

In conclusion, further work is needed with regard to the role of the orthotist in treating sagittal deformity in scoliosis patients, and clear protocols need to be developed. This field is ripe for an infusion of new ideas. The paper that found the number to treat to be three patients also reported that this number was only for patients who were considered compliant. It also reads “routine bracing without efforts to maximize brace compliance are likely to be less effective than the brace trial indicates” [45]. It has been suggested that all conservative care centers should make a strong effort to maximize brace compliance and this should be the new routine, or standard of care as Karol has shown in a recent article. Karol’s study demonstrated that if patients engage in compliance counseling, then patients will wear their brace an extra 3 h per day. This increase in bracing compliance also correlated with a decreased surgical rate of 11% [45]. This topic requires further consideration of factors involved in setting up clinics that can handle this portion of treatment.

### 3. Conclusion

This chapter has introduced current concepts and evidence-informed practice patterns around knowledge of sagittal alignment and its implications for the conservative care practitioner managing adults with spinal deformity and for the orthotist managing adolescents with idiopathic scoliosis. Much research and clinical practice lie ahead for practitioners in this field, and it has been the intention of the authors to begin to start a deeper conversation around the role of sagittal alignment in the clinical decision-making process with this unique patient population.

## Acknowledgements

The authors wish to thank the orthopedics department of Columbia University Medical Center, especially Dr. Charla Fischer, and East Coast Prosthetics/Orthotics for their support and expertise in our professional and personal learning journeys, and for the opportunity to work collaboratively for the optimal health of our patients. Additionally, the authors wish to thank Patricia Orthwein, Nicholas Feinberg, and Anas Minkara for their contributions to editing this chapter. Many thanks!

## Author details

Prachi Bakarania<sup>1</sup>, Hagit Berdishevsky<sup>1</sup>, Kelly Grimes<sup>1\*</sup> and John Tunney<sup>2</sup>

\*Address all correspondence to: [kg2648@cumc.columbia.edu](mailto:kg2648@cumc.columbia.edu)

1 Columbia University Medical Center, New York, NY, USA

2 East Coast Orthotics & Prosthetics, New York, NY, USA

## References

- [1] Ailon T, Smith JS, Shaffrey CI, et al. Degenerative spinal deformity. *Neurosurgery*. 2015;**77**(Suppl 4):S75–S91
- [2] Schwab F, el-Fegoun AB, Gamez L, Goodman H, Farcy JP. A lumbar classification of scoliosis in the adult patient: Preliminary approach. *Spine*. 2005;**30**(14):1670-1673
- [3] Schwab FJ, Blondel B, Bess S, Hostin R, Shaffrey CI, Smith JS, et al. Radiographical spino-pelvic parameters and disability in the setting of adult spinal deformity: A prospective multicenter analysis. *Spine*. 2013;**38**(13):E803–E812
- [4] American Physical Therapy Association. Guide to physical therapist practice 3.0. Alexandria: American Physical Therapy Association; 2014. Available from: <http://guidetoptpractice.apta.org/> [Accessed: February 1, 2017]
- [5] Shumway-Cook A, Woollacott MH. Normal postural control. In: Shumway-Cook A, Woollacott MH, editors. *Motor control: Translating research into clinical practice*. 4th ed. Philadelphia: Lippincott Williams and Williams; 2012. pp. 161-194
- [6] Basmajian JV. Man's posture. *Archives of Physical Medicine and Rehabilitation*. 1965;**46**:26-36
- [7] Kendall FP. *Muscles, Testing and Function with Posture and Pain*. 5th ed. Philadelphia: Lippincott Williams & Wilkins; 2005



- [8] Schultz AH. Vertebral column and thorax. *Primatologia*. 1961;**5**:1-66
- [9] Lovejoy CO. The natural history of human gait and posture. Part 1. Spine and pelvis. *Gait Posture*. 2005;**21**(1):95-112
- [10] Neumann DA, *Kinesiology of the Musculoskeletal System: Foundations for Rehabilitation*. 3rd ed. St Louis: Elsevier; 2017
- [11] Staffell F. Die menschlichen Haltungstypen und ihre Beziehungen zu den Buckgratsverkrümmungen. Wiesbaden: J. F. Bergmann; 1889
- [12] Bonne AJ. On the shape of the human vertebral column. *Acta Orthopaedica Belgica*. 1969;**35**(3):567-583
- [13] McMorris RO. Faulty posture. *Pediatric Clinics of North America*. 1961;**8**:213-224
- [14] Roussouly P, Gollogly S, Berthonnaud E, Dimnet J. Classification of the normal variation in the sagittal alignment of the human lumbar spine and pelvis in the standing position. *Spine*. 2005;**30**(3):346-353
- [15] Mac-Thiong JM, Roussouly P, Berthonnaud E, Guigui P. Sagittal parameters of global spinal balance: normative values from a prospective cohort of seven hundred nine Caucasian asymptomatic adults. *Spine*. 2010;**35**(22):E1193-E1198
- [16] Bullock-Saxton JE. Normal and abnormal postures in the sagittal plane and their relationship to low back pain. *Physiotherapy Practice*. 1988;**4**:94-104
- [17] During J, Goudfrooij H, Keessen W, Beeker TW, Crowe A. Toward standards for posture. Postural characteristics of the lower back system in normal and pathologic conditions. *Spine*. 1985;**10**(1):83-87
- [18] Potter BK, Lenke LG, Kuklo TR. Prevention and management of iatrogenic flatback deformity. *Journal of Bone and Joint Surgery-American Volume*. 2004;**86-A**(8):1793-1808
- [19] Legaye J, Duval-Beaupere G, Hecquet J, et al. Pelvic incidence: A fundamental pelvic parameter for three-dimensional regulation of spinal sagittal curves. *The European Spine Journal*. 1998;**7**:99-103
- [20] Schwab F, Ungar B, Blondel B, et al. Scoliosis Research Society—Schwab adult spinal deformity classification: A validation study. *Spine*. 2012;**37**(12):1077-1082
- [21] Lafage V, Schwab F, Patel A, et al. Pelvic tilt and truncal inclination two key radiographic parameters in the setting of adults with spinal deformity. *Spine*. 2009;**34**(17):E599-E606
- [22] Joseph SA, Jr, Moreno A, Brandoff J. Sagittal plane deformity in the adult patient. *The Journal of the American Academy of Orthopaedic Surgeons*. 2009;**17**:378-388
- [23] Hu P, Yu M, Sun Z, Li W, Jiang L, Wei F, Li, X, Chen Z, Liu Z. Analysis of global sagittal postural patterns in asymptomatic Chinese adults. *Asian Spine Journal*. 2016;**10**(2):282-288
- [24] Lamartina C, Berjano P. Classification of sagittal imbalance based on spinal alignment and compensatory mechanisms. *European Spine Journal*. 2014;**23**:1177-1189

- [25] Senteler M, Weisse B, Snedeker JG, Rothenfluh DA. Pelvic incidence-lumbar lordosis mismatch results in increased segmental joint loads in the unfused and fused lumbar spine. *European Spine Journal*. 2014;**23**(7):1384-1393
- [26] Bernhardt M, Bridwell KH. Segmental analysis of the sagittal plane alignment of the normal thoracic and lumbar spines and thoracolumbar junction. *Spine (Phila Pa 1976)*. 1989;**14**(7):717-721
- [27] Glassman SD, Bridwell K, Dimar JR, et al. The impact of positive sagittal balance in adult spinal deformity. *Spine*. 2005;**30**(18):2024-2029
- [28] Terran J, Schwab F, Shaffrey CI, Smith JS, Devos P, Ames CP, Fu KM, Burton D, Hostin R, Klineberg E, Gupta M, Deviren V, Mundis G, Hart R, Bess S, Lafage V. The SRS-Schwab adult spinal deformity classification: Assessment and clinical correlations based on a prospective operative and nonoperative cohort. *Neurosurgery*. 2013;**73**(4):559-568
- [29] Schwab F, Farcy JP, Bridwell K, et al. A clinical impact classification of scoliosis in the adult. *Spine (Phila Pa 1976)*. 2006;**31**(18):2109-2114
- [30] Schwab F, Lafage V, Farcy JP, et al. Surgical rates and operative outcome analysis in thoracolumbar and lumbar major adult scoliosis: Application of the new adult deformity classification. *Spine (Phila Pa 1976)*. 2007;**32**(24):2723-2730
- [31] Berjano P, Aebi M. Pedicle subtraction osteotomies (PSO) in the lumbar spine for sagittal deformities. *European Spine Journal*. 2015;**24**(Suppl 1):S49-S57
- [32] Morris WZ, Fowers AC, Yuh RT, Gebhart JJ, Salata MJ, Liu RW. Decreasing pelvic incidence is associated with greater risk of cam morphology. *Bone and Joint Research*. 2016;**5**:387-392
- [33] Berdishevsky H, Lebel VA, Bettany-Saltikov J, Rigo M, Lebel A, Hennes A, Romano M, Białek M, M'hango A, Betts T, de Mauroy JC, Durmala J. Physiotherapy scoliosis-specific exercises—A comprehensive review of seven major schools. *Scoliosis and Spinal Disorders*. 2016;**11**:20
- [34] Zampini JM, Sherk HH. Lewis A Sayre: The first professor of orthopedic surgery in America. 2007;**466**:2263-2267
- [35] Scoliosis Research Society. SRS Bracing Manual [Internet]. Photovoltaic Modules [Internet]. 2014. Available from: <http://www.srs.org/professionals/online-education-and-resources/srs-bracing-manual> [Accessed: March 30, 2017]
- [36] Weinstein SL, Dolan LA, Wright JG, Dobbs MB. Effects of bracing in adolescents with idiopathic scoliosis. *New England Journal of Medicine*. 2013;**369**:1512-1521
- [37] HCUP Kids' Inpatient Database (KID). Healthcare Cost and Utilization Project (HCUP). Rockville: Agency for Healthcare Research and Quality; 2009. Available from: <http://www.hcup-us.ahrq.gov/kidoverview.jsp>
- [38] Kouwenhoven JW, Smit TH, van der Veen AJ, Kingma I, van Dieën JH, Castelein RM. Effects of dorsal versus ventral shear loads on the rotational stability of the thoracic



spine: A biomechanical porcine and human cadaveric study. *Spine (Phila Pa 1976)*. 2007;**32**:2545-2550

- [39] Schlösser TP, Vincken KL, Rogers K, Castelein RM, Shah SA. Natural sagittal spinopelvic alignment in boys and girls before, at and after the adolescent growth spurt. *European Spine Journal*. 2015;**24**(6):158-167
- [40] Labelle H, Dansereau J, Bellefleur C, Poitras B. Three-dimensional effect of the Boston brace on the thoracic spine and rib cage. *Spine (Phila Pa 1976)*. 1996;**21**(1):59-64
- [41] Clin J, Aubin CE, Parent S, Sangole A, Labelle H. Comparison of the biomechanical 3D efficiency of different brace designs for the treatment of scoliosis using a finite element model. *European Spine Journal*. 2010;**19**(7):1169-1178
- [42] Rigo M, Negrini S, Weiss HR, Grivas TB, Maruyama T, Kotwicki T. SOSORT consensus paper on brace action: TLSO biomechanics of correction (investigating the rationale for force vector selection). *Scoliosis*. 2006;**1**:11
- [43] Carlson M, Smith M. Description for new overall balance: Summation for the conservative treatment of idiopathic scoliosis in determining orthosis design. *Academy Today*. 2007;**3**:A-13-A-15
- [44] Sanders JO, Newton PO, Browne RH, Katz DE, Birch JG, et al. Bracing for idiopathic scoliosis: how many patients require treatment to prevent one surgery? *Journal of Bone and Joint Surgery-American Volume*. 2014;**96**:649-653
- [45] Karol L, et al. Effect of compliance counseling on brace use and success in patients with adolescent idiopathic scoliosis. *Journal of Bone and Joint Surgery-American Volume*. 2016;**98**(1):9-14