

We are IntechOpen, the world's leading publisher of Open Access books Built by scientists, for scientists

6,900

Open access books available

186,000

International authors and editors

200M

Downloads

Our authors are among the

154

Countries delivered to

TOP 1%

most cited scientists

12.2%

Contributors from top 500 universities



WEB OF SCIENCE™

Selection of our books indexed in the Book Citation Index
in Web of Science™ Core Collection (BKCI)

Interested in publishing with us?
Contact book.department@intechopen.com

Numbers displayed above are based on latest data collected.
For more information visit www.intechopen.com



Limits of Normality and Symmetry in Standing Back Shape and Posture: 3D Mapping and Analysis of Young Adults

Josette Bettany-Saltikov,
Gokulakannan Kandasamy, Dariusz Czaprowski and
Lukasz Stolinski

Additional information is available at the end of the chapter

<http://dx.doi.org/10.5772/intechopen.69575>

Abstract

Abnormalities of posture are a common cause of pain and disability. Objective measurement systems for postural evaluation are not widely accessible in the UK especially on the National Health Service. Within physiotherapy practice one of the most common methods of assessing posture and/or back shape is by visual observation which is prone to error and lacks objectivity. The study has sought to produce normative values for back shape and posture indices in young asymptomatic adults. A convenience sample of 100 Teesside University (TU) students were recruited. This study used a 3-D Digitizer. Data was analyzed using SPSS. The acromion and the inferior scapular angle in the dorsal frontal plane differed between the right and left shoulders of the back in females. The distance between the inferior angle of the scapula and the apical thoracic vertebrae also differed. No other statistically significant differences were found in distances between key landmarks. Overall young adults are very symmetrical. Frontal plane angles showed that overall healthy young adults have relatively straight spines. The left inferior angle of the scapula in females was found to be rotated anteriorly in comparison to the right shoulder. Results will provide a normative database for clinicians who routinely assess back posture.

Keywords: posture, assessment, gender differences, normative values, digitizer

1. Introduction

Abnormalities of back shape and posture are a common cause of pain and disability with the range of effect from discomfort to incapacitating disability being related to both the **severity**

as well as to the **persistence** of the faults [1]. While the terms “back shape” and “back posture” are sometimes used interchangeably it is important to be clear of what precisely is meant by each term. The focus of the term “posture” is on **muscular and skeletal balance** as seen from the definition provided by the American academy of orthopedic surgeons. The society define “good” posture as “that state of muscular and skeletal balance which protects the supporting structures of the body against injury or progressive deformity irrespective of the attitude [sitting, lying erect] in which these structures are working or resting.” Under such conditions the muscles will function most efficiently and the optimum positions are afforded for the thoracic and abdominal organs [2].”

The focus of the term “back shape” on the other hand is on the **back surface** and generally refers to the surface topography of the back. “Topography [from Greek topo-, “place,” and graphia, “writing”] is the study of the back’s surface shape and includes the measurement of parameters that may or may not be similar to those measured for back posture.” For instance, thoracic kyphosis and lumbar lordosis are usually measured when assessing both back shape and back posture.

The measurement of the surface equivalent of the spinal curvature [Cobb angle] in the frontal plane, however is usually measured solely during the assessment of spinal deformities within orthopedic clinics or private practices. A further key difference is that different professional health practitioners traditionally use different terminologies. Spinal deformity clinics within orthopedic medical practice generally refer to back shape whereas within physiotherapy practice the term ‘posture’ is usually the term of choice.

The assessment of back shape and posture is common practice in a number of disciplines within rehabilitation [1]. Within physiotherapy practice one of the most common methods of assessing posture and/or back shape is by visual observation of standing posture as viewed from the back and sides and is a routine part of all back assessments for patients with low back pain and/or spinal dysfunctions. Kipling et al. [3] in a survey on Common methods of assessing posture in Physiotherapy practice, found that up to 82% of physiotherapists reported using observation alone to evaluate patients posture.

A more recent survey was developed very recently in 2016 by Johnson et al. [4] who created the “The Postural Assessment Survey.” The authors surveyed a group of manual therapists (chiropractors, physical therapists, osteopaths and sports therapists) to ascertain whether or not they actually used postural assessment within their practice, and if so what type of assessment they used. 432 therapists answered the question about which method of postural assessment they used. The large majority of therapists (98.15% n = 424) said that they used visual postural assessment.

Back shape/postural assessment is also part of the clinical examination for patients with spinal deformities in musculoskeletal clinics. Within Physiotherapy and Orthopedic clinical settings, the parameters evaluated may differ. Physiotherapists primarily evaluate asymmetries in standing back posture at four key areas; the shoulder level, scapular level, pelvic level and the posterior superior iliac spines (PSIS) levels [5]. In the orthopedic setting however

the assessment of back shape and posture is predominantly focused on the assessment of the skeletal measurement of spinal curvature on x-ray together with the measurement of the maximum trunk inclination values in forward bending [5].

Normative values of back shape and posture values may assist in classifying back shape types and provide normal ranges of different back surface parameters for the purpose of research or clinical decision making.

Two key studies in this area are those by Bettany-Saltikov [6] and Duff and Draper [7]. Bettany-Saltikov conducted a study evaluating normal back shape in young adults using the Integrated spinal imaging system (ISIS1). This is an optical computer system that is able to measure the 3D surface topography of the back. We were able to produce a representative scan for the interpretation of the back shape for all participants included in the study. This study found a mean *thoracic kyphosis* of 24.9 mm (median 24 mm, deciles: 6.8–47.2 mm). The thoracic kyphosis values found in this group of young adults are very similar to the children in Duff and Draper's study [7] who reported a median value for thoracic kyphosis of 27.8 mm (17–40 mm).

Carr et al. [8] reported these values in degrees and therefore values were not directly comparable. In this study the mean *lumbar lordosis* was 14.9 mm (median 14 mm). The lumbar lordosis values were found to be greater in Saltikov's study [6] that evaluated young adults compared to the Duff and Draper study (median 9 mm) that evaluated children. This suggests the possibility that lumbar lordosis may increase during growth from young adolescence to young adulthood. Carr et al. [8] however reported no significant differences in lumbar lordosis angles between children and adults. It is possible that these changes may be due to variables such age, race and other population differences.

Duff and Draper [7] conducted a survey of back shape in children using the Integrated spinal imaging system (ISIS1). with a sample of 105 boys and 101 girls, with an age range of 12.28–13.69 years. It was noted by the authors that these parameters were specific to the age group of the subject's used. Duff and Draper [7] also commented on the need for a standardized value for what should be considered a "normal" degree of back shape and spinal curvature that may be used as a reference against which back posture and shape parameters can be measured in young teenagers.

Within both fields therefore uncertainly still remains as to what constitutes "normality" within the context of standing back shape and/or posture. More pertinently the question remains "what are the limits of normality in standing back shape and posture?" In other words, how do physiotherapists and other clinicians know when a patient's posture is abnormal, if the ranges of normality are not known? Knowledge of what actually constitutes normality would significantly benefit clinicians in this field as it would enable them to decide when postural retraining exercises or other treatment modalities are warranted.

A further problem with regards to the quantification of back shape is that no boundaries of "normality" have been established that are *universally accepted*. Sahrman [9] comments on

the need for establishing normative values with standard deviations for spinal curvature that would benefit the analysis of extreme variations of spinal alignment and better inform the clinician as to the nature of the condition as a whole. However, in the literature while numerous spinal deformities have been defined, sparse information is available on the quantification of normal back parameters in standing. Kawchuk and McArthur comment that the primary limitation in the study and treatment of scoliosis is the lack of an accurate, reliable, convenient and completely safe form of scoliosis quantification [10]. Indeed, normative data of standing back shape and posture for comparison and reference in young adults is not currently available.

2. Objectives

1. To identify the limits of normality and symmetry/asymmetry of back shape and posture in a group of healthy young male and female subjects (i.e., to establish normative reference values).
2. To evaluate the symmetry/asymmetry between key anatomical landmarks and distances between the left and right sides of the back in normal young female and male subjects.
3. To compare back shape and posture in normal young males and females.

3. Materials and methods

3.1. Subjects

A convenience sample of 100 TU students were recruited for this study ($n = 59$ females and 41 males). Their ages ranged from 18 to 40 years old. Subjects were excluded if they had any lower limb or back injury that prevented the subject standing for the duration of data collection, any vestibular problems that prevented the subject maintaining normal balance for the duration of data collection or a known allergy to self-adhesive stickers when in contact with the skin. Ethical approval was granted by Teesside University School of Health and Social Care ethics committee.

3.2. Instrumentation

The Middlesbrough Integrated Digital Assessment System (MIDAS) (**Figure 1**) is a tool for acquiring a static 3-D computer recording of a physical object. A counterbalanced mechanical arm has optical sensors in each joint for X, Y, Z coordinate awareness with a mean accuracy of 0.23 mm. A footplate was created with marks to standardize foot position and a chart was placed on the wall in front of the subject with markers to focus on [11–13].

Through assessment with an anatomical mannequin this system demonstrated very high intra-rater reliability ($ICC > 0.999$, $p < 0.0001$) [12], with a sample of 50 human subjects ($r = 0.92$ – 0.99 , $p < 0.001$). Further intra and inter rater reliability were also found excellent when evaluated by McAlpine et al. [14]. Additionally previous work has found improvements




Figure 1. The microscribe digitizer in resting position.

in repeat measurements with foot and vision standardization [10]. The MIDAS was placed on an adjustable tripod for positioning and connected via a serial port to a laptop PC for data storage. A set of scales and a stadiometer were used to obtain weight and height measurements of subjects.

3.3. Procedure

Subjects read the subject information sheet and after consenting to participate were attired so that their back was visible for landmark identification. Subjects stood and fixed their vision to a point on a wall chart, in agreement with other studies of postural assessment tools [14]. The landmarks used were identical to those used in previous MIDAS studies [11, 15]. Landmarks were identified as shown in **Table 1**. Selection of anatomical landmarks.

The landmarks above were carefully chosen from current clinical methods, back shape studies as well as studies related to spinal deformities [16]. The intention was to produce a map of the back for cervical, thoracic and lumbar regions that enabled the two sides of the back to be identified and produced a “normal” back shape profile in three dimensions. To date it is still unclear what “normal” back shape is although attempts have been made in school children [8]. The spinal vertebrae chosen were those at the ends of the apices of each curve, i.e., VP TA and T12 in the cervical thoracic and lumbar regions. For landmarks on either side of the back, bony points were chosen that were as far from the spine as possible to enable a total picture of back shape to be produced. It needs to be remembered that this is a work in progress and changes could be made in future in response to the results obtained.

Data collection involved the tester touching the MIDAS stylus tip to each of the marked points in a standardized order dictated by the software and pressing the foot pedal of the MIDAS to store the position on the computer. Data was analyzed using the Statistical Package for Social Sciences (SPSS) version 23.

Label	Anatomical point
AL	Left acromion processes
AR	Right acromion process
SL	Left inferior angle of scapulae
SR	Right inferior angle of scapulae
ICL	Left iliac crest
ICR	Right iliac crest
PSL	Left posterior superior iliac spine
PSR	Right posterior superior iliac spine
C2	2nd cervical vertebra
CA	Anterior cervical vertebra
VP	Vertebra prominens
TA	Anterior thoracic vertebra
T12	12th thoracic vertebra
LA	Anterior lumbar vertebra
SA	Sacral point

Table 1. Key to standing back anatomical landmarks measured.

4. Results

4.1. Frontal plane values

4.1.1. Mean distances between key anatomical landmarks in male and female subjects

In the frontal plane, the mean distances between key anatomical landmarks can be seen in **Table 2**. The only statistically significant differences found between the two sides of the back in females were the distances between the acromion and the inferior scapular angle; with the right side distance (AR-SR) being significantly smaller than the left side distance AL-SL as seen in **Figure 2**. The other statistically significant difference found was between the inferior angle of the scapula and the apical thoracic vertebrae. For this parameter the right side distance (TA-SR) was significantly greater than the left sided value (TA-SL). No other significant differences in the distances between key anatomical landmarks between the left and right sides of the back were found. Further no significant differences were found for all key anatomical landmark distances in male subjects between the two sides of the back. The mean female and male distances and standard deviations on the left and right sides of the back can be seen in **Tables 2** and **3**. The back landmarks positions and representation of key anatomical landmarks on a mannequin are presented in **Figures 3** and **4**. Normative values of analysed parameters can be seen in **Tables 4** and **5**.

Frontal plane back shape distances between key anatomical landmarks for female subjects	Female left side (mm and SD)	Male left side (mm and SD)	Female right side (mm and SD)	Male right side (mm and SD)	Mean diff between left and right side distances mm		P value	
					F	M	F	M
Distance between vertebra prominans and the acromion (VP-AL; VP-AR)	174.6 ± 16.6	195.2 ± 26.2	171.9 ± 14.2	198.2 ± 29.1	2.7	3.12	NS	NS
Distance between the acromion and the inferior scapula	175.9 ± 12.1	191.1 ± 14.4	171.3 ± 16.7	190.1 ± 14.8	4.6	0.97	0.003	NS
Distance between the inferior scapular angle and iliac crest	221.3 ± 18.9	234.8 ± 28	220.7 ± 21.8	238.9 ± 33.1	0.5	-4.14	NS	NS
Distance between the iliac crest and the PSIS	63.8 ± 17.9	73.4 ± 58.3	63.5 ± 17.8	63.7 ± 19.7	.33	9.61	NS	NS
Distance between the PSIS the sacral point	55.1 ± 11.9	59.7 ± 12.08	53.8 ± 12.8	60.4 ± 21.4	1.24	-0.65	NS	NS
Distance between the inf. angle of the scapula and the apical thoracic vertebrae	88.4 ± 12.2	116.7 ± 54.2	92.3 ± 13.5	115.9 ± 30.8	3.96	.75	0.046	NS
Distance between the iliac crest and the lumbar apical vertebra	65.8 ± 19.8	76.8 ± 47.3	65.4 ± 16.9	71.1 ± 25.5	0.46	5.72	NS	NS

Table 2. The distance between the acromion and the inferior scapula on the left side is statistically longer than the right side and the distance between the inf. angle of the scapula and the apical thoracic vertebrae on the right side is significantly longer on the right side than on the left side.

4.1.2. Differences in female and male height values between the left and right sides of the back for key anatomical landmarks in the frontal plane

The set of values below **Table 3** refers to the differences in height levels between specific key anatomical landmarks on the two sides of the back. The only significant differences found were at the level of the shoulders; The left shoulder acromion was significantly higher than the right (AL > AR). Otherwise no other statically significant differences were found at the levels of the inferior scapular angle, the iliac crests and the PSIS. In males there were no stat sign difference at any level, however at the PSIS level the left PSIS showed a trend toward being higher than the right PSIS

4.2. Dorsal frontal plane spinal angles

The mean frontal plane angles values showed that overall healthy young adults have relatively straight spines. The mean thoracic curvature value was +2.38° and the mean lumbar curve was +1.65°.

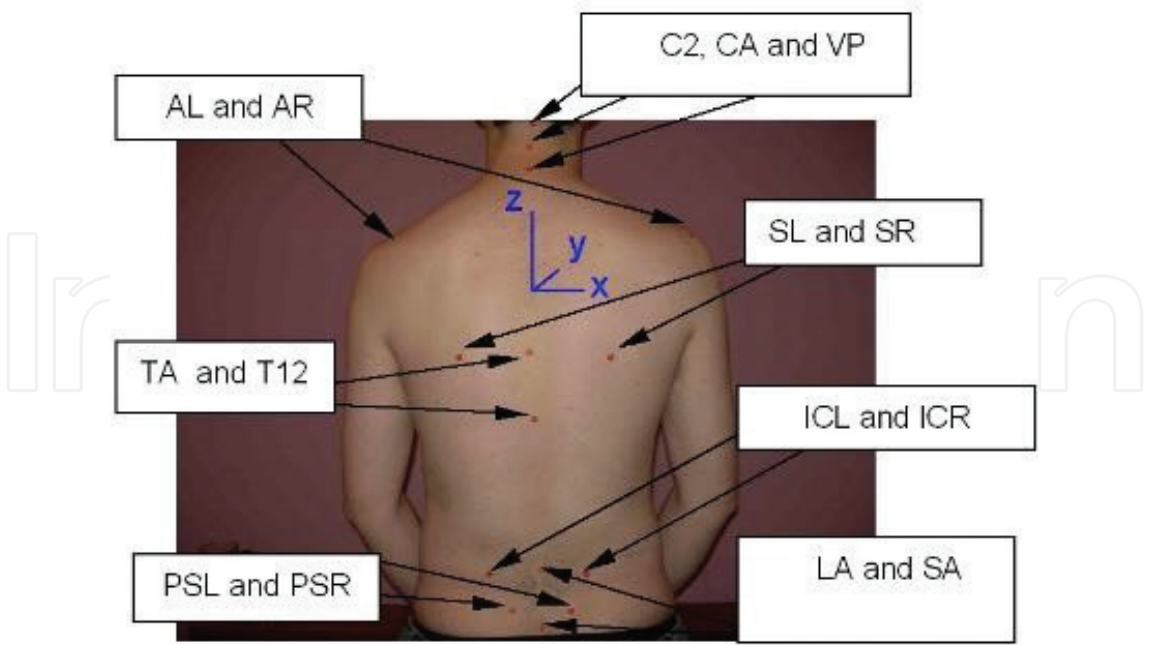


Figure 2. Back landmarks identified with self-adhesive marker.

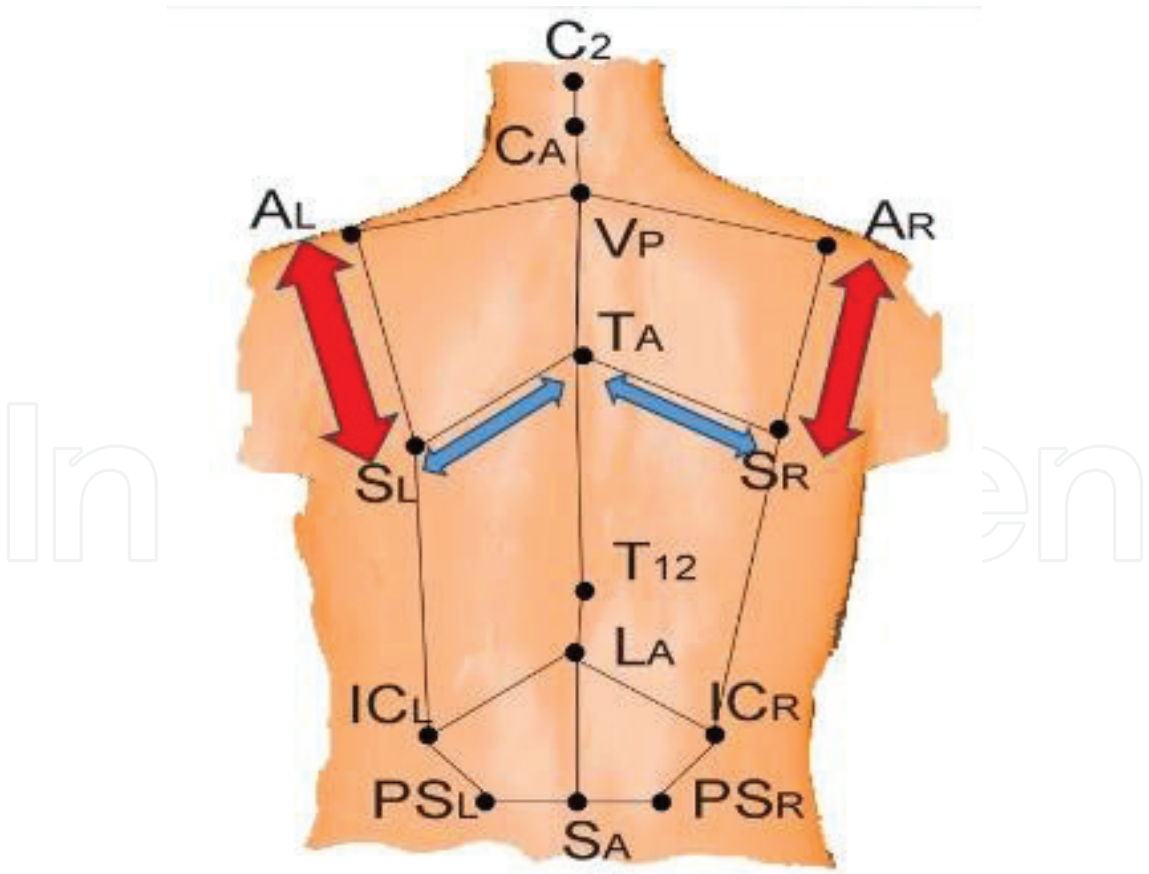


Figure 3. Representation of key anatomical landmarks on a mannequin, with a description below.

1. AL is higher than AR in the frontal plane

2. Distance AL-SL greater on left side than on right side

3. Right side distance (TA-SR) was significantly greater than the left sided value (TA-SL) for females

4. No significant differences were found for all key anatomical landmark distances in male subjects between the two sides of the back

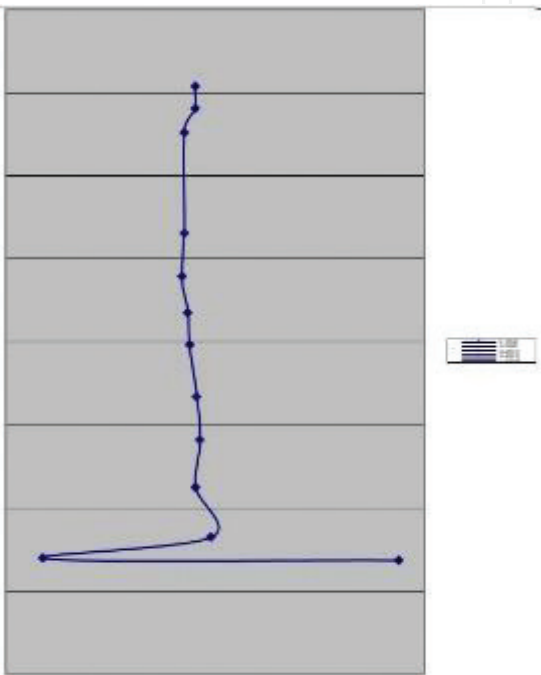


Figure 4. Frontal plane lateral asymmetry value for one female subject [surface equivalent to Cobb angle].

Differences in height levels between the two sides of the back in males and females Left side minus right side	Females			Males		
	Height difference and SD in mm	95% CI of the difference	P value	Height difference and SD in mm	95% CI of the difference	P value
Shoulder level (acromium) ALz-ARz	4.48 ± 10.98	1.63–7.35	.003	−1.34 ± 13.07	−5.71 to 3.01	NS
Inf. angle of scapula SLz-SRz	0.12 ± 7.6	−1.86 to 2.11	NS	−2.43 ± 9.06	−5.44 to 0.59	NS
Iliac crests ICLz-ICRz	−0.22 ± 7.2	−2.24 to 1.78	NS	−5.7 ± 9.11	−3.61 to 2.47	NS
PSIS PSLz-PSRz	0.53 ± 4.10	−5.3 to 1.6	NS	1.38 ± 4.91	−0.25 to 3.02	NS (0.09)

Table 3. Differences in height levels between the two sides of the back in males and females.

Mean spinal distances between spinal anatomical landmarks in the frontal plane	Mean values and SD in mm	
	For female subjects	For male subjects
Distance between C2 and the apical cervical vertebra CA	27.9 ± 8.1	44.2 ± 73.5
Distance between the apical cervical vertebra and the vertebra prominens	49.5 ± 29.7	66.6 ± 41.8
Distance between the vertebra prominens and the thoracic apical vertebra	371.0 ± 51.2	388.6 ± 67.6
Distance between the thoracic apical vertebra and the 12th Thoracic vertebra	227.9 ± 32.6	241.1 ± 40.6
Distance between the 12th Thoracic vertebra and the lumbar apical vertebra	90.5 ± 29.6	88.9 ± 40.7
Distance between the lumbar apical vertebra and the sacral point	89.5 ± 25.8	96.3 ± 27.5

Table 4. Normative values for the mean spinal distances between spinal anatomical landmarks in the frontal plane for female and male subjects.

Differences in depth levels between the two sides of the back in males and females Left side minus right side	Females			Males		
	Height difference and SD in mm	95% CI mm of the difference in mm	P value	Height difference and SD in mm	95% CI of the difference in mm	P value
Shoulder level (acromium) ALy-ARy	5.85 ± 40.05	-4.58 to 16.29	NS	11.55 ± 34.9	-0.10 to 23.19	P = 0.05
Inf. angle of scapula SLy-SRy	5.82 ± 23.24	-0.23 to 11.88	P = 0.05	6.22 ± 18.64	0.01 to 12.44	P = 0.05
Iliac crests ICLy-ICRy	2.08 ± 13.81	-1.52 to 5.69	NS	-0.298 ± 34.2	-14.41 to 8.45	NS
PSIS PSLy-PSRy	2.45 ± 13.84	-1.15 to 6.06	NS	3.29 ± 12.54	-0.89 to 7.47	NS

Table 5. Female and male normative values and mean differences between the left and right side of the back in the horizontal plan.

4.3. Horizontal plane values (rotation)

The left inferior angle of the scapula in females was rotated forward in comparison to the right shoulder. No other statistically significant differences at the acromium, iliac crests or PSIS were found (see **Table 5**).

4.4. Sagittal plane values for female and male subjects

The mean thoracic kyphosis angle was $29.37 + 3.94^\circ$ and the mean lumbar lordosis angle was -37.7 .

5. Discussion

The purpose of this study was to produce normative data for asymptomatic standing back shape and posture in young adults, against which significant postural deformity could be defined. Although numerous commercial optical and computer systems are available [17–20] data on normal adolescent and adult back shape have so far been scarce [12, 13]. This will affect the clinical certainty with which we can establish an observed spinal curve as abnormal and therefore be able to initiate appropriate treatment.

Overall young adults in the current study were very symmetrical. The mean distances between the left and right sides of the back and the average values were calculated. Overall only the distance between the scapula and the acromion process was significantly smaller on the right side than the left side of the back. It is possible that this is related to the fact that most subjects were right handed and asymmetry can be related to the upper limb dominance influence. In a typical posture pattern the right shoulder is lower than left in right-handed people [1, 21]. Additionally, as the body is not perfectly symmetrical, some deviations may have no clinical implications [5].

“Normal” standing posture is generally described as one with a straight back and no trunk asymmetries [22]. Comparison between studies using quantitative results is difficult because of the wide diversity of tools used within other studies. A further challenge is that different quantitative variables have been measured in different studies through different approaches; for example, the different back shape instruments that have been used in previous studies, such as non-tactile optoelectronic systems like the formetric and ISIS2 systems where a light beam is shone onto the back [23–25]. The microscribe digitizer used in this study is a tool for acquiring a static 3-D computer recording of a physical object based on optical sensors in each joint of the instrument and is capable of measuring all three X, Y, Z coordinates. The methods for measuring angles or distance used by these different systems has meant that comparison of “normal” values between different systems is very difficult as the individual parameters are calculated in different ways.

With regards to the methodological aspects of this study, the sample size of 100 individuals comprised a homogenous population of young adults. The results have provided a template or framework of the range and limits of normative values for specific back variables of young adults in a standing posture. We acknowledge that a hundred subjects is not usually considered to be a large sample size and agree that a larger sample size of a few hundred subjects would have increased the external validity of this study (the degree to which the results can be transferred to the general population of young adults).

The other statistically significant difference was the distance between the inferior angle of the scapula and the apical thoracic vertebrae. For this parameter the right side distance was significantly greater than the left sided value. No other significant differences in the distances between key anatomical landmarks between the left and right sides of the back were found in females. For male subjects however no statistically significant differences were found between the left and right sides of the back for all the key anatomical landmark distances. To the best of our

knowledge no similar studies using the Microscribe have been conducted that have measured similar variables so it was not possible to compare the results of this study with previous studies.

In the frontal plane the key difference in height levels between specific key anatomical landmarks on the two sides of the back was at the level of the shoulders; the left shoulder acromion was found to be significantly higher than the right. Further, no statistically significant differences were found at the levels of the inferior scapular angle, the iliac crests and the PSIS. In males there were no statistically significant differences between the two sides of the back. However, at the PSIS level, the left PSIS showed a trend toward being higher than the right PSIS.

With regards to the measurement of the frontal plane spinal angles, the mean frontal plane angles values showed that overall healthy young females have relatively straight spines. As stated previously, in this current study the mean thoracic curvature value was $+2.38^\circ$ and the mean lumbar curve was $+1.65^\circ$. This supports the textbook “Ideal” of adults having a relatively straight spine [1]. These results however differ to the results we obtained previously using the surface topography equipment ISIS to measure a similar cohort of young adult students [6]. In this study, the mean thoracic curvature value found was $16.1^\circ + 6.9^\circ$ and the mean lumbar curvature value was $13.4^\circ + 6.9^\circ$. It is the authors belief that the differences in values obtained from the ISIS2 scanner and the microscribe digitizer are due to the fact that the ISIS2 scanner has previously been shown to overestimate the magnitude of small curves [26].

In our study and in this population of young asymptomatic adults we found a mean thoracic kyphosis of 29.37° and lumbar lordosis of -37.7° in the sagittal plane. These values support the values provided by the Scoliosis Research Society who suggest that the normal range of thoracic kyphosis is between 20 and 40° on X-ray measurement [18, 26]. Our results also support the study by Betz [27] who found that the normal range for lumbar lordosis on X-ray ranged between -20 and -60° . Propst-Proctor and Bleck and Stagnara et al. evaluated the sagittal profile of a group of normal subjects aged 20–29 years old [28, 29]. The mean values of thoracic kyphosis ranged from 30 to 50° and the mean values of lumbar lordosis was calculated to be 55° which was greater than the lumbar lordosis in our group of subjects.

Bernhardt and Bridwell [30] conducted a segmental analysis of sagittal plane alignment of the normal thoracic and lumbar spines as well the thoracolumbar junction on X-rays. Within this study a wide range of healthy subjects ($n = 102$) aged between 5 and 29 years old were included. The authors reported a mean value of thoracic kyphosis at 40° , and mean of lumbar lordosis at -44° . While the thoracic Kyphosis in our study support the results obtained in the Bernhardt study, the lumbar lordosis reported in the Bernhardt study is much higher than the mean lumbar lordosis in our study. This may possibly be attributed to the fact that Bernhardt study included a wide range of ages comprised of children, adolescents and adults.

6. Limitations

The Microscribe is a manual measurement tool and although is very easy to use in a research setting it is not really ideal to use in a clinical setting at the current time. More research

as well as instrument development is needed before this Microscribe can be used within a clinical setting. It should be particularly well suited to use in small clinical units owing to its simplicity of operation, size and cost. In today's climate of evidence based medicine there is an increasing emphasis on objective assessment to monitor treatment effectiveness. Our results stress the need for clinicians to objectively assess back shape and posture in three dimensions, as our study shows that changes in one dimension are associated with changes in other dimensions.

Future studies should focus on measuring normal back shape and posture throughout the life cycle as well as evaluating the effectiveness of different management strategies on back shape and posture. This is necessary to provide a positive shift toward a more objective and evidence based profession. More work is necessary to determine an appropriate set of clinically relevant measures to be implemented for use in clinical practice.

7. Conclusions

Ranges for normality of back shape and posture suggest that overall young asymptomatic males and females are very symmetrical, with the exception of shoulder values in young females. The normative ranges provided should help clinicians decide when postural retraining exercises or conservative treatment is warranted.

The results will also provide a normative database for clinicians (physiotherapists, chiropractors, spinal surgeons) who routinely assess back posture. Additionally, this method of assessment will provide an evidenced based objective alternative to other crude methods of assessment or just "eyeballing" back posture during clinical evaluation. Accurate recording of intervention or efficacy of treatment, if scientifically based on reliable measures can be used to credibly validate treatment effectiveness.

Author details

Josette Bettany-Saltikov^{1*}, Gokulakannan Kandasamy², Dariusz Czaprowski^{3,4} and Lukasz Stolinski⁵

*Address all correspondence to: j.b.saltikov@tees.ac.uk

1 School of Health and Social Care, Teesside University, Victoria Road, Middlesbrough, UK

2 School of Social Sciences Business and Law, Teesside University, Middleborough, UK

3 Department of Physiotherapy, Józef Rusiecki University College, Olsztyn, Poland

4 Center of Body Posture, Olsztyn, Poland

5 Spine Disorders and Pediatric Orthopedic Department, University of Medical Sciences, Poznan, Poland

References

- [1] Kendall FP, McCreary EK, Provance PG, Rodgers MM, Romani WA. *Muscles; Testing and Function with Posture and Pain*. Seoul. Hanmi Medical Publishing Co.; 2006
- [2] Core Standards of Physiotherapy Practice, London. The Chartered Society of Physiotherapy. 2000;**10**:1c
- [3] Kipling Kay, Bettany-Saltikov J. *Survey of Postural Assessment by Physiotherapists*. Teesside University, Middlesbrough. 2001
- [4] Johnson Jane, Bettany-Saltikov, Josette Newell, David Van-Schaik, Paul; Cordry J. *The Postural Assessment Survey*, Teesside University, Middlesbrough. 2017
- [5] Magee DJ. *Orthopedic Physical Assessment*. Elsevier Health Sciences, Missouri. 2014
- [6] Saltikov JA, Van Schaik P, Bell JA, Warren JG, Wojcik AS, Papastefanou SL. 3D back shape in normal young adults. *Studies in Health Technology and Informatics*. 2002;**88**:81-85
- [7] Duff ES, Draper R. Survey of normal adolescent back shape as measured by ISIS. Stokes, Pekelsky IF, Moreland, M S *Surf Topogr Spinal Deform IV*. Stuttgart, New York: Gustav-Fisher; 1987. pp. 163-169
- [8] Carr AJ, Jefferson RJ, Turner-Smith AR, Beavis A. An analysis of normal back shape measured by ISIS scanning. *Spine (Phila, Pa 1976)*. 1991;**16**(6):656-659
- [9] Sahrman SA. Does postural assessment contribute to patient care? *Journal of Orthopaedic & Sports Physical Therapy, Inc. JOSPT* 2002;**32**(8):376-379
- [10] Kawchuk G, McArthur R. Scoliosis quantification: An overview. *The Journal of the Canadian Chiropractic Association*. 1997;**41**(3):137
- [11] Warren JG, Bettany-Saltikov JA, van Schaik P, Papastefanou SL. Evidence-based postural assessment for use in therapy and rehabilitation. *International Journal of Therapy and Rehabilitation*. 2005;**12**(12):527-532
- [12] Warren JG, Bettany-Saltikov JA, Van Schaik P, Papastefanou SL. 3-D measurement of posture and back shape using a low cost, portable system—A reliability study. *Studies in Health Technology and Informatics*. 2002; Jan 1:100-104
- [13] Immersion Corporation (online) Microscribe digitizer [Internet]. 2005. [cited 24 Nov 2008]. Available from: http://www.immersion.com/digitizer/docs/MSG2_0704_V1.pdf
- [14] McAlpine RT, Bettany-Saltikov JA, Warren JG. Computerized back postural assessment in physiotherapy practice: Intra-rater and inter-rater reliability of the MIDAS system. *Journal of Back and Musculoskeletal Rehabilitation*[Internet]. Jan 2009 [cited 23 Feb 2012];**22**(3):173-178. Available from: <http://www.ncbi.nlm.nih.gov/pubmed/20023347>
- [15] McEvoy MP, Grimmer K. Reliability of upright posture measurements in primary school children. *BMC Musculoskeletal Disorders*. 2005;**6**(1):35

- [16] Fortin C, Feldman DE, Cheriet F, Gravel D, Gauthier F, Labelle H. Reliability of a quantitative clinical posture assessment tool among persons with idiopathic scoliosis. *Physiotherapy* [Internet]. Mar 2012 [cited 16 Mar 2012];**98**(1):64-75. Available from: <http://www.ncbi.nlm.nih.gov/pubmed/22265387>
- [17] Van Schaik P, Bettany-Saltikov Ja, Warren JG. Clinical acceptance of a low-cost portable system for postural assessment. *Behaviour & Information Technology* [Internet]. Jan 2002 [cited 23 Feb 2012];**21**(1):47-57. Available from: <http://www.tandfonline.com/doi/abs/10.1080/01449290110107236>
- [18] Cobb D. Controllability, observability, and duality in singular systems. *IEEE Transactions on Automatic Control*. 1984;**29**(12):1076-1082
- [19] Scutt ND, Dangerfield PH, Dorgan JC. The relationship between surface and radiological deformity in adolescent idiopathic scoliosis: Effect of change in body position. *European Spine Journal*. 1996;**5**(2):85-90
- [20] Posture Score Sheet Orthopedic Assessment and Treatment of the Geriatric Patient. Reedco, Mosby, St Louis. 1974
- [21] Milanesi JM, Borin G, Corrêa ECR, da Silva AMT, Bortoluzzi DC, Souza JA. Impact of the mouth breathing occurred during childhood in the adult age: Biophotogrammetric postural analysis. *International Journal of Pediatric Otorhinolaryngology*. 2011;**75**(8): 999-1004
- [22] Fidler C, Turner-Smith AR, Gant CA. Repeatability of ISIS analysis in normal subjects. *Annual Report of Oxford Orthopaedic Engineering Centre*. 1984;**11**:45-48
- [23] Schroder J. Posture analysis: Variations and reliability of biomechanical parameters in bipedal standing by means of Formetric-system. In: 14th Annual Congress of the European College of Sports Science, Oslo. 2009
- [24] Lason G, Peeters L, Vandenberghe K, Byttebier G, Comhaire F. Reassessing the accuracy and reproducibility of diers formetric measurements in healthy volunteers. *International Journal of Osteopathic Medicine*. 2015;**18**(4):247-254
- [25] Berryman F, Pynsent P, Fairbank J, Disney S. A new system for measuring three-dimensional back shape in scoliosis. *European Spine Journal* [Internet]. May 2008 [cited 20 jul 2011];**17**(5):663-672. Available from: <http://www.pubmedcentral.nih.gov/articlerender.fcgi?artid=2367415&tool=pmcentrez&rendertype=abstract>
- [26] Bettany-Saltikov, Josette, Forbes H, Edgar, Michael, Harrison D. The ISIS experience at the Royal national orthopaedic hospital. In: Alberti, Drerup, Hierholzer, editor. *Surface Topography and Spinal Deformity*. VI. 1992: pp. 70-75
- [27] Betz RR. Kyphosis of the thoracic and thoracolumbar spine in the pediatric patient: Normal sagittal parameters and scope of the problem. *Instructional Course Lectures*. 2003;**53**:479-484

- [28] Propst-Proctor SL, Bleck EE. Radiographic determination of lordosis and kyphosis in normal and scoliotic children. *Journal of Pediatric Orthopaedics*. 1983;3(3):344-346
- [29] Stagnara P, De Mauroy JC, Dran G, Gonon GP, Costanzo G, Dimnet J, Pasquet A. Reciprocal angulation of vertebral bodies in a sagittal plane: Approach to references for the evaluation of kyphosis and lordosis. *Spine (Phila Pa 1976)*. 1982;7(4):335-342
- [30] Bernhardt M, Bridwell KH. Segmental analysis of the sagittal plane alignment of the normal thoracic and lumbar spines and thoracolumbar junction. *Spine (Phila Pa 1976)*. 1989;14(7):717-721