

We are IntechOpen, the world's leading publisher of Open Access books Built by scientists, for scientists

6,900

Open access books available

185,000

International authors and editors

200M

Downloads

Our authors are among the

154

Countries delivered to

TOP 1%

most cited scientists

12.2%

Contributors from top 500 universities



WEB OF SCIENCE™

Selection of our books indexed in the Book Citation Index
in Web of Science™ Core Collection (BKCI)

Interested in publishing with us?
Contact book.department@intechopen.com

Numbers displayed above are based on latest data collected.
For more information visit www.intechopen.com



Treatment Planning in Brachytherapy HDR Based on Three-Dimensional Image

Marcin Sawicki

Additional information is available at the end of the chapter

<http://dx.doi.org/10.5772/intechopen.68557>

Abstract

Treatment planning in High Dose Rate (HDR) brachytherapy based on three-dimensional (3D) imaging allows for prearranging and realization optimal treatment process. This process consists of procedure planning, the choice of applicators, adjusting the appropriate implantation technique, and planning of three-dimensional distribution of dose in computerized treatment planning system. 3D images used in treatment planning in HDR brachytherapy allows for choosing the most appropriate application technique. This in turn allows for the best area coverage by reference dose with simultaneous protection of critical organs. Treatment planning on 3D images assures individual planning of dose dispersion in target area. Several techniques will be presented based on 3D imaging in location such as lung, skin cancer, breast, and prostate cancer. For each location, relative cases will be provided where different applicators and techniques were applied. These examples are going to present images from before and after performed application along with the pictures from computer treatment planning system. In each of described locations, relative advice and rules of conducting accurate application will be provided.

Keywords: HDR brachytherapy, treatment planning, 3D, three-dimensional images

1. Introduction

HDR brachytherapy is a radiotherapy method in which a source of ionizing radiation is administered directly into the tumor area or to its nearest surroundings. Dissemination of this method, nowadays, is associated with the possibility of using radiation sources with relatively low dimension. Small size of capsules made administration of catheter possible in the areas where previously it would have not been possible or would have involved a number of inconveniences for the patient as well as considerable risks of complications, e.g., bronchial

carcinoma. This unique method also provides the possibility to determine the exact location of catheter in the tumor area for applying several visualization methods.

The purpose of the following chapter is to introduce practical application of HDR brachytherapy based on the three-dimensional (3D) computed tomography method. This publication is for those who are interested in applying and using 3D images in HDR brachytherapy and are searching for practical treatment examples based on this method. The purpose of this section is to spread treatment HDR brachytherapy treatment planning based on 3D images. The majority of brachytherapy departments still base their treatment on 2D imaging in spite of relatively popular CT scanners.

This chapter aims to familiarize the reader with treatment planning based on CT imaging to draw attention to the benefits coming from this method not only for the treatment planning but also for the patient. It is a practical guide based on brachytherapy department experiences located in Subcarpathian Cancer Center.

This chapter includes CT images presenting brachytherapy treatment in different stages of treatment planning. It is going to introduce a course of planning process in different locations as well as the application methods used in correspondence to the location of the treatment. With each location, relevant suggestions and recommendations will be provided, which would improve the whole treatment planning process.

This chapter is mainly addressed to radiotherapy specialists but also residents, physical medics, radiologists, and everyone who is interested in the topic of applying CT imaging in HDR brachytherapy.

First section deals with what the approach of brachytherapy is and what imaging methods it uses. Also, the differences emerging from using different imaging methods and locations where 3D imaging was used will be described as well as the methods applied to enhance the treatment planning procedure. It will illustrate the guidelines we use in our department when treating different tumor locations along with the necessary equipment relevant in the 3D imaging method.

Second section will demonstrate, in detail, its applications in various locations. In this chapter, I am going to demonstrate the utilization of HDR brachytherapy in treatment of breast, prostate, skin, and lung cancers. Depending on the tumor location, one or more examples will be provided. For each case, there will be one accepted treatment plan presented. Each case includes a wide range of materials in the form of CT images and computed planning system, each of them will be described under the angle of planning and conducting in most optimal application, based on the experience of our department. I am going to present several planning stages, starting from CT scans on different application levels to the demonstration of images and results of computer treatment planning system (TPS).

2. Treatment planning in brachytherapy HDR

Brachytherapy HDR is administration of a source of ionizing radiation into the immediate vicinity of the tumor. Because of the high gradient dose, the administered application

allows for reduction of ionizing radiation in the critical organs area with simultaneous coverage of tumor area with reference dose. Treatment planning process can be based on two- and three-dimensional imaging. In case of 2D imaging, distribution of dosage around the **catheter** would conventionally be calculated on X-ray pictures taken in two different projections. This reconstruction allows us to determine the dose around the guide or guides [1]. We do not have the exact information about the dose in the target and the critical organs in the immediate vicinity to catheter. When planning a treatment, CT images provide actual information about the location of the applicator, target, and organ at risk (OAR). Images from computer tomography are electronic cross-sections (scans) of a patient body, which includes cancerous areas. The distance between those scans is adjusted accordingly to achieve best-possible three-dimensional reconstruction of the patient's body. It is necessary to calculate and determine the dose on the clear scans from the CT. The dosage calculation area here is the patient's body. Second, radiation area is determined along with critical organs and structures. Using the linear method, involving manual or automatic contouring of selected areas in each scan, ionizing areas are determined as well as critical organs and structures. Ionizing area in brachytherapy is defined by a three-step process:

- Gross tumor volume (GTV)—macroscopic tumor area defined by diagnostic methods.
- Clinical target volume (CTV)—clinical area for radiation.
- Planning target volume (PTV)—1 cm safety margin top-bottom in regard to CTV and additional 1 cm resulting from uncertain location of catheter or possible applicator movements caused, i.e., transporting the patient.

As a result of reconstruction, you get a three-dimensional image of target volume and critical organs. Application of computer treatment planning methods enables a precise dosage calculation. Dosage distribution is determined using formalism TG-43 or Monte Carlo method. Individual treatment plan is verified before the treatment starts. Designated dosage, active length, dwell times, and source activity are being confirmed. Once all these data have been verified, the treatment plan begins to be realized.

The main purpose of treatment planning based on computed tomography images is to determine the best-possible dosage in the therapeutic area, simultaneously decreasing its volume in organs and critical structures. Such adjustment can be accomplished by treatment planning enhancement [2–6].

This process depends on defining the location and appropriate dwell time to achieve the desired dose distribution in the patient's body. Introduction of new 3D methods that are applied in treatment planning triggered studies on optimization algorithms using data from three-dimensional imaging. One example is graphical optimization. Thanks to the information from target volume and surrounding it structures, optimization algorithm provided a possibility to target the area of interest with reference dose while protecting tissues surrounding implant. Graphical optimization allows change of shape of the isodose in any way. Applying such set of applicators enables the reduction of organ at risk (OARs) dose. Utilizing 3D imaging allows us to define the exact application place as well as determine the type and correct amount of applicators.

2.1. Lung cancer

In case of lung cancer, HDR brachytherapy treatment planning is conventionally based on two-dimensional imaging. More and more brachytherapy departments get access to computer tomography, which provide three-dimensional imaging. In our brachytherapy department, the entire treatment process is based on three-dimensional imaging. Dosage distribution in treatment planning based on 2D imaging is conventionally set in reference points of axis. Reference points are identified in constant proximity from the reconstructed applicator axis, which usually is 1 cm. The applicators curvature is an important factor taken into consideration while calculating dose distribution in 3D-based treatment. Dose disperse is set on the target area taking into consideration critical organs. Equipment routinely used for administering bronchial applicators in our department is a bronchovideoscope.

Before the treatment begins, the patient has computed tomography. Then, radiotherapist familiarizes themselves with the patient's history and then determines the area for administering the ionizing radiation.

In cases where the tumor area allows for applying the catheter into the tumor, usually only one applicator is used. In situations where the tumor location does not allow for the direct application of a catheter into the tumor area, several applicators are applied into the immediate surroundings of therapeutic area. Usage of one applicator in the tumor area does not allow for optimal coverage by the reference dose. It is caused by unsymmetrical shape of the target in the reference to the applicator. By such implantation, applicator can be the reason for a quantity that exceeds reference dose many times over. To achieve the best coverage of the tumor area, it is best to use several applicators. Applicators, as long as the clinical situation allows, are placed to be inside the tumor and in the external target area. Such treatment allows the reduction of high contact dose, which is the case when using only one applicator, as well as a considerable dose reduction in OARs.

Once application is completed, markers are injected to each of the catheters. Markers role is to visualize the catheter in which stepping source is going to maneuver. The next step is to execute CT imaging, and it is advised to perform imaging of the entire inspiration stage. Its purpose is to mineralize movement of markers during the treatment. When images indicate patients major movements while breathing, it is necessary to repeat the procedure as there is a possibility of artifacts occurring, e.g., in form of blurred images. Changes in applicator location in reference to the target caused by the patient's movement do not have a significant effect on dose dispersion in the patients system [7]. Scans are performed every 2.5 mm. In case, scans are performed below 2.5 mm proximity, the quality of images is significantly impaired.

Once CT images are accepted by radiotherapist and medical physicist, they are being sent to the computerized system of treatment planning. Radiotherapist marks each image for PTV and OARs areas. In lung cancer area, the critical organs are esophagus, heart, and spinal cord. In our department, we contour the actual image of target and critical organs on the images from computed tomography. Dose is specified for the entire PTV area. Most recent American Brachytherapy Society guidelines suggest 3D imaging for lung cancer treatment planning while applying HDR brachytherapy [8].

During the next stage, medical physicist performs reconstruction of applicators trajectory. Selection of the optimal source step and stop place in the in the nearest proximity from PTV. Then, the treatment plan is being optimized. Generally, treatment plan is optimized onto dose reference points usually situated 1 cm from catheter axis [9]. Reference dose should be calculated for the target area. This process is greatly influenced by the number of applicators. In our department, it is usually between two and four. The number of catheters administered depends mainly on patient's condition, location, and the volume of therapeutic area. When possible, bronchial applicators are implemented into the terminal bronchioles. Such allocation prevents catheter from sliding out what can stem from patient's couch movements caused by the presence of excrescence in patient's airways.

Routinely, treatment plans are optimized by graphical optimization. It is crucial to examine the dose dispersion in patient's system after each modification based on graphic optimization. After the development process is completed, plan is evaluated. Radiotherapist analyzes volume dose histogram (DVH). Evaluation of target coverage by reference dose in 85, 100, and 115% volume, as well as the dose in most important critical volume structures, was done. In instances of heart, spinal cord, and esophagus, the dose examined was 0.1, 1, and 2 cm³ volume in each of those structures. After initial DVH, the dose dispersion is determined on each cross-section (image). After the plan is accepted, it is sent to the Treatment Control Station.

2.1.1. Case

In this case, patient is diagnosed with an inoperable non-small cell right lung cancer. Before the treatment begins, the patient has computed tomography (**Figure 1**). Overall patient's condition and the location of changes allowed the introduction of three bronchial applicators. All applicators were in the immediate proximity to tumor area. **Figure 2** shows scans with volume target contoured in computerized treatment planning systems (TPS). Illustration from computerized planning system depicts three-dimensional reconstruction of bronchial applicators, PTV, OARs, and dose distribution (**Figure 3**). Reconstruction on several planes and DVH is presented in **Figure 4**. The patient was treated with 18 Gy dose in three fractions.

2.1.2. Case

Second situation presents a patient with an inoperable non-small cell right lung cancer. Before the treatment begins, the patient has computed tomography. Overall patient's condition and the location of changes allowed the introduction of three bronchial applicators. Two applicators (nr1 and nr2) were introduced through the PTV area and planted in bronchial tubes. Applicator nr3 was placed where the bronchial tubes light has been blocked by the neoplastic changes. Very often, such applicator placement causes dilatation of bronchial tube, making it possible to introduce applicator through this area during next fraction. This, furthermore, improves the coverage on tumor area. **Figure 5** shows scans with volume target contoured in TPS. Illustration from computerized planning system depicts three-dimensional reconstruction of bronchial applicators, PTV, OARs, and dose distribution (**Figure 6**). Reconstruction on several planes and DVH is presented in **Figure 7**. The patient was treated with 18 Gy dose in three fractions. In **Figure 8**, cancer photo was captured during the application.

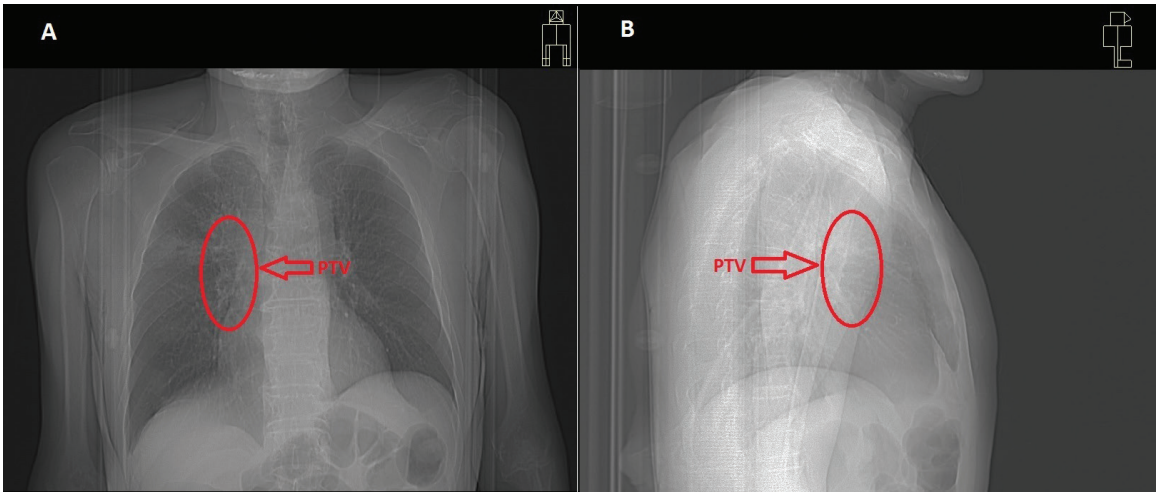


Figure 1. CT image of the front (A) and side (B) of the patient with marked PTV.

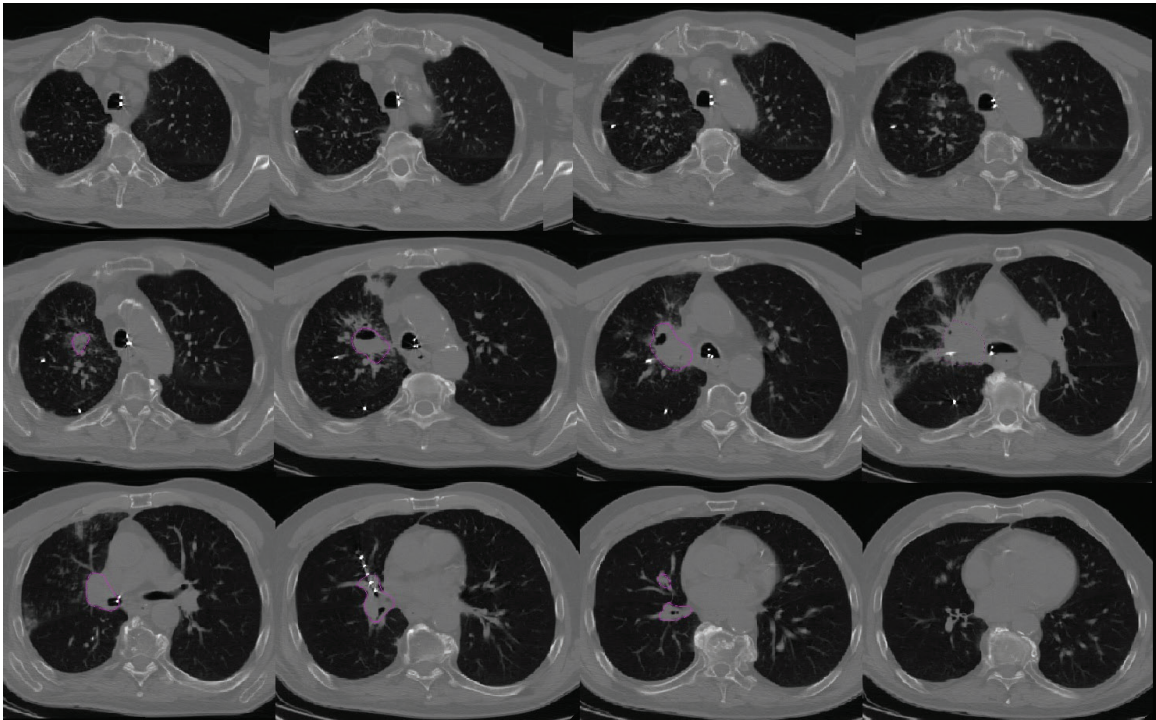


Figure 2. Images of the TPS with PTV.

2.2. Skin cancer

In the case of skin cancer, depending on its size and location, we can differentiate several types of applicators. With small and superficial skin changes, usually Leipzig applicators are being used. When dealing with long and flat changes, i.e., on the leg, then usually Freiburg flap is applied. The advantage of this applicator derives from the parallel positioning of catheters and consistent length at which they are situated. The distance of the catheters from the surface is also consistent. This type of applicator is also characterized

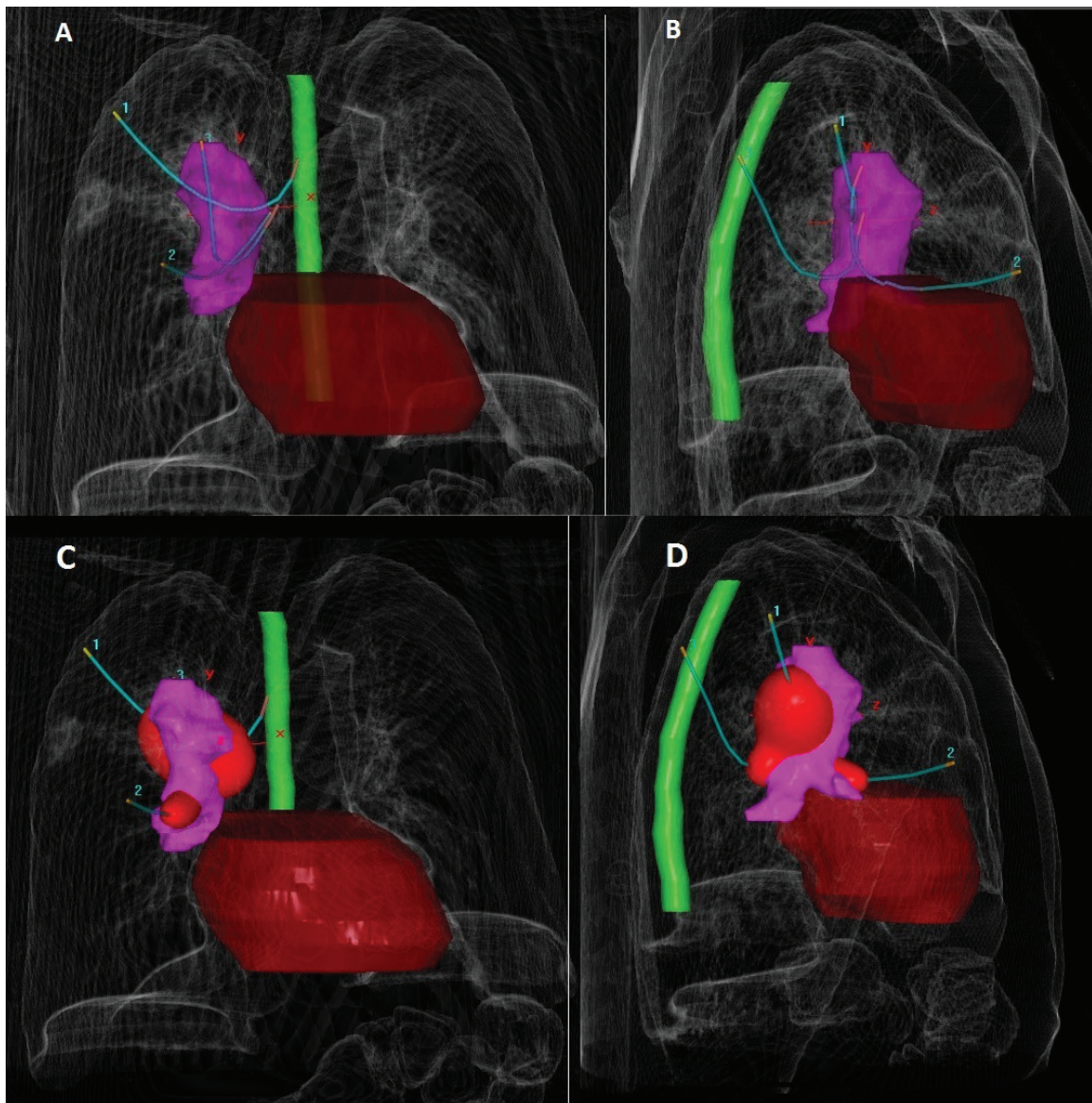


Figure 3. 3D reconstruction (A, C: front; B, D: side) of PTV applicators and OARs and 3D dose reference distribution.

by the high repetitiveness during the following irradiation fractions. The only requirement is the correct marking of applicator placement on the patient's skin. Very often, the place in which cancer is situated, i.e., in nose, ear, or cheek area, doesn't allow for application of standard applicators. In this case, it is very difficult to determine with the use of standard applicator. Using of standard applicator will not allow for ensuring optimal dose distribution in the PTV area. It is caused by inability to adjust catheter location in reference to the target [10].

Applicator adjustment during the following irradiation fractions is influenced by a considerable inaccuracy margin caused by a limited applicator placement repetitiveness in regard to patient's body. In cases when changes are located in close proximity to risk organs, applicator reconstruction can be planned so that it can decrease irradiation dose in those organs. The dose can also be reduced by appropriate arrangement of catheters in the applicator.

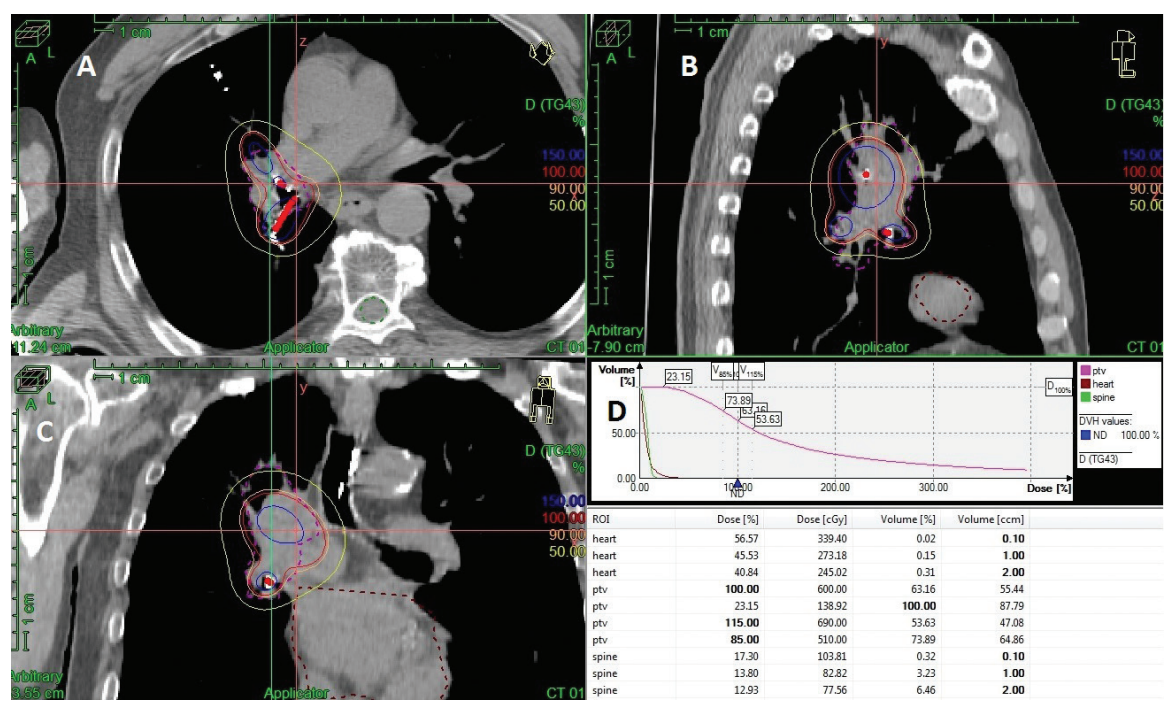


Figure 4. CT images and reconstruction on several planes (A, B, and C) and DVH (D).

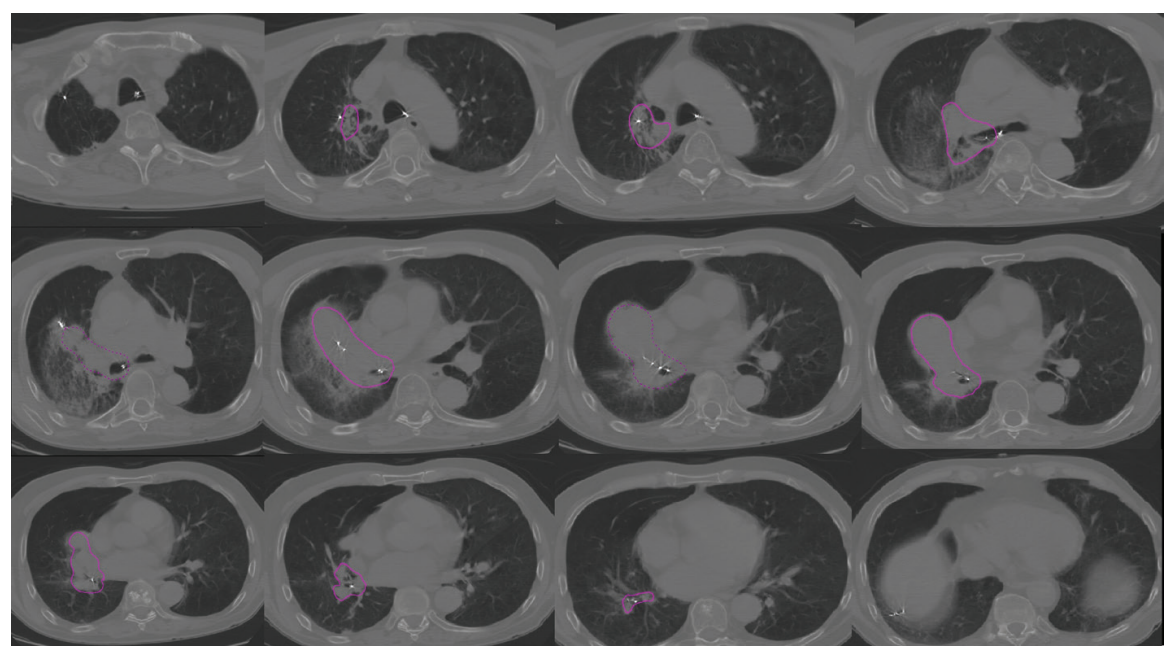


Figure 5. Images of the TPS with PTV.

In cases of shallow changes, situated in immediate proximity to applicators surface, catheters can be placed slightly further away from the target to avoid high dosage besides the PTV area. However, if the cancerous region is situated underneath the layer of skin and skin itself is OAR, the applicators will be moved toward the skin surface, inside the silicone

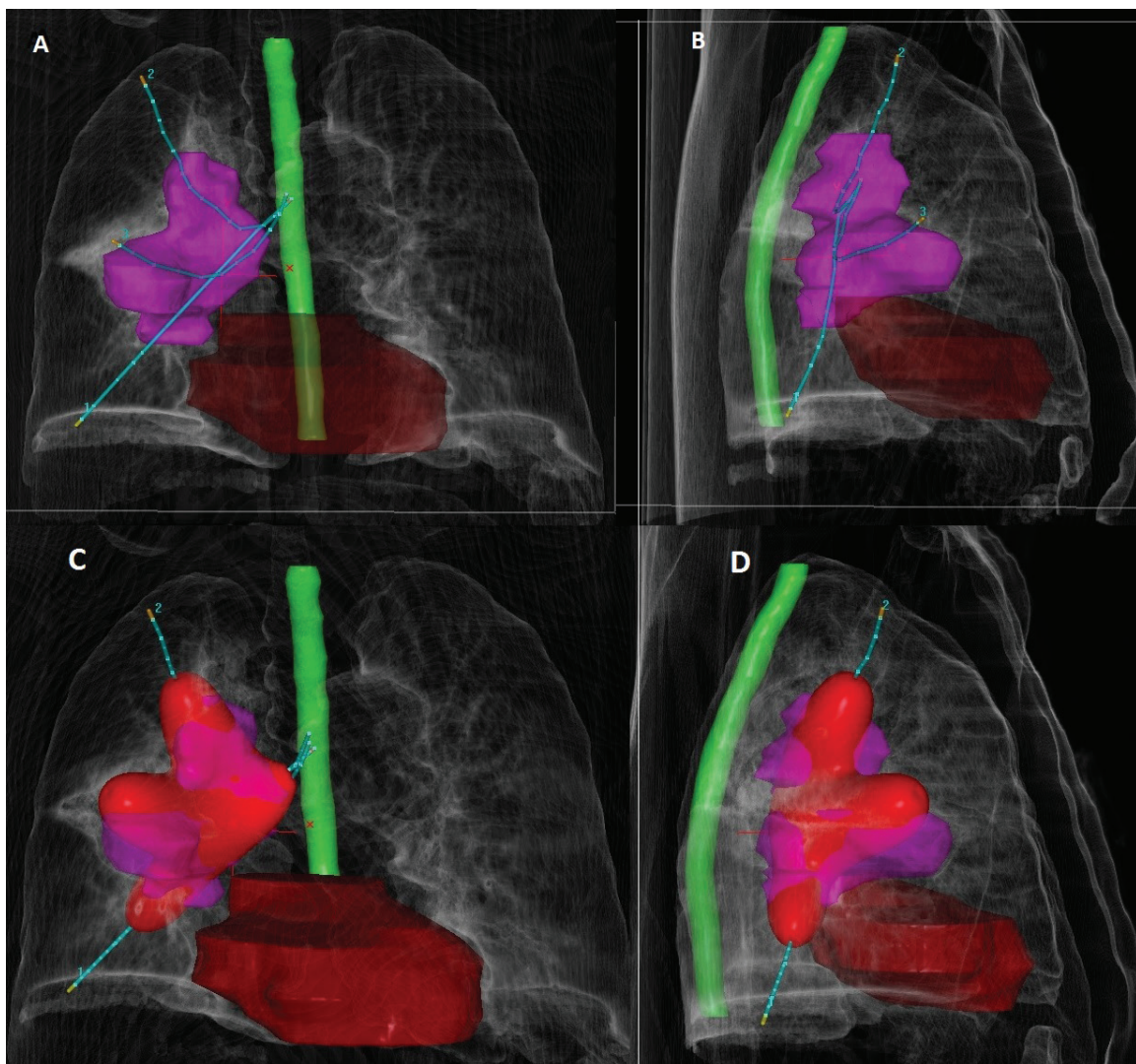


Figure 6. 3D reconstruction (A, C: front; B, D: side) of PTV applicators OARs and 3D dose reference distribution.

mask. Such applicator distribution is the reason for the high dose, and catheters being the source do not reach to skin region. Another way to dose distribution, and therefore protection for critical organs, is the adoption of shields. Their task is to absorb (reduce) the dose, for I192 the half value is 2.5 mm for lead (HVL pb). Shields can be in the form of led strips in different thickness. Such shield can be produced in workshop of teleradiotherapy department. Shield adjustment takes place on provided patient's gypsum cast. Shields are fixed in a silicone mask with the exception of the three-dimensional computer tomography imaging. LED shields are the source of artifacts during CT imaging, hence disturbing the treatment process. Because the individual shields are removed for the CT imaging, they are not visible on patient's scans sent to the computerized system of treatment planning. The dose that reaches critical organs protected by shields is calculated based on the thickness of applied shield. It is necessary to conduct *in vivo* dosimetry before the first irradiation to verify the prearranged dosage. Dosimetry can be conducted through applying the MOSFET detector. In cases where it is necessary to determine the dosage absorbed by an individual

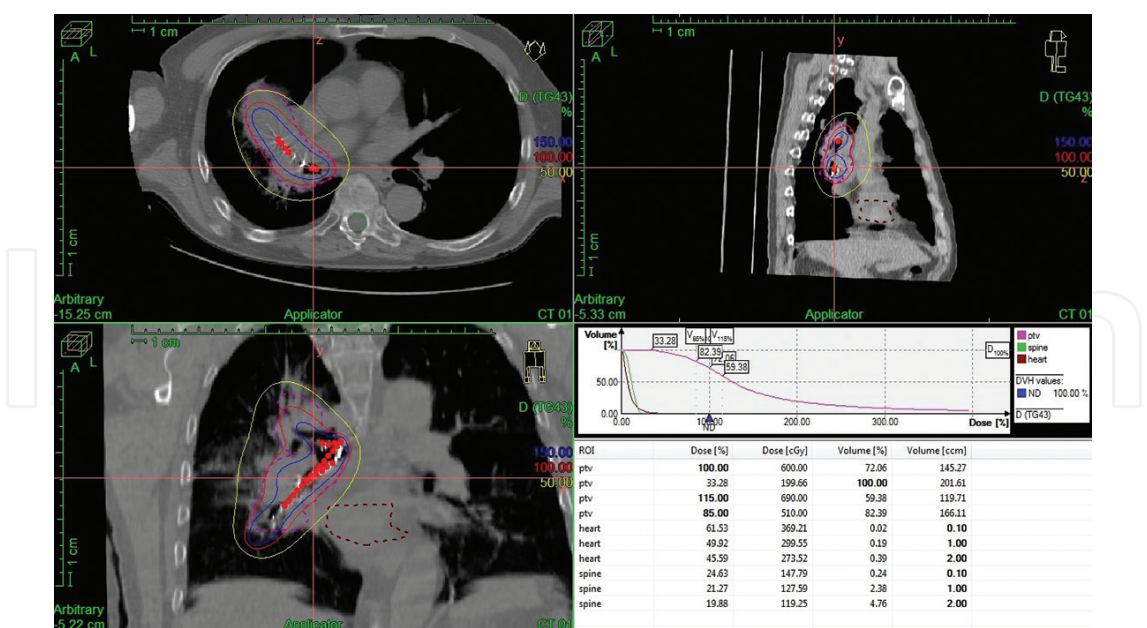


Figure 7. CT images and reconstruction on several planes (A, B, and C) and DVH (D).

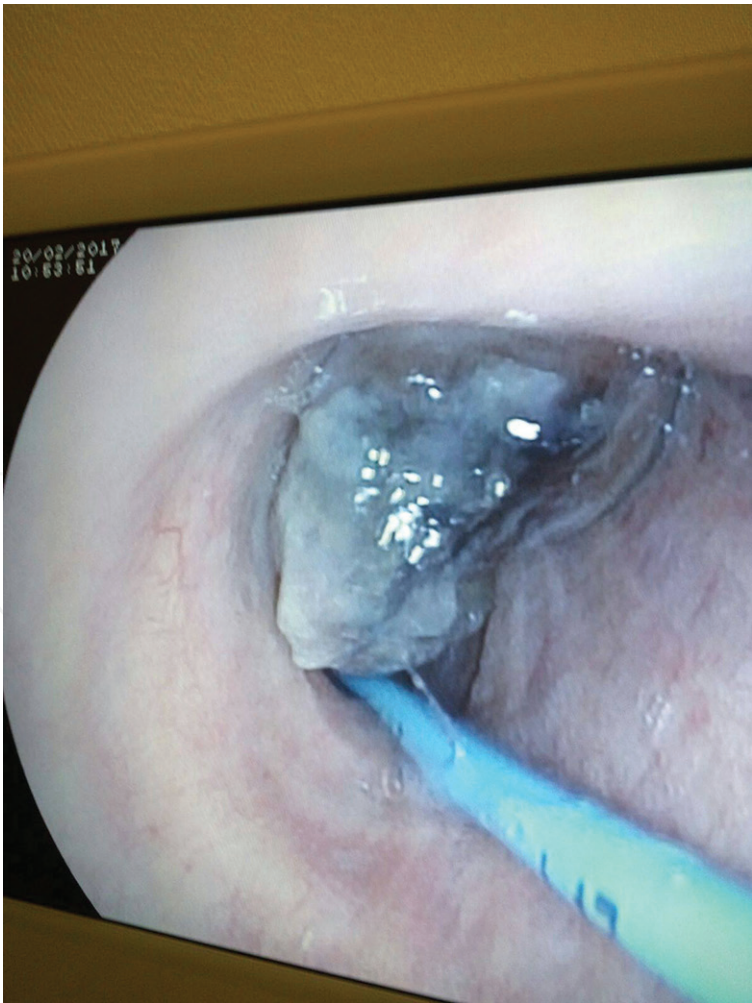

Figure 8. Lung cancer photo.

shield, Micro-MOSFET detectors are very effective, and because of their small-scale dimensions, they can be placed between irradiative area and the shield itself. In cases where cancerous changes are located in the area of nose or cheeks, it is advised to place such shields around patient's eyes. Such placement prevents the shield from moving while during the treatment process.

Another method of manufacturing individual applicators is the usage thermoplastic mask. Usage of the orfit masks is widely spread in teleradiotherapy. They are applied to immobilize the patient during treatment with help of external bundles. They are characterized by very good tracing qualities. Forming process takes place on patient's body. High level of its reproducibility is advantageous during the treatment process. They can be used to immobilize any location. In case of brachytherapy, such properties as reproducibility of patient's curvatures are very desirable. This is one of the reasons why I became interested in applying this type of material in the HDR brachytherapy treatment process. The concept and theory are quite similar to silicone masks. However, there are some relevant differences between these two types of individual applicators. First, it is the use of the material itself. With the orfit mask, we get a premade product that has to be heated. When heat treated, it becomes very malleable, and after applying it onto the given surface, it easily adapts to its shape. It is setting just within few minutes. If the reproduction is not satisfying, the material can be reheated and formed again. Once it reaches ambient temperature, the mask is ready to use. Another difference lays in the way catheters are mounted to the surface of the individual applicator. With the silicone mask, applicators are inside, and with the Orfit mask, they can be freely mounted onto it. So in situation where the applicators need to be close to the surface of the skin, we can immobilize catheters by sewing them to the mask. When they have to be further away from the surface of the orfit mask, we can use paraffin bolus or secure silicone mask. With shields, the workflow procedure is the same as with the silicone mask. Because we use thermoplastic material, we can contour the shield placement, which allows the position control throughout every treatment fraction. The last difference between the orfit and silicone masks is the manner of mounting it onto the patient. The silicone mask uses patient's natural curvatures for the appropriate setting. In large areas, it is easy to adjust the applicator; however, in cases with flat areas, it is necessary to mark reference points on the patient's body. Additionally, for the mask to adhere properly through irradiation process, it is advisable to use immobilizing bands. The orfit mask is fixed to the base on which the patient is laid. It is mounted to specialized brackets and that is why mask adjustment is the same during every fraction. Immobilizing bands are no more necessary nor is the marking of reference points on the patient's body. Routinely, silicone masks are ready in 4 to 5 days after taking the imprint. When adopting the use of the orfit mask, first fraction can be performed on the same day that the patient is accepted to the brachytherapy department.

2.2.1. Case

The first case presents a patient with skin cancer (squamous cell carcinoma). Cancer is located in the vicinity of the ear. The patient was qualified for treatment with the applicator individual (silicone mask). In the silicone mask were placed seven applicators. The patient was treated with 40 Gy in 10 fractions once a day. **Figure 9** shows scans with volume target contoured in TPS. Illustration from computerized planning system depicts three-dimensional

reconstruction applicators, PTV, and dose distribution (**Figure 10**). Reconstruction on several planes and DVH is presented in **Figure 11**. Patient treated with silicone mask is presented in **Figure 12**.

2.2.2. Case

The second case presents a patient with skin cancer (basal cell carcinoma). Cancer is located in the vicinity of the nose. The patient was qualified for treatment with the applicator individual (orfit mask). In the silicone mask were placed four applicators. The patient was treated with 50 Gy in 10 fractions once a day. The patient had a shield on both eyes. Before the treatment begins, the patient has computed tomography to verify the mask fit to the patient (**Figure 13**). **Figure 14** shows scans with volume target contoured in TPS. Illustration from TPS depicts three-dimensional reconstruction applicators, PTV, OARs, and dose distribution (**Figure 15**). Reconstruction on several planes and DVH is presented in **Figure 16**. Patient treated with the orfit mask is presented in **Figure 17**.

2.2.3. Case

The third case presents a patient with skin cancer (basal cell carcinoma). Cancer is located in the vicinity of the nose. The patient was qualified for treatment with the applicator individual

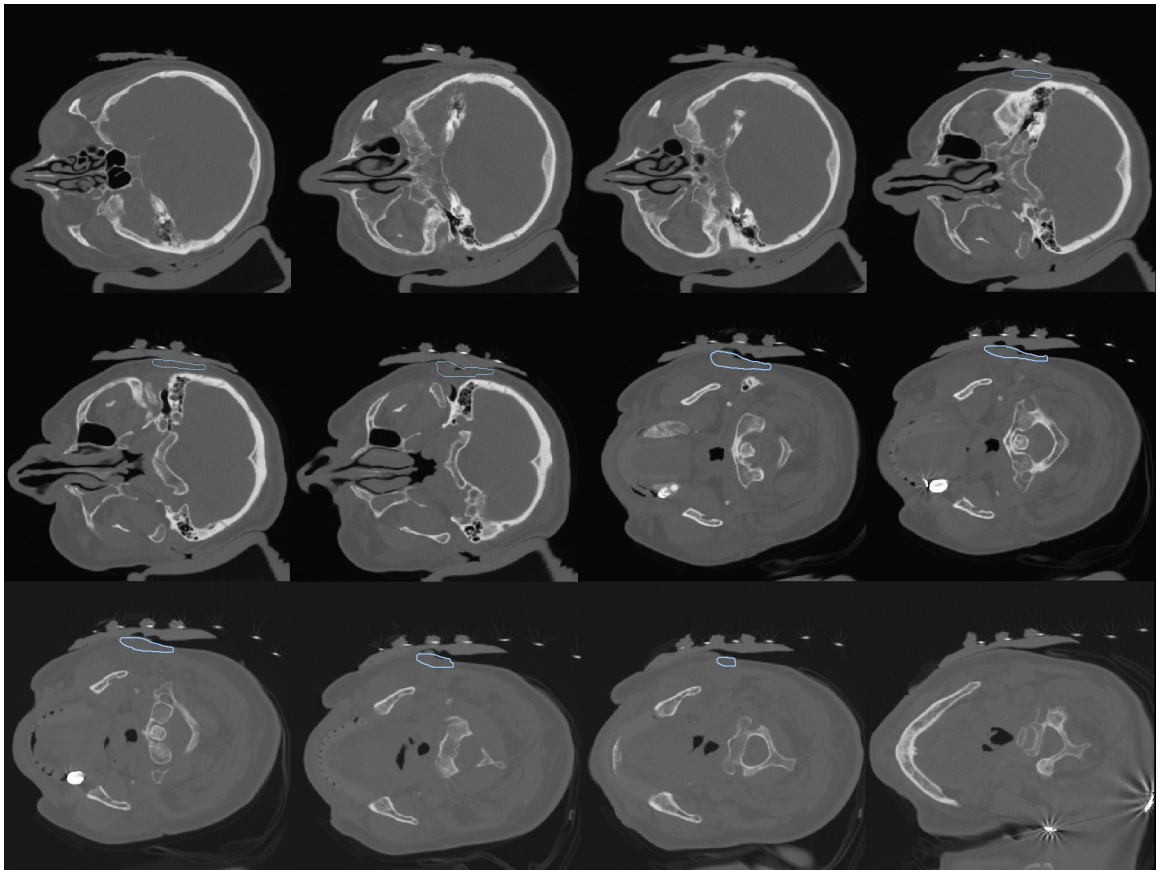


Figure 9. Images of the TPS with PTV.

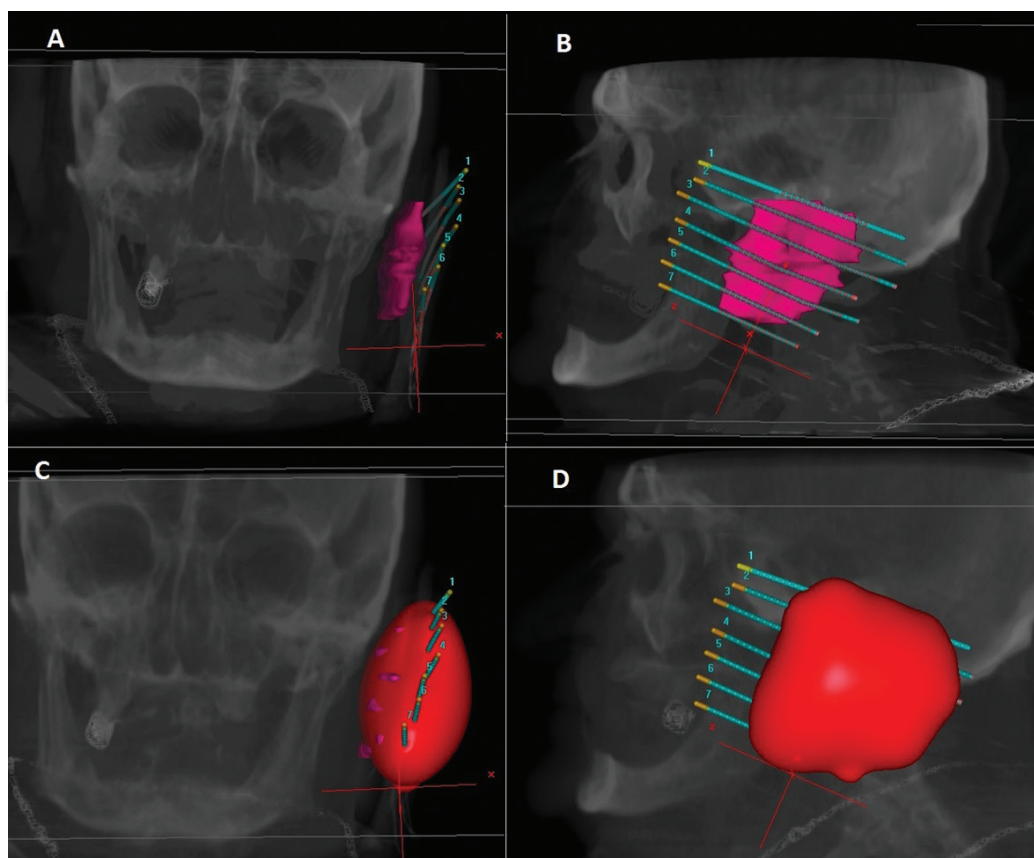


Figure 10. 3D reconstruction (A, C: front; B, D: side) of PTV applicators and 3D dose reference distribution.

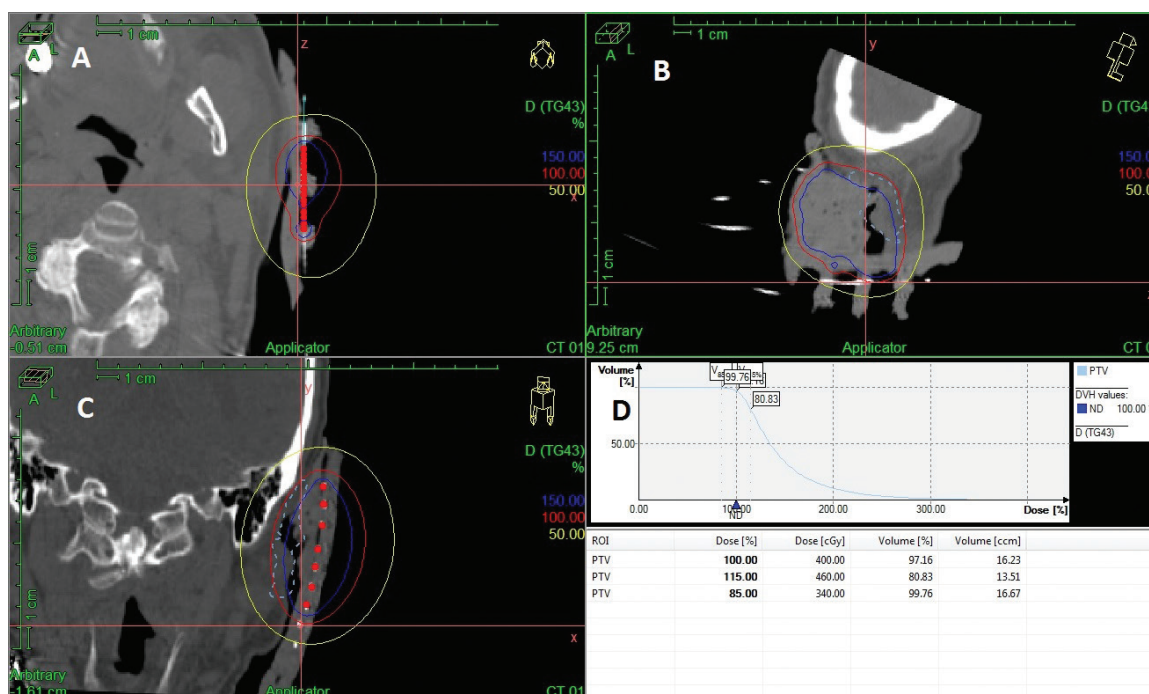


Figure 11. CT images and reconstruction on several planes (A, B, and C) and DVH (D).

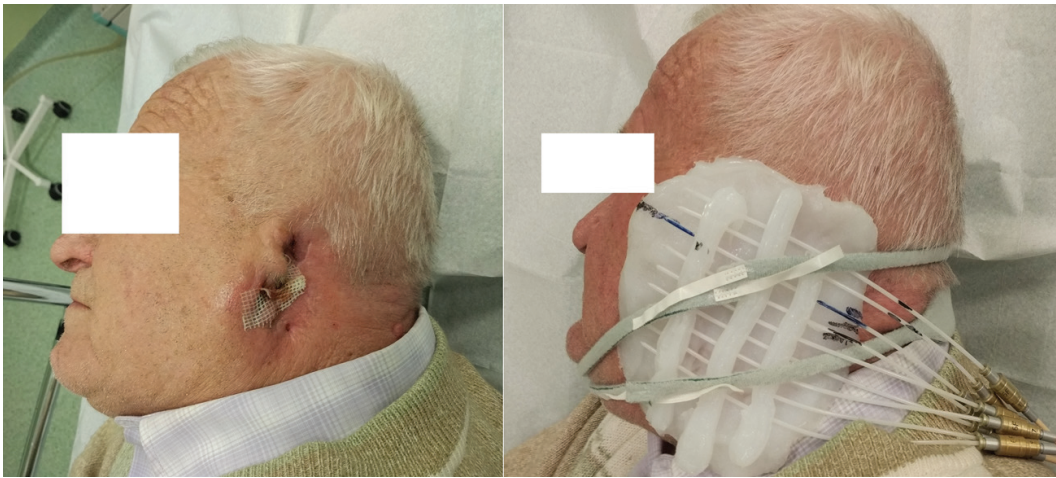


Figure 12. Patient treated with the silicone mask.

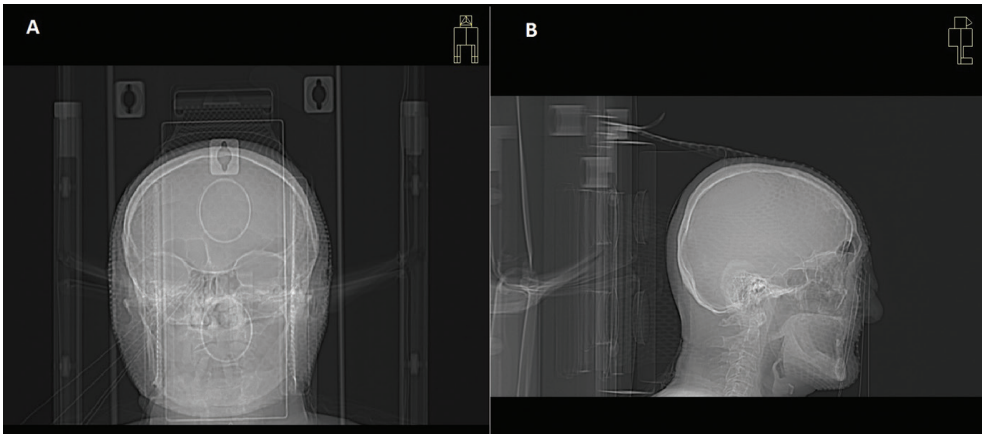


Figure 13. CT image of the front (A) and side (B) of the patient with an orfit mask.

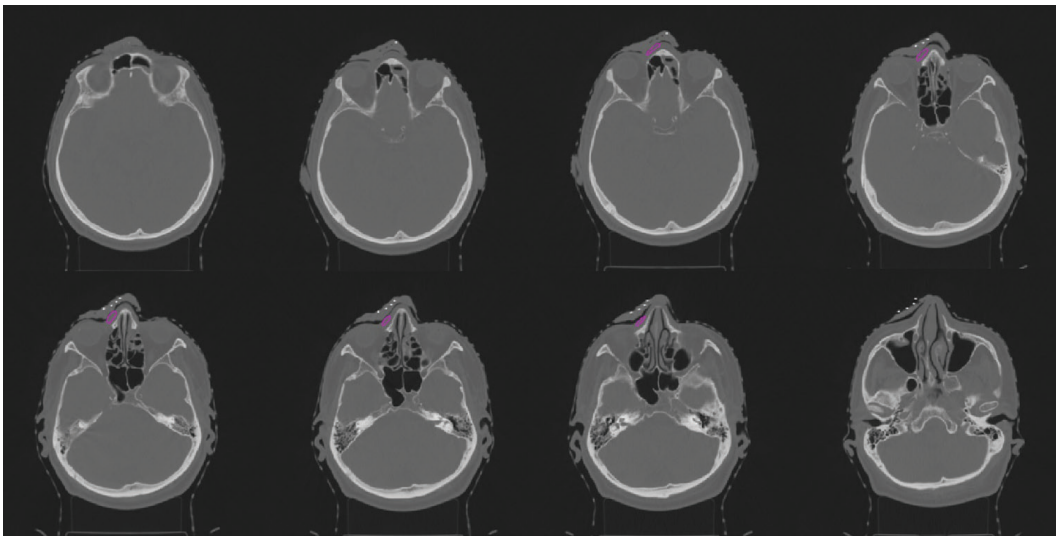


Figure 14. Images of the TPS with PTV.

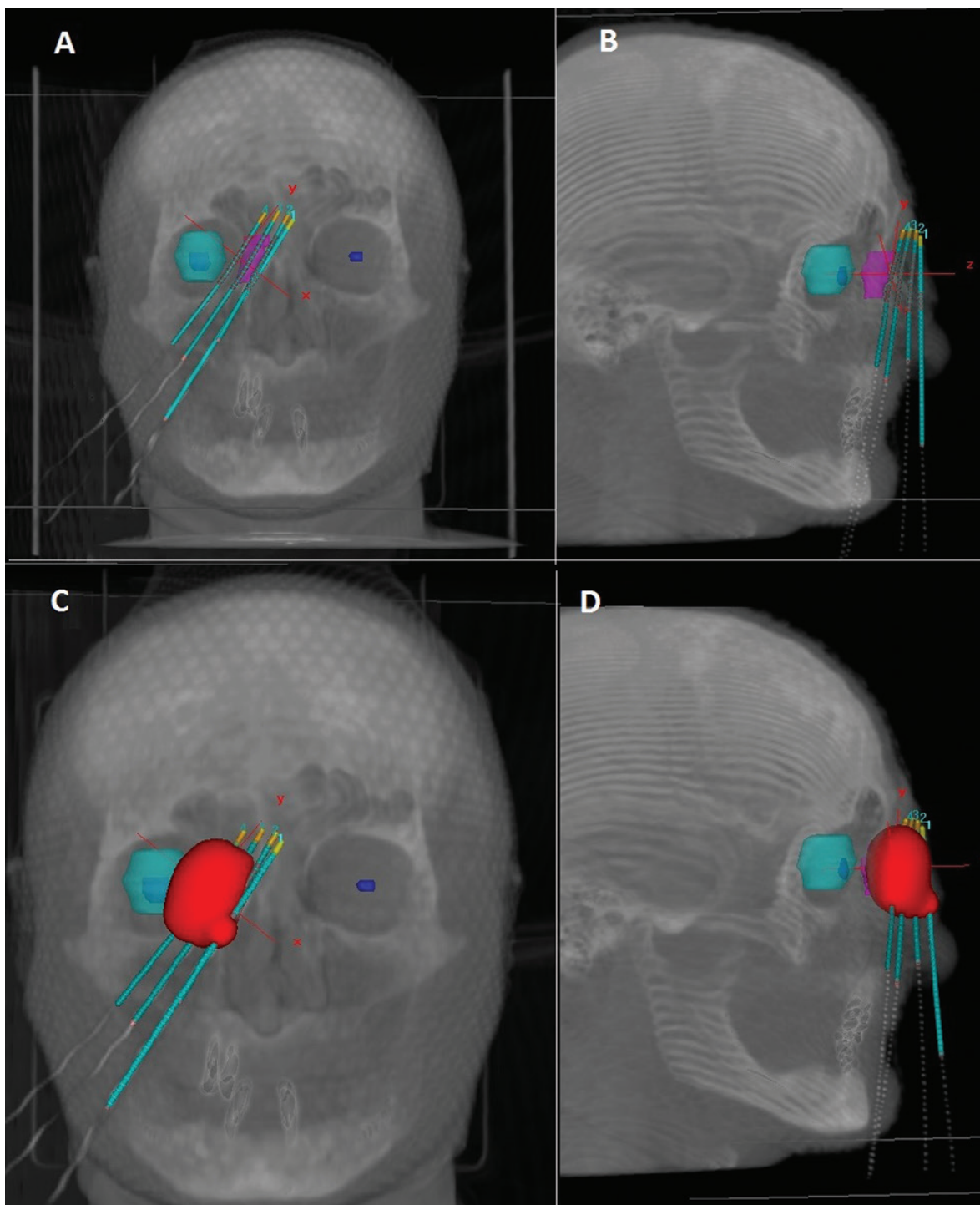


Figure 15. 3D reconstruction (A, C: front; B, D: side) of PTV applicators OARs and 3D dose reference distribution.

(Orfit mask). In the silicone mask were placed eight applicators. The patient was treated with 50 Gy in 10 fractions once a day. The patient had individual shield on one eye and standard shield on the other eye (**Figure 18**). Before the treatment begins, the patient has computed tomography to verify the mask fit to the patient (**Figure 19**). **Figure 20** shows scans with

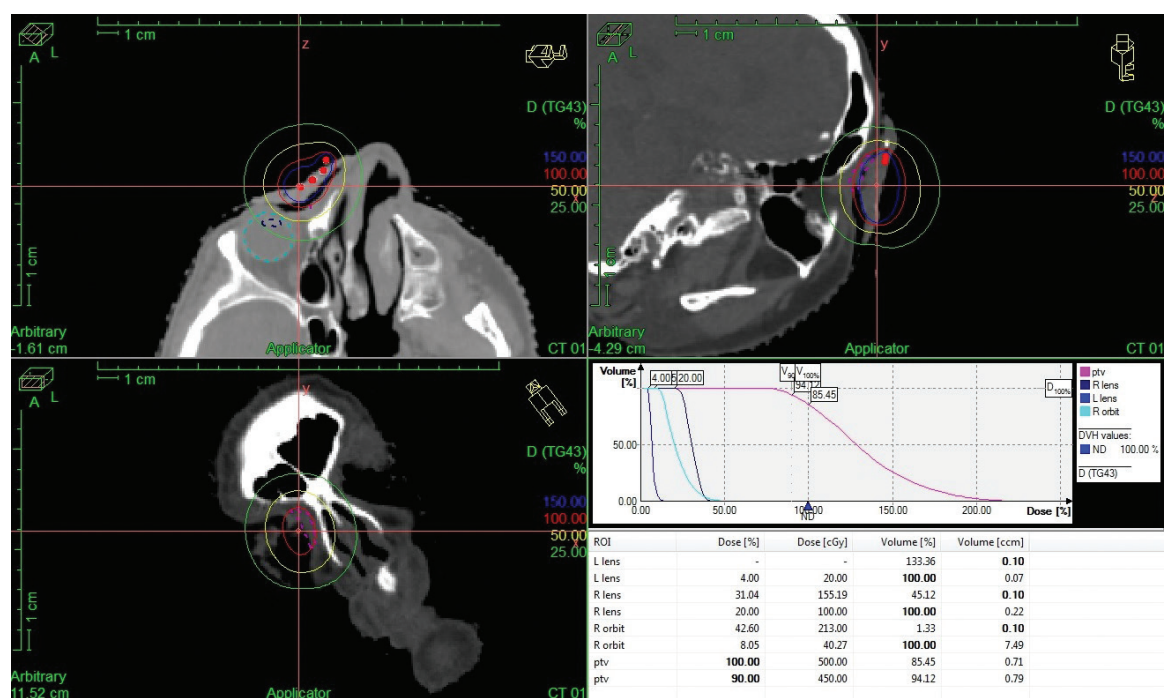


Figure 16. CT images and reconstruction on several planes (A, B, and C) and DVH (D).

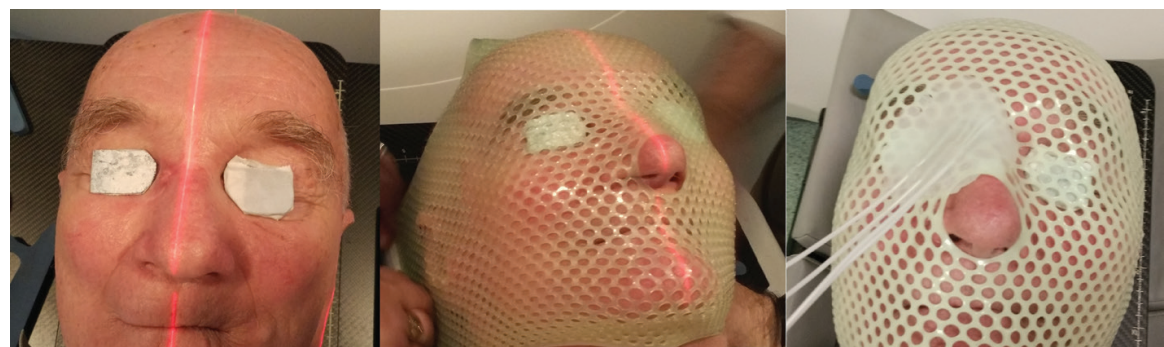

Figure 17. Patient treated with an orbit mask.



Figure 18. Picture of shield.

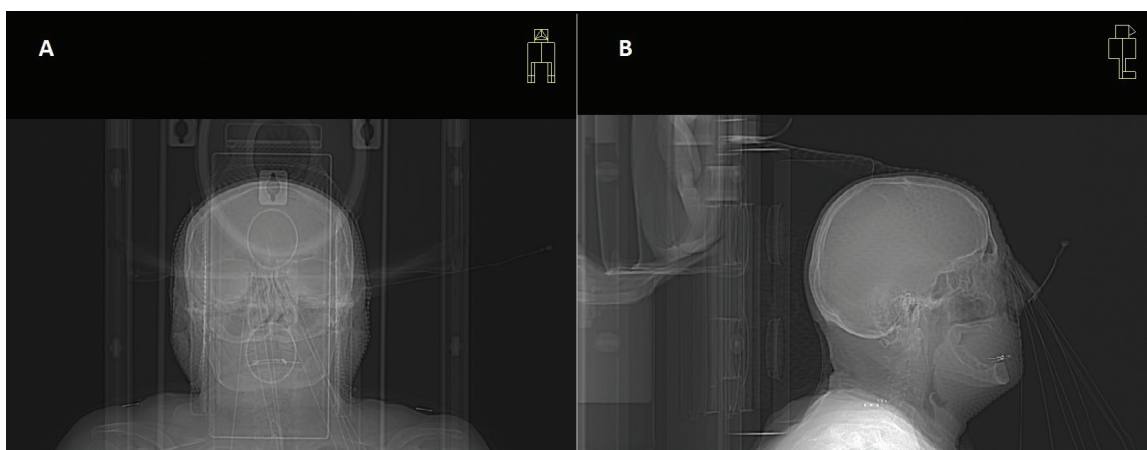


Figure 19. CT image of the front (A) and side (B) of the patient with an orfit mask.

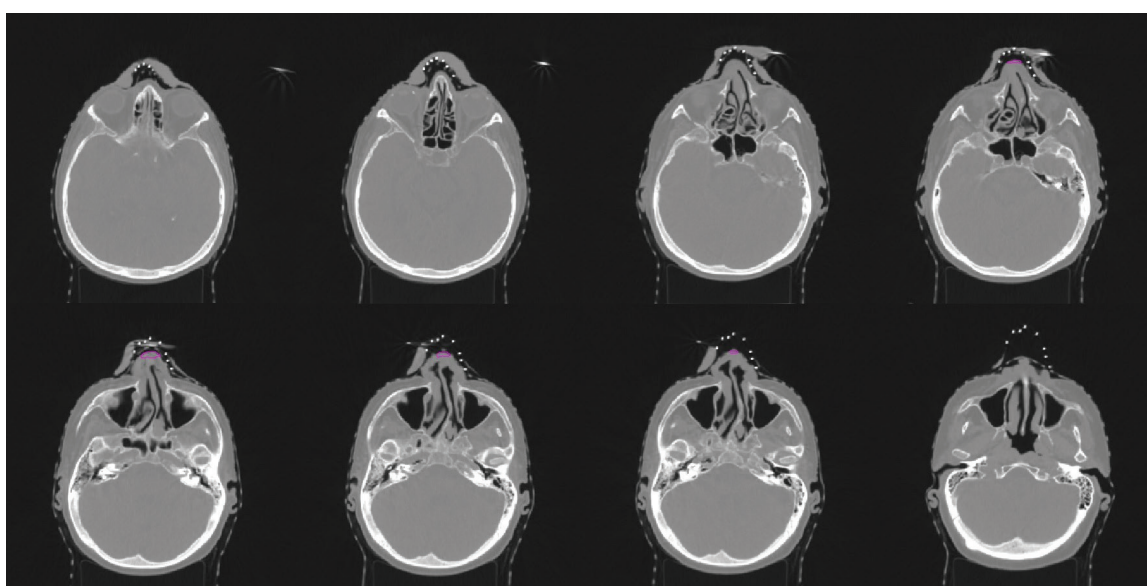


Figure 20. Images of the TPS with PTV.

volume target contoured in TPS. Illustration from TPS depicts three-dimensional reconstruction applicators, PTV, OARs, and dose distribution (**Figure 21**). Reconstruction on several planes and DVH is presented in **Figure 22**. Patient treated with the orfit mask is presented in **Figure 23**

2.3. Breast cancer

With breast cancer, brachytherapy can be applied as a method associated with teleradiotherapy after breast-conserving surgery. It is realized in form of boost. It can also be applied as an independent form of post-surgical treatment (Accelerated Partial Breast Irradiation) as an alternative to the external beam radiotherapy.

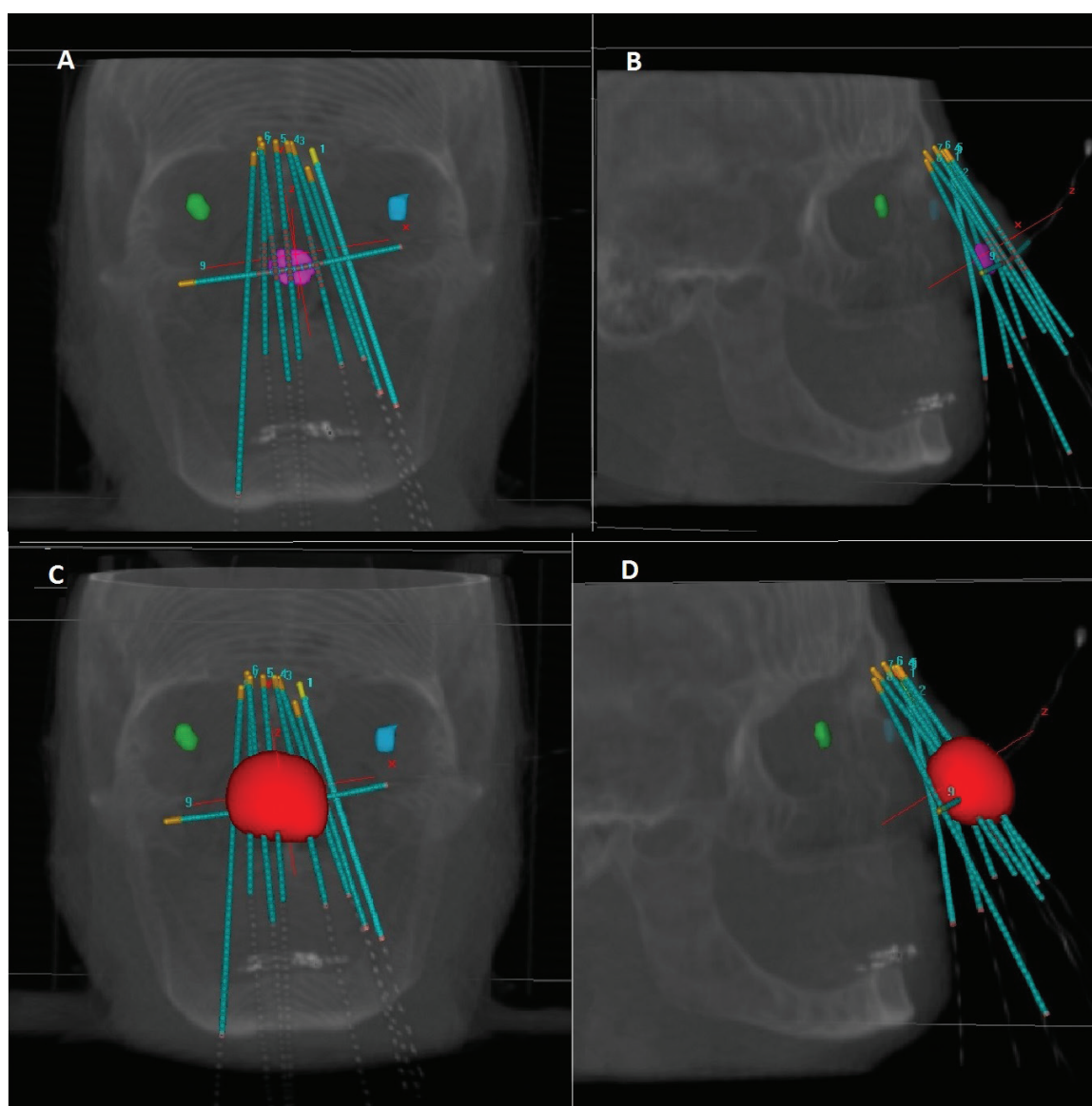


Figure 21. 3D reconstruction (A, C: front; B, D: side) of PTV applicators OARs and 3D dose reference distribution.

Before breast brachytherapy treatment begins, after radical dissection, it is necessary to perform tumor bed imaging. Computed tomography is the advised method to apply. Before CT examination, it is necessary to place markers on the post-surgical scar. The presence of this marker does not have a significant effect on the quality of images from CT. It is possible to use specialized markers for CT which, because of the material they are made of, is not the source of artifacts. Markers placed on the scar allow more precise tumor bed localization and therefore more precise applicator administration into the tumor bed area. The process for locating of tumor area is facilitated by surgical clips. They are easily identifiable in CT examination. Their presence allows for exact defining of targets location. We can adopt two techniques with the boost. One technique takes advantage of a frame so-called a template; another one on the other hand uses metal needles. The choice of a given technique depends mainly on target

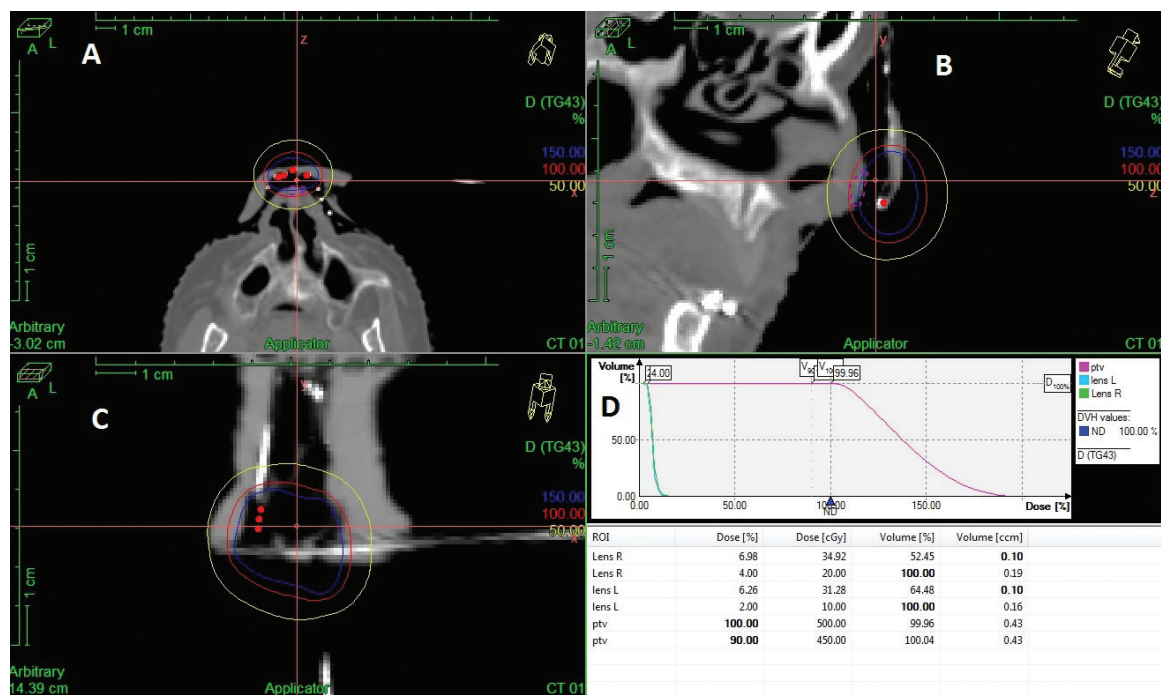


Figure 22. CT images and reconstruction on several planes (A, B, C) and DVH (D).

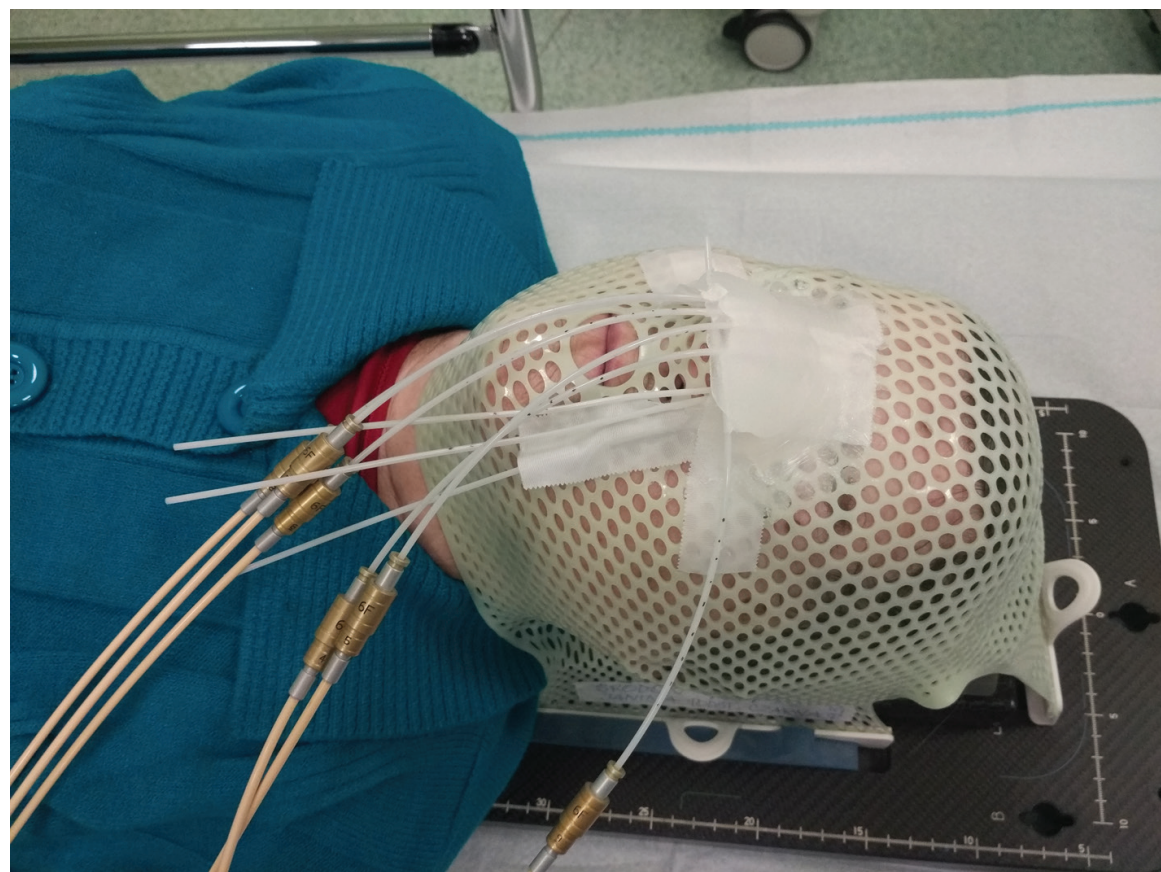


Figure 23. Patient treated with an orfit mask.

location and patient's anatomical structure. If a patient has got big breasts and the tumor bed is located in the central area of the breast, then we use the template. This template consists of two plates and a connector which mounts those plates parallel within specified proximity. The plates have openings through which applicators are put through. The number and the arrangement of the plates are the same on both plates. The distance between openings on plates is between 10 and 18 mm. The choice of the appropriate template depends on the size, positioning of the tumor bed, and patient's anatomical structure. By using templates, the position of needles is parallel. By applying the template, depending on patient's breast size, we can change its form. The breast is squeezed by the plates what can result in differences in implantation geometry. This kind of obstacle can be avoided by performing three-dimensional imaging with already applied template. In cases where the application geometry is not satisfactory, it is possible to use a different template. Where the implant geometry is not satisfactory after application deriving from the used template, there is no possibility to change it without removing applicators.

Second technique, so-called free hand, differs from the one already mentioned as in this case, the needles are applied without using templates. This technique requires extensive experience from the person performing the treatment. Location of needles is not determined by the plates so they can run non parallel. Such distribution can provoke difficulties in obtaining the required spatial distribution of isodose in the target area. Creating of an acceptable computerized treatment plan by physicist requires wide experience in this type of application. It is simply because it is possible that some areas can occur with higher or lower dosage than the reference dosage prepared for PTV areas. This method can be successfully applied with small and average breasts. Arbitrariness in needle maneuvering in the breast allows for higher degree of risk organs protection. After applying templates, skin, as its being squeezed by plates, can move to closer proximity to the PTV area. This can cause telangiectasias in the skin area. When applicators are applied free hand, tumor beds do not change their location in reference to the skin. In cases where tumor bed is positioned in small proximity to the chest wall, it is possible to introduce applicators directly into bed area while applying the free-hand technique. Where templates are used, structure of the plate reduces the possibility of introducing applicators in the PTV area. After deciding on palliation technique based on previously performed imaging, we can proceed to needle implantation. During application, it is possible to perform low-dose CT in order to regulate applicator's trajectory through tumor bed area. After application is completed, it is necessary to secure the needles from moving out by applying clips onto them. It is particularly important when taking advantage of this technique, but it also secures the needles from relocation while attaching transfer tubes. It is crucial to remove mandrins from the needles as they are the source of numerous artifacts in computer tomography imaging. They significantly affect the image quality especially because they are in the PTV area.

In case of brachytherapy as an independent form of treatment, we can use several different applicators. As with the boost, we can apply plate/template techniques. The difference between boost procedures and unassisted treatment lies mainly in the number of fractions. Boost is applied in one of the fractions whereas Accelerated Partial Breast Irradiation (APBI) in eight fractions. Because of that, all metal needles have been replaced with plastic guides,

which remain in patient's body through the whole treatment process. The guides are closed up with clips on the one end, whereas on the other end, we can find a connector that mounts introduced needle. Plastic needle is present in patient's body only during irradiation; they are being removed once irradiation has been completed. Because those needles are made of plastic, it is necessary to introduce dedicated markers to make them visible in CT imaging. Another method applied is so-called balloon method which takes advantage of SAVI applicator. This applicator consists of several channels with in its central part and rest in its circumferential area. To be able to apply this applicator, the patient has to be operated for open cavity surgery. After introducing applicator into tumor bed, it is being adjusted by dilating channels located on its borders (circumferentially). Applicator is monitored by ultrasonography (USG) while being introduced; then, three-dimensional imaging is performed. Before CT examination, it is important to mark one of the channels on patient's body to be able to verify applicator's location in reference to the tumor bed. Verification should be taken place before each and every irradiation fraction. The applicator is introduced into patient's body for the whole time of treatment process. Breast cancer treatment process based on three-dimensional images allows you to determine the dosage for the actual PTV area. Taking advantage of computer tomography made it possible to search for new types of applicators, which, in course, allows to cover the desirable target area and protection of critical organs. TPS images present marked the target and all risk organs. Reference dose is specified for the whole PTV area, and risk organs in this case are skin area and the wall of the chest. In case of boost, the dosage equals 10 Gy, and in case of APBI/SAVI, it is 4 Gy 8 times twice a day [11].

2.3.1. Case

The first case presents a patient with breast cancer. The patient is after conservative treatment. Treatment is realized in the form of boost after external beam radiotherapy. The patient was treated with 10 Gy in 1 fraction. Before the treatment begins, the patient has computed tomography (**Figure 24**). The patient was treated with template. In the tumor bed were placed five applicators. **Figure 25** shows scans with volume target contoured in TPS. Illustration from computerized planning system depicts three-dimensional reconstruction applicators, PTV, and dose distribution (**Figure 26**). Reconstruction on several planes and DVH is presented in **Figure 27**.

2.3.2. Case

The second case presents a patient with breast cancer. Patient is after breast-conserving surgery. Treatment is realized in the form of boost after external beam radiotherapy. The patient was treated with 10 Gy in 1 fraction. Before the treatment begins, the patient has computed tomography (**Figure 28**). The patient was treated with the free-hand technique. In the tumor bed were placed eight applicators. **Figure 29** shows scans with volume target contoured in TPS. Illustration from computerized planning system depicts three-dimensional reconstruction applicators, PTV, and dose distribution (**Figure 30**). Reconstruction on several planes and DVH is presented in **Figure 31**. Patient with breast cancer treated using the free-hand technique is presented in **Figure 32**.

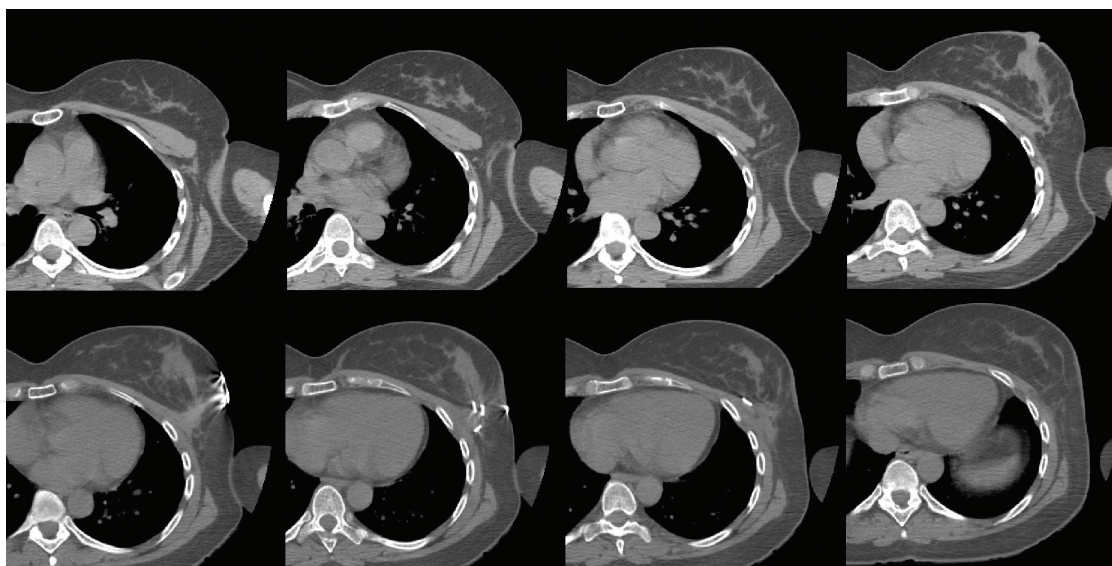


Figure 24. CT image before application with a marked scar.

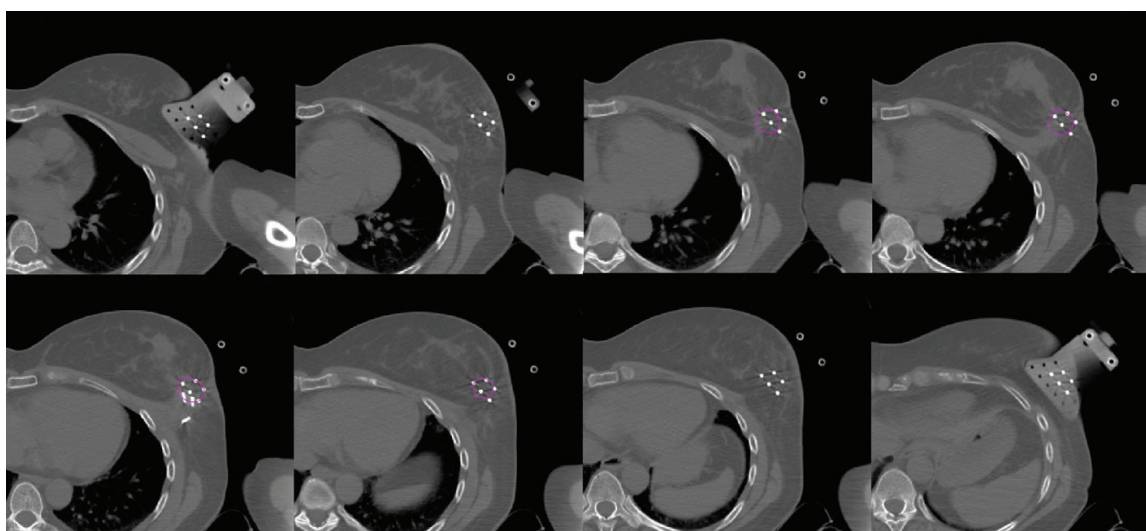


Figure 25. Images of the TPS with PTV.

2.3.3. Case

The third case presents a patient with breast cancer. Patient is after breast-conserving surgery. Treatment is realized in the form of post-surgical treatment (Accelerated Partial Breast Irradiation). The patient was treated with 32 Gy in eight fractions twice a day. Before the treatment begins, the patient has computed tomography (**Figure 33**). In the tumor bed were placed 12 applicators. **Figure 34** shows scans with volume target contoured in TPS. Illustration from computerized planning system depicts three-dimensional reconstruction applicators, PTV, and dose distribution (**Figure 35**). Reconstruction on several planes and DVH is presented in **Figure 36**.

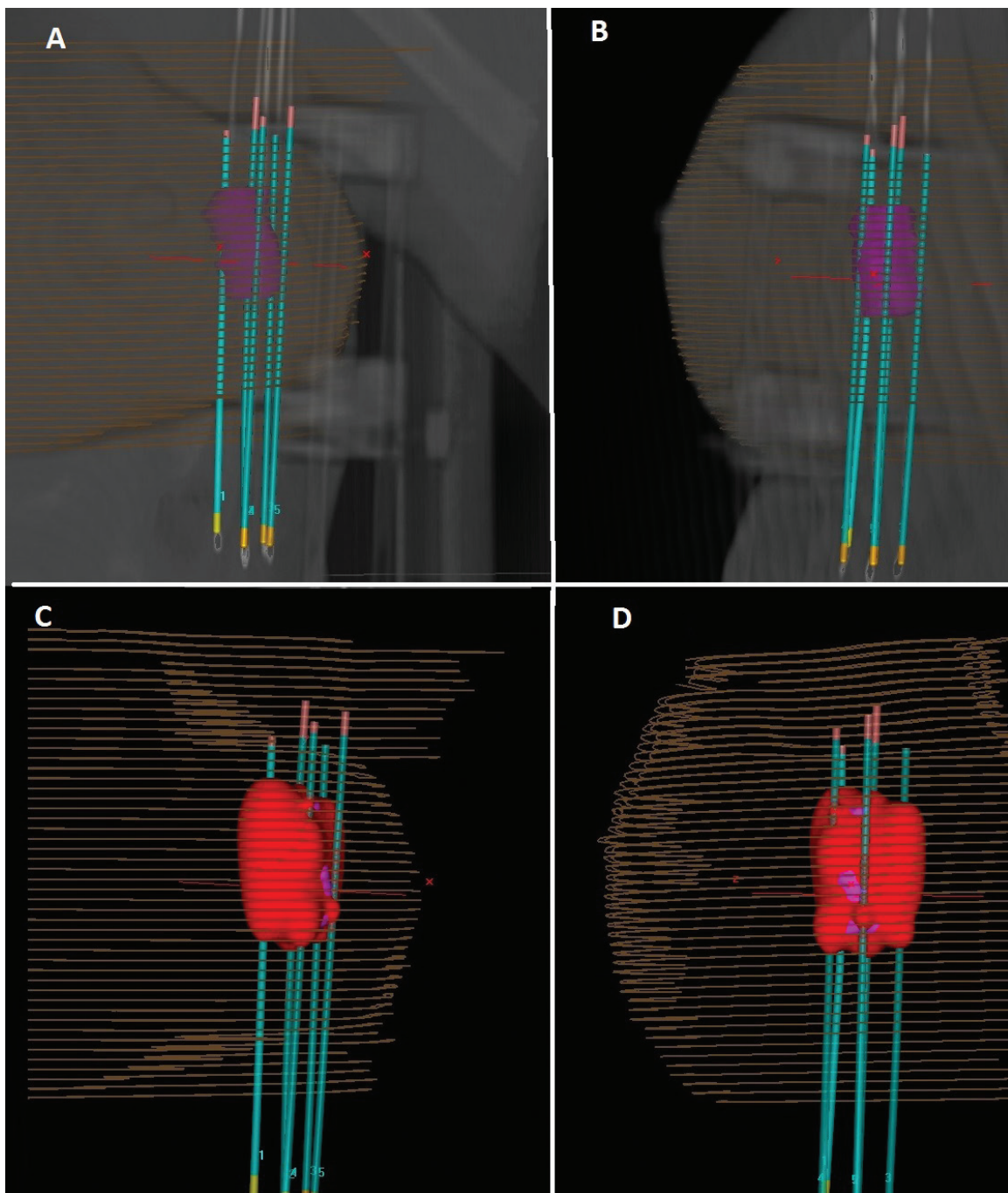


Figure 26. 3D reconstruction (A, C: front; B, D: side) of PTV applicators OARs and 3D dose reference distribution.

2.3.4. Case

The fourth case presents a patient with breast cancer. Patient is after breast-conserving surgery. Treatment is realized in the form of post-surgical treatment (Accelerated Partial Breast Irradiation). The patient was treated with 34 Gy in 10 fractions twice a day. Patient was treated by using applicator SAVI. Before the treatment begins, the patient has computed tomography

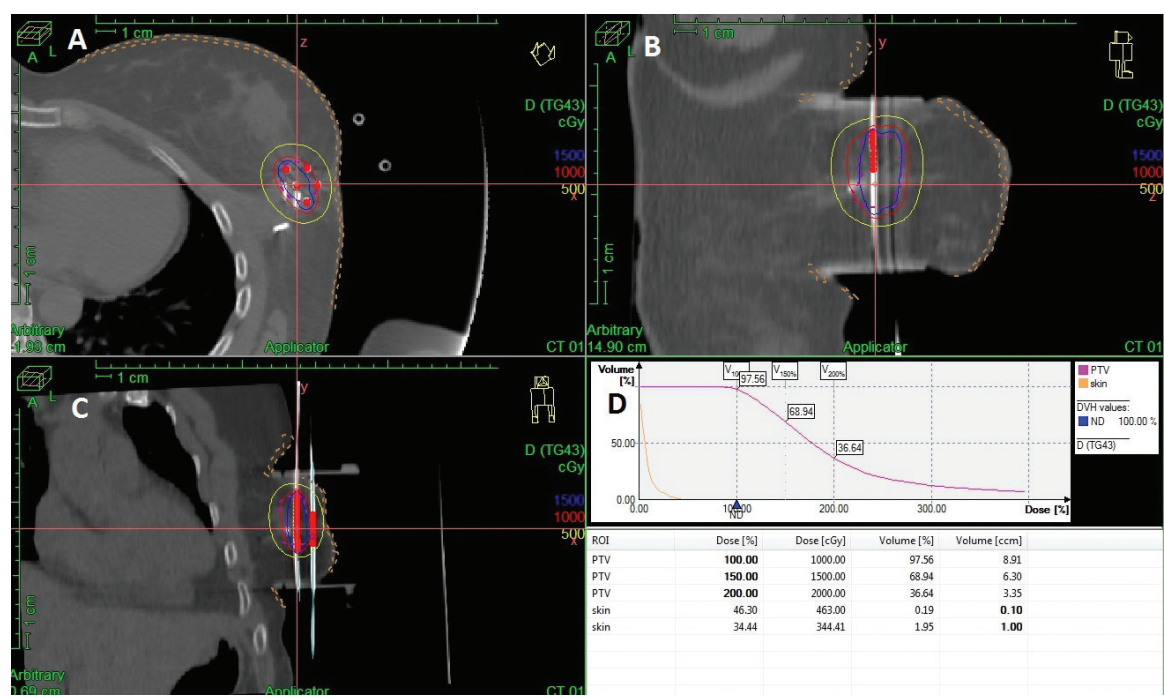


Figure 27. CT images and reconstruction on several planes (A, B, and C) and DVH (D).

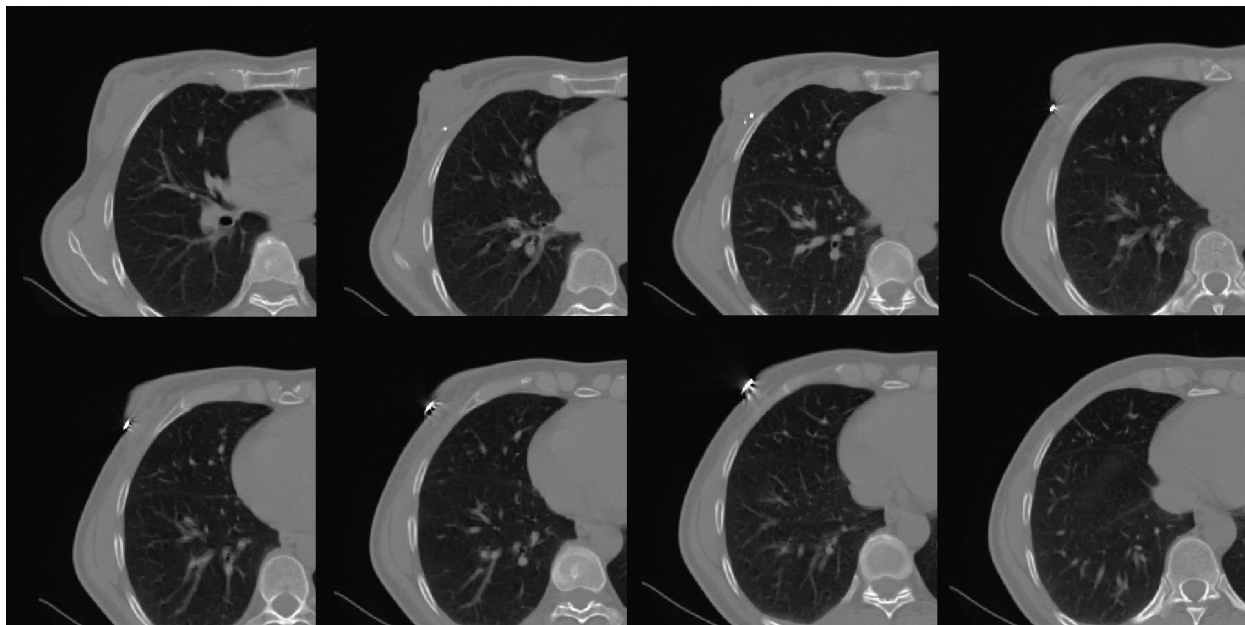


Figure 28. CT images before application with a marked scar.

(Figure 37). In the tumor bed was placed one applicator with seven channels. Figure 38 shows scans with volume target contoured in TPS. Illustration from computerized planning system depicts three-dimensional reconstruction applicators, PTV, and dose distribution (Figure 39). Reconstruction on several planes and DVH is presented in Figure 40.

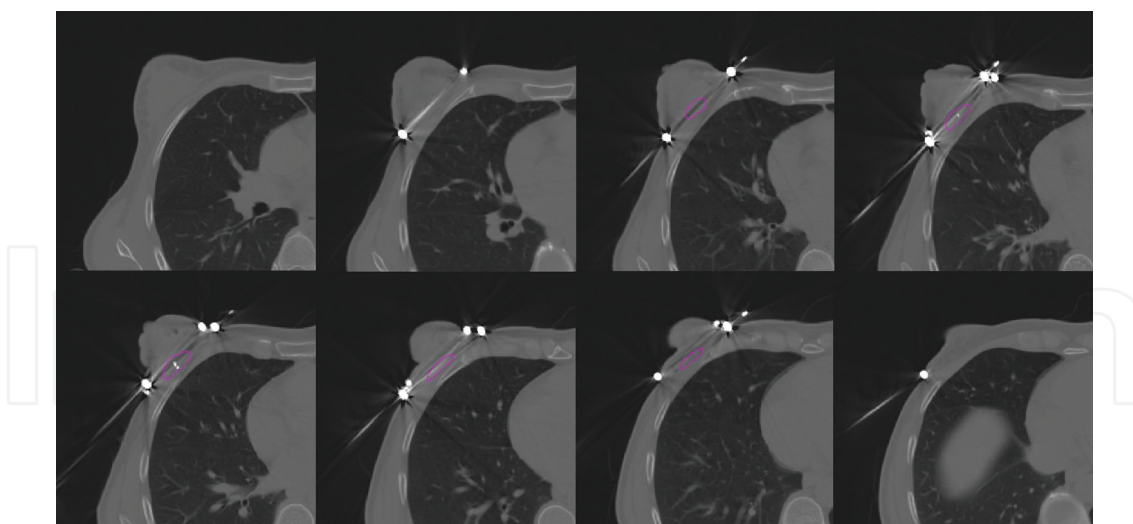


Figure 29. Images of the TPS with PTV.

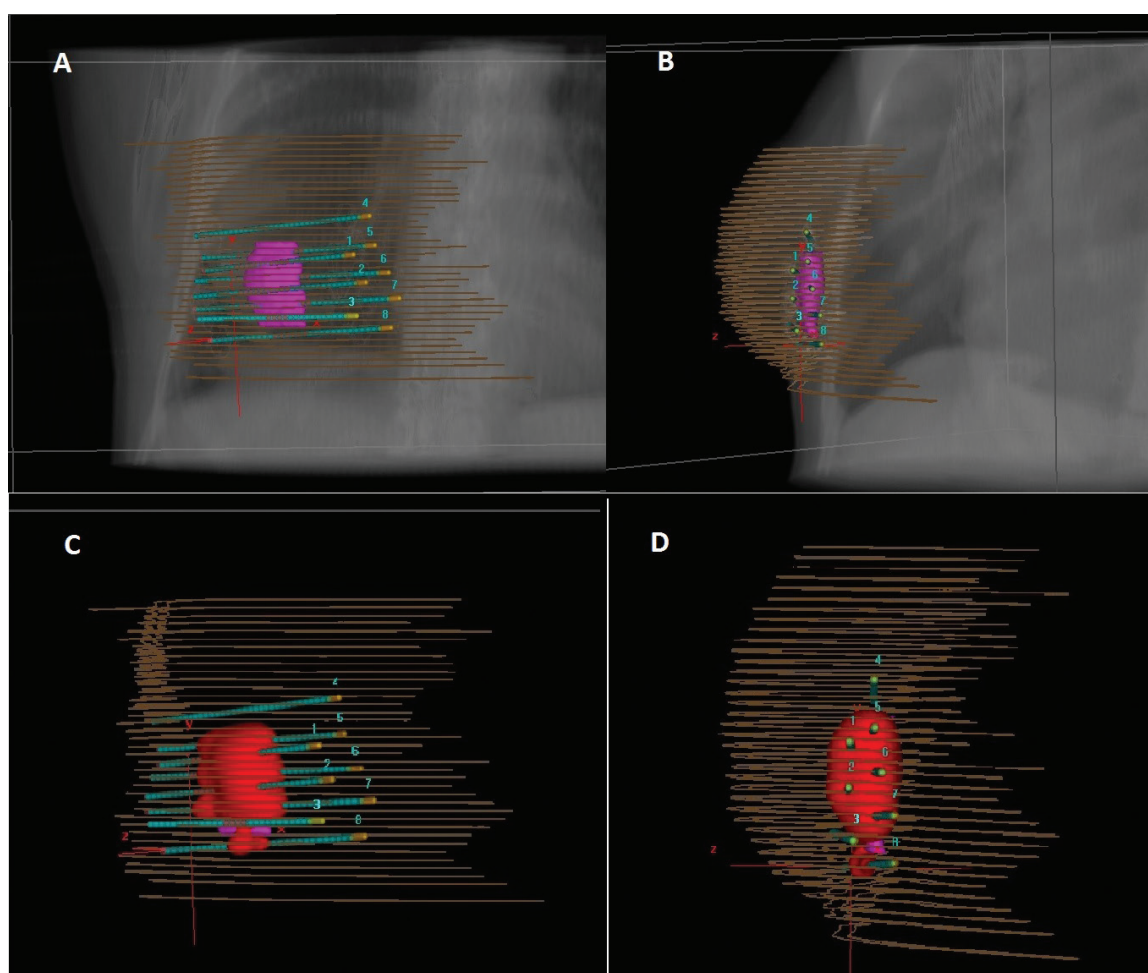


Figure 30. 3D reconstruction (A, C: front; B, D: side) of PTV applicators OARs and 3D dose reference distribution.

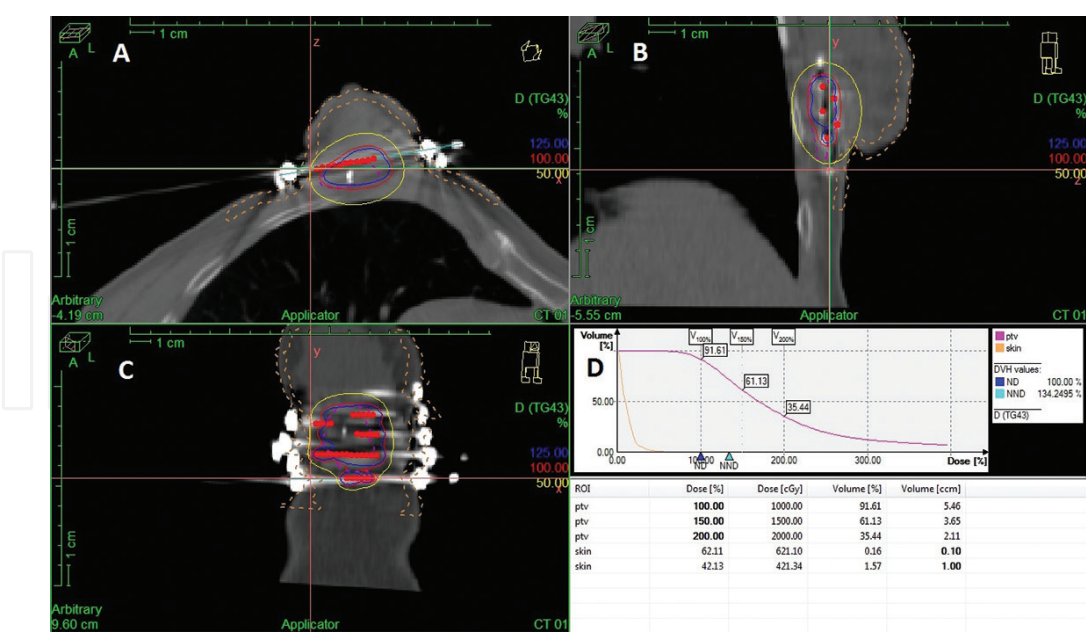


Figure 31. CT images and reconstruction on several planes (A, B, and C) and DVH (D).

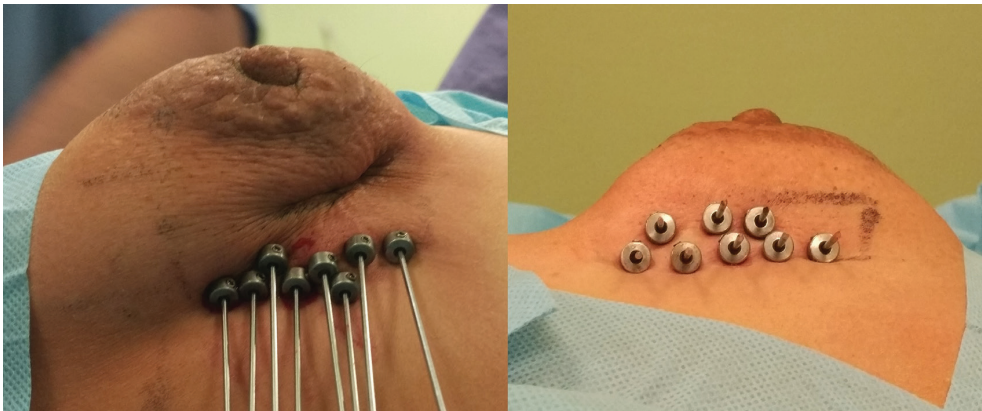


Figure 32. Patient with breast cancer treated using the free-hand technique.

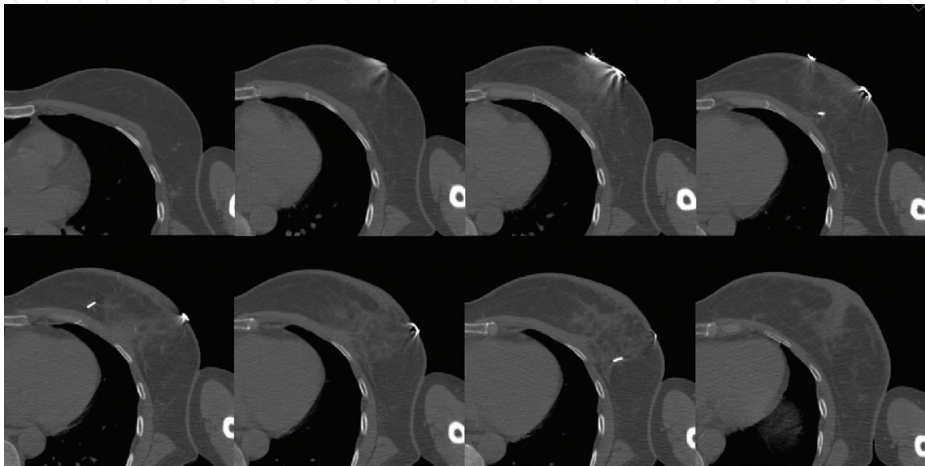


Figure 33. CT images before application with a marked scar.

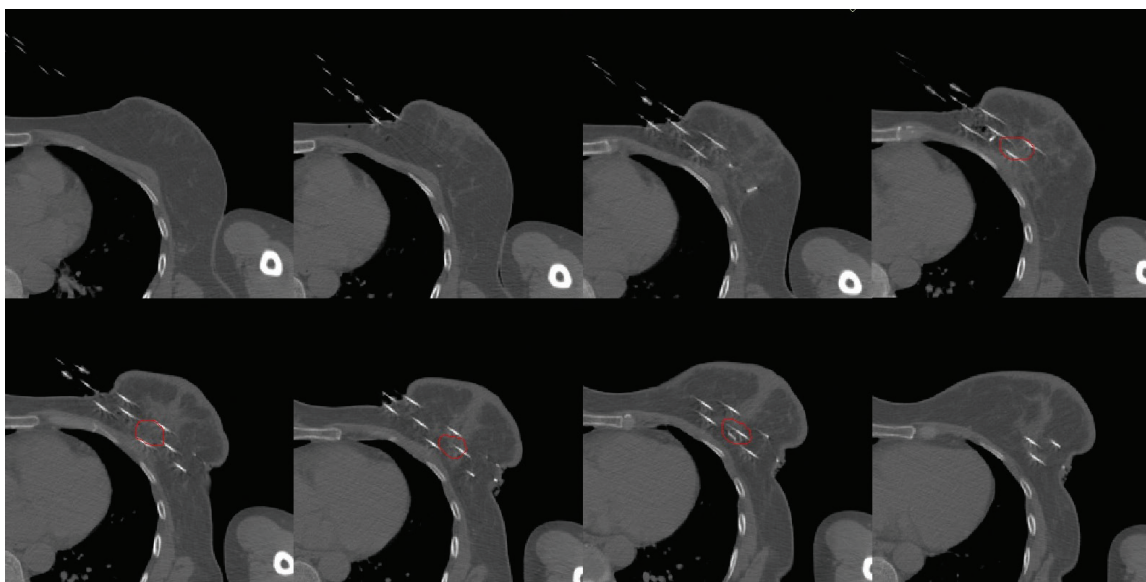


Figure 34. Images of the TPS with PTV.

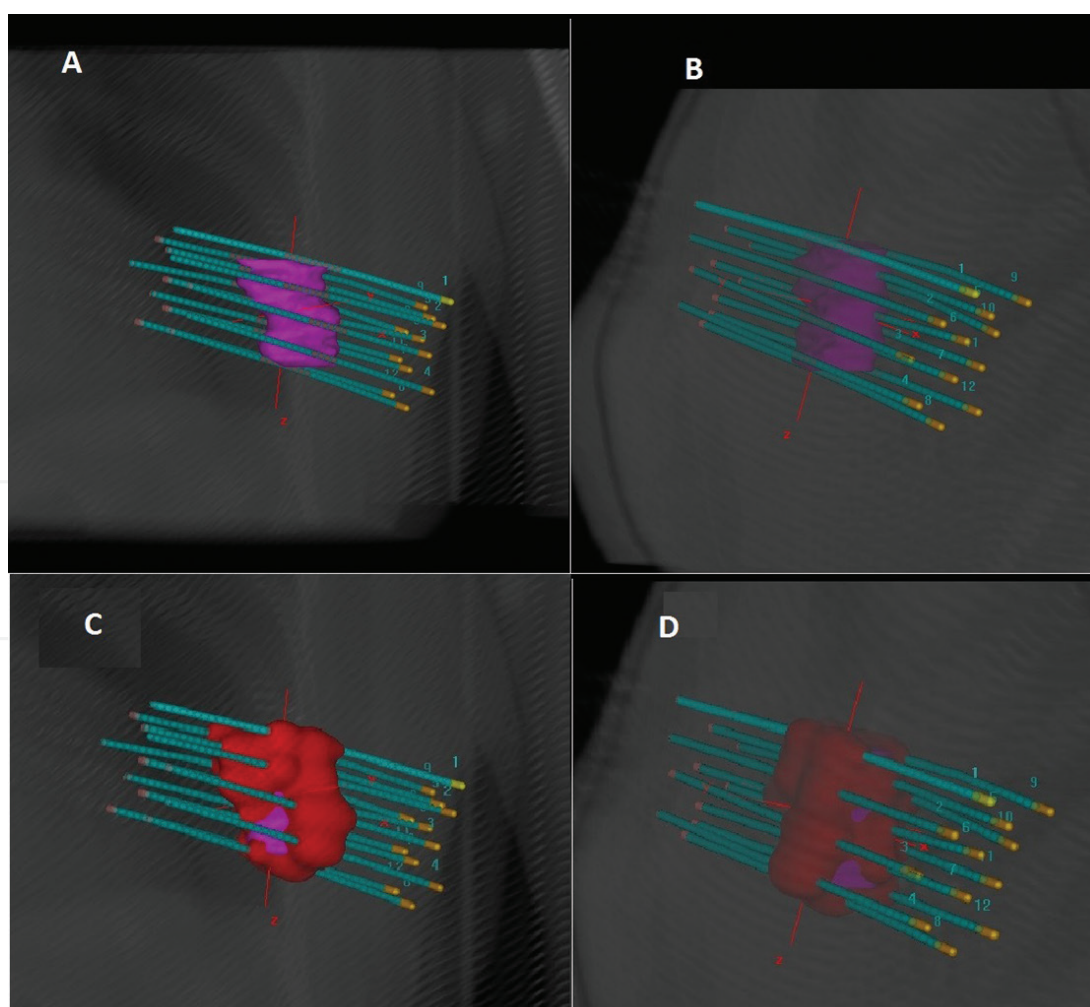


Figure 35. 3D reconstruction (A, C: front; B, D: side) of PTV applicators OARs and 3D dose reference distribution.

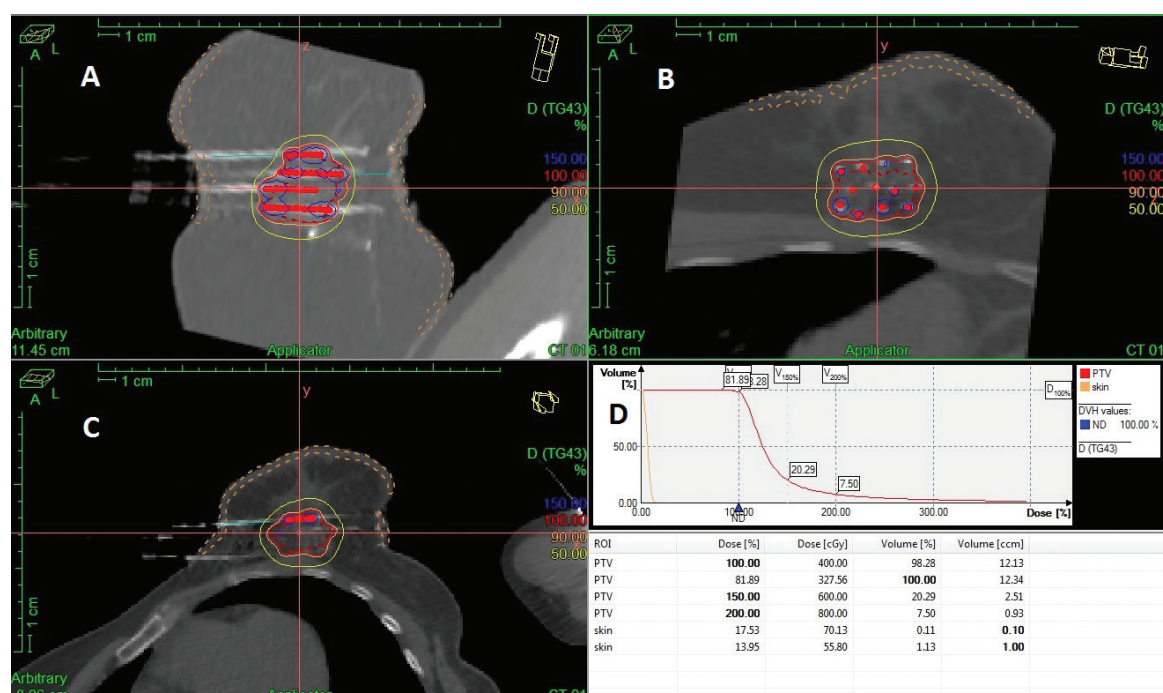


Figure 36. CT images and reconstruction on several planes (A, B, and C) and DVH (D).

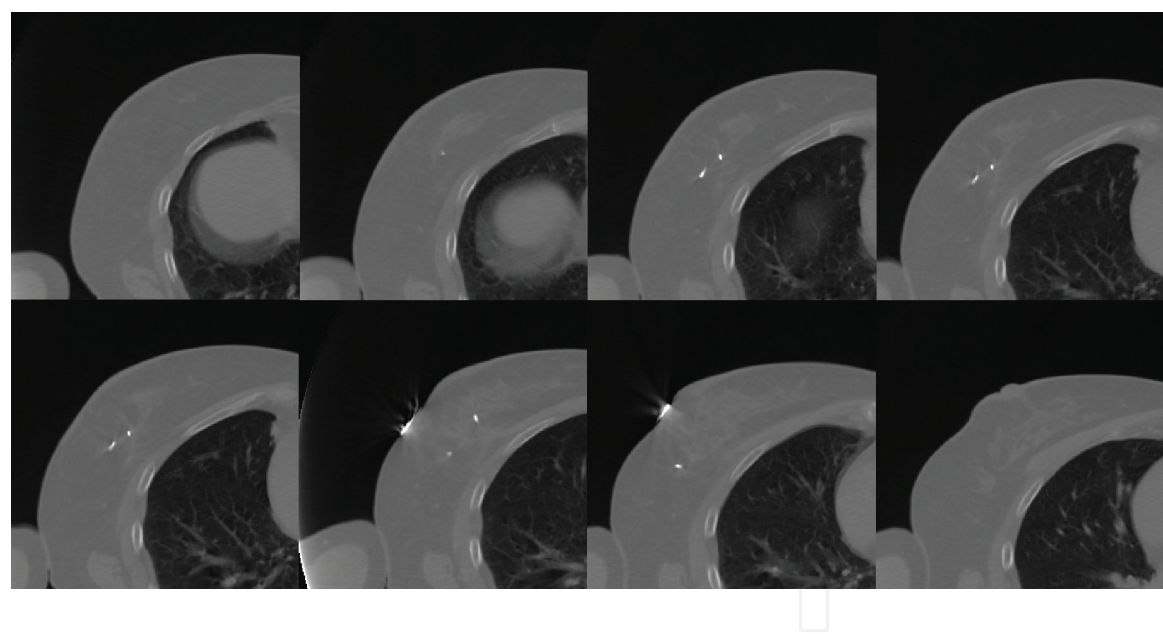


Figure 37. CT images before application with a marked scar.

2.4. Prostate cancer

Standard hospitalization procedure for patients suffering from prostate cancer in HDR brachytherapy is ultrasonographic imaging. Applicators used for the treatment are metal and plastic needles. Images are generated by Transrectal Ultrasound Scan (TRUS). Normally, the treatment kit consists of a transrectal probe that is mounted onto so-called stepper. A stepper is a set of mechanical lever system, a specialized stand with longitudinal boat for USG head at

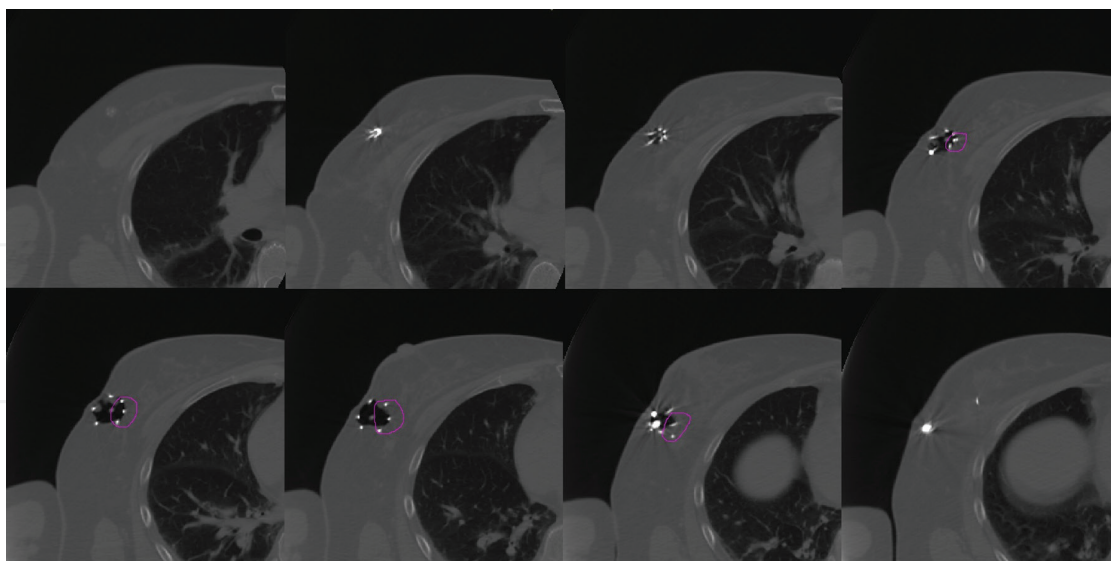


Figure 38. Images of the TPS with PTV.

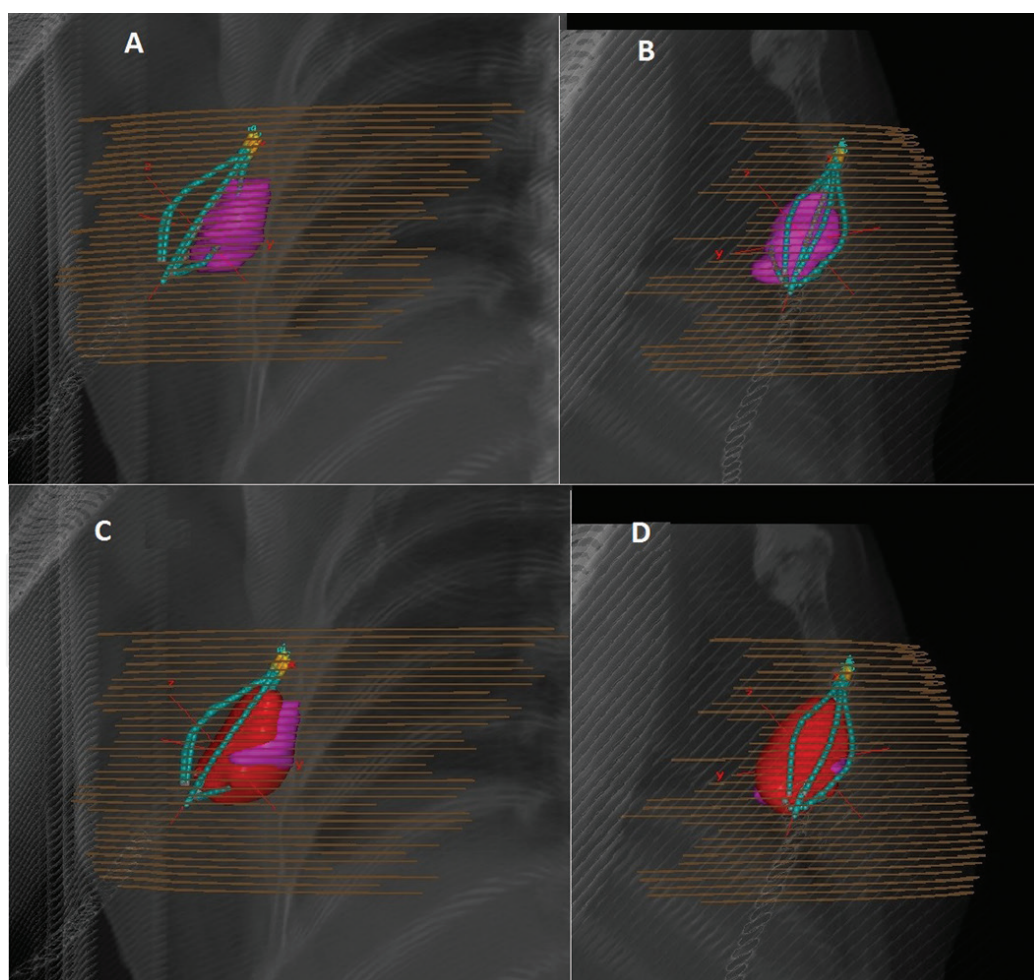


Figure 39. 3D reconstruction (A, C: front; B, D: side) of PTV applicators OARs and 3D dose reference distribution.

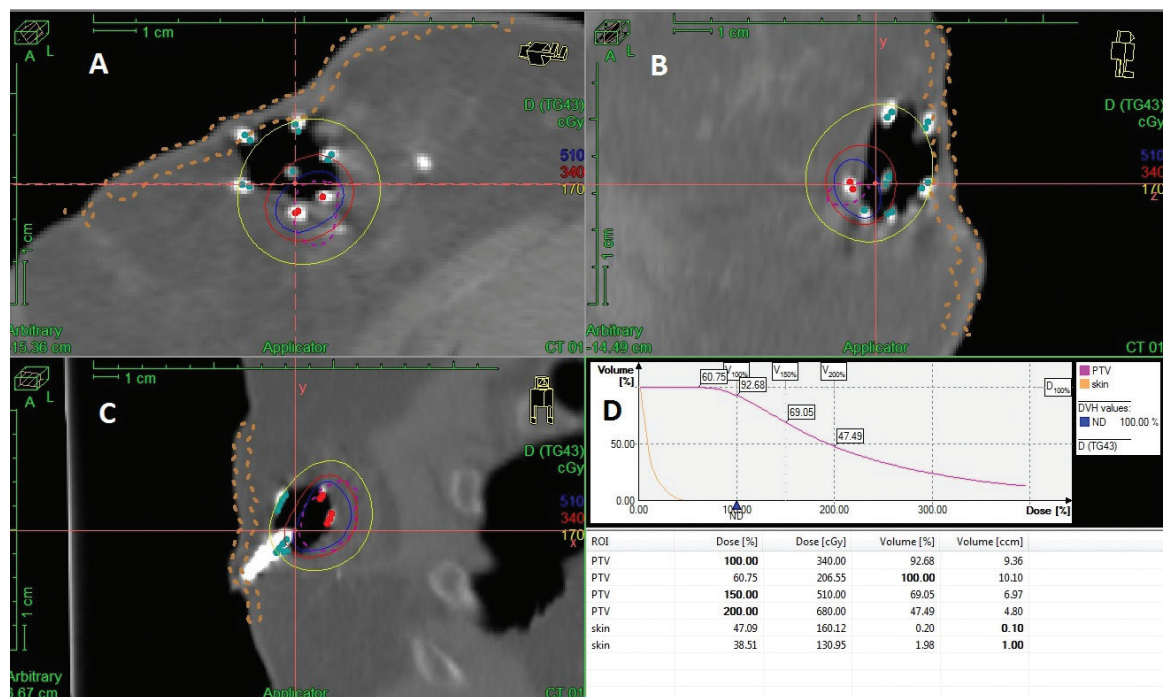


Figure 40. CT images and reconstruction on several planes (A, B, and C) and DVH (D).

its peak. During treatment, stepper was immobilized by being fixed to the floor. This prevents potential twists as well as target volume reading errors through planning system. Important function of the stepper was support of special ceramic targeting plate (template) and ultrasonographic head. This plate has a grid of coordinate system correlating to this equivalently in the planning system. It is setting distance between the needles and the correct direction of the needle applicators is established. Gland images acquired from the ultrasonograph (1 mm intervals) were sent to the planning system simultaneously (on-line), enabling real-life change in volume target irradiation in reference to metal applicators and neighboring organs.

Prostate cancer can also be treated with means of HDR brachytherapy based on three-dimensional imaging from computer tomography. In this case, the procedure is more complicated compared to applying TRUS. This technique is usually applied with patients who already went through surgery where rectum was removed along the cancerous tumor. It is not possible to introduce transrectal probe after having undergone Miles surgery. Treatment is conducted with the help of computer tomography. We do not have an online preview while inserting catheters into the prostate area. The patient is laid in lateral position and not, as it is for standard treatment, in gynecological position. The reason for this comes from the fact that the treatment itself takes place on computer tomography. With patient laid like that, we can introduce applicators and perform CT imaging. They do not have to change the position between application and imaging processes. Hence, the danger of applicator relocation caused by patient's movement is eliminated. Furthermore, the position and inability to apply the stepper exclude the option of applying the ceramic plate. The needles are reviewed in the free-hand technique. Before the treatment begins, a three-dimensional imaging is performed to determine target's location as well as its volume. After the analysis of 3D images, the depth to which applicators will be introduced into patient's body can be determined. After first few

needles have been applied, another computer tomography is performed to examine application geometry. The location as well as the depth, to which applicators have been introduced, is being inspected. Verification scheme is repeated after applying few applicators. After the application process is completed, a CT imaging is performed. Then, the images are sent to TPS with marked PTV and OAR areas. Prostate treatment planning based on CT imaging requires great experience from radiotherapist while introducing the needles into the prostate area. Medical physicists have to possess a wide experience in this type of procedures. In cases where needles are injected “free hand,” it is common for catheters to intersect in patient’s body, what in consequence can lead to difficulties when identifying individual applicators [12].

2.4.1. Case

The first case presents a patient with prostate cancer. Miles operation is a surgery for rectal cancer or anal cancer. The patient was treated with 30 Gy in two fractions twice a day. During application, the patient had twice CT examination for verification (**Figure 41**). In the tumor bed were placed 12 applicators. **Figure 42** shows scans with volume target contoured in TPS. Illustration from computerized planning system depicts three-dimensional reconstruction applicators, PTV, and dose distribution (**Figure 43**). Reconstruction on several planes and DVH is presented in **Figure 44**.

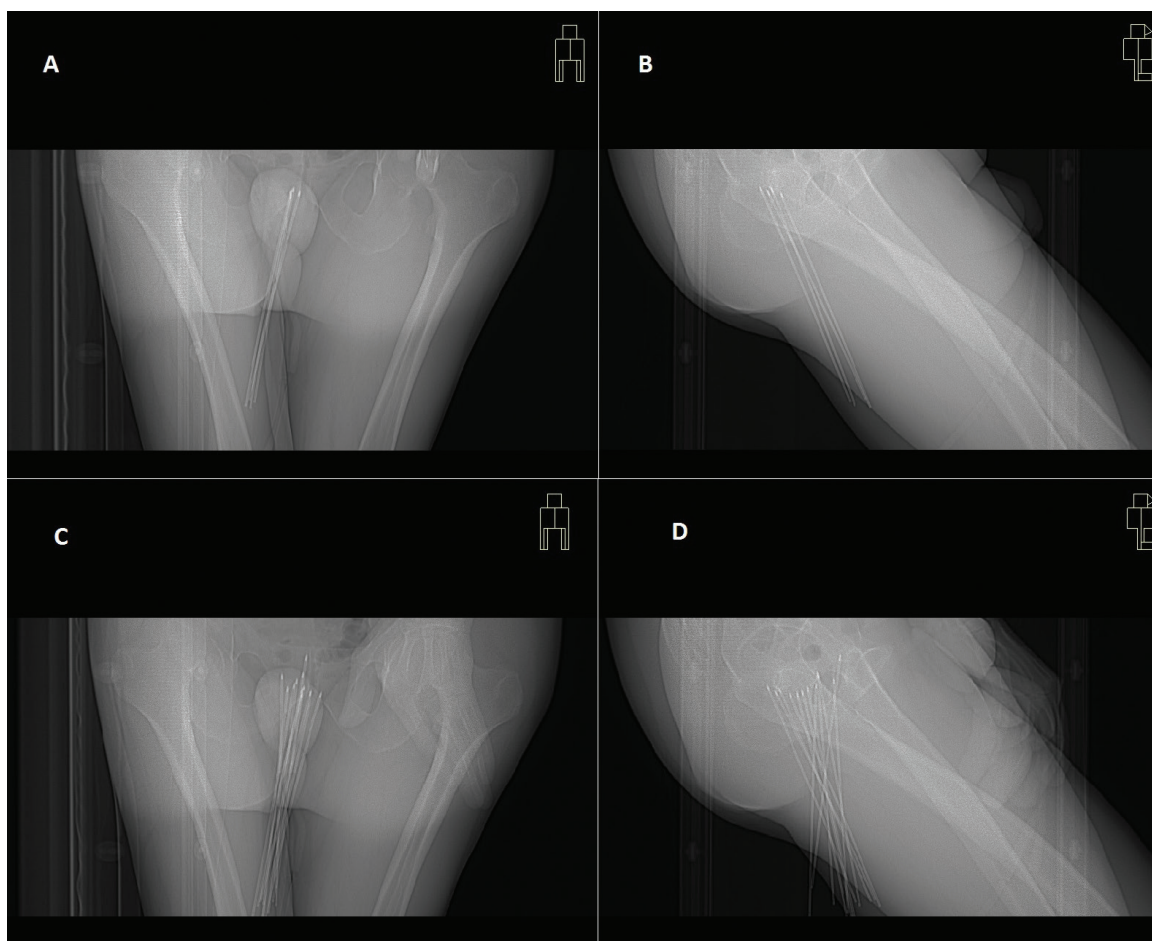


Figure 41. CT images: first imaging (A, B) and second imaging (C, D).

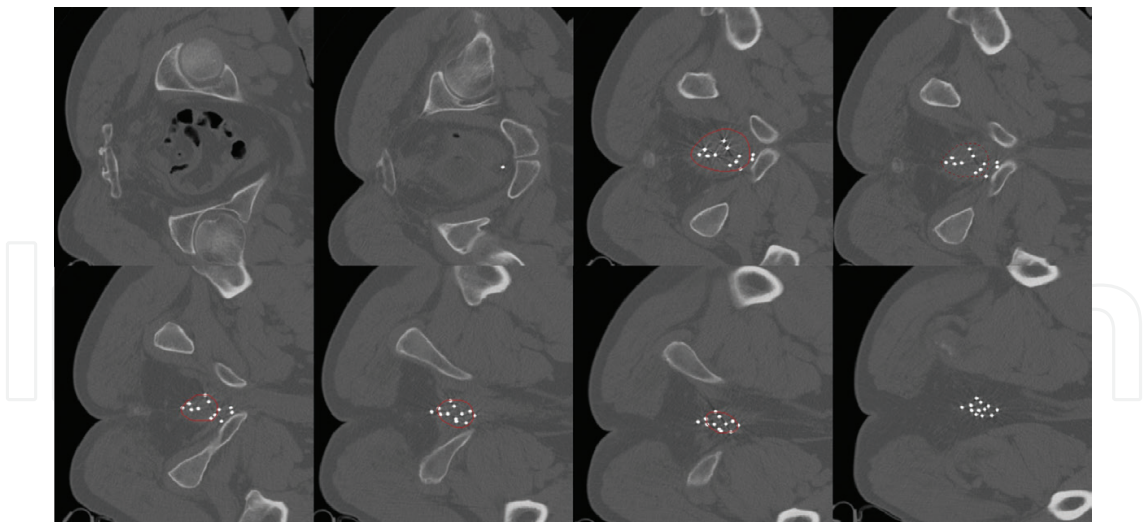


Figure 42. Images of the TPS with PTV.

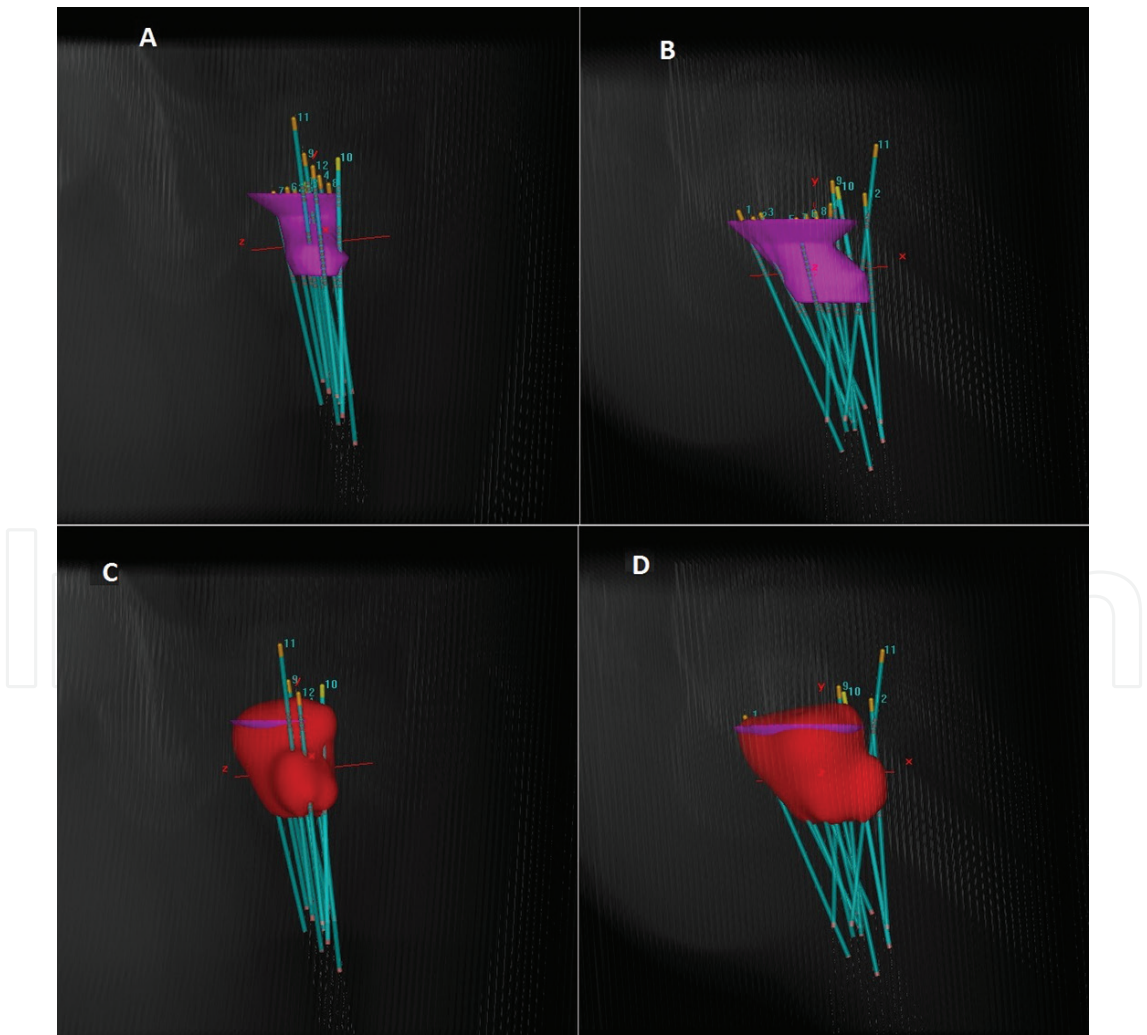


Figure 43. 3D reconstruction (A, C: front; B, D: side) of PTV applicators and 3D dose reference distribution.

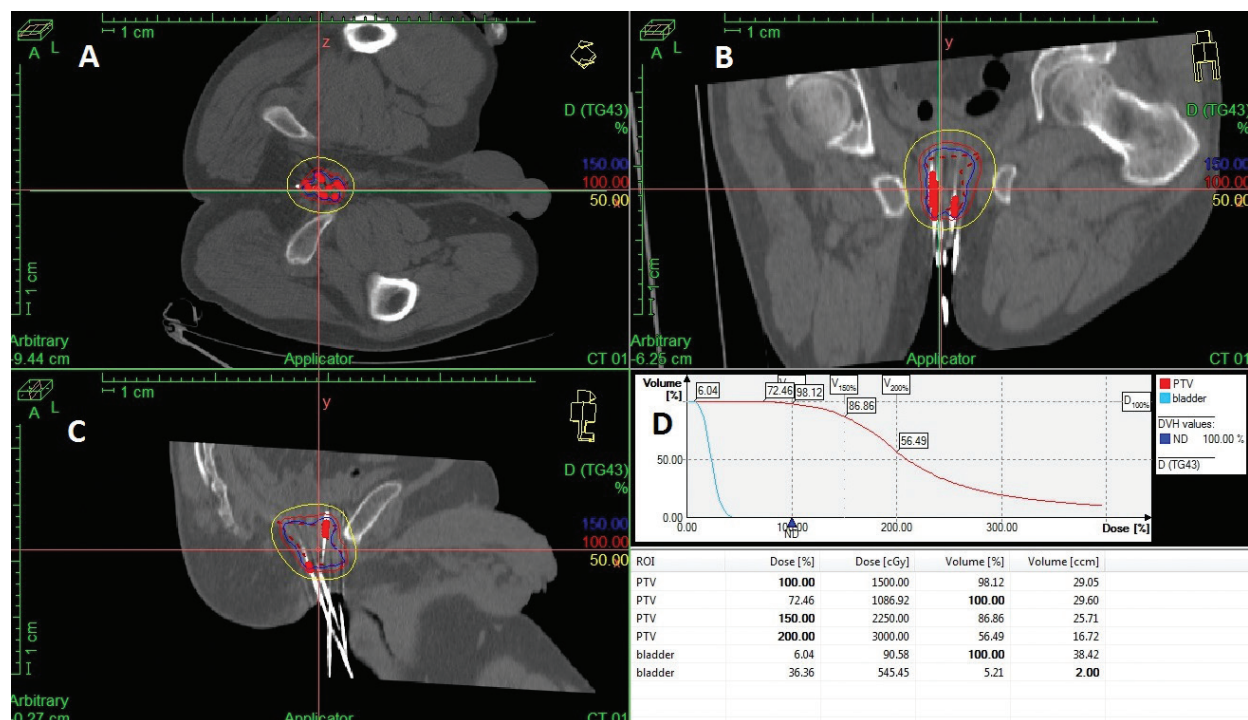


Figure 44. CT images and reconstruction on several planes (A, B, and C) and DVH (D).

3. Summary

Treatment planning in HDR brachytherapy based on three-dimensional imaging allows for prearranging and conducting optimal treatment in a given location. Routinely, in parts like the lung or esophagus, treatment plan is based on 2D imaging. Academic literature provides reports about incorporating 3D along with 2D imaging in lung cancer treatment. Significant differences are also pointed out when it comes to the coverage of the therapeutic area between these two methods. Thanks to the use of computer tomography, we have got the precise location of the irradiation area. We can adjust the most appropriate technique and applicators to conduct the most optimal treatment. What's more, the geometry of introduced implant allows for the ultimate target coverage with simultaneous protection of organs at risk

Utilizing three-dimensional imaging provides great possibility for treatment in location where previous access was hindered or impossible because of patient's anatomical structure or previously undergone procedures, i.e., Miles surgery.

Computer tomography allows for establishing individual treatment solutions that provide optimal approach to every patient as in skin cancer. With more and easier access to three-dimensional imaging, new ways of applying HDR brachytherapy open in new location as well as in form of radical treatment. With the use of imaging, we are now able to introduce catheters precisely into the tumor area with putting the patient at risk of posttreatment complications. It allows the treatment of people that no more qualify for other forms of treatment (radiotherapy). Because of the high gradient dose in HDR brachytherapy and patients with internal intracranial implants, i.e., pacemaker or cardioverter-defibrillator, we know exactly

the dose the device will receive, so we can perform the procedures without exposing the patient to additional risk. Thanks to different optimization forms based on 3D images, HDR brachytherapy is applied not only in palliative treatment but also in new ways of radical treatment, i.e., in case of APBI.

Author details

Marcin Sawicki

Address all correspondence to: savi8307@poczta.fm

Brachytherapy Department, Subcarpathian Cancer Center, Brzozów, Poland

References

- [1] Makarewicz R, editor. Brachyterapia HDR. Via Medica, Gdańsk; 2004
- [2] Sawicki M. The evaluation of treatment plans in high-dose-rate endobronchial brachytherapy by utilizing 2D and 3D computed tomography imaging methods. *Journal of Contemporary Brachytherapy*. 2014;**6**(3):289-292
- [3] Zvonarev PS. 2D/3D registration algorithm for lung brachytherapy. *Medical Physics*. 2013;**40**:021913
- [4] Khan FM, Gibbons J, Mihailidis D, Alkhatib H, Khan's Lectures: Handbook of the Physics of Radiation Therapy. LWW, Gdańsk; 2009
- [5] Melhus CS, Rivard MJ. Approaches to calculating AAPM TG-43 brachytherapy dosimetry parameters for Cs, I, Ir, Pd, and Yb sources. *Medical Physics*. 2006;**33**:1729
- [6] Pérez-Calatayud J, Granero D, Casal E, Ballester F, Puchades V. Monte Carlo and experimental derivation of TG43 dosimetric parameters for CSM-type Cs-137 sources. *Medical Physics*. 2005;**32**(1):28-36
- [7] Cavanaugh SX, Vidovic A, Law T, Bechara R, Parks C, Wei J, Swanson J. Multichannel endobronchial HDR catheter respiratory motion and resultant dosimetric variation. *Brachytherapy*. 2015;**14**:47
- [8] Stewart A, et al. American Brachytherapy Society consensus guidelines for thoracic brachytherapy for lung cancer. *Brachytherapy*. 2016;**15**(1):1-11
- [9] Łyczek J, et al. Comparison of the GTV coverage by PTV and isodose of 90% in 2D and 3D planning during endobronchial brachytherapy in the palliative treatment of patients with advanced lung cancer. Pilot study. *Journal of Contemporary Brachytherapy*. 2012;**4**:113-115

- [10] Kowalik L, Łyczek J, Sawicki M, Kazalski D. Individual applicator for brachytherapy for various sites of superficial malignant lesions. *Journal of Contemporary Brachytherapy*. 2013;**5**(1):45-49
- [11] Polgár C, Ott OJ, Hildebrandt G, Kauer-Dorner D, Knauerhase H, Major T, Slampa P. Late side-effects and cosmetic results of accelerated partial breast irradiation with interstitial brachytherapy versus whole-breast irradiation after breast-conserving surgery for low-risk invasive and in-situ carcinoma of the female breast: 5-year results of a randomised, controlled, phase 3 trial. *The Lancet Oncology*. 2017;**18**(2):259-268
- [12] Łyczek J, Kazalski D, Sawicki M. Brachytherapy treatment planning for prostate cancer with the use of the computed tomography-based (CT-based) planning software in patients after total primary amputation of the rectum and EBRT (External Beam Radiation Therapy) due to rectal cancer. *Physica Medica*. 2016;**32**:227

