

# We are IntechOpen, the world's leading publisher of Open Access books Built by scientists, for scientists

6,900

Open access books available

186,000

International authors and editors

200M

Downloads

Our authors are among the

154

Countries delivered to

TOP 1%

most cited scientists

12.2%

Contributors from top 500 universities



WEB OF SCIENCE™

Selection of our books indexed in the Book Citation Index  
in Web of Science™ Core Collection (BKCI)

Interested in publishing with us?  
Contact [book.department@intechopen.com](mailto:book.department@intechopen.com)

Numbers displayed above are based on latest data collected.  
For more information visit [www.intechopen.com](http://www.intechopen.com)



---

# Robotic Ventral Hernia Repair

---

Kaylene Barrera, Paul Chung, Sarrina Shrager and  
Gainosuke Sugiyama

Additional information is available at the end of the chapter

<http://dx.doi.org/10.5772/intechopen.68950>

---

## Abstract

Approximately 350,000 to 500,000 ventral hernias are repaired yearly in the United States. These hernias include congenital umbilical hernias, incisional hernias from previous surgeries, or epigastric hernias. The crux of hernia repair is honoring the principle of achieving a tension-free repair, often achieved with utilization of a synthetic mesh. Over the last quarter of this century, laparoscopic ventral hernia repair has established itself as a valuable tool in repair of ventral hernias, with the advantages of reduced postoperative complications. More recently, the adaptation of the robotic platform has given another tool to perform ventral hernia repairs. The aim of this chapter is to describe the evolution of ventral hernia repairs and highlight the robotic approaches to repair.

**Keywords:** robotic ventral hernia repair, incisional hernia, umbilical hernia, robotic surgery introduction

---

## 1. Introduction

Ventral hernias are a classification of hernias affecting the abdominal wall. Included in this definition are epigastric, umbilical, Spigelian, and incisional hernias [1]. Repair of these hernias remains one of the most commonly performed procedures with more than 350,000 performed per year in the United States (SAGES) [2]. In addition to the cosmetic detriment, these hernias also pose a risk for bowel ischemia and strangulation, which can result in grave consequences.

Early descriptions of ventral hernias were evident in tomb paintings from ancient Egypt. Servants and workmen were depicted with abdominal protrusions [3]. Historian George Moritz Ebers (1837–1898) obtained an ancient papyrus, now referred to as the “Ebers papyrus.”

---

In that document, additional descriptions of hernias were given. In ancient Greece, Hippocrates (460–375 BC) also described inguinal hernias [4]. While attempts to operate on inguinal hernias have been well described through the Middle Ages to the nineteenth century, reports on ventral hernia repairs during this era were limited.

The first reports of surgical hernia repair were published in the late nineteenth and early twentieth centuries, mostly describing umbilical hernia repair. At the time, surgical repair of hernias was considered “radical,” with most people preferring reduction with a pad or suspension of incarcerated hernias [5]. Dr. Lucas-Championniere was one of the first surgeons to describe the principle of excising the hernia sac and closure of the neck [6]. The next evolution in hernia repair came in circa 1901, when William Mayo described primary repair using overlapping layers of fascia, or “pants over vest” technique. He “advocated the overlapping of the aponeurotic structures which were already at hand, securing a wide area of adhesions in place of edge to edge union” [7]. Incisional hernias were also recognized in this era. Kenelm Winslow described the experience of surgeons at the time emphasizing prevention of these hernias by closing incisions in layers. He also noted that although the repair described by Mayo had become popular, recurrence was a persistent problem, especially with large hernias [8]. In the early 1960s, knitted polypropylene mesh was introduced, which revolutionized repair, allowing for decreased recurrence rates. This repair allowed for additional variations in repair based on the placement of the mesh including extraperitoneal versus intraperitoneal placement [9, 10].

The evolution of hernia repair continued with adaptation of minimally invasive surgery. The first laparoscopic ventral hernia repair was described in 1993 by LeBlanc and Booth [11]. Using 4 to 5 trocars, they repaired hernias in five patients using polytetrafluoroethylene (PTFE) mesh [8]. Laparoscopic ventral hernia repair has become increasingly utilized in select cases, allowing for increased mesh overlap of defects and reduced postoperative complications compared to open repair. A limitation to laparoscopic ventral hernia repair, however, is that it remains a technically challenging procedure with a steep learning curve.

Robotic surgery allows for a way to alleviate the challenges presented by laparoscopic surgery. In 2000, the FDA approved the first robotic surgery system. The first robotic assisted ventral hernia repair was first described by Ballantyne et al. in 2003 [12] during which a PTFE mesh was placed and secured with a combination of sutures and tacks. Currently, the use of robotic ventral hernia repair is growing worldwide as a robotic platform allows for a more straightforward primary closure of the defect with the aid of wristed instruments. As the current body of literature is still evolving, the evaluation of its role as it relates to laparoscopic or open ventral hernia repairs is yet to be determined.

## 2. Indications

- Incisional hernia
- Umbilical hernia
- Spigelian hernia

- Epigastric hernia
- Incarcerated hernia

### 3. Contraindications

- Inability to tolerate general anesthesia
- Dense adhesions
- Bowel necrosis

### 4. Conversion to laparoscopic or open procedure

Conversion to conventional laparoscopy may be necessary if there is malfunction of the robotic components.

The surgeon should be prepared to convert to an open procedure in the event of significant hemorrhage, bowel injury, or limited accessibility due to diffuse adhesive disease.

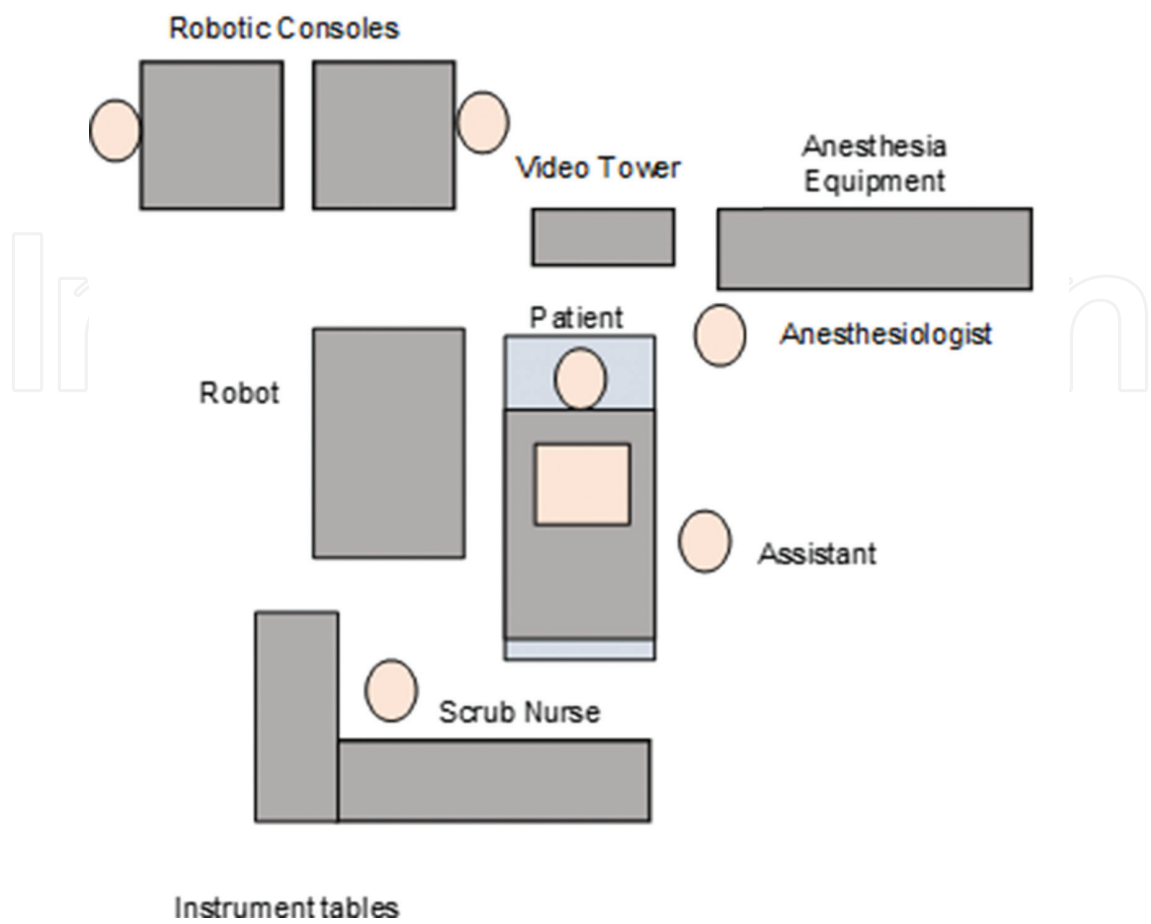
### 5. Procedure

#### Materials

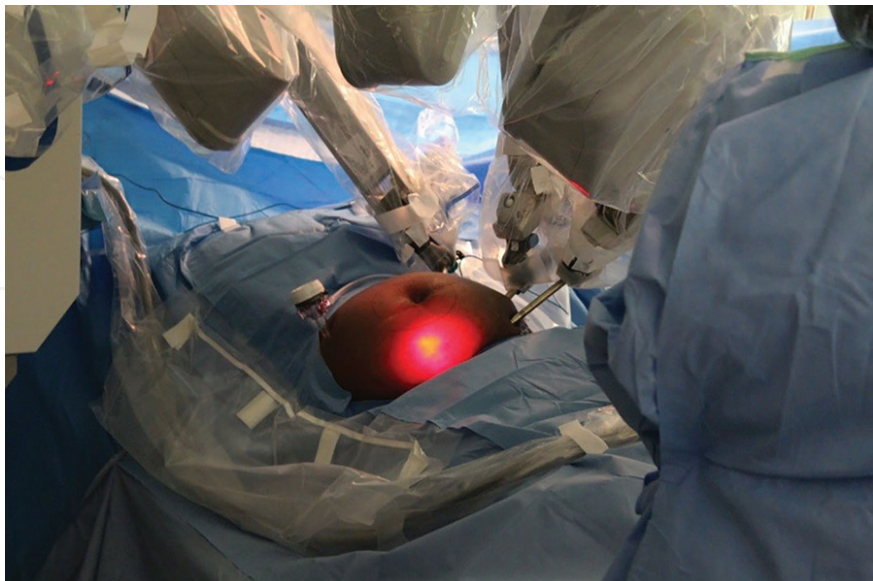
- da Vinci robotic platform
- Endo shears
- Blunt grasper
- Hook cautery
- Available energy source
- Mesh
- (optional) Sterile ruler; ruler provided with marking pen can be used
- (optional) Air seal

#### 5.1. Patient setup

After administration of general anesthesia, the patient is placed in the supine position with arms tucked. The operating table can be rotated to accommodate positioning of the robotic tower (**Figures 1 and 2**). Three ports are placed on the contralateral (or any side if hernia is



**Figure 1.** Operating room setup.



**Figure 2.** Docked robot with port placement.

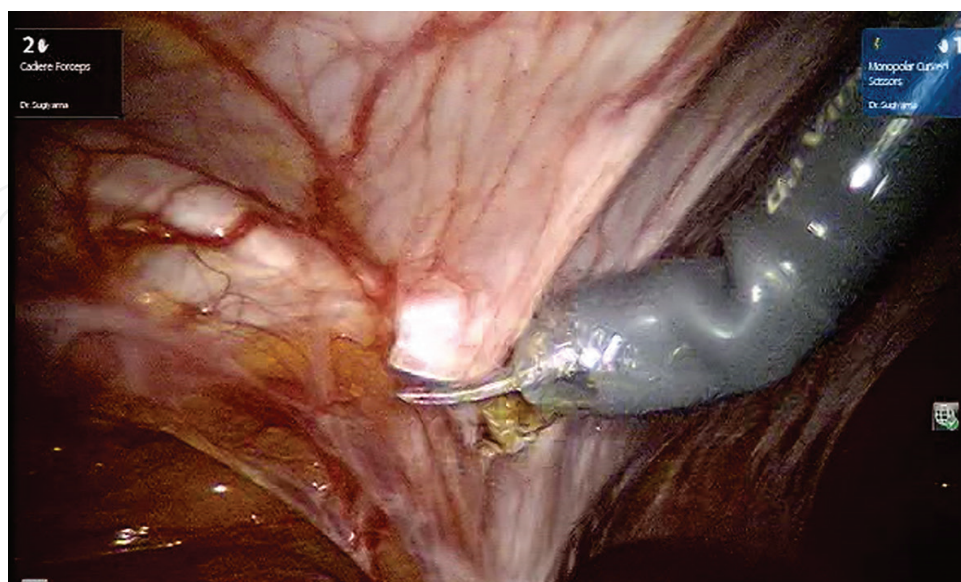
midline) side to accommodate the instrument arms and camera. The ports are 5 or 8 mm wide and are placed 8 to 10 cm apart to avoid instrument collision. If using the da Vinci Si system, it may help to place bariatric trocar near the anterior superior iliac spine to avoid collision with the hip during dissection. Utilizing bariatric long trocar will move the instruments away from the hip, thus allowing for a free range of motion with the instruments. In our practice, we sometimes also include an accessory port on the opposite side to assist with instrument exchanges such as sutures and mesh introduction.

## 5.2. Dissection of the hernia sac

Adhesions are taken down using a combination of blunt dissection using a blunt grasper and Endoshears. The Endoshears have a versatile use, and when connected to an energy source, they can function in place of a hook cautery (using either with closed tips or with one jaw), control bleeding, or aid in blunt dissection (**Figure 3**). In our practice, we measure the defect by inserting a sterile ruler into the abdominal cavity. After insufflation is released to 5 to 8 mmHg, the dimensions of the defect are recorded to allow for adequate estimation of the defect.

## 5.3. Mesh selection

A 4- to 5-cm circumferential overlap is desirable for ventral hernia repairs and accommodates for related shrinkage. Products available include polypropylene and polyester mesh. At our institution, we most commonly use the polypropylene mesh. The mesh is rolled extracorporeally and secured with a single stay suture. It is then introduced into the cavity using an accessory



**Figure 3.** Dissection of hernia sac with Endoshears.



12-mm port. The mesh repair can then proceed using one of the following methods: intraperitoneal onlay mesh (IPOM), transabdominal preperitoneal (TAPP), transversus abdominis release (TAR), and retromuscular repair.

#### **5.4. Intraperitoneal onlay mesh (IPOM)**

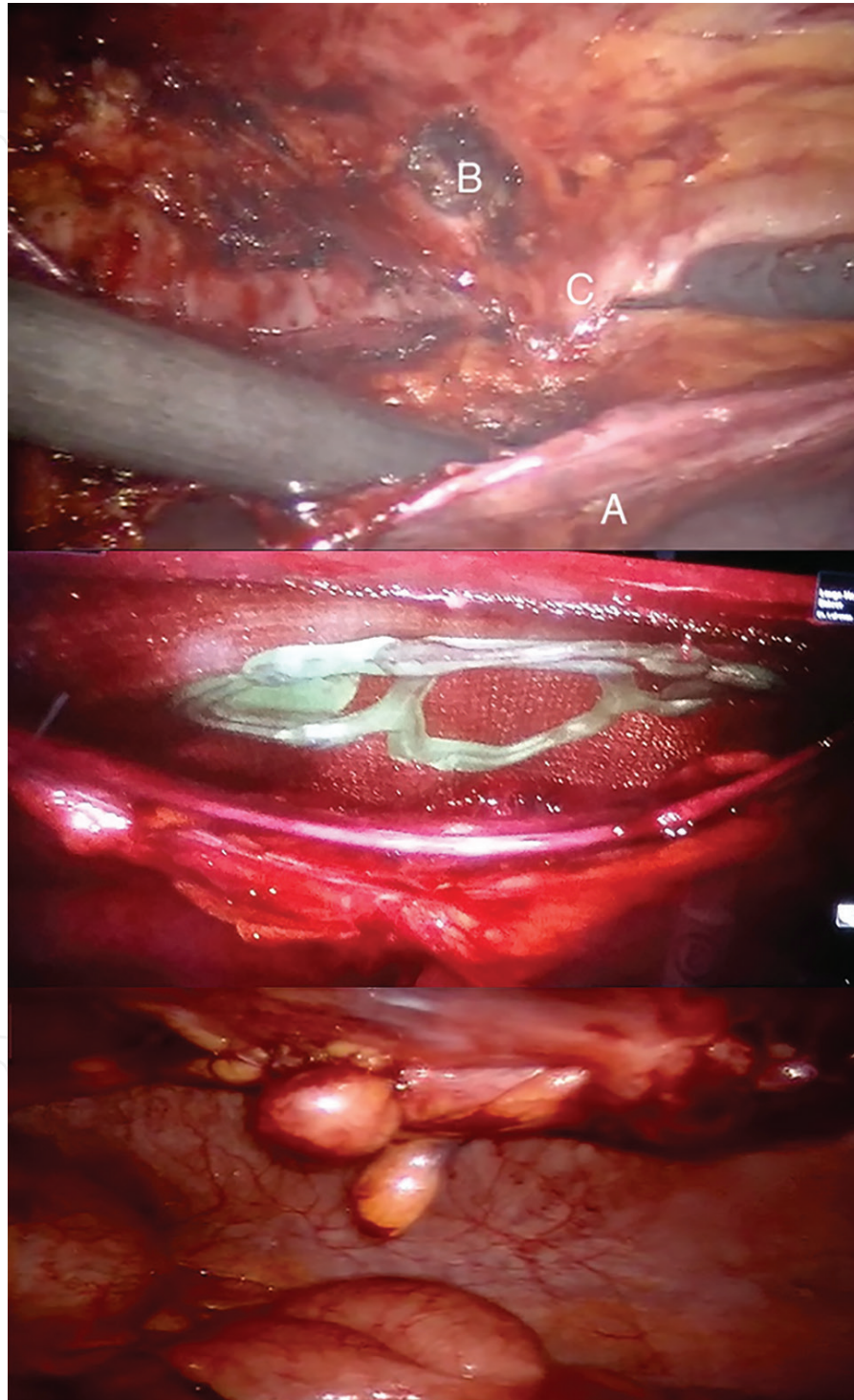
Repairs using intraperitoneal onlay mesh originated with inguinal hernia repair and soon found a role in ventral hernia repair [13–15]. The repair is completed by positioning the mesh over the defect with 4 to 5 cm overlap. The mesh can be secured using permanent or absorbable tackers. This can be done using the standard laparoscopic technique. An advantage of the robotic platform is that with the degrees of freedom, the mesh can also be sewn in. In this method, two to four tacks can be used to position the mesh if needed. The mesh is secured with a running absorbable suture around the border.

Early hypotheses associated transfascial sutures and tacks with increased pain; however, there has been no significant difference in retrospective reviews. Transfascial sutures and tacking have demonstrated similar pain profiles in available series that analyzed postoperative pain, opiate use, and telephone interview follow-up (mean follow-up 30 months). Transfascial sutures were, however, associated with increased infection rate [16–18]. To date, there are no comparisons of prospective randomized controlled studies on running suture versus transfascial sutures or tacking.

#### **5.5. Transabdominal preperitoneal (TAPP) repair**

Given the concern for adhesions to mesh, potential for mesh migration, and other complications associated with intraperitoneal onlay mesh, there has been an increasing interest in more physiologic repairs. Preperitoneal repair for ventral hernia was first described in 2002, after it had already gained popularity in the repair of inguinal hernias [19]. In this technique, a peritoneal flap is created, and after the mesh is secured with tacks, the peritoneum is reconstructed with intracorporeal sutures. When compared to laparoscopic IPOM, there were no major differences in outcomes [20–22]. Despite the benefits of laparoscopic preperitoneal repair, the literature reflects a select few limited case series and case reports using this technique [23]. This may reflect the technical difficulty of laparoscopy in creating and closing the peritoneal flap. The articulating instruments and degree of freedom offered by robotic surgery can compensate for the difficult maneuvers required to perform a TAPP ventral hernia repair. The experience with robotic TAPP is evolving and has been demonstrated as a safe and feasible procedure in small retrospective case series [24]. The procedure starts with adhesiolysis and careful delineation of the hernia sac. Upon reduction of hernia sac, peritoneal flap creation starts. We typically start the dissection on the ipsilateral side of the port midway on the falciform ligament. By gently pulling down on the falciform ligament, a small area of peritoneum is opened and the dissection is initially carried out in superior to inferior dissection. Once the peritoneum is opened, the peritoneal flap creation is carried out laterally to accommodate the mesh with a 4- to 5-cm overlap. If enough peritoneum is dissected off of the posterior sheath, the peritoneum can be flexible enough to cover the mesh on the

ipsilateral side to equally cover the mesh (**Figure 4A**). The flap can be created either through single docking with unilateral ports on one side or via double docking with ports on both sides of the abdomen. In our experience, TAPP repair for primary hernias such as epigastric



**Figure 4.** (Top) Creation of preperitoneal flap. (A) Lateral edge of peritoneal dissection. (B) Hernia defect and (C) lateral border of dissection. (Middle) Placement of mesh in preperitoneal space. (Bottom) Closure of peritoneum over the hernia defect.



and umbilical hernias can be accomplished using single docking; however, for the incisional hernias, it is preferable to employ double-docking technique by creating a flap starting in the midline. Upon completion of flap creation, the hernia defect can be primarily approximated using locking sutures. The mesh can then be placed in the preperitoneal space and secured to the posterior sheath with either sutures or absorbable tackers (**Figure 4B**). Upon completing mesh fixation, the peritoneal flap created can then be used to cover the mesh providing space for the mesh to integrate with posterior sheath and avoiding contact with intraperitoneal contents (**Figure 4C**) [30].

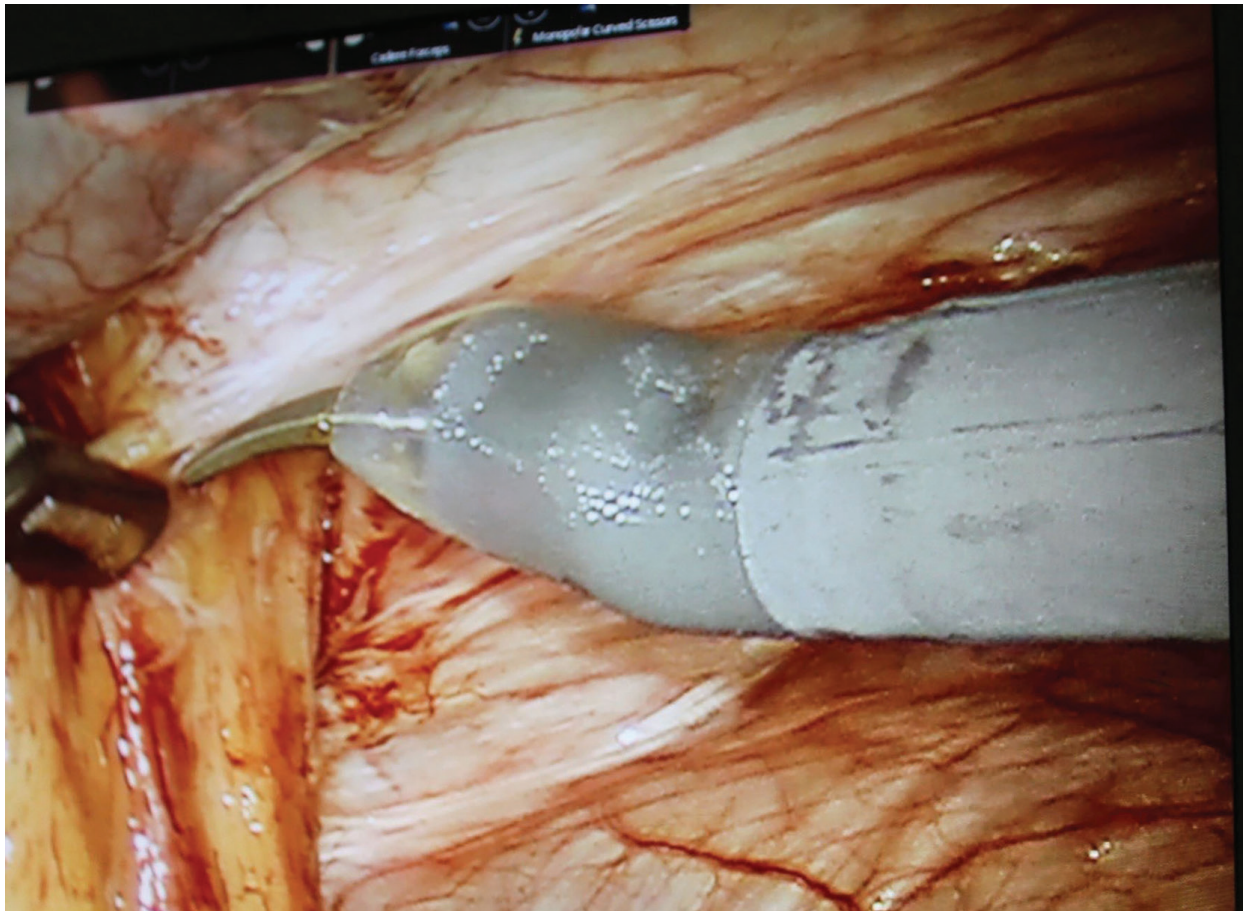
### 5.6. Transversus abdominis release (TAR)

Although tension-free repairs using mesh have been successful, the patient's posterior rectus provides a natural and less costly abdominal wall barrier. In this technique, after reduction of the hernia, the peritoneum and posterior rectus sheath are dissected from the rectus muscle. The dissection is then extended laterally and the transversus abdominis muscle aponeurosis is incised, producing component separation which allows for primary repair of the hernia defect. The primary repair can be completed using locking sutures, such as the STRATAFIX, which has been approved by the FDA for fascial closure [25].

### 5.7. Robotic retromuscular ventral hernia repair (RRVHR)

Component separation, a therapy for extensive abdominal wall defects, can also be achieved using minimally invasive techniques. Open component separation is still limited by recurrence and associated wound complications. Carbonell et al. reported release of the posterior rectus sheath in the retromuscular space and referred to it as posterior component separation technique (PCST) [26]. Posterior component separation was also adapted to minimally invasive techniques using the robot. When compared to laparoscopic ventral hernia repair in an analysis of Americas Hernia Society Quality Collaborative database, RRVHR was not significantly different in terms of direct hospital costs, narcotic requirements but was associated with increased incidence of seroma [27].

After the hernia is identified and reduced, edges of the hernia sac are delineated and edges are opened with electrocautery. Once the edges are opened, posterior sheath is separated from the rectus and the anterior sheath, and the dissection is carried out laterally until neurovascular bundles are found. Care must be taken to avoid disrupting the linea alba as the dissection is carried out. This should classically be done with ports on the bilateral flank. The initial dissection can start on one side, and once posterior sheath is separated on one edge of the hernia sac, additional ports are placed on the contralateral side. The above step is repeated to separate the posterior sheath from the rectus (**Figure 5**). Upon completely entering the retromuscular space, the hernia defect can be approximated using locking sutures and mesh reinforcement can be performed below the primary repair of the defect. The posterior sheath, which was separated, is then closed below the mesh using sutures to fully place the mesh in the retromuscular space. The peritoneum and posterior rectus fascia are both separated from

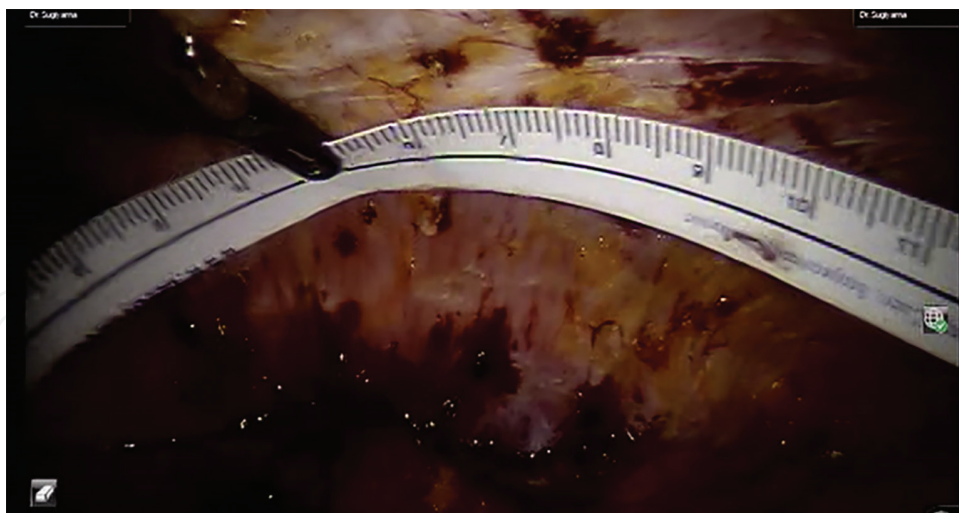


**Figure 5.** Dissection of the peritoneum and posterior rectus sheath to create a retromuscular space.

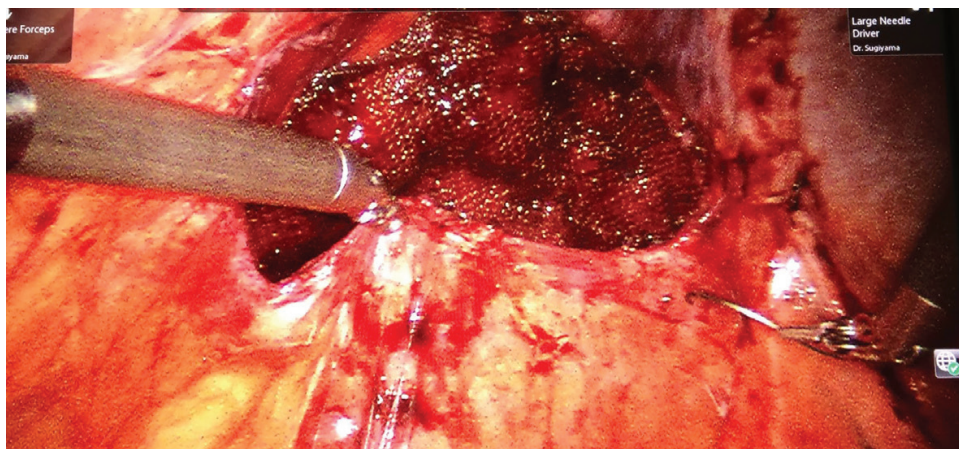
the posterior rectus muscle. A 4 to 5 cm perimeter is dissected. After repair of the primary defect, the polypropylene mesh is then placed inside the cavity and secured using a circumferential locking suture. The peritoneum and posterior fascia are then reapproximated using running locking suture.

## 6. Tips

- When securing the mesh during IPOM, avoid large gaps, which can allow bowel to become caught in the mesh
- To obtain an accurate measurement, we can use a sterile ruler with reduction in pneumoperitoneum (**Figure 6**)
- If complete closure of the peritoneum cannot be achieved, we can suture borders of peritoneum to preperitoneal mesh (**Figure 7**).



**Figure 6.** Intracorporeal measurement of the defect.



**Figure 7.** Partial peritoneal coverage of preperitoneal mesh.

## 7. Considerations

### 7.1. Cost

The cost benefit to laparoscopic ventral hernia repairs mirrors the clinical benefits of this approach. With decreased operative times and complications, accounting for readmissions and recurrences, laparoscopic ventral hernia repair was shown to be cost effective, including 1-year follow-up in analysis of both a statewide database and the National Inpatient Sample [28]. A concern of the use of robotic surgery is the cost of the technology. Consensus on the impact of cost has been a topic of controversy. As previously noted, laparoscopic and robotic retromuscular repairs do not significantly differ in terms of direct hospital costs in an analysis of a large multicenter database [27]. Differences in costs are multifactorial, and



costs can be distributed in centers where multiple services are utilizing the robot. Kudsi et al., after finding improvement in operative times, suggested that this may also be an area of cost savings [29].

## 7.2. Obesity

Minimally invasive surgery in obese patients can be challenging. Body habitus and extensive subcutaneous tissue can hinder efforts to achieve pneumoperitoneum and maneuver laparoscopic instruments. Moreover, this population is at higher risk of developing recurrent incisional hernias and higher risks of complications following repair. Patients with a body mass index (BMI)  $\geq 30$  kg/m<sup>2</sup> have demonstrated poorer outcomes following ventral hernia repair, have higher rates of recurrence, more complications, and longer hospital stays [30]. The benefits of performing minimally invasive surgery in obese patients can compensate for the associated difficulties. Minimally invasive ventral hernia repair is associated with lower complication and recurrence rates. In a retrospective review of 163 obese patients (BMI  $\geq 30$  kg/m<sup>2</sup>), Novitsky et al. found significantly lower rates of both complications and recurrences with laparoscopic PTFE mesh repair compared to open repair. The improved outcomes were associated with safe entry into abdomen via left upper quadrant, meticulous adhesiolysis, adequate mesh overlap (4 to 5 cm) and use of 4 to 6 equally spaced nonabsorbable sutures to secure the mesh [31]. Several other studies have reached similar conclusions, including more recent retrospective review in 2016 by Froylich et al., who found similar outcomes when comparing open to minimally invasive ventral hernia repair [32].

Robotic hernia repair provides several advantages to laparoscopy, but the literature is sparse for its use specifically in the obese patient population. In a small retrospective review comparing robotic-assisted to laparoscopic repair, where the mean BMI was 31.5 kg/m<sup>2</sup>, the outcome showed a comparable success rate for robotic repair [33].

## 7.3. Pediatric patients

In our practice, we do not include pediatric patients; however, minimally invasive ventral hernia repair has been practiced in this population. The first series of minimally invasive ventral hernia repair in children was reported in 2006 using 3-mm ports and standard laparoscopic equipment with a mean age of 2 years in those with epigastric hernias and 4.2 years in patients with umbilical hernias, demonstrating that the procedure was safe and feasible [34]. Robotic ventral hernia repair is yet to be reported in this population; however, the scope of robotic surgery has expanded to include repair of congenital diaphragmatic hernias, cholecystectomy, and inguinal hernias.

## 8. Role of robotics in surgical education

As robotic surgery becomes increasingly integrated into various practices, including cardiothoracic surgery, oncologic surgery as well as urology and gynecology, it is also becoming

important for trainees to become familiar with this technology. Simulation software included with the system allows trainees to develop skills. During live surgery, the ability to alternate between consoles provides a similar learning environment to standard open and laparoscopic surgery without affecting patient safety. A consensus on general surgery training and robotic training has not been described; however, in the field of urology, the importance of robotic training has been well recognized as a vital tool for trainees to grasp projecting that it will become basic skill in the future [35, 36]. In a recent survey addressing attitudes of general surgery attendings and residents, 73% of residents completed robotic simulator training, with 20% having experience as the primary console operator. One hundred percent of attending surgeons surveyed believed that robotic surgery training should be included in general surgery training programs [37].

## 9. Conclusions

The evolution of surgery for ventral hernias has followed developments in inguinal hernia repair. From trusses and external devices came open repair followed by minimally invasive techniques. The difficulties encountered with the limits of laparoscopic repair have been alleviated by the versatility offered by robotic surgery which includes enhanced dexterity, visualization, and ergonomics. Options for minimally invasive techniques include a wide variety of techniques reflecting the complexity of abdominal wall components and include intraperitoneal onlay mesh, transabdominal preperitoneal repair, transverse abdominis release, and retromuscular repairs. While the safety and efficacy of all of these modalities has been well validated, the type of repair should be patient centered.

While cost remains a concern in robotic ventral hernia repair, this is a topic of controversy. Assessing cost is a complex moving target and is sensitive to metrics such as operative times, utilization, and maintenance. Analysis of total robotic utilization across all specialties in an institution may be warranted to capture the true effect on healthcare costs.

As the use of robotic surgery has spread to include ventral hernia repair, it is likely that this can prove to be true for a broad range of procedures, making the techniques used in ventral hernia repair useful for building a basic skillset. For our current surgical trainees, this is especially true, and it is yet to be determined how this will shape general surgery curricula.

## Author details

Kaylene Barrera, Paul Chung, Sarrina Shraga and Gainosuke Sugiyama\*

\*Address all correspondence to: gainosuke.sugiyama@downstate.edu

Downstate Medical Center, State University of New York, Brooklyn, New York, United States of America



## References

- [1] Jacob BP, Ramshaw B. The SAGES Manual of Hernia Repair. Los Angeles, CA: Society of American Gastrointestinal Endoscopic Surgeons; 2013
- [2] Laparoscopic Ventral Hernia Repair Information from SAGES. n.d. Available from: <https://www.sages.org/publications/patient-information/patient-information-for-laparoscopic-ventral-hernia-repair-from-sages/>. January 22, 2017
- [3] Nunn JF. Ancient Egyptian Medicine. Norman: University of Oklahoma Press; 1996
- [4] Holzheimer RG. Surgical treatment: Evidence-based and problem-oriented. In: Holzheimer RG, Mannick JA, editors. Surgical Treatment: Evidence-Based and Problem-Oriented. W Zuckschwerdt Verlag: Munich; 2001
- [5] Bullitt JB. III. Retrenchment of lipomatous abdominal wall combined with operation for radical cure of umbilical hernia. *Annals of Surgery*. 1900;**32**(5):663-667
- [6] Keetley CB. The radical cure of hernia. *Annals of Surgery*. 1888;**8**(1):5-23
- [7] Mayo WJ. VI. An operation for the radical cure of umbilical hernia. *Annals of Surgery*. 1901;**34**(2):276-280
- [8] Winslow K VI. The aponeuroses the supporting structures of the abdominal wall; their approximation for the prevention and cure of hernia. *Annals of Surgery*. 1904;**39**(2): 245-255
- [9] Cassar K, Munro A. Surgical treatment of incisional hernia. *The British Journal of Surgery*. 2002;**89**(5):534-545
- [10] Usher FC. Hernia repair with knitted polypropylene mesh. *Surgery, Gynecology & Obstetrics*. 1963;**117**:239-240
- [11] LeBlanc KA, Booth WV. Laparoscopic repair of incisional abdominal hernias using expanded polytetrafluoroethylene: Preliminary findings. *Surgical Laparoscopy & Endoscopy*. 1993 Feb;**3**(1):39-41
- [12] Ballantyne GH, Hourmont K, Wasielewski A. Telerobotic laparoscopic repair of incisional ventral hernias using intraperitoneal prosthetic mesh. *Journal of the Society of Laparoendoscopic Surgeons*. 2003;**7**(1):7-14
- [13] Fitzgibbons RJ, Jr, Salerno GM, Filipi CJ, Hunter WJ, Watson P. A laparoscopic intraperitoneal onlay mesh technique for the repair of an indirect inguinal hernia. *Annals of Surgery*. 1994;**219**(2):144-156
- [14] Chan AC, Lee TW, Ng KW, Chung SC, Li AK. Early results of laparoscopic intraperitoneal onlay mesh repair for inguinal hernia. *The British Journal of Surgery*. 1994;**81**(12):1761-1762

- [15] Tsimoyiannis EC, Tassis A, Glantzounis G, Jabarin M, Siakas P, Tzourou H. Laparoscopic intraperitoneal onlay mesh repair of incisional hernia. *Surgical Laparoscopy & Endoscopy*. 1998;**8**(5):360-362
- [16] Nguyen SQ, Divino CM, Buch KE, Schnur J, Weber KJ, Katz LB, Reiner MA, Aldoroty RA, Herron DM. Postoperative pain after laparoscopic ventral hernia repair: A prospective comparison of sutures versus tacks. *Journal of the Society of Laparoendoscopic Surgeons*. 2008;**12**(2):113-116
- [17] Kitamura RK, Choi J, Lynn E, Divino CM. Suture versus tack fixation of mesh in laparoscopic umbilical hernia repair. *Journal of the Society of Laparoendoscopic Surgeons*. 2013;**17**(4):560-564
- [18] Brill JB, Turner PL. Long-term outcomes with transfascial sutures versus tacks in laparoscopic ventral hernia repair: A review. *The American Surgeon*. 2011;**77**(4):458-465
- [19] Sarli L, Pietra N, Choua O, Costi R, Cattaneo G. Laparoscopic hernia repair: A prospective comparison of TAPP and IPOM techniques. *Surgical Laparoscopy & Endoscopy*. 1997;**7**(6):472-476
- [20] Miserez M, Penninckx F. Endoscopic totally preperitoneal ventral hernia repair. *Surgical Endoscopy*. 2002;**16**(8):1207-1213
- [21] Prasad P, Tantia O, Patle NM, Khanna S, Sen B. Laparoscopic transabdominal preperitoneal repair of ventral hernia: A step towards physiological repair. *Indian Journal of Surgery*. 2011;**73**(6):403-408
- [22] Prasad P, Tantia O, Patle NM, Khanna S, Sen B. Laparoscopic ventral hernia repair: A comparative study of transabdominal preperitoneal versus intraperitoneal onlay mesh repair. *Journal of Laparoendoscopic and Advanced Surgical Techniques A*. 2011;**21**(6):477-483
- [23] Luque JA, Luque AB, Menchero JG, Grau JM, Moreno JG, Gomez AT, Jurado JG. Safety and effectiveness of self-adhesive mesh in laparoscopic ventral hernia repair using transabdominal preperitoneal route. *Surgical Endoscopy*. 2017;**31**(3):1213-1218
- [24] Sugiyama G, Chivukula S, Chung PJ, Alfonso A. Robot-assisted transabdominal preperitoneal ventral hernia repair. *Journal of the Society of Laparoendoscopic Surgeons*. 2015;**19**(4):e2015.00092
- [25] Krause D. Letter to Donna Marshall. Ethicon Incorporated a Johnson and Johnson Company Inc.; 2015. Available from: [https://www.accessdata.fda.gov/cdrh\\_docs/pdf15/K151200.pdf](https://www.accessdata.fda.gov/cdrh_docs/pdf15/K151200.pdf)
- [26] Carbonell AM, Cobb WS, Chen SM. Posterior components separation during retromuscular hernia repair. *Hernia: The Journal of Hernias and Abdominal Wall Surgery*. 2008;**12**(4):359-362
- [27] Warren JA, Cobb WS, Ewing JA, Carbonell AM. Standard laparoscopic versus robotic retromuscular ventral hernia repair. *Surgical Endoscopy*. 2017;**31**(1):324-332

- [28] Funk LM, Perry KA, Narula VK, Mikami DJ, Melvin WS. Current national practice patterns for inpatient management of ventral abdominal wall hernia in the United States. *Surgical Endoscopy*. 2013;**27**(11):4104-4112
- [29] Kudsi OY, Paluvoi N, Bhurtel P, McCabe Z, El-Jabri R. Robotic repair of ventral hernias: Preliminary findings of a case series of 106 consecutive cases. *American Journal of Robotic Surgery*. 2015;**2**(1):22-26
- [30] Kaoutzanis C, Leichtle SW, Mouawad NJ, Welch KB, Lampman RM, Wahl WL, Cleary RK. Risk factors for postoperative wound infections and prolonged hospitalization after ventral/incisional hernia repair. *Hernia: The Journal of Hernias and Abdominal Wall Surgery*. 2015;**19**(1):113-123
- [31] Novitsky YW, Cobb WS, Kercher KW, Matthews BD, Sing RF, Heniford BT. Laparoscopic ventral hernia repair in obese patients: A new standard of care. *Archives of Surgery* 2006;**141**(1):57-61
- [32] Froylich D, Segal M, Weinstein A, Hatib K, Shiloni E, Hazzan D. Laparoscopic versus open ventral hernia repair in obese patients: A long-term follow-up. *Surgical Endoscopy*. 2016;**30**(2):670-675
- [33] Allison N, Tieu K, Snyder B, Pigazzi A, Wilson E. Technical feasibility of robot-assisted ventral hernia repair. *World Journal of Surgery*. 2012;**36**(2):447-452
- [34] Albanese CT, Rengal S, Bermudez D. A novel laparoscopic technique for the repair of pediatric umbilical and epigastric hernias. *Journal of Pediatric Surgery*. 2006;**41**(4):859-862
- [35] Grover S, Tan GY, Srivastava A, Leung RA, Tewari AK. Residency training program paradigms for teaching robotic surgical skills to urology residents. *Current Urology Reports*. 2010;**11**(2):87-92
- [36] Patel HR, Linares A, Joseph JV. Robotic and laparoscopic surgery: Cost and training. *Annals of Surgical Oncology*. 2009;**18**(3):242-246
- [37] Nolan HR, Christie DB III, Ashley DW. Comparison of attending and resident surgeons' opinions of robotic surgery training in general surgery residency. *The American Surgeon*. 2015;**81**(8):303-305

