

We are IntechOpen, the world's leading publisher of Open Access books Built by scientists, for scientists

6,900

Open access books available

185,000

International authors and editors

200M

Downloads

Our authors are among the

154

Countries delivered to

TOP 1%

most cited scientists

12.2%

Contributors from top 500 universities



WEB OF SCIENCE™

Selection of our books indexed in the Book Citation Index
in Web of Science™ Core Collection (BKCI)

Interested in publishing with us?
Contact book.department@intechopen.com

Numbers displayed above are based on latest data collected.
For more information visit www.intechopen.com



Bilateral Axillo-Breast Approach Robotic Thyroidectomy: Introduction and Update

Do Hoon Koo, Dong Sik Bae and June Young Choi

Additional information is available at the end of the chapter

<http://dx.doi.org/10.5772/intechopen.68951>

Abstract

Bilateral axillo-breast approach (BABA) endoscopic thyroidectomy was introduced at Seoul National University Hospital in 2004, and it has been used to treat a variety of benign and malignant thyroid diseases. In 2008, we began using the da Vinci robotic system with BABA endoscopic thyroidectomy and reported our initial experiences in 2009. Since then, the outcomes of many clinical studies have been reported. In this chapter, we will introduce the BABA robotic thyroidectomy (RoT) procedure and review evidence for the safety of performing BABA. First, we will introduce the history of BABA RoT, which is based on an endoscopic BABA method. Second, we will review the BABA RoT equipment, operating room (OR) set-up, and the procedures, including surgical indications. Third, technical, oncological, and functional evidence for the safety of performing BABA will be described. Fourth, we will highlight the esthetic superiority of BABA RoT compared with conventional thyroidectomy. Finally, the BABA robotic modified radical neck dissection procedure will be introduced, with mention of our experiences and special concerns. We conclude that BABA RoT is technically, oncologically, and functionally safe. In addition, its esthetic superiority should be emphasized. Further research on the prognosis of patients treated by BABA RoT should follow in the future.

Keywords: bilateral axillo-breast approach, robot, thyroidectomy

1. History and introduction to bilateral axillo-breast approach robotic thyroidectomy (BABA RoT)

1.1. Beyond the endoscopic limits

Thyroid carcinoma is the most common endocrine malignancy. Although the treatment of choice for patients with thyroid carcinoma is conventional open thyroidectomy (OT), it inevitably

leaves scarring in the neck because of the anatomical location of the thyroid. Thyroid carcinoma is especially prevalent in young women. The prognosis of thyroid carcinoma is favorable, which increases concerns related to quality of life in terms of postoperative neck scars. To avoid cosmetically unfavorable outcomes, a variety of remote approaches have been used in patients at low risk of recurrence. The two most common techniques are the transaxillary approach (TAA) and bilateral axillo-breast approach (BABA). BABA consists of two axillary incisions 0.8 cm in size and two circumareolar incisions, one left (0.8 cm) and one right (1.2 cm).

BABA endoscopic thyroidectomy is a modification of Axillo Bilateral Breast Approach (ABBA) developed by Shimazu et al. [1]. It was introduced at Seoul National University Hospital (SNUH) in 2004 and has since been used to treat a variety of benign and malignant thyroid diseases. Compared with OT, BABA Endoscopic Thyroidectomy (ET) yields comparable postoperative complication rates and thyroglobulin levels but with excellent cosmetic results [2, 3]. Based on these results, in 2008, we combined our unique BABA thyroidectomy technique with the fundamental advantages of the da Vinci robotic system. These advantages include a good operative view using high-definition three-dimensional imaging, an EndoWrist function that enables a high degree of freedom of motion, a tremor-filtering system, and a short learning curve. This enables precise surgical maneuvers to be performed in difficult and narrow workspaces, even though robotic thyroidectomy (RoT) is associated with some disadvantages including high cost, longer operation time, and lack of tactile sensation. In 2009, we reported our initial experiences with BABA RoT at SNUH, which was the first report of its use [4]. Since then, there have been many clinical studies assessing the surgical outcomes and safety of BABA RoT. In this chapter, we aim to introduce the detailed procedure of BABA RoT and review evidence from published studies regarding the technical, oncological, and functional safety and cosmetic outcomes of BABA RoT.

2. Patient selection: indications and contraindications

The indications for BABA RoT are as follows: (1) a well-differentiated thyroid carcinoma such as papillary or follicular thyroid carcinoma <4 cm in diameter, regardless of preoperative lymph node (LN) involvement, (2) minimal invasion of the anterior thyroid capsule and strap muscle, (3) Graves' disease (recommended for <100 ml in volume), (4) male patients who experienced difficulty with endoscope application, (5) a larger benign thyroid nodule or follicular neoplasm (5–8 cm) not eligible for treatment by a conventional endoscopic approach, and (6) obese patients (body mass index [BMI] >30), who cannot undergo endoscopy [4–10]. Absolute contraindications to RoT include patients with distant metastasis, thyroid malignancies that are likely to recur (e.g., medullary thyroid carcinoma, undifferentiated, or poorly differentiated thyroid carcinoma) and are located posteromedially and thus may be very close to the recurrent laryngeal nerve (RLN) or may have invaded into the tracheal wall and concomitant obvious breast malignancy [11, 12]. Thyroid nodules >8 cm in diameter or those in substernal goiters are also relative contraindications to RoT. BABA thyroid surgery does not involve the breast parenchyma in subcutaneous dissection after circumareolar incision. Consequently, previous breast-conserving surgery due to breast cancer or breast augmentation is not a

contraindication to BABA RoT. In addition, Kim et al. recently reported that BABA RoT and lateral LN dissection were performed simultaneously in a thyroid carcinoma patient with preoperative cervical LN metastasis [13]. Therefore, BABA RoT is selectively applicable in patients with suspected lateral LN metastasis.

3. Basic equipment and operating room (OR) setup

3.1. Operating theater

A robotic system requires more space than does either open or endoscopic surgery. Therefore, most hospitals have a dedicated robot operating room. The room is maintained such that surgery can be performed under aseptic conditions.

3.2. da Vinci Si HD surgical system (Intuitive, Sunnyvale, CA, USA)

3.3. Instruments

1. Endoscope: $\Phi 10$ mm, 30° endoscope
2. Thyroid pillow (Emtas, Seoul, Korea) (**Figure 1**)



Figure 1. Thyroid pillow.

3. EndoWrist instruments (**Figure 2**)

- 1 Maryland bipolar forceps, $\Phi 8$ mm
- 1 Prograsp TM forceps, $\Phi 8$ mm
- 1 Cautery hook, $\Phi 8$ mm
- 1 Harmonic®, $\Phi 8$ mm

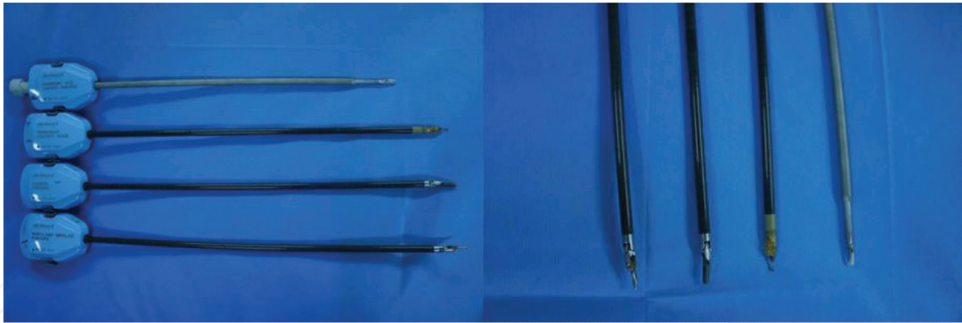


Figure 2. Endowrist instruments.

- 4. Harmonic® (Ethicon Endo-surgery, Cincinnati, OH, USA)
- 5. Vascular tunneler (Gore-Tex) (**Figure 3**)

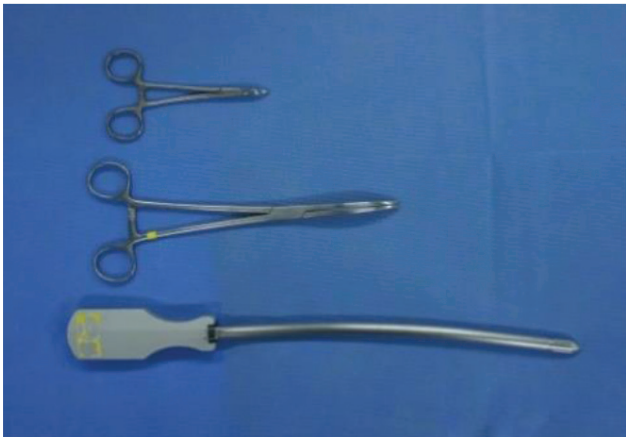

Figure 3. Vascular tunneler.

- 6. Trocars (**Figure 4**)

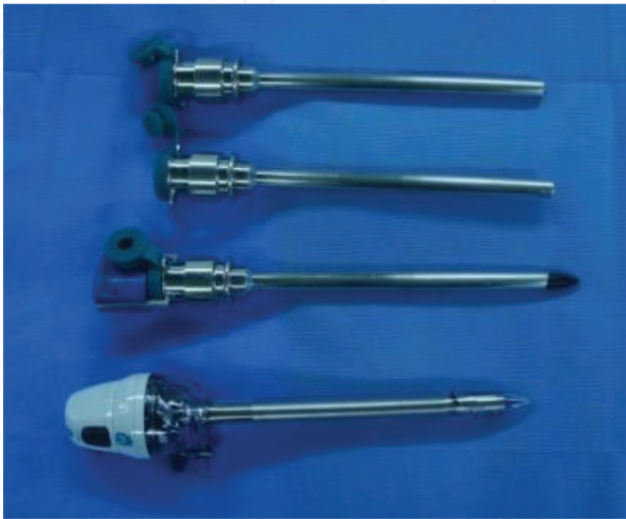

Figure 4. Trocars.

7. Endobag, 10 mm (**Figure 5**)




Figure 5. Endobag.

8. Suction-irrigator (**Figure 6**)

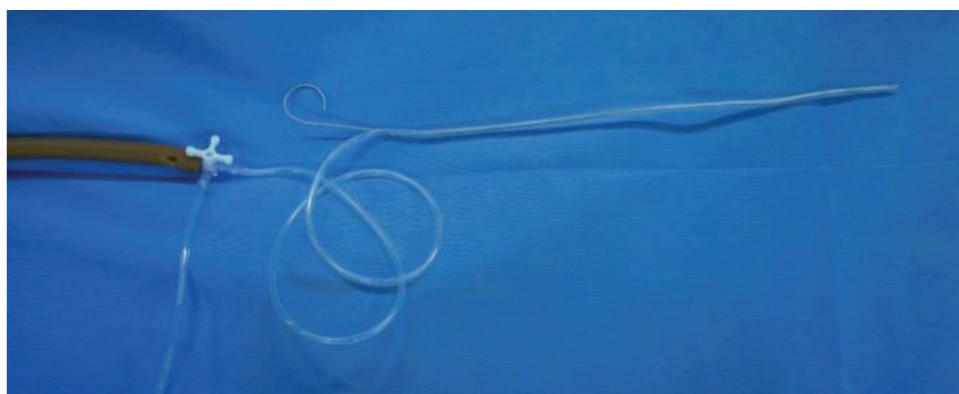


Figure 6. Suction-irrigator.

9. Other instruments (**Figure 7**)

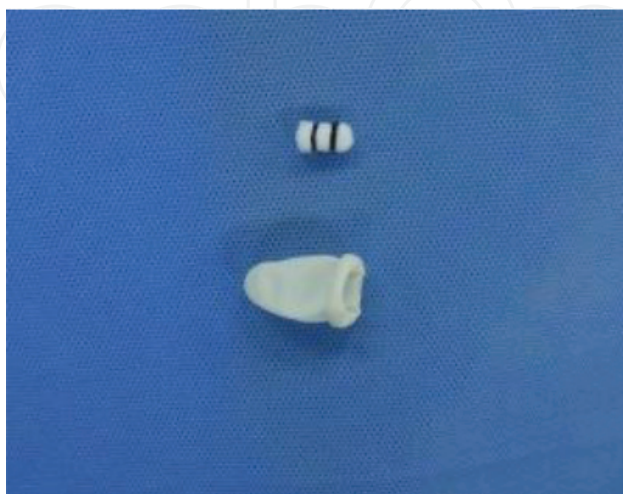

Figure 7. Peanut and thimble.

10. OR Setup (Figure 8)

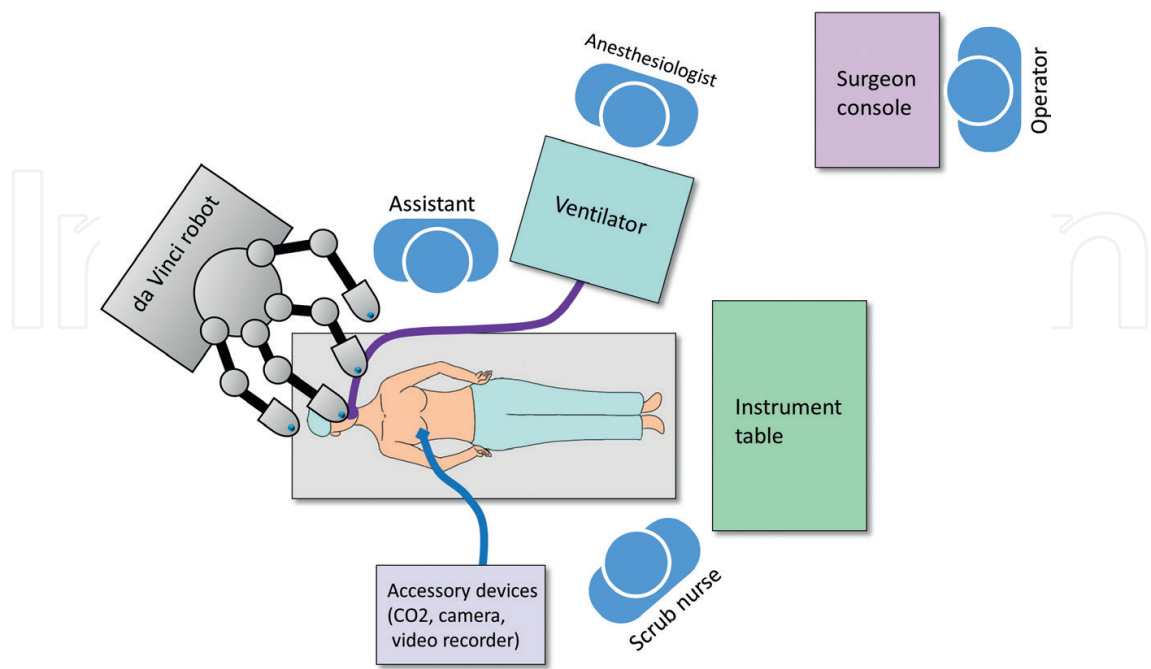


Figure 8. Schematic depiction and the view from above for the operating room setting on robotic thyroidectomy.

4. Procedure and techniques

4.1. Thyroidectomy

4.1.1. Preparation

4.1.1.1. Positioning and draping

Under general anesthesia, the patient is placed in the supine position with a Q-pillow under the shoulder extending the head and neck and the arm resting alongside the body (**Figure 9**).

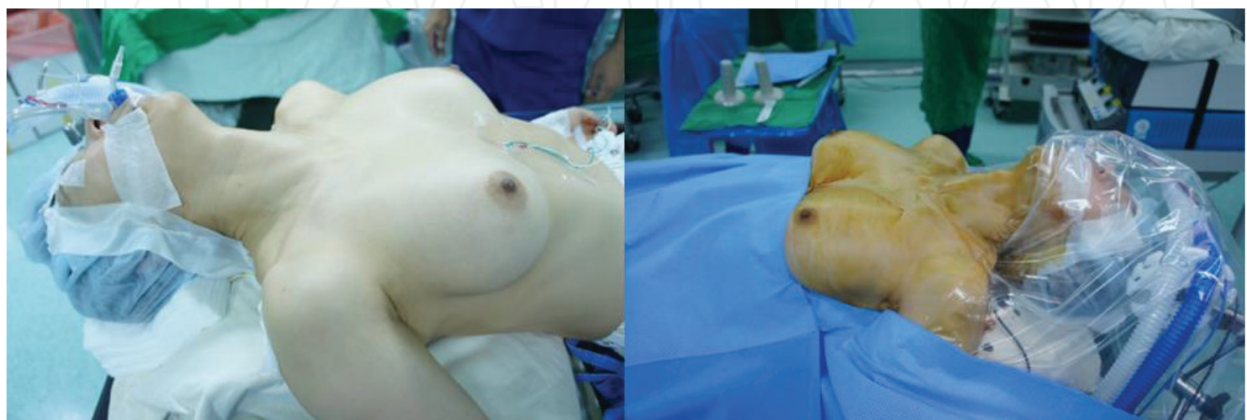


Figure 9. Position and drape.

Care should be taken not to overstretch the patient's neck. Alternatively, Kang et al. suggested a "verticalizing maneuver (VM)" that lifts up the circumareolar sites as high as possible by surrounding the lower part of the lower breast with elastic bands [6]. This method positions the trocar axis more perpendicular, which reduces the blind spot in the lower neck during central compartment node dissection. The surgical field is prepared according to routine surgical maneuvers, and sterile drainage is performed using a universal drape package to expose the anterior neck, bilateral axilla, and lower contour of the breasts. The visual field of the patient's face and endotracheal tube can be maintained by covering the patient's head and face with a transparent plastic sheet (**Table 1**).

1. Preparation

- (1) Positioning and draping
- (2) Drawing guidelines
- (3) Epinephrine-mixed saline injection

2. Flap making

- (1) Skin incision and blunt dissection
- (2) Port insertion and sharp dissection using an energy device
- (3) Robot docking and complete elevation of the flap

3. Thyroidectomy on the lesion side

- (1) Midline division
- (2) Isthmectomy and/or removal of the pyramidal lobe and midline LN
- (3) Lateral and anteromedial dissection of the thyroid gland
- (4) Dissection of the thyroid lower pole
- (5) Preservation of the recurrent laryngeal nerve and parathyroid glands
- (6) Dissection of the thyroid upper pole

4. Specimen removal

5. Central compartment dissection and contralateral thyroidectomy (if indicated)

6. Closure

Table 1. Surgical steps of bilateral axillo-breast approach robotic thyroidectomy.

4.1.1.2. Drawing guidelines

Guidelines are drawn along the following anatomical markings of the chest and neck: thyroid cartilage notch, cricoid cartilage (+), suprasternal notch (U), midline connecting them above, anterior border of the sternocleidomastoid muscle (SCM), superior border of the clavicle and 2 cm below the border, incisions (two circumareolar incisions at the superomedial margins and two axillary incisions using conventional skin wrinkles), and four trajectory lines from each of four skin incision sites to the cricoid cartilage and workspace (**Figure 10**). The dissecting area is bordered by the thyroid cartilage superiorly, 2 cm below the superior border of the clavicle inferiorly and just beyond the medial border of the SCM muscles laterally.

4.1.1.3. Epinephrine-mixed saline injection

Diluted (1:200,000) epinephrine solution is injected into the workspace below the platysma of the neck and subcutaneously into the anterior chest. A 23-G spinal needle is then used to check the intravenous puncture by pulling the syringe back slightly before injecting the solution (**Figure 11a**). At this time, it is possible to inject the solution more securely while avoiding puncturing the blood vessel by bending the needle slightly at an angle. A “pinch and raise”

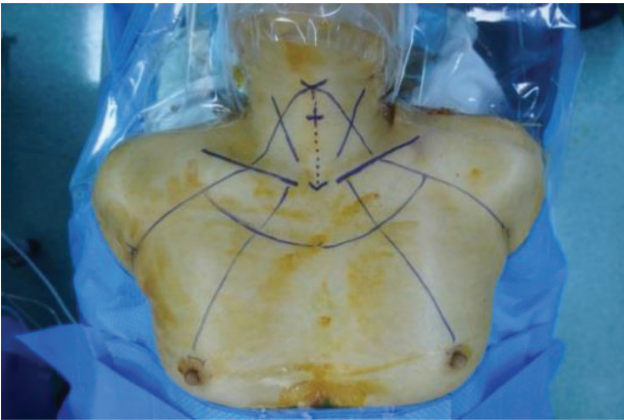


Figure 10. Drawing guideline.

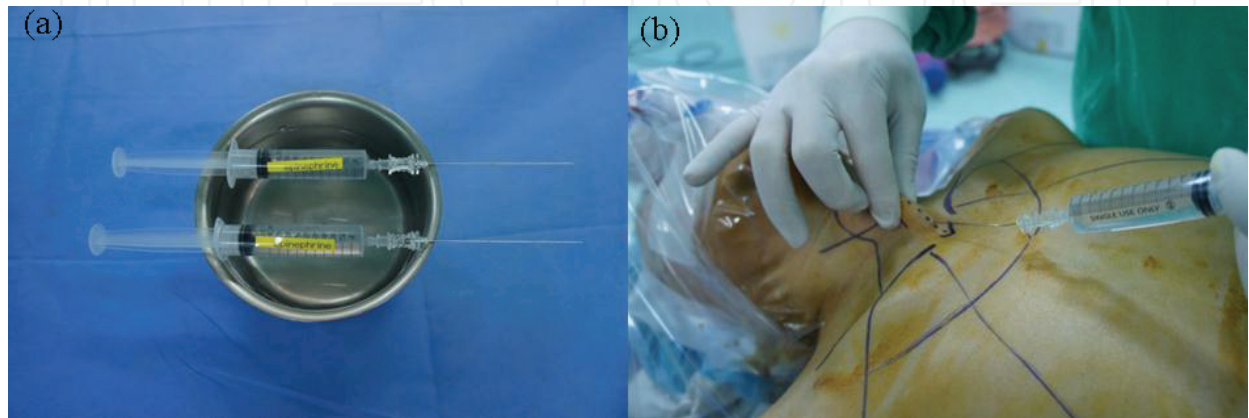


Figure 11. Epinephrine-mixed saline injection (a) 23 G spine needle (b) “pinch and raise” technique.

maneuver of the skin from the neck area facilitates injection of saline into the subplatysmal area (**Figure 11b**). This “hydrodissection” technique is used to create a saline pocket in the subplatysmal layer to reduce bleeding in the flap area and facilitate subsequent dissection. Additionally, Kang et al. previously reported that infiltration of the flap sites with a ropivacaine-saline solution (100 cc normal saline mixed with 3 mg/kg 0.1% ropivacaine) is a safe and effective method for reducing postoperative pain and postoperative analgesic need [14].

4.1.2. Flap making

4.1.2.1. Skin incision and blunt dissection

A circumareolar incision is made along the superomedial margin of each areola (**Figure 12**). First, a 12-mm incision is made on the right side to be used as a camera port, and the subcutaneous tissue is dissected using an electric cauterizer. Next, a straight mosquito hemostat, a long Kelly clamp, and a vascular tunneler are used to generate a subcutaneous narrow tunnel along the trajectory line for trocar insertion. Blunt dissection of the flap formed by hydrodissection begins at zone 2 and extends to zone 1 using a vascular tunneler. At this time, excessive force must not be used when performing blunt dissection near the sternal notch. Next, an 8-mm incision is made on the superomedial margin of the left areola, and blunt dissection of zones 1 and 2 is completed by repeating the same procedure described above.

4.1.2.2. Port insertion and sharp dissection using an energy device

After blunt dissection of the flap from the incision sites to the cricoid cartilage using the tunneler, the ports are inserted through the incision (**Figure 13**). The flap is located higher than the breast parenchyma so that it does not injure the patient’s breast. The 12-mm camera port is inserted through the right breast incision, and the 8-mm port is inserted through the left breast incision. At this time, the port insertion sites around the areola are encircled with Duoderm® to cover and protect the areolar after the port is inserted, prevent skin burns on the incision surface, and avoid air leakage. The workspace is maintained at low pressure (5–6 mmHg) by pumping CO₂ gas through the 12-mm camera port [15]. The ultrasonic shear (Harmonic, Ethicon EndoSurgery Inc., Cincinnati, OH, USA) is inserted through the 8-mm port on the left areolar incision to meet the camera through the 12-mm port and to secure the field of view and remove the remaining trabeculae of the subcutaneous tissue. After creating a workspace in the anterior chest (zone 1 and/or 2), avoiding the firm area near the sternal notch, two 8-mm incisions are made, and the trocar is inserted along the axillary trajectory line.

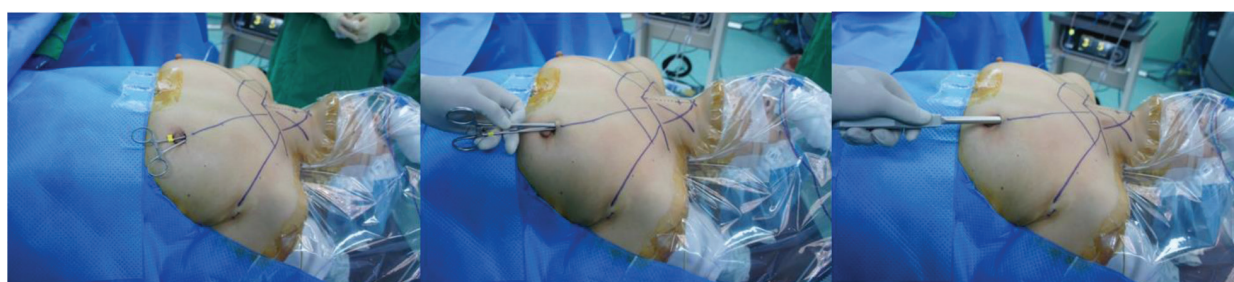

Figure 12. Skin incision and blunt dissection.

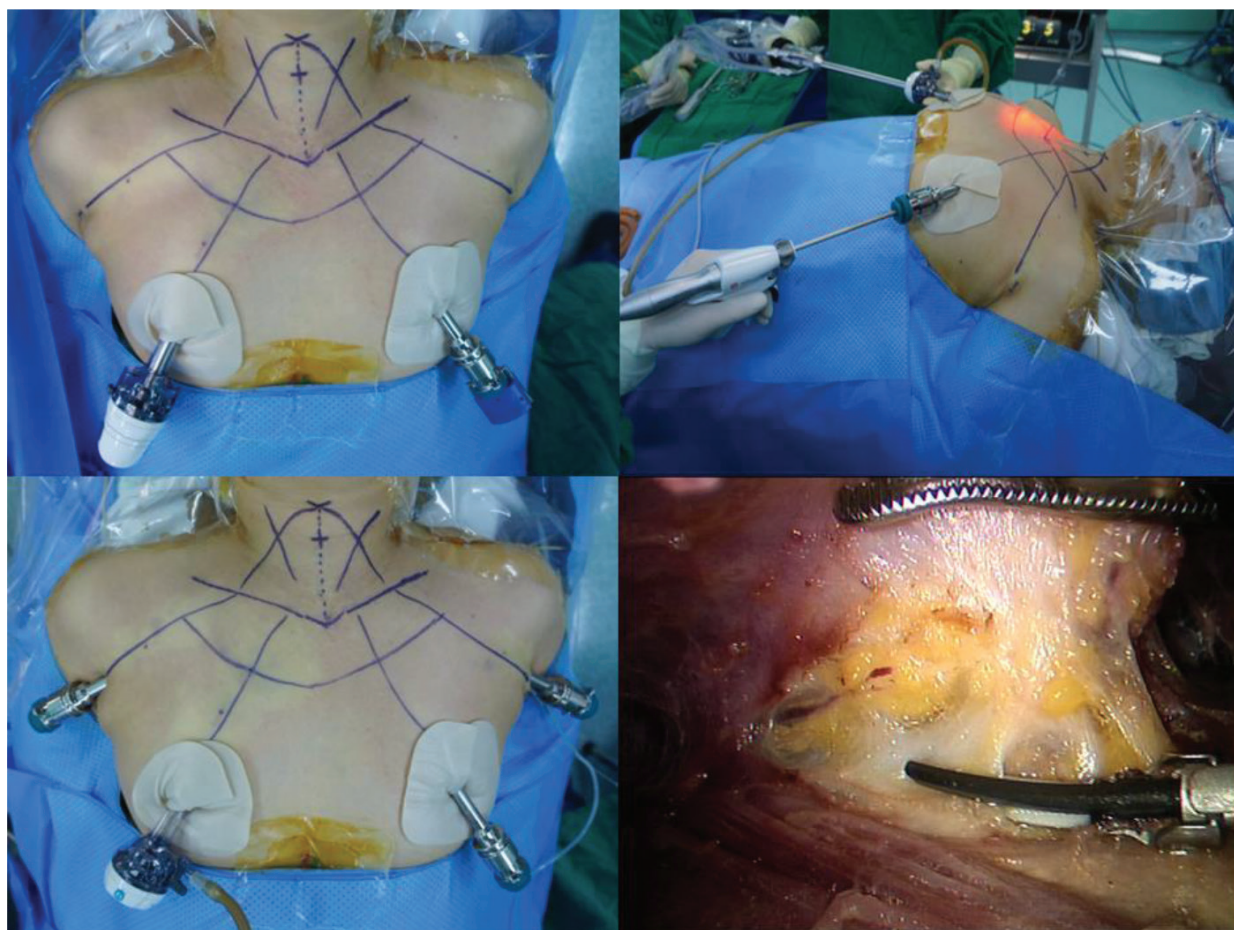


Figure 13. Four ports insertion and sharp dissection with energy device.

4.1.2.3. Robot docking and complete elevation of the flap

After inserting the four ports, the operation bed is switched to a reverse Trendelenburg position of $\sim 20\text{--}30^\circ$. The central columns of the robot carts and the camera arm are aligned with the camera port in a straight line, and the robot is docked to the port and connected via each of the four robot arms (**Figure 14**). The camera is inserted into the right areolar incision site port, and a monopolar electrocautery or ultrasonic shear is inserted into the left port. Graspers (ProGrasp forceps and Maryland forceps, Intuitive Surgical Inc., Sunnyvale, CA, USA) are inserted through both axillary ports, and further dissection is performed (**Figure 15**). This procedure completes the flap safely and effectively without bleeding. The border of the completed flap extends from the thyroid cartilage superiorly to 2 cm below the clavicle and to the point just beyond the medial margin of the SCM muscle. Recent reports suggested that subfascial layers likely cause less postoperative adhesion than do conventional subplatysmal layers in making flaps [16]. Anterior jugular vein ligation is necessary for dissections performed using the subfascial layer, which can be safely ligated near the sternal notch using an ultrasonic shear or a bipolar coagulator connected to Maryland forceps.

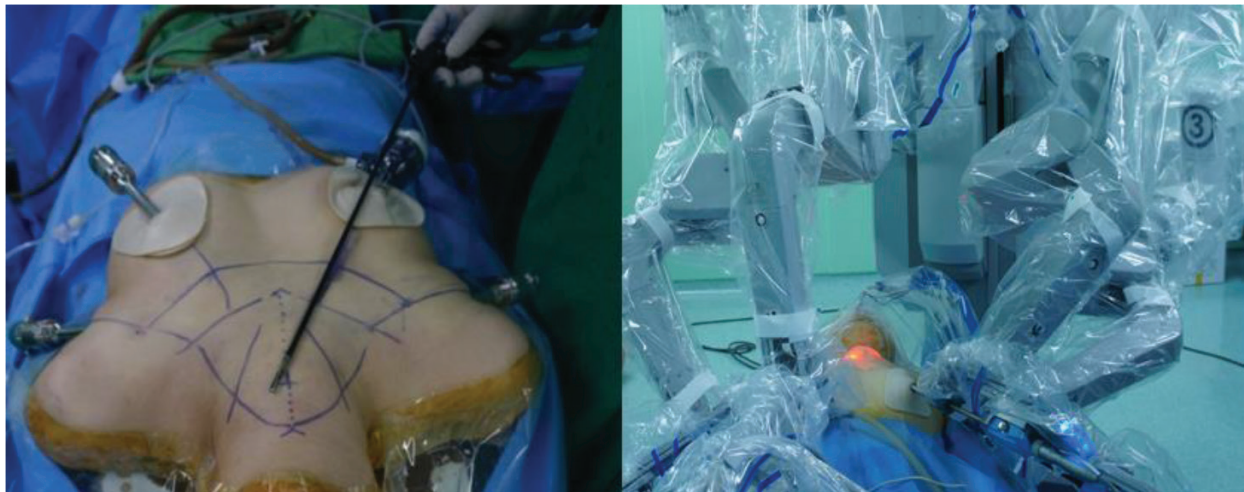


Figure 14. Robot docking.

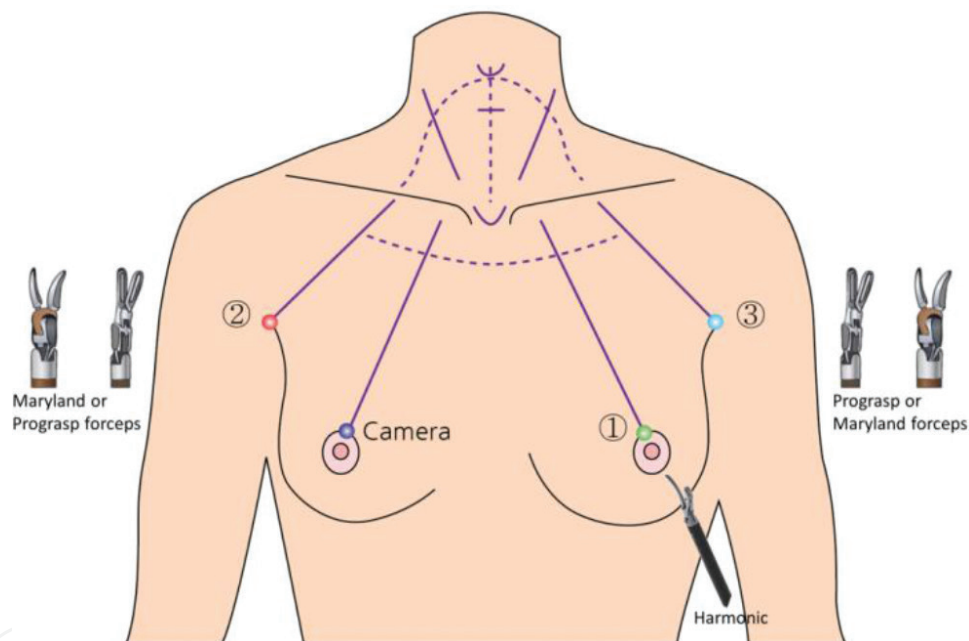


Figure 15. Placement of robotic instruments.

4.1.3. Thyroidectomy on the lesion side

4.1.3.1. Midline division

The first step of BABA RoT is resection, performing a midline division of the strap muscle in a similar fashion to conventional OT (**Figure 16**). The midline between the strap muscles is identified and separated by monopolar electrocautery. At this time, the cervical fascia is opened from the suprasternal notch to the thyroid cartilage to expose the entire length of the strap muscle. For identifying the midline, it is helpful for confirming the boundary that the first assistant palpates the prominence of the thyroid cartilage and the suprasternal notch from the outside.

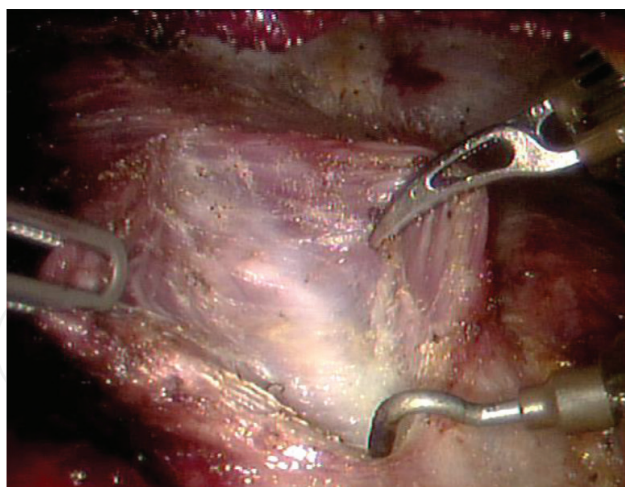


Figure 16. Midline division.

4.1.3.2. Isthmectomy and/or removal of the pyramidal lobe and midline (pretracheal and prelaryngeal) LNs

After verifying the trachea, isthmus, and cricothyroid membranes in the visual field, the isthmus is separated by ultrasonic shear or hook electrocautery (**Figure 17**). The trachea is easily identified by dissecting the soft tissue caudally from the thyroid isthmus, taking care not to injure the trachea. In addition, because there is a vessel in the upper border of the isthmus, care should be taken to avoid bleeding when dissecting. It is important to confirm the presence of isthmus lesions on preoperative images. If the tumor or nodule is located in the isthmus on the preoperative image, the lesion should be avoided, i.e., by using the paraisthmic line. Sometimes, the pyramidal lobes extend cranially to the level of the hyoid bone, and a thyroid duct cyst is detected incidentally. This structure should be removed for complete resection of the thyroid tissue; this procedure is possible with BABA RoT [17]. Furthermore, a delphian or prelaryngeal node between the cricothyroid muscles above the isthmus and a pretracheal

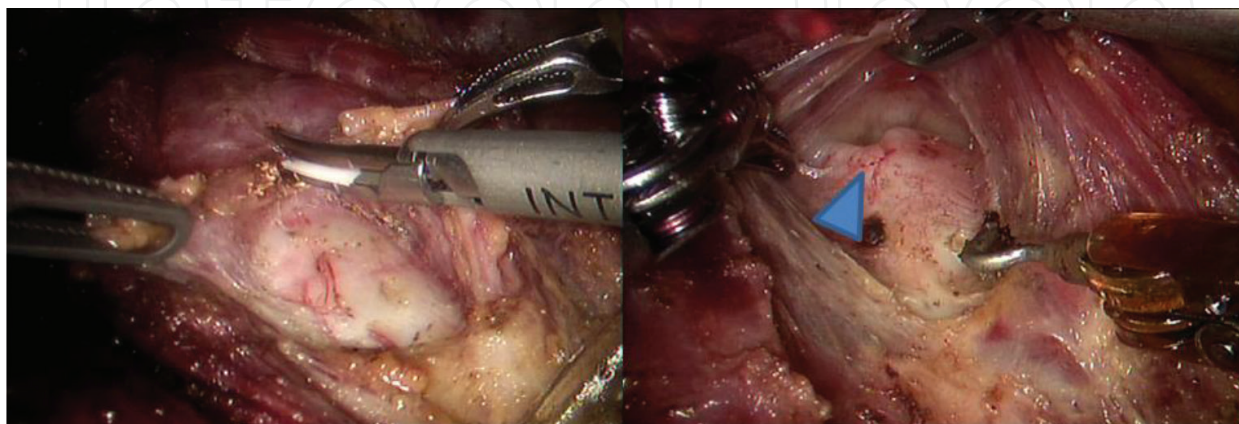


Figure 17. Isthmectomy, arrow; thyroid notch.

node below the isthmus shoulder may be found during soft tissue dissection. If LN metastasis is suspected, it is possible to excise the LN and confirm metastasis intracorporeally using frozen biopsy [18]. This area always contains small blood vessels, but monopolar electrocautery allows hemostasis. Extra attention is needed to avoid injuring the cricothyroid muscles during dissection.

4.1.3.3. Lateral and anteromedial dissection of the thyroid gland

After isthmectomy and/or midline LN resection, the thyroid gland on the lesion side is retracted medially using ProGrasp forceps, and the strap muscle is retracted laterally using Maryland forceps to separate the strap muscle from the capsule of the thyroid gland (**Figure 18**). This dissection extends to the deep aspect of the gland to expose the lateral side of the thyroid gland. Upon lateral dissection, the middle thyroid vein is visible and is ligated using ultrasonic shears or Maryland forceps. Ultrasonic shears are useful to reduce unnecessary bleeding from the muscles and thyroid capsule during this process. The so-called “switching action,” which moves the thyroid gland in the medial direction in phase with two robotic arms, facilitates medial retraction of the thyroid gland. In addition, the thyroidectomy procedure may be facilitated by dissection of the medial side (peritracheal and cricoid cartilage) as well as the lateral side. Further dissection is then performed from the lower pole to the medial side of the trachea in accordance with the principle of capsular dissection.

4.1.3.4. Dissection of the thyroid lower pole

After completing the lateral and medial dissections of the thyroid gland, the next step is dissection of the inferior portion of the thyroid gland (**Figure 19**). The lower pole of the thyroid gland is dissected bluntly using ultrasound scissors or Maryland forceps, because the inferior thyroid artery passes directly below or crosses over the recurrent laryngeal nerve before entering the thyroid gland. Therefore, the inferior thyroid artery can be used as an anatomical guide for exposing the recurrent laryngeal nerve.

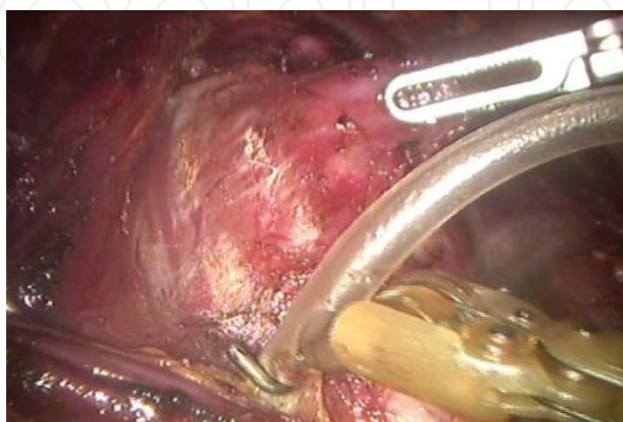


Figure 18. Lateral dissection of the thyroid gland.

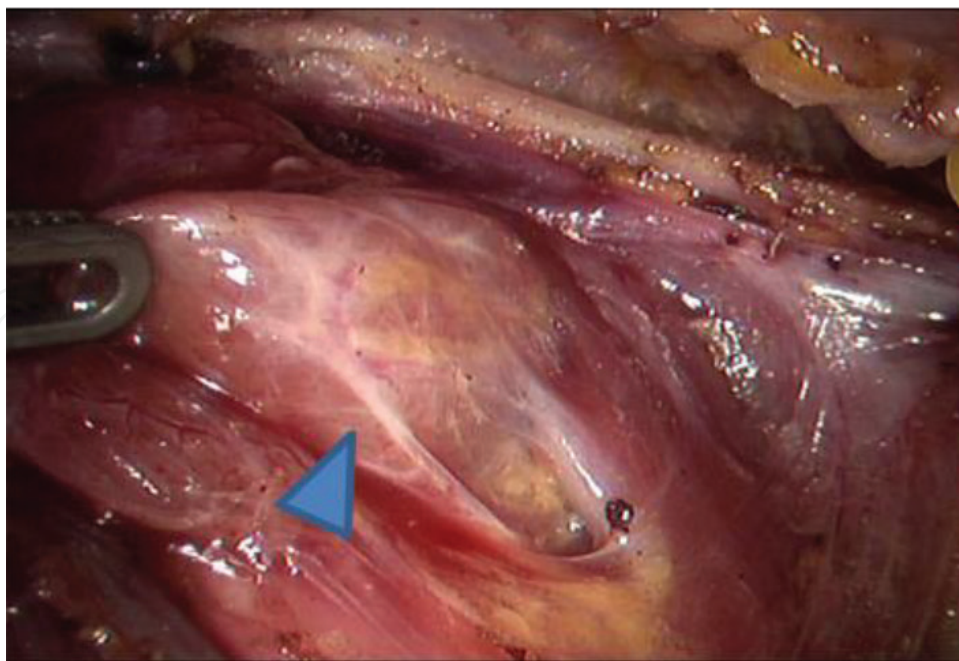


Figure 19. Dissection of the thyroid lower pole, arrow; inferior thyroid vein.

4.1.3.5. Preservation of the RLN and parathyroid gland (PTG)

During dissection of the thyroid gland from the perithyroidal tissue, it is important to preserve the RLN and PTG (**Figure 20**). The RLN and PTG should be identified while carefully dissecting the inferolateral side of the thyroid gland. Once the RLN is found, a plane delineated just superficial to the nerve and the ligament of Berry is separated using ultrasonic shears. Dissection progresses in the cephalad direction to the point where the nerve enters the larynx. Near the ligament of Berry, careful dissection is needed to avoid traction or thermal injury to the RLN. It was reported that intraoperative neuromonitoring can help identify and preserve the RLN [19, 20]. In addition, Yu et al. introduced near-infrared light-induced indocyanine green fluorescence to identify the PTG during BABA RoT and reduce the risk of

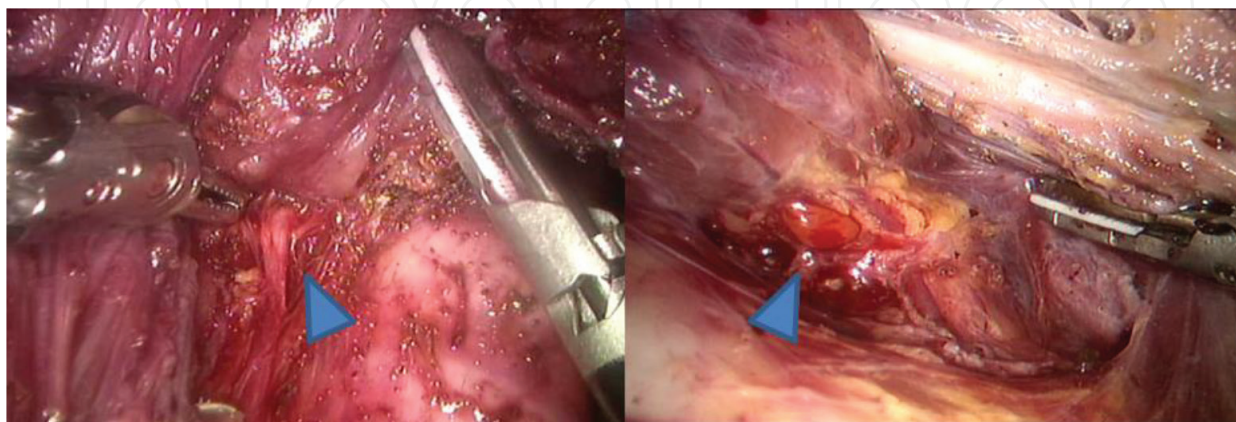


Figure 20. Preservation of the recurrent laryngeal nerve and parathyroid gland.

incidental parathyroidectomy [21]. If the nerve is not immediately exposed, the loose fibrous tissue needs to be further dissected from the inferior point of the artery near the tracheo-esophageal groove. At this time, the inferior PTG, which can be used as a guide to the RLN, can be detected. The Zuckerkandl tubercle can also be used as a guide to the RLN. Therefore, the area under the Zuckerkandl tubercle requires caution when dissecting using Maryland forceps. Because the inferior thyroid vessels supply blood to the inferior PTGs, the inferior vessels should be ligated close to the thyroid to preserve blood flow. If preservation of the PTGs is not possible, reimplantation should be considered. The pectoralis major muscle is preferred for autotransplantation of the PTG.

4.1.3.6. Dissection of the thyroid upper pole

With the retractor pulling the upper portion of the strap muscles in a cephalad direction and the trachea in a medial direction, ultrasonic shears are used to dissect the upper pole of the thyroid gland (**Figure 21**). The medial and lateral sides are dissected alternately to separate the upper pole of the thyroid gland. It is important to preserve the fascia of the cricothyroid muscle, because the external branch of the superior laryngeal nerve is closely related to the cricothyroid muscles [22]. Therefore, it is helpful to maintain the fascia using medial traction of the trachea during this procedure. In most cases, the posterior branch of the upper thyroid vessel, which supplies blood to the superior PTG, can be preserved by careful capsular dissection. There may be one or two small veins entering the posterior portion of the upper pole; these vessels should be identified and ligated carefully. Then, the terminal branches of the superior thyroid artery and vein should be identified and ligated carefully using ultrasonic shears. The three approaches to dissecting the upper thyroid gland are the (1) lateral, (2) anteromedial, and (3) posterior medial approaches. The lateral approach refers to gradual and careful dissection of the strap muscles attached to the thyroid gland. The anteromedial approach to the thyroid upper pole corresponds to extending the space between the thyroid gland and the anterior portion of the cricothyroid muscle. The posteromedial approach involves coming in close contact with the superior thyroid vessels along the ligament of Berry and cricothyroid fascia.

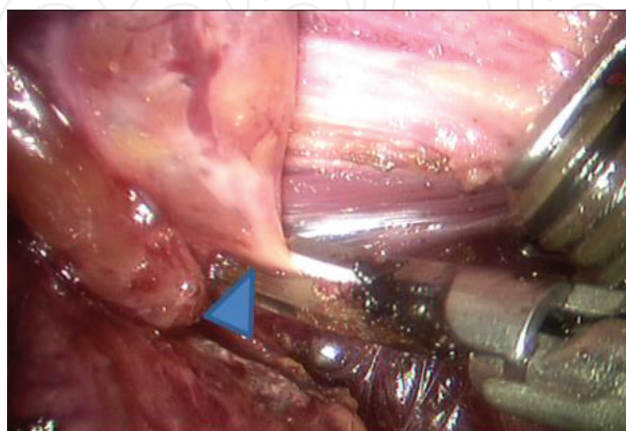


Figure 21. Dissection of thyroid upper pole, arrow, superior thyroid artery.

4.1.4. Specimen removal

After complete dissection of the thyroid gland from the trachea, the specimen is wrapped in an endoplastic bag (LapBag; Sejong Medical, Seoul, Korea) and removed through the left axillary port (**Figure 22**). If the incision of the left axilla is insufficient to extract the specimen, the incision can be widened using a knife. Once the specimen is extracted, it is diagnosed by analyzing intraoperative frozen sections and used to determine the extent of the operation required.

4.1.5. Central compartment dissection and contralateral thyroidectomy (if indicated)

If the frozen section is confirmed as malignant, central LN dissection (therapeutic or prophylactic) should be performed (**Figure 23**). Care should be taken to avoid injury to the recurrent laryngeal nerve by central compartment dissection. The contralateral lobe is handled in the same way. As shown in the figure, the operator has a comfortable and symmetrical view of the surgical field using BABA.

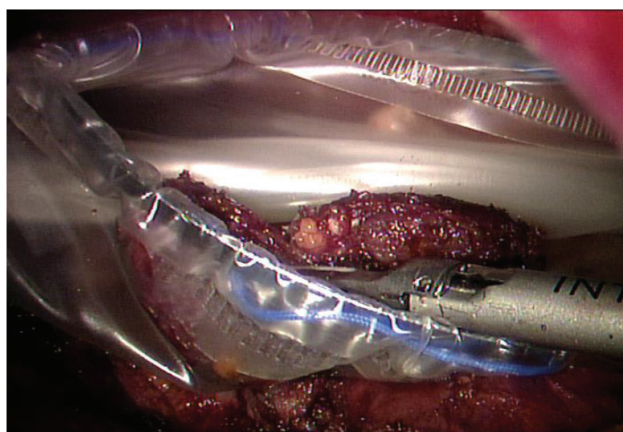


Figure 22. Specimen removal using endobag.

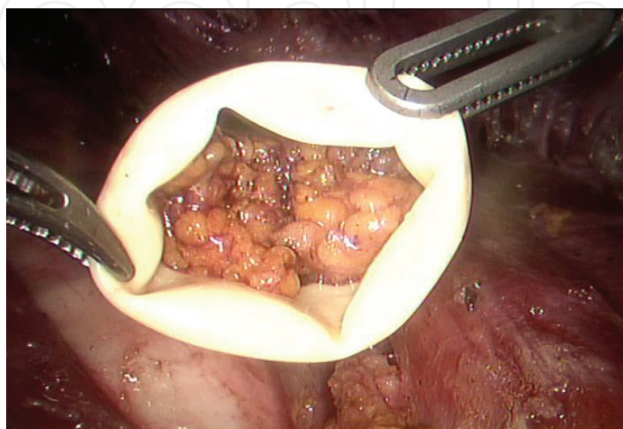


Figure 23. Central lymph node removal using thimble.

4.1.6. Closure

After the thyroidectomy is completed, the operative field is irrigated with warm saline. Hemostasis is performed carefully, and fibrin sealant (Tisseel®; Baxter Healthcare Corporation, Westlake Village, CA, USA) is then applied if necessary. The antiadhesive material is placed between the trachea and strap muscle and then between the skin and fascia. The midline between the two strap muscles is closed by a continuous running suture (**Figure 24**). Then, one or two Jackson-Pratt drains are inserted into the thyroid pockets through the opposite or bilateral axillary incisions; however, drainless BABA thyroidectomy was reported to be feasible [23]. It was also reported that a ropivacaine solution can be instilled into the skin flap before skin closure to reduce postoperative pain and the requirement for analgesia [24]. Finally, the skin of both breasts and the axilla are sutured by the knot-burying technique using an absorbable ligature.

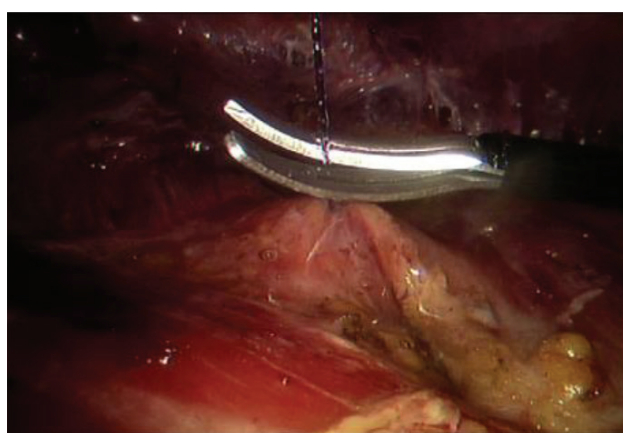


Figure 24. Midline closure.

4.2. LN dissection

4.2.1. Central compartment dissection (**Figure 25**)

After completion of thyroidectomy on the lesion side, ipsilateral neck LN dissection is performed. For therapeutic central LN dissection, it is particularly important to avoid RLN injury, preserve the PTG, and achieve complete resection of the suspected LN. In advance, it is useful to have a spacious field of vision to expose the central LNs and major structures. Kang et al. reported that blind spots are reduced using a deep-seated LN approach around the central compartment below the sternal notch via a VM that repositions the pivot point of the robot arm as high as possible [6]. In addition, Kim et al. reported that the addition of a snake retractor to the axillary trocar site enhances the central view and increases the number of resected LNs [23].

For complete and safe central LN dissection, an understanding of the anatomical relationship among the thymus, lower PTG, and soft tissues containing the LNs is needed. The vertical inferior thyroid veins running along the thymus help to indicate the dissection plane. The central compartment LN is located deeper vertically than the plane of these veins and the thymus.

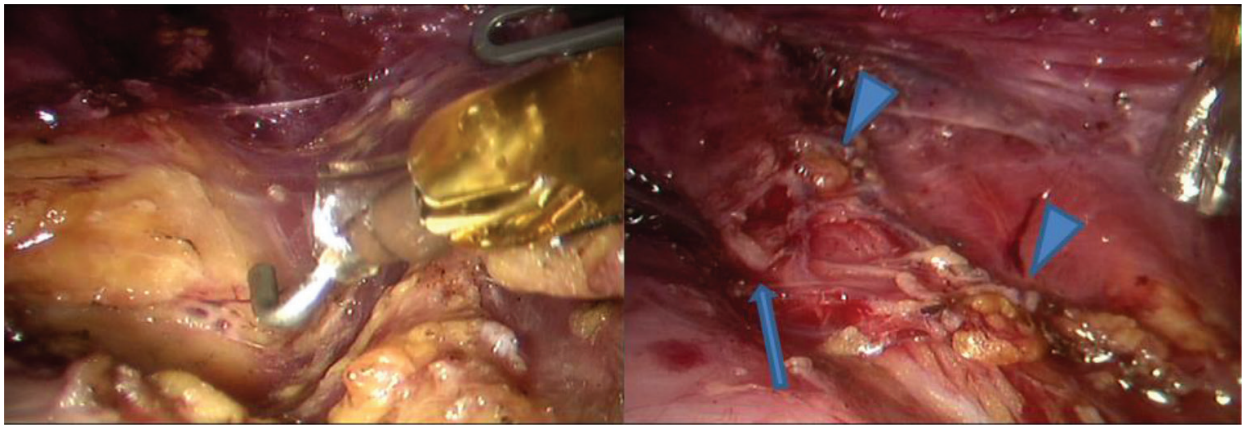


Figure 25. Central compartment dissection, arrow long; left recurrent laryngeal nerve, arrow short; left superior and inferior parathyroid glands.

The inferior PTG is located on the superficial plane, usually within or near the thymus. Thus, preserving the thymus helps reduce the risk of hypoparathyroidism (hypoPTH). Usually, the central LN is separated, with preservation of the thymus and the inferior PTG, and removed from the carotid artery in the medial direction. If a PTG is accidentally removed along with the resected tissue containing the central LN, autotransplantation into the pectoralis major is recommended. The RLN should be carefully monitored and preserved at this stage. Therefore, a nerve-monitoring device connected to a monopolar electrocautery is helpful for identifying the RLN.

4.2.2. Lateral compartment dissection

The procedures related to BABA robotic lateral neck dissection are essentially similar to those of the open method and have been reported previously [13]. First, this procedure requires a larger skin flap than that required for conventional thyroidectomy, with the boundaries being the inferior border of the submandibular glands cranially, the mandible angle superiorly, and the anterior edge of the trapezius muscle posteriorly. The fascia between the sternothyroid muscles and the SCM muscles is incised. After the medial and lateral borders of the SCM muscle are fully exposed, the SCM muscle is pulled upward using a #0 polydioxanone suture (Ethicon, San Angelo, TX, USA) and fixed. In the level IV dissection, the transverse cervical artery and phrenic nerve are identified, and the level II dissection is extended until the posterior belly of the digastric muscle preserves the spinal accessory nerve. The direction of the camera port can be changed such that the dissecting field of view is secured and pulled further cranially when necessary. It can also be helpful to rotate the camera port slightly clockwise or counterclockwise.

5. Review of the evidence: the safety of performing BABA RoT

5.1. Technical

Table 2 shows the technical safety parameters for BABA RoT. Below, we describe various surgical complications, including RLN paralysis and hypoPTH, the most important factors for thyroidectomy.

First author, year	No. of samples (total cases)	VC palsy*	VC palsy [‡]	HypoPTH*, [‡]	HypoPTH [‡] , [‡]	Bleeding	Chyle leak
Kim, 2011 [25] [‡]	69 (69)	1.4%	0%	33.3%	1.4%	0%	1.4%
Lee, 2013 [8]	1026 (872)	14.2% [‡]	0.2% [‡]	39.1%	1.5%	0.4%	NA
Kim, 2014 [6]	123 (100)	4.9%	0%	29%	0%	0%	NA
Lee, 2015 [26]	100 (88)	3.0%	0%	21.6%	0%	0%	0%
Kim, 2015 [23]	300 (143)	2.6%	0%	23.1%	1.4%	0.3%	0.6%
Cho, 2016 [27]	109 (99)	6.4%	0.9%	33.0%	1.8%	0.9%	0%
Bae, 2016 [28]	118 (91)	3.3% [‡]	0% [‡]	35.2%	2.2%	0%	NA

*Transient.

[‡]Permanent.

[‡]For total thyroidectomy cases.

Note: No.: number; VC: vocal cord; hypoPTH: hypoparathyroidism; NA: not available.

Table 2. Technical safety of performing bilateral axillo-breast approach robotic thyroidectomy.

5.1.1. Recurrent laryngeal nerve (RLN)

Table 2 shows the incidences reported to date of transient and permanent RLN injury during BABA RoT [6, 8, 23, 25–28]. These studies were published in Korea. In most studies, transient RLN damage was defined as hoarseness or vocal fold paralysis of <6 months. The reported incidence of transient RLN injury in patients undergoing BABA RoT ranges from 1.4 to 14.2%, and most studies have reported an incidence of <7%. Particularly, permanent RLN injuries were observed in <1% of patients, which is an excellent result, comparable to that of conventional OT. **Table 3** shows the results of five studies that compared RoT with OT or ET;

First author, year	No. of pts. (RoT vs. OT)	No. of TT (RoT vs. OT)	Evaluation	Transient palsy (%) (RoT vs. OT)	Permanent palsy (%) (RoT vs. OT)
Kim, 2011 [25] [‡]	69 vs. 138	69 vs. 138	Laryngoscopy	1.4 vs. 0.7 (0.615)	0 vs. 0 (1.000)
Kim, 2014 [6]	123 vs. 392	100 vs. 364	Laryngoscopy	4.9 vs. 6.1 (0.607)	0 vs. 0.3 (1.000)
Kwak, 2015 [29]	206 vs. 634	157 vs. 544	Stroboscopy	0.5 vs. 0.9 (0.363)	NA
Cho, 2016 [27]	109 vs. 109 [*]	–	Laryngoscopy	6.4 vs. 5.5 (0.775)	0.9 vs. 0.9 (1.000)
First author, year	No. of pts. (RoT vs. ET)	No. of TT (RoT vs. ET)	Evaluation	Transient palsy (%) (RoT vs. ET)	Permanent palsy (%) (RoT vs. ET)
Kim, 2011 [25] [‡]	69 vs. 95	69 vs. 95	Laryngoscopy	1.4 vs. 2.1 (0.757)	0 vs. 2.1 (0.623)
Kim, 2016 [30]	289 vs. 289 [*]	114 vs. 114	Medical record ± laryngoscopy	4.5 vs. 3.8 (0.677)	0.7 vs. 0.3 (1.000)

^{*}After propensity score matching.

[‡]For total thyroidectomy cases.

Notes: No.: number; pts: patients; NA: not available; TT: total thyroidectomy.

Table 3. Comparison of recurrent laryngeal nerve palsy between bilateral axillo-breast approach robotic thyroidectomy (RoT) and open thyroidectomy (OT) or endoscopic thyroidectomy (ET).

these studies reported no difference in incidence between transient and permanent RLN injuries [6, 25, 27, 29, 30]. Therefore, the technical safety of BABA RoT for RLN preservation has been demonstrated sufficiently. These results were also validated in several meta-analyses of studies that included BABA and TAA methods, with the exception of one study [31–35].

5.1.2. Hypoparathyroidism (hypoPTH)

Table 2 shows the incidence of transient and permanent hypoPTH after BABA RoT [6, 8, 23, 25–28]. The definition of hypoPTH varies but is generally defined according to parathyroid hormone and calcium levels and hypocalcemic symptoms. In most studies, permanent hypoPTH was defined as the need for medication for at least 6 months. The incidence of transient hypoPTH in patients undergoing BABA RoT was 22–39%, and the incidence of permanent hypoPTH in patients undergoing the total thyroidectomy was <3%. This is an important indicator of the technical safety of BABA RoT, which is comparable to traditional OT. Furthermore, in five studies that compared RoT and OT (**Table 4**), the incidence of transient or permanent hypoPTH was similar between RoT and OT, suggesting that BABA RoT is a more appropriate method for total thyroidectomy [6, 25, 27, 29, 30].

5.1.3. Other complications

Among the other complications, bleeding and chyle leak are described in **Table 2**. Bleeding was reported in four out of seven studies with no cases and in the remaining three studies

First author, year	No. of pts. (RoT vs. OT)	No. of TT (RoT vs. OT)	Definition of transient hypoPTH	Transient (%) (RoT vs. OT)	Permanent (%) (RoT vs. OT)
Kim, 2011 [25]	69 vs. 138	69 vs. 138	PTH normalized within 6 months	33.3 vs. 27.5 (0.484)	1.4 vs. 2.9 (0.873)
Kim, 2014 [6]	123 vs. 392	100 vs. 364	Serum calcium <4.0 mEq/L	29.0 vs. 22.0 (0.161)	0 vs. 0 (0.000)
Kwak, 2015 [†] [29]	206 vs. 634	157 vs. 544	iCa <4.4 mg/dL or PTH < 8 pg/mL	14.6 vs. 15.0 (0.296)	NA
Cho, 2016 [‡] [27]	109 vs. 109 [*]	–	PTH <13 pg/mL	33.0 vs. 26.6 (0.374)	1.8 vs. 1.8 (1.000)
First author, year	No. of pts. (RoT vs. ET)	No. of TT (RoT vs. ET)	Definition of transient hypoPTH	Transient (%) (RoT vs. ET)	Permanent (%) (RoT vs. ET)
Kim, 2011 [25]	69 vs. 95	69 vs. 95	PTH normalized within 6 mo	33.3 vs. 25.3 (0.340)	1.4 vs. 3.2 (0.851)
Kim, 2016 [‡] [30]	289 vs. 289 [*]	114 vs. 114	PTH <5 pg/mL	38.6 vs. 33.3 (0.408)	0.9 vs. 1.8 (1.000)

^{*}After propensity score matching.

[†]Including lobectomy cases.

Notes: No.: number; pts: patients; TT: total thyroidectomy; NA: not available; iCa: ionized calcium.

Table 4. Comparison of hypoparathyroidism between bilateral axillo-breast approach robotic thyroidectomy (BABA RoT) and open thyroidectomy (OT) or endoscopic thyroidectomy (ET).

<1% [6, 8, 23, 25–28]. The incidence of chyle leak was low in the two studies that reported this complication (1.4 and 0.6%, respectively) [23, 25]. Postoperative bleeding and hematoma are potentially fatal complications of thyroidectomy, because reoperation may be necessary to resolve the airway compression caused by hematoma. Otherwise, unlike TAA, brachial plexus and tracheal injury have not been reported in BABA RoT [36].

5.2. Oncological safety

The clinical parameters used to assess oncological safety after thyroidectomy include the number of retrieved LNs in the neck, stimulated thyroglobulin (sTg) level, and radioactive iodine (RAI) uptake on whole-body scan (WBS). Both the sTg level and RAI uptake reflect the surgical completeness of thyroidectomy.

5.2.1. LN retrieval

As the main indication of BABA RoT, papillary thyroid carcinoma frequently exhibits loco-regional metastasis into the surrounding cervical LNs. Therefore, LN dissection is performed for therapeutic or prophylactic purposes in most institutions, and the number of resected LNs is an indicator of the oncological safety associated with RoT [37, 38]. In all previous studies except for Kim et al. [25], the number of central neck LNs retrieved by RoT was statistically lower than that by OT [6, 23, 27, 29]. Nevertheless, the total LN count was five to nine, which is considered to exceed the minimum level of adequacy for LN dissection in the central compartment (**Table 5**). Only one study has compared RoT with OT in terms of the number of LNs excised during BABA robotic lateral neck dissection for locally advanced cancer, but no significant difference was observed (RoT vs. OT; 12.8 vs. 12.7 LNs) [13]. However, the currently available data indicate that BABA RoT is not superior to OT in terms of the number of central LNs retrieved.

5.2.2. Surgical completeness: sTg level and WBS

The surgical completeness of resection in thyroid carcinoma is generally assessed by measurements of serum thyroglobulin levels after RAI ablation and RAI uptake on posttherapeutic WBS [46, 47]. sTg levels are measured prior to RAI ablation combined with elevated thyroid stimulating hormone (TSH) treatment, via either thyroid hormone withdrawal or recombinant human TSH injection. Increased sTg levels after total thyroidectomy suggest the presence of remnant thyroid tissue. Therefore, a low sTg level is a reliable surrogate marker for the amount of remnant thyroid tissue after total thyroidectomy. **Table 5** shows the results of studies that measured sTg levels after the first RAI ablation following RoT or OT. Five studies reported no statistically significant difference in sTg levels between RoT and OT [6, 23, 25, 27, 39]. Compared with the sTg levels (mean, 4.9–10.2; median, 3.8) following OT, endoscopic surgery, or TAA [41, 42, 44, 45], the mean (0.8–1.4) and median sTg levels (0.2–0.6) following BABA RoT were remarkably lower [6, 23, 25, 27, 28, 39]. In addition, the proportion of patients with a sTg level <1.0 ng/mL was much higher: 65–87% after BABA RoT [6, 23, 39] compared with 21–48% after other approaches [40–43] (reported in previous studies). In two meta-analyses performed by Wang et al. and Son et al., there was no statistically significant difference between RoT and OT in terms of sTg levels [33, 35]. However, in another meta-analysis performed by Lang et al., sTg

First author, year	No. cases. (RoT vs. OT)	LN number (RoT vs. OT)	No. RAI cases (RoT vs. OT)	sTg after 1st RAI ablation (RoT vs. OT)	Proportion of cases with sTg <1.0 ng/mL (RoT vs. OT)
Kim, 2011 [25]	69 vs. 138	4.7 vs. 4.8 (0.802)	–	0.8 vs. 0.8 (0.978)	NA
Lee, 2011 [39]	174 vs. 237	NA	174 vs. 237	1.4 vs. 1.2 (0.998)	69.1% vs. 68.6% (0.924)
Kim, 2014 [6]	123 vs. 392	8.7 vs. 10.4 (0.006)	37 vs. 148	1.4 vs. 1.2 (0.652)	75.7% vs. 76.4% (0.931)
Kim, 2015 [23]	300 vs. 300	6.7 vs. 8.9 (<0.001)	68 vs. 130	0.8 vs. 1.8 (0.001)	86.6% vs. 67.6% (0.004)
Kwak, 2015 [29]	206 vs. 634	5.9 vs. 8.4 (0.001)	–	NA	NA
Cho, 2016 [27]	126 vs. 689	3.6 vs. 5.1 (<0.001)	67 vs. 52	0.25 vs. 0.2* (0.954)	NA
Bae, 2016 [28]	118 (RoT)		67	0.6*	

References about RAI ablation

First author, Year	No. cases (RoT/ vs. OT)	Approach	sTg after 1st RAI ablation (RoT vs. OT)	Proportion of cases with sTg < 1.0 ng/mL
Schlumberger, 2012 [40]	652	Conventional open	–	48.3%
Mallick, 2012 [41]	110	Conventional open	3.8*	21% [†]
Lombardi, 2007 [42]	152	Minimally invasive video-assisted	5.5	21%
Choi, 2012 [43]	99	Endoscopic BABA	NA	40.3%
Tae, 2014 [44]	62 vs. 183	Gasless unilateral axillo-breast	10.2 vs. 3.9 (<0.001)	NA
Lee, 2014 [45]	43 vs. 51	Transaxillary	4.9 vs. 4.2 (0.674)	NA

*Median.

[†]sTg < 2.0 ng/mL.

Notes: NA: not available; RAI: radioactive iodine; No.: number; LN: lymph node; sTg: stimulated thyroglobulin.

Table 5. Oncological safety: comparison of surgical completeness between bilateral axillo-breast approach robotic thyroidectomy (BABA RoT) and open thyroidectomy (OT).

levels were significantly higher after robotic compared with open surgery, which was more pronounced after TAA compared with BABA RoT [48].

Remnant thyroid tissue can also be measured by RAI thyroid uptake on WBS. Lee et al. reported that RAI uptake on the initial WBS was similar in the BABA RoT and OT groups after propensity score matching (the two groups were matched using a total of eight factors, including three demographic and five pathological characteristics) to minimize selective bias [39]. This study is the first report to systematically analyze the surgical completeness of BABA RoT and OT. Statistical techniques were applied to improve comparison of the two groups; therefore, this was a meaningful attempt to overcome the limits of a retrospective study design.

5.3. Functional

5.3.1. Pain

Since RoT requires formation of a larger skin flap than that does OT, there is concern that the postoperative neck and chest pain will be greater after RoT. In a prospective study, Chai et al. reported no significant difference in the postoperative pain score for the throat, anterior neck, posterior neck, or back at 1, 2, 3, and 14 days postoperatively between the BABA RoT ($n = 27$) and OT ($n = 27$) groups [49]. They also reported that the postoperative analgesic requirements were similar between the two groups using applications on mobile devices such as the iPad to facilitate the assessment and management of pain in postoperative patients. In addition, Cho et al. reported similar pain scores between the RoT and OT groups ($P = 0.669$ after surgery, $P = 0.952$ on postoperative day 1) [27]. Koo et al. reported no significant difference in chronic pain levels ($P = 0.321$) between the BABA RoT and OT groups after correcting for age and the postoperative follow-up period [50]. Because previous studies have used different assessment scales, it is not possible to provide a standardized comparison of postoperative pain by meta-analyses; nevertheless, the overall evidence suggests that RoT and OT achieve similar results in terms of postoperative pain. **Table 6** shows the results of three prospective randomized controlled trials (including 108, 55, and 34 subjects, respectively) that attempted to reduce postoperative pain after BABA RoT [14, 24, 51]. In all three studies, the preoperative and postoperative instillation of analgesics (ropivacaine or levobupivacaine spray) to the flap site during BABA RoT reduced postoperative pain and the need for analgesics compared with the OT group.

5.3.2. Voice quality and swallowing function

Postoperative voice quality after BABA RoT, independent of RLN injury, has been assessed in two studies. In 2015, Bae et al. assessed the VHI-10 score before surgery and 2 weeks, 3 months, and 6 months postoperatively [28]. After adjusting for the effect of time, they concluded that the mean Korean VHI-10 score during the postoperative 6 months increased initially but tended to

Author, year	Study design	Number subjects (patients vs. controls)	Analgesic	Parameters
Bae et al. 2015 [24]	PRCT	108 (54 vs. 54)	Ropivacaine, postoperative	VAS score, analgesic requirements, and adverse events
Ryu et al. 2015 [51]	PRCT	55 (28 vs. 27)	Levobupivacaine spray, postoperative	Pain score, need for PCA, other adverse effects
Kang et al. 2015 [14]	PRCT, double-blind	34 (17 vs. 17)	Ropivacaine, preincision	VAS score, bottom hit counts from PCA, need for fentanyl, CRP levels, BP, and HR

Notes: PRCT, prospective randomized controlled trial; VAS, visual analog scale; PCA, patient-controlled anesthesia.

Table 6. Postoperative pain management after BABA RoT.

decrease thereafter; there was no significant difference ($P = 0.308$) between the 91 BABA RoT cases and 27 lobectomy cases. Moreover, Chai et al. reported that patient satisfaction in terms of voice quality, as assessed using an iPad, was similar on days 1, 2, 3, and 14 between the two groups [49]. They also reported that the mean VHI10 scores on day 14 were similar between the BABA RoT and OT groups ($P = 0.849$). However, more large-scale prospective studies are needed to assess the difference in voice dysfunction between BABA RoT and OT. In addition, no studies have reported data pertaining to swallowing disorders after BABA RoT.

5.3.3. Sensory changes

There is concern regarding potential changes in the sensation of skin flaps caused by the more extensive dissection with BABA techniques compared with OT. In a prospective study by Kim et al., 19 patients underwent skin flap sensory assessments preoperatively and at 1 and 3 months postoperatively [52]. After BABA thyroidectomy, anterior chest paresthesia was normalized completely by 3 months. These results suggest that BABA has minimal adverse effects on anterior chest sensation.

5.4. Cosmetic satisfaction

The cosmetic outcome of the BABA technique involves practically no scarring, because this method transfers the anterior neck scar to four small hidden areas (the bilateral axilla and breasts), leaving the neck free of scars (**Figure 26**) [4]. Despite the early phase, we have already reported cosmetic satisfaction with endoscopic BABA according to a simple questionnaire [2]. Using an in-depth survey performed by a psychology consultant to evaluate neck scarring and psychological distress in patients who underwent BABA RoT, Koo et al. reported that the degree of scarring was significantly lower in the RoT group than the OT group ($P < 0.001$) [50]. There was also a significant difference in psychological distress between the immediate postoperative ($P = 0.009$) and follow-up period ($P < 0.001$). These results show the importance of scarless neck surgery and the esthetic superiority of the BABA method. In addition, Chai et al. reported significantly higher wound satisfaction scores in the 27 BABA RoT cases compared with the OT cases (7.4 vs. 5.7; $P = 0.016$) [49].

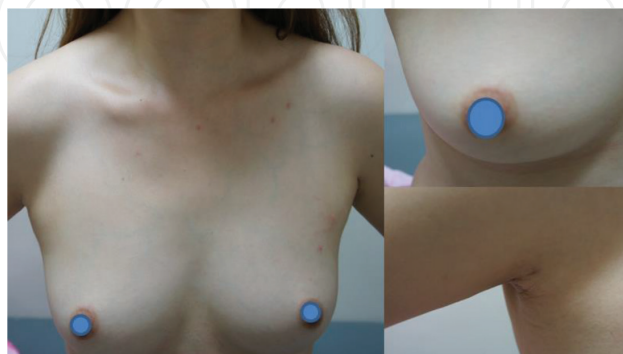


Figure 26. Postoperative wound after 6 months.

6. Special concerns for BABA RoT

6.1. BABA RoT experience with Graves' disease in comparison with OT

The application of ET for Graves' disease has been controversial. The major limitation is that it is not easy to control bleeding in cases of large hypervascular thyroid glands using non-flexible endoscopic instruments in a narrow two-dimensional field of view. Use of the surgical robot system has helped to overcome these limitations by introducing three-dimensional high-definition images and EndoWrist functions, which have resulted in more meticulous bleeding control. With recent technological advances and accumulation of experience, Kwon et al. reported successful results with comparable complication rates in 30 patients with Graves' disease [7]. There were no major complications, such as bleeding, open conversion, or permanent RLN injury, except for one case of permanent hypoPTH. In a subsequent article, Kwon et al. compared the safety of BABA RoT with that of OT in patients with Graves' disease ($n = 44$ and $n = 145$, respectively) and found comparable surgical completeness and complications between BABA RoT and conventional OT [53]. Therefore, BABA RoT may be a good surgical alternative for patients with Graves' disease who are concerned about cosmesis.

6.2. Influence of obesity on BABA RoT

Obesity is associated with various medical comorbidities that pose technical and clinical challenges, especially during surgery. For example, since a high BMI is a risk factor for various surgical complications, a retrospective study analyzed the influence of obesity on the surgical outcome of BABA RoT ($n = 310$) [10]. There was no statistically significant difference in body habitus indices, the length of hospital stay, surgical completeness, or complication rates between patients with a BMI <25 kg/m² and those with a BMI ≥ 25 kg/m². In conclusion, patients with a high BMI undergoing BABA RoT are not at increased risk of surgical complications; therefore, BABA RoT may be a good alternative for obese patients concerned with cosmesis.

Author details

Do Hoon Koo^{1*}, Dong Sik Bae¹ and June Young Choi²

*Address all correspondence to: dohoon.koo.md@gmail.com

1 Department of Surgery, Inje University College of Medicine & Haeundae Paik Hospital, Busan, Korea

2 Department of Surgery, Seoul National University Bundang Hospital and College of Medicine, Seoul, Korea

References

- [1] Shimazu K, Shiba E, Tamaki Y, et al. Endoscopic thyroid surgery through the axillo-bilateral-breast approach. *Surgical Laparoscopy Endoscopy & Percutaneous Techniques*. 2003;**13**:196-201
- [2] Choe JH, Kim SW, Chung KW, et al. Endoscopic thyroidectomy using a new bilateral axillo-breast approach. *World Journal of Surgery*. 2007;**31**:601-606
- [3] Chung YS, Choe JH, Kang KH, et al. Endoscopic thyroidectomy for thyroid malignancies: Comparison with conventional open thyroidectomy. *World Journal of Surgery*. 2007;**31**:2302-2306
- [4] Lee KE, Rao J, Youn YK. Endoscopic thyroidectomy with the da Vinci robot system using the bilateral axillary breast approach (BABA) technique: Our initial experience. *Surgical Laparoscopy, Endoscopy & Percutaneous Techniques*. 2009;**19**:e71-75
- [5] Chai YJ, Suh H, Woo JW, et al. Surgical safety and oncological completeness of robotic thyroidectomy for thyroid carcinoma larger than 2 cm. *Surgical Endoscopy*. 2017 Mar; **31**(3):1235-1240
- [6] Kim BS, Kang KH, Kang H, et al. Central neck dissection using a bilateral axillo-breast approach for robotic thyroidectomy: Comparison with conventional open procedure after propensity score matching. *Surgical Laparoscopy, Endoscopy & Percutaneous Techniques*. 2014;**24**:67-72
- [7] Kwon H, Koo doH, Choi JY, et al. Bilateral axillo-breast approach robotic thyroidectomy for Graves' disease: An initial experience in a single institute. *World Journal of Surgery*. 2013;**37**:1576-1581
- [8] Lee KE, Kim E, Koo do H, et al. Robotic thyroidectomy by bilateral axillo-breast approach: Review of 1,026 cases and surgical completeness. *Surgical Endoscopy*. 2013; **27**:2955-2962
- [9] Choi JY, Lee KE, Koo do H, et al. Use of spiral computed tomography volumetry for determining the operative approach in patients with Graves' disease. *World Journal of Surgery*. 2014;**38**:639-644
- [10] Lee HS, Chai YJ, Kim SJ, et al. Influence of body habitus on the surgical outcomes of bilateral axillo-breast approach robotic thyroidectomy in papillary thyroid carcinoma patients. *Annals of surgical treatment and research*. 2016;**91**:1-7
- [11] Bae DS, Koo doH, Choi JY, et al. Current status of robotic thyroid surgery in South Korea: A web-based survey. *World Journal of Surgery*. 2014;**38**:2632-2639
- [12] Lee KE, Koo doH, Kim SJ, et al. Outcomes of 109 patients with papillary thyroid carcinoma who underwent robotic total thyroidectomy with central node dissection via the bilateral axillo-breast approach. *Surgery*. 2010;**148**:1207-1213

- [13] Seup Kim B, Kang KH, Park SJ. Robotic modified radical neck dissection by bilateral axillary breast approach for papillary thyroid carcinoma with lateral neck metastasis. *Head Neck*. 2015;**37**:37-45
- [14] Kang KH, Kim BS, Kang H. The benefits of preincision ropivacaine infiltration for reducing postoperative pain after robotic bilateral axillo-breast approach thyroidectomy: A prospective, randomized, double-blind, placebo-controlled study. *Annals of Surgical Treatment and Research*. 2015;**88**:193-199
- [15] Kim HY, Choi YJ, Yu HN, et al. Optimal carbon dioxide insufflation pressure during robot-assisted thyroidectomy in patients with various benign and malignant thyroid diseases. *World Journal of Surgical Oncology*. 2012;**10**:202
- [16] Jung SP, Kim SH, Bae SY, et al. A new subfascial approach in open thyroidectomy: Efficacy for postoperative voice, sensory, and swallowing symptoms. A randomized controlled study. *Annals of Surgical Oncology*. 2013;**20**:3869-3876
- [17] Paek SH, Choi JY, Lee KE, et al. Bilateral axillo-breast approach (BABA) endoscopic Sistrunk operation in patients with thyroglossal duct cyst: Technical report of the novel endoscopic Sistrunk operation. *Surgical Laparoscopy, Endoscopy & Percutaneous Techniques*. 2014;**24**:e95-98
- [18] Chai YJ, Kim SJ, Choi JY, et al. Papillary thyroid carcinoma located in the isthmus or upper third is associated with Delphian lymph node metastasis. *World Journal of Surgery*. 2014;**38**:1306-1311
- [19] Lee HY, Lee JY, Dionigi G, et al. The efficacy of intraoperative neuromonitoring during robotic thyroidectomy: A prospective, randomized case-control evaluation. *Journal of Laparoendoscopic & Advanced Surgical Techniques Part A*. 2015;**25**:908-914
- [20] Bae DS, Kim SJ. Intraoperative neuromonitoring of the recurrent laryngeal nerve in robotic thyroid surgery. *Surgical Laparoscopy, Endoscopy & Percutaneous Techniques*. 2015;**25**:23-26
- [21] Yu HW, Chung JW, Yi JW, et al. Intraoperative localization of the parathyroid glands with indocyanine green and Firefly(R) technology during BABA robotic thyroidectomy. *Surgical Endoscopy*. 2016 Nov [Epub ahead of print].
- [22] Kim SJ, Lee KE, Oh BM, et al. Intraoperative neuromonitoring of the external branch of the superior laryngeal nerve during robotic thyroid surgery: A preliminary prospective study. *Annals of Surgical Treatment and Research*. 2015;**89**:233-239
- [23] Kim WW, Jung JH, Park HY. A single surgeon's experience and surgical outcomes of 300 robotic thyroid surgeries using a bilateral axillo-breast approach. *Journal of Surgical Oncology*. 2015;**111**:135-140
- [24] Bae DS, Kim SJ, Koo do H, et al. Prospective, randomized controlled trial on use of ropivacaine after robotic thyroid surgery: Effects on postoperative pain. *Head Neck*. 2016;**38**(Suppl 1):E588-593

- [25] Kim WW, Kim JS, Hur SM, et al. Is robotic surgery superior to endoscopic and open surgeries in thyroid cancer? *World Journal of Surgery*. 2011;**35**:779-784
- [26] Lee HY, Yang IS, Hwang SB, et al. Robotic thyroid surgery for papillary thyroid carcinoma: Lessons learned from 100 consecutive surgeries. *Surgical Laparoscopy, Endoscopy & Percutaneous Techniques*. 2015;**25**:27-32
- [27] Cho JN, Park WS, Min SY, et al. Surgical outcomes of robotic thyroidectomy vs. conventional open thyroidectomy for papillary thyroid carcinoma. *World Journal of Surgical Oncology*. 2016;**14**:181
- [28] Bae DS, Suh BJ, Park JK, et al. Technical, oncological, and functional safety of bilateral axillo-breast approach (BABA) robotic total thyroidectomy. *Surgical Laparoscopy, Endoscopy & Percutaneous Techniques*. 2016;**26**:253-258
- [29] Kwak HY, Kim HY, Lee HY, et al. Robotic thyroidectomy using bilateral axillo-breast approach: Comparison of surgical results with open conventional thyroidectomy. *Journal of Surgical Oncology*. 2015;**111**:141-145
- [30] Kim SK, Woo JW, Park I, et al. Propensity score-matched analysis of robotic versus endoscopic bilateral axillo-breast approach (BABA) thyroidectomy in papillary thyroid carcinoma. *Langenbeck's Archives of Surgery*. 2017 Mar;**402**(2):243-250
- [31] Kandil E, Hammad AY, Walvekar RR, et al. Robotic thyroidectomy versus nonrobotic approaches: A meta-analysis examining surgical outcomes. *Surgical Innovation*. 2016;**23**:317-325
- [32] Lang BH, Wong CK, Tsang JS, et al. A systematic review and meta-analysis comparing surgically-related complications between robotic-assisted thyroidectomy and conventional open thyroidectomy. *Annals of Surgical Oncology*. 2014;**21**:850-861
- [33] Son SK, Kim JH, Bae JS, et al. Surgical safety and oncologic effectiveness in robotic versus conventional open thyroidectomy in thyroid cancer: A systematic review and meta-analysis. *Annals of Surgical Oncology*. 2015;**22**:3022-3032
- [34] Sun GH, Peress L, Pynnonen MA. Systematic review and meta-analysis of robotic vs. conventional thyroidectomy approaches for thyroid disease. *Otolaryngology—Head and Neck Surgery: Official Journal of American Academy of Otolaryngology-Head and Neck Surgery*. 2014;**150**:520-532
- [35] Wang YC, Liu K, Xiong JJ, et al. Robotic thyroidectomy versus conventional open thyroidectomy for differentiated thyroid cancer: Meta-analysis. *Journal of Laryngology and Otology*. 2015;**129**:558-567
- [36] Lee J, Yun JH, Choi UJ, et al. Robotic versus endoscopic thyroidectomy for thyroid cancers: A multi-institutional analysis of early postoperative outcomes and surgical learning curves. *Journal of Oncology*. 2012;**2012**:734541
- [37] Hughes DT, White ML, Miller BS, et al. Influence of prophylactic central lymph node dissection on postoperative thyroglobulin levels and radioiodine treatment in papillary thyroid cancer. *Surgery*. 2010;**148**:1100-1106

- [38] Randolph GW, Duh QY, Heller KS, et al. The prognostic significance of nodal metastases from papillary thyroid carcinoma can be stratified based on the size and number of metastatic lymph nodes, as well as the presence of extranodal extension. *Thyroid: Official Journal of the American Thyroid Association*. 2012;**22**:1144-1152
- [39] Lee KE, Koo do H, Im HJ, et al. Surgical completeness of bilateral axillo-breast approach robotic thyroidectomy: Comparison with conventional open thyroidectomy after propensity score matching. *Surgery*. 2011;**150**:1266-1274
- [40] Schlumberger M, Catargi B, Borget I, et al. Strategies of radioiodine ablation in patients with low-risk thyroid cancer. *The New England Journal of Medicine*. 2012;**366**:1663-1673
- [41] Mallick U, Harmer C, Yap B, et al. Ablation with low-dose radioiodine and thyrotropin alfa in thyroid cancer. *The New England journal of medicine*. 2012;**366**:1674-1685
- [42] Lombardi CP, Raffaelli M, de Crea C, et al. Report on 8 years of experience with video-assisted thyroidectomy for papillary thyroid carcinoma. *Surgery*. 2007;**142**:944-951; discussion 44-51
- [43] Choi JY, Lee KE, Chung KW, et al. Endoscopic thyroidectomy via bilateral axillo-breast approach (BABA): Review of 512 cases in a single institute. *Surgical Endoscopy*. 2012;**26**:948-955
- [44] Tae K, Song CM, Ji YB, et al. Comparison of surgical completeness between robotic total thyroidectomy versus open thyroidectomy. *Laryngoscope*. 2014;**124**:1042-1047
- [45] Lee S, Lee CR, Lee SC, et al. Surgical completeness of robotic thyroidectomy: A prospective comparison with conventional open thyroidectomy in papillary thyroid carcinoma patients. *Surgical Endoscopy*. 2014;**28**:1068-1075
- [46] Kim TY, Kim WB, Kim ES, et al. Serum thyroglobulin levels at the time of 131I remnant ablation just after thyroidectomy are useful for early prediction of clinical recurrence in low-risk patients with differentiated thyroid carcinoma. *The Journal of Clinical Endocrinology and Metabolism*. 2005;**90**:1440-1445
- [47] Mazzaferri EL, Robbins RJ, Spencer CA, et al. A consensus report of the role of serum thyroglobulin as a monitoring method for low-risk patients with papillary thyroid carcinoma. *The Journal of Clinical Endocrinology and Metabolism*. 2003;**88**:1433-1441
- [48] Lang BH, Wong CK, Tsang JS, et al. A systematic review and meta-analysis evaluating completeness and outcomes of robotic thyroidectomy. *Laryngoscope*. 2015;**125**:509-518
- [49] Chai YJ, Song J, Kang J, et al. A comparative study of postoperative pain for open thyroidectomy versus bilateral axillo-breast approach robotic thyroidectomy using a self-reporting application for iPad. *Annals of Surgical Treatment and Research*. 2016;**90**:239-245
- [50] Koo do H, Kim da M, Choi JY, et al. In-depth survey of scarring and distress in patients undergoing bilateral axillo-breast approach robotic thyroidectomy or conventional open thyroidectomy. *Surgical Laparoscopy, Endoscopy & Percutaneous Techniques*. 2015;**25**:436-439

- [51] Ryu JH, Yom CK, Kwon H, et al. A prospective, randomized, controlled trial of the postoperative analgesic effects of spraying 0.25 % levobupivacaine after bilateral axillo-breast approach robotic thyroidectomy. *Surgical Endoscopy*. 2015;**29**:163-169
- [52] Kim SJ, Lee KE, Myong JP, et al. Prospective study of sensation in anterior chest areas before and after a bilateral axillo-breast approach for endoscopic/robotic thyroid surgery. *World Journal of Surgery*. 2013;**37**:1147-1153
- [53] Kwon H, Yi JW, Song RY, et al. Comparison of bilateral axillo-breast approach robotic thyroidectomy with open thyroidectomy for graves' disease. *World Journal of Surgery*. 2016;**40**:498-504