

# We are IntechOpen, the world's leading publisher of Open Access books Built by scientists, for scientists

6,900

Open access books available

186,000

International authors and editors

200M

Downloads

Our authors are among the

154

Countries delivered to

TOP 1%

most cited scientists

12.2%

Contributors from top 500 universities



WEB OF SCIENCE™

Selection of our books indexed in the Book Citation Index  
in Web of Science™ Core Collection (BKCI)

Interested in publishing with us?  
Contact [book.department@intechopen.com](mailto:book.department@intechopen.com)

Numbers displayed above are based on latest data collected.  
For more information visit [www.intechopen.com](http://www.intechopen.com)



---

# Utility of Colposcopy: Comparison of Colposcopic Abnormality with Histology and Cytology, with Colposcopic Findings Focusing on the Lesion in Cervical Canal

---

Hiroyuki Kuramoto and Toshiko Jobo

Additional information is available at the end of the chapter

<http://dx.doi.org/10.5772/intechopen.68358>

---

## Abstract

This chapter discusses four significant items: (1) incidences of abnormal colposcopy in healthy women, (2) comparison of its abnormality with histology and (3) cytology, and (4) colposcopic findings focused on the lesions in cervical canal to prevent misdiagnosis.

1. The incidence of atypical colposcopic findings (ACF) was 3.6%, whereas that of abnormal cytology ( $\geq$ ASC-US: Atypical Squamous Cells with Undetermined Significance) was 1.1%. The former is more frequent than the latter.
2. The incidence of unsatisfactory colposcopic findings (UCF) was high (24.2%). Pap smear is more useful in primary screening, if performed satisfactorily.
3. Colposcopy detects squamous intraepithelial lesions (SILs) constantly regardless of the severity of lesions. In cytology, it is easier to miss the lower lesions.
4. The incidence of benign reparatory lesion was 61.4% among women ( $n = 1317$ ) who had either abnormal cytology or colposcopy and was 74.6% if cytology is negative. We should realize that colposcopic abnormality does not always show neoplastic lesions.
5. Main colposcopic abnormalities were the triad of mosaic, punctation, and aceto-white epithelium, which appeared admixed in the majority of cases with tendency of lesion severity. However, colposcopic abnormal findings in benign lesions are also the triad, although the admixed ones are few.
6. The abnormal areas were wider in order of severity of SILs.

**Keywords:** colposcopy, cytology, Pap smear, colposcopy-guided biopsy, cervical cancer, screening for uterine cervix

---

## 1. Introduction

Cytological smear taken from the cervix (Pap smear) has been a useful tool for the primary screening of the cervix. However, the sensitivity of cytology is not always high to detect milder squamous intraepithelial lesions (SILs, i.e., mild and moderate dysplasia) [1, 2]. It is clarified that cancer of the cervix originates from human papillomavirus (HPV) infection [3]. Accordingly, the introduction of HPV testing has been suggested as the useful strategy for screening for this cancer [4, 5]. Therefore, the standard screening method for this type of cancer shall be to use Pap smear with a simultaneous or ancillary HPV test as the primary screening method, and colposcopy shall be reserved for the detailed examination.

Medical institutions in Japan including ours, and Central and Eastern Europe, including Hungary, have had a long history of the cancer detection program for the uterine cervix, using simultaneous cervical cytology and colposcopy [6, 7]. Therefore, data from the program with simultaneous screening with cytology and colposcopy may be a good model for comparing the two methods.

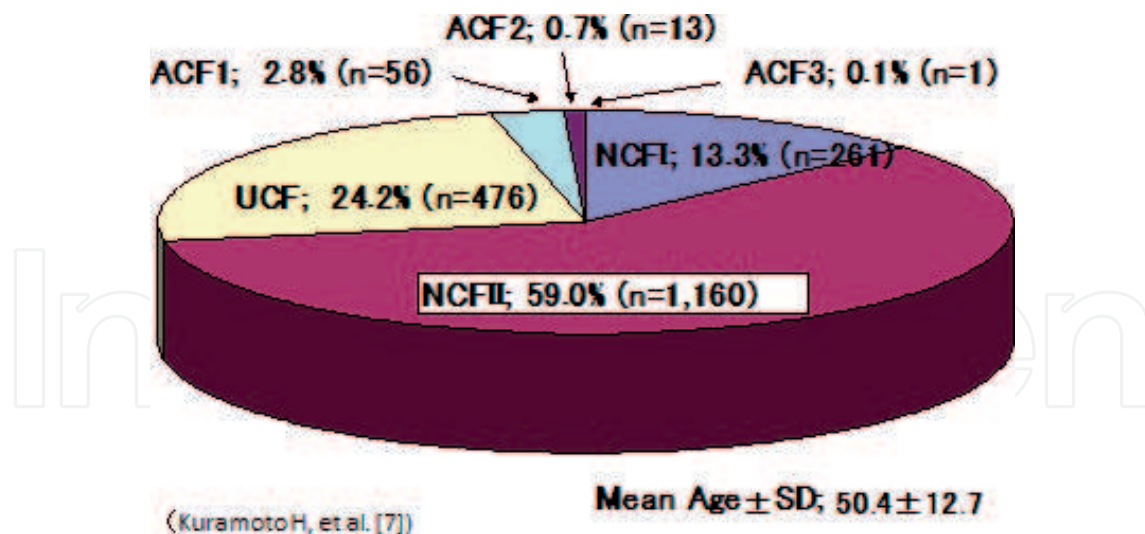
In this chapter, we report the characteristics of colposcopy and cytology based on the colposcopy-guided biopsy and discuss three significant items: (1) incidences of unsatisfactory and abnormal colposcopic findings in healthy women, (2) comparison of colposcopic abnormality with histology, and (3) cytology. In addition, (4) we also show colposcopic photos focusing on the lesions localized in the cervical canal, which is easily missed to be detected.

## 2. Incidences of colposcopic utility and abnormality in healthy women

### 2.1. Incidences of unsatisfactory colposcopic findings

Cancer of the cervix originates at the squamocolumnar junction (SCJ), where layers of squamous cells and columnar cells come into contact with each other. Therefore, the SCJ should be visualized on colposcopy, and cellular samples for Pap smear should be correctly obtained from the SCJ area when screening is performed. The result of colposcopy is categorized as unsatisfactory colposcopic findings (UCF) if the SCJ is not visible. The incidence of UCF was 24.2% in total ( $n = 1967$ , **Figure 1**) and 20.3% in women ( $n = 1313$ ) with a history of vaginal delivery, whereas in women ( $n = 97$ ) with a history of Cesarean Section (CS) and those ( $n = 557$ ) who had no history of delivery, these were 53.6% and 28.2%, respectively [7].

In other words, at least one out of every four women shows unsatisfactory findings on colposcopy. The incidence of UCF was high in the present series, although it has been generally considered to a range from 10 to 15%. This may be due to the increasing older age group in the



**Figure 1.** Distribution of colposcopic findings in healthy women ( $n = 1967$ ) [7].

Japanese population. The mean age of the present series was  $50.4 \pm 12.7$ . The results suggest that colposcopy is not suitable for primary screening for cervical cancer. In contrast, there were no unsatisfactory Pap smear results in this series.

## 2.2. Abnormal colposcopic findings and comparison of incidences with cytology

The incidence of abnormal findings on colposcopy (ACF), including ACF 1, 2, and 3 was 3.6% (**Figure 1**), and those in women who had undergone vaginal delivery and CS were 1.0 and 2.3%, respectively, whereas that in those who have no history of delivery was 9.8% [7]. Therefore, the screening procedure for women who have no history of delivery should be performed carefully.

In contrast, the incidence of abnormal Pap smear was 1.1%, including incidences of 0.7% ( $n = 14$ ) for ASC-US, 0.1% ( $n = 1$ ) for atypical glandular cells (AGC), and 0.3% ( $n = 6$ ) for low-grade squamous intraepithelial lesion (LSIL). The incidence of abnormal cytology is reasonable for primary screening in Japan.

Note that the incidence of colposcopic abnormality is more frequent than that of cytology.

## 3. Details of colposcopic abnormality

### 3.1. Comparison with histology

Abnormal colposcopic findings were compared with histology based on the colposcopy-guided regional biopsies. Women who showed abnormal findings with cytology and/or colposcopy were 2016 in number among those ( $n = 12,138$ ) who were screened and registered at the Kitasato Gynecologic Tumor Clinic (**Table 1**) [2]. Incidences of benign reparatory lesion, mild, moderate, and severe dysplasia and carcinoma in situ (CIS) were 61.4, 17.1, 7.6, 5.2, and 7.4%, respectively,

Cytology	Histology							No biopsy
	Benign*	Mild dysplasia	Moderate dysplasia	Severe dysplasia	CIS	Others	Total	
NILM	646 (74.6%)	162 (18.7%)	39 (4.5%)	5 (0.6%)	3 (0.3%)	10 (1.2%)	865 (100%)	424
LSIL+HSIL (MD <sup>2*</sup> )	124 (52.8%)	46 (19.6%)	28 (11.9%)	26 (11.1%)	5 (2.1%)	6 (2.6%)	235 (100%)	238
ASC	13 (44.8%)	6 (20.7%)	3 (10.3%)	6 (20.7%)		1 (3.4%)	29 (100%)	29
HSIL(SD <sup>3*</sup> )	20 (18.5%)	6 (5.6%)	24 (22.2%)	27 (25%)	31 (28.7%)		108 (100%)	8
CIS	4 (10.5%)	3 (7.9%)	4 (10.5%)	1 (2.6%)	26 (68.4%)		38 (100%)	0
SCC	2 (4.8%)	2 (4.8%)	2 (4.8%)	3 (7.1%)	33 (78.6%)		42 (100%)	0
Total	809 (61.4%)	225 (17.1%)	100 (7.6%)	68 (5.2%)	98 (7.4%)	17 (1.3%)	1317 (100%)	699
Total							2016	

Modified with update in cytologic nomination from Kuramoto et al. [2].  
\*Squamous metaplasia, reserve cell proliferation and chronic cervicitis.  
<sup>2\*</sup>MD=moderate dysplasia.  
<sup>3\*</sup>SD=severe dysplasia.

**Table 1.** Histological diagnosis and cytology in cases with either cytologic or colposcopic abnormality.

among 1317 women who had colposcopy-guided biopsy excluding invasive carcinomas. The benign incidence was 74.6% if cytology ( $n = 865$ ) was negative.

In other words, the majority of histology shows benign lesions, including squamous metaplasia, reserve cell proliferation or chronic cervicitis. We should realize that colposcopic abnormality does not always show neoplastic lesions.

**3.2. Abnormal colposcopic findings: extent and characters of the findings**

Incidences of abnormal colposcopic findings related to mosaic (M), punctation (P), and aceto-white epithelium (W) are shown in **Table 2**, and those with benign, mild, moderate, and severe dysplasia, CIS, and stage Ia1 were 76.6, 76.6, 80.0, 93.8, and 83.7%, respectively.

Note that the triad of M, P, and W has significant abnormality on the early cervical lesions, including the benign lesions.

The extent of occupying lesions on the vaginal portio were compared with individual SILs, including mild, moderate, and severe dysplasia, and carcinoma *in situ* were compared (**Figure 2**), and the incidences of those >3/4 circle on the portio were 11.4, 8.8, 16.7, and 26.6%, respectively, whereas those of ≤1/4 were 51.6, 40.5, 26.3, and 16.0%, respectively [1].

The abnormal colposcopic area is wider along with the more severe lesion.

The characteristic abnormal findings of colposcopy were the triad of mosaic (M), punctation (P), and aceto-white epithelium (W) (**Figure 3**). When compared with each of SILs, incidences



of those of single M, P, or W in mild, moderate, and severe dysplasia, and CIS were 56.0, 54.0, 40.5, and 30.7, whereas those of combined M, P, and W were 33.2, 37.4, 50.0, and 46.4%, respectively, and those of M, P, and W + aV were 4.5, 5.6, 7.0, and 19.2%, respectively [1].

Colposcopic findings	benign	mild & moderate dysplasia	Severe dysplasia	CIS	Stage Ia1
UCF	1 (0.3%)	1 (0.5%)	2 (6.7%)	1 (1.3%)	3 (6.1%)
NCF	56 (19.0%)	33 (18.0%)	1 (3.3%)	1 (1.3%)	1 (2.0%)
M.P.W. single	141 (48.1%)	87 (47.6%)	10 (33.3%)	15 (18.7%)	5 (10.2%)
M.P.W. combined	61 (20.7%)	225 (76.6%)	140 (76.6%)	24 (80.0%)	75 (93.9%)
M.P.W.+aV	18 (6.1%)	41 (22.4%)	9 (30.0%)	35 (43.7%)	20 (40.9%)
M.P.W.+IC	5 (1.7%)	12 (6.6%)	5 (16.7%)	23 (28.7%)	15 (30.6%)
aV	9 (3.1%)	9 (4.9%)	3 (10.0%)	2 (2.5%)	2 (4.1%)
IC	3 (1.0%)			1 (1.3%)	2 (4.1%)
Total	294 (100%)	183 (100%)	30 (100%)	80 (100%)	49 (100%)

Table 2. Variety of colposcopic findings and cervical lesions.

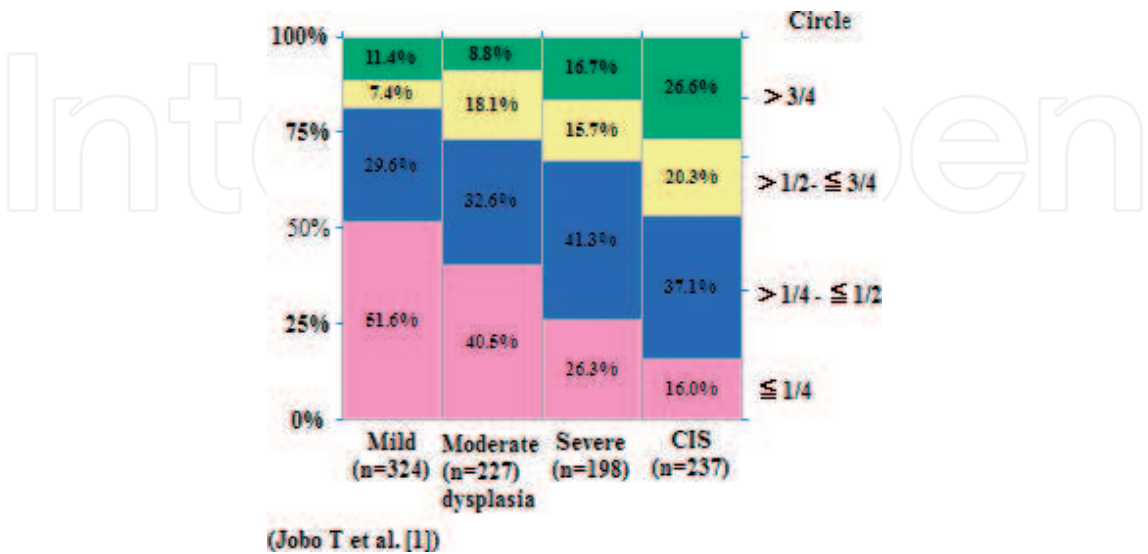


Figure 2. Extent of occupying lesions on abnormality in circle and SILs [1].

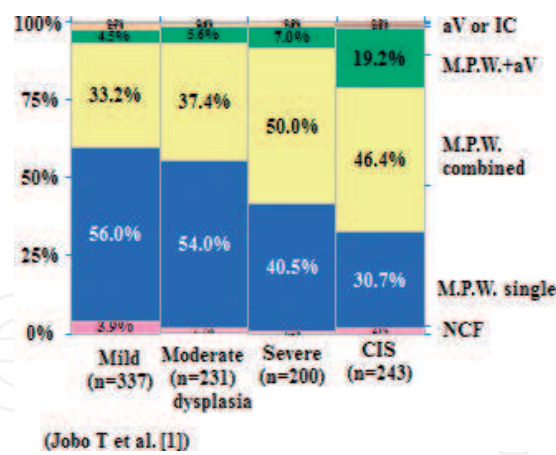


Figure 3. Abnormal findings in colposcopy and SILs [1].

The combined appearance of the triad of MPW with or without atypical vessels (aV) was more frequent in the more severe lesions.

3.3. Comparison between colposcopy and cytology

The incidences between abnormal findings of colposcopy (ACF) and cytology ( $\geq$ ASC) are compared in SILs. The positive incidences of colposcopy in mild ( $n = 225$ ), moderate ( $n = 100$ ), and severe ( $n = 68$ ) dysplasia, and CIS (98) were 87.6, 88.0, 95.6, and 99.0%, respectively, whereas those of cytology were 28.0, 61.0, 92.6, and 96.9%, respectively (Figure 4) [2]. The later study revealed that the negative incidences of mild ( $n = 337$ ) and moderate ( $n = 231$ ) dysplasia were decreased into 57.5 and 24.2%, respectively (Table 3) [1].

Note that colposcopy finds constantly the early lesions irrespective of severity. In contrast, cytology is inferior in detecting less severe lesions of mild or moderate dysplasia.

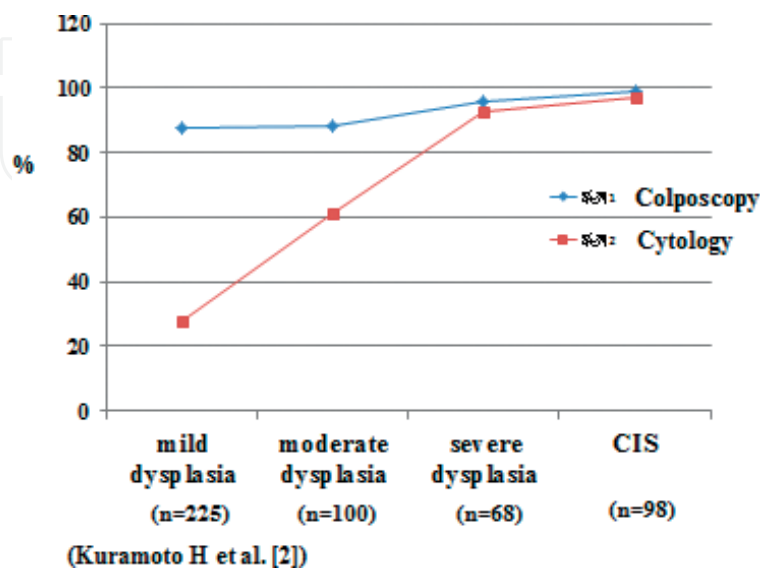


Figure 4. Comparison of abnormal incidences between colposcopy and cytology in SILs [2].

Cytology	Colposcopy	Mild dysplasia (n=337)	Moderate dysplasia (n=231)	Severe dysplasia (n=200)
≥ASC	ACF	130 (38.6%)	171 (74.1%)	176 (88.0%)
	NCF	6 (1.8%)	1 (0.4%)	2 (1.0%)
MLM	ACF	194 (57.5%)	56 (24.2%)	22 (11.0%)
	NCF	7 (2.1%)	3 (1.3%)	0 (0%)

**Table 3.** Combined effect of cytology and colposcopy [1].

The combined use of cytology and colposcopy, however, is a good combination to elevate the quality of correct diagnosis. In addition, colposcopy fails rarely to find each of mild, moderate, and severe dysplasia being compared with cytology (**Figure 4** and **Table 3**), the results of which show that colposcopy is a good tool for the secondary screening or the detailed examination.

## 4. Materials and methods

### 4.1. Materials

#### 4.1.1. For Section 2

The subjects were 1967 consecutive women who underwent screening at the Central Clinic of the Kanagawa Health Service Association using Pap smear and colposcopy simultaneously [7]. The screening programs are based on governmental or company regulations or individual application.

#### 4.1.2. For Section 3

The data are from the registry of Tumor Clinic, Department of Gynecology, Kitasato University Hospital, where the screening for cervix carcinoma was performed by using simultaneous cytology and colposcopy and were analyzed twice at the level of registry numbers (12,138 and 20,900), at which occasion cases who showed abnormal findings either cytology (≥ASC) or colposcopy (≥ACF), excluding invasive carcinoma of the cervix, were 1918 and 2037, respectively.

### 4.2. Methods of cytology and colposcopy

#### 4.2.1. Pap smear

The cell samples were obtained using a cotton tip (Osaki applicator, Osaki Medical Co. Ltd, Nagoya, Japan) and Cytobrush® plus (Medscand Medical and Cooper Surgical Company, Trumbull, USA) rinsed with physiological saline for the vaginal portio and the cervical canal, respectively, and the cells from the two samples were separately placed onto two slides or each half of a slide, and the tips of the instruments were rotated without making



the cell-free area. The slide samples were immediately placed into 95% ethyl alcohol for fixation. Then, the cellular samples were processed using routine Papanicolaou staining procedures.

The cytologic diagnosis for Section 2 was based on the Bethesda System for reporting cervical cytology [8, 9]. The diagnosis for Section 3 was based on the criteria of the Japan Association of Obstetricians and gynecologists (JAOG), which was modified Papanicolaou classification, and rearranged according to the Bethesda System.

#### 4.2.2. Colposcopy

The colposcopic diagnosis was based on the IFCPC 2011 colposcopic classification [10]. Additionally, normal colposcopic findings (NCF) were divided into two subcategories, NCFI and NCFII. Abnormal colposcopic findings (ACF) were divided into three groups, according to their sub-groupings for white epithelium (W), punctation (P), and mosaic (M), which were divided into three categories, as listed below:

##### 1. NCF

1. NCFI: NCF with a squamocolumnar junction (SCJ) localized outside of the external os.
2. NCFII: NCF with an SCJ localized within the cervical canal that was confirmed by opening the canal with forceps.

##### 2. ACF

1. ACF1: W1, M1, and P1, with which we image squamous metaplasia.
2. ACF2: W2, M2, and P2, with which we image mild or moderate dysplasia.
3. ACF3: W3, M3, and P3, with which we image severe dysplasia or carcinoma *in situ*.
4. ACF4: atypical vessels (aV) associated with W, M, and P, with which microinvasive cancer is suspected.

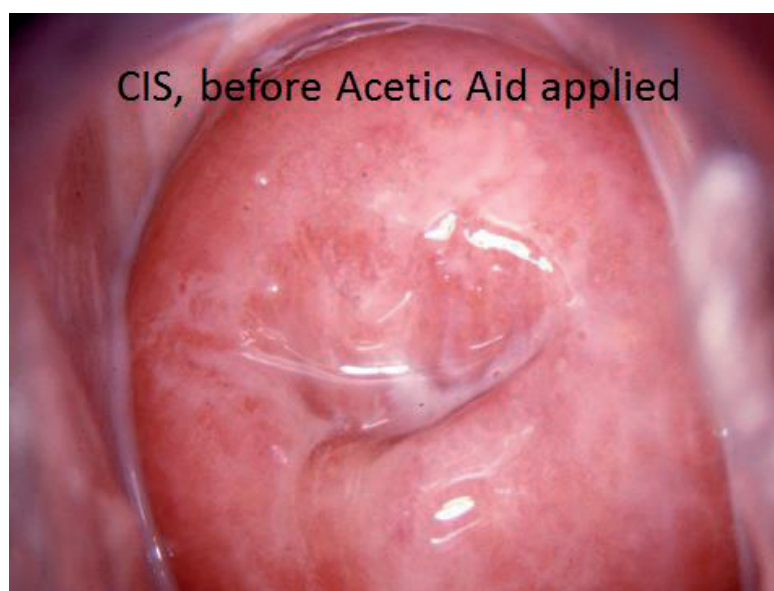W was quantitatively subgrouped based on thickness, i.e., color (bluish, pure, or ivory white) and surface texture (smooth or coarse). M was based on the presence of a regular or irregular vessel network and vessel diameter. P was based on the distance between Ps and P shape.

#### 4.2.3. Histology

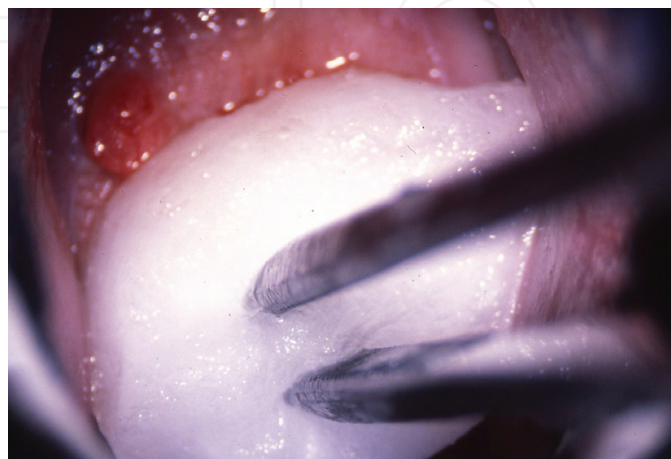
Colposcopy-guided biopsies, not infrequently multiple, were obtained from the regional ACF areas for histological analysis. SILs were classified into four and adopted the criteria of mild dysplasia, moderate dysplasia, severe dysplasia, or carcinoma *in situ* following Japanese custom, and the most significant portion of diagnosis was selected as the diagnosis of the case.

## 5. Colposcopy focusing on the lesion in cervical canal

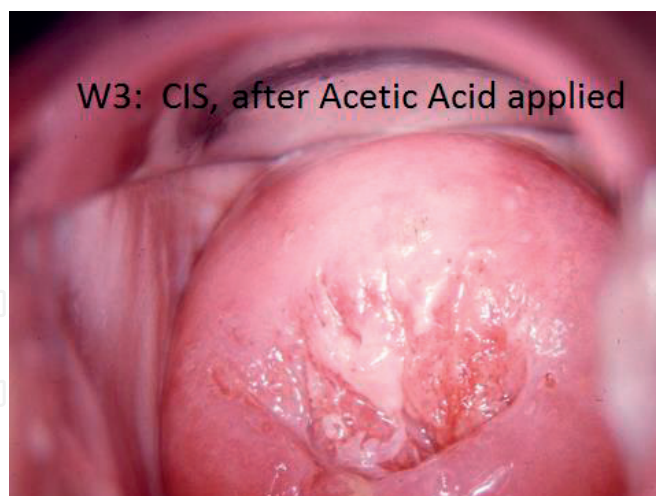1. Acetic acid is inevitable for colposcopy (**Figures 5–7**).
2. Normal colposcopic findings (NCF) (**Figures 8–10**).
3. Grading of M, P, and W (**Figures 11–13**).
4. Illustrations of colposcopic findings are mandatory (**Figure 14**).
5. Colposcopy-guided “sniping” biopsy taking (**Figure 15**).
6. Special attention on the lesion in cervical canal (**Figures 16–21**).



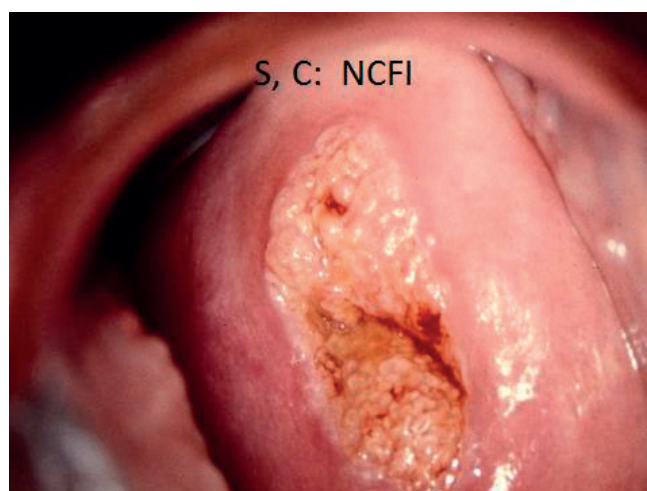
**Figure 5.** Colposcopic finding before applying acetic acid.



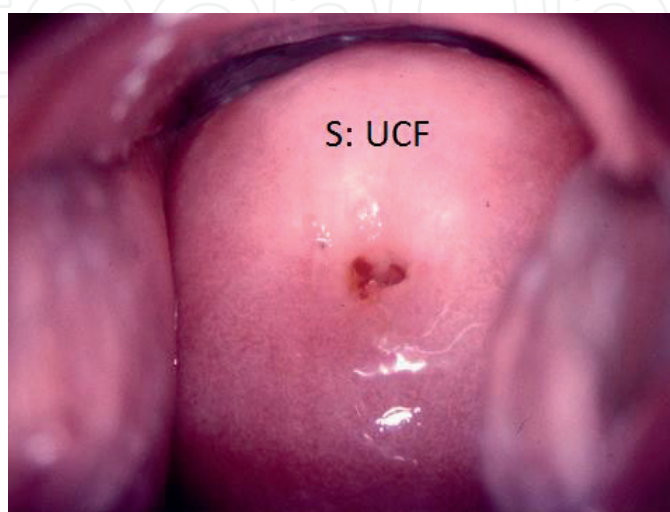
**Figure 6.** Careful application of 3% acetic acid giving time longer than 30 s is mandatory. A cotton tip being shaped by forceps from cotton ball is effective in the cervical canal.



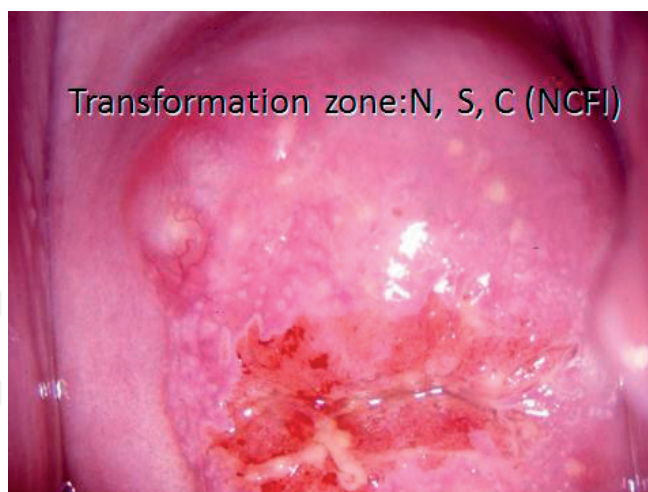**Figure 7.** Aceto-white grade 3 (w3) after acetic acid applied.



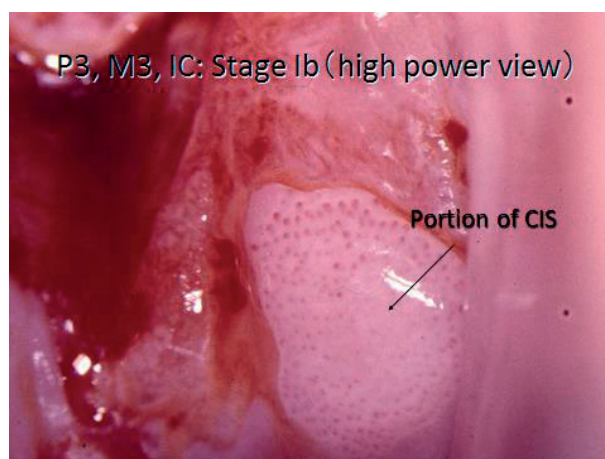
**Figure 8.** Squamocolumnar junction (SCJ) without transformation zone.



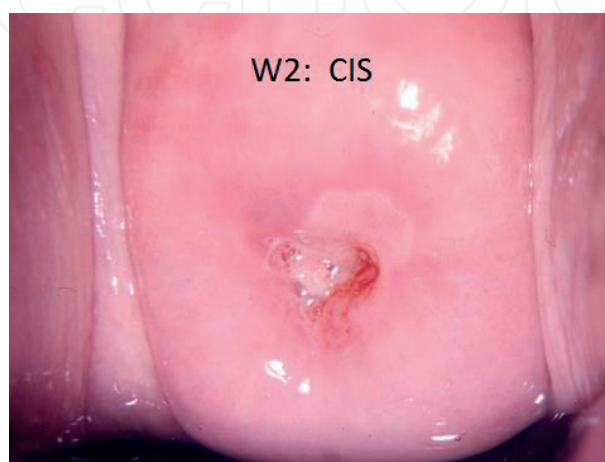**Figure 9.** Unsatisfactory colposcopic finding (UCF); SCJ is not visible.



**Figure 10.** Transformation zone with nabothian follicle.



**Figure 11.** Punctation, grade 3 (P3).



**Figure 12.** Aceto-white epithelium, grade 2 (W2).



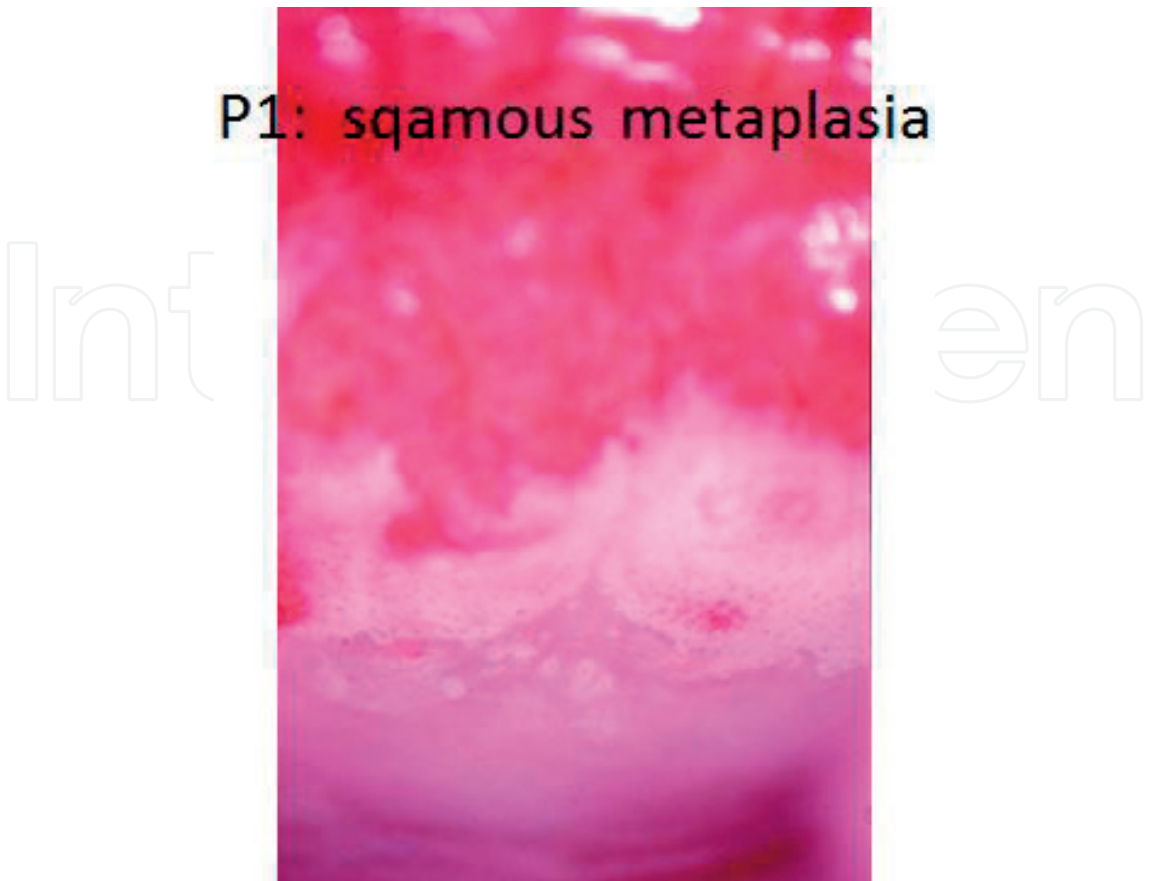

Figure 13. Punctuation, grade 1 (P1) of benign lesion.

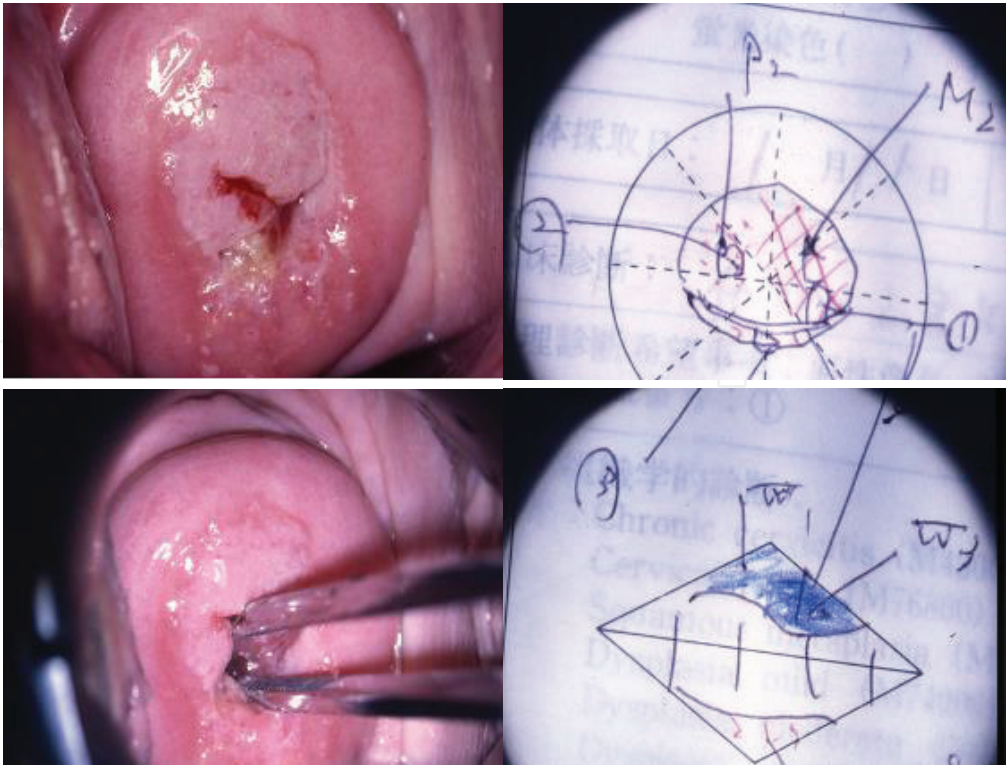
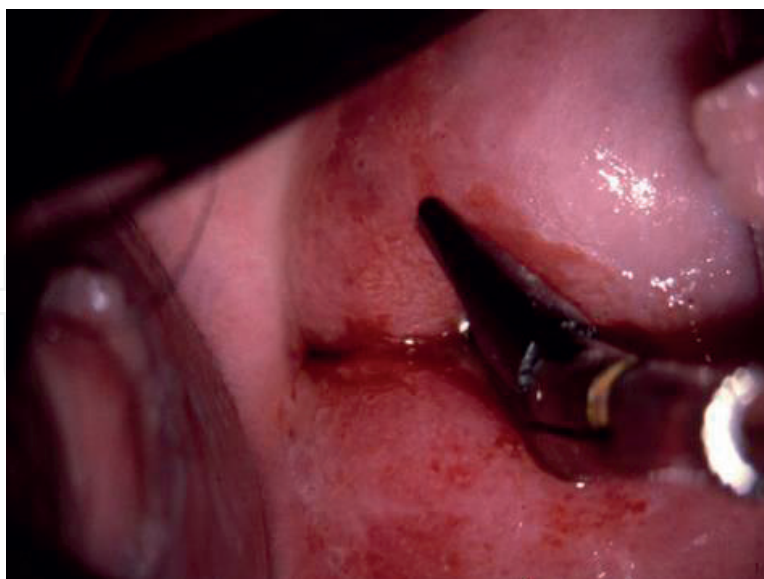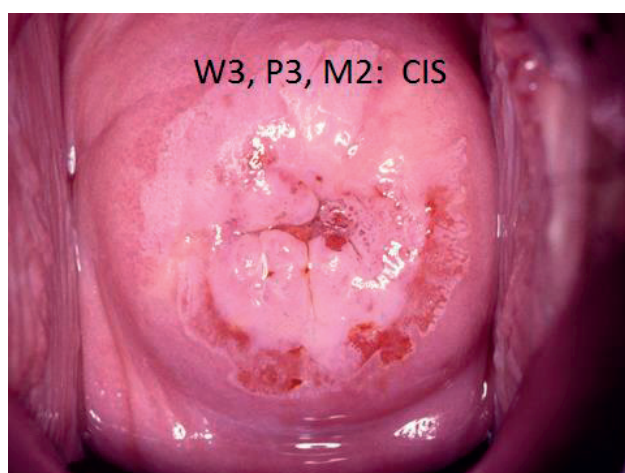


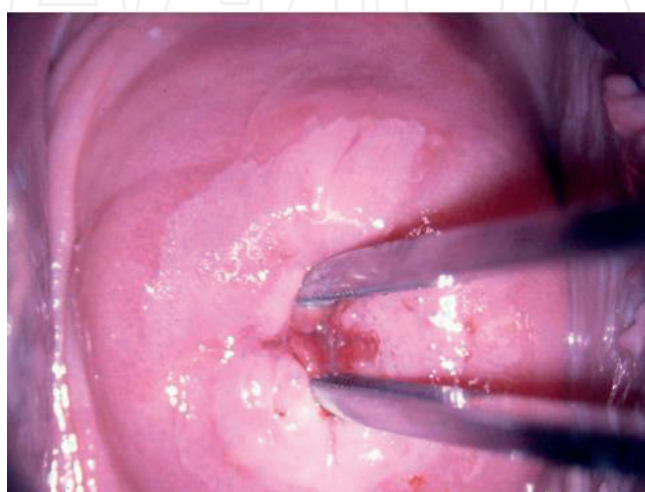
Figure 14. Illustration of colposcopic findings with indicating biopsy points.



**Figure 15.** Colposcopy-guided biopsy, being sniped under colposcopic observation.

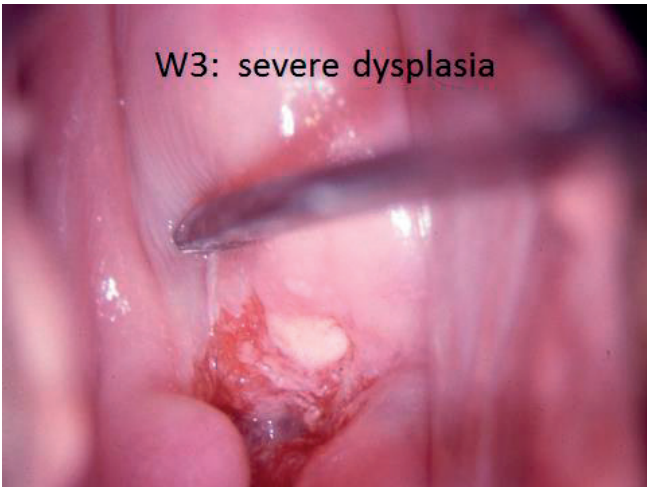

**Figure 16.** Combined ACFs with a large lesion.

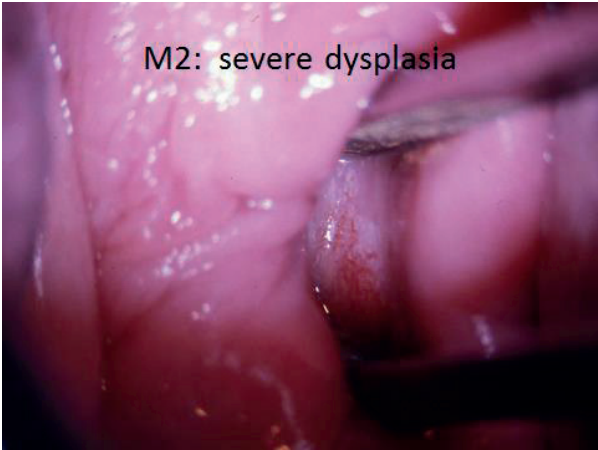

**Figure 17.** Careful inspection in the cervical canal using a forceps is mandatory.

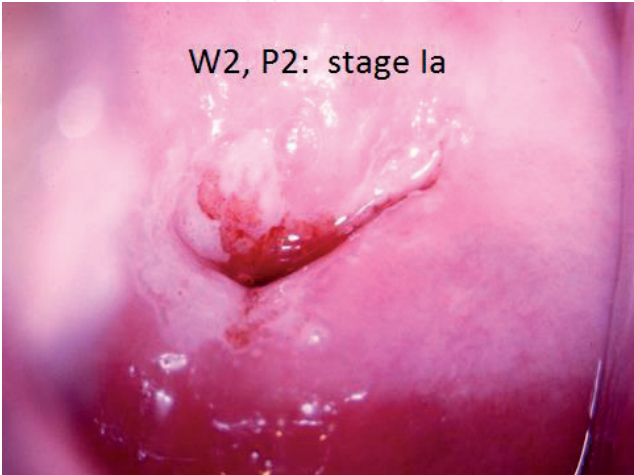



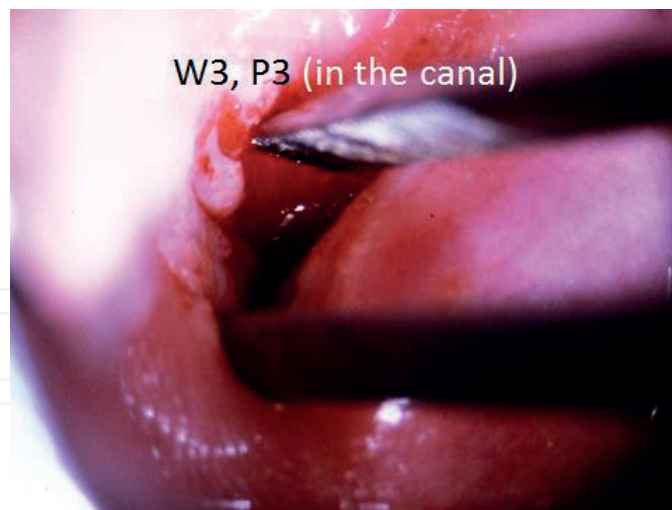**Figure 18.** A lesion with W3, localized in the canal.



**Figure 19.** M2 lesion localized in the canal.



**Figure 20.** W2 and P2 localized both outside and inside the canal.



**Figure 21.** The more significant lesion is located inside the canal.

## Author details

Hiroyuki Kuramoto<sup>1,2\*</sup> and Toshiko Jobo<sup>3,4</sup>

\*Address all correspondence to: [kuramoto@yobouigaku-kanagawa.or.jp](mailto:kuramoto@yobouigaku-kanagawa.or.jp)

1 Department of Cancer Detection for Females, The Kanagawa Health Service Association, Yokohama, Japan

2 Kitasato University, Sagamihara, Japan

3 Gynecologic Oncology Center, (JCHO) Sagamino Hospital, Sagamihara, Japan

4 School of Medicine, Kitasato University, Sagamihara, Japan

## References

- [1] Jobo T, Wakita K, Sasaki N, Hayashi R, Morisawa T, Tsunoda S, Kuramoto H, Arai M. Diagnosis and treatment of dysplasia of the uterine cervix. *Japanese Journal of Cancer & Chemotherapy*. 1989;**16**:1592-1597 (in Japanese)
- [2] Kuramoto H, Ohno E, Jobo T, Hayashi R. An approach to the diagnosis of dysplasia, CIS and stage Ia cancer using cytology and colposcopy. *Obstetrics and Gynecology*. 1984;**51**:1289 (in Japanese)
- [3] Zur Hausen H. Papillomavirus infection: A major cause of human cancers. *Biochemica et Biophysica Acta*. 1996;**1288**:F55-F78
- [4] Wright TC Jr, Massard LS, Dunton CJ, Spitzer M, Wilkinson EJ, Solomon D. 2006 American Society for Colposcopy and Cervical Pathology-sponsored Consensus Conference. 2006

consensus guidelines for the management of women with cervical intraepithelial neoplasia or adenocarcinoma *in situ*. Journal of Lower Genital Tract Disease. 2007;**11**:223. Erratum in: Journal of Lower Genital Tract Disease.2008;**12**:63

- [5] Wight TC Jr. Cervical cancer screening in the 21st century: Is it time to retire the Pap smear? Clinical Obstetrics and Gynecology. 2007;**50**:313
- [6] Bosze P. Colposcopy used in a primary setting (routine colposcopy): Advantages and concerns. European Journal of Gynaecological Oncology. 2006;**27**:5
- [7] Kuramoto H, Sugimoto N, Iida M. Screening for cancer of the cervix with simultaneous Pap smear and colposcopy. The efficacy of Pap smear and colposcopy. European Journal of Gynaecological Oncology. 2010;**32**:73
- [8] Solomon D, Nayar, R, editors. The Bethesda System for Reporting the Cervical Cytology. 2nd ed. New York: Springer; 2004
- [9] Japan Society of Obstetricians and Gynecologists (JSOG). Understanding the Reporting Method of Cervical Cytology Based on the Bethesda System. Tokyo, 2008 (in Japanese)
- [10] Japan Society of Gynecologic Oncology (JSGO). Revised Standard Atlas of New Colposcopy. Chugai-igaku sha, Tokyo, 2014 (in Japanese)