

We are IntechOpen, the world's leading publisher of Open Access books Built by scientists, for scientists

6,900

Open access books available

185,000

International authors and editors

200M

Downloads

Our authors are among the

154

Countries delivered to

TOP 1%

most cited scientists

12.2%

Contributors from top 500 universities



WEB OF SCIENCE™

Selection of our books indexed in the Book Citation Index
in Web of Science™ Core Collection (BKCI)

Interested in publishing with us?
Contact book.department@intechopen.com

Numbers displayed above are based on latest data collected.
For more information visit www.intechopen.com



Unusual Presentations of Adrenal Masses

Santosh Kumar and Shivanshu Singh

Additional information is available at the end of the chapter

<http://dx.doi.org/10.5772/intechopen.69393>

Abstract

With the advancement in imaging technology and pathological evaluation, several unusual adrenal gland lesions have been identified over the years. Presently, the literature consists of case reports or small case series without a comprehensive review on these uncommon adrenal pathologies. The current chapter discusses the epidemiology, pathogenesis, pathology, imaging features and management principles of uncommonly reported infectious and neoplastic adrenal masses.

Keywords: tuberculosis, echinococcosis, myelolipoma, oncocytoma, hemangioma

1. Introduction

The diagnosis of unusual adrenal gland masses over the past years has been facilitated by advances in imaging and molecular histopathology. This chapter of unusual adrenal masses as a result of infection, benign or malignant tumors provides the most comprehensive review and recent information on this topic. The epidemiology, clinical presentation, radiologic and pathologic features of atypical adrenal masses as well as their current management will be discussed.

2. Infections presenting as adrenal masses

The adrenal gland can be infected by several pathogens including bacteria, fungi, viruses and parasites. Infections of the adrenal gland are important, but an underreported clinical entity. Such infections can cause either direct adrenal tissue damage during microbial replication and toxin production or indirect damage through alteration of host's immunologic and endocrine

response to an infection from a distant site. Disparities in pathogen tropism, adrenal anatomy, and host immune integrity contribute to active disease progression and adrenal dysfunction. Timely diagnosis and management of such adrenal infections significantly improves outcome, thereby highlighting the importance of clinical suspicion in the clinic setting [1].

2.1. Adrenal tuberculosis

In one reported series, the incidence of adrenal involvement was 6% of patients with active tuberculosis [2]. Adrenal glands are infected through a hematogenous route [3]. Clinical manifestations may take years to appear while others may have asymptomatic infections. Tuberculosis must be suspected in patients with a fever along with adrenomegaly [4]. At least 90% of the adrenal gland must be involved with parenchymal destruction before clinical features of adrenal insufficiency appear [5]. Stress and inflammation are thought to be underlying reasons for adrenal enlargement in patients with tuberculosis without microbial seeding of the glands. While few studies have demonstrated elevated basal and stimulated cortisol levels [6], others have shown lower cortisol levels [7].

Imaging studies help in the evaluation of affected adrenal glands (**Figure 1**). Most patients with active or recently acquired disease (within 2 years) have bilateral adrenal enlargement, while the remaining with remote infection or inactive disease have calcifications and/or gland atrophy [5, 8]. In one study, 91% of patients with adrenal tuberculosis who underwent CT had bilaterally enlarged adrenal glands, while 2% had normal sized glands. Among those with adrenal enlargement, mass-like lesions were noted in 49% while enlargement with preserved contours was found in the remaining 51% of patients; more than half of them had peripheral rim enhancement. With longer duration of disease, calcifications and contour preservation were seen more frequently, whereas peripheral rim enhancement and mass-like enlargement seen less significantly on CT images [9]. Adrenal glands may also be enlarged in patients with extra-adrenal tuberculosis. Although not needed in cases of extra-adrenal tuberculosis, an adrenal biopsy may be diagnostic in patients with suspected adrenal tuberculosis without extra-adrenal disease [3, 10].

Treatment includes multiple antituberculosis medications. Studies have demonstrated reduction of gland size after successful treatment of extra-adrenal tuberculosis [11]. In patients with adrenal insufficiency, antituberculosis medications do not effectively restore adrenal function after treatment. Furthermore, steroid replacement therapy may need to be increased as rifampicin induces glucocorticoid metabolism in the liver [12].

2.2. Adrenal histoplasmosis

Adrenal involvement is usually found in patients with disseminated histoplasmosis. The clinical, pathologic and radiologic presentation is similar to that of tuberculosis with diagnosis confirmed by adrenal gland biopsy [13, 14]. In one series, primary adrenal insufficiency was reported in 41% of patients [15]. Populations at risk for adrenal histoplasmosis include immunocompromised, posttransplant and elderly patients [16]. CT usually demonstrates bilaterally enlarged adrenal glands, whereas pathologic examination reveals necrotizing granulomas and caseous necrosis. Differential diagnosis of bilateral adrenomegaly includes lymphoma, metastasis, sarcoidosis, adrenal hemorrhage, and infections like tuberculosis, histoplasmosis,

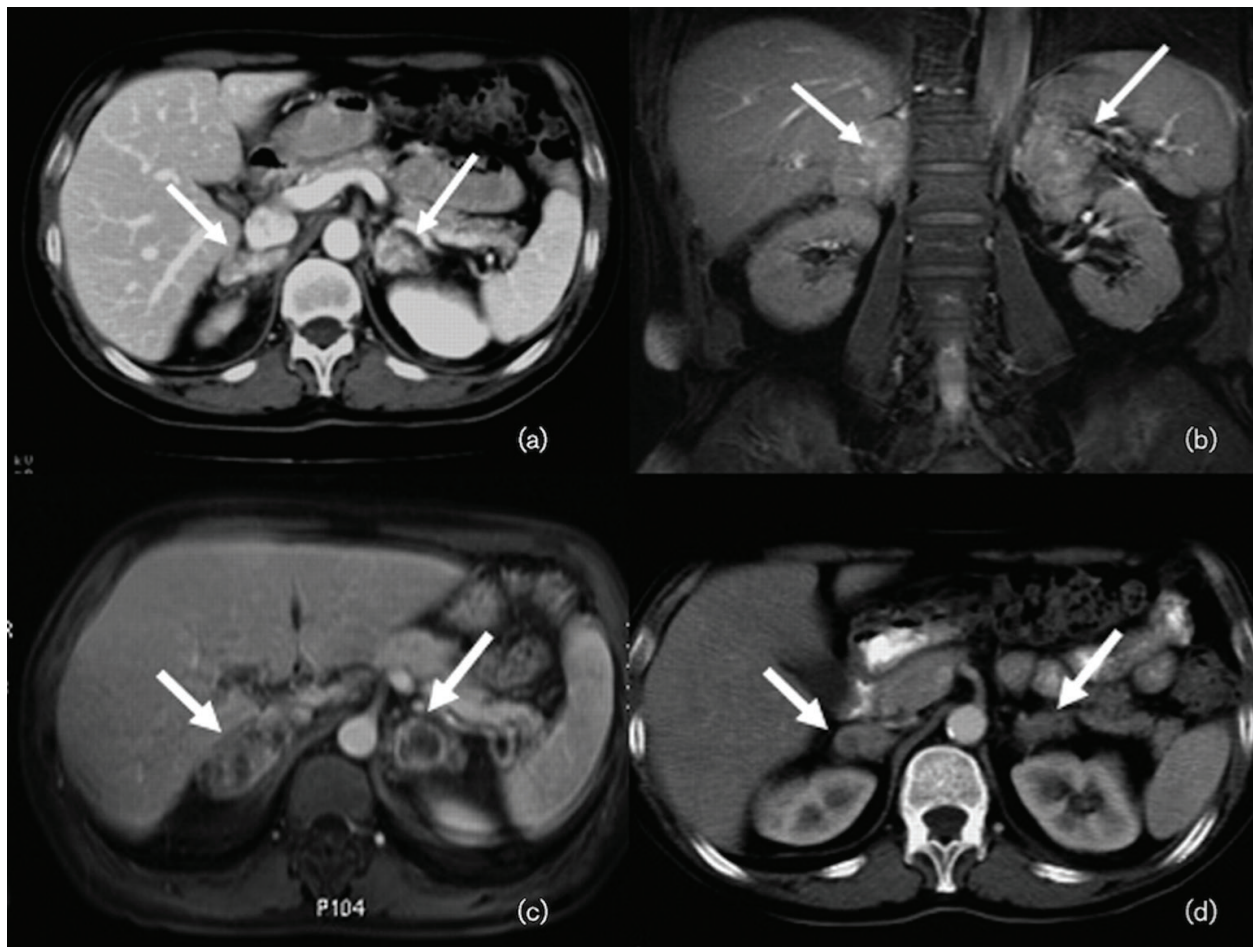


Figure 1. Radiological features of adrenal tuberculosis. (a) Adrenal enlargement with high contrast uptake and rim enhancement demonstrated on CT scan; (b) Adrenal enlargement shown on a coronal FS T1 MRI scan; (c) Adrenal enlargement shown on an axial FS T1 MRI scan; (d) Significant reduction of the volume of the adrenal glands with no pathological contrast uptake on a CT scan after treatment. (Courtesy: Ref. [4].)

cryptococcosis, coccidioidomycosis and blastomycosis. However, central hypodensity and peripheral rim enhancement of the adrenal glands by CT narrows the differential diagnosis to histoplasmosis and tuberculosis only [17]. Recommended antifungal therapy includes amphotericin B followed by itraconazole (for disseminated disease), and glucocorticoid and mineralocorticoid replacement for adrenal insufficiency.

2.3. Adrenal cryptococcosis

Cryptococcal infections most commonly present as pneumonia or meningitis with adrenal glands only usually involved in immunocompromised patients with disseminated cryptococcal infection [18]. However, cases of isolated adrenal gland involvement have been reported [19]. CT can demonstrate enlarged adrenal glands [20], and diagnosis is confirmed by a biopsy that shows budding yeasts with capsules on smear examination with India ink or methenamine silver stain (**Figure 2**). In most cases, cryptococcal antigen titers are elevated and used as a biomarker for disease resolution [21]. Intensive Amphotericin B therapy followed by oral fluconazole consolidation (usually 6-month course) is an effective multidrug treatment regimen

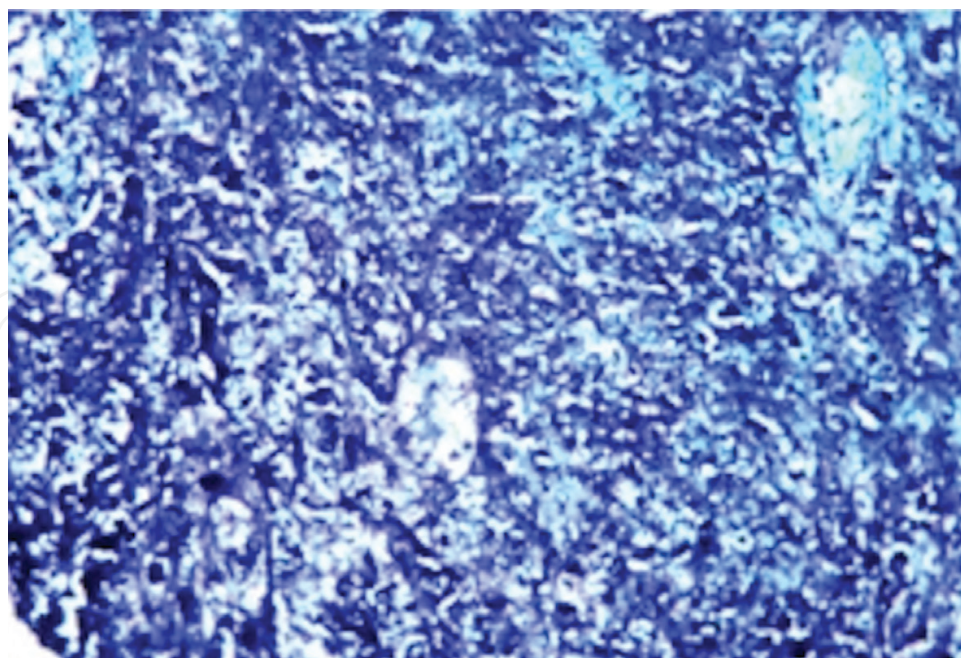


Figure 2. Microscopic examination of cryptococcal infection. Methenamine silver stain shows the yeast, some of which demonstrate budding (40x). (Courtesy: Ref. [22].)

[22, 23]. In contrast to adrenal tuberculosis and histoplasmosis, adrenal insufficiency is often improved with resolution of this infection. Adrenal cryptococcal infection resistant to antifungal therapy may respond to adrenalectomy [24].

3. Parasitic infections of the adrenal glands

Parasitic infections of the adrenal glands are rarely reported, and their prevalence depends on the organism, residence in endemic areas and host immune integrity [1]. The nature of adrenal gland involvement varies significantly depending on the microbe. Case reports have shown adrenal involvement with a wide range of pathogens that includes *Echinococcus*, *Leishmania*, *Trypanosoma*, *Microsporidia* and amebic species.

3.1. Adrenal echinococcosis

Echinococcal infections of the adrenal glands are uncommon, accounting for 6–7% of all cysts [25–27]. Adrenal involvement is usually secondary, and part of generalized echinococcosis [25, 28]. Most cases are discovered incidentally, although some cases present with nonspecific dull aching flank pain [29]. Adrenal hydatids can cause hypertension, known as “the Goldblatt phenomenon”, due to irritation of functional tissue of the adrenal gland by the growing cyst [30].

Imaging studies are helpful in characterizing infected adrenal cysts, and ultrasonography (US) is particularly helpful in securing the diagnosis. US of the adrenal cyst can demonstrate location, size and number along with cyst features that include floating membranes, daughter cysts, multiple septa and hydatids. The WHO/IWG-E classification for diagnosis and treatment

of echinococcal cysts is based on US imaging characteristics that classify cysts into six subtypes (CL, CE1 to CE5) and three relevant groups: active (CE1 and 2), transitional (CE3) and inactive (CE4 and 5) [31]. On CT, unilocular or multilocular cysts are identified with debris, calcified walls, small daughter cysts and increased tissue density of hydatid membrane, which shows contrast enhancement [32]. CT provides information regarding the cyst number, origin and residual parenchyma of the affected organ, and relationship of the cyst with adjacent structures. Serological tests are marred by low sensitivity and specificity. Latest immunodiagnostic tests detect echinococcal antigens in hydatid fluid fraction. These tests detect *Echinococcus granulosus* antigen 5, *E. granulosus* antigen B (AgB), and EpC1. AgB8/2 antigen has shown maximum diagnostic sensitivity (84–93%) and specificity (98–99%) [33, 34]. Serology is helpful in continued patient monitoring as titers decrease following definitive therapy [35].

Multiple therapeutic options include medical therapy, percutaneous intervention, open and minimally invasive laparoscopic and robotic surgeries. Surgical excision usually results in definitive cure. Medical therapy is usually implemented as an adjunct to surgical excision. Antiparasitic medications as primary treatment is recommended for cases with disseminated hydatidosis, brain or bony echinococcosis or in patients with poor surgical risk [32]. Preoperative oral therapy with albendazole (10–15 mg/kg per day) with or without praziquantel (50 mg/kg) for 4 weeks before surgery may kill scolices, make the cyst inactive, decrease cyst material antigenicity, reduce cyst wall tension and thereby reduce the risk of spillage [26]. In liver echinococcosis, studies have shown a lower risk of recurrence following surgery in cases that had received preoperative albendazole versus those who did not (4 vs. 19%), respectively [36]. Limitations of medical therapy include serious drug-related adverse effects such as leukopenia, hepatotoxicity, allergic reactions and alopecia [37], and limited experience in its use in genitourinary echinococcosis.

Surgical management involves adrenal hydatid cyst excision by laparoscopic or open techniques [29]. It is difficult to determine whether complete excision of adrenal is mandatory as data is limited. In a series of nine cases, adrenalectomy was performed in patients with adrenal cysts with no recurrence at a median follow-up of 16 months (range: 6–64 months) [25]. In another study, transperitoneal laparoscopic aspiration with instillation of scolicidal agent with partial cystectomy for an adrenal hydatid cyst was performed (**Figure 3**). The cyst densely adhered to the renal vessels and complete excision involved risk of nephrectomy. Betadine soaked gauze pieces were packed around the cyst. The cyst was aspirated followed by instillation of scolicidal agent that was maintained for 10 min. A 10-mm trocar was introduced into the cyst, and its contents, including the germinal layer, were suctioned and followed by partial cyst wall excision. No recurrence was noted at 6-months follow-up. The authors concluded that total adrenal gland excision may be needed only in cases with complete gland destruction [38]. Complete evacuation of cyst contents and prevention of viable scolices spillage intraperitoneally remains a key principle in the management of adrenal hydatid cysts.

3.2. Other adrenal infections presenting as cysts/masses

Visceral leishmaniasis can present with cystic adrenal disease in both immunocompetent and immunocompromised individuals [39, 40]. Rarely, amebic species have been found in cystic lesions of the adrenal gland [1]. *Trypanosoma cruzi*, the causative agent of Chagas disease, has

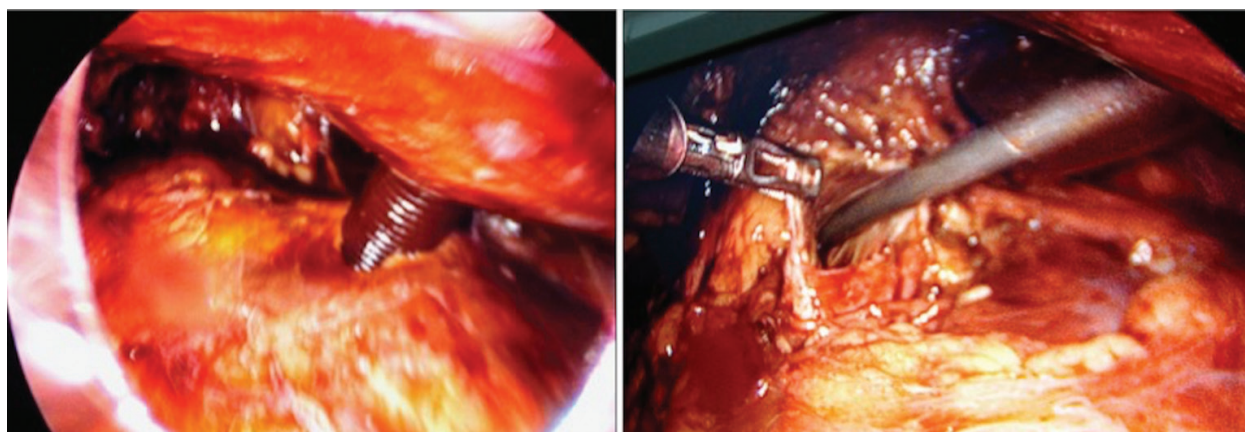


Figure 3. Laparoscopic management of adrenal hydatid cysts. Intraoperative photograph showing cyst aspiration by directly inserting a trocar into the cyst and laparoscopic cyst dissection after aspiration. (Courtesy: Ref. [38].)

been found in infected adrenal glands, which may serve as a reservoir. Investigators have found a correlation between central vein infection of the adrenal gland and development of chagasic myocarditis [41]. African trypanosomiasis has been found to be associated with polyendocrinopathies including hypothyroidism, hypogonadism and adrenal insufficiency resulting from either primary gland or secondary (central) involvement. In a series of 137 patients, adrenal and thyroid function recovered with medical treatment, but hypogonadism tended to persist for years [42]. Two drugs, benznidazole, and nifurtimox are available for treatment of *T. cruzi* infection. However, both benznidazole and nifurtimox are limited in their capacity to provide a parasitologic cure, especially in chronically infected patients [43]. Adrenal involvement from disseminated microsporidia in immunocompromised patients induces large necrotic lesions with histiocytic and fibrotic reactions within the gland substrate [44].

HIV infection affects the adrenal gland in several ways. Apart from direct infection, opportunistic infections and antiretroviral medications also have a significant effect on adrenal glands that can lead to adrenal insufficiency. Cases with HIV infection can harbor adrenal tumors like Kaposi's sarcoma secondary to co-infection with oncogenic human herpesvirus type 8 (HHV8), and non-Hodgkin's lymphoma (high-grade malignant B phenotype) secondary to Epstein-Barr virus (EBV) infection [45, 46].

4. Adrenal tumors

This section describes uncommon benign and malignant adrenal tumors and current concepts in their management.

4.1. Adrenal leiomyoma

Leiomyoma of the adrenal glands is extremely rare tumors with less than 20 cases reported in the literature [47]. Although benign tumors, they may mimic malignant adrenal tumors on

radiologic imaging. Age at presentation in patients ranges from 2 to 72 years with 61% usually occurring in women. Tumor size varies from 3 to 11 cm in diameter [48]. Usually asymptomatic and nonfunctional, such tumors present as adrenal incidentalomas and occasionally as calcified masses [49]. Some patients may present with vague, nonspecific flank or upper abdominal pain. Many cases of adrenal leiomyomas have been reported to occur in patients with acquired immune deficiency syndrome (AIDS), or latent Epstein-Barr infection [48, 50]. Associated smooth-muscle tumors and Kaposi's sarcoma may arise from a common stem cell under the influence of some unknown factor produced during HIV infection [51]. Grossly, cut sections often demonstrate a whorled appearance. Light microscopy shows spindle-shaped cells arranged in fascicles and whorls (**Figure 4**) [47]. Immunohistochemistry helps in establishing a diagnosis as the tumor cells show diffuse and strong positivity for smooth muscle actin [52]. Prognosis is good following complete surgical resection. With the advent of minimally invasive surgery, laparoscopic resection is feasible with good perioperative outcomes [49]. Large tumors, however, do pose challenges for adjacent vital organ preservation during surgical resection.

4.2. Inflammatory myofibroblastic tumor (IMT)

Inflammatory myofibroblastic tumor (IMT) was first described in 1939. Previously known as plasma cell granuloma or inflammatory pseudotumor, the term "inflammatory myofibroblastic tumor" was introduced in 1986 [53–55]. Although found in the adrenal glands, the most common site of IMT is the lung followed by the orbit [55].

Cytogenetic and molecular advancements have confirmed the neoplastic nature of IMT and their recurrence potential [56, 57]. They exhibit cytogenetic clonality, the involvement of chromosomal region 2p23, occasional aggressive local behavior, and metastasis described in most locations, in both sexes and at all ages [58, 59]. Mean tumor size at the time of presentation ranges from 5 to 10 cm. IMT usually present as an adrenal incidentaloma, although 10–20% of

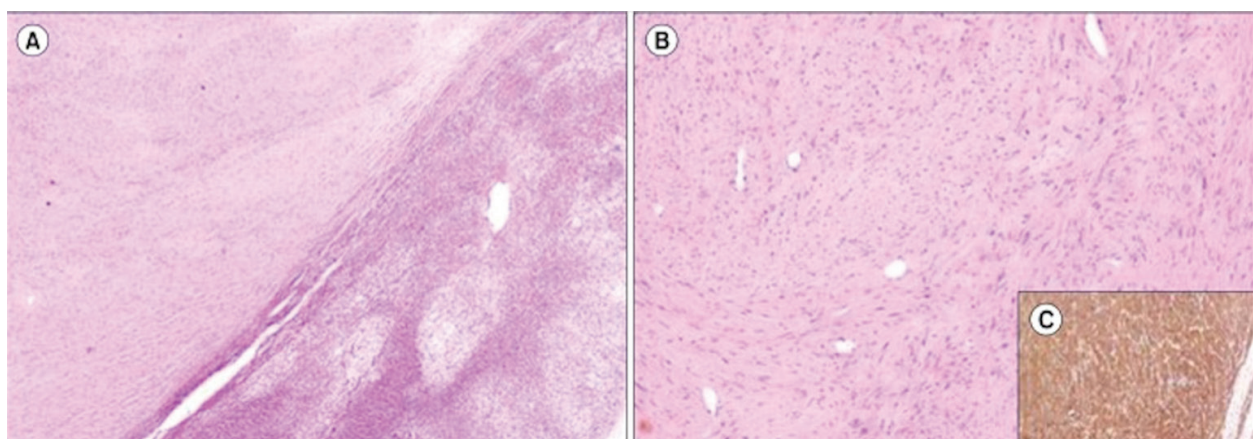


Figure 4. Histopathologic images of adrenal leiomyoma. (A) Normal adrenal gland seen at the periphery with encapsulated tumor arranged in long and short fascicles (H&E, ×40). (B) Higher magnification showing fascicles of benign spindle-shaped cells with minimal nuclear atypia (H&E, ×200). (C) Neoplastic cells showing strong positivity with smooth muscle actin (immunoperoxidase, ×200). (Courtesy: Ref. [49].)

patients have a fever, weight loss or flank pain [60]. These lesions do not demonstrate specific imaging features [60]. Enhanced CT may show heterogeneity or homogeneity of a hypo-, iso- or hyperdense adrenal mass [61].

Grossly, IMT appears firm, fleshy or gelatinous with a white or tan cut surface. Few may also demonstrate calcification, hemorrhage, and necrosis [59]. Histopathology reveals plump fibroblast or myofibroblast proliferation along with prominent infiltrate of chronic inflammatory cells, especially plasma cells. The presence of these plasma cells helps distinguish these adrenal tumors from fibromatosis and fasciitis. The epithelioid variant of IMT is rare with an aggressive clinical course [62]. Histologic markers of aggressive behavior include the presence of ganglion-like cells, cellular atypia, aneuploidy, and p53 overexpression [63]. On immunohistochemistry, these adrenal tumors usually express actin with occasional positivity for desmin and keratin. Thirty to 40% of tumors have ALK protein overexpression as a result of ALK gene rearrangement. Clinical correlation has shown that most patients with tumor metastasis were negative for ALK overexpression [64].

Complete surgical resection is essential since malignancy cannot be excluded preoperatively. Ten to 25% of patients have been reported to have a local recurrence following complete surgical excision. These tumors are considered to be low-grade sarcomas with less than 5% incidence of metastasis. Nevertheless, their biological behavior cannot be predicted based on their morphologic appearance [60].

4.3. Primitive neuroectodermal tumors (PNETs)

Primitive neuroectodermal tumors (PNETs) are associated with a family of small round cell tumors. Initially described a century ago by Arthur Stout in a 42-year male with an ulnar nerve tumor, it was not until 1973 when Hart and Earle coined the term “primitive neuroectodermal tumor” for such unspecialized small round cell tumors [65, 66]. PNETs are classified as central (arising from the central nervous system) and peripheral [67]. Peripheral PNETs that arise from the adrenal glands are extremely rare with less than two-dozen cases reported in the literature. They usually present as a large (>10 cm), nonfunctioning adrenal mass often associated with abdominal pain and metastasis. These solid and/or cystic lesions can rapidly grow and are difficult to differentiate from adrenocortical carcinoma (ACC) radiologically [67, 68]. CT can show irregular bordered, diffusely growing, and unevenly enhancing adrenal masses [67].

Both PNETs and Ewing’s sarcoma share a unique translocation “t(11;22)(q24q12): fusion gene designated EWS/FLI-1” [69]. FLI-1 is a member of ETS family of transcription factors [69]. Microscopic examination along with immunohistochemistry helps establish the diagnosis. On light microscopy, classic features include small round cell tumors arranged in nests/rosettes (**Figure 5**). These cells have little endoplasm with dark stained nucleus high in nucleoplasm [67]. Among all the markers, Mic-2 (CD-99) is the most sensitive and specific marker (nearly 100%), which is a cell surface glycoprotein coded by genes on X and Y-chromosomes [70]. Other common markers of neural differentiation include neuron-specific enolase (NSE), S-100 protein, neurofilaments, synaptophysin (Syn), chromogranin A (CgA) and vimentin. The most reliable findings for pathologic diagnosis of PNETs are the existence of rosettes, and two or more positive results of the aforementioned neural markers [67, 71–73].

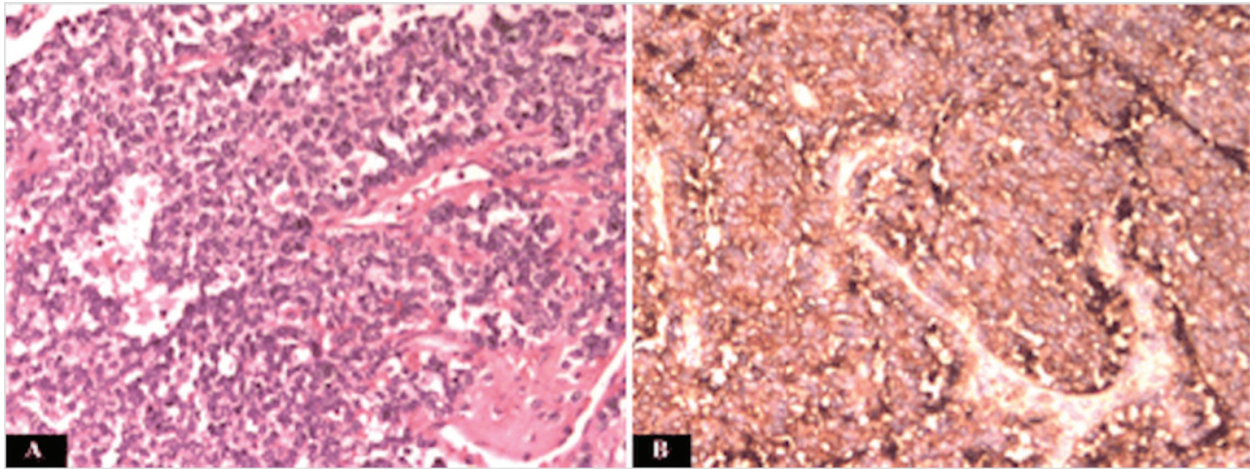


Figure 5. Microscopic picture of adrenal primitive neuroectodermal tumor. (A) Hematoxylin and eosin stains for adrenal primitive neuroectodermal tumor (20×). (B) CD99 Immunohistochemical stains for adrenal primitive neuroectodermal tumor (20×). (Courtesy: Ref. [67].)

Since adrenal PNETs are an uncommon clinical entity, an effective treatment protocol is not yet established. Surgical excision remains the mainstay for local disease control. Adrenalectomy is usually followed by adjuvant radiochemotherapy [74]. A recommended regimen is the alternating use of CAV (cyclophosphamide: CTX; adriamycin: ADM; and vincristine: VCR), and IE (ifosfamide: IFO; and etoposide: ETO) protocols as PNET rapidly develop resistance to a particular regimen [75]. In general, 5-year survival of patients with PNETs is 58–61% with a median survival of 120 months. Local or distant metastasis at the time of diagnosis is associated with poor outcome [70].

4.4. Adrenal oncocytoma

Adrenal oncocytomas are rare tumors. Although considered benign and nonfunctional, these adrenal masses are malignant in 20% and hormonally active in 10–20% of patients [76]. Adrenal oncocytomas have been described in a wide age group (27–72 years) and usually discovered as incidentalomas [77]. Women are more commonly affected [78] with a predominance of the left adrenal gland (3.5:1) [79].

Such adrenal tumors are classified as either benign, borderline malignant potential or malignant using the Lin-Weiss-Bisceglia system that includes the major criteria of high mitotic rate > 5 per 50 HPF, atypical mitoses, venous invasion; and minor criteria that include large size and weight, necrosis, capsular invasion, sinusoidal invasion [80]. The presence of one major criterion indicates malignancy, and one to four minor criteria indicates uncertain malignant potential. The absence of all major and minor criteria indicates a benign adrenal tumor.

Microscopically, tumor cells have abundant eosinophilic granular cytoplasm due to the accumulation of mitochondria with a central pyknotic nucleus [81]. They may be arranged in trabecular, tubular, papillary or solid patterns. The classic central stellate scar of renal oncocytoma may not be seen. Immunophenotyping, in general, reveals diffuse positivity for vimentin, melan-A, synaptophysin and alpha-inhibin [82].

Due to its large size and lack of characteristic preoperative imaging features for benignity, surgical resection remains the principal management for adrenal oncocytomas [79]. Surgical excision is a challenging task in giant adrenal oncocytomas (**Figure 6**). Although not infiltrating, the large size of these tumors can alter the orientation and position of adjacent viscera and major blood vessels. *En bloc* mobilization of spleen, stomach, and pancreas helps provide optimum exposure for large left-sided adrenal oncocytomas [83].

4.5. Adrenal myelolipoma

First described in 1905, adrenal myelolipoma is a rare adrenal tumor with a prevalence of <1% in autopsy series [84]. These adrenal tumors have an overall incidence of 0.05–0.2%, and account for about 2.5–5% of all adrenal incidentalomas. Both women and men are equally affected, and they are usually unilateral and rarely arise from extra-adrenal sites such as the retroperitoneum, thorax, and pelvis [85]. Symptomatic patients may present with abdominal pain or uncommonly with massive hemorrhage and shock, or with fever and abscess [85]. Tumor size varies widely from a few centimeters to >30 cm [84]. Although the tumor is metabolically inactive, there is a 10% incidence of associated endocrine disorders such as Cushing's and Conn's syndromes, congenital adrenal hyperplasia and diabetes [86].

These adrenal lesions are also rarely associated with thalassemia and sickle cell anemia [87, 88]. For reasons not yet understood, myelolipomas in patients with thalassemia are usually giant and bilateral. Such association might be due to excess erythropoietin production [89]. Various mechanisms have been proposed regarding its pathogenesis. These tumors are

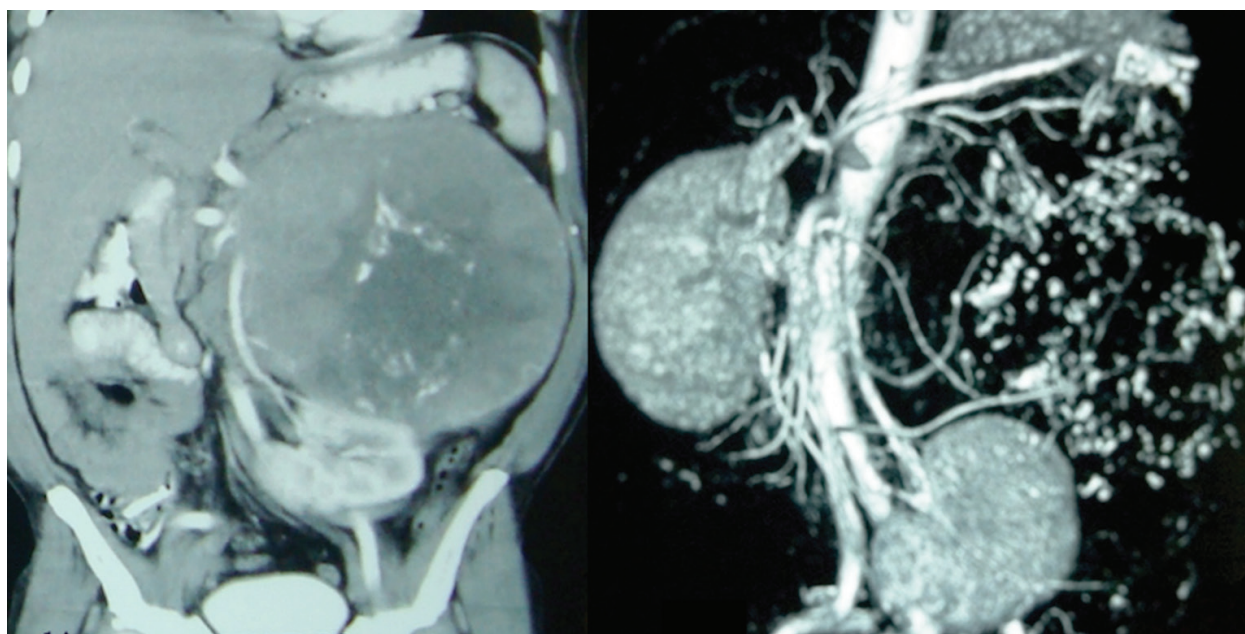


Figure 6. CT in preoperative planning in case of giant adrenal oncocytoma. Coronal section of contrast enhanced CT demonstrating a giant left adrenal oncocytoma with left kidney lying in transverse plane at iliac crest. The left renal vessels are stretched over the inferolateral aspect of the adrenal mass. CT-angiography shows multiple feeding vessels to the tumor.

believed to arise from metaplasia of reticuloendothelial cells of blood capillaries within the adrenal glands in response to inflammation, necrosis, infection, or stress [84]. Studies have shown nonrandom X-chromosome inactivation in hematopoietic lineage and fat cells, and balanced translocations between 3q25 and 21p11 suggestive of clonal origin [90, 91]. Tumor tissue consists of an admixture of mature adipose tissue, normal trilineage hematopoietic elements, and an overabundance of megakaryocytes. Unlike normal bone marrow, their cellularity varies widely that does not decrease with advanced age. These lesions do not contribute to hematopoietic cells in circulation due to stromal irregularities and lack of capillary venous sinuses [90]. In most cases, this diagnosis can be made accurately on cross-sectional imaging. CT demonstrates a well-circumscribed lesion with a variable amount of mature adipose tissue with low attenuation value (around -30 Hounsfield units) with higher density myeloid component that enhances on contrast administration (**Figure 7**). Nearly one-fourth of cases have calcifications while many have hemorrhagic areas [85]. Rare differential diagnoses include adrenal lipomas, teratomas, liposarcomas, metastasis and upper polar renal angiomyolipoma. Percutaneous biopsy may be helpful when the diagnosis is in doubt [92].

Surgical resection is the mainstay of definitive treatment; however, it is reserved for symptomatic or large adrenal myelolipomas. Small and asymptomatic adrenal lesions can be followed as they remain stable or even decrease in size over long periods of time [92]. In one study, the calculated doubling time of adrenal myelolipomas ranged from 4.6 to 95.1 months (mean 31.9 months) that confirmed the relatively slow growing nature of these tumors [93]. Spontaneous rupture of these lesions is a rare event and usually, occurs in lesions > 10 cm [94].

4.6. Adrenal schwannoma

Schwannomas are benign, well-encapsulated tumors arising from the nerve sheaths of cranial and peripheral nerves [95]. Initially described by Verocay and later subclassified by Antonini

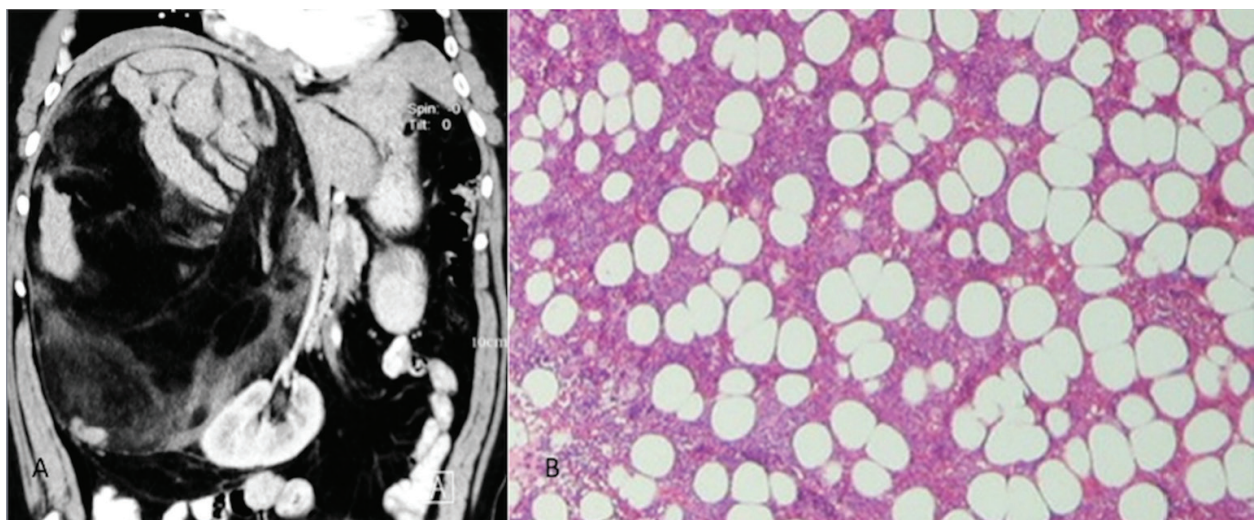


Figure 7. Adrenal myelolipoma. (A) Enhanced CT abdomen showing a 35 × 19 cm right suprarenal mass with areas of macroscopic fat densities (-19 HU) along with focal areas of enhancement. (B) Histopathology showing mature adipocytes admixed with hematopoietic cells suggestive of myelolipoma.

in 1920, they account for 1–5% of all retroperitoneal tumors [96, 97]. Adrenal schwannomas are very rare and restricted to a few case reports. In the adrenal glands, these tumors are believed to arise from Schwann cells surrounding the nerves innervating the adrenal medulla [98]. They may present either as incidentalomas or with abdominal pain. Nonfunctional by nature, positive biochemical evaluation of an adrenal incidentaloma excludes the diagnosis of a schwannoma [96]. CT scan reveals a well-circumscribed, homogeneous, round-oval mass with calcification or cystic degeneration [99]. MRI findings are nonspecific and demonstrate solid tumors with low signal intensity on T1WI and heterogeneously high intensity on T2WI [100]. 18FDG–PET is helpful in differentiating benign from malignant adrenal masses based on standardized uptake value (SUV) [101].

Treatment of choice for adrenal schwannomas is complete surgical excision. Histologic examination reveals characteristic Antoni α and Antoni β areas seen under the microscope, and also nuclear free zones known as Verocay bodies that confirm the diagnosis of Schwannoma. The role of immunohistochemical markers including S-100 and vimentin cannot be overlooked as they are used for final confirmation in addition to the typical pattern described above [97, 98]. They also stain positive for laminin and collagen IV, and negative for desmin, keratin, actin, CD34 and CD117 [97]. A positive stain for calretinin is helpful in differentiating Schwannoma from neurofibroma [102]. Although prognosis is usually good following complete surgical resection, the possibility of local recurrence and malignant formation in benign Schwannomas does remain [103].

4.7. Adrenal ganglioneuroma

Adrenal ganglioneuromas are extremely rare benign neuroectodermal tumors composed of ganglion and Schwann cells [104]. These tumors are predominantly found in younger populations with 50% of patients between 10 and 29 years of age [104]. Although benign, isolated case reports of ganglioneuroma undergoing malignant transformation, cases of peripheral nerve sheath tumors arising within ganglioneuromas, and composite tumors of ganglioneuroma with pheochromocytoma have been reported in the literature [104, 105]. Most ganglioneuromas are asymptomatic, however, some patients with these tumors may present with diarrhea as they have been reported to secrete vasoactive intestinal polypeptide (VIP) [104, 105]. These tumors can grow to large size with blood vessel encasement without compromising the vascular lumen [105]. The biologic and radiologic features that should raise the suspicion of ganglioneuroma include: no adrenal hormone hyperactivity; presence of punctuate calcifications, no vascular involvement, nonenhanced CT attenuation of <40 Hounsfield units (HU); a homogeneous, hypointense mass on T1-weighted MRI; heterogeneous, hyperintense adrenal mass on T2-weighted MRI; and poor, delayed enhancement on dynamic MRI [106]. Histopathology reveals mature ganglion cells and Schwann cells among a fibrous stroma. Complete surgical resection of these adrenal masses is the treatment of choice. Although adrenal ganglioneuromas may encase major vessels at the time of surgery, organ preservation is feasible, as these tumors do not infiltrate them [107].

4.8. Adrenal lipoma

Adrenal lipomas are rare adrenal masses with the majority predominantly occurring in men with a range from 35 to 78 years of age [108]. These lesions account for 0.7% of all lipomatous

adrenal tumors [109]. These tumors are more common on the right side with a size ranging from 1 to 20 cm [110]. Although usually asymptomatic, patients with larger tumors may experience abdominal pain whereas few patients may present with an acute abdomen due to retroperitoneal bleeding [111], and a smaller minority with hypertension [112]. These adrenal masses are thought to arise from metaplasia of either stromal or adrenal cortical cells [113]. CT demonstrates a well-defined adrenal lesion with fat densities without enhancing hematopoietic tissue as seen in myelolipomas. Microscopic examination reveals well-demarcated lesions composed of mature adipose lobules with occasional focal areas of calcification due to degenerative changes [113]. Surgical excision is curative. Although the laparoscopic approach is preferred, it is difficult to perform in giant adrenal lipomas and those complicated by rupture, bleeding or sarcomatous changes [114].

4.9. Cystic pheochromocytoma

Cystic pheochromocytomas are rare adrenal masses thought to arise as a result of bleeding, necrosis, and liquefaction within solid pheochromocytomas. Patients with such adrenal lesions are more likely to be asymptomatic with occasional nonspecific abdominal symptoms and may have a normal biochemical profile when compared to solid tumors [115, 116]. CT often reveals a thick walled cystic lesion with presence or absence of septa within the adrenal mass, and persistent wall enhancement after contrast administration [115]. Surgical excision is the most definitive treatment of pheochromocytomas regardless of whether the tumor is cystic or not [117]. It is essential to consider this diagnosis in the differential as normotensive patients with unsuspected cystic pheochromocytoma have been reported to have intraoperative hypertensive crises during surgical excision [118].

4.10. Adrenal plasmacytoma (extramedullary plasmacytoma)

Extramedullary plasmacytoma (EMP) is defined as an extraosseous proliferation of neoplastic plasma cells. These adrenal tumors are cytogenetically identical to plasma cell myeloma but occur as isolated lesions [119]. Solitary EMP of the adrenal glands is extremely rare with fewer than a dozen cases reported in the literature. These adrenal masses usually occur in men than women (3:1) within the age range of 50–60 years [120]. The most common site of solitary EMP is the head and neck region followed by the gastrointestinal tract [121]. Although plasma cell proliferation caused by trauma might ultimately lead to clonal cell infiltration, pathogenesis of such tumors remains unclear [122]. Preoperative imaging of these lesions has heterogeneous hyperintensity on T2-weighted images.

Definitive diagnosis of adrenal plasmacytoma is based on the pathologic confirmation of a solitary plasma cell tumor, with or without a monoclonal gammopathy, and the absence of plasma cell myeloma on bone marrow biopsy [119]. Pathologic examination reveals dense and diffuse infiltrate of atypical plasma cells with very few admixed lymphocytes. Immunohistochemistry shows monoclonal immunoglobulin light chain expression. The diagnosis of solitary EMP can be confirmed after excluding systemic disease by serum and urine protein electrophoresis, immunoelectrophoresis, skeletal imaging survey, and bone marrow biopsy. Staging bone marrow biopsy is essential to exclude plasma cell myeloma [121].

A standard treatment protocol has not been established for adrenal EMP. In cases with solitary lesions, complete surgical resection with or without radiotherapy has been reported with good outcomes in term of disease-free status [122–124]. In one report, bilateral adrenal EMP was treated by chemotherapy and autologous hematopoietic stem cell transplantation with no recurrence at 47 months follow-up [125].

4.11. Non-Hodgkin lymphoma (NHL) of adrenal glands

Primary adrenal lymphoma is defined as a malignant neoplastic proliferation of lymphoid cells exclusively within the adrenal tissue. The adrenal glands are involved in up to 24% of patients with disseminated lymphoma [126]. Isolated primary adrenal lymphoma is rare, and constitutes 3% of extranodal lymphoma [127]. Bilateral adrenal involvement is reported in 70% of patients [128]. Most cases are found in the elderly with a male to female ratio of 2:1. The most common subtype found in the adrenal glands is diffuse large B-cell lymphoma [126]. Multi-agent chemotherapy that includes cyclophosphamide, hydroxyl-doxorubicin (adriamycin), vincristine (oncovin), and prednisolone (CHOP) along with rituximab for CD20 positive cases represents the cornerstone of management [129]. When an isolated adrenal mass, diagnosis is usually made following adrenalectomy. However, adjuvant chemotherapy is given to prevent disease recurrence [126]. Prognostic factors that include age, elevated serum lactate dehydrogenase, adrenal insufficiency and tumor size may have a significant impact on treatment outcome and survival. Prognosis for patients has slightly improved with recent chemotherapeutic agents. Although a median survival of nearly 3 months was previously reported [130], most recent data in the literature suggests disease free status of 12 months [126].

4.12. Adrenal hemangioma

Adrenal hemangiomas are rare benign tumors. These lesions arise from the endothelial cell lining of blood vessels. Adrenal hemangiomas are believed to be congenital in origin with enlargement of >10 cm at the time of presentation as a result of vascular ectasia [131]. They are usually detected in 6 to 7th decade of life. Women are twice more commonly affected than men, and most cases occur unilaterally [132]. Patients are usually asymptomatic, although spontaneous life-threatening hemorrhage from adrenal hemangiomas has been reported [133]. Cases of bilateral adrenal hemangioma can also occur [134]. CT reveals heterogeneous, hypodense lesions with a high-density rim of tissue at the periphery [131]. Contrast-enhanced CT scans show peripheral spotty contrast with centripetal enhancement; this enhancement pattern is pathognomonic for hemangiomas. Certain patterns of calcification have also been reported, and include either speckled calcifications throughout the lesion or centrally located calcifications with an irregular, stellate branching pattern [135]. MRI reveals marked hyperintensity on T2-weighted images and focal hyperintensity on T1-weighted images with focal areas of hemorrhage [136]. Pathologic examination reveals multiple dilated vascular channels lined by single layer of endothelium with areas of hemorrhage, necrosis, and calcification [131]. Tumor size and symptoms help determine the need for surgical intervention in patients where characteristic imaging features make the diagnosis of adrenal hemangioma; lesions < 3.5 cm can be safely observed by serial imaging studies [137]. Surgical excision is recommended for larger lesions, symptomatic patients or in those patients where imaging features are atypical.

5. Surgical excision of giant adrenal tumors

Since the adrenal glands are situated in the retroperitoneum, various vital organs lie in close vicinity. Giant benign adrenal tumors pose challenges for safe surgical resection with preservation of vital organs such as kidneys, spleen, mesenteric and great vessels. One such technique is *en bloc* mobilization of the pancreas and spleen for large left adrenal masses derived from multi-visceral transplantation techniques [83]. Prompt recognition and management of vascular injury can prevent catastrophe. In a case report of a giant left adrenocortical carcinoma where the superior mesenteric artery (SMA) was injured due to anatomical distortion, prompt recognition followed by end-to-end anastomosis salvaged the SMA [138]. At times, major vascular resection with the placement of a prosthesis may be required. Certain operative principles for giant adrenal tumors include a thorough knowledge of retroperitoneal anatomy, careful and meticulous dissection, enhanced CT with 3D reconstructions for delineating relationship of the adrenal tumor to the surrounding structures, a low threshold for conversion to open procedure, use of specialized vessel sealing devices that can secure small parasitic vessels with minimal collateral thermal damage; and adherence to oncologic goals for complete surgical excision to minimize disease recurrence.

6. Conclusion

Knowledge of unusual adrenal masses is essential for those clinicians involved in the management of adrenal disorders. This chapter has provided a comprehensive review of the pathogenesis, clinical presentation, and management of uncommon adrenal masses.

Acknowledgements

Authors confirm the copyright permission for use of pictures throughout the chapter.

Author details

Santosh Kumar* and Shivanshu Singh

*Address all correspondence to: santoshsp1967jaimatadi@yahoo.co.in

Department of Urology, Advanced Urology Center, Postgraduate Institute of Medical Education and Research, Chandigarh, India

References

- [1] Paolo WF Jr, Nosanchuk JD. Adrenal infections. *International Journal of Infectious Diseases*. 2006;10:343–353

- [2] Lam KY, Lo CY. A critical examination of adrenal tuberculosis and a 28-year autopsy experience of active tuberculosis. *Clinical Endocrinology*. 2001;**54**:633–639
- [3] Upadhyay J, Sudhindra P, Abraham G, Trivedi N. Tuberculosis of the adrenal gland: A case report and review of the literature of infections of the adrenal gland. *International Journal of Endocrinology*. 2014;**2014**:876037
- [4] Borgo CD, Urigo C, Marocco R, Belvisi V, Pisani L, Citton R. et al. Diagnostic and therapeutic approach in a rare case of primary bilateral adrenal tuberculosis. *Journal of Medical Microbiology*. 2010;**59**:1527–1529
- [5] Kelestimur F. The endocrinology of adrenal tuberculosis: the effects of tuberculosis on the hypothalamo-pituitary-adrenal axis and adrenocortical function. *Journal of Endocrinological Investigation*. 2004;**27**:380–386
- [6] Keleştimur F, Göktaş Z, Gülmez I, Ünlühizarci K, Bayram F, Özesmi M. et al. Low dose (1 µg) adrenocorticotropin stimulation test in the evaluation of hypothalamo-pituitary-adrenal axis in patients with active pulmonary tuberculosis. *Journal of Endocrinological Investigation*. 2000;**23**:235–239
- [7] Laway BA, Khan I, Shah BA, Choh NA, Bhat MA, Shah ZA. Pattern of adrenal morphology and function in pulmonary tuberculosis: Response to treatment with antitubercular therapy. *Clinical Endocrinology*. 2013;**79**:321–325
- [8] McMurry JF, Long D, McClure R, Kotchen TA. Addison's disease with adrenal enlargement on computed tomographic scanning: Report of two cases of tuberculosis and review of the literature. *The American journal of medicine*. 1984;**77**:365–368
- [9] Guo YK, Yang ZG, Li Y, Ma ES, Deng YP, Min PQ. et al. Addison's disease due to adrenal tuberculosis: contrast-enhanced CT features and clinical duration correlation. *European Journal of Radiology*. 2007;**62**:126–131
- [10] Kelestimur F, Unlu Y, Ozesmi M, Tolu I. A hormonal and radiological evaluation of adrenal gland in patients with acute or chronic pulmonary tuberculosis. *Clinical Endocrinology*. 1994;**41**:53–56
- [11] Gülmez I, Kelestimur F, Durak AC, Özesmi M. Changes in the size of adrenal glands in acute pulmonary tuberculosis with therapy. *Endocrine Journal*. 1996;**43**:573–576
- [12] Bhatia E, Jain SK, Gupta RK, Pandey R. Tuberculous Addison's disease: Lack of normalization of adrenocortical function after anti-tuberculous chemotherapy. *Clinical Endocrinology*. 1998;**48**:355–359
- [13] Goodwin JR RA, Shapiro JL, Thurman GH, Thurman SS, Des Prez RM. Disseminated histoplasmosis: Clinical and pathologic correlations. *Medicine*. 1 Jan 1980;**59**(1):1–33
- [14] Mukherjee JJ, Villa ML, Tan L, Lee KO. Image in endocrinology: Bilateral adrenal masses due to histoplasmosis. *The Journal of Clinical Endocrinology and Metabolism*. 2005;**90**:6725–6726

- [15] Koene RJ, Catanese J, Sarosi GA. Adrenal hypofunction from histoplasmosis: A literature review from 1971 to 2012. *Infection*. 2013;**41**:757–759
- [16] Kauffman CA. Fungal infections in older adults. *Clinical Infectious Diseases*. 2001;**33**: 550–555
- [17] Vyas S, Kalra N, Das PJ, Lal A, Radhika S, Bhansali A. Adrenal histoplasmosis: An unusual cause of adrenomegaly. *Indian Journal of Nephrology*. 2011;**21**:283–285
- [18] Subramanian S, Mathai D. Clinical manifestations and management of cryptococcal infection. *Journal of Postgraduate Medicine*. 2005;**51**:S21-S26
- [19] Cocker R, McNair SA, Kahn L, Kwon S, Ding X, Zeltsman V. et al. Isolated adrenal cryptococcosis, diagnosed by fine-needle aspiration biopsy: A case report. *Diagnostic Cytopathology*. 2014;**42**:899–901. DOI: 10.1002/dc.23079
- [20] Walker BF, Gunthel CJ, Bryan JA, Watts NB, Clark RV. Disseminated cryptococcosis in an apparently normal host presenting as primary adrenal insufficiency: Diagnosis by fine needle aspiration. *American Journal of Medicine*. 1989;**86**:715–717
- [21] Hung ZS, Lai YH, Hsu YH, Wang CH, Fang TC, Hsu BG. Disseminated cryptococcosis causes adrenal insufficiency in an immunocompetent individual. *Internal Medicine*. 2010;**49**:1023–1026
- [22] Ranjan P, Jana M, Krishnan S, Nath D, Sood R. Disseminated cryptococcosis with adrenal and lung involvement in an immunocompetent patient. *Journal of Clinical and Diagnostic Research*. 2015;**9**:OD04-OD05. DOI: 10.7860/JCDR/2015/11499.5752
- [23] Huston SM, Mody CH. Cryptococcosis: An emerging respiratory mycosis. *Clinics in Chest Medicine*. 2009;**30**:253–264
- [24] Takeshita A, Nakazawa H, Akiyama H, Takeuchi K, Kawai R, Ohashi K. et al. Disseminated cryptococcosis presenting with adrenal insufficiency and meningitis: Resistant to prolonged antifungal therapy but responding to bilateral adrenalectomy. *Internal Medicine*. 1992;**31**:1401–1405
- [25] Akcay MN, Akcay G, Balik AA, Boyuk A. Hydatid cysts of the adrenal gland: Review of nine patients. *World Journal of Surgery*. 2004;**28**:97–99. DOI: 10.4111/kju.2014.55.7.493
- [26] Goel MC, Agarwal MR, Misra A. Percutaneous drainage of renal hydatid cyst: Early results and follow-up. *British Journal of Urology*. 1995;**75**:724–728
- [27] Foster DG. Adrenal cysts: Review of literature and report of case. *Archives of Surgery*. 1966;**92**:131–143
- [28] Schoretsanitis G, de Bree E, Melissas J, Tsiftsis D. Primary hydatid cyst of the adrenal gland. *Scandinavian Journal of Urology*. 1998;**32**:51–53
- [29] Kumar S, Singh S. Genitourinary hydatid disease. In: Rodriguez-Morales AJ, editor. *Current Topics in Echinococcosis*. InTech. 2015. DOI: 10.5772/60904

- [30] Yeniyol CO, Minareci S, Ayder AR. Primary cyst hydatid of adrenal: A case report. *International Urology and Nephrology*. 2000;**32**:227–229
- [31] Rexiati M, Mutalifu A, Azhati B, Wang W, Yang H, Sheyhedin I. et al. Diagnosis and surgical treatment of renal hydatid disease: A retrospective analysis of 30 cases. *PLoS ONE*. 2014;**9**:e96602. DOI: 10.1371/journal.pone.0096602
- [32] Kumar S, Pandya S, Agarwal S, Lal A. Laparoscopic management of genitourinary hydatid cyst disease. *Journal of Endourology*. 2008;**22**:1709–1713
- [33] Rott MB, Fernandez V, Farias S, Ceni J, Ferreira HB, Haag KL, et al. Comparative analysis of two different subunits of antigen B from *Echinococcus granulosus*: Gene sequences, expression in *Escherichia coli* and serological evaluation. *Acta Tropica*. 2000;**75**:331–340
- [34] Virginio VG, Hernandez A, Rott MB, Monteiro KM, Zandonai AF, Nieto A, et al. A set of recombinant antigens from *Echinococcus granulosus* with potential for use in the immunodiagnosis of human cystic hydatid disease. *Clinical & Experimental Immunology*. 2003;**132**(2):309–315
- [35] Feki W, Ghazzi S, Khiari R, Ghorbel J, Elarbi H, Khouni H, et al. Multiple unusual locations of hydatid cysts including bladder, psoas muscle and liver. *Parasitology International*. 2008;**57**:83–86
- [36] Arif SH, Shams Ul B, Wani NA, Zargar SA, Wani MA, Tabassum R, et al. Albendazole as an adjuvant to the standard surgical management of hydatid cyst liver. *International Journal of Surgery*. 2008;**6**:448–451
- [37] Von Sinner WN, Hellstorm M, Kavegi I, Norlen BJ. Hydatid disease of urinary tract. *Journal of Urology*. 1993;**149**:577–580
- [38] Kumar S, Nanjappa B, Gowda KK. Laparoscopic management of a hydatid cyst of the adrenal gland. *Korean Journal of Urology*. 2014;**55**:493–495
- [39] Mondain-Miton V, Toussaint-Gari M, Hofman P, Marty P, Carles M, De Salvador F, et al. Atypical leishmaniasis in a patient infected with human immunodeficiency virus. *Clinical Infectious Diseases*. 1995;**21**:663–665
- [40] Brenner DS, Jacobs SC, Drachenberg CB, Papadimitriou JC. Isolated visceral leishmaniasis presenting as an adrenal cystic mass. *Archives of Pathology & Laboratory Medicine*. 2000;**124**:1553–1556
- [41] Teixeira Vde P, Hial V, Gomes RA, Castro EC, Reis M das G, Rodrigues ML, et al. Correlation between adrenal central vein parasitism and heart fibrosis in chronic chagasic myocarditis. *The American Journal of Tropical Medicine and Hygiene*. 1997;**56**:177–180
- [42] Reincke M, Arlt W, Heppner C, Petzke F, Chrousos GP, Allolio B. Neuroendocrine dysfunction in african trypanosomiasis: The role of cytokines. *Annals of the New York Academy of Sciences*. 1998;**840**:809–821
- [43] Pinto AY, Valente Vda C, Coura JR, Valente SA, Junqueira AC, Santos LC, et al. Clinical follow-up of responses to treatment with benznidazol in Amazon: A cohort study of acute chagas disease. *PLoS One*. 2013;**8**:e64450

- [44] Mertens RB, Didier ES, Fishbein MC, Bertucci DC, Rogers LB, Orenstein JM. Encephalitozoon cuniculi microsporidiosis: Infection of the brain, heart, kidneys, trachea, adrenal glands, and urinary bladder in a patient with AIDS. *Modern Pathology*. 1997;**10**:68–77
- [45] Mastorakos G, MAGIAKOU MA, Chrousos GP. Effects of the immune/inflammatory reaction on the hypothalamic-pituitary-adrenal axis. *Annals of the New York Academy of Sciences*. 1995;**771**:438–448
- [46] Grulich AE, Li Y, McDonald AM, Correll PK, Law MG, Kaldor JM. Decreasing rates of Kaposi's sarcoma and non-Hodgkin's lymphoma in the era of potent combination anti-retroviral therapy. *Aids*. 2001;**15**:629–633
- [47] Meher D, Duttab D, Giric R, Kard M. Adrenal leiomyoma mimicking adrenal malignancy: Diagnostic challenges and review of literature. *Journal of Endocrinology and Metabolism*. 2015;**5**:304–308
- [48] Alteer M, Ascott-Evans BH, Conradie M. Leiomyoma: A rare cause of adrenal incidentaloma. *JEMDSA*. 2013;**18**:71–74
- [49] Kumar S, Nanjappa B, Agrawal P, Pushkarna A. Large bilateral adrenal leiomyomas presenting as calcified adrenal masses: A rare case report. *Korean Journal of Urology*. 2014;**55**:363–366
- [50] Dahan H, Bèges C, Weiss L, Abitbol M, Ledreff O, Teman G, et al. Leiomyoma of the adrenal gland in a patient with AIDS. *Abdominal Imaging*. 1994;**19**:259–261
- [51] Radin DR, Kiyabu M. Multiple smooth-muscle tumours of the colon and adrenal gland in an adult with AIDS. *American Journal of Roentgenology*. 1992;**159**:545–546
- [52] Lin J, Wasco MJ, Korobkin M, Doherty G, Giordano TJ. Leiomyoma of the adrenal gland presenting as a non-functioning adrenal incidentaloma: Case report and review of the literature. *Endocrine Pathology*. 2007;**18**:239–243
- [53] Day DL, Sane S, Dehner LP. Inflammatory pseudotumor of the mesentery and small intestine. *Pediatric Radiology*. 1986;**16**:210–215. DOI: 10.1007/BF02456289
- [54] Brunn H. Two interesting benign lung tumours of contradictory histopathology: Remarks on the necessity for maintaining the chest tumour registry. *The Journal of Thoracic and Cardiovascular Surgery*. 1939;**9**:119–131
- [55] Umiker WO, Iverson L. Postinflammatory 'tumours' of the lung: report of four cases simulating xanthoma, fibroma, or plasma cell tumour. *The Journal of Thoracic and Cardiovascular Surgery*. 1954;**28**:55–63
- [56] Sastre-Garau X, Couturier J, Derré J, Aurias A, Klijanienko J, Lagacé R. Inflammatory myofibroblastic tumour (inflammatory pseudotumour) of the breast. Clinicopathological and genetic analysis of a case with evidence for clonality. *The Journal of Pathology*. 2002;**196**(1):97–102. DOI: 10.1002/path.1004
- [57] Pettinato G, Manivel JC, De Rosa N, Dehner LP. Inflammatory myofibroblastic tumor (plasma cell granuloma). Clinicopathologic study of 20 cases with immunohistochemical and ultrastructural observations. *American Journal of Clinical Pathology*. 1990;**94**(5):538–546

- [58] Materne R, Van Beers BE, Gigot JF, et al. Inflammatory pseudotumor of the liver: MRI with mangafodipir trisodium. *Journal of Computer Assisted Tomography*. 1998;**22**:82–84
- [59] Chawla A, Hameed Z, Mishra D, Monappa V. Adrenal inflammatory myofibroblastic tumour. *BMJ Case Reports*. 2013. DOI: 10.1136/bcr-2013-010122
- [60] Tran-Dang M-A, Banga N, Khoo B, Bates AW. Inflammatory myofibroblastic tumour arising in the adrenal gland: A case report. *Journal of Medical Case Reports*. 2014;**8**:411. DOI: 10.1186/1752-1947-8-411
- [61] Abehsera M, Vilgrain V, Belghiti J, Fléjou JF, Nahum H. Inflammatory pseudotumor of the liver: Radiologic–pathologic correlation. *Journal of Computer Assisted Tomography*. 1995;**19**:80–83
- [62] Marino-Enriquez A, Wang WL, Roy A, Lopez-Terrada D, Lazar AJ, Fletcher CD, et al. Epithelioid inflammatory myofibroblastic sarcoma; an aggressive intra-abdominal variant of inflammatory myofibroblastic tumour with nuclear membrane or perinuclear ALK. *The American Journal of Surgical Pathology*. 2011;**35**:135–144. DOI: 10.1097/PAS.0b013e318200cfd5
- [63] Attili SV, Chandra CR, Hemant DK, Bapsy PP, RamaRao C, Anupama G. Retroperitoneal inflammatory myofibroblastic tumor. *World Journal of Surgical Oncology*. 2005;**3**:66. DOI: 10.1186/1477-7819-3-66
- [64] Coffin CM, Hornick JL, Fletcher CDM. Inflammatory myofibroblastic tumour; comparison of clinicopathologic, histologic, immunohistochemical features and ALK expression in atypical and aggressive cases. *The American Journal of Surgical Pathology*. 2007;**31**:509–520. DOI: 10.1097/01.pas.0000213393.57322.c7
- [65] Stout AP. A tumor of the ulnar nerve. *Proc NY Pathol Soc*. 1918;**12**:2–12
- [66] Hart MN, Earle KM. Primitive neuroectodermal tumors of the brain in children. *Cancer*. 1973;**32**:890–897
- [67] Zhang Y, Li H. Primitive neuroectodermal tumors of adrenal gland. *Japanese Journal of Clinical Oncology* 2010;**40**:800–804
- [68] Khong PL, Chan GC, Shek TW, Tam PK, Chan FL. Imaging of peripheral PNET: Common and uncommon locations. *Clinical Radiology*. 2002;**57**:272–277
- [69] Rossi S, Orvieto E, Furlanetto A, Laurino L, Ninfo V, Dei Tos AP. Utility of the immunohistochemical detection of FLI-1 expression in round cell and vascular neoplasm using a monoclonal antibody. *Modern Pathology*. 2004;**17**:547–552
- [70] Dutta D, Shivaprasad KS, Das RN, Ghosh S, Chowdhury S. Primitive neuroectodermal tumor of adrenal: Clinical presentation and outcomes. *Journal of Cancer Research and Therapeutics*. 2013;**9**:709–711. DOI: 10.4103/0973-1482.126459
- [71] Fellingner EJ, Garin-Chesa P, Triche TJ, Huvos AG, Rettig WJ. Immunohistochemical analysis of Ewing's sarcoma cell surface antigen p30/32MIC2. *American Journal of Pathology*. 1991;**139**:317–325

- [72] Weidner N, Tjoe J. Immunohistochemical profile of monoclonal antibody O13: antibody that recognizes glycoprotein p30/32MIC2 and is useful in diagnosing Ewing's sarcoma and peripheral neuroepithelioma. *The American Journal of Surgical Pathology*. 1994;**18**:486–494
- [73] Komatsu S, Watanabe R, Naito M, Mizusawa T, Obara K, Nishiyama T, et al. Primitive neuroectodermal tumor of the adrenal gland. *International Journal of Urology*. 2006;**13**: 606–607
- [74] Tsang YP, Lang BHH, Tam SC, Wong KP. Primitive neuroectodermal adrenal gland tumour. *Hong Kong Medical Journal*. 2014;**20**:444–446
- [75] Phukan C, Nirmal TJ, Kumar RM, Kekre NS. Peripheral primitive neuroectodermal tumor of the adrenal gland: A rare entity. *Indian Journal of Urology : IJU : Journal of the Urological Society of India*. 2013;**29**:357–359. DOI: 10.4103/0970-1591.120128
- [76] Wong DD, Spagnolo DV, Bisceglia M, Havlat M, McCallum D, Platten MA. Oncocytic adrenocortical neoplasms—A clinicopathologic study of 13 new cases emphasizing the importance of their recognition. *Human Pathology*. 2011;**42**:489–499. DOI: 10.1016/j.humpath.2010.08.010
- [77] Sharma N, Dogra PN, Mathur S. Functional adrenal oncocytoma: A rare neoplasm. *Indian Journal of Pathology and Microbiology*. 2008;**51**:531–533
- [78] Alexander A, Paulose KP. Oncocytic variant of adrenal carcinoma presenting as Cushing's syndrome. *The Journal of the Association of Physicians of India*. 1998;**46**:235–237
- [79] Mearini L, Sordo RD, Costantini E, Nunzi E, Porena M. Adrenal oncocytic neoplasm: A systematic review. *Urologia Internationalis*. 2013;**91**:125–133. DOI: 10.1159/000345141
- [80] Bisceglia M, Ludovico O, Mattia AD, Ben-Dor D, Sandbank J, Pasquinelli G, et al. Adrenocortical oncocytic tumors: Report of 10 cases and review of the literature. *International Journal of Surgical Pathology*. 2004;**12**:231–243
- [81] Shah VN, Premkumar A, Walia R, Kumar S, Nahar U, Bhansali A. Large but benign adrenal mass: Adrenal oncocytoma. *Indian Journal of Endocrinology and Metabolism*. 2012;**16**:469–471. DOI: 10.4103/2230-8210.95717
- [82] Schittenhelm J, Ebner FH, Harter P, Bornemann A. Symptomatic intraspinal oncocytic adrenocortical adenoma. *Endocrine Pathology*. 2009;**20**:73–77. DOI: 10.1007/s12022-008-9051-1
- [83] Ciancio G, Vaidya A, Shirodkar S, Manoharan M, Hakky T, Soloway M. En bloc mobilization of the pancreas and spleen to facilitate resection of large tumors, primarily renal and adrenal, in the left upper quadrant of the abdomen: Techniques derived from multivisceral transplantation. *European Urology*. 2009;**55**:1106–1111. DOI: 10.1016/j.eururo.2008.12.038

- [84] Kumar S, Jayant K, Prasad S, Agrawal S, Parmar KM, Roat R, et al. Rare adrenal gland emergencies: A case series of giant myelolipoma presenting with massive hemorrhage and abscess. *Nephro-Urology Monthly*. Jan 2015;**7**(1):e22671
- [85] Kenney PJ, Wagner BJ, Rao P, Heffess CS. Myelolipoma: CT and pathologic features. *Radiology*. 1998;**208**:87–95. DOI: 10.1148/radiology.208.1.9646797
- [86] Lee JK. *Computed Body Tomography with MRI Correlation*. Lippincott Williams & Wilkins; 2006 ISBN: 0781745268
- [87] Gamss C, Chia F, Chernyak V, Rozenblit A. Giant hemorrhagic myelolipoma in a patient with sickle cell disease. *Emergency Radiology*. 2009;**16**:319–322. DOI: 10.1007/s10140-008-0740-3
- [88] Kamani F, Mohammadi SS, Hessami R, Rezvani N, Peirovi H, Tavassoli S. Giant adrenal myelolipoma associated with beta-thalassemia: A case report. *International Journal of Endocrinology and Metabolism*. 2009;**7**:259–262
- [89] Civrilli K, Damry N, Steppe R, Efira A, Mathieu J. Bilateral adrenal myelolipomas. *JBR-BTR*. 2008;**91**:90–91
- [90] Bishop E, Eble JN, Cheng L, Wang M, Chase DR, Orazi A, O'Malley DP. Adrenal myelolipomas show nonrandom X-chromosome inactivation in hematopoietic elements and fat: Support for a clonal origin of myelolipomas. *The American Journal of Surgical Pathology*. 2006;**30**:838–843
- [91] Chang KC, Chen PI, Huang ZH, Lin YM, Kuo PL. Adrenal myelolipoma with translocation (3;21)(q25; p11). *Cancer Genetics and Cytogenetics*. 2002;**134**:77–80
- [92] Han M, Burnett AL, Fishman EK, et al. The natural history and treatment of adrenal myelolipoma. *Journal of Urology*. 1997;**157**:1213–1216
- [93] Meyer A, Behrend M. Presentation and therapy of myelolipoma. *International Journal of Urology*. 2005;**12**:239–243. DOI: 10.1111/j.1442-2042.2005.01034.x
- [94] Russell C, Goodacre BW, vanSonnenberg E, Orihuela E. Spontaneous rupture of adrenal myelolipoma: Spiral CT appearance. *Abdominal Imaging*. 2000;**25**:431–434
- [95] Behrend M, Kaaden S, von Wasielewski R, Frericks B. Benign retroperitoneal schwannoma mimicking an adrenal mass. *Surgical Laparoscopy Endoscopy & Percutaneous Techniques*. 2003;**13**:133–138
- [96] Korets R, Berkenblit R, Ghavamian R. Incidentally Discovered Adrenal Schwannoma. *JLS*. 2007;**11**:113–115
- [97] Adas M, Ozulker F, Adas G, Koc B, Ozulker T, Sahin IM. A rare adrenal incidentaloma: Adrenal schwannoma. *Case Reports in Gastroenterology*. 2013;**7**:420–427
- [98] Lau SK, Spagnolo DV, Weiss LM. Schwannoma of the adrenal gland: Report of two cases. *The American Journal of Surgical Pathology*. 2006;**30**:630–634

- [99] Târcoveanu E, Dimofte G, Bradea C, Moldovanu R, Vasilescu A, Anton R, Ferariu D. Adrenal schwannoma. *JLS*. 2009;**13**:116–119
- [100] Onoda N, Ishikawa T, Toyokawa T, Takashima T, Wakasa K, Hirakawa K. Adrenal schwannoma treated with laparoscopic surgery. *JLS*. 2008;**12**:420–425
- [101] Tenenbaum F, Groussin L, Foehrenbach H, Tissier F, Gouya H, Bertherat J, Dousset B, Legmann P, Richard B, Bertagna X. 18F-fluorodeoxyglucose positron emission tomography as a diagnostic tool for malignancy of adrenocortical tumours? Preliminary results in 13 consecutive patients. *European Journal of Endocrinology*. 2004;**150**:789–792
- [102] Fine SW, McClain SA, Li M. Immunohistochemical staining for calretinin is useful for differentiating schwannomas from neurofibromas. *American Journal of Clinical Pathology*. 2004;**122**:552–559
- [103] Nishio A, Adachi W, Igarashi J, Koide N, Kajikawa S, Amano J. Laparoscopic resection of a retroperitoneal schwannoma. *Surgical Laparoscopy Endoscopy & Percutaneous Techniques*. 1999;**9**:306–309
- [104] Enzinger F, Weiss S. Primitive neuroectodermal tumors and related lesions. *Soft Tissue Tumors*. St. Louis: Mosby; 1995. pp. 929–964
- [105] Radin R, David CL, Goldfarb H, Francis IR. Adrenal and extra-adrenal retroperitoneal ganglioneuroma: imaging findings in 13 adults. *Radiology*. 1997;**202**:703–707
- [106] Majbar AM, Elmouhadi S, Elaloui M, Raiss M, Sabbah F, Hrra A, et al. Imaging features of adrenal ganglioneuroma: A case report. *BMC Research Notes*. 2014;**7**:791
- [107] Kumar S, Singh S, Chandna A. Organ Preservation in a Case of Retroperitoneal Ganglioneuroma. *Case Reports in Surgery*. Accepted 17 August 2016. Ahead of print. <http://www.hindawi.com/journals/cris/aip/6597374/>
- [108] Jain D, Chopra P, Sharma A. Adrenal lipoma with hemorrhage. *Urology Journal*. 2012;**9**:721–724
- [109] Lam KY, Lo CY. Adrenal lipomatous tumours: A 30 year clinicopathological experience at a single institution. *Journal of Clinical Pathology*. 2001;**54**:707–712
- [110] Milathianakis KN, Farfarelos CD, Mpogdanos IM, Karamanolakis DK. Giant lipoma of the adrenal gland. *Journal of Urology*. 2002;**167**:1777
- [111] Singaporewalla RM, Thamboo TP, Rau A, Cheah WK, Mukherjee JJ. Acute abdominal pain secondary to retroperitoneal bleeding from a giant adrenal lipoma with review of literature. *Asian Journal of Surgery*. 2009;**32**:172–176
- [112] Shumaker N, Rochman C, Legallo R, Northup C, Hanks J. Incidentally identified adrenal lipoma: Case report and review of related literature. *Endocrine Practice*. 2008;**14**:209–212
- [113] Lam KY, Chan AC, Ng IO. Giant adrenal lipoma: A report of two cases and review of literature. *Scandinavian Journal of Urology*. 1997;**31**:89–90

- [114] Grumbach MM, Biller BM, Braunstein GD, Campbell KK, Carney JA, Godley PA, et al. Management of the clinically inapparent adrenal mass ("incidentaloma"). *Annals of Internal Medicine*. 2003;**138**:424–429
- [115] Andreoni C, Krebs RK, Bruna PC, Goldman SM, Kater CE, Alves MT, et al. Cystic pheochromocytoma is a distinctive subgroup with special clinical, imaging and histological features that might mislead the diagnosis. *BJU International*. 2008;**101**:345–350
- [116] Erem C, Kocak M, OnderErsoz H, Ersoz S, Yucel Y. Epinephrine-secreting cystic pheochromocytoma presenting with an incidental adrenal mass: A case report and a review of the literature. *Endocrine*. 2005;**28**:225–230
- [117] Takarabea D, Takahashib Y, Tsujimotoa T, Notoa H, Kishimotoa M, Minowadad S, et al. Cystic pheochromocytoma discovered as an adrenal incidentaloma. *Journal of Medical Cases*. 2013;**11**:753–757
- [118] Wang H, Sun B, Xu Z, Lei W, Wang X. Undiagnosed giant cystic pheochromocytoma: A case report. *Oncology Letters*. 2015;**10**:1444–1446. <http://dx.doi.org/10.3892/ol.2015.3484>
- [119] Rogers CG, Pinto PA, Weir EG. Extraosseous (Extramedullary) Plasmacytoma of the adrenal gland. *Archives of Pathology & Laboratory Medicine*. 2004;**128**:e86–e88
- [120] Soutar R, Lucraft H, Jackson G, Reece A, Bird J, Low E, et al. Guidelines on the diagnosis and management of solitary plasmacytoma of bone and solitary extramedullary plasmacytoma. *Clinical Oncology*. 2004;**16**:405–413
- [121] Cao D, Li L, Liu L, Xiao W, He X, Tang Z, et al. Solitary extramedullary plasmacytoma of the adrenal gland: A rare case report with review of the literature. *International Journal of Clinical and Experimental Pathology*. 2014;**7**:9072–9075
- [122] Pasch W, Zhao XH, Pezk SA. Solitary plasmacytoma of the bone involving young individuals, is there a role for preceding trauma?. *International Journal of Clinical and Experimental Pathology*. 2012;**5**:463–467
- [123] Bhattacharya AK, Han K, Baredes S. Extramedullary plasmacytoma of the head and neck associated with the human immunodeficiency virus. *Ear, Nose & Throat Journal*. 1998;**77**:61–62
- [124] Fujikata S, Tanji N, Aoki K, Ohoka H, Hojo N, Yokoyama M. Extramedullary plasmacytoma arising from an adrenal gland. *Urology*. 2002;**60**:514v–514. viii
- [125] Ahmed M, Al-Ghamdi A, Al-Omari M, Aljurf M, Al-Kadhi Y. Autologous bone marrow transplanation for extramedullary plasmacytoma presenting as adrenal incidentaloma. *Annals of Saudi Medicine*. 2009;**29**:219–222. DOI: 10.4103/0256-4947.51785
- [126] Khurana A, Kaur P, Chauhan AK, Kataria SP, Bansal N. Primary non Hodgkin's lymphoma of left adrenal gland—A rare presentation. *Journal of Clinical and Diagnostic Research*. 2015;**9**:XD01–XD03. DOI: 10.7860/JCDR/2015/8079.5745
- [127] Freeman C, Berg JW, Culter SJ. Occurrence and prognosis of extranodal lymphomas. *Cancer*. 1972;**29**:252–260

- [128] Sachico IW, Tohru A, Nayoyoshi M. Bilateral adrenal lymphoma with hypercalcaemia: An autopsy case report with a review of the literature. *Journal of Clinical and Experimental Hematopathology*. 2003;**51**:101–109
- [129] Simpson WG, Babbar P, Payne LF. Bilateral primary adrenal non-Hodgkin's lymphoma without adrenal insufficiency. *Urology Annals*. 2015;**7**:259–261. DOI: 10.4103/0974-7796.152942
- [130] Cavanna L, Civardi G, Vallisa D, Bertè R. Primary adrenal non-Hodgkin's lymphoma associated with autoimmune hemolytic anemia: A case diagnosed by ultrasound-guided fine needle biopsy. *Annali italiani di medicina interna*. 1999;**14**(4):298–301
- [131] Edwards JP, Stuart HC, Urbanski SJ, Pasioka JL. A rare cavernous hemangioma of the adrenal gland. *International Journal of Surgery Case Reports*. 2014;**5**:52–55. DOI: 10.1016/j.ijscr.2013.11.003
- [132] Abou El-Ghar M, Refaie H, El-Hefnawy A, El-Diasty T. Adrenal hemangioma: Findings at multidetector CT with short review of the literature. *Case Reports in Radiology*. 2011;**2011**:601803
- [133] Forbes TL. Retroperitoneal hemorrhage secondary to a ruptured cavernous hemangioma. *Canadian Journal of Surgery*. 2005;**48**:78–79
- [134] Auh YH, Anand J, Zirinsky K, Kazam E. Adrenal hemangioma: A case report. *Journal of Computer Assisted Tomography*. 1986;**10**:57–59
- [135] Boraschi P, Campatelli A, Di Vito A, Perri G. Hemorrhage in cavernous hemangioma of the adrenal gland: US, CT and MRI appearances with pathologic correlation. *European Journal of Radiology*. 1995;**21**:41–43
- [136] Yamada T, Ishibashi T, Saito H, Majima K, Tsuda M, Takahashi S, et al. Two cases of adrenal hemangioma: CT and MRI findings with pathological correlations. *Radiation Medicine*. 2002;**20**:51–56
- [137] Deckers F, De Schepper A, Shamsi K, Hauben E, Van March E. Cavernous hemangioma of the adrenal gland: CT appearance. *Journal of Computer Assisted Tomography*. 1993;**17**:506–507
- [138] Kumar S, Mandal AK, Acharya N, Thingnam SK, Bhalla V, Singh SK. Superior mesenteric artery injury during en bloc excision of a massive left adrenal Tumor. *Urologia Internationalis* 2007;**78**:182–184. DOI: 10.1159/000098081

