

We are IntechOpen, the world's leading publisher of Open Access books Built by scientists, for scientists

6,900

Open access books available

185,000

International authors and editors

200M

Downloads

Our authors are among the

154

Countries delivered to

TOP 1%

most cited scientists

12.2%

Contributors from top 500 universities



WEB OF SCIENCE™

Selection of our books indexed in the Book Citation Index
in Web of Science™ Core Collection (BKCI)

Interested in publishing with us?
Contact book.department@intechopen.com

Numbers displayed above are based on latest data collected.
For more information visit www.intechopen.com



Current Approaches in the Minimally Invasive Surgical Treatment of Adrenal Tumors

Pasquale Cianci, Alberto Fersini, Nicola Tartaglia,
Sabino Capuzzolo, Libero Luca Giambavicchio,
Antonio Ambrosi and Vincenzo Neri

Additional information is available at the end of the chapter

<http://dx.doi.org/10.5772/intechopen.69419>

Abstract

The use of imaging modalities and minimally invasive surgery plays an important role in the current management of adrenal tumors. Ultrasonography frequently allows for the incidental diagnosis of adrenal masses. The most frequent adrenal pathologies encountered are hypercortisolism (Cushing's syndrome), primary hyperaldosteronism (Conn's syndrome), and pheochromocytomas. Clinical presentation of these adrenal tumors can often be non-specific, or such lesions may present as "incidentalomas" in patients who undergo imaging for clinical reasons unrelated to the adrenal glands. Adrenal malignancy is suggested by morphologic characteristics found on imaging studies: increased size, irregular borders, local invasion, and large necrotic areas. The risk of malignancy increases for larger adrenal masses. Minimally invasive surgery has become the initial choice for the treatment of adrenal tumors with retroperitoneal and transperitoneal approaches. This chapter describes the surgical indications and compares the various minimally invasive surgical approaches for the therapeutic management of adrenal masses.

Keywords: minimally invasive adrenalectomy, laparoscopic adrenalectomy, transperitoneal adrenalectomy, robotic adrenalectomy, NOTES

1. Introduction

Two main factors that have advanced the clinical management of adrenal tumors in the past 20 years include the technologic progress and widespread use of imaging studies such as

ultrasonography (US), computed tomography (CT), magnetic resonance imaging (MRI), and the advent and implementation of minimally invasive surgery. In many parts of the world, US frequently allows for the incidental diagnosis of adrenal tumors. The prevalence of adrenal “incidentalomas” in autopsy series reaches 8%, whereas in imaging studies, incidentalomas occur in 4% of patients. The prevalence of adrenal incidentalomas may increase because of the improvement and widespread use of abdominal imaging [1, 2]. Minimally invasive adrenalectomy has become the initial treatment of benign adrenal tumors with transperitoneal and retroperitoneal approaches. This chapter evaluates the surgical indications and compares the various minimally invasive approaches and outcomes in the surgical management of adrenal masses.

2. Adrenal pathology

The adrenal gland encompasses two distinct tissue zones with different functional activities. The adrenal medulla, derived from neuroectodermal cells, produces catecholamines, such as epinephrine and metanephrine. The adrenal cortex, derived from mesenchymal cells, is formed by three concentric zones: the granulosa that secretes aldosterone, the fasciculata that secretes cortisol, and the inner reticularis that secretes androgens. The most frequent clinical presentations of adrenal disease are related to the hypersecretion of these adrenal hormones.

2.1. Hypercortisolism

High levels of plasma glucocorticoids or hypercortisolism result in the classic symptoms and clinical features associated with Cushing’s syndrome [3]. Clinical features suggestive of hypercortisolism include central obesity, proximal myopathy, spontaneous bruising, facial plethora, wide purplish striae (>1 cm), hypokalemia, and osteoporosis. Clinical presentation of hypercortisolism can be assessed in patients by following changes in appearance from serial photographs. Cushing’s syndrome may be differentiated from ACTH-dependent (e.g., pituitary adenoma, ectopic ACTH secretion), and ACTH-independent (e.g., adrenal adenoma, adrenal carcinoma, adrenal hyperplasia). ACTH-independent Cushing’s syndrome due to adrenal adenoma or carcinoma can be surgically treated with adrenalectomy.

2.2. Primary hyperaldosteronism

The most common type of primary hyperaldosteronism is caused by aldosterone-producing adenomas, and less frequently, bilateral idiopathic adrenal hyperplasia. Solitary adrenal adenomas associated with primary hyperaldosteronism are usually <2cm in size [4]. Clinically characterized by symptoms of moderate or severe hypertension and hypokalemia, patients with primary hyperaldosteronism may also have polyuria, nocturia, polydipsia, and paraesthesias. Hypertension is usually refractory to conventional antihypertensive agents. The major diagnostic challenge is distinguishing between aldosterone-producing adenomas and idiopathic hyperaldosteronism. In the former, patients have severe hypertension, higher likelihood of hypokalemia, decrease or little (<30%) increase of serum aldosterone level in

upright posture test, and an adrenal mass (>1 cm) on CT. In idiopathic hyperaldosteronism, hypertension is less severe and hypokalemia less frequent. The increase of serum aldosterone level reaches $>30\%$ with upright posture test, and CT usually shows bilateral thickening of adrenal glands. For unilateral aldosterone-producing adenomas (localized lesions by imaging), surgical resection should be performed, whereas medical treatment using eplerenone (steroid-based anti-mineralocorticoid), spironolactone, and triamterene should be reserved for patients with idiopathic hyperaldosteronism.

2.3. Pheochromocytoma

Pheochromocytomas are chromaffin cell tumors, and their clinical presentation is associated with excess catecholamine production. Such adrenal tumors are usually sporadic and benign. Paragangliomas or extra-adrenal pheochromocytomas are usually located (75%) in para-aortic areas (e.g., organ of Zuckerkandl) or less frequently within the bladder, thorax, or neck. The majority of pheochromocytomas are unilateral, whereas bilateral lesions occur in 5–10% of cases and frequently as part of a familial syndrome. Pheochromocytomas can be associated with MEN2A and MEN2B syndromes, von Recklinghausen's disease, and tuberous sclerosis. Pheochromocytomas are malignant in 10% of cases with higher prevalence in ectopic locations. For malignancy, there are no clinical, laboratory, or imaging criteria. Only larger adrenal size (generally >4 – 5 cm) is useful to predict malignancy. Diagnostic certainty of malignant lesions is based on the presence of metastasis, not histologic features of the tumor. Clinical presentation of pheochromocytomas can encompass paroxysmal (48%), and persistent hypertension (29%) in patients. Only 10% of patients present with normotensive blood pressure. Other clinical manifestations include headaches, palpitations, diaphoresis, orthostatic hypotension, weight loss, dyspnea, polyuria, and polydipsia [5].

Plasma-free metanephrines that include total-free normetanephrines and metanephrines have 99 and 97% sensitivity, respectively. If plasma metanephrine levels are more than three or four times the upper limit of normal, specificity reaches 100% for pheochromocytomas. CT and MRI studies can detect pheochromocytomas that are ≥ 2 cm, and those cystic lesions with areas of necrosis. If CT or MRI does not localize the adrenal tumor, functional imaging with meta-iodobenzylguanidine (MIBG) can be useful.

Minimally invasive adrenalectomy (e.g., laparoscopic transperitoneal approach) is the initial surgical treatment of choice for benign pheochromocytomas. Adequate medical preparation before surgical resection is essential for operative success.

2.4. Incidentalomas

Adrenal incidentalomas are usually benign adrenal masses (≥ 1 cm) discovered “incidentally” on imaging studies conducted for other reasons not related to the adrenal glands. Current widespread use of imaging studies has led to increased discovery of incidental adrenal tumors in patients. Prevalence of incidentalomas reaches 8% in autopsy series and 4–6% in imaging studies [1, 2]. The definition of adrenal incidentaloma should be excluded in patients with known malignant disease and in patients with clinical evidence of adrenal disease. The initial

evaluation of adrenal incidentalomas should define benignity or malignancy, and underlying hormonal hyperactivity. Adrenal incidentalomas are hormonally hyperactive in 35% of cases. All patients with an incidental adrenal tumor should undergo hormonal evaluation for hypercortisolism, primary hyperaldosteronism, and pheochromocytoma. Other functional evaluation (e.g., androgen hypersecretion) can also be determined by clinical manifestation. Surgical indication for non-functional adrenal incidentalomas is principally guided by tumor size. Surgical excision is recommended for adrenal tumors >4 cm since most of the adrenocortical carcinomas (ACC) are usually large [6].

2.5. Adrenal malignancy

Primary adrenal malignancies are rare and encompass adrenocortical carcinoma (ACC) and malignant pheochromocytoma. ACC comprises 0.2% of all cancers, and these tumors can secrete excess cortisol, aldosterone, and androgens [19, 20]. Pheochromocytomas can be sporadic, hereditary, or part of MEN2A or MEN2B syndrome. Furthermore, the incidence of malignant pheochromocytoma ranges from 5 to 26% [21]. The diagnosis of malignant pheochromocytoma by imaging is based on local invasion and distal metastasis; the histologic diagnosis is frequently indeterminate due to uncertain criteria.

Assessment for adrenal malignancy is based on the size on imaging studies. Larger adrenal masses are associated with increased risk for malignancy. More specifically, incidental, non-functioning adrenal masses that measure ≥ 4 cm have an increased rate of malignancy and should be surgically removed. Furthermore, some reports suggest that imaging studies can delineate malignant from benign adrenal lesions. Non-contrast CT attenuation coefficient in Hounsfield units (HU) of an adrenal mass revealing densitometry <10 HU demonstrates high fat composition and increases the likelihood of a benign adenoma. CT sensitivity and specificity are 71 and 98%, respectively. Unfortunately, several adrenal adenomas (30%) are lipid-poor, and unenhanced CT is not indicative [7, 8].

The risk of malignancy is very high for larger adrenal tumors with a size threshold of 4 cm having a sensitivity of 96% and specificity of 52% for cancer. An adrenal tumor size threshold of 6 cm has a sensitivity of 90% and specificity of 80% for malignancy [9]. Adrenal tumor size not only suggests malignancy risk but also a criterion of reference for the choice surgical approach. Adrenal malignancy is also suggested by morphologic characteristics by imaging studies including irregular border, local invasion, large necrotic areas and infiltration of the tumor into the periadrenal fat [9]. Other malignant adrenal lesions are metastases from lung, breast, and other non-adrenal cancers. Removal of such adrenal masses does not commonly occur as the only site of metastatic disease [10, 11].

Fine-needle aspiration of adrenal masses is not an initial diagnostic test. It is primarily useful in cases of suspected metastatic lesions. Most adrenal lesions, within the realm of surgical treatment, are unilateral benign tumors including pheochromocytomas, adrenocortical adenomas, and adrenal incidentalomas. Other less common surgical indications include adrenal cysts, ganglioneuromas, myelolipomas, androgen-secreting tumors, and bilateral lesions such as macronodular adrenal hyperplasia.

3. Indication for adrenalectomy

The size threshold of benign and functional adrenal tumors for laparoscopic adrenalectomy has traditionally ranged from 8 to 9 cm. Nevertheless, the size limit of adrenal masses for laparoscopic resection has incrementally increased following the improvement in surgical skills and technologies. Some limitation criteria for laparoscopic removal such as size >9 cm, and preoperative radiologic evidence of and/or intraoperative local infiltration of periadrenal tissue may be useful in patient selection.

A remaining controversial issue is the laparoscopic resection of highly suspicious or malignant adrenal masses. In the opinion of the authors, well-defined local invasiveness is essential for determining the suitability for laparoscopic adrenalectomy [12–18]. Recent data from the literature confirm that laparoscopic adrenalectomy can replicate open surgical oncologic resection of ACC, showing comparable survival and recurrence rates. The most important contraindication for the minimally invasive adrenalectomy is local infiltration of periadrenal tissue determined by preoperative imaging and intraoperative inspection.

Adrenal metastases may come from primary tumors of lung, breast, stomach, and kidney. Detection of metastasis has increased with the widespread use of imaging studies for cancer surveillance. If solitary metastatic lesions are limited within the capsule of the adrenal gland, adrenalectomy can be performed [22]. Laparoscopic adrenalectomy can also be performed for high-risk lesions for malignancy, but general experience is limited, and oncologic effectiveness of minimally invasive approaches remains uncertain in this setting [12, 17, 18, 23–28].

When malignant adrenal tumors, primary or metastatic, are removed laparoscopically, surgical oncologic principles must be followed: low likelihood for conversion, complete removal with the slightest manipulation and without fragmentation of periadrenal tissues. If required, the conversion to an open procedure must be performed very early, before the advanced dissection of the operative site and possible fragmentation of periadrenal fat or tumor capsule. Recent data from the literature confirm that laparoscopic adrenalectomy is safe and effective for malignant adrenal tumors. In some studies, outcome results with regard to peritoneal carcinomatosis, positive resection margins, and time to recurrence showed no statistically significant differences between open and laparoscopic approaches [12, 28–33]. In other studies with regard to ACC, oncologic outcomes of laparoscopic adrenalectomy were not comparable to open adrenalectomy [17, 34, 35].

4. Minimally invasive surgery for adrenal tumors

The surgical approach to the adrenal glands has evolved considerably from the description of the first laparoscopic adrenalectomy by Gagner et al. [36]. This minimally invasive surgical approach has established itself as the “gold standard” for the surgical treatment of most adrenal lesions. The advantages in performing laparoscopic adrenalectomy include reduced hospital stay, fewer complications, and better aesthetic results. Traditional open adrenalectomy is still reserved for

malignant or larger adrenal tumors [37, 38]. Regardless of approach, the key to successful adrenalectomy remains the same: proper patient selection for surgery, solid understanding of adrenal pathophysiology, and a thorough knowledge of adrenal anatomy. Over the last two decades, many minimally invasive techniques have been introduced including the lateral transabdominal (LT), retroperitoneal (RE), anterior transabdominal (AT), hand-assisted (HA), thoracoscopic transdiaphragmatic (TT) approaches, and natural orifice transluminal endoscopic surgery (NOTES). With the advent of robotic surgery, its integration into adrenal surgery has made it feasible to offer an alternative to patients requiring surgical treatment of adrenal disorders.

The most frequently performed laparoscopic approach is LT (79%), followed by RE (32%) and AT access (14%) [39]. These different laparoscopic approaches are determined by the surgeon's skill set. Laparoscopic LT adrenalectomy is the most popular procedure as it allows for wide exposure of the retroperitoneal space and takes advantage of mobilization of organs due to gravity in both left and right lateral positions: spleen, pancreas or liver. Using laparoscopic LT access, there are no major differences between the right and left adrenalectomy except for longer operative time for left adrenal glands [40]. Open adrenalectomy consists of transabdominal or retroperitoneal approaches that can be mimicked by minimally invasive surgery for adrenal resection.

4.1. Transabdominal approach

4.1.1. Lateral

Under general anesthesia, the patient is positioned with left lateral side down for right adrenalectomy and the right lateral side down for left adrenalectomy. Pneumoperitoneum is induced through a Veress needle inserted in the flank or through a laparoscopic trocar (**Figure 1**—port **B**) with CO₂ pressure regulated at 12 mmHg for the whole procedure; a 0°/30° laparoscope is introduced through this port. Three other 10 mm (**Figure 1** ports **A-C-D**) ports are inserted for the introduction of atraumatic graspers, hook, retractors, an instrument with peanut swab, and scissors.

For left adrenalectomy, the first step of intervention is dissection and mobilization of pancreaticosplenic bloc by the division of the splenorenal ligament. The lateral position of the patient allows for better mobilization of the spleen and pancreatic tail (**Figure 2**). In some patients, the division of phrenocolic ligament for mobilization of the left colonic flexure is useful. This mobilization allows for the exposure of the left adrenal gland that involves dissection into the retroperitoneal fat above the left kidney. Most important is the careful dissection and ligation of the left adrenal vein, usually by clips, that runs directly into a left renal vein.

For right adrenalectomy, the retroperitoneal space can be entered with incision of posterior peritoneum along the inferior visceral surface of the liver and right triangular ligament. Upper retraction of the liver to expose the surface and superior pole of the right adrenal gland is useful. Most important is the identification and exposure of the inferior vena cava (IVC). The right adrenal gland is partially retrocaval, and a very short adrenal vein runs directly into the IVC. The right adrenal vein should be carefully identified, clipped, and divided (**Figure 3**). The right adrenal gland can be dissected free from the retroperitoneal fat, hemostasis is checked, and the adrenal bed is irrigated. The specimen is placed in a plastic bag and extracted through the anterior trocar.

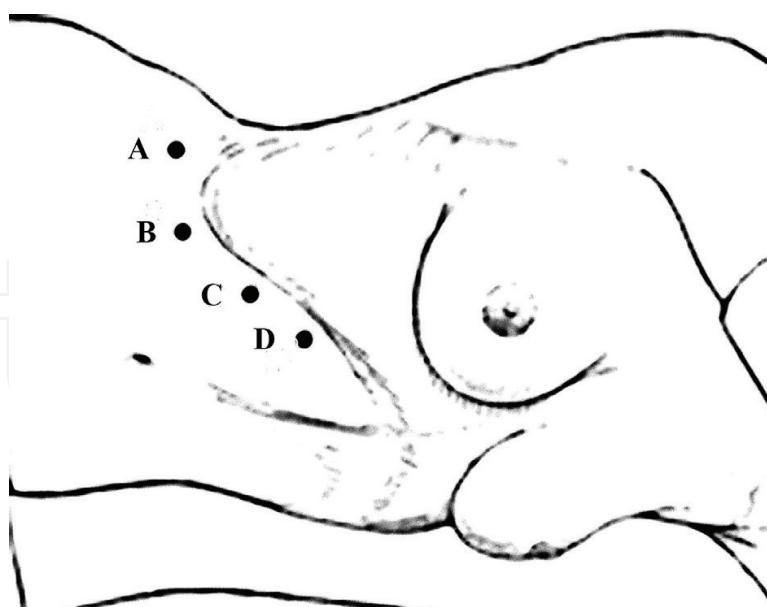


Figure 1. Trocar access in the lateral transabdominal approach.



Figure 2. Laparoscopic exposure of left adrenal gland: mobilization of the spleen and tail of the pancreas and dissection of left colonic flexure.

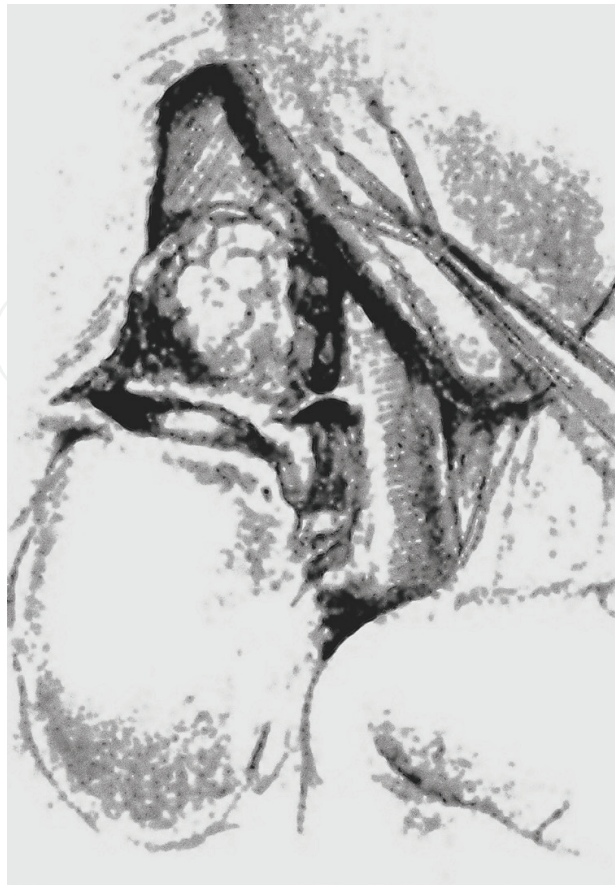

Figure 3. Laparoscopic exposure of right adrenal gland: mobilization of the liver, identification of short right adrenal vein—partial retrocaval position of the right adrenal gland.

4.1.2. Anterior

The anterior transabdominal approach is a less preferred initial choice for laparoscopic adrenalectomy [41, 42]. Under general anesthesia, the patient is placed on the operative table in the supine position with containment devices on both sides to allow for table tilting laterally, if required. Pneumoperitoneum is induced with a Veress needle at the umbilicus, or with an open technique based on surgeon preference or previous surgery.

For left adrenalectomy, four trocars are employed in the following positions: above the umbilicus, in the subxiphoid position, along with the left midclavicular line at the umbilicus level, and in the left flank region along the midaxillary line. The anterior transabdominal approach does not allow for mobilization by the gravity of the spleen and pancreatic tail. Consequently, wide dissection and mobilization of the left colon to the splenic flexure and division of splenocolic and phrenocolic ligaments are required. Exposure of the retroperitoneum allows for identification of the superior pole of left kidney and surface of the adrenal gland, which can be dissected and mobilized into retroperitoneal fat. The left adrenal vein should be identified and clipped during the first phase of the dissection [43].

For right adrenalectomy, trocar position is similar to left adrenalectomy, but on the opposite side. After separation of omental adhesions, the peritoneal reflection along the lateral side

of the inferior vena cava is exposed. The incision is extended transversely to the peritoneum overlying the posterior margin of the liver. This dissection permits transverse identification of the short right adrenal vein directly entering the IVC. Liver retraction allows the surgeon to gain exposure of the upper portion of the right adrenal gland. After identification and careful dissection, the right adrenal vein is ligated with titanium clips and divided. The right adrenal gland is mobilized by blunt dissection and electrocautery until completely free. The adrenal gland is then placed into a specimen retrieval bag for removal through any of the port sites [43].

4.2. Retroperitoneal approach

Although transperitoneal techniques remain more popular and widely used, the retroperitoneal approach has several distinct advantages that make it an attractive alternative for surgical removal of adrenal tumors [41]. The retroperitoneal approach for adrenalectomy is the second most common surgical technique utilized. Some authors report the advantage of a more direct route to the adrenal gland without interference from intra-abdominal organs using the retroperitoneal approach. Furthermore, shorter operative times and hospital stay with fewer postoperative fluid collections have been reported with this technique [37, 41, 44–48]. The major difficulties associated with the retroperitoneal approach are restricted operative space and difficult detection of anatomical landmarks that may cause longer operative times and increased carbon dioxide absorption [44, 49–51].

4.2.1. Lateral

The patient is in full flank position with the operating table flexed to open the space between the iliac crest and costal margin. The procedure starts with the open insertion of a balloon trocar in the middle axillary line 3 cm above the iliac crest. After retroperitoneal dilation using a balloon, a 10 mm trocar is inserted for a 30 degree 10 mm laparoscope, and then, carbon dioxide is insufflated to generate a pneumoretroperitoneum pressure of 15 mmHg. Three other trocars are placed above the first: along the anterior axillary line, along with the lateral border of sacrospinalis muscle, and below the costal margin always along the anterior axillary line. An optional fifth port may be necessary in order to retract the liver or in cases where the peritoneum has been lacerated.

For left adrenalectomy, dissection begins along the lateral border of psoas muscle to medial border left kidney, where the left kidney is retracted upward and anteriorly. The renal hilum is isolated to identify the left renal vein and medial border of the left adrenal gland. The left adrenal vein is located at the inferomedial left adrenal gland in conjunction with the left renal vein. After identification, the left adrenal vein is ligated between clips. The adrenal gland is mobilized and separated from the left kidney, and the superior and inferior phrenic vessels are controlled with an ultrasonic coagulation instrument or bipolar cautery. The left adrenal gland is placed into a sterile plastic bag and extracted from a primary port.

For right adrenalectomy, dissection of right adrenal gland follows the same principles described for left adrenal gland dissection. The psoas muscle is an important key anatomical landmark. After identification of right kidney and right adrenal gland, careful dissection to the IVC located at the medial part of psoas muscle is performed. The right adrenal vein is

identified in conjunction to the IVC, clipped, and divided. After complete excision of the right adrenal gland, the specimen is placed into a sterile plastic bag and extracted from a primary port. The trocars are removed and port sites sutured closed.

4.2.2. *Posterior*

The patient may be placed in the prone or jack-knife position, and this is valid for both sides. Access to the retroperitoneum begins with the insertion of a balloon trocar to 2.5 cm lateral to the tip of 12th rib and insufflated [52]. Through the balloon trocar, a laparoscope is inserted to evaluate the retroperitoneal space, and the balloon trocar is then replaced with another 10 mm trocar. CO₂ is injected at 12–20 mm Hg pressure to sustain an adequate retroperitoneal space. A second trocar is inserted under the edge of the 12th rib, the 3rd at the 11th and last at the 9th and 10th ribs. An atraumatic retractor is introduced through the inferior trocar to retract the kidney downwards and fatty tissue. Mobilization of the upper renal pole will allow visualization of the adrenal gland. A retractor inserted into the medial or lateral trocar controls the upper pole of the kidney. The adrenal gland is mobilized medially and then caudally. Between the diaphragmatic branch and adrenal gland, the arteries pass posterior to the vena cava. These vessels may be ligated by electrocautery or by clips. Dissecting the right adrenal gland superiorly will expose the vena cava posteriorly and the short adrenal vein posterolateral that can be cleared by 1 cm and divided between clips. Continued lateral and cranial dissection will completely mobilize the right adrenal gland. The left adrenal vein is isolated in the area between the left adrenal gland and diaphragmatic branch, which is medial to the upper pole of the left kidney. The dissection of the adrenal gland continues medially, laterally and then cranially, and it will remain raised in relation only to the left renal vein. Delicate dissection with instruments is necessary to avoid damaging of the adrenal capsule.

4.3. Hand-assisted approach

The hand-assisted technique is a hybrid between the open and laparoscopic approach. For some, this technique is useful for large tumor removal with reduced surgical time [53]. For left adrenalectomy, the patient is placed in the supine position with legs separated, and two ports are inserted into the left subcostal region, and the camera port is inserted level with and lateral to the umbilicus. In the case of right adrenalectomy, two ports are placed in the right upper quadrant and another for the laparoscope that is introduced through umbilical access. The surgeon stands on the right side of the patient, and the camera operator assistant stands between the patient's legs and a second assistant retracts and assists with dissection via the remaining port sites. After the establishment of pneumoperitoneum, a midline incision is made for the placement of the HandPort for the left side, and for the right side, a right subcostal oblique incision. The size of the incision for the HandPort must be proportional to the surgeon's glove size. The HandPort base retractor is then inflated, and the surgeon connects the HandPort sleeve by initially placing the bracelet around his wrist. A second glove is then placed over the bracelet, and the back of the hand is lubricated with sterile gel. The operator's arm slides inside the sleeve of the hand port, the ring is fixed inside the abdominal incision and the basic retractor on the skin edge. The latter is inflated and the sleeve rewound and trapped in the

basic retractor. Once the system is sealed, the pneumoperitoneum can be reestablished. At this point, the operator's hand can be inserted into the abdomen. To the right side, the approach is anterior, where the duodenum is mobilized, and the retroperitoneal fascia is dissected to the upper renal pole. By visualization and palpation, the surgeon begins gland dissection by isolating for the short right adrenal vein and dividing it between clips. The dissection can be performed with a combination of forceps diathermy, clips, and/or the harmonic scalpel. The left side is also performed through an anterior approach. After entering through the omentum and raising the stomach, a retroperitoneal incision along the lower edge of the body and tail of the pancreas is made. After dissection of retroperitoneal adhesions, the distal pancreas is lifted to show the left renal vein, left adrenal gland, and its central vein. The gland is dissected free from its surrounding structures, and the left adrenal vein is divided between clips [54].

4.4. Thoracoscopic transdiaphragmatic approach

The first clinical thoracoscopic adrenal biopsy was described in 1993 for non-small cell lung cancer (NSCLC) metastasis to the adrenal glands. Since then, successive experiments have described left adrenalectomy in swine models. In 2001, the access technique on four human cadavers was perfected and then performed in three patients with primary adrenal tumors and later expanded to right adrenalectomy. Transdiaphragmatic adrenalectomy was accomplished in all three cases without complication. This technique was performed after double lumen endotracheal intubation without pneumoinsufflation, and the patient was placed in the prone position. A total of four ports were used in the transthoracic approaches [55–57]. The diaphragm was incised under thoracoscope vision and then entered through the retroperitoneal space to identify the adrenal gland. The adrenal vasculature was controlled, and complete mobilization of adrenal gland was performed. The specimen was entrapped and retrieved through a thoracic port. The diaphragm was suture repaired with intracorporeal knot tying, and a chest tube was placed. Conditions that may preclude this approach include cardiopulmonary diseases and previous thoracic surgery.

4.5. Natural orifice transluminal endoscopic surgery (NOTES)

Since the first transvaginal cholecystectomy performed by Marescaux et al. 30 years ago, these procedures are performed to achieve less invasiveness during surgery [58]. Natural orifice transluminal endoscopic surgery (NOTES) is a technique that allows entry into the peritoneal cavity through transgastric or transvaginal or transcolonic access to avoid surgical scars.

Currently, NOTES has been employed on porcine and cadaveric models. Right and left adrenalectomies with a transvaginal retroperitoneal approach in a porcine model by a 1 cm posterolateral colpotomy have been performed and described [59]. The retroperitoneal tunnel is created using carbon dioxide. Dissection by movement of gastroscope up to the superior pole of kidney allows access to the adrenal gland. The vascular pedicle is identified and controlled by clips or endloop. The authors concluded that this access is also possible in human cadavers.

Zou and colleagues reportedly treated 11 consecutive women for adrenal diseases with NOTES, but with assisted-laparoscopy [60]. Under general anesthesia, patients were placed

in the lithotomy position with the affected side elevated at 30°. A 5-mm trocar and a 10-mm trocar were inserted in the umbilical edge for conventional operating apparatus, and a 10-mm trocar was inserted in the posterior vaginal fornix for a conventional 30° laparoscope. Carbon dioxide pneumoperitoneum was achieved by Veress needle, and dissection was performed according to standard laparoscopic adrenalectomy with conventional operating apparatus placed in the abdomen under direct vision achieved by a conventional 30° laparoscope placed through a vaginal trocar. The dissection and mobilization of left colonic flexure for left adrenalectomy and right colonic flexure for right adrenalectomy should be performed. Similar to traditional approaches, the adrenal gland is mobilized and the vascular supply ligated. The specimen is then removed through the posterior vaginal fornix. Recent data from the literature suggest that this combined technique is feasible and effective. With ongoing development of technique and instruments, it may be an alternative technique for the treatment of some women with adrenal tumors because of its improved cosmetic results. For NOTES, further clinical studies and more practiced surgical skills are needed.

4.5.1. Robotic adrenalectomy

Although the benefits of laparoscopic adrenalectomy are well known, its drawbacks include the two-dimensional view, unstable camera platform, poor ergonomics, and rigid instrumentation. Subsequently, robotic technology has been recently introduced to join the armamentarium of minimally invasive adrenal surgery with capabilities of three-dimensional view, wristed instrument, and a stable camera platform [61]. Since the first fully robotic adrenalectomy in 2002, many studies have shown the safety and efficacy of robotic adrenalectomy (RA) [62, 63]. Transperitoneal and retroperitoneal RA approaches demonstrating the efficacy of both techniques have been described in several reports [64, 65]. Current drawbacks, however, associated with RA include its cost, technical difficulty, need of advanced training and a team with the technical expertise to ensure operative success [66–68]. It is still controversial as to whether the RA should be performed by the transperitoneal or retroperitoneal approach. Several surgeons prefer the retroperitoneal technique in patients with tumors < 6 cm in size [69]. Although it necessitates previous experience with the transperitoneal approach, the retroperitoneal approach is preferred in patients with abdominal scarring and adhesions.

Right robotic adrenalectomy is performed with the patient in the left lateral decubitus position. The table is flexed at the level of the kidneys. Trocar position and surgical steps are comparable to traditional transabdominal lateral laparoscopic adrenalectomy. The triangular liver ligament is divided as cranially as possible to release the liver. Access to retroperitoneum and right adrenal gland is obtained by incision of the posterior peritoneum along the posterior border of visceral surface of the liver with detection of the IVC. After the duodenum is Kocherized, the lateral border of the IVC and right renal vein is identified. Dissecting cranially along the lateral border of the IVC, the right adrenal vein is encountered, dissected, and clipped. The right adrenal gland with any associated pathology is then progressively dissected off of the superior pole of the kidney and retroperitoneum in a circumferential manner with electrocautery. After checking for hemostasis by lowering the pneumoperitoneum, a laparoscopic entrapment sac is introduced by the assistant, and the specimen is placed into the sac. After undocking the robot, the bagged specimen is extracted through the accessory port.

Left robotic adrenalectomy is performed with the patient in the right lateral decubitus position. After the placement of the trocars in a conventional way according to the transabdominal lateral approach, the splenorenal ligament is transected. Mobilization of the spleen and pancreatic tail, made easier by gravity, allows for dissection of the left adrenal gland in the retroperitoneal fat, and identification and hemostasis of the left adrenal vein. The subsequent phases of circumferential dissection of the left adrenal gland, specimen retrieval with the closing of port-sites are identical to that described for right robotic adrenalectomy.

Comparison between laparoscopic and robotic adrenalectomy outcomes is similar including operative time, postoperative complications, hospital stay, and conversion rate [70]. In the future, RA will likely assume an increased role in the management of surgical disease. Research teams are dedicated to the development of robotic systems with greater intelligence and instruments with expanded capabilities, and it is essential that surgeons continue to evaluate these new technologies.

5. Authors' institutional experience

The surgical experience from the authors' institution that examines the outcomes of laparoscopic transperitoneal adrenalectomy is presented. Laparoscopic adrenalectomy has become the procedure of choice for most adrenal pathologies with multiple studies demonstrating significant benefits of this minimally invasive surgical approach compared to open adrenalectomy in terms of reduced operative morbidity, blood loss, analgesic requirements, shorter hospital stay, and earlier return to normal activity.

Over a 10-year period (2006–2015), the authors treated 76 patients with adrenal lesions. The laparoscopic transperitoneal approach was performed in 67 patients; open procedures were chosen in nine patients. **Tables 1** and **2** report the demographic and clinical features of these patients who underwent laparoscopic transperitoneal adrenalectomy.

All patients underwent preoperative biochemical testing and CT and MRI imaging studies. MIBG was used in selected patients. Indications for surgical treatment included: hyperactive adrenal tumors in patients with Conn's syndrome, Cushing's syndrome (**Figure 4**), and pheochromocytoma; and in those patients with non-hyperfunctional adrenal lesions such as cortical adenomas (**Figure 5**), myelolipomas, oncocytomas, and incidentalomas (**Figure 6**).

The operative outcomes for laparoscopic adrenalectomy at the authors' institution (**Table 3**) reveal very low conversion, perioperative, and postoperative complication rates. Operative time and blood loss were comparable to results reported in the literature.

Patients	N = 67
Functioning neoplasms	35 (52.38%)
Non-functioning neoplasms	32 (47.62%)

Table 1. Functional appearances.

Patients	N = 67	*P value
Age		
Mean (SD)	50.87 (14.40)	0.295
Median	51.25	
Range	20–73	
BMI		
Mean (SD)	26.16 (3.84)	0.393
Median	25.5	
Range	19.5–33	
ASA score		
Mean (SD)	1.50 (0.67)	0.245
Median	1	
Range	I–III	

*P value obtained from Mann-Whitney U test.

Table 2. Demographic and clinical features.

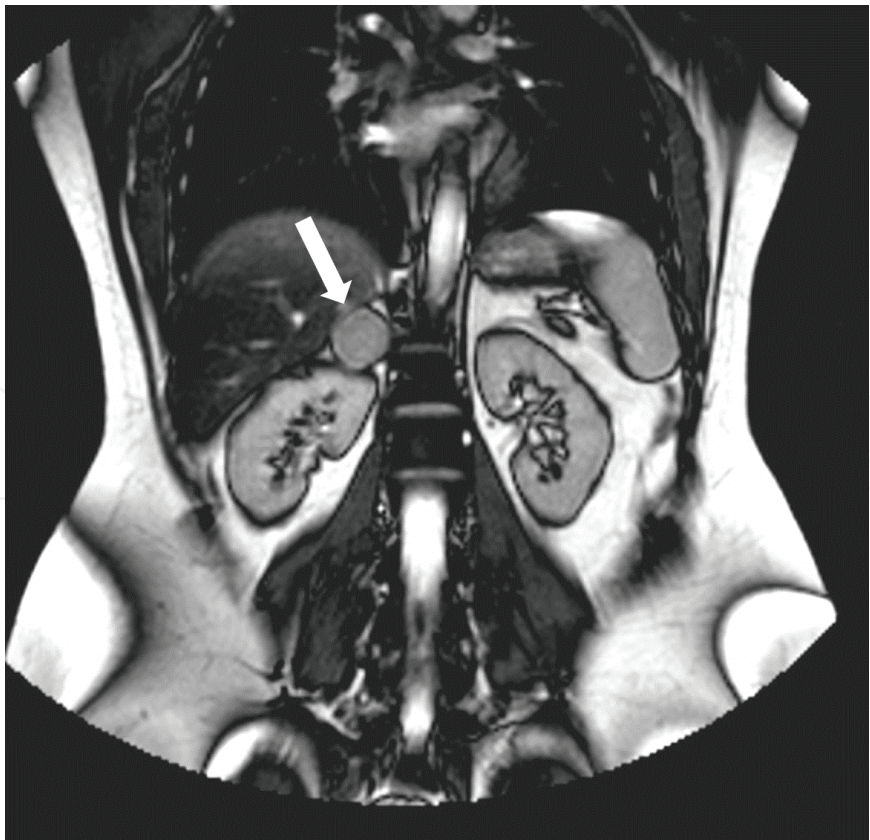


Figure 4. MRI: right adrenal adenoma (Cushing’s syndrome).

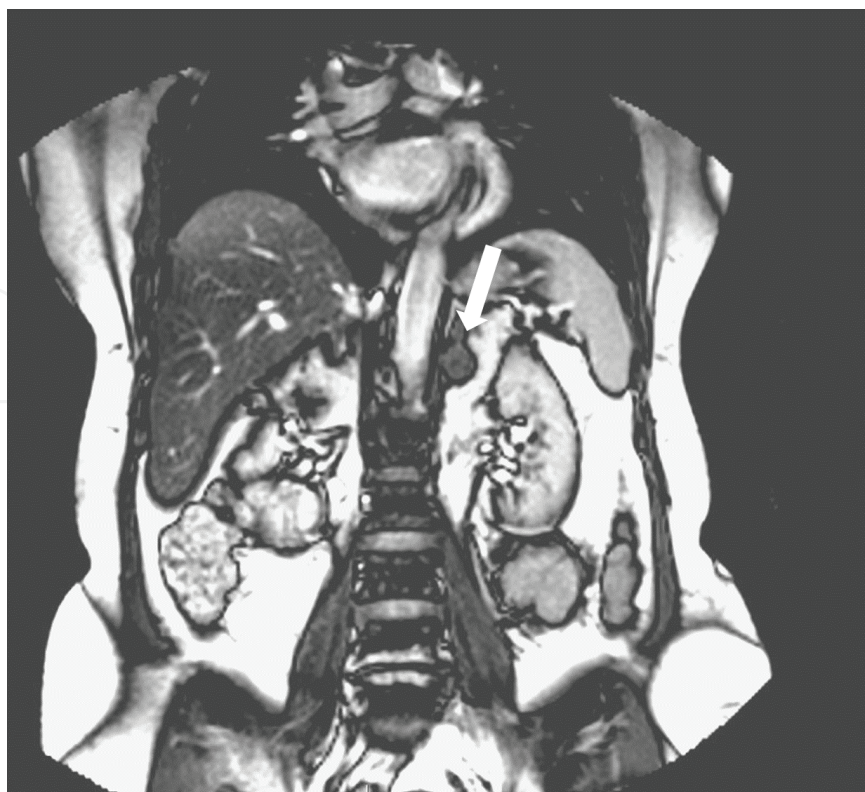

Figure 5. MRI: left adrenal cortical adenoma.

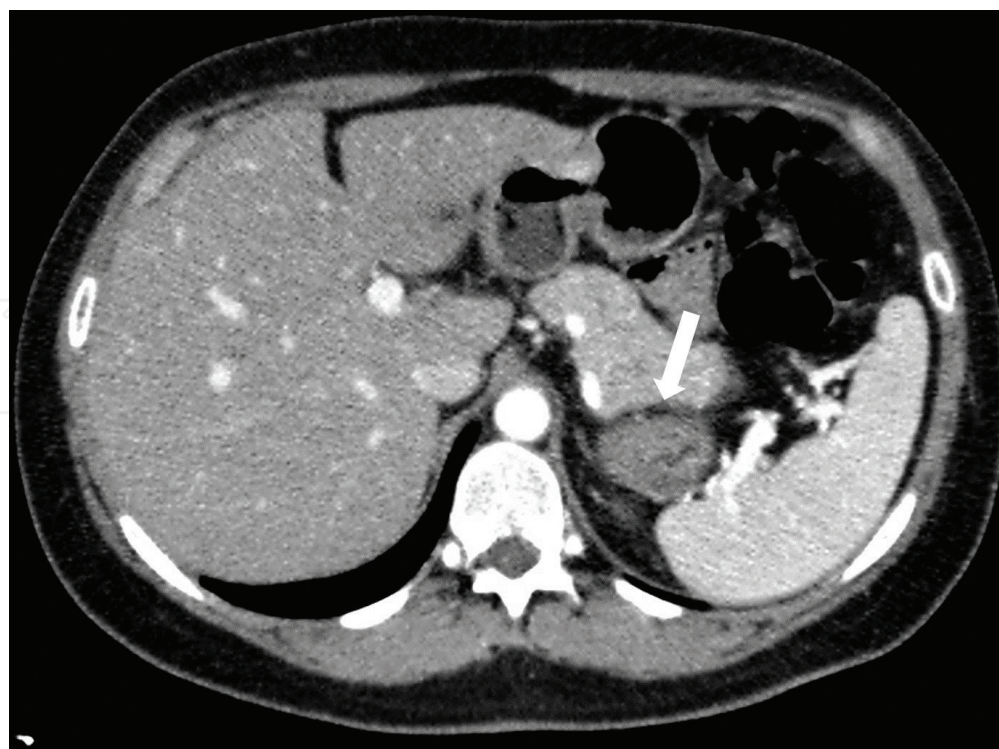

Figure 6. CT: left adrenal incidentaloma.

Patients	N = 67	*P value
Operative time (min)		
Mean (SD)	143 (34.27)	0.012
Median	138.75	
Range	105–210	
Blood loss (ml)		
Mean (SD)	87.22 (33.50)	0.006
Median	82	
Range	50–188	
Conversion rate (%)	5/67 (7%)	0.116
Gland size (cm)		
Mean (SD)	5.81 (1.37)	0.168
Median	5.5	
Range	3.7–9	
Tumor size (cm)		
Mean (SD)	3.13 (1.49)	0.113
Median	2.8	
Range	1.15–6.5	
Postoperative ambulation (hours)		
Mean (SD)	31.25 (8.94)	0.142
Median	27.75	
Range	22–47.5	
Hospital stay (days)		
Mean (SD)	4.05 (1.09)	0.452
Median	4	
Range	3–6	
Perioperative complication rate (%)	1/67 (2%)	0.5
Postoperative complication rate (%)	6/67 (9%)	0.697

*P value obtained from Mann-Whitney U-test (operative time, blood loss, gland size, tumor size, postoperative ambulation, and postoperative hospitalization) and Fisher exact test (conversion, perioperative complication and postoperative complication).

Table 3. Intraoperative and postoperative results of laparoscopic adrenalectomy.

The authors prefer laparoscopic transperitoneal lateral adrenalectomy for all patients with adrenal diseases. In their opinion, the laparoscopic transperitoneal and retroperitoneal approaches are essentially equivalent in relation to the surgical skill and surgeon experience.

Choice of the procedure is strongly influenced by the background training of the surgeon. The transperitoneal access allows for complete dissection and control of the adrenal mass and its vascular supply. Most important is the careful dissection of the right adrenal gland that is partially retrocaval with a short adrenal vein that flows directly into the inferior vena cava posterolaterally. Surgical dissection on right side involves close proximity of the liver, duodenum, and right kidney.

Anatomic structures around the left adrenal gland can make dissection difficult. The left adrenal gland is in close proximity with the tail of the pancreas and spleen; the splenopancreatic complex should be widely mobilized and, in some cases, mobilization of the splenic flexure of the colon may be required for adequate exposure of the left adrenal gland. In contrast to the right, along left adrenal vein usually flows into the left renal vein. Some variations of this venous supply can occur (5–6% of cases) and can predispose to intraoperative bleeding [71]. The authors customarily place a drain at the end of their procedure.

For large adrenal tumors, lateral, superior, and inferior dissection of the mass is initially performed because earlier mobilization of the gland can allow easier access to the adrenal vein. More recent surgical devices for dissection and hemostasis have been useful in reducing operative time, but are not essential in the performance of successful adrenalectomy. At their institution, the authors routinely use a monobipolar scalpel and mechanical clips for hemostasis during adrenalectomies that have provided satisfactory results.

6. Conclusion

Minimally invasive adrenalectomy is the preferred surgical treatment of adrenal tumors at many specialized medical centers worldwide. The laparoscopic transabdominal lateral operative technique is most commonly performed. The choice of laparoscopic transabdominal or retroperitoneal adrenalectomy is strongly influenced by background training, skill, and experience of the surgeon. Two issues that constantly evolve with minimally invasive adrenalectomy are a size limit of adrenal mass and appropriateness for malignant adrenal tumors. Some relative limits to laparoscopic adrenalectomy are adrenal tumors >9 cm. Contraindication to minimally invasive adrenalectomy is determined by local neoplastic invasiveness outside the adrenal gland capsule into the periadrenal fat usually delineated by preoperative CT and MRI imaging studies.

Author details

Pasquale Cianci, Alberto Fersini, Nicola Tartaglia, Sabino Capuzzolo, Libero Luca Giambavichio, Antonio Ambrosi and Vincenzo Neri*

*Address all correspondence to: vincenzo.neri@unifg.it

Department of Medical and Surgical Sciences, University of Foggia, Foggia, Italy

References

- [1] Sing PK, Buch HN. Adrenal incidentaloma: Evaluation and management. *Journal of Clinical Pathology*. 2008;**61**:1168–1173
- [2] Bovio S, Cataldi A, Raimondo G, et al. Prevalence of adrenal incidentaloma in a contemporary computerized tomography series. *Journal of Endocrinological Investigation*. 2006;**29**:298–302
- [3] Arnaldi G, Angeli A, Atkinson AB, et al. Diagnosis and complications of Cushing's Syndrome: A consensus statement. *The Journal of Clinical Endocrinology & Metabolism*. 2003;**88**:5593–5602
- [4] Young WF Jr. Minireview: Primary aldosteronism changing concepts in diagnosis and treatment. *Endocrinology*. 2003;**144**:2208–2213
- [5] Bravo EL, Tagle R. Pheochromocytoma: State of the art and future prospects. *Endocrine Reviews*. 2003;**24**:539–553
- [6] Kapoor A, Morris T, Rebello R. Guidelines for the management of the incidentally discovered adrenal mass. *Canadian Urological Association Journal*. 2011;**5**:241–247
- [7] Boland GW, Blake MH, Hahn PF, et al. Incidental adrenal lesions: principles, techniques and algorithms for imaging characterization. *Radiology*. 2008;**249**:756–775
- [8] Hamrahian HH, Ioachimescu AG, Remer EM, et al. Clinical utility of noncontrast computed tomography attenuation value (Hounsfield units) to differentiate adrenal adenomas/hyperplasias from nonadenomas: Cleveland clinic experience. *The Journal of Clinical Endocrinology and Metabolism*. 2005;**90**: 871–877
- [9] Sturgeon C, Shen WT, Clark OH, et al. Risk assessment in 457 adrenal cortical carcinoma; how much does tumor size predict the likelihood of malignancy? *Journal of the American College of Surgeons*. 2006;**202**:423–430
- [10] Thompson L. Pheochromocytoma of the adrenal gland scaled score (PASS) to separate benign from malignant neoplasms. *The American Journal of Surgical Pathology*. 2002;**26**:551–566
- [11] Fernandez MR, Pallares PB, Menendez Torre E, et al. Pheochromocytoma of the adrenal gland scaled score (PASS) as a predictor of aggressive biologic behavior. *Endocrine Abstract 2010*; 22P44—12th European Congress Endocrinology; 22–28 April 2010; Prague
- [12] Machado NO, Qadhi H, Wahaibi K, et al. Laparoscopic adrenalectomy for large adrenocortical carcinoma. *Journal of the Society of Laparoendoscopic Surgeons*. 2015;**19**(3)-e2015.00036
- [13] Porpiglia F, Destefanis P, Fiori C, et al. Does adrenal mass size really affect safety and effectiveness of laparoscopic adrenalectomy? *Urology*. 2002;**60**:801–805

- [14] Kelebew E, Siperstein AE, Clark OH, et al. Results of laparoscopic adrenalectomy for suspected and unsuspected malignant adrenal neoplasms. *Archives of Surgery*. 2002;**137**: 948–951
- [15] Walz MK, Petersenn S, Koch JA, et al. Endoscopic treatment of large primary adrenal tumors. *British Journal of Surgery*. 2005;**92**:719–723
- [16] Palazzo FF, Sebag F, Sierra M, et al. Long-term outcome following laparoscopic adrenalectomy for large solid adrenal cortex tumors. *World Journal of Surgery*. 2006;**30**:893–898
- [17] Ramacciato G, Mercantini P, La Torre M, et al. Is laparoscopic adrenalectomy safe and effective for adrenal masses larger than 7 cm? *Surgical Endoscopy*. 2008;**22**:516–521
- [18] Porpiglia F, Miller BS, Manfredi M, et al. A debate on laparoscopic versus open adrenalectomy for adrenocortical carcinoma. *Hormones and Cancer*. 2011;**2**(6):372–377
- [19] Latronico AC, Chrousos GP. Extensive personal experience: Adrenocortical tumors. *The Journal of Clinical Endocrinology and Metabolism*. 1997;**82**:1317–1324
- [20] Dackiw AP, Lee JE, Gagel RF, et al. Adrenal cortical carcinoma. *World Journal of Surgery*. 2001;**25**:914–926
- [21] Kebelew E, Duh QY. Benign and malignant pheochromocytoma: Diagnosis, treatment and follow-up. *Surgical Oncology Clinics of North America*. 1998;**7**:765–789
- [22] Kim SH, Brennan MF, Russo P, et al. The role of surgery in the treatment of clinically isolated adrenal metastasis. *Cancer*. 1998;**82**:389–394
- [23] Corcione F, Miranda L, Marzano E, et al. Laparoscopic adrenalectomy for malignant neoplasm: our experience in 15 cases. *Surgical Endoscopy*. 2005;**19**:841–844
- [24] Sun C-Y, Ho Y-F, Ding W-H, et al. Laparoscopic adrenalectomy for adrenal tumors. *International Journal of Endocrinology*. 2014. DOI: 10.1155/2014/241854
- [25] Pedziwiatr M, Wierda KM, Natkanier M, et al. Laparoscopic transperitoneal lateral adrenalectomy for malignant and potentially malignant adrenal tumors. *BMC Surgery*. 2015;**15**:101–107
- [26] Sroka G, Slijper N, Shteinberg D, et al. Laparoscopic adrenalectomy for malignant lesions: Safe and effective! SAGES abstract archive. 2012-SS07-S042
- [27] Cobb WS, Kercher KW, Sing RF, et al. Laparoscopic adrenalectomy for malignancy. *The American Journal of Surgery*. 2005;**189**:405–411
- [28] Zografos GN, Vasiliadis G, Farfaras AN, et al. Laparoscopic surgery for malignant adrenal tumors. *Journal of the Society of Laparoendoscopic Surgeons*. 2009;**13**:196–202
- [29] Donatini G, Caiazzo R, Do Cao CD, et al. Long-term survival after adrenalectomy for stage I/II adrenocortical carcinoma (ACC): A retrospective comparative cohort study of laparoscopic versus open approach. *Annals of Surgical Oncology*. 2014;**21**:284–291

- [30] Porpiglia F, Fiori C, Daffara F, et al. Retrospective evaluation of the outcome of open versus laparoscopic adrenalectomy for stage I and II adrenocortical cancer. *European Urology*. 2010;**57**:873–878
- [31] Fossa A, Rosok BI, Kazaryan AM, et al. Laparoscopic versus open surgery in stage I–III adrenocortical carcinoma: A retrospective comparison of 32 patients. *Acta Oncologica*. 2013;**52**:1771–1777
- [32] Lombardi CP, Raffaelli M, De Crea C, et al. Open versus endoscopic adrenalectomy in the treatment of localized (stage I/II) adrenocortical carcinoma: Results of a multiinstitutional Italian survey. *Surgery*. 2012;**152**:1158–1164
- [33] Foxius A, Ramboux A, Lefebvre Y, et al. Hazards of laparoscopic adrenalectomy for Conn's adenoma when enthusiasm turns to tragedy. *Surgical Endoscopy - Springer*. 1999;**13**:715–717
- [34] Miller BS, Ammori JB, Gauger PG, et al. Laparoscopic resection is inappropriate in patients with known or suspected adrenocortical carcinoma. *World Journal of Surgery*. 2010;**34**:1380–1385
- [35] Leboulleux S, Deandreis D, AlGhuzlan A, et al. Adrenocortical carcinoma: Is the surgical approach a risk factor of peritoneal carcinomatosis? *European Journal of Endocrinology*. 2010;**162**:1147–1153
- [36] Gagner M, Lacroix A, Bolté E. Laparoscopic adrenalectomy in Cushing's syndrome and pheochromocytoma. *The New England Journal of Medicine*. 1 Oct 1992;**327**(14):1033
- [37] Fernández-Cruz L, Saenz A, Benarroch G, et al. Laparoscopic unilateral and bilateral adrenalectomy for Cushing's syndrome. Transperitoneal and retroperitoneal approaches. *Annals of Surgery*. 1996;**224**:727–736
- [38] Lee J, El-Tamer M, Schiffneretal JB, Inabnet WB, 3rd. Open and laparoscopic adrenalectomy: Analysis of the national surgical quality improvement program. *Journal of the American College of Surgeons*. 2008;**206**: 953–961
- [39] Assalia A, Gagner M. Laparoscopic adrenalectomy. *British Journal of Surgery*. Oct 2004;**91**(10):1259–1274
- [40] Cianci P, Fersini A, Tartaglia N, et al. Are there differences between the right and left laparoscopic adrenalectomy? Our experience. *AnnaliItaliani di Chirurgia*. 2016;**87**:242–246
- [41] Fernández-Cruz L, Saenz A, Taura P, et al. Retroperitoneal approach in laparoscopic adrenalectomy: Is it advantageous? *Surgical Endoscopy*. Jan 1999;**13**(1):86–90
- [42] Takeda M. Laparoscopic adrenalectomy: Transperitoneal vs retroperitoneal approaches. *Biomedicine & Pharmacotherapy*. 2000;**54**(Suppl 1):207s-210s
- [43] Lezoche E, Guerrieri M, Paganini AM, et al. Laparoscopic adrenalectomy by the anterior transperitoneal approach. Results of 108 operations in unselected cases. *Surgical Endoscopy*. 2000;**14**:920–925

- [44] Chiu AW. Laparoscopic retroperitoneal adrenalectomy: Clinical experience with 120 consecutive cases. *Asian Journal of Surgery*. 2003;**26**:139–144
- [45] Bonjer HJ, Sorm V, Berends FJ, et al. Endoscopic retroperitoneal adrenalectomy: Lessons learned from 111 consecutive cases. *Annals of Surgery*. 2000;**232**:796–803
- [46] Gasman D, Droupy S, Koutani A, et al. Laparoscopic adrenalectomy: The retroperitoneal approach. *The Journal of Urology*. 1998;**156**:1816–1820
- [47] Soulié M, Mouly P, Caron P, et al. Retroperitoneal laparoscopic adrenalectomy: Clinical experience in 52 procedures. *Urology*. 2000;**56**:921–925
- [48] Salomon L, Soulié M, Mouly P, et al. Experience with retroperitoneal laparoscopic adrenalectomy in 115 procedures. *The Journal of Urology*. 2001;**166**:38–41
- [49] Fazeli-Matin S, Gill IS, Hsu TH, et al. Laparoscopic renal and adrenal surgery in obese patients: Comparison to open surgery. *The Journal of Urology*. 1999;**162**:665–670
- [50] Wolf JS Jr, Monk TG, McDougall EM, et al. The extraperitoneal approach and subcutaneous emphysema are associated with greater absorption of carbon dioxide during laparoscopic renal surgery. *The Journal of Urology*. 1995;**154**:959–963
- [51] Ng CS, Gill IS, Sung GT, et al. Retroperitoneoscopic surgery was not associated with increased carbon dioxide absorption. *The Journal of Urology*. 1999;**162**:1268–1271
- [52] Walz MK, Alesina PF, Wenger FA, et al. Posterior retroperitoneoscopic adrenalectomy — Results of 560 procedures in 520 patients. *Surgery*. Dec 2006;**140**(6):943-948;discussion 948-950
- [53] Suzuki K, Ihara H, Mugiya S, et al. Complications of laparoscopic adrenalectomy in 75 patients treated by the same surgeon. *European Urology*. 1999;**36**:40–47
- [54] Bennet IC, Ray M. Hand-assisted laparoscopic adrenalectomy: An alternative minimal invasive surgical technique for the adrenal gland. *ANZ Journal of Surgery*. 2002;**72**:801–805
- [55] Mack MJ, Aronoff RJ, Acuff TE, et al. Thoracoscopic transdiaphragmatic approach for adrenal biopsy. *The Annals of Thoracic Surgery*. 1993;**55**:772–773
- [56] Pompeo E, Coosemans W, De Leyn P, et al. Thoracoscopic transdiaphragmatic left adrenalectomy. An experimental study. *Surgical Endoscopy*. 1997;**11**:390–392
- [57] Gill IS, Meraney AM, Thomas JC, et al. Thoracoscopic transdiaphragmatic adrenalectomy: The initial experience. *The Journal of Urology*. 2001;**165**:1875–1881
- [58] Marescaux J, Dallemagne B, Perretta S, et al. Surgery without scars: Report of transluminal cholecystectomy in a human being. *Archives of Surgery*. Sep 2007;**142**(9):823–826
- [59] Perretta S, Allemann P, Asakuma M, et al. Adrenalectomy using natural orifice transluminal endoscopic surgery (NOTES): A transvaginal retroperitoneal approach. *Surgical Endoscopy*. Jun 2009;**23**(6):1390. DOI: 10.1007/s00464-009-0367-9. Epub 5 Mar 2009

- [60] Zou X, Zhang G, Xiao R, et al. Transvaginal natural orifice transluminal endoscopic surgery (NOTES)-assisted laparoscopic adrenalectomy: First clinical experience. *Surgical Endoscopy*. Dec 2011;**25**(12):3767–3772. DOI: 10.1007/s00464-011-1786-y. Epub.3 Jun 2011
- [61] Horgan S, Vanuno D. Robots in laparoscopic surgery. *Journal of Laparoendoscopic & Advanced Surgical Techniques. Part A*. 2001 Dec;**11**(6):415–419
- [62] Young JA, Chapman WH 3rd, Kim VB, Albrecht RJ, Ng PC, Nifong LW, Chitwood WR Jr. Robotic-assisted adrenalectomy for adrenal incidentaloma: Case and review of the technique. *Surgical Laparoscopy, Endoscopy & Percutaneous Techniques*. Apr 2002;**12**(2):126–130
- [63] Hyams ES, Stifelman MD. The role of robotics for adrenal pathology. *Current Opinion in Urology*. 2009;**19**(1):89–96
- [64] Desai MM, Gill IS, Kaouk JH, et al. Robotic-assisted laparoscopic adrenalectomy. *Urology*. 2002 Dec;**60**(6):1104–1107
- [65] Berber E, Mitchell J, Milas M, et al. Robotic posterior retroperitoneal adrenalectomy: operative technique. *Archives of Surgery*. 2010 Aug;**145**(8):781–784
- [66] Merseburger AS, Herrmann TR, Shariat SF, et al. European Association of Urology. EAU guidelines on robotic and single-site surgery in urology. *European Urology* 2013;**64**:277–291
- [67] Brunaud L, Bresler L, Ayav A, et al. Robotic-assisted adrenalectomy: What advantages compared to lateral transperitoneal laparoscopic adrenalectomy? *The American Journal of Surgery*. 2008;**195**:433–438
- [68] Winter JM, Talamini MA, Stanfield CL, et al. Thirty robotic adrenalectomies: A single institution's experience. *Surgical Endoscopy*. 2006;**20**:119–124
- [69] Taskin HE, Berber E. Robotic adrenalectomy. *The Cancer Journal*. 2013;**19**(2):162–166
- [70] Brandao LF, Autorino R, Laydner H, et al. Robotic versus laparoscopic adrenalectomy: A systematic review and meta-analysis. *European Urology*. 2014;**65**(6):1154–1161
- [71] Sebe P, Peyromaure M, Raynand A, et al. Anatomical variations in the drainage of the principal adrenal veins: The results of 88 venograms. *Surgical and Radiologic Anatomy*. 2002;**24**:222–225