

# We are IntechOpen, the world's leading publisher of Open Access books Built by scientists, for scientists

6,900

Open access books available

186,000

International authors and editors

200M

Downloads

Our authors are among the

154

Countries delivered to

TOP 1%

most cited scientists

12.2%

Contributors from top 500 universities



WEB OF SCIENCE™

Selection of our books indexed in the Book Citation Index  
in Web of Science™ Core Collection (BKCI)

Interested in publishing with us?  
Contact [book.department@intechopen.com](mailto:book.department@intechopen.com)

Numbers displayed above are based on latest data collected.  
For more information visit [www.intechopen.com](http://www.intechopen.com)



---

# Stem Cell Therapy in Pediatric Neurological Disabilities

---

Alok Sharma, Hemangi Sane,  
Nandini Gokulchandran, Prerna Badhe,  
Pooja Kulkarni, Suhasini Pai, Ritu Varghese and  
Amruta Paranjape

Additional information is available at the end of the chapter

<http://dx.doi.org/10.5772/67656>

---

## Abstract

Pediatric neurological disorders represent a major part of the disabilities worldwide. In over 10 decades of research to find a cure for these disorders, medical science has not been able to repair the underlying brain injury. This chapter focuses on recent advances in the application of stem cells as a therapeutic tool for some of the common neurodevelopmental disorders (cerebral palsy, autism, intellectual disability and muscular dystrophy). The mechanism of action of stem cells in each disorder has been explained. A review of clinical data has been described giving a clear understanding of current status of stem cell therapy in these disorders. Various factors influencing the outcome of stem cell therapy such as different types of cells, different routes of administration and dosage and frequency of transplantation have also been discussed. Our experience of treating these disorders is exhibited in the form of our published data. Use of novel monitoring tools such as MRI MSK and PET-CT scan brain to track the changes occurring at cellular level after stem cell therapy are described. We also highlight the importance of a multi-disciplinary approach of combining rehabilitation with stem cell therapy.

**Keywords:** stem cell therapy, autism, cerebral palsy, muscular dystrophy, intellectual disability

---

## 1. Introduction

Neurodevelopmental disorders (NDD) are characterized by an abnormal development of the brain during the early development phase, leading to a myriad of symptoms and diseases, including delayed milestones and deficits in personal and social functioning [1]. The developmental deficits can vary from specific limitations of adaptive, behavioral and

cognitive functioning, motor dysfunction, to global impairments of social skills [2]. Some of the common neurodevelopmental disorders are cerebral palsy (CP), autism spectrum disorders, attention deficit hyperactivity disorder, intellectual disability (ID) or intellectual and developmental disability (IDD), learning disabilities, muscular dystrophies, Down's syndrome, genetic disorders such as fragile-X syndrome, spinal muscular atrophy (SMA) and metabolic disorders.

Pediatric neurological disorders represent a major part of the disabilities worldwide. In over 10 decades of research to find a cure for these disorders, medical science has not been able to repair the underlying brain injury [3]. The causes of NDD can be classified as congenital (present at birth) or acquired (developed after birth). The various etiologies are genetic defects, metabolic disorders, nutritional deficiencies, exposure to toxins, infections, hypoxia/asphyxia, low birth weight, perinatal complications leading to traumatic brain injury or spinal cord injury in children [4]. This may affect language and speech, motor skills, behavior, memory, learning or other neurological functions affecting activities of daily life. While the severity of symptoms often change or evolve as the child's age progresses, these disabilities remain permanent. As these are lifelong disabilities, they pose a substantial economic burden on the society [5]. Hence, finding a treatment for them is the need of the hour. Improvement in the performance of these children would be of great significance to the quality of life of patients and their families.

## 2. Unmet medical needs

Therapeutic strategies and clinical expectations of patients and medical professionals have not yet been met. Currently, available treatments such as physiotherapy, occupational therapy, behavioral therapy, psychological intervention, speech therapy and pharmacological intervention only focus on alleviating the symptoms of these disabilities and do not address the underlying neuropathophysiology. However, the advent of stem cell therapy has opened new avenues for treatment of pediatric neurological disorders. In recent years, extensive research has been done to explore the potential of stem cells for the treatment of pediatric neurological disabilities. Until now, it was believed that once injured, the cells of the central nervous system cannot regenerate. However, owing to the distinct properties of stem cells to repair and regenerate, they can be considered as a potential therapeutic strategy.

This chapter focuses on recent advances in the application of stem cells as a therapeutic tool for some of the common NDDs (cerebral palsy, autism, intellectual disability and muscular dystrophy). The mechanism of action of stem cells in each disorder has been explained. A review of clinical data has been described giving a clear understanding of current status of stem cell therapy in these disorders. Various factors influencing the outcome of stem cell therapy such as different types of cells, different routes of administration and dosage and frequency of transplantation have also been discussed. Our experience of treating these disorders is exhibited in the form of our published data. Use of novel monitoring tools such as MRI MSK and PET-CT scan brain to track the changes occurring at cellular level after stem cell therapy

is described. We also highlight the importance of a multidisciplinary approach of combining rehabilitation with stem cell therapy. Adverse effects of stem cell therapy are also enumerated.

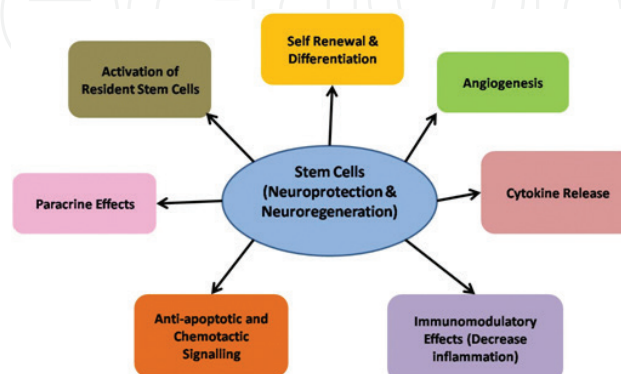
### 3. What are stem cells?

Stem cells are blank, immature cells which have a capacity to self-renew and differentiate into host-specific multiple lineage cells [6]. Several types of stem cells are being explored for the treatment of neurological disorders such as bone marrow stem cells, embryonic stem cells, olfactory ensheathing cells and umbilical cord blood cells. The main aim of stem cell therapy is replacement of injured/dead neuronal cells and recovery of lost functions [7]. These cells perform repair process directly by regeneration of new cells or indirectly through paracrine activity. The chief underlying mechanisms of stem cells include neuroregeneration, neuroreplacement, neuroprotection, immunomodulation, axon sprouting and neural circuit reconstruction [8] (**Figure 1**).

### 4. Mechanism of action of stem cells in pediatric neurological disorders

Pediatric neurological disorders are caused due to mechanisms affecting the molecular, cellular and tissue plasticity of the brain and nervous system [9].

Stem cells when transplanted migrate and home towards the injured areas of the brain [10]. This homing property is attributed to the expression of growth factors, chemokine and extracellular matrix receptors on the surface of cells such as stromal cell-derived factor 1 (SDF-1), monocyte chemo attractant protein-3 (MCP-3), stem cell factor (SCF) and/or IL-8. They differentiate into the host tissue cells and replace the injured/dead neuronal tissue [11]. Through paracrine mechanisms they halt further injury and stimulate endogenous cells to carry out the repair and restoration process [12]. Stem cells secrete a vast array of neuroprotective growth factors including brain-derived neurotrophic factor (BDNF), nerve growth factor (NGF), neurotrophin-3 (NT-3), glial cell line-derived neurotrophic factor (GDNF) and insulin-like



**Figure 1.** Mechanism of action of stem cells in pediatric neurological disorders.

growth factor type 1. These growth factors activate a number of signaling pathways and help in enhancing differentiation, survival of neurons and maintaining neuronal functions [13]. They also produce vascular endothelial growth factor (VEGF), hepatocyte growth factor (HGF) and basic fibroblast growth factor (FGF-2) which improve perfusion and enhance angiogenesis [14]. Anti-inflammatory paracrine factors such as Interleukin 10 (IL 10) and Transforming growth factor (TGF)- $\beta$  help in immunomodulation [15].

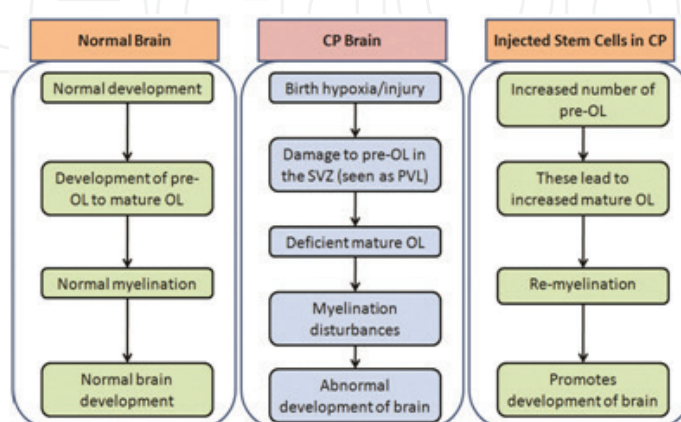
## 5. Clinical application of stem cell therapy in NDD

In this section, we discuss the literature review of various stem cell therapy studies in each disorder followed by our experience.

We published a study of 71 children diagnosed with different incurable neurological disorders. Autologous bone marrow-derived mononuclear cells were transplanted intrathecally and intramuscularly. Improvements were noted in muscle power, functional independent measure (FIM) and Brooke and Vignos scale. Imaging and electrophysiological investigations also showed improvement. Overall 97% muscular dystrophy cases showed subjective, functional and investigational improvement. Eighty-five percent of cases of cerebral palsy cases showed improvements. Eighty-eight percent of cases of other incurable neurological disorders such as autism, Retts syndrome and giant axonal neuropathy also showed improvement. No major adverse events were noted.

## 6. Stem cell therapy in cerebral palsy

In cerebral palsy, white matter injury also known as periventricular leukomalacia (PVL) is one of the major pathologies observed [16]. Stem cells differentiate into neurons, oligodendrocytes and astrocytes which replace and repair the white matter injury in CP [17] (**Figure 2**). The growth factors secreted by these cells also help in remyelination, synaptogenesis, cytoprotection and angiogenesis which reverse the cellular injury in CP [18, 19]. Numerous preclinical studies have



**Figure 2.** Stem cell therapy in cerebral palsy.

demonstrated the potential of stem cell transplantation in cerebral palsy. The homing property of these cells was confirmed by Chen et al., who transplanted magnetically labeled mesenchymal stem cells in a model of perinatal brain injury and found that these cells migrate to lesion sites and proliferate [20]. Studies have demonstrated the differentiation of bone marrow, umbilical cord blood, neural and other progenitor stem cells into neurons and oligodendrocytes in experimental animal models [21–25]. Transplantation of stem cells in rat models have resulted in improved cognition and sensorimotor deficits along with functional recovery [26].

### 6.1. Clinical evidence

In cerebral palsy, around 26 studies have been published explaining the effect of stem cell therapy. Overall, 579 (90%) out of 646 patients have shown improvements (**Table 1**) [20, 27–51].

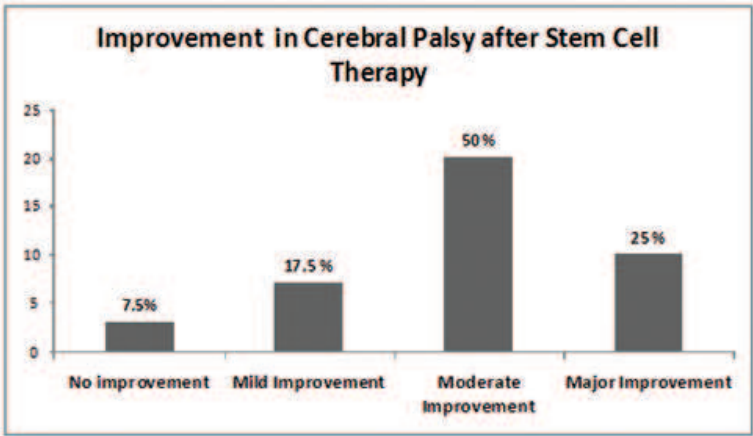
Sr. no	Citations	Cells used	Route of administration	Sample size	Patient improved	Adverse events
1.	Sharma et al. [27]	Autologous bone marrow mononuclear cells (BMMNCs)	Intrathecal	40	None	
2.	Min et al. [28]	Allogenic umbilical cord blood	Intravenous	96	86	Pneumonia and irritability
3.	Lee et al. [29]	Autologous umbilical cord blood	Intravenous	20	5	Nausea, hemoglobinuria or urticaria
4.	Purandare et al. [30]	Autologous BMMNCs	Intrathecal	1	1	None
5.	Chen et al. [20]	Autologous bone marrow mesenchymal cells	Subarachnoid	60	60	Increased frequency of crying
6.	Li et al. [31]	Autologous bone marrow mesenchymal cells	Subarachnoid	1	1	None
7.	Luan et al. [32]	Neural progenitor cells	Intracranial	45	45	None
8.	Chen et al. [33]	Olfactory ensheathing cells	Intracranial	33	33	None
9.	Ramirez et al. [34]	Umbilical cord blood cells	Intramuscular injection	8	8	Localized mild pain at the site of injection.
10.	Payne [35]	Umbilical cord blood cells	Subcutaneous	16	16	None
11.	Sharma et al. [36]	Autologous BMMNCs	Intrathecal	1	1	None
12.	Sharma et al. [37]	Autologous BMMNCs	Intrathecal	1	1	None
13.	Papadopoulos et al. [38]	Autologous BMMNCs	Intrathecal	2	2	None
14.	Sharma et al. [39]	Autologous BMMNCs	Intrathecal	1	1	None
15.	Jensen and Hamelmann [40]	Autologous umbilical cord blood cells	Intravenous	1	1	None
16.	Wang et al. [41]	Umbilical cord mesenchymal stem cells	Intravenous and intrathecal administration	1	1	Temporary low-grade fever
17.	Luan et al. [42]	Human neural stem cells	Intracerebral	7	4	None



Sr. no	Citations	Cells used	Route of administration	Sample size	Patient improved	Adverse events
18.	Wang et al. [43]	Bone marrow mesenchymal stromal cells	–	52	52	none
19.	Yang et al. [44]	Umbilical cord mesenchymal stem cell	Intravenous and intrathecal	25	22	none
20.	Zali et al. [45]	CD133-positive enriched bone marrow progenitor cells	Intrathecal	12	12	seizure
21.	Mancías-Guerra et al. [46]	Autologous bone marrow–derived total nucleated cell (TNC)	Intrathecal and intravenous injection	18	18	Headache, vomiting, fever and stiff neck
22.	Romanov et al. [47]	Allogenic umbilical cord blood cells	Intravenous	80	80	None
23.	Zang et al. [48]	Umbilical cord blood mesenchymal stem cells	Intravenous	1	1	None
24.	Wang et al. [49]	Umbilical cord–derived mesenchymal stromal cell	Subarachnoid	16 (8 pair of twins)	16 (8 pair of twins)	None
25.	Shroff et al. [50]	Human embryonic stem cells	Intravenous	91	63	Seizures
26.	Abi Chahine et al. [51]	Bone marrow mononuclear cells	Intrathecal	17	11	Headaches, transient fever and vomiting

**Table 1.** Clinical evidence demonstrating the use of stem cells in cerebral palsy.

In 2015, we published a nonrandomized study demonstrating the benefits of autologous bone marrow mononuclear cells (BMMNCs) in cerebral palsy [27]. These patients were followed up at 3 and 6 months. Six months after intervention, 38 out of 40 (95%) patients showed improvements and 2 did not show any improvement but remained stable without any deterioration (**Figure 3**). No major adverse events were noted except for seizures in two patients which were controlled by medications.



**Figure 3.** Graph showing improvement in children with cerebral palsy after stem cell therapy.

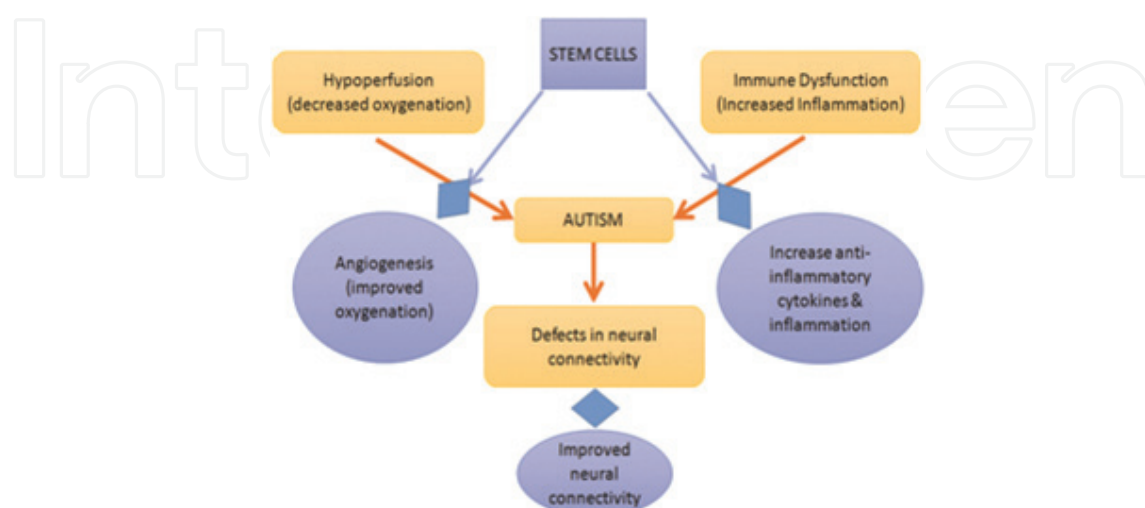
We have also published three case reports demonstrating the safety and efficacy of BMMNC transplantation in cerebral palsy [36, 37, 39]. In these case reports, the functional improvements are supported by improved brain metabolism recorded in comparative PET-CT scans performed before and after the intervention.

## 7. Stem cell therapy in autism

In autism, immune dysfunction, hypoperfusion, oxidative stress, decreased number of Purkinje cells (PCs), cerebellum alterations, defective cortical organization and altered plasticity of dendritic spine morphology are the underlying neuropathologies (**Figure 4**) [52, 53]. Stem cells modulate the immune dysfunction by releasing anti-inflammatory molecules and inhibiting pro-inflammatory molecules, which further reduces neural injury [54]. They also facilitate angiogenesis which increases blood and oxygen supply to the brain thus reversing the hypoperfusion [55]. Stem cells may also reinforce cortical plasticity, promote synaptic plasticity and restore cerebellar PCs [56]. These mechanisms collectively may improve the lost neural connectivity and restore lost functions in autism. In an experimental model of mice, H Segal Gavish et al. transplanted mesenchymal stem cells, which resulted in reduction of stereotypical behaviors, decrease in cognitive rigidity and improvement in social behavior. Tissue analysis revealed elevated BDNF protein levels in the hippocampus accompanied by increased hippocampal neurogenesis in the MSC-transplanted mice compared with sham treated mice [57].

### 7.1. Clinical evidence

A total of 11 studies (3 case series and 8 case reports) have been published all over the world demonstrating the benefits of stem cell therapy in autism. Overall, 122 patients were administered with cellular therapy and 90 showed improvements (**Table 2**) [58–68].



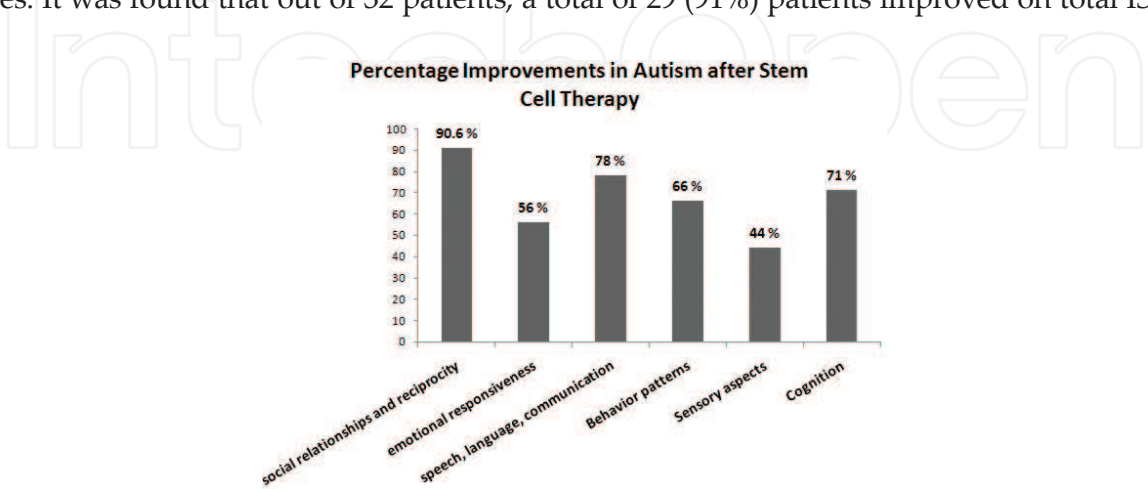
**Figure 4.** Stem cell therapy in autism.



Author	Type of cells used	Route of administration	Sample size	How many patients improved	Demonstrated safety
Sharma et al. [58]	Autologous bone marrow mononuclear cells (BMMNCs)	Intrathecal	32	29	Yes
Lv et al. [59]	Human cord blood mononuclear cells (CBMNCs) and umbilical cord-derived mesenchymal stem cells (UCMSCs)	Intravenous and intrathecal	37	18	Yes
Bradstreet et al. [60]	Fetal stem cells	Subcutaneous	45	35	Yes
Sharma et al. [61]	Autologous BMMNCs	Intrathecal	1	1	Yes
Sharma et al. [62]	Autologous BMMNCs	Intrathecal	1	1	Yes
Sharma et al. [63]	Autologous BMMNCs	Intrathecal	1	1	Yes
Sharma et al. [64]	Autologous BMMNCs	Intrathecal	1	1	Yes
Sharma et al. [65]	Autologous BMMNCs	Intrathecal	1	1	Yes
Sharma et al. [66]	Autologous BMMNCs	Intrathecal	1	1	Yes
Sharma et al. [67]	Autologous BMMNCs	Intrathecal	1	1	Yes
Sharma et al. [68]	Autologous BMMNCs	Intrathecal	1	1	Yes

**Table 2.** Clinical evidence demonstrating the use of stem cells in autism.

In 2013, we published an open label proof of concept study which included 32 patients of autism [58] (**Figure 5**). These patients were followed up for 26 months (mean 12.7). The outcome measures used were Childhood Autism Rating Scale (CARS), Indian Scale for Autism Assessment (ISAA), Clinical Global Impression (CGI) and Functional Independence Measure (FIM/Wee-FIM) scales. It was found that out of 32 patients, a total of 29 (91%) patients improved on total ISAA



**Figure 5.** Graph showing percentage improvement in various symptoms of autism post stem cell therapy.

scores and 20 patients (62%) showed decreased severity on CGI-I. On CGI-II 96% of patients showed global improvement. Improvements in brain metabolism were also observed on positron emission tomography-computed tomography (PET-CT) scan brain. All 32 patients were monitored through the duration of follow-up for any major adverse events. Incidence of seizures was recorded in three patients, which were reversible and easily controlled with medications.

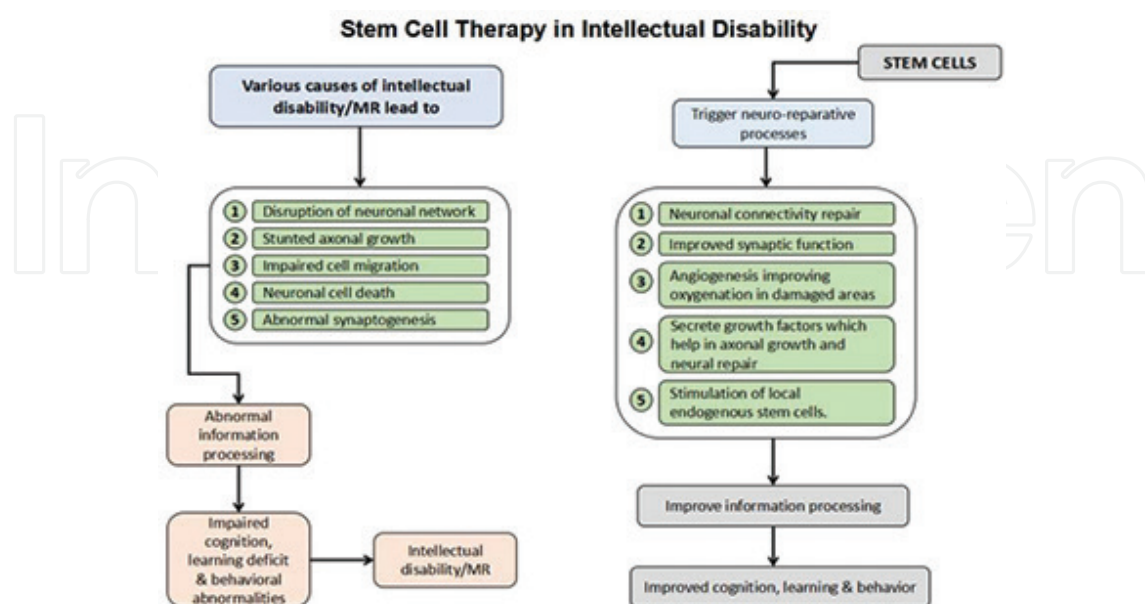
In addition to the above study, we have also published eight case reports demonstrating the safety, efficacy and objective improvements on PET-CT scan brain in patients with autism following stem cell therapy [61–68].

## 8. Stem cell therapy in intellectual disability

In intellectual disability (ID), the neuronal connectivity in the brain is impaired along with disrupted cell migration, cell multiplication, axon growth, brain plasticity and synaptogenesis (**Figure 6**) [9]. Studies have recorded defects in hippocampus and cerebral cortex areas of the brain leading to faulty information processing, consecutively affecting cognition and adaptive behavior in ID. Stem cells restore the synaptic transmitters released and provide local reinnervations to the area affected. It also integrates existing neural and synaptic network and re-establishes connections of functional afferent and efferent cells which may have contributed in restoring the cognitive and functional deficit in IDs [69].

### 8.1. Clinical evidence

We are currently under process of analyzing the data of a prospective study conducted to demonstrate the effect of autologous bone marrow mononuclear cells in intellectual disability.



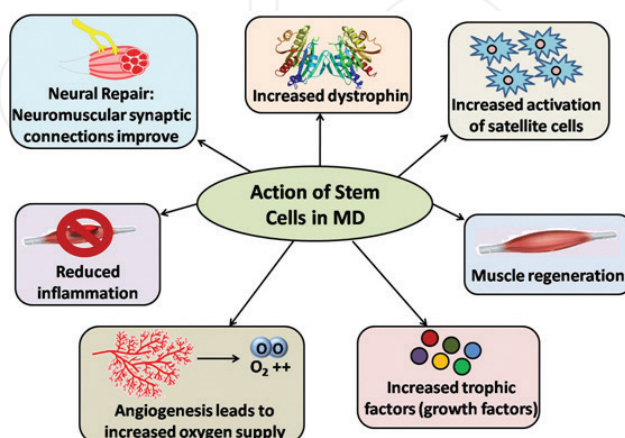
**Figure 6.** Stem cell therapy in intellectual disabilities.

However, in 2015, we published a report of a 13-year-old boy with intellectual disability who exhibited improvements after stem cell therapy [70]. He was followed up after 3 and 6 months of intervention. No major adverse events were recorded post intervention. Over a period of 6 months, he showed improved eye contact, cognition, learning ability, behavior and ability to perform activities of daily living. His score on Functional Independence Measure (FIM) increased from 67 to 76. On comparing the pre and post PET-CT scan, improvement in metabolic activity of hippocampus, left amygdala and cerebellum was recorded. These changes correlated to the functional outcome.

## 9. Stem cell therapy in Duchenne muscular dystrophy

The underlying pathogenic mechanism of muscular dystrophy is an imbalance between muscle degeneration and resident satellite cell-mediated regeneration [71]. Satellite cells, the adult skeletal muscle progenitor cells, are considered to be the main cell type involved in skeletal muscle regeneration. Continuous cycles of degeneration and regeneration of muscle fibers exhausts the muscle stem cell pool, leading to muscle being replaced by adipose and fibrotic tissue. Stem cell therapy holds great promise as a treatment for Duchenne muscular dystrophy by providing cells that can both deliver functional muscle proteins and replenish the stem cell pool [72].

Stem cells are known to enhance angiogenesis, contribute to neovascularization, promote tissue remodeling, prevent apoptosis, decrease inflammation, release growth factors and activate the satellite cells [73] (**Figure 7**). In animal models, these cells have shown to produce the deficient proteins and make new muscle cells which fuse with the host fibers. Further, stem cell-derived exosomes which are small membrane vesicles and are responsible for inter-cellular communication, promote muscle regeneration by enhancing myogenesis and angiogenesis [74].



**Figure 7.** Role of stem cells in muscular dystrophy.

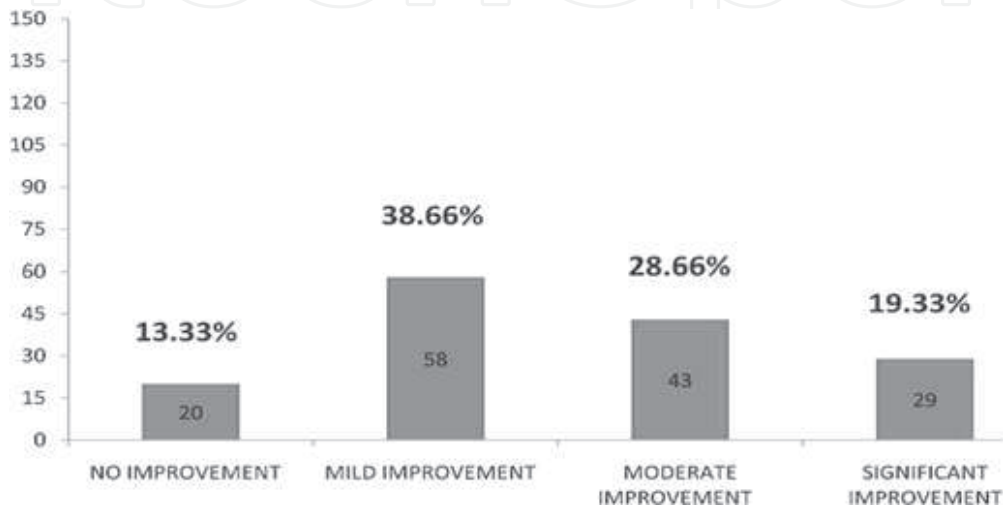
## 9.1. Clinical evidence

A total of 14 studies have been conducted demonstrating the efficacy of stem cells in muscular dystrophy. Various types of stem cells such as bone marrow–derived cells, umbilical cord stem cells and muscle-derived cells were used. Out of a total of 346 patients who underwent stem cell therapy, 296 showed a positive outcome (**Table 3**) [75–90].

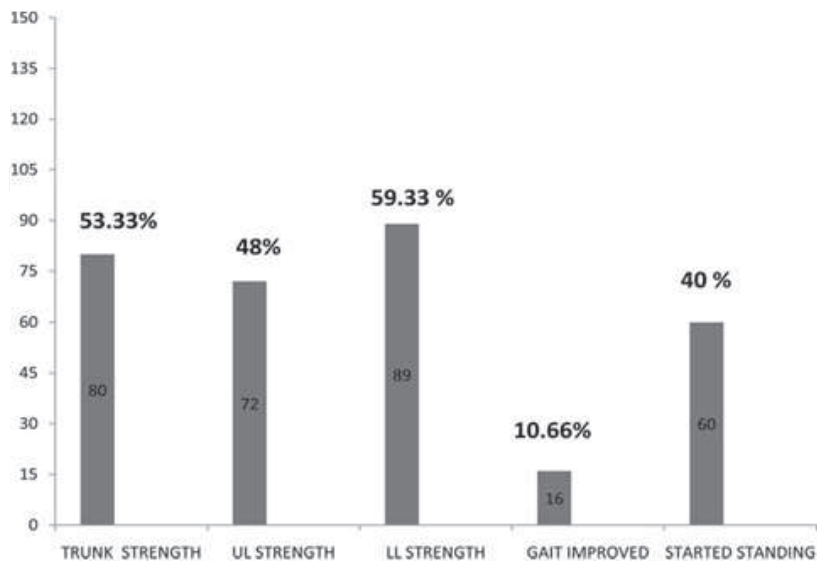
Author	Sample size	Type of cells used	Route of administration	Number of patients improved	Level of evidence
Torrente et al. [75]	8	Muscle-derived CD133 <sup>+</sup> cell	Intramuscular	8	4
Yang et al. [76]	82	Autologous bone marrow mesenchymal stem cells (BMSC) and umbilical cord mesenchymal stem cells (UMSC)	Intravenous and intramuscular	Effective in 68 [82.9%] cases.	4
Mendell et al. [77]	12	Muscle precursor cells	Intramuscular	In one patient, 10.3% of muscle fibers expressed donor-derived dystrophin after myoblast transfer. Three other patients also had a low level of donor dystrophin; eight had none.	4
Sharma et al [78]	150	BMMNCs	Intrathecal, Intramuscular	130 [86.67%] cases showed symptomatic and functional improvements	4
Rajput et al. [79]	16	Human umbilical cord mesenchymal stem cells	IV and IM injection	9 out of 11 patients were stable no deterioration.	
Sharma et al. [80]	65	BMMNCs	Intrathecal, Intramuscular	65 (plateau phase, no further progression)	4
Skuk et al. [81]	1	Muscle-precursor cells	Intramuscular	27.5% of the myofiber profiles expressed donor-derived dystrophin, 1 month post-transplantation and 34.5%, 18 months post-transplantation	5
Sharma et al. [82–87]	6 case reports	BMMNCs	Intrathecal, Intramuscular	6	5
Kang et al. [88]	1	Umbilical cord–derived hematopoietic stem cell	Intrathecal	not effective	5
Skuk et al. [89]	3	Myogenic cells	Intramuscular	dystrophin-positive myofibers in the cell-grafted sites amounting to 9 (patient 1), 6.8 (patient 2) and 11% (patient 3).	
Zhang et al. [90]	1	Allogeneic cord blood stem cells	Intravenous	1	5

**Table 3.** Clinical evidence demonstrating the use of stem cells in muscular dystrophy.

We conducted a study on 150 patients diagnosed with muscular dystrophy. On a mean follow up period of 12 months  $\pm$  1 month, 86.67% cases showed symptomatic and functional improvements, with six patients showing muscle regeneration and decrease in fatty infiltration on musculoskeletal magnetic resonance imaging (MRI MSK) and nine showing improved muscle electrical activity on electromyography (EMG). Fifty-three percent cases showed increase in trunk muscle strength, 48% an increase in upper limb (UL) strength, 59% an increase in lower limb (LL) strength and about 10% showed an improved gait pattern (Figures 8 and 9).



**Figure 8.** Graph showing improvements in muscular dystrophy patients after stem cell therapy. *y*-axis = number of patients (*n* = 150).



**Figure 9.** Graph showing symptomatic improvements in muscular dystrophy patients after stem cell therapy. Number of patients showing improvements in trunk strength, upper limb (UL) strength, lower limb (LL) strength, gait pattern, and standing function are shown. *y*-axis = number of patients (*n* = 150).

## 10. Adverse events of stem cell therapy

The adverse events following stem cell transplantation mainly depends on the type of stem cell and the route of administration. Other factors like dosage of cells, frequency of transplantation and age of the patient may also contribute. Fetal stem cells are known to be potentially tumorigenic [91]. Use of umbilical cord stem cells is limited due to slow or incomplete immune reconstitution, resulting in a high transplantation-related mortality (TRM) due to infections. Most studies have demonstrated a predominance of Gram-positive bacteria (GPB) bloodstream infections [92]. On the contrary, adult stem cell has not shown any serious adverse events. Autologous cell transplantation is safer than allogenic.

Adverse events of stem cell therapy can be categorized into minor and major adverse events. Minor adverse events include procedure related events such as spinal headache, nausea, diarrhea, vomiting, pain or bleeding at the site of aspiration/injection and fever amongst others. These are treated using medications. Anesthetic complications and allergic reactions may also occur depending on the procedure. Major adverse events include episodes of seizures occurring after intervention. These can be managed prophylactically. Pre-existing epileptogenic focus in Electroencephalogram (EEG) also predicts the occurrence of seizures. Evidence suggests that antiepileptic prophylactic regimen decreases the incidence of seizures as an adverse event after stem cell therapy [93].

## 11. Factors influencing the outcome of stem cell therapy for NDDs

### 11.1. Routes of administration

The route of delivery of cells plays an important role in maximizing the clinical output of cellular therapy. Intrathecal route of administration is a relatively minimally invasive and targeted route of administration of cells. It is devoid of any major side effects [94]. In neurological disorders, intrathecal transplantation enhances the accessibility of the injected cells into the CNS [95]. Intramuscular injections are administered at the motor points plotted on the affected muscles. Motor points are the points where the innervating nerve enters the muscle. Thus, implantation of cells in the muscles enhances the effect of stem cells on the degenerating muscles [96]. Intravenous administration is the least invasive route. However, evidence suggests that majority of cells get trapped in the pulmonary passage and only few cells reach the injured site [97]. An alternate route of administration is via intra-cerebral route. But, it is an invasive technique and might result in secondary complications such as bleeding and neural tissue injury [98]. Hence, as compared to all the delivery routes, intrathecal administration is most efficacious.

### 11.2. Types of cells

Cells used from allogenic sources have an inherent risk of immunogenicity and may potentially cause immune rejection of graft versus host disease. Autologous cells have the least



possibility of immune reaction and so far clinical studies with autologous minimally manipulated cells have shown no immunogenic reactions in the host post transplantation. Autologous cells may therefore be a safer option in children with NDD.

### **11.3. Etiology**

Genetic factors play a major part in the pathology of neurological disorders and gene therapy has provided novel insights in treating the underlying genetic aberrations. But gene therapy cannot replace the lost neurons and practical difficulties have prevented it from being a clinically feasible and viable option at present. The sporadic nature of the disease is also an important factor influencing the outcome, where the etiology of the disease is unknown. Stem cell therapy addresses the core injury occurring in the brain. The multiple mechanism of action of the stem cells addresses the multifactorial pathology of the NDD.

### **11.4. Severity**

It has been observed that the mild cases of neurodevelopment disorders have a better recovery curve than the chronic cases. In mild cases, axonal function remains intact and recovery can be rapid if remyelination occurs. In severe cases, axonal degeneration occurs and recovery depends on axonal regeneration. Recovery becomes much slower, and there is a greater degree of residual injury. Mild cases require lesser dosage of cells and the frequency of doses required is less to attain potential recovery than the severe cases.

### **11.5. Age of the patient**

One of postulated hypothesis is that the neural circuits, that form the basis for learning, behavior and health, are more plastic during the initial years of life. They become increasingly difficult to alter over time. Age-related decline in the potency of the stem cells is observed which might also affect the remodeling of CNS by these cells. Early intervention is advised for better outcome of stem cell therapy.

## **12. Importance of neurorehabilitation**

Neurorehabilitation aims at restoration and maximization of functions that have been lost due to impairments caused by injury or disease of nervous system making the patient functionally independent. The rehabilitation regime promotes and facilitates neural plasticity [99]. Studies have shown that exercise enhances the effect of injected stem cells by inducing mobility of the cells, activating and proliferating the local stem cells, promoting muscle angiogenesis and release of cytokines and nerve growth factors. Hence, neurorehabilitation compliments with the stem cell therapy [100].

### 13. Objective evidence: neuroimaging techniques to monitor the outcome of stem cell therapy

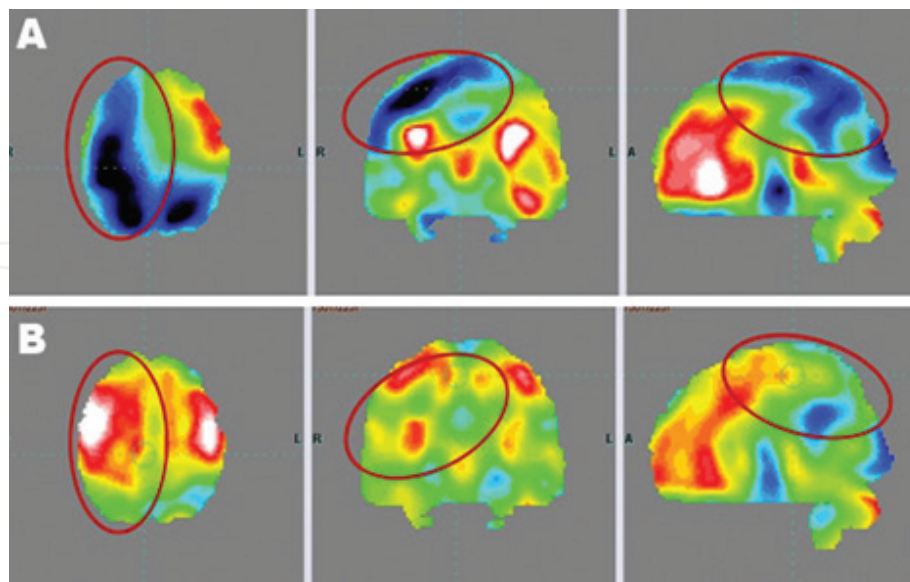
Neuroimaging techniques enable the quantitative measurement of various biological markers which may serve as a powerful tool for optimizing the use of stem cells for clinical applications.

#### 13.1. Positron emission tomography (PET-CT) scan brain

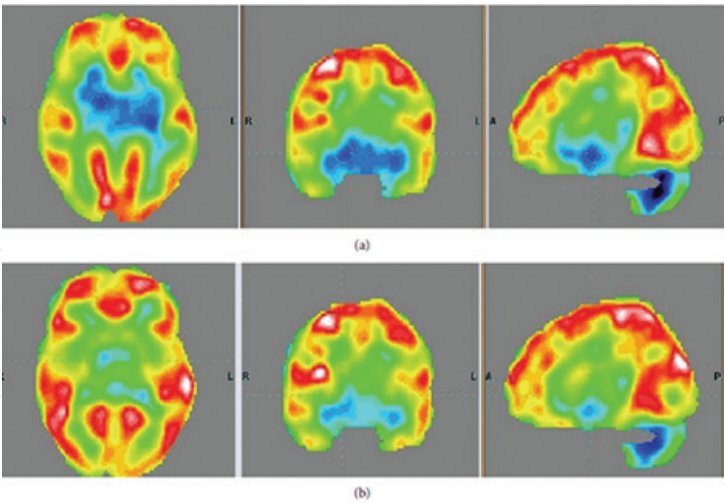
PET-CT scan brain can be used efficiently as a monitoring tool to study the outcome of stem cell therapy. One of the advantages of using PET-CT is its extreme sensitivity enabling it to detect molecules at the nanomolar level [101]. Brain 18F-FDG PET allows studying the cerebral glucose metabolism, indicating the neuronal and synaptic activity. It dynamically measures the energy metabolism along with blood oxygenation and blood flow [102]. The alteration in neuronal activity caused by disease is reflected in change of glucose metabolism and can be revealed in the PET-CT scan brain. As mentioned previously in the clinical results, there were improvements recorded in the brain metabolism of patients included in the clinical studies. The changes seen on PET-CT scan brain correlated with the clinical improvement indicating that it can identify alteration occurring at the tissue levels (**Figures 10–12**).

#### 13.2. Magnetic resonance imaging (MRI)

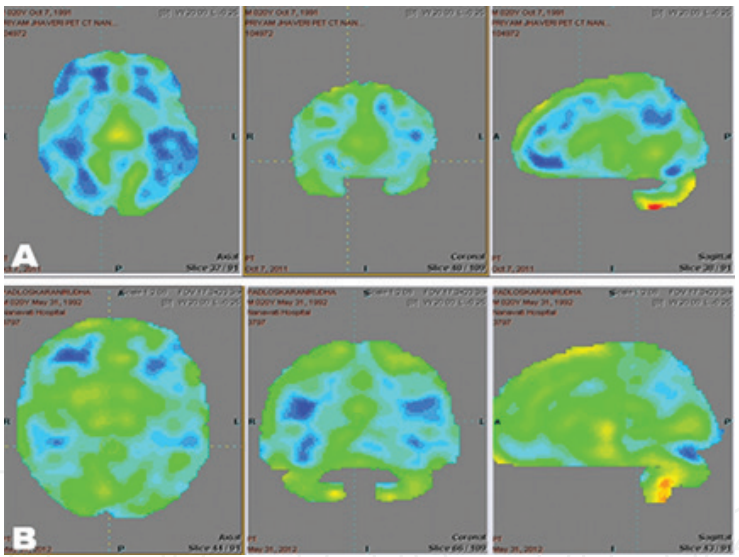
Magnetic resonance imaging (MRI) is gaining popularity because of its capacity to reveal characteristic findings that address the diagnosis and support therapeutic interventions.



**Figure 10.** (A) Pre SCT PET-CT scan images with blue areas indicating hypometabolism. (B) These areas have almost disappeared after SCT as seen in the post PET-CT scan image. This shows improvement in the metabolism/functioning in the affected areas of the brain after SCT.



**Figure 11.** Findings in PET-CT scan before and after cellular therapy. (a) PET-CT scan before intervention showing reduced FDG uptake in the areas of frontal lobe, cerebellum, amygdala, hippocampus, parahippocampus, and mesial temporal lobe. (b) PET-CT scan six months after intervention comparison shows increased FDG uptake in the areas of frontal lobe, cerebellum, amygdala, hippocampus, parahippocampus, and mesial temporal lobe.



**Figure 12.** (A) Pre stem cell therapy PET-CT scan showing blue areas with hypometabolism. (B) Post stem cell therapy PET-CT scan showing decrease in blue areas which is replaced by green areas indicating improved functioning of the brain.

Since MRI is devoid of ionizing radiations, it has turned out to be a valuable imaging method in children, although sometimes sedation might be necessary. In the past few years, studies have reported on the detection of muscle involvement pattern in various muscular dystrophies through MRI musculoskeletal imaging (MRI/MSK). The images provide a high soft tissue contrast allowing assessment of affected striated muscles in terms of shape, volume (hypotrophy and hypertrophy) and architecture [103, 104]. MRI MSK was used as a tool to

assess the therapeutic efficacy of stem cell therapy in muscular dystrophy. In our published data, images of MRI MSK performed after intervention has revealed stabilization of disease progression in muscular dystrophy.

## 14. Conclusion

In children, the brain is still at a developing stage and not fully matured resulting in maximal neural plasticity during childhood. Hence, likelihood of improvement in affected areas of the brain increases manifold with early intervention. Stem cell therapy has recently gained lot of importance as a therapeutic strategy for various disorders including NDDs. In this review, we have demonstrated the outcome of stem cell therapy in NDDs mainly cerebral palsy, autism, intellectual disability and muscular dystrophy supported by our published data. Through its neurorestorative and neuroregenerative property, stem cells have the capacity of repairing the underlying neural and muscular dysfunction. This property can augment neurodevelopment, facilitating achievement of milestones earlier as compared to the current conventional treatment modalities. In progressive developmental disorders like muscular dystrophies, stem cell therapy has shown to slow down the disease progression. The data also establishes the fact that autologous stem cell therapy is a safe and efficacious treatment which helps in recovery of lost functions and neural plasticity.

Though stem cell therapy is not a cure, the gap between normalcy and disability can be minimized. Stem cells in combination with the multidisciplinary medical and rehabilitative modalities can enhance and hasten the recovery from NDD which will help the patient to lead a productive and respectable life in the society.

## 15. Future directions

Stem cell therapy is still in its developing stage. There are still numerous uncertainties prevailing with respect to optimum volume of cells to be injected, number of doses, route of administration, types of cells amongst others. The advent of induced pluripotent stem cells (iPSCs) has provided opportunities for the study of human neurodevelopmental diseases in a controlled environment. Reprogramming cells from patients with neurological diseases will allow the study of disease-specific cellular and molecular pathways causing these diseases. Also, the establishment of neural stem cells (NSCs), a life-long source of neurons and glia, has contradicted the dogma that the nervous system lacked regenerative power. Future studies need to focus on the precautionary pre-intervention assessments to identify patients with high risk for seizures and related adverse events after stem cell therapy. A better knowledge of all these factors will improve the therapeutic effectiveness of stem cell therapy. Future studies should consider the use of modern radiological tools as monitoring

tool and substantiate the effects of cellular therapy in NDDs. Large scale, multicentre and randomized controlled trials are recommended to further establish the safety and efficacy of cellular therapy.

## Author details

Alok Sharma<sup>1</sup>, Hemangi Sane<sup>2</sup>, Nandini Gokulchandran<sup>1</sup>, Prerna Badhe<sup>3</sup>, Pooja Kulkarni<sup>2,3</sup>, Suhasini Pai<sup>2</sup>, Ritu Varghese<sup>2</sup> and Amruta Paranjape<sup>2,4</sup>

\*Address all correspondence to: poojakul28@gmail.com

1 Department of Medical Services and Clinical research, NeuroGen Brain & Spine Institute, Navi Mumbai, India

2 Department of Research & Development, NeuroGen Brain & Spine Institute, Navi Mumbai, India

3 Department of Regenerative Laboratory Services, NeuroGen Brain & Spine Institute, Navi Mumbai, India

4 Department of Neurorehabilitation, NeuroGen Brain & Spine Institute, Navi Mumbai, India

## References

- [1] Telias M, Ben-Yosef D. Modeling neurodevelopmental disorders using human pluripotent stem cells. *Stem Cell Reviews and Reports*. 2014;**10**(4):494–511
- [2] American Psychiatric Association. *Neurodevelopmental Disorders: DSM-5® Selections*. Arlington, VA: American Psychiatric Pub; 2015
- [3] Mullin AP, Gokhale A, Moreno-De-Luca A, Sanyal S, Waddington JL, Faundez, V. Neurodevelopmental disorders: Mechanisms and boundary definitions from genomes, interactomes and proteomes. *Translational Psychiatry*. 2013;**3**(12):e329
- [4] Kelleher E, Corvin A. Overlapping etiology of neurodevelopmental disorders. In: Mitchell KJ, editor. *The Genetics of Neurodevelopmental Disorders*. New Jersey: John Wiley & Sons, Inc. 2015.
- [5] World Health Organization. *Neurological Disorders: Public Health Challenges*. Geneva: World Health Organization; 2006.
- [6] Ul Hassan A, Hassan G, Rasool Z. Role of stem cells in treatment of neurological disorder. *International Journal of Health Sciences*. 2009;**3**(2):227–233
- [7] Lindvall O, Björklund A. Cell replacement therapy: Helping the brain to repair itself. *NeuroRx*. 2004;**1**(4):379–381



- [8] Karussis D, Kassis I, Kurkalli BG, Slavin S. Immunomodulation and neuroprotection with mesenchymal bone marrow stem cells (MSCs): A proposed treatment for multiple sclerosis and other neuroimmunological/neurodegenerative diseases. *Journal of Neurological Science*. 2008;**265**(1-2):131–135
- [9] Kroon T, Sierksma MC, Meredith RM. Investigating mechanisms underlying neurodevelopmental phenotypes of autistic and intellectual disability disorders: A perspective. *Frontiers in Systems Neuroscience*. 2013;**7**:75
- [10] Smart N, Riley PR. The stem cell movement. *Circulation Research*. 2008;**102**(10):1155–1168
- [11] Verma RS. Breaking dogma for future therapy using stem cell – Where we have reached? *The Indian Journal of Medical Research*. 2016;**143**(2):129–131
- [12] Baraniak PR, McDevitt TC. Stem cell paracrine actions and tissue regeneration. *Regenerative Medicine*. 2010;**5**(1):121–143
- [13] Hung C-W, Liou Y-J, Lu S-W, et al. Stem cell-based neuroprotective and neurorestorative strategies. *International Journal of Molecular Sciences*. 2010;**11**(5):2039–2055
- [14] Crisostomo PR, Wang M, Herring CM, Markel TA, Meldrum KK, Lillemoe KD, et al. Gender differences in injury induced mesenchymal stem cell apoptosis and VEGF, TNF, IL-6 expression: role of the 55 kDa TNF receptor (TNFR1). *Journal of Molecular and Cellular Cardiology*. 2007;**42**(1):142–149
- [15] Markel TA, Crisostomo PR, Wang M, Herring CM, Meldrum DR. Activation of individual tumor necrosis factor receptors differentially affects stem cell growth factor and cytokine production. *American Journal Physiology Gastrointestinal Liver Physiology*. 2007;**293**(4):G657–G662
- [16] Khwaja O, Volpe JJ. Pathogenesis of cerebral white matter injury of prematurity. *Archives of Disease in Childhood Fetal and Neonatal Edition*. 2008;**93**(2):F153–F161
- [17] Castillo-Melendez M, Yawno T, Jenkin G, Miller SL. Stem cell therapy to protect and repair the developing brain: A review of mechanisms of action of cord blood and amnion epithelial derived cells. *Frontiers in Neuroscience*. 2013;**7**:194.
- [18] Giulian D, Johnson B, Krebs JF, Tapscott MJ, Honda S. A growth factor from neuronal cell lines stimulates myelin protein synthesis in mammalian brain. *Journal of Neuroscience*. 1991;**11**(2):327–336
- [19] Garofalo L, Ribeiro-da-Silva A, Cuello AC. Nerve growth factor-induced synaptogenesis and hypertrophy of cortical cholinergic terminals. *Proceeding of National Academy of Sciences of the United States of America*. 1992;**89**:2639–2643
- [20] Chen G, Wang Y, Xu Z, Fang F, Xu R, Wang Y, Hu X, Fan L, Liu H. Neural stem cell-like cells derived from autologous bone mesenchymal stem cells for the treatment of patients with cerebral palsy. *Journal of Translational Medicine*. 2013;**11**:21



- [21] Woodbury D, Schwarz EJ, Prockop DJ, Black IB. Adult rat and human bone marrow stromal cells differentiate into neurons. *Journal of Neuroscience Research*. 2000;**61**:364–370
- [22] Wang XL, Zhao YS, Hu MY, Sun YQ, Chen YX, Bi XH. Umbilical cord blood cells regulate endogenous neural stem cell proliferation via hedgehog signaling in hypoxic ischemic neonatal rats. *Brain Research*. 2013;**1518**:26–35
- [23] Park KI, Himes BT, Stieg PE, Tessler A, Fischer I, Snyder EY. Neural stem cells may be uniquely suited for combined gene therapy and cell replacement: evidence from engraftment of Neurotrophin-3-expressing stem cells in hypoxic-ischemic brain injury. *Experimental Neurology*. 2006;**199**(1):179–190.
- [24] Yasuhara T, Matsukawa N, Yu G, Xu L, Mays RW, Kovach J, Deans RJ, Hess DC, Carroll JE, Borlongan CV. Behavioral and histological characterization of intrahippocampal grafts of human bone marrow-derived multipotent progenitor cells in neonatal rats with hypoxic-ischemic injury. *Cell Transplant*. 2006;**15**(3):231–238.
- [25] Webber DJ, van Blitterswijk M, Chandran S. Neuroprotective effect of oligodendrocyte precursor cell transplantation in a long-term model of periventricular leukomalacia. *American Journal of Pathology*. 2009;**175**(6):2332–2342
- [26] Pimentel-Coelho PM, Magalhães ES, Lopes LM, deAzevedo LC, Santiago MF, Mendez-Otero R. Human cord blood transplantation in a neonatal rat model of hypoxic-ischemic brain damage: Functional outcome related to neuroprotection in the striatum. *Stem Cells and Development*. 2010;**19**(3):351–358
- [27] Sharma A, Sane H, Gokulchandran N, Kulkarni P, Gandhi S, et al. A clinical study of autologous bone marrow mononuclear cells for cerebral palsy patients: a new frontier. *Stem Cells International*. 2015;**2015**:11 pages. Article ID 905874
- [28] Min K, Song J, Kang JY, Ko J, Ryu JS, Kang MS, Jang SJ, Kim SH, Oh D, Kim MK, Kim SS, Kim M. Umbilical cord blood therapy potentiated with erythropoietin for children with cerebral palsy: A double-blind, randomized, placebo-controlled trial. *Stem Cells*. 2013;**31**(3):581–591
- [29] Lee YH, et al. Safety and feasibility of countering neurological impairment by intravenous administration of autologous cord blood in cerebral palsy. *Journal of Translational Medicine*. 2012;**10**:58
- [30] Purandare C, Shitole DG, Belle V, Kedari A, Bora N, Joshi M. Therapeutic potential of autologous stem cell transplantation for cerebral palsy. *Case Reports in Transplantation*. 2012;**2012**:825289
- [31] Li M, Yu A, Zhang F, Dai GH, Cheng H, Wang X, An Y. Treatment of one case of cerebral palsy combined with posterior visual pathway injury using autologous bone marrow mesenchymal stem cells. *Journal of Translational Medicine*. 2012;**10**:100

- [32] Luan Z, Liu W, Qu S, Du K, He S, Wang Z, Yang Y, Wang C, Gong X. Effects of neural progenitor cell transplantation in children with severe cerebral palsy. *Cell Transplantation*. 2012;**21**(Suppl 1):S91-S98
- [33] Chen L, Huang H, Xi H, Xie Z, Liu R. Intracranial transplant of olfactory ensheathing cells in children and adolescents with cerebral palsy: A randomized controlled clinical trial. *Cell Transplantation*. 2010;**19**(2):185–191.
- [34] Ramirez F, Steenblock D, Payne AG, Darnall L. Umbilical cord stem cell therapy for cerebral palsy. *Medical Hypotheses and Research*. 2006;**3**:679–686
- [35] Payne G. Beneficial effects of subcutaneously injected human umbilical cord stem cells on cerebral palsy and traumatic brain injury in children and a posited mechanism. *Medical Hypotheses and Research*. 2005;**2**(3):497–501
- [36] Sharma A, Sane H, Paranjape A, Gokulchandran N, Kulkarni P, Nagrajan A, Badhe P. Positron emission tomography–computer tomography scan used as a monitoring tool following cellular therapy in cerebral palsy and mental retardation – A case report. *Case Reports in Neurological Medicine*. 2013;**2013**:6 pages. Article ID 141983
- [37] Sharma A, Kulkarni P, Sane H, Gokulchandran N, Badhe P, Lohia M, Mishra P. Positron emission tomography–computed tomography scan captures the effects of cellular therapy in a case of cerebral palsy. *Journal of Clinical Case Reports*. 2012;**2**:195
- [38] Papadopoulos KI, Low SS, Aw TC, Chantarojanasiri T. Safety and feasibility of autologous umbilical cord blood transfusion in 2 toddlers with cerebral palsy and the role of low dose granulocyte-colony stimulating factor injections. *Restorative Neurology and Neuroscience*. 2011;**29**(1):17–22
- [39] Sharma A, Sane H, Kulkarni P, D'sa M, Gokulchandran N, Badhe P. Improved quality of life in a case of cerebral palsy after bone marrow mononuclear cell transplantation. *Cell Journal*. 2015;**17**(2):389–394
- [40] Jensen A, Hamelmann E. First autologous cell therapy of cerebral palsy caused by hypoxic-ischemic brain damage in a child after cardiac arrest-individual treatment with cord blood. *Case Report of Transplantation*. 2013;**2013**:951827
- [41] Wang L, Ji H, Zhou J, Xie J, Zhong Z, et al. Therapeutic potential of umbilical cord mesenchymal stromal cells transplantation for cerebral palsy: A case report. *Case Report of Transplantation*. 2013;**2013**:146347.
- [42] Luan Z, Qu SQ, Liu WP, et al. Treatment of heteroptics after cerebral palsy with transplantation of human neural stem cells into cerebral ventricle in infants: 7 case report. *Zhongguo Kangfu Lilun yu Shijian*. 2007;**13**(12):1103–1105
- [43] Wang X, Cheng H, Hua R, Yang J, Dai G, Zhang Z, Wang R, Qin C, An Y. Effects of bone marrow mesenchymal stromal cells on gross motor function measure scores of children with cerebral palsy: A preliminary clinical study. *Cytotherapy*. 2013;**15**(12):1549–1562

- [44] Wang X, Hu H, Hua R, Yang J, Zheng P, Niu X, Cheng H, Dai G, Liu X, Zhang Z, An Y. Effect of umbilical cord mesenchymal stromal cells on motor functions of identical twins with cerebral palsy: pilot study on the correlation of efficacy and hereditary factors. *Cytotherapy*. 2015;**17**(2):224-31.
- [45] Zali A, Arab L, Ashrafi F, Mardpour S, Niknejhadi M, et al. Intrathecal injection of CD133-positive enriched bone marrow progenitor cells in children with cerebral palsy: Feasibility and safety. *Cytotherapy*. 2015;**17**(2):232-241
- [46] Mancías-Guerra C, Marroquín-Escamilla AR, González-Llano O, Villarreal-Martínez L, Jaime-Pérez JC, et al. Safety and tolerability of intrathecal delivery of autologous bone marrow nucleated cells in children with cerebral palsy: An open-label phase I trial. *Cytotherapy*. 2014;**16**(6):810-820
- [47] Romanov YA, Tarakanov OP, Radaev SM, Dugina TN, Ryaskina SS, et al. Human allogeneic AB0/Rh-identical umbilical cord blood cells in the treatment of juvenile patients with cerebral palsy. *Cytotherapy* 2015;**17**(7):969-978
- [48] Zhang C, Huang L, Gu J, Zhou X. Therapy for cerebral palsy by human umbilical cord blood mesenchymal stem cells transplantation combined with basic rehabilitation treatment: a case report. *Global Pediatric Health*. 2015;**2**:1-7
- [49] Wang X, Hu H, Hua R, Yang J, Zheng P, et al. Effect of umbilical cord mesenchymal stromal cells on motor functions of identical twins with cerebral palsy: Pilot study on the correlation of efficacy and hereditary factors. *Cytotherapy*. 2015;**17**(2):224-231
- [50] Shroff G, Gupta A, Barthakur JK. Therapeutic potential of human embryonic stem cell transplantation in patients with cerebral palsy. *Journal of Translational Medicine*. 2014;**12**(1):1
- [51] Abi Chahine NH, Wehbe TW, Hilal RA, Zoghbi VV, Melki AE, Bou Habib EB. Treatment of cerebral palsy with stem cells: A report of 17 cases. *International Journal of Stem Cells*. 2016;**9**(1):90-95
- [52] Fatemi SH, Aldinger KA, Ashwood P, Bauman ML, Blaha CD, et al. Consensus paper: Pathological role of the cerebellum in autism. *Cerebellum (London, England)* 2012;**11**(3):777-807
- [53] Sajdel-Sulkowska EM, Xu M, McGinnis W, Koibuchi N. Brain region-specific changes in oxidative stress and neurotrophin levels in autism spectrum disorders (ASD). *Cerebellum*. 2011;**10**(1):43-48
- [54] Wada N, Gronthos S, Bartold PM. Immunomodulatory effects of stem cells. *Periodontology* 2000. 2013;**63**(1):198-216
- [55] Oswald J, Boxberger S, Jørgensen B, Feldmann S, Ehninger G, Bornhäuser M, Werner C. Mesenchymal stem cells can be differentiated into endothelial cells in vitro. *Stem Cells*. 2004;**22**(3):377-384

- [56] Siniscalco D, Sapone A, Cirillo A, Giordano C, Maione S, Antonucci N, Autism Spectrum Disorders: Is Mesenchymal Stem Cell Personalized Therapy the Future? *Journal of Biomedicine and Biotechnology*, vol. 2012, Article ID 480289, 6 pages, 2012.
- [57] Segal-Gavish H, Karvat G, Barak N, Barzilay R, Ganz J, Edry L, Aharony I, Offen D, Kimchi T. Mesenchymal stem cell transplantation promotes neurogenesis and ameliorates autism related behaviors in BTBR mice. *Autism Research*. 2016;**9**(1):17–32
- [58] Sharma A, Gokulchandran N, Sane H, Nagrajan A, Paranjape A, et al. Autologous bone marrow mononuclear cell therapy for autism – An open label proof of concept study. *Stem Cells International*. 2013;**2013**:13 pages. Article ID 623875.
- [59] Lv YT, Zhang Y, Liu M, Qiuwaxi J, Ashwood P, et al. Transplantation of human cord blood mononuclear cells and umbilical cord-derived mesenchymal stem cells in autism. *Journal of Translational Medicine*. 2013;**11**:196
- [60] Bradstreet JJ, Sych N, Antonucci N, Klunnik M, Ivankova O, Matyashchuk I, M Demchuk, Siniscalco D. Efficacy of fetal stem cell transplantation in autism spectrum disorders: An open-labeled pilot study. *Cell Transplantation*, 2014;**23**:105–112
- [61] Sharma A, Gokulchandran N, Badhe P, Kulkarni P, Mishra P, Shetty A, Sane H. An improved case of autism as revealed by PET CT scan in patient transplanted with autologous bone marrow derived mononuclear cells. *Journal of Stem Cell Research and Therapy*. 2013;**3**:2
- [62] Sharma A, Gokulchandran N, Shetty A, Sane H, Kulkarni P, Badhe P. Autologous bone marrow mononuclear cells may be explored as a novel. Potential therapeutic option for autism. *Journal of Clinical Case Reports*. 2013;**3**:7
- [63] Sharma A, Gokulchandran N, Sane H, Kulkarni P, Thomas N, Paranjape A, Badhe P. Intrathecal autologous bone marrow mononuclear cell transplantation in a case of adult autism. *Autism Open Access*. 2013;**3**:2
- [64] Sharma A, Gokulchandran N, Sane H, Bhovad P, Biju H, Shetty A, Kali M, Badhe P. Cell therapy effects portrayed on positron emission tomography computerized tomography scan of the brain serve as a new dimension for autism: A case report. *Journal of Paediatric Neurology*. 2014;**12**:3
- [65] Sharma A, Gokulchandran N, Shetty A, Kulkarni P, Sane H, Badhe P. Neuropsychiatric disorder tackled by innovative cell therapy – A case report in autism. *Journal of Stem Cell Research Transplantation*. 2014;**1**(1):4
- [66] Sharma A, Gokulchandran N, Sane H, Patil A, Shetty A, Biju H, Kulkarni P, Badhe P. Amelioration of autism by autologous bone marrow mononuclear cells and neurorehabilitation: A case report. *American Journal of Medical Case Reports*. 2015;**3**(10):304–309

- [67] Sharma A, Sane H, Gokulchandran N, Badhe P, Patil A, Kulkarni P, Paranjape A. PET-CT scan shows decreased severity of autism after autologous cellular therapy: A case report. *Autism Open Access*. 2016;**6**:169
- [68] Sharma A, Chopra G, Gokulchandran N, Lohia M, Kulkarni P. Autologous bone derived mononuclear transplantation in Rett syndrome. *Journal of Paediatric Practice*. 2011;**15**(1):22–24
- [69] Kang H, Schuman EM. Long-lasting neurotrophin-induced enhancement of synaptic transmission in the adult hippocampus. *Science*. 1995;**267**:1658–1662
- [70] Sharma A, Sane H, Paranjape A, Gokulchandran N, Kulkarni P, Nagrajan A, Badhe P. Positron emission tomography–computer tomography scan used as a monitoring tool following cellular therapy in cerebral palsy and mental retardation – A case report. *Case Reports in Neurological Medicine*. 2013;**2013**:6 pages. Article ID 141983
- [71] Wallace GQ, McNally EM. Mechanisms of muscle degeneration, regeneration, and repair in the muscular dystrophies. *Annual Review of Physiology*. 2009;**71**:37–57
- [72] Meregalli M, Farini A, Colleoni F, Cassinelli L, Torrente Y. The role of stem cells in muscular dystrophies. *Current Gene Therapy*. 2012;**12**(3):192–205
- [73] Torrente Y, Belicchi M, Sampaolesi M, Pisati F, Meregalli M, D’Antona G, Tonlorenzi R, Porretti L, Gavina M, Mamchaoui K, Pellegrino MA. Human circulating AC133+ stem cells restore dystrophin expression and ameliorate function in dystrophic skeletal muscle. *The Journal of Clinical Investigation*. 2004;**114**(2):182–195.
- [74] Goetzl L, Darbinian N, Goetzl EJ. Novel window on early human neurodevelopment via fetal exosomes in maternal blood. *Annals of Clinical and Translational Neurology*. 2016;**3**(5):381–385
- [75] Torrente Y, Belicchi M, Marchesi C, D’Antona G, Cogiamanian F, et al. Autologous transplantation of muscle-derived CD133+ stem cells in Duchenne muscle patients. *Cell Transplantation*. 2007;**16**(6):563–577.
- [76] Yang XF, Xu YF, Zhang YB, Wang HM, Lü NW, et al. Functional improvement of patients with progressive muscular dystrophy by bone marrow and umbilical cord blood mesenchymal stem cell transplantations. *Zhonghua Yi Xue Za Zhi*. 2009;**89**(36):2552–2556
- [77] Mendell JR, Kissel JT, Amato AA, King W, Signore L, Prior TW, Sahenk Z, Benson S, McAndrew PE, Rice R, Nagaraja H. Myoblast transfer in the treatment of Duchenne’s muscular dystrophy. *New England Journal of Medicine*. 1995;**333**(13):832–838
- [78] Sharma A, Sane H, Badhe P, Gokulchandran N, Kulkarni P, Lohiya M, Biju H, Jacob VC. A clinical study shows safety and efficacy of autologous bone marrow mononuclear cell therapy to improve quality of life in muscular dystrophy patients. *Cell Transplantation*. 2013;**22**(Suppl 1):S127-S138
- [79] Rajput BS, Chakrabarti SK, Dongare VS, Ramirez CM, Deb KD. Human umbilical cord mesenchymal stem cells in the treatment of Duchenne muscular dystrophy: Safety and feasibility study in India. *Journal of Stem Cells*. 2015;**10**(2):141



- [80] Sharma A, Sane H, Gokulchandran N, Gandhi S, Bhovad P, Khopkar D, Paranjape A, Bhagwanani K, Badhe P. The role of cell transplantation in modifying the course of limb girdle muscular dystrophy: A longitudinal 5-year study. *Degenerative Neurological and Neuromuscular Disease*. 2015;**5**:93–102
- [81] Skuk D, Goulet M, Roy B, Piette V, Côté CH, Chapdelaine P, Hogrel JY, Paradis M, Bouchard JP, Sylvain M, Lachance JG. First test of a “high-density injection” protocol for myogenic cell transplantation throughout large volumes of muscles in a Duchenne muscular dystrophy patient: eighteen months follow-up. *Neuromuscular Disorders*. 2007;**17**(1):38–46.
- [82] Sharma A, Sane H, Paranjape A, Bhagawanani K, Gokulchandran N, Badhe P. Autologous bone marrow mononuclear cell transplantation in Duchenne muscular dystrophy – A case report. *The American Journal of Case Reports*. 2014;**15**:128.
- [83] Sharma A, Paranjape A, Sane H, Bhagawanani K, Gokulchandran N, Badhe P. Cellular transplantation alters the disease progression in Becker’s muscular dystrophy. *Case reports in transplantation*. 2013;**2013**:7 pages. Article ID 909328
- [84] Sharma A, Sane H, Paranjape A, Badhe P, Gokulchandran N, Jacob V. Effect of cellular therapy seen on musculoskeletal magnetic resonance imaging in a case of Becker’s muscular dystrophy. *Journal of Case Reports*. 2013;**3**(2):440–447
- [85] Sharma A, Kulkarni P, Chopra G, Gokulchandran N, Lohia M, Badhe P. Autologous bone marrow-derived mononuclear cell transplantation in Duchenne muscular dystrophy. *Indian Journal of Clinical Practice*. 2012;**23**(3):169–172
- [86] Sharma A, Sane H, Gokulchandra N, Sharan R, Paranjape A, Kulkarni P, Yadav J, Badhe P. Effect of cellular therapy in progression of Becker’s muscular dystrophy: A case study. *European Journal of Translational Myology*. 2016;**26**(1):5522
- [87] Sharma A, Sane H, Kaur J, Gokulchandran N, Paranjape A, Yadav J, Badhe P. Autologous bone marrow mononuclear cell transplantation improves function in a case of Becker’s muscular dystrophy. *American Based Research Journal*. 2016;**5**(2):1–12
- [88] Kang PB, Lidov HG, White AJ, Mitchell M, Balasubramanian A, et al. Inefficient dystrophin expression after cord blood transplantation in Duchenne muscular dystrophy. *Muscle & Nerve*. 2010;**41**(6):746–750
- [89] Skuk D, Roy B, Goulet M, Chapdelaine P, Bouchard JP, Roy R, Dugré FJ, Lachance JG, Deschênes L, Senay H, Sylvain M. Dystrophin expression in myofibers of Duchenne muscular dystrophy patients following intramuscular injections of normal myogenic cells. *Molecular Therapy*. 2004;**9**(3):475–482
- [90] Zhang C, Chen W, Xiao LL, Tan EX, Luo SK, Zheng D, Ye X, Li Z, Lu XL, Liu Y. Allogeneic umbilical cord blood stem cell transplantation in Duchenne muscular dystrophy. *Zhonghua Yi Xue Za Zhi*. 2005;**85**(8):522–525
- [91] Hentze H, Graichen R, Colman A. Cell therapy and the safety of embryonic stem cell-derived grafts. *Trends in Biotechnology*. 2007;**25**(1):24–32



- [92] Montoro J, Piñana JL, Moscardó F, Sanz J. Infectious complications after umbilical cord-blood transplantation from unrelated donors. *Mediterranean Journal of Hematology and Infectious Diseases*. 2016;**8**(1):e2016051
- [93] Sharma A, Sane H, Paranjape A, Gokulchandran N, Takle M, et al. Seizures as an adverse event of cellular therapy in pediatric neurological disorders and its prevention. *Journal of Neurological Disorders*. 2014;**2**:164
- [94] Minguell JJ, Pereira A, Bartholomew P, Lasala GP. The intrathecal infusion of mesenchymal stem cells into healthy rabbits is safe and devoid of neurological or clinical complications. *Journal of Stem Cell Research and Therapy*. 2011;**1**:104
- [95] Xu Q, Zhang M, Liu J, Li W. Intrathecal transplantation of neural stem cells appears to alleviate neuropathic pain in rats through release of GDNF. *Annals of Clinical and Laboratory Science*. 2013;**43**(2):154–162
- [96] Torrente Y, Belicchi M, Marchesi C, D'Antona G. Autologous transplantation of muscle-derived CD133<sup>+</sup> stem cells in Duchenne muscle patients. *Cell Transplantation*. 2007;**16**(6):563–577
- [97] Fischer UM, Harting MT, Jimenez F, Monzon-Posadas WO, Xue H, Savitz SI, Laine GA, Cox CS Jr. Pulmonary passage is a major obstacle for intravenous stem cell delivery: The pulmonary first-pass effect. *Stem Cells and Development*. 2009;**18**(5):683–692
- [98] Boltze J, Arnold A, Walczak P, Jolkkonen J, Cui L, Wagner DC. The dark side of the force – constraints and complications of cell therapies for stroke. *Frontiers of Neurology*. 2015;**6**:155
- [99] Wang X, Zhang M, Feng R, Li WB, Ren SQ, Zhang J, Zhang F. Physical exercise training and neurovascular unit in ischemic stroke. *Neuroscience*. 2014;**271**:99–107
- [100] Wahl P, Brixius K, Bloch W. Exercise-induced stem cell activation and its implication for cardiovascular and skeletal muscle regeneration. *Minimally Invasive Therapy & Allied Technologies*. 2008;**17**(2):91–99
- [101] Acton PD, Zhou R. Imaging reporter genes for cell tracking with PET and SPECT. *Quarterly Journal of Nuclear Medicine and Molecular Imaging*. 2005;**49**(4):349–360
- [102] Berti V, Mosconi L, Pupi A. Brain: Normal variations and benign findings in FDG PET/CT imaging. *PET Clinics*. 2014;**9**(2):129–140
- [103] Mercuri E, Jungbluth H, Muntoni F. Muscle imaging in clinical practice: diagnostic value of muscle magnetic resonance imaging in inherited neuromuscular disorders. *Current Opinion of Neurology*. 2005;**18**:526–537
- [104] Klotzenburg M, Yousry T. Magnetic resonance imaging of skeletal muscle. *Current Opinion of Neurology*. 2007;**20**:595–599