

# We are IntechOpen, the world's leading publisher of Open Access books Built by scientists, for scientists

6,900

Open access books available

185,000

International authors and editors

200M

Downloads

Our authors are among the

154

Countries delivered to

TOP 1%

most cited scientists

12.2%

Contributors from top 500 universities



WEB OF SCIENCE™

Selection of our books indexed in the Book Citation Index  
in Web of Science™ Core Collection (BKCI)

Interested in publishing with us?  
Contact [book.department@intechopen.com](mailto:book.department@intechopen.com)

Numbers displayed above are based on latest data collected.  
For more information visit [www.intechopen.com](http://www.intechopen.com)



---

# Cleft Lip and Palate Management from Birth to Adulthood: An Overview

---

Maen Hussni Zreagat, Rozita Hassan and  
Abdulfattah Hanoun

Additional information is available at the end of the chapter

<http://dx.doi.org/10.5772/intechopen.68448>

---

## Abstract

Cleft lip and palate (CLP) is the most common congenital deformity of the orofacial. Clefts are thought to be of multifactorial etiology due to genetic and environmental factors. Different dental abnormalities are usually seen in cleft patients, including midface deficiency, collapsed dental arches, malformation of teeth, hypodontia, and supernumerary teeth. Moreover, feeding and speech are major functional dilemmas for those patients. The goal of treatment is to restore esthetics and functional impairments associated with clefts. The nature and the extent of medical and dental problems among CLP patients dictate the need toward multidisciplinary approach where different medical and dental specialists are involved in the treatment. The purpose of this section is to codify and synthesize a literature about management of cleft lip and palate deformity from birth until adulthood so that general concepts, principles, and axioms can be formulated. In this regard, feeding plates, nasoalveolar molding (NAM), lip and palate repair, palatal expansion, alveolar bone grafting, rhinoplasty, orthodontic treatment, and orthognathic surgery will be discussed. Furthermore, the question of proper timing for each therapeutic procedure is scrutinized in this chapter. Suggested clinical tips and changes of treatment modalities are summarized and illustrated as well.

**Keywords:** cleft lip and palate, multidisciplinary management, lip repair, palate repair, orthognathic surgery

---


## 1. Introduction

Cleft lip and palate (CLP) is the most common orofacial malformation affecting one in every 700–1000 newborns worldwide [1]. The anomaly is characterized by the lack continuity of tissues forming the lip, alveolus, and soft and hard palate. The severity ranges from a small

notch in the lip to a complete fissure extending into the roof of the mouth and nose. Due to their disturbing appearance in many cases, these deformities have attracted much attention in terms of treatment and research. The large impact of the cleft lip and palate on appearance and function renders them a major public health problem worldwide [2]. Data from human and animal studies have suggested that the etiology of cleft lip and palate results from gene-environment interaction where genes have a major influence. Current research is emphasizing on detection of location and nature of mutations in genes associated with cleft lip and palate.

In comparison with unaffected children, individuals with unilateral cleft lip and palate (UCLP) present with striking asymmetries of the soft tissues as well as the nasomaxillary and lower facial structures. The facial profile is significantly affected by the cleft anomaly; the profile is generally concave due to the maxillary retrognathia. Several studies had reported that unilateral cleft lip and palate children have increased nose width, reduced mouth width, nose asymmetry, increased nose width/mouth width ratio, reduced upper lip length [3], and reduced lip elasticity [4]. For the dentoalveolar relationships, crossbite and open bite are common findings among unilateral cleft lip and palate patients [5].

Bishara et al. suggested that differences in dentoalveolar morphology between cleft and non-cleft subjects could be related to many factors. These include the morphogenetic pattern of the cleft anomaly, long-term management, and adaptive changes due to the mechanical presence of the cleft or lack of continuity of tissues [6].



**Figure 1.** Surgical instruments for cleft surgery (Heister's surgical textbook, 1731).

The management of children with cleft lip and palate is a real challenge. Intervention of cleft patients starts as early as intrauterine and continues into late adulthood. Related families are involved as well. Those patients are presented with various problems, and thus, effective therapeutic outcomes can be only through a multidisciplinary approach. The cleft team consists of different specialists work closely together, so that maximum care can be delivered in the optimum way. There is a consensus that understanding of the requirements and specialist skills of the other team members is necessary so that all members within the team can work coordinately which leads to improving outcomes.

The first proven description of treatment of a cleft lip and palate appeared in ancient China in the fourth century after Christ. Heister in 1731 described a clinical picture of cleft lip and palate management (**Figure 1**). It was Hagedorn who laid the basics of geometrical anatomical and surgical lip repair in 1884. He developed the surgical technique of repair using a geometric cutting procedure, the flap exchange, which in principle is in practice up to now. Thus, he founded basics of oriented surgical procedures that were described later by clinicians in the twentieth century [7].

## 2. Incidence of cleft lip and palate

Incidence of cleft lip and palate had been the subjects of many studies. There are significant differences in the incidence of cleft lip and palate, with the highest rates in Asian populations and Native Americans, intermediate rates in Caucasians, and lowest rates in African American. According to the European registration of congenital and twins (EUROCAT), incidence rates of cleft lip and palate for various regions in Europe between the year 1980 and 1988 were 1.45–1.57/1000 living birth [8]. Unilateral cleft lip and palate (UCLP) occurred in 40% of all cleft groups with male/female ratio (2:1) and was more common on the left side [9]. On the other hand, isolated cleft palate occurs more in females and is usually associated with syndromes [10].

## 3. Classification of cleft lip and palate

Different systems were introduced to classify cleft lip and palate.

### 3.1. Veau classification (1931)

Veau (1931) classified oral clefts based on the anatomy of the oral cavity into four groups:

1. Cleft of soft palate.
2. Cleft of soft and hard palate from incisive foramen up to the secondary palate.

3. Complete unilateral cleft from the uvula to incisive foramen, going on one side through the alveolus at the side of the future lateral incisor tooth.
4. Complete bilateral cleft from the incisive foramen to the alveolus, the premaxilla remains suspended from the nasal septum.

### 3.2. Classification by International Confederation for Plastic and Reconstructive Surgery (1966)

International Confederation for Plastic and Reconstructive Surgery had classified oral cleft into three groups:

1. Clefts of anterior primary palate, where the lip and alveolus are affected.
2. Clefts of anterior and posterior palate, where the alveolus and the hard palate are affected.
3. Clefts of the posterior palate, where the hard and soft palate are affected.

### 3.3. Kernahan and Stark classification (1958)

This classification is based on embryology and classifies oral clefts into two main groups:

1. Cleft of primary palate: extends from alveolus up to the incisive foramen.
2. Cleft of secondary palate: extends from soft and hard palate up to incisive foramen. Both groups could be complete or incomplete, unilateral or bilateral (Kernahan and Stark, 1958).

Kernahan and Stark classification was widely accepted because it is simple and embryologically sound [11].

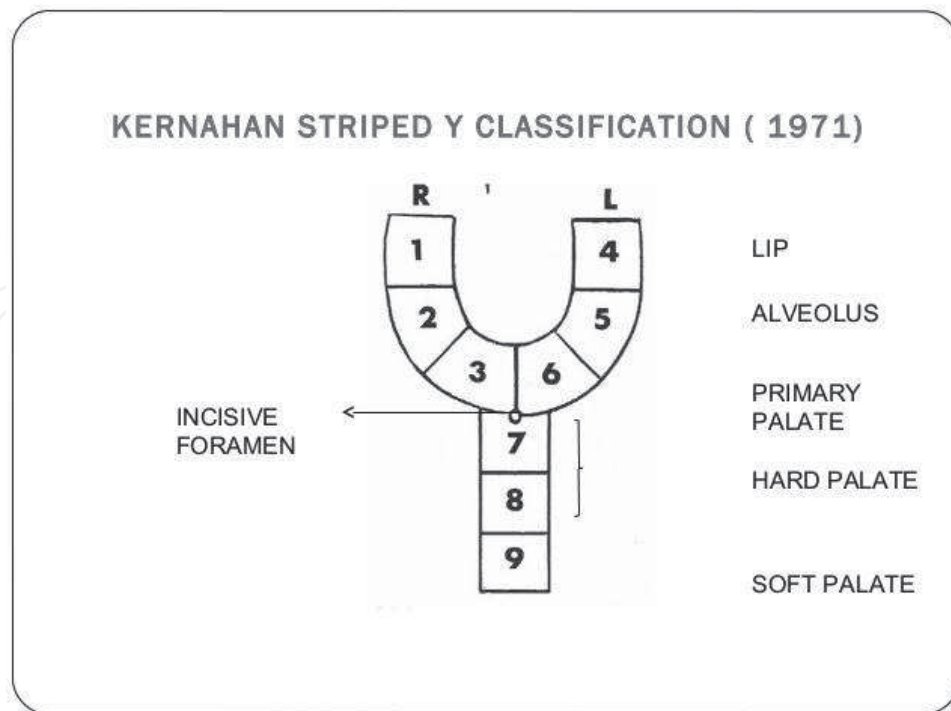
### 3.4. Kernahan stripped "Y" classification

This classification is represented as a stripped "Y" with numbered blocks. Different numbers represent a specific affected area in the cleft deformity (**Figure 2**).

- Blocks 1 and 4 indicate the lip.
- Blocks 2 and 5 indicate the alveolus.
- Blocks 3 and 6 indicate hard palate to the incisive foramen.
- Blocks 7 and 8 indicate hard palate to incisive foramen.
- Block 9 indicates the soft palate.

The shaded boxes represent the site of cleft deformity.

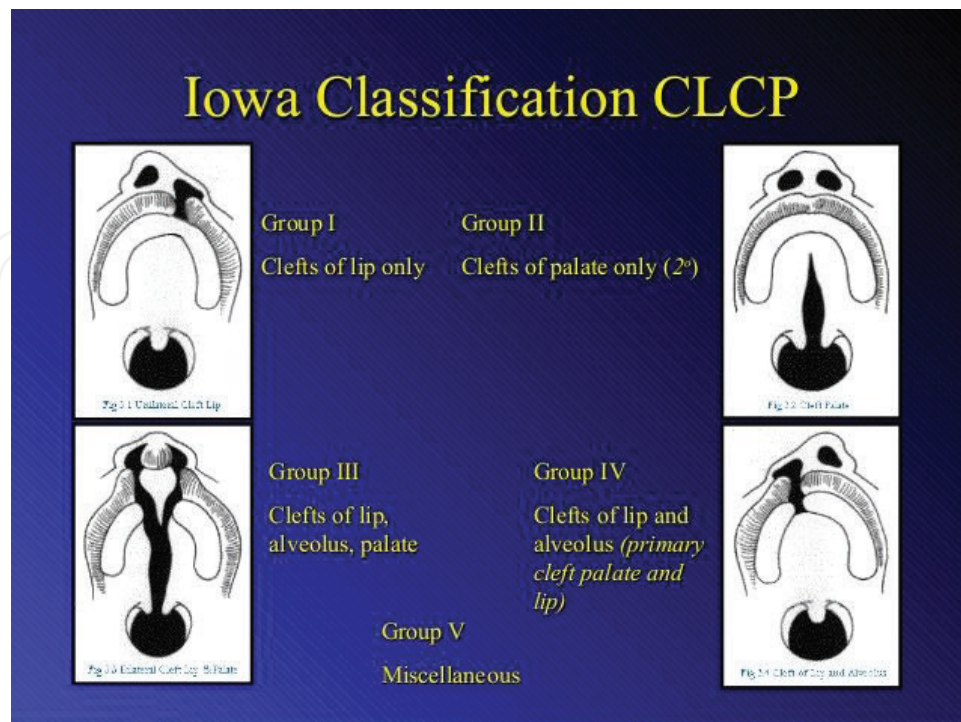




**Figure 2.** Kernahan's stripped "Y" classification.

### 3.5. Iowa classification

Iowa classification had classified cleft lip and palate into five groups (**Figure 3**). This descriptive classification was a variation of Veau classification and is more commonly used.



**Figure 3.** Iowa classification of cleft lip and palate.

## 4. Embryology background

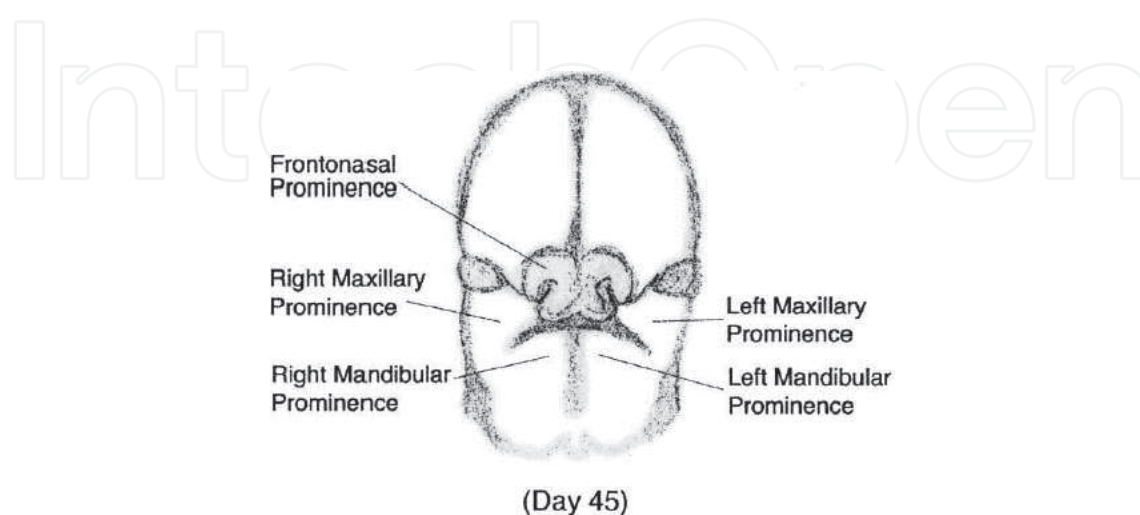
Knowledge of the normal embryological development of the lip and palate is essential for understanding and management of cleft lip and palate. The face is formed by the fusion of a number of embryonic processes that form around the primitive oral cavity (stomodeum). By the 4<sup>th</sup> week of intrauterine life, five branchial arches develop at the site of future neck. The nasomaxillary complex is formed through the development of the first branchial arch (the mandibular arch). The upper boundary of the stomodeum (primitive oral cavity) originates as a large frontal prominence. The primary mouth is divided from the foregut by the buccopharyngeal membrane. The dorsal end of developing mandibular arch gives off a bud called maxillary process with the formation of the nasal pit. One medial and two lateral nasal processes are formed as the frontonasal process gets divided [12] (**Figure 4**).

### 4.1. Development of the primary palate (upper lip and premaxilla)

The maxillary process undergoes rapid growth between the 5<sup>th</sup> and the 6<sup>th</sup> weeks of intrauterine life. By the 7<sup>th</sup> week, the maxillary, the medial, and lateral nasal processes are integrated to form the intermaxillary segment with its labial component forming the philtrum of the upper lip while its triangular palatal component forming the maxillary incisors and extend backwards to the incisive foramen. As a result, the upper lip and the maxilla are formed. Cleft lip may develop due to inadequate proliferation of the maxillary and medial nasal processes.

### 4.2. Development of the secondary palate

The rest of the palatal shelves forms hard and soft palates, which are formed from secondary palate. By the 6<sup>th</sup> week of the intrauterine life, palatal shelves are formed from the medial surface of the maxillary process. These will grow medially and downwards, lateral to the tongue being elevated in the 7<sup>th</sup> week, and more marked in the anterior region and leading to growth of the mandible.



**Figure 4.** Facial embryo at day 45.

The tongue plays a vital role in the initial prevention of the palatal shelves union. Thus, the shelves grow vertically down. By the 8<sup>th</sup> week of intrauterine life, palatal shelves approximate touching each other. As a result, the related epithelium degenerates and mesenchyme from both shelves join in the midline. Final closure by fusion is completed by the 10<sup>th</sup> week and usually occurs a little bit later in males than females. Failure of fusion of the maxillary shelves with each other and with the frontonasal processes results in cleft palate.

## 5. Etiology of cleft lip and palate

Recent studies have shown that the etiology of cleft lip and palate is multifactorial. The underlying genetic factors are enhanced by environmental factors [13].

### 5.1. Genetic factors

The genetic factors for the etiology of nonsyndromic cleft lip with or without cleft palate and for nonsyndromic cleft palate only were first indicated in the population studies of Fogh-Anderson. Animal studies of cleft deformity were directed toward the importance of the secondary palate formation. These studies have pointed out the importance of extracellular matrix proteins and soluble factors in normal palate formation. Transforming growth factor- $\alpha$  (TGF- $\alpha$ ), epidermal growth factor, fibroblast growth factor, and TGF- $\beta$ 3 are of clinical significance in this process. Moreover, transforming growth factor- $\alpha$  (TGF- $\alpha$ ) has been suggested as a target gene in the etiology of nonsyndromic cleft deformity. In animal studies, high levels of TGFA were detected in the epithelial tissue of the medial edge of the palatal shelves at the time of shelf fusion. The biologic support for the role of TGFA gene in cleft etiology was addressed due to the reported association of TGFA alleles with human cleft lip and palate [14].

Glu mutation of the PVRL 1 gene proved to be a genetic factor for nonsyndromic clefts of the primary and the secondary palates, but simultaneous occurrence of PVRL1 and CLPTM 1 gene mutations in cleft patients does not correlate with the type of cleft (left, right, bilateral) or the gender of the patients [15, 16].

### 5.2. Environmental factors

A positive association between maternal cigarette smoking and cleft lip and palate has been observed in number of studies [17]. A case-control study of the association between cleft lip and palate and maternal exposure to tobacco smoke during the first trimester of pregnancy in United Kingdom proved that there is a statistically significant positive association between active smoking during pregnancy and the risk of developing cleft lip and palate [18]. B group vitamin deficiency (including folic acid) during pregnancy has been shown to be a teratogen in the etiology of cleft lip and palate formation in humans [19].

Krost and Schubert evaluated the seasonal influence on the occurrence of cleft lip and palate and proved a significant maximum risk in spring and minimum in winter for the conception date. They claimed that there are seasonal factors implicated in the etiology of cleft lip and palate.



These include deficiency of vitamins and fluctuations in mother's diet, intensive UV light exposure, the use of fertilizers and pesticides in agriculture, and infectious disease cycles [20].

## 6. Cleft management

Management of children with cleft lip and palate should go through a multidisciplinary team who will provide the optimal treatment (Bill, 2006). The managing team should provide comprehensive diagnosis, planning, and treatment. The cleft team usually includes orthodontist, maxillofacial surgeon, plastic surgeon, prosthodontist, speech therapist, audiologist (ENT specialist), psychologist, and pediatrician [21]. Goals of treatment of the child with a cleft lip and palate should include the repairing the birth defect (lip, palate, and nose), achieving normal speech, language, hearing, functional occlusion, and good dental health. It should also optimize the psychosocial and developmental outcomes [22]. However, protocols for the management of CLP patients vary from center to center. According to the Eurocleft project between 1996 and 2000, there were 194 different surgical approaches followed for treatment of unilateral cleft alone [23]. Management is discussed according to specific time periods as shown below.

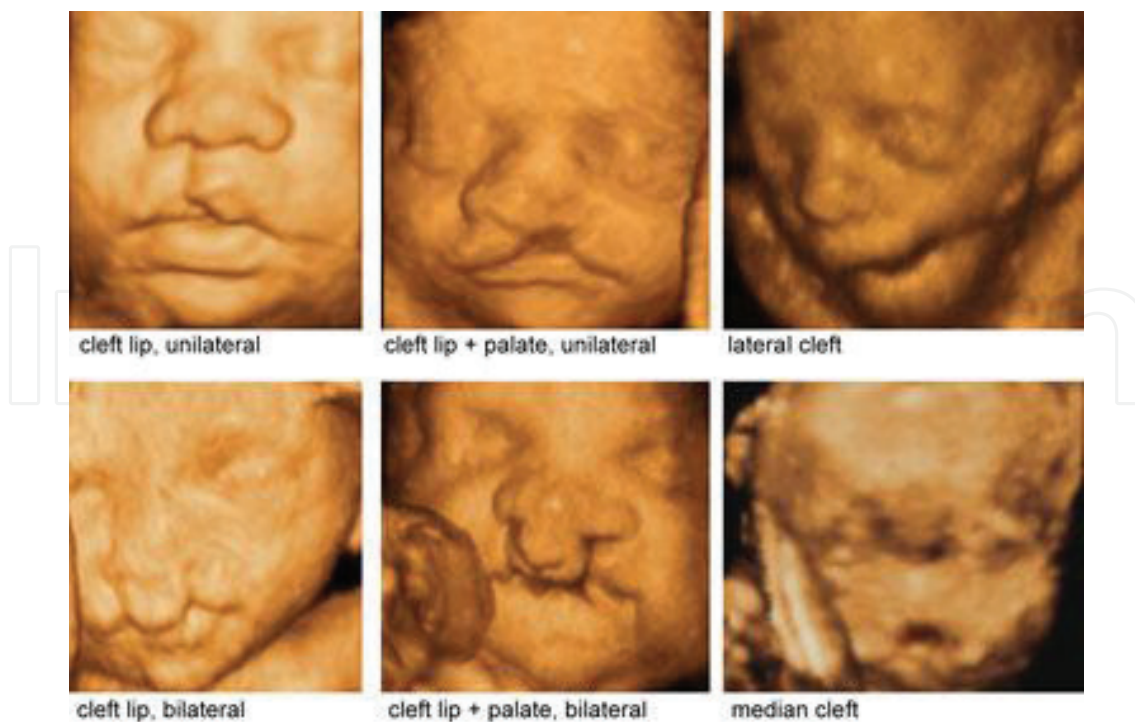
### 6.1. Pre-natal diagnosis

Ultrasound examination may detect clefts of the lip and alveolus unlike cleft palate, which is difficult to diagnose through routine screening (**Figure 5**). Additional examinations and tests can confirm the presence of deformity. These include cephalic presentation of the child, low body mass index of the mother, and examination preferably around the 20th gestational week [24]. Moreover, information about family history should be addressed so that provisions for postnatal measures in adequately equipped hospitals can be made in with improvement in ultrasound technology.

In case of cleft identification, genetic counseling the family including amniocentesis should be performed. For this purpose, a complete pregnancy progress and family history should be addressed. Exposure to any teratogenic factors, the presence of family members with cleft or other birth defects, developmental problems, and genetic syndromes are all important parameter to explore during counseling. In cases where clefts are diagnosed prenatally, the cleft team will be involved in the management so that the family can learn about the nature of the deformity and its care and treatment strategies. Psychological and emotional support of the family is very essential procedure at this time due to the very negative effect once the diagnosis was confirmed.

### 6.2. Birth time

The most immediate problem caused by orofacial clefting is likely to be difficulty with feeding. The anatomical characteristics of cleft lip and palate greatly hinder infants' ability to feed. Poor intraoral suction may produce choking, emission of milk through the nose, and

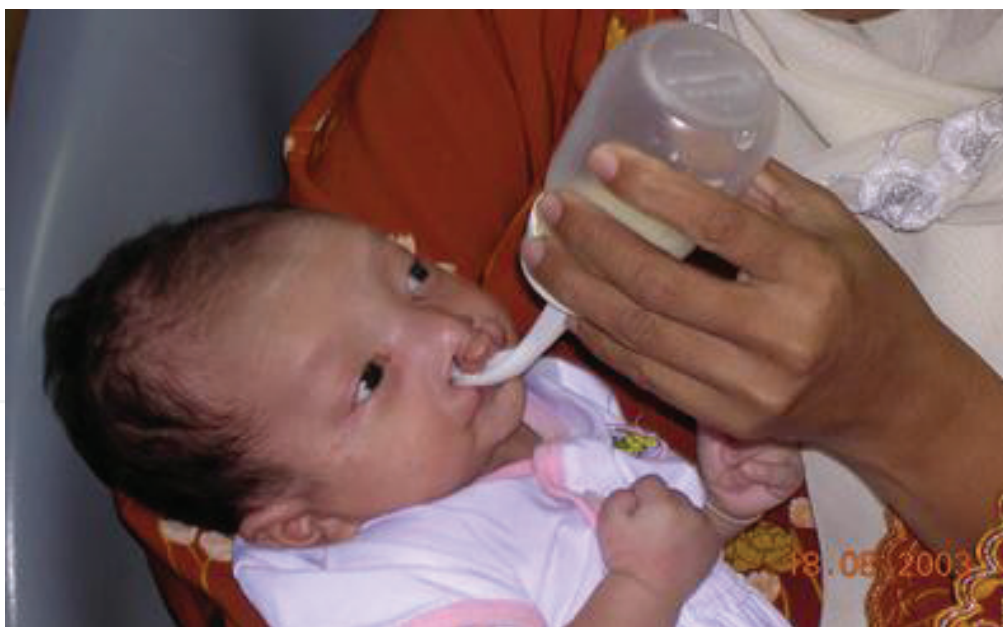

**Figure 5.** Three-dimensional neonatal view — various cleft deformities.

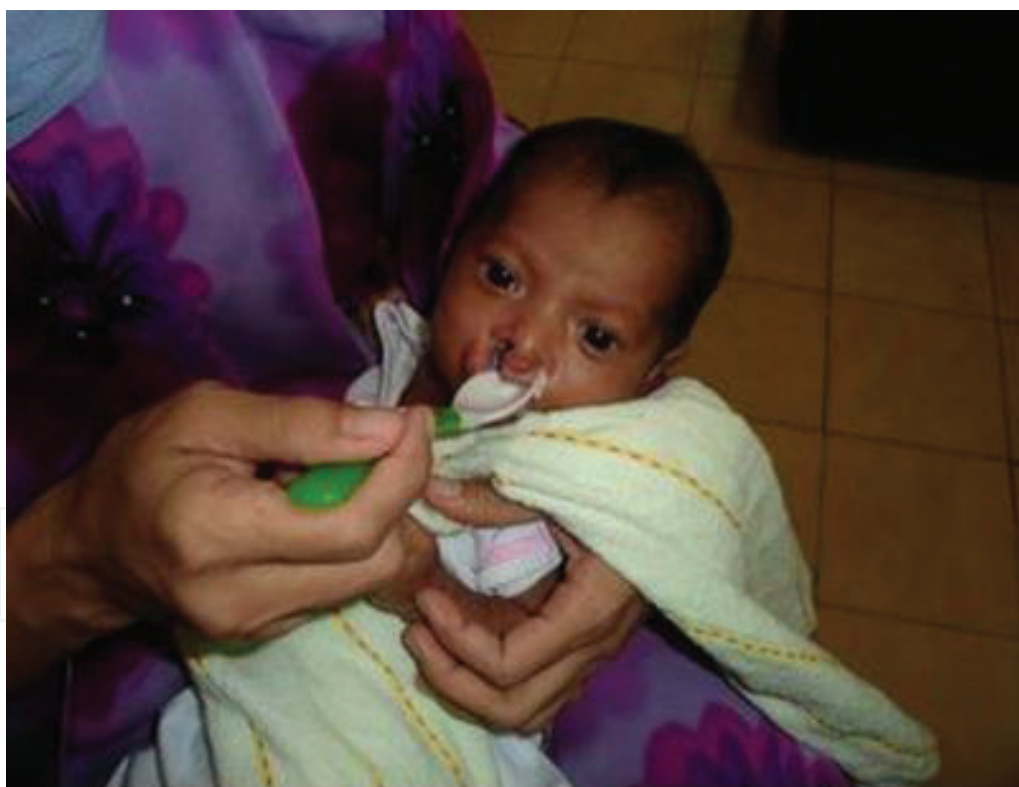excessive air intake. The feeding process can also be extremely stressful for the parents of such infants who often struggle to find effective feeding method [25]. Early referral to the infant-feeding specialist or nurses associated with cleft teams can facilitate to solve this problem. Those children need special teat and bottles that allow milk to be delivered to the back of throat where it can be swallowed (**Figure 6**). In addition, we may use special dental plates (palatal prosthesis) to seal the cleft side. Such prosthesis could be effective in increasing the volume of fluid intake, decreasing time of feeding, and promoting adequate growth and gain in infants with cleft lip and palate [26]. Some babies may not have the energy to suck from a teat, and here a cup and spoon method may be helpful (**Figure 7**).

Presurgical orthopedics and nasoalveolar molding have become part of the treatment protocol in many cleft centers to improve the treatment outcome. Presurgical orthopedics approximates the maxillary alveolar segments and results in reduction of the tension on the repaired lip. The Latham appliance is an active presurgical orthopedic device used for cleft defects (**Figure 8**). Its long-term effects are debated. The basic idea behind appliance is to decrease the anatomical dilemma in cleft deformity so that better surgical outcome can be obtained. The device has proved its success in expanding and aligning the maxillary segments; retruding protruded premaxilla; aligning bilateral alveolar ridges; reducing tension on surgical closures; and reducing rates of fistula development. However, its long-term effect on maxillary development or occlusion has not been proven [27].

On the other hand, presurgical nasoalveolar molding (PNAM) can reduce soft tissues and cartilaginous cleft deformity to facilitate surgical soft tissue repair with minimum tension

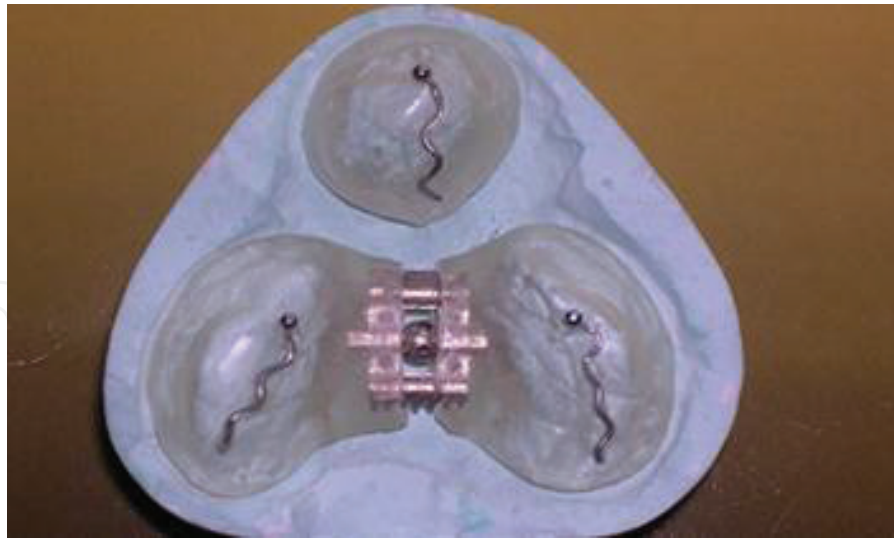


**Figure 6.** Special feeding bottle for cleft patients.



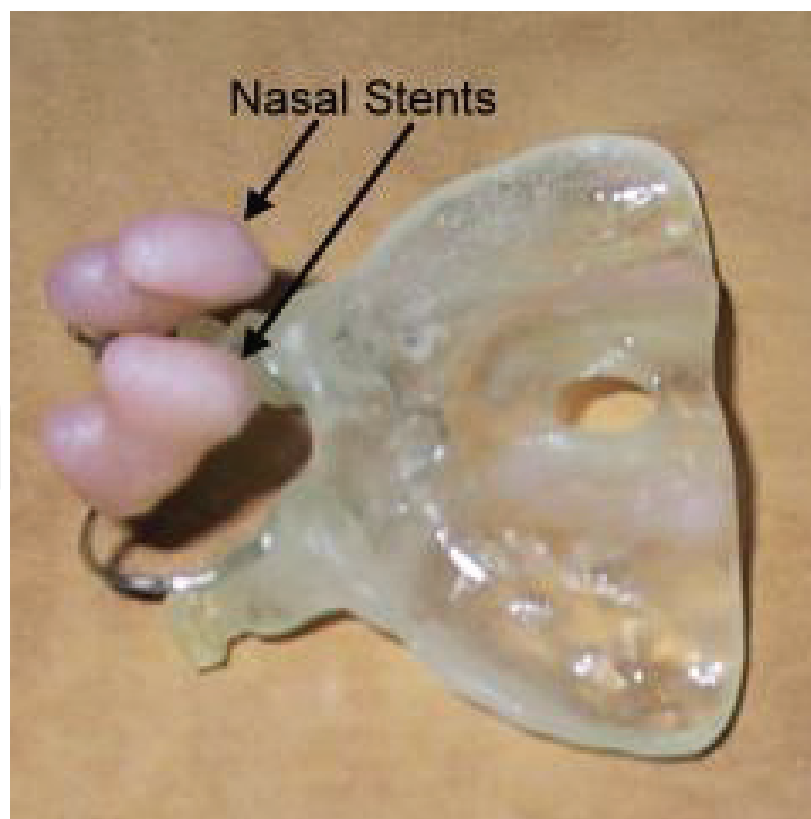
**Figure 7.** Spoon feeding for cleft patients.

to minimize scar formation [28]. It stimulates and redirects growth of the alveolar segments, which will lead to ideal arch formation. Moreover, it aids in normal speech development through better positioning of the tongue. Other benefits include improvement of appearance



**Figure 8.** Pre-surgical orthopedic plate—Latham appliance.

psychosocial wellbeing, better feeding, and bone contour [29]. PNAAM appliance consists of a removable alveolar molding plate made of orthodontic acrylic from a dental cast of the infant's maxilla. The nasal stent is bent at the end of a 0.032-inch stainless steel wire that is embedded into the anterior portion of the alveolar molding plate (**Figure 9**). The nasal stent



**Figure 9.** Active alveolar molding appliance.



and the intraoral molding plate are adjusted weekly or biweekly to gradually correct the nasal and alveolar deformities, giving rise to the name nasoalveolar molding. PNAM can be applied to the entire range of cleft deformities including complete clefts without an intact nasal floor [30].

### 6.3. Lip repair

There is a wide variation in the timing and techniques of primary lip repair depending upon the preference and protocol of the surgeon and cleft team involved. These include LeMesurier—1949, Tennison—1952, Randall—1959, Pfeifer—1970, Millard—1976, Del cheilorhinoplasty technique (Delaire—1978), "alar-leapfrog" technique (Pigott—1985) and many others. In broad terms, lip repair is performed at 3 months of age and palate repair at 12 months of age (Millard technique). Other schools perform surgery earlier (soft palate repair at 3 months of age and lip and hard palate repair at 6 months of age) as in the case of Malek protocol [31]. Cleft surgery has a major target in dissecting and approximating the muscles of the lip and alar base in their correct anatomical position. Debates continue to point out the suitable dissection procedure (subperiosteal dissection or supraperiosteal dissection) [32].

Neonatal repair is still being evaluated. Some schools suggest doing the surgery as early as possible. According to them, the early surgery improves the facial appearance and reduces parent's apprehension. Moreover, earlier surgeries would help in the development of normal articulation [33]. On the other hand, some schools oppose earlier surgical intervention as this will restrict future growth leading to maxillary collapse and occlusal crossbites. Moreover, delayed surgery means that surgeons will have more tissues to deal with giving better outcome.

### 6.4. Palate repair

Cleft palate repair is a challenging procedure to learn because of the delicate tissue handling required and the small confines of the infant oral cavity. Hard and soft palate repair is performed at the age range of 9–18 months. The idea behind this relatively early intervention is giving priority to development of normal articulation, which can be extremely difficult to eradicate after the age of 5 years [34]. Different surgical protocols are followed to repair the palate; these include: Von Langbeck repair, vomer flap repair, and Z-plasty repair. In general, scar retraction due to exposed bone in palatoplasty is the leading cause of constricted maxilla. Modern techniques have focused on minimizing the effects of scarring by reducing the exposure of the bone area.

It is self-evident that a physical defect that affects the structures of the mouth and face has the potential to influence articulatory development [35]. Cleft palate often causes problems with speech and hearing. It has been primarily considered as a disorder of the vocal tract. Parents are encouraged to stimulate and converse with infants normally expecting the development of good speech. Speech and language therapist should carry out early assessment with special expertise in clefts. Assessment at 18 months gives a good indication and is repeated, for example, at 3 years. In most cases, the majority of children following cleft palate repair have normal intelligibility. On the other hand, many babies with cleft lip and palate have recurrent



otitis media and develop glue ear. A possible etiology for this is that palatal muscles (levator palati and tensor palati) are involved in cleft deformity leading to eustachian tube dysfunction. Cleft subjects need extensive screening in ENT department [36].

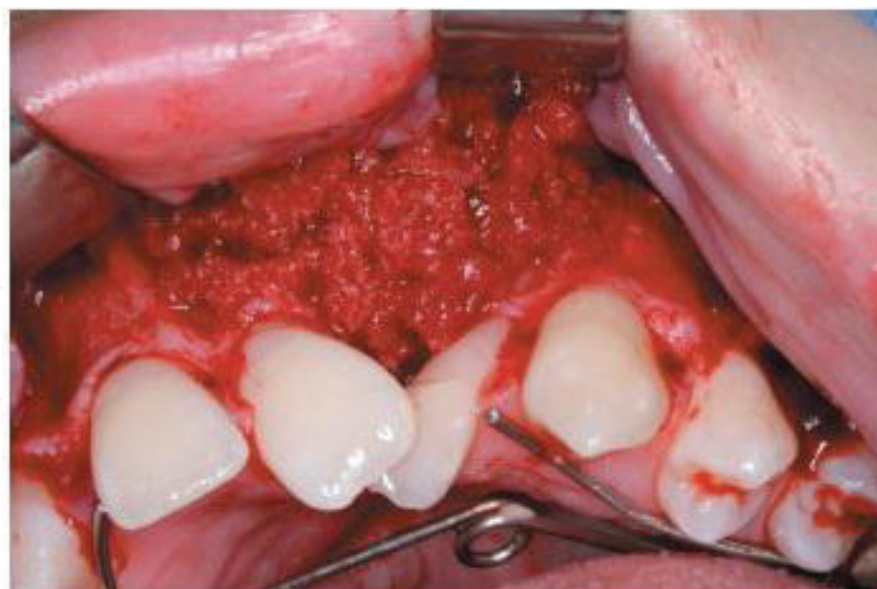
### 6.5. Primary dentition (2–6 years)

Velopharyngeal insufficiency (VPI) is a common finding in cleft patients. VPI is the incomplete closure of the velopharyngeal sphincter resulting in hypernasal resonance, which can compromise speech intelligibility. Most sounds are divided to be oral (produced in the oral cavity) and nasal (m & n only). Speech nasality happens when the oral cavity is not completely sealed from the nasal cavity. As a result, air escapes through the nose. Even after palate repair, cleft patients can still sound nasal due to the inability of the soft palate to seal and separate these two cavities. The reason for that is weakness in muscles of the soft palate. Moreover, the soft palate is short, which hinders its contact with pharyngeal wall [37]. Speech assessment might be commenced as early as 18 months of age taking into consideration the needs of the patient [38]. Assessment of speech must continue through childhood along with cleft team to detect any developing problems that may arise with growth. ENT surgeon will be involved throughout all monitoring phase. Lip revision and closure of any residual palatal fistula before schooling might be considered to support speech development [39].

Orthodontic treatment in this stage is limited to the correction of certain posterior crossbite and anterior crossbite of mild-to-moderate degree. Posterior crossbites are of both skeletal and dental origin. A crossbite of a dental origin and accompanied with occlusal shift can be managed by selective grinding; anterior crossbite of mild-to-moderate degree can be managed by the use of elastic protraction forces delivered through a facial mask [40]. However, if this crossbite is related to severe maxillary hypoplasia, the patient is best managed with surgical procedures that are done at later stages. During this age, it is important to develop good dental care habits, instituting fluoride supplements in nonfluoridated areas [41].

### 6.6. Mixed dentition (6–12 years)

The negative effects of surgical repair become clear during this phase including maxillary collapse and arch discrepancies. Moreover, defects in alveolar bone, tooth number, formation, and position can be detected. Surgeons start to consider alveolar bone graft to correct the maxillary defects at this stage (**Figure 10**). Grafting is best performed with autogenously cancellous bone. Alveolar bone grafting will provide maxillary-alveolar ridge continuity for tooth eruption and alignment. It also provides nasal base support and provides bone through which the permanent canines and laterals can erupt into the dental arch. In bilateral cases, alveolar bone grafting stabilizes the premaxillary segment with bone support [42]. Alveolar bone grafting is performed using a gingival flap of mucoperiosteum, turned back “book” flaps and cancellous bone harvested from the iliac crest. The covering flap of gingival mucoperiosteum is used to cover the graft in the alveolus, nostril floor, and anterior maxilla. The ideal age for bone grafting is 9–11 years to give chance for the lateral incisor or the canine to erupt through the graft and stabilize it. Supernumerary teeth in the surgical site should be extracted 8–12 weeks before surgery. This will allow the surgeon to have intact

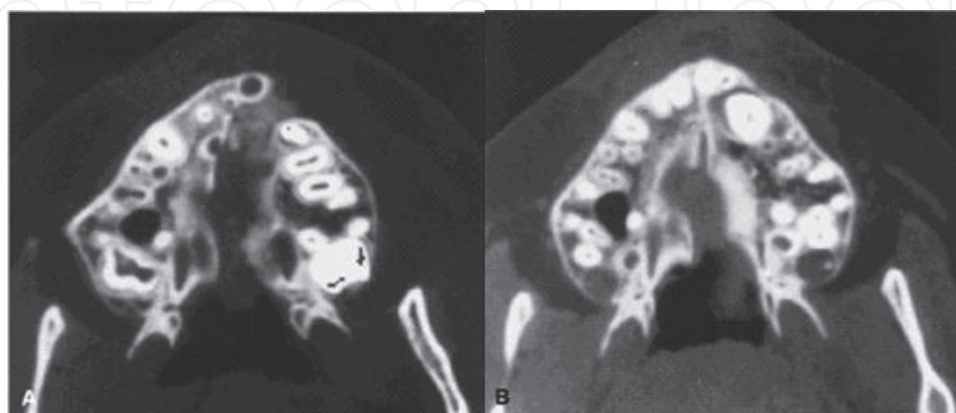


**Figure 10.** Alveolar bone graft.

gingival tissues for proper coverage of the alveolar bone graft. At the time of complete eruption of permanent dentition (approximately 12 or 13 years of age), orthodontic treatment is commenced.

The timing of bone grafting will be decided on the basis of the dental development of individual patients [43]. In patients with well-formed lateral incisors that are in the line of the dental arch, bone grafting can be done quite early, around 7 or 8 years. However, most patients with complete unilateral cleft lip and palate have a missing, ectopic, or deformed lateral incisor, so it is preferable that bone grafting is postponed until they are 10 or 11 years of age (**Figure 11**). This allows the root development of the cleft-side canine to progress more and may help in better canine eruption [44].

An interceptive orthodontic treatment is undertaken in the mixed dentition to reposition the dentition adjacent to the cleft preparing the cleft side for the secondary alveolar bone graft,



**Figure 11.** CBCT of alveolar bone graft in UCLP patient (A: before and B: after).

but such procedure must be postponed until the development of the incisor roots to avoid any resorptive effect on teeth. If maxillary segments and dentition on either side of the cleft are well aligned, it is not necessary to do presurgical orthodontics [45]. Thus, orthodontic treatment is not generally commenced until age 9 or 10 years when, if necessary, the maxillary segments are expanded to correct the transverse relationship using palatal expansion appliances, these include upper removable appliance, quad helix (**Figure 12**), rapid maxillary expansion, bonded “fan” appliance (**Figure 13**), and others [46, 47].

### 6.7. Permanent dentition

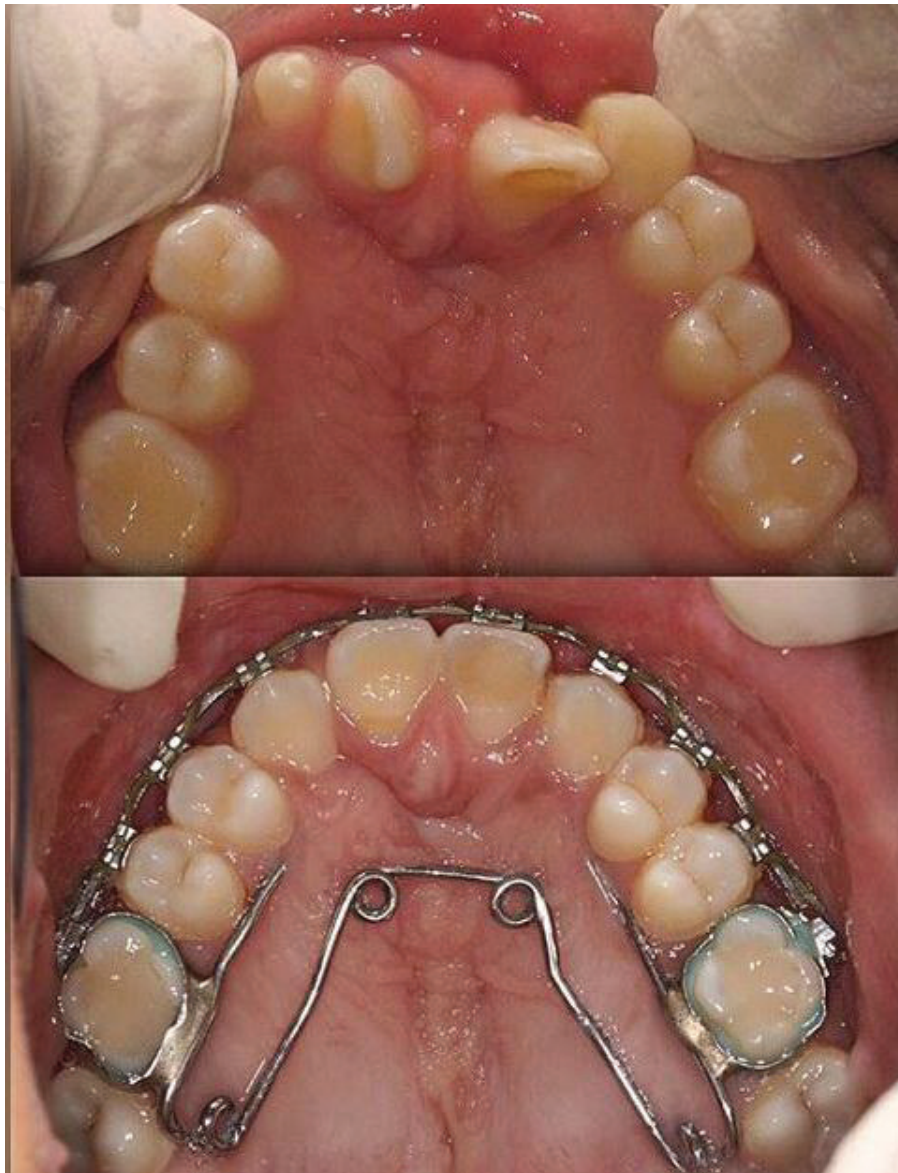Definitive orthodontic treatment must be commenced at this time. The goals of treatment are similar to those for noncleft patients, but certain conditions must be taken into consideration during the treatment planning. These include maintenance of the integrity of the dentition and supporting structures especially for teeth adjacent to the cleft side, correction of impacted and transposed teeth, and management of congenitally missing teeth [48].

If the cleft side lateral incisor is missing, management will be based on either replacing the missing tooth with prosthesis or closing the space. In those patients with missing lateral incisor in whom the maxillary canine has migrated mesially and is erupting into the grafted alveolar ridge, replacement of the missing lateral incisor by the canine and movement of all posterior teeth forward will be the treatment of choice. In cases where the alveolar bone graft is not ideal, bone morphology can be improved by moving the canine forward into graft side [49].

Extractions may be required to create space for arch alignment with the second premolars being first choice in the maxilla. This is related to formation of scar tissue during the course of primary palatal repair, which pulls the premolars palatally. However, relapse is common after orthodontic correction. Invariably, fixed appliances are required to achieve a satisfactory degree of precision in tooth alignment with sound values of tip and torque movements [50]. Once the permanent dentition has been established, planning for orthognathic surgery must take place in a tempt to correct mid-face retrusion. Factors such as maxillary retrognathia, the magnitude and effect of any future growth, and patient wishes should be taken into consideration. Surgical correction is indicated only when growth is complete. Surgical revision of the nose (rhinoplasty) will be the last surgical step. This is because movement of the underlying bone will affect the contour of the nose [51].

Hypodontia, microdontia, and conical crowns are common findings in cleft lip and palate (**Figure 14**). In broad terms, treatment strategies reflect the pattern of tooth absence, the amount of residual spacing, existing malocclusions, and patient’s attitude [52, 53]. The congenital missing of teeth may result in minimal spacing; still, it may not be an esthetic concern to patients and can be accepted. Space closure and modification of the canine to resemble a lateral incisor is a common treatment option where maxillary lateral incisors are missing. However, where several teeth are congenitally absent, the orthodontic redistribution of space to allow restoration with prostheses is frequently the treatment of choice. The esthetic and functional outcomes of such an approach should be confirmed with a trial diagnostic set-up.



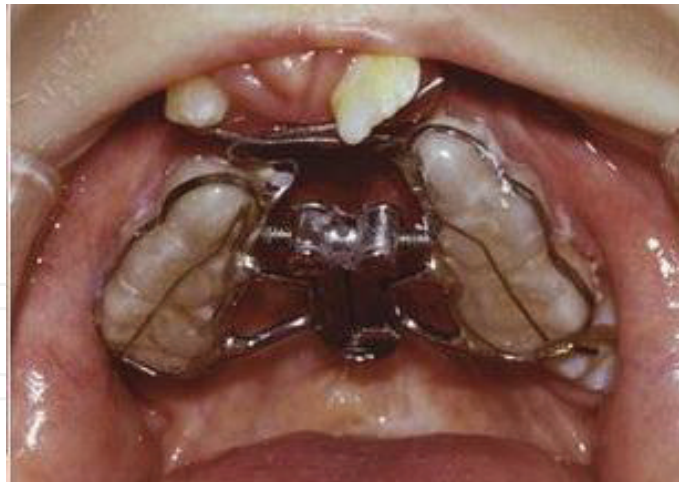

**Figure 12.** Quad helix expansion in UCLP.

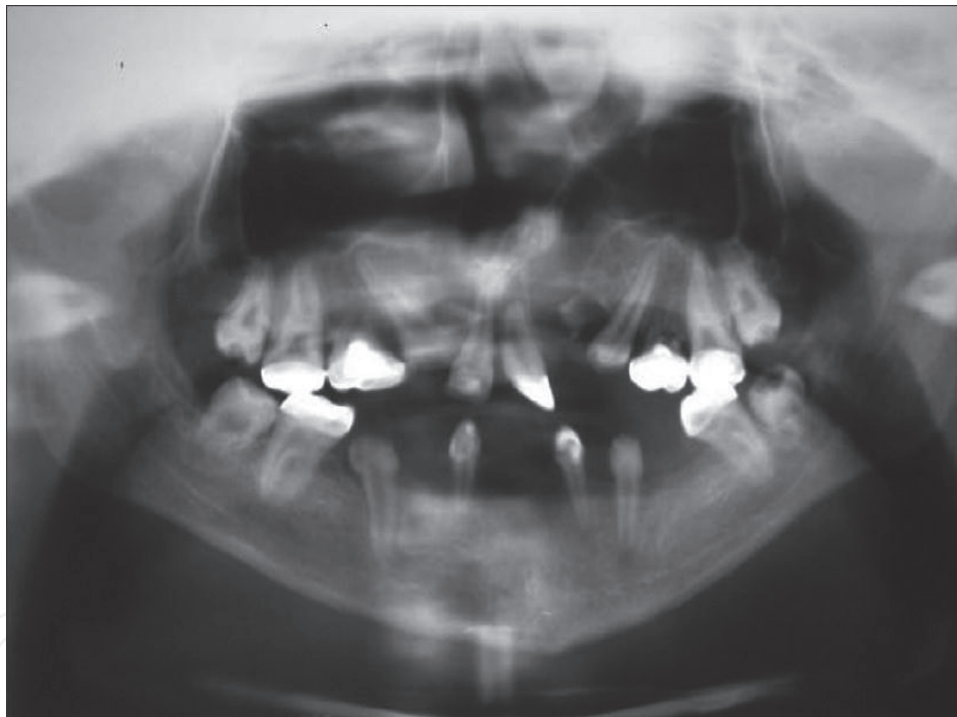Replacement of missing teeth with prosthesis includes removable partial dentures, conventional and adhesive bridges, and implant supported prostheses. Clearly, both the timing and manner of their application must reflect the needs and limitations imposed by a young, growing individual [54].

### 6.8. Orthognathic surgery

The midfacial hypoplasia or maxillary constriction is a common secondary deformity in cleft deformity involving primary palate. This hypoplasia and constriction are related to growth impairment and scar formation in hard palate during the palate repair. Despite of orthodontic treatment, up to 25% of patients with cleft lip and palate needs surgical interventions to achieve balanced and harmonious facial appearance.



**Figure 13.** Bonded "fan" expansion appliance.



**Figure 14.** Hypodontia in cleft lip and palate.

At approximately the age of 17–18, a final assessment of facial pattern is carried out clinically. Detailed cephalometric assessment and growth analyses are carried out to plan for orthognathic surgery. No orthognathic surgery is carried out until growth is complete. Surgeons perform the corrective surgery in the maxillary bone or both jaws according to the severity of the underlying skeletal discrepancy. The advantage of this surgical-orthodontic approach is that the clinicians can provide the patient with occlusal relations close to ideal and markedly improved function and esthetics.



### 6.9. Psychological effects

Children with craniofacial anomalies are at greater risk of developing behavioral, emotional, or social competence problems [55]. Some children with oral clefts have decreased social competence as shown by fewer friends and poor social interaction. Slifer et al. have found that 30–50% of children with cleft lip and/or palate between the ages of 6 and 16 are rated by their parents to be 1.0 or more standard deviations below the mean compared to noncleft peers on measures of social adjustment and competence (sharing their friends in social activities, degree, and quality of social interaction). Unfortunately, this tendency continued through adolescence and into adulthood [56].

All the above features will have psychological effects on cleft patients as well as their families; these effects become more significant when patients get younger. Two stages where those children have a real challenge to deal with; are when they go to school (5–6) years i.e. the difficulty of being different. The second when they start to look after their appearance, i.e. the pre-puberty and adolescence time. Children with visible clefts are often very self-conscious about their appearance, speech, and schooling.

### 6.10. Learning disorders and behavioral problems

Children with cleft lip and palate are at an increased risk for learning disorders. There is a consensus that language skills of cleft palate patients tend to be delayed even if the cleft was a small one [57]. Broder et al. have examined the prevalence of learning disability, level of school achievement, and prevalence of grade retention by type of cleft and gender at two craniofacial centers. The results showed that 46% of subjects with cleft had learning disability and 47% had deficient educational progress. Moreover, 27% had repeated a grade in the school. The results also showed that males with only cleft palate and females with cleft lip and palate were at higher risk among all cleft subjects [58].

## Acknowledgments

To my wife Huda Zurigat whose never-failing sympathy and encouragement, without your support, this chapter would not have been finished on time.

## Author details

Maen Hussni Zreagat<sup>1\*</sup>, Rozita Hassan<sup>1</sup> and Abdulfattah Hanoun<sup>2</sup>

\*Address all correspondence to: maenzreagat@yahoo.com

<sup>1</sup> Universiti Sanins Malaysia, Kota Bharu, Malaysia

<sup>2</sup> Orthodontic Department, Universiti Sains Malaysia, Penang, Malaysia

## References

- [1] Murray J. Gene/environment causes of cleft lip and/or palate. *Clinical Genetics*. 2002;**61**(4):248-256. DOI: 10.1016/j.coms.2016.01.004
- [2] Bender P. Genetics of cleft lip and palate. *Journal of Pediatric Nursing*. 2000;**15**(4):242-249. DOI: 10.1016/j.coms.2016.01.2300
- [3] Duffy S, Noar J, Evans R, Sanders R. Three-dimensional analysis of the child cleft face. *Cleft Palate Craniofacial Journal*. 2000;**37**(2):137-144. DOI: 10.1016/j.coms.2016.01.004
- [4] Susami T, Kamiyama H, Uji M, Motohashi N, Kuroda T. Quantitative evaluation of the shape and the elasticity of repaired cleft lip. *Cleft Palate Craniofacial Journal*. 1993;**30**(3):309-312. DOI: 10.1016/j.fsc.2016.06.015
- [5] Mars M, Asher-McDade C, Brattstrom V, Dahl E, McWilliam J, Molsted K, Plint D, Prah-Andersen B, Semb G, Shaw W. A six-center international study of treatment outcome in patients with clefts of the lip and palate: Part 3. Dental arch relationships. *Cleft Palate Craniofacial Journal*. 1992;**29**(5):405-408. DOI: 10.1016/j.fsc.2016.06.052
- [6] Bishara SE, de Arrendondo RS, Vales HP, Jakobsen JR. Dentofacial relationships in persons with unoperated clefts: Comparisons between three cleft types. *American Journal of Orthodontics*. 1985;**87**(6):481-507. DOI: 10.1097/SCS.0000000000002889
- [7] Bill J, Proff P, Bayerlein T, Weingaertner J, Fanghanel J, Reuther J. Treatment of patients with cleft lip, alveolus and palate – A short outline of history and current interdisciplinary treatment approaches. *Journal of Cranio-maxillofacial Surgery*. 2006; **34**(2):17-21. DOI: 10.1016/j.ijporl.2016.12.030
- [8] Derijcke A, Eerens A, Carels C. The incidence of oral clefts: A review. *British Journal of Oral and Maxillofacial Surgery*. 1996;**34**(6):488-494. DOI: 10.1097/MCD.0000000000000172
- [9] Daskalogiannakis J, Kuntz K, Chudley A, Ross B. Unilateral cleft lip with or without cleft palate and handedness: Is there an association?. *Cleft Palate Craniofacial Journal*. 1998;**35**(1):46-51. DOI: 10.1097/SCS.00000000000003506
- [10] Shprintzen R, Higgins M, Antshel K, Fremont W, Roizen N, Kates W. Velo-cardio-facial syndrome. *Current Opinion in Pediatrics*. 2005;**17**(6):725-30. DOI: 10.1111/1460-6984.12307
- [11] Sandham A. Classification of clefting deformity. *Early Human Development*. 1985;**12**(1): 81-85 DOI: 10.1007/s00268-017-3896-8
- [12] Thornton J, Nimer S, Howard P. The incidence, classification, etiology, and embryology of oral clefts. *Seminars in Orthodontics*. 1996;**2**(3):162-168. DOI: 10.1016/j.actbio.2017.01.053
- [13] Wong F, Hagg U. An update on the aetiology of orofacial clefts. *Hong Kong Medical Journal*. 2004;**10**(5):331-336. DOI: 10.1597/14-296

- [14] Machida J, Yoshiura K, Funkhauser C, Natsume N, Kawai T, Murray J. Transforming growth factor- $\alpha$  (TGFA): Genomic structure, boundary sequences, and mutation analysis in nonsyndromic cleft lip/palate and cleft palate only. *Genomics*. 1999;**61**:237-242. DOI: 10.1597/16-156
- [15] Turhani D, Item C, Watzinger E, Sinko K, Watzinger F, Lauer G, Ewers R. Mutation analysis of CLPTM 1 and PVRL 1 genes in patients with non-syndromic clefts of lip, alveolus and palate. *Journal of Cranio-maxillofacial Surgery*. 2005;**33**(5):301-306. DOI: 10.1093/hmg/ddx012
- [16] Arosarena O. Cleft lip and palate. *Otolaryngologic Clinics of North America*. 2007;**40**(1):27-60. DOI: 10.1597/16-008
- [17] Seller MJ, Bnait KS. Effects of tobacco smoke inhalation on the developing mouse embryo and fetus. *Reproductive Toxicology*. 1995;**9**(5):449-459. DOI: 10.1097/SCS.0000000003324
- [18] Little J, Cardy A, Arslan M, Gilmour M, Mossey A. Smoking and orofacial clefts: A United Kingdom-based case-control study. *Cleft Palate Craniofacial Journal*. 2004;**41**(4):381-386. DOI: 10.1038/srep38872
- [19] Schubert J, Schmidt R, Syska E. B group vitamins and cleft lip and cleft palate. *International Journal of Oral and Maxillofacial Surgery*. 2002;**31**(4):410-413. DOI: 10.3889/oamjms
- [20] Krost B, Schubert J. Influence of season on prevalence of cleft lip and palate. *International Journal of Oral and Maxillofacial Surgery*. 2006;**35**(3):215-218. DOI: 10.3892/mmr.2017.6107
- [21] Schnitt D, Agir H, David D. From birth to maturity: A group of patients who have completed their protocol management. Part I. Unilateral cleft lip and palate. *Plastic and Reconstructive Surgery*. 2004;**113**(3):805-817. DOI: 10.1186/s12887
- [22] Sommerlad B, Mehendale F, Birch M, Sell D, Hattee C, Harland K. Palate re-repair revisited. *Cleft Palate Craniofacial Journal*. 2002;**39**(3):295-307. DOI: 10.1080/08870446.2016.1275630
- [23] Shaw W, Semb G, Nelson P, Brattstrom V, Molsted K, Prahl-Andersen B, Gundlach K. The eurocleft project 1996–2000: Overview. *Journal of Maxillofacial Surgery*. 2001;**29**(3):131-140. DOI: 10.1111/jop.12548
- [24] Heinrich A, Proff P, Michel T, Ruhland F, Kirbschus A, Gedrange T. Prenatal diagnostics of cleft deformities and its significance for parent and infant care. *Journal of Craniomaxillofacial Surgery*. 2006;**34**(2):14-16. DOI: 10.1155/2016/3054578
- [25] Endriga C, Speltz L, Mark L, Jones K. Do psychosocial variables predict the physical growth of infants with orofacial clefts? *Infant Behavior & Development*. 1998;**21**(4):700-712. DOI: 10.1002/ajmg.a.37740
- [26] Turner C, Zagirova A, Frolova E, Courts F, Williams W. Oral health status of Russian children with unilateral cleft lip and palate. *Cleft Palate Craniofacial Journal*. 1998;**35**(6):489-494. DOI: 10.1002/bdra.23512

- [27] Cruz C. Presurgical orthopedics appliance: The latham technique. *Oral and Maxillofacial Surgery Clinics of North America*. 2016;**28**(2):161-168. DOI: 10.1016/j.coms.2016.01.004
- [28] Attiguppe P, Karuna Y, Yavagal C, Naik S, Deepak M, Maganti R, Krishna G. Presurgical nasoalveolar molding: A boon to facilitate the surgical repair in infants with cleft lip and palate. *Contemporary Clinical Dentistry*. 2016;**7**(4):569-573. DOI: 10.1001/jamaoto.2016.3175
- [29] Liang Z, Yao J, Chen PK, Zheng C, Yang J. Effect of presurgical nasoalveolar molding on nasal symmetry in unilateral complete cleft lip/palate patients after primary cheiloplasty without concomitant nasal cartilage dissection: Early childhood evaluation. *Cleft Palate Craniofacial Journal*. 2017;**13**(7):75-81. DOI: 10.1597/14-296
- [30] Grayson B, Garfinkle S. Early cleft management: The case for nasoalveolar molding. *American Journal of Orthodontics and Dentofacial Orthopedics*. 2014;**145**:134-142. DOI: 10.1016/j.oorth.2016.08.007
- [31] da Silva FO, de Castro MM, de Andrade A, de Souza Freitas A, Bishara S. Upper dental arch morphology of adult unoperated complete bilateral cleft lip and palate. *American Journal of Orthodontics and Dentofacial Orthopedics*. 1998;**114**(2):154-161. DOI: 10.7196/SAMJ.2016.v106i10.11314
- [32] Mitchell L. *An Introduction to Orthodontics*. 2nd ed. Oxford University Press, New York; 2012. pp. 177-189. DOI:10.1111/jan.12994
- [33] Taub P, Piccolo P. Cleft lip repair: Through the looking glass. *Journal of Craniofacial Surgery*. 2016;**27**(8):2031-2035. DOI: 10.1097/SCS.0000000000002889
- [34] Woo A. Evidence-based medicine: Cleft palate. *Plastic and Reconstructive Surgery*. 2017;**139**(1):191e-203e. DOI: 10.1097/PRS.0000000000002854
- [35] Larsson A, Schölin J, Mark H, Jönsson R, Persson C. Speech production in 3-year-old internationally adopted children with unilateral cleft lip and palate. *International Journal of Language and Communication Disorders*. 2017;**14**(5):52-59. DOI: 10.1111/1460-6984.1230
- [36] Prathanee B, Pumnum T, Seepuham C, Jaiyong P. Five-year speech and language outcomes in children with cleft lip-palate. *Craniofacial Surgery*. 2016;**44**(10):1553-1560. DOI: 10.1016/j.jcms.2016.08.004
- [37] Lam D, Starr R, Perkins A, Lewis W, Eblen E, Dunlap J, Sie K. A comparison of nasendoscopy and multiview videofluoroscopy in assessing velopharyngeal insufficiency. *Otolaryngology Head and Neck Surgery*. 2006;**134**(3):394-402. DOI: 10.1016/j.coms.2016.01.003
- [38] Nyberg J, Havstam C. Speech in 10-year-olds born with cleft lip and palate: What do peers say?. *Cleft Palate Craniofacial Journal*. 2016;**53**(5):516-526. DOI: 10.1597/15-140
- [39] Paliobei V, Psifidis A, Anagnostopoulos D. Hearing and speech assessment of cleft palate patients after palatal closure. Long-term results. *International Journal of Pediatric Otorhinolaryngology*. 2005;**69**(10):1373-1381. DOI: 10.1097/SCS.0b013e3181b6c82d

- [40] Subtelny D. Oral respiration: Facial maldevelopment and corrective dentofacial orthopedics. *The Angle Orthodontist*. 1980;**50**:147-164. DOI: 10.1097/SCS.0b013e3181b6c69f
- [41] Rivkin C, Keith O, Crawford P, Hathorn S. Dental care for the patient with a cleft lip and palate. Part 2: The mixed dentition stage through to adolescence and young adulthood. *British Dental Journal*. 2000;**188**(3):131-134. DOI: 10.1097/SCS.0b013e3181b5d4c0
- [42] Takahashi T, Fukuda M, Yamaguchi T, Kochi S, Inai T, Watanabe M, Echigo S. Use of an osseointegrated implant for dental rehabilitation after cleft repair by periosteoplasty: A case report. *Cleft Palate Craniofacial Journal*. 1997;**34**(3):268-271. DOI: 10.1097/SCS.0b013e3181b5d08e
- [43] Gürsoy S, Hukki J, Hurmerinta K. Five-year follow-up of maxillary distraction osteogenesis on the dentofacial structures of children with cleft lip and palate. *Journal of Oral and Maxillofacial Surgery*. 2010;**68**(4):744-750. DOI: 10.1016/j.joms.2009.07.036
- [44] Newlands C. Secondary alveolar bone grafting in cleft lip and palate patients. *British Journal of Oral and Maxillofacial Surgery*. 2000;**38**(5):488-491. DOI: 10.1097/SCS.0b013e3181b3
- [45] Solis A, Figueroa A, Cohen M, Polley J, Evans A. Maxillary dental development in complete unilateral alveolar clefts. *Cleft Palate Craniofacial Journal*. 1998;**35**:320-328. DOI: 10.1597/14-136
- [46] Figueiredo D, Cardinal L, Bartolomeo F, Palomo M, Horta C, Andrade I, Oliveira DD. Effects of rapid maxillary expansion in cleft patients resulting from the use of two different expanders. *Dental Press Journal of Orthodontics*. 2016;**21**(6):82-90. DOI: 10.1590/2177-6709.2016-001.aop
- [47] Garib DG, Garcia LC, Pereira V, Lauris RC, Yen S. A rapid maxillary expander with differential opening. *Journal of Clinical Orthodontics*. 2014;**48**(7):430-435 DOI: 10.3109/2000656X.2015
- [48] Vig K, Mercado M. Overview of orthodontic care for children with cleft lip and palate, 1915-2015. *American Journal of Orthodontics and Dentofacial Orthopedics*. 2015;**148**(4):543-556. DOI: 10.1016/j.ajodo.2015.07.021
- [49] Tome W, Yashiro K, Kogo M, Yamashiro T. Cephalometric outcomes of maxillary expansion and protraction in patients with unilateral cleft lip and palate after two types of palatoplasty. *Cleft Palate Craniofacial Journal*. 2016;**53**(6):690-694. DOI: 10.1097/01.prs.0000472269.61556.61
- [50] Hammond J. The Belle Maudsley memorial lecture 1986. Treatment of maxillary retrusion in a case of cleft lip and palate. *Dental Update*. 1987;**14**(5):193-196, 198, 200. DOI: 10.1007/s12663-013-0490-y
- [51] Bhuskute A, Tollefson T. Cleft lip repair, nasoalveolar molding, and primary cleft rhinoplasty review. *Facial Plastic Surgery Clinics of North America*. 2016;**24**(4):453-466. DOI: 10.1016/j.fsc.2016.06.015



- [52] Berniczei-Roykó Á, Tappe JH, Krinner A, Gredes T, Végh A, Gábor K, Linkowska-Świdzińska K, Botzenhart UU. Radiographic study of the prevalence and distribution of hypodontia associated with unilateral and bilateral cleft lip and palate in a Hungarian population. *Medical Science Monitor*. 2016;**21**(22):3868-3885. DOI: 10.4103/2231-0746.161060
- [53] Al-Kharboush G, Al-Balkhi K, Al-Moammar K. The prevalence of specific dental anomalies in a group of Saudi cleft lip and palate patients. *Saudi Dental Journal*. 2015;**27**(2):75-80. DOI: 10.1016/j.sdentj.2014.11.007
- [54] Jepson M, Noh S, Carter E, Gillgrass J, Meechan G, Hobson S, Nunn H. The interdisciplinary management of hypodontia: Restorative dentistry. *British Dental Journal*. 2003;**194**(6):299-304. DOI: 10.1093/jamia/ocv125
- [55] Pruzinsky T. Social and psychological effects of major craniofacial deformity. *Cleft Palate Craniofacial Journal*. 1992;**29**(6):578-584. discussion 570. DOI: 10.1093/jamia/ocv125
- [56] Slifer K, Diver T, Amari A, Cohn F, Hilley L, Beck M, McDonnell S, Kane A. Assessment of facial emotion encoding and decoding skills in children with and without oral clefts. *Journal of Craniomaxillofacial Surgery*. 2003;**31**(5):304-315. DOI: 10.1002/ajmg.a.37342
- [57] Millard T, Richman C. Different cleft conditions, facial appearance, and speech: Relationship to psychological variables. *Cleft Palate Craniofacial Journal*. 2001;**38**(1):68-75. DOI: 10.1002/ajmg.a.35767
- [58] Broder H, Richman C, Matheson B. Learning disability, school achievement, and grade retention among children with cleft: A two-center study. *Cleft Palate Craniofacial Journal*. 1998;**35**(2):127-131. DOI: 10.4103/1817-1745.131491

