

We are IntechOpen, the world's leading publisher of Open Access books Built by scientists, for scientists

6,900

Open access books available

185,000

International authors and editors

200M

Downloads

Our authors are among the

154

Countries delivered to

TOP 1%

most cited scientists

12.2%

Contributors from top 500 universities



WEB OF SCIENCE™

Selection of our books indexed in the Book Citation Index
in Web of Science™ Core Collection (BKCI)

Interested in publishing with us?
Contact book.department@intechopen.com

Numbers displayed above are based on latest data collected.
For more information visit www.intechopen.com



Endoscopic Ultrasonography (EUS) and Gallbladder

Amir Houshang Mohammad Alizadeh

Additional information is available at the end of the chapter

<http://dx.doi.org/10.5772/67758>

Abstract

Diseases of the gallbladder commonly manifest as cholelithiasis and gallbladder cancer. Cholelithiasis has become a significant health problem in developed societies, affecting 10–15% of the adult population. Gallbladder polyps are incidentally detected in approximately 4–7% of patients. In addition, other gallbladder problems may also occur, but these are extremely rare: remnant cystic duct, gallbladder anomalies, Mirizzi syndrome, and gallbladder parasites. Endoscopic ultrasound (EUS) is an excellent method for visualizing the bile duct and gallbladder given its proximity when imaging from the duodenum. EUS can be used for evaluation of gallbladder disease that includes investigation of suspected cholelithiasis or biliary sludge, imaging of polypoid lesions of the gallbladder, and diagnosis and staging of gallbladder cancer. This procedure can be helpful to further distinguish benign from malignant or potentially malignant gallbladder polyps and play an important role in determining the treatment strategy for gallbladder polyps. Furthermore, EUS can help in the diagnosis of rarely gallbladder diseases such as remnant cystic duct, gallbladder anomalies, Mirizzi syndrome, and gallbladder parasites. Recent studies have suggested that EUS-guided gallbladder drainage (EUS-GBD) can be considered to be an effective emergency treatment for acute cholecystitis patients at high risk for surgery.

Keywords: gallbladder, EUS, FNA

1. Introduction

The gallbladder diseases are relatively common. Of these, cholelithiasis is the most common pathology that affects 10–15% of the adult population. Other conditions such as gallbladder polyp are found in about 5% of the global population, while the estimated incidence of gallbladder cancer is approximately two cases per 100,000 population worldwide [1, 2].

The diseases of gallbladder are generally diagnosed by several different imaging methods in the clinic. Endoscopic ultrasonography (EUS) was introduced in 1980 and has developed considerably in the past 30 years. EUS has recently played an increasing role in the diagnosis of gallbladder diseases [1, 3]. Clinical situations in which EUS can be used for evaluation of gallbladder disease include investigation of suspected cholelithiasis or biliary sludge, imaging of polypoid lesions of the gallbladder, and diagnosis and staging of gallbladder cancer. This diagnostic procedure provides high-resolution images that can improve the diagnosis of gallbladder diseases [1, 4].

It is noteworthy that EUS is an accurate modality for imaging gallbladder structures because of the close proximity of the duodenum to the gallbladder and extrahepatic biliary tree. EUS can differentiate the double-layered structure of the gallbladder wall and provide higher resolution for imaging small polypoid lesions (<2 cm) with sensitivity to up to 91.7% and specificity to up to 87.7 [1, 4]. Finally, EUS-guided gallbladder drainage (EUS-GBD) is recently gaining favor as an attractive alternative for managing acute cholecystitis in high-risk patients. The advantages of EUS-GBD are the avoidance of external drainage (unlike percutaneous transhepatic gallbladder drainage) and the potential for no risk of post-ERCP (endoscopic retrograde cholangiopancreatography) pancreatitis or cholangitis (unlike transpapillary drainage) [5, 6].

2. EUS and gallbladder microlithiasis

Gallstones (Cholelithiasis) constitute a significant health problem in developed societies, affecting 10–15% of the adult population. Microlithiasis is defined as small stones (radiological invisibility stones less than 5 mm in diameter and/or stones less than 3 mm in diameter) in the gallbladder and is also referred to as sludge, biliary sand, biliary sediment, microcrystalline disease, pseudolithiasis, and reversible choledocholithiasis [7–9].

Transabdominal US is considered the gold standard for evaluation of gallbladder stones that have been shown to have a high sensitivity (about 98%) for the detection of cholecystolithiasis. However, in some patients, this procedure may miss gallstones, particularly those with small gallstones, and a high level of clinical suspicion for cholelithiasis may make additional studies warranted. Detection of the gallbladder microlithiasis because of their small size may be difficult [4, 8]. Microlithiasis in the gallbladder may be undetected by transabdominal ultrasound and rarely detected on other imaging modalities including multidetector computed tomography (CT) and magnetic resonance imaging (MRI). In some patients with microlithiasis, biliary sludge and/or gallstones can be detected by EUS, with its high spatial resolution [9–11].

It is noteworthy that idiopathic pancreatitis is diagnosed in 10–30% of acute pancreatitis episodes. Recent studies have suggested that microlithiasis is a cause of unexplained pancreatitis in up to 75% of patients with an intact gallbladder [11, 12]. Given the high incidence of microlithiasis and/or biliary sludge as a cause of idiopathic pancreatitis and high accuracy

of EUS for recognizing these diagnoses, EUS should be considered as a minimally invasive highly accurate diagnostic tool for idiopathic pancreatitis after conventional radiography fails (Figure 1).

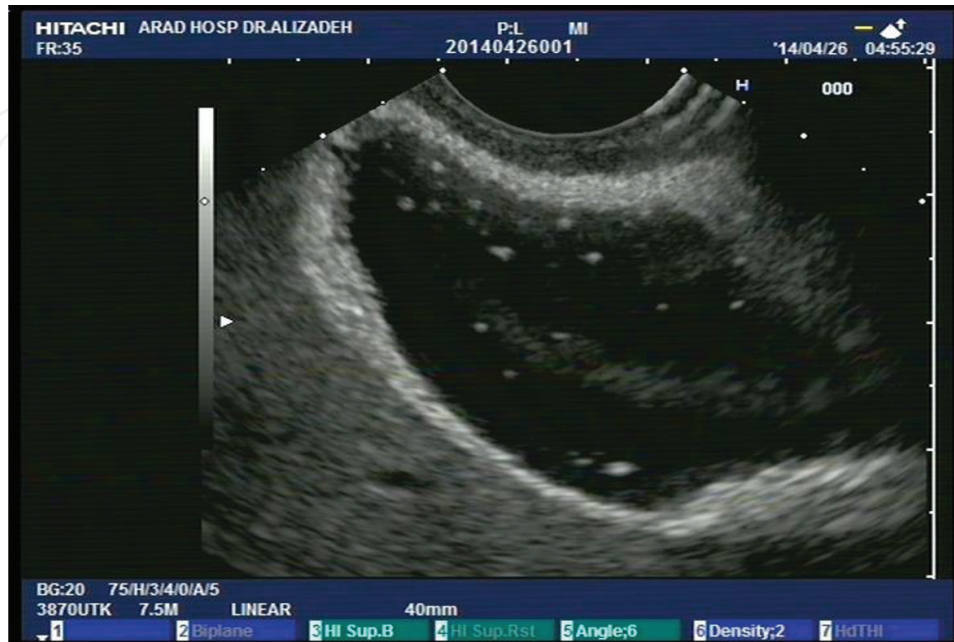

Figure 1. EUS revealed microlithiasis of gallbladder.

Overall, the diagnostic yield of EUS in recurrent idiopathic pancreatitis (RIP) varies from 32 to 88%. Chronic pancreatitis, identified by EUS, is emerging as an important and potential cause of RIP, although EUS may be lack of specificity in the diagnosis of chronic pancreatitis if secretin stimulation testing is used as the gold standard. Preliminary observations indicate that EUS may decrease the need for ERCP through the identification of microlithiasis and chronic pancreatitis [11, 13].

3. EUS and gallbladder polypoid lesions

The gallbladder polypoid lesions are relatively common, with a reported prevalence of approximately 3–7% in patients who undergo transabdominal ultrasonography (US).

On US, these masses have an image with similar echogenicity as that of the gallbladder wall, the lesion projects into the lumen, are fixed, and lack an acoustic shadow. Gallbladder polyps are classified as benign or malignant [4, 14]. Cholesterol polyps are most common benign polypoid gallbladder lesions (62.8%), which appear as pedunculated lesions with a granular surface and an internal echo pattern of a tiny echogenic spot or spots, sometimes with echogenic areas. Other polypoid lesions include adenomyomatosis, adenoma, and adenocarcinoma.

The poor prognosis of gallbladder carcinoma patients means it is important to differentiate between benign polyps and malignant or premalignant polyps [14, 15].

The development and refinement of diagnostic imaging modalities such as EUS and their widespread application have led to an increase in the coincidental diagnosis of gallbladder polyps. Current recommendations for the management of gallbladder polyps are based largely on polyp size. Gallbladder polyps larger than 10 mm in diameter, particularly among patients more than 50 years of age, are generally indications for cholecystectomy because of the risk of malignancy [4, 14, 16].

Transabdominal ultrasonography (US) has made the detection of gallbladder polyps easier, but the differential diagnosis of polyps less than 20 mm remains difficult. EUS can be helpful to further distinguish benign from malignant or potentially malignant gallbladder polyps, and is superior to transabdominal US for this purpose. Overall, EUS markedly improves the accuracy of the differential diagnosis of gallbladder polyps and is thought to play an important role in determining the treatment strategy for gallbladder polyps [4, 14, 17].

3.1. Adenomyomatoses

Adenomyomatosis is a non-inflammatory gallbladder alteration that occurs in middle age patients and the incidence increases with age. Adenomyomatosis of the gallbladder (GA) remains a common entity among benign gallbladder masses, diagnosed in 2–8% of all cholecystectomies in recent studies. The differentiation of GA from gallbladder cancer is still required because of the similarity in the appearance between gallbladder adenomyomatosis and gallbladder cancer, although many studies have reported imaging findings of adenomyomatosis of the gallbladder using US, computed tomography (CT), magnetic resonance imaging (MRI) and EUS [15, 18, 19].

EUS is a minimally invasive imaging method that can provide high quality images of the gallbladder. EUS has been reported to identify gallbladder adenomyomatosis lesions that were missed by routine abdominal ultrasound. However, this procedure may mistakenly misdiagnose gallbladder cancer as adenomyomatosis. This inaccuracy may occur because of the sole presence of multiple microcysts that can also be seen in gallbladder cancer. In addition to this, EUS provides an additional valuable function, which is the ability to perform EUS fine-needle aspiration of local lymph nodes, although a resectable gallbladder mass suspicious for cancer should not undergo biopsy due to the risk of seeding. Due to the high cost of performing EUS (its relative invasiveness) and the advanced training it requires, ultrasound remains the primary screening method. So, EUS may be unnecessary in patients in whom ultrasonography produces characteristic findings of adenomyomatosis [18–20].

3.2. Gallbladder carcinoma

Gallbladder carcinoma (GBC) is the fifth most common gastrointestinal malignancy and the most common biliary tract cancer, accounting for 3% of all tumors. Detection and diagnosis of the gallbladder carcinoma in its early stages is hard because it usually has very slight symptoms or is asymptomatic (**Figure 2**). But once the diagnosis is confirmed, most of these patients often have metastasis and invasion. In addition to this, gallbladder carcinoma is not sensitive to radiotherapy

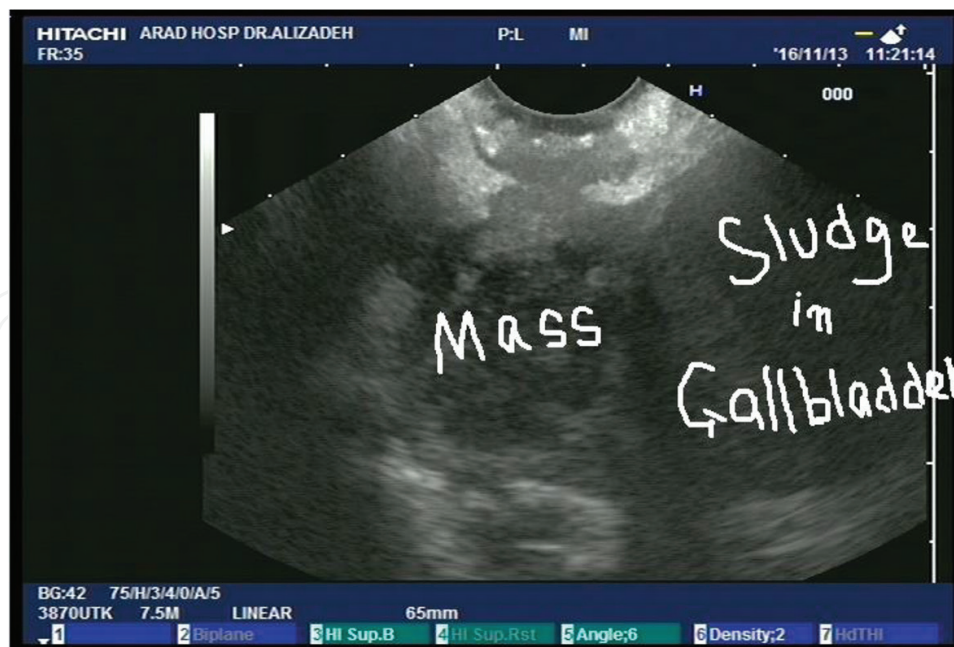


Figure 2. Gallbladder carcinoma in EUS: thickness and irregularity in the wall of gallbladder with invasion to duodenal wall.

and chemotherapy. All of these characteristics make gallbladder carcinoma as a highly lethal tumor with a five-year survival rate of less than 5% [16, 21]. Many of the signs and symptoms of gallbladder carcinoma are nonspecific, so it is more likely to be diagnosed at an advanced stage in patients and is associated with a high mortality rate. It is important the accurate preoperative staging (Table 1) of gallbladder carcinoma, because staging is essential to determine the operative approach, and depth of invasion (T stage) closely correlates with prognosis [4, 15].

Considering that survival after simple cholecystectomy for T1 disease is reported to be near 100%. It becomes increasingly necessary for early diagnosis and identifying patients at high risk of gallbladder carcinoma. As mentioned earlier, EUS can be helpful to distinguish benign from malignant or potentially malignant gallbladder polyps (Figure 3).

In addition, there has been interest in using EUS for preoperative staging of gallbladder carcinoma because of this procedure allow detailed visualization of the layers of the gallbladder wall [4, 16]. This procedure is more sensitive than transabdominal US and has the added benefit of determining depth of invasion, extent of local disease, and nodal disease. Moreover, diagnostic accuracy of EUS has been shown for T-stage: Tis-stage 100%, T1-stage 75.6%, T2-stage 85.3%, and T3,4-stage 92.7%. EUS also adds the possibility of fine needle aspiration (FNA) for tissue diagnosis of the primary as well as lymph nodes, where diagnostic accuracy approaches 100% [16, 21].

Finally, a scoring system to predict malignant gallbladder polyps has been presented. The total EUS score on the basis of coefficient of multivariate analysis has been shown as follows: (maximum diameter in mm) + (internal echo pattern score; where heterogeneous = 4, homogeneous = 0) + (hyperechoic spot score; where presence = 5, absence = 0). According to EUS scoring system, the specificity, sensitivity, and accuracy for the risk of malignant gallbladder polyps with scores of 12 or higher were reported for 83, 78, and 83%, respectively [4, 15]. Proposed algorithm for management of gallbladder polyps is shown in Figure 4.

Primary tumor (T)	
TX, primary tumor cannot be assessed	
T0, no evidence of primary tumor	
Tis, carcinoma in situ	
T1, tumor invades lamina propria or muscle layer	
T1a, tumor invades lamina propria	
T1b, tumor invades muscle layer	
T2, tumor invades perimuscular connective tissue; no extension beyond serosa or into liver	
T3, tumor perforates the serosa (visceral peritoneum) and/or directly invades the liver and/or one other adjacent organ or structure	
T4, tumor invades main portal vein or hepatic artery or invades two or more extrahepatic organs or structures	
Regional lymph nodes (N)	
NX, regional lymph nodes cannot be assessed	
N0, no regional lymph node metastasis	
N1, metastases to nodes along the cystic duct, common bile duct, hepatic artery, and/or portal vein	
N2, metastases to periaortic, pericaval, superior mesenteric artery, and/or celiac artery lymph nodes	
Distant metastasis (M)	
M0, no distant metastasis	
M1, distant metastasis	

Table 1. TNM (tumor, node, metastasis) staging of gallbladder carcinoma [4].

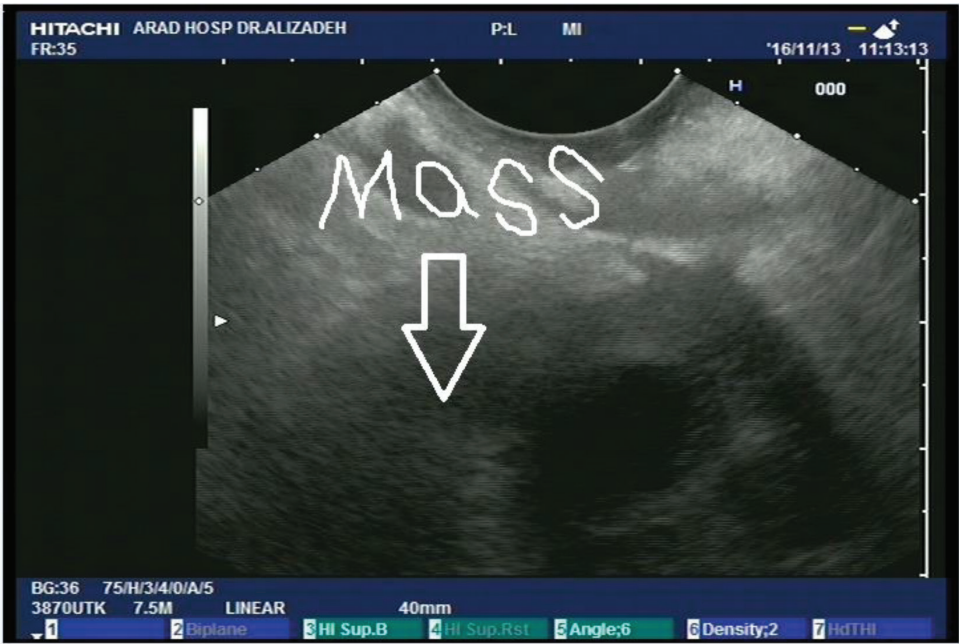


Figure 3. Mass of gallbladder.

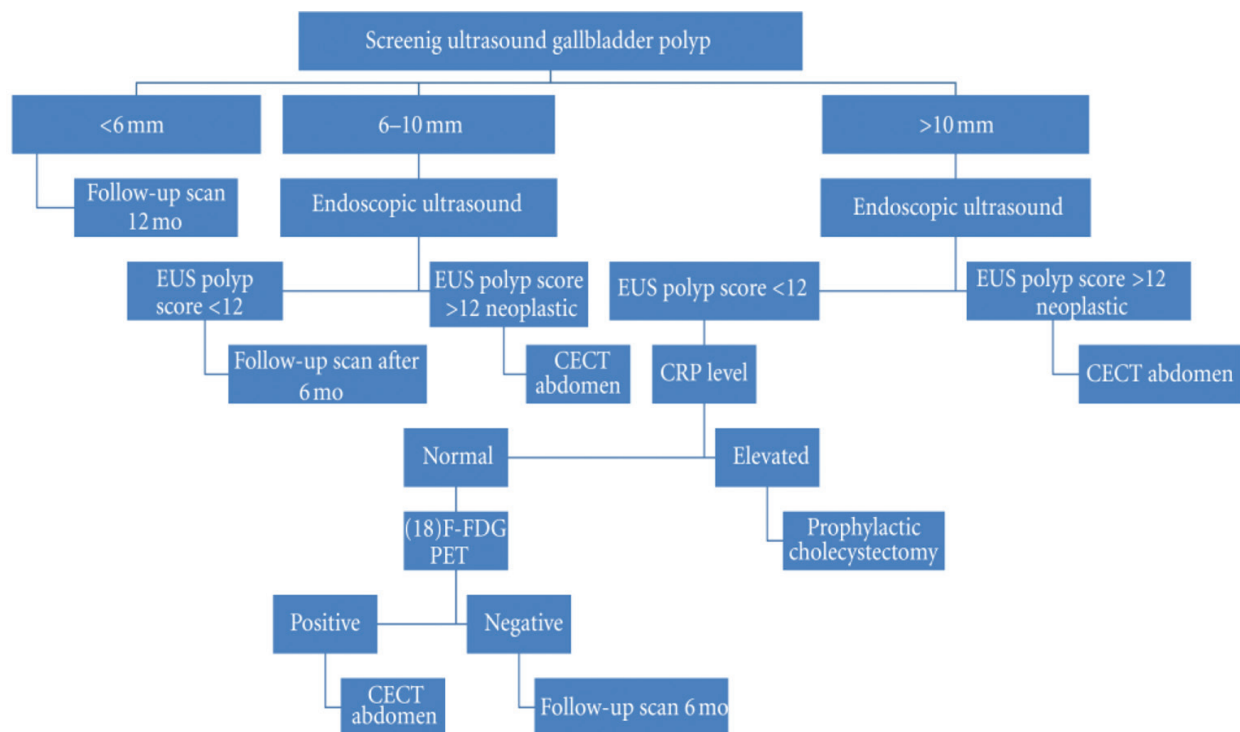


Figure 4. Proposed algorithm for management of gallbladder polyps. EUS, endoscopic ultrasound; CECT, contrast-enhanced computer tomography; FDG PET, fludeoxyglucose positron emission tomography [16].

4. EUS and remnant cystic duct

Postcholecystectomy syndrome (PCS) is a common manifestation in patients with cholecystectomy. Choledocholithiasis, biliary dyskinesia, and dilation of cystic duct remnants are common causes of these symptoms. Cystic duct or gallbladder remnant with or without stones is one of the important causes of postcholecystectomy syndrome [22, 23]. Usually, a cystic duct remnant measuring 1–2 cm in length is left, although remnants can be seen up to 6 cm in length. Stones in the gallbladder remnant after cholecystectomy are difficult to identify [23, 24].

Recent progress in radiological imaging has greatly improved diagnostic accuracy in detecting the causes of persistence of symptoms in postcholecystectomy patients. Noninvasive methods of imaging such as US, CT scan, MRCP, and ERCP have been used effectively for diagnosis of gallbladder remnant with or without stones in patients complaining of symptoms suggestive of postcholecystectomy syndrome. Nevertheless, diagnosis of residual gallbladder with gallstones remains difficult. EUS is an excellent diagnostic modality in this situation. EUS procedure is indicated in the presence of strong clinical suspicion with a negative finding on abdominal US. Furthermore, EUS has proven feasibility in diagnosing liver and biliary pathologies with sensitivity and specificity of 96.2 and 88.9%, respectively, and has also been shown to be cost effective in preventing a number of ERCPs [24–26].

5. EUS and Mirizzi syndrome

Mirizzi syndrome is the extrinsic compression of the bile duct by a gallstone at the level of the gallbladder neck or at the cystic duct level. Pablo Luis Mirizzi first described the syndrome in 1948 [27, 28]. Mirizzi syndrome occurs in 0.7–2.8% of patients undergoing cholecystectomy. The syndrome represents a diagnostic challenge because standard imaging may fail to demonstrate external compression of the bile duct, and no findings are pathognomonic for Mirizzi syndrome. However, awareness and diagnosis of this syndrome are essential for safe operative intervention due to the high risk of injury to the bile duct during surgical procedures [28, 29].

ERCP is considered as a procedure of choice for diagnosis of Mirizzi syndrome. The radiological manifestations of the syndrome may be misinterpreted as a tumor of the gallbladder or the cystic duct, metastatic disease of the hilum or acute cholecystitis. These diseases should be differentiated from Mirizzi syndrome by a CT scan or an ultrasound. EUS images depicting Mirizzi syndrome are rare [28, 30]. However, very few studies use EUS as a diagnostic method for this syndrome. This seemed strange because EUS is a procedure that allows the observation of the complete bile duct. Furthermore, EUS adequately evaluates the condition of the whole gallbladder, from the bottom to the cystic duct, which is the place in which Mirizzi specifically locates. Finally, since EUS is less risky and less expensive than ERCP, it is suggested that EUS is used as the first diagnostic procedure to confirm whether or not this syndrome is present [27, 29].

6. EUS and gallbladder anomalies

The gallbladder is affected by a large number of congenital anomalies, which may affect its location, number, size, or form. Congenital abnormalities of the gallbladder and biliary system result from embryonic maldevelopment and are most interesting for the surgeon attempting to identify biliary anatomy at cholecystectomy. Some of gallbladder malformations are very rare and may lead to misdiagnosis. Being difficult to diagnose during routine preoperative studies, these anomalies can provide surgeons with an unusual surprise during laparoscopic surgery [31–33].

Preoperative imaging of patients with anomalies of the gallbladder and biliary tract includes US, CT, MRI, EUS, and ERCP. Anomalies of the number of gallbladder include its agenesis and duplication, which may be difficult to diagnose with the use of ultrasound. Agenesis of the gallbladder is very rare, having a prevalence of 0.007–0.13%. Abdominal CT exposes patients to radiation and might not be able to provide detailed anatomy of the gallbladder anomalies compared to magnetic resonance cholangiopancreatography (MRCP). Studies have shown that intraoperative ultrasound and postoperative MRCP or EUS can help in the diagnosis of agenesis or ectopic gallbladder. Overall, it is thought that ultrasonography is the primary imaging modality for gallbladder anomalies with CT, MRI being even more helpful, and the MRCP or EUS providing a more thorough visualization of the biliary tract [31, 34, 35].

7. EUS and gallbladder parasites

Parasitic infections of the biliary tract are a major concern in the tropical and subtropical countries with significant morbidity and mortality. These infections occur most commonly with *Ascaris lumbricoides*, *Clonorchis sinensis*, *Opisthorchis felineus*, and *Fasciola hepatica*. Biliary tree parasites can cause cholecystitis, recurrent cholangitis, biliary obstruction, stone formation, and biliary tree strictures, and some may lead to cholangiocarcinoma. Hence, it is important to be aware of the clinical features, diagnostic modalities, and management strategies for various parasites that infest the biliary tract [36–38].

Ultrasonography, CT, and MRI are not only important in the diagnosis of parasitic biliary diseases but also in the follow-up and surveillance. Furthermore, ERCP is a highly sensitive procedure to demonstrate the presence of parasites in the biliary tree [39, 40]. This procedure is also used in the therapy of biliary parasitic infestations and carries less morbidity and mortality than the surgical approach. It is noteworthy that EUS may also be helpful in the detection of a mobile worm in the extrahepatic bile duct. This diagnostic method can also be a sensitive imaging modality for the extrahepatic bile duct in real time and may be useful for the diagnosis of biliary fascioliasis. Overall, several studies have shown that EUS may be helpful in the diagnosis of parasites in the biliary tract including *Fasciola hepatica* and *Ascaris* [40–42].

8. EUS-guided gallbladder drainage

Acute cholecystitis is defined as an acute inflammation of the gallbladder wall, regardless of the cause. It results from obstruction to the cystic duct secondary to multiple causes, of which cholelithiasis is the most common followed by benign or malignant biliary strictures. The first line management of acute cholecystitis remains cholecystectomy for patients with good operative candidates. However, early surgical management in elderly patients, those with multiple comorbidities, and those with severe cholecystitis is associated with increased morbidity and mortality [43–45].

Percutaneous transhepatic gallbladder drainage (PTGBD) has been considered the preferred method for several decades in patients with high surgical risk. Although PTGBD has a technical success of nearly 97%, clinical response rates range from 56 to 100% and is also associated with adverse events as high as 14%. PTGBD may be inappropriate for patients with uncorrectable coagulopathy or massive ascites. Moreover, patient discomfort and postprocedure pain have been associated with the percutaneous drainage catheters [46, 47].

Endoscopic gallbladder drainage (GBD) technique includes transpapillary gallbladder stenting, transpapillary gallbladder drainage with nasobiliary drainage (ENGBD), and EUS-guided gallbladder drainage (EUS-GBD). EUS-GBD is recently gaining favor as an attractive alternative approach for management of acute cholecystitis in high-risk surgical patients [5, 46]. EUS-GBD has been performed by using plastic stents, nasobiliary catheters, covered self-expandable metal stents, and, most recently, lumen-apposing metal stents (LAMs). Self-expandable metal stents have an advantage over plastic stents because of their ability to seal

the gap between the stent and the gallbladder wall, theoretically reducing bile leaks. The perceived advantages of EUS-GBD are the avoidance of external drainage, internalization of bile, less postprocedure pain (unlike PTGBD), and the potential for no risk of ERCP pancreatitis or cholangitis (unlike transpapillary drainage) [6, 48].

9. Conclusion

EUS is an important new modality for the evaluation of gallbladder disease. This procedure can effectively identify patients with cholelithiasis and gallbladder microlithiasis. Furthermore, studies have shown that EUS can help in the diagnosis of remnant cystic duct, gallbladder anomalies, Mirizzi syndrome, and gallbladder parasites. Polypoid lesions of the gallbladder can be accurately classified by EUS, which can also be safely used to perform FNA to provide a histologic diagnosis. EUS staging of gallbladder carcinoma can help guide therapy and predict prognosis. Recently, EUS-GBD has become an attractive alternative procedure for management of acute cholecystitis in high-risk surgical patients.

Author details

Amir Houshang Mohammad Alizadeh

Address all correspondence to: ahmaliver@yahoo.com

Endoscopy Department, Shahid Beheshti University of Medical Sciences, Taleghani Hospital, Tehran, Iran

References

- [1] Chantarojanasiri T, Hirooka Y, Kawashima H, Ohno E, Kongkam P, Goto H. The role of endoscopic ultrasound in the diagnosis of gallbladder diseases. *Journal of Medical Ultrasonics*. 2016;1–8.
- [2] Corwin MT, Siewert B, Sheiman RG, Kane RA. Incidentally detected gallbladder polyps: is follow-up necessary? Long-term clinical and US analysis of 346 patients 1. *Radiology*. 2011;258(1):277–82.
- [3] Ko H, Choi I, Chang K, Jeong G, Gong G, Seo H, et al. Amphiphilic metabolites in gallbladder bile: potential biomarkers for gallbladder diseases. *Applied Spectroscopy Reviews*. 2016;51(7–9):706–17.
- [4] O'Neill DER, Saunders MD. Endoscopic ultrasonography in diseases of the gallbladder. *Gastroenterology Clinics of North America*. 2010;39(2):289–305.
- [5] Patil R, Ona MA, Papafragkakis C, Anand S, Duddempudi S. Endoscopic ultrasound-guided placement of the lumen-apposing self-expandable metallic stent for gallbladder

drainage: a promising technique. *Annals of Gastroenterology: Quarterly Publication of the Hellenic Society of Gastroenterology*. 2016;29(2):162.

- [6] Choi JH, Lee SS. Endoscopic ultrasonography-guided gallbladder drainage for acute cholecystitis: from evidence to practice. *Digestive Endoscopy*. 2015;27(1):1–7.
- [7] Stinton LM, Shaffer EA. Epidemiology of gallbladder disease: cholelithiasis and cancer. *Gut Liver*. 2012;6(2):172–87.
- [8] Ardengh JC, Malheiros CA, Rahal F, Pereira V, Ganc AJ. Microlithiasis of the gallbladder: role of endoscopic ultrasonography in patients with idiopathic acute pancreatitis. *Revista da Associacao Medica Brasileira*. 2010;56(1):27–31.
- [9] Choi CS, Ku YJ, Yoon DY, Yun EJ, Seo YL, Lim KJ, et al. Harmonic ultrasonography for the detection of microlithiasis in the gallbladder. *Ultrasonography*. 2014;33(4):275.
- [10] Gerke H, Baillie J. Biliary microlithiasis: a neglected cause of recurrent pancreatitis and biliary colic? *Journal of Gastroenterology and Hepatology*. 2005;20(4):499–501.
- [11] Smith I, Ramesh J, Baig KRKK, Mönkemüller K, Wilcox CM. Emerging role of endoscopic ultrasound in the diagnostic evaluation of idiopathic pancreatitis. *The American Journal of the Medical Sciences*. 2015;350(3):229–34.
- [12] VanWoerkom R, Adler DG. Acute pancreatitis: review and clinical update. *Hospital Physician*. 2009;1:9–19.
- [13] Wilcox CM, Varadarajulu S, Eloubeidi M. Role of endoscopic evaluation in idiopathic pancreatitis: a systematic review. *Gastrointestinal Endoscopy*. 2006;63(7):1037–45.
- [14] Gallahan WC, Conway JD. Diagnosis and management of gallbladder polyps. *Gastroenterology Clinics of North America*. 2010;39(2):359–67.
- [15] Andrén-Sandberg Å. Diagnosis and management of gallbladder polyps. *North American Journal of Medical Sciences*. 2012;4(5):203.
- [16] Vijayakumar A, Vijayakumar A, Patil V, Mallikarjuna M, Shivaswamy B. Early diagnosis of gallbladder carcinoma: an algorithm approach. *ISRN Radiology*. 2012;2013.
- [17] Ito H, Hann LE, D'Angelica M, Allen P, Fong Y, Dematteo RP, et al. Polypoid lesions of the gallbladder: diagnosis and followup. *Journal of the American College of Surgeons*. 2009;208(4):570–5.
- [18] Bang SH, Lee JY, Woo H, Joo I, Lee ES, Han JK, et al. Differentiating between adenomyomatosis and gallbladder cancer: revisiting a comparative study of high-resolution ultrasound, multidetector CT, and MR imaging. *Korean Journal of Radiology*. 2014;15(2):226–34.
- [19] Hammad AY, Miura JT, Turaga KK, Johnston FM, Hohenwarter MD, Gamblin TC. A literature review of radiological findings to guide the diagnosis of gallbladder adenomyomatosis. *HPB*. 2016;18(2):129–35.
- [20] Sugiyama M, Atomi Y, Yamato T. Endoscopic ultrasonography for differential diagnosis of polypoid gall bladder lesions: analysis in surgical and follow up series. *Gut*. 2000;46(2):250–4.

- [21] Ejaz A, Sachs T, Kamel IR, Pawlik TM. Gallbladder cancer—current management options. *Oncology & Hematology Review*. 2013;9(2).
- [22] Harwani Y, Goenka M, Rai V, Goenka U. Cystic duct remnant stone removal by endoscopic retrograde cholangiopancreatography. *Journal of Digestive Endoscopy*. 2016;7(2):65.
- [23] Perera E, Bhatt S, Dogra VS. Cystic duct remnant syndrome. *Journal of Clinical Imaging Science*. 2011;1:1–4.
- [24] Mohamadnejad M, Hashemi SJ, Zamani F, Baghai-Wadji M, Malekzadeh R, Eloubeidi MA. Utility of endoscopic ultrasound to diagnose remnant stones in symptomatic patients after cholecystectomy. *Endoscopy*. 2014;46(08):650–5.
- [25] Chowbey P, Sharma A, Goswami A, Afaq Y, Najma K, Baijal M, et al. Residual gallbladder stones after cholecystectomy: a literature review. *Journal of Minimal Access Surgery*. 2015;11(4):223.
- [26] Topazian M, Salem RR, Robert ME. Painful cystic duct remnant diagnosed by endoscopic ultrasound. *The American Journal of Gastroenterology*. 2005;100(2):491–5.
- [27] Gómez MA, Meneses JC. Usefulness of endoscopy for diagnosing Mirizzi syndrome. *Revista Colombiana de Gastroenterología*. 2010;25(3):312–5.
- [28] Rayapudi K, Gholami P, Olyae M. Mirizzi syndrome with endoscopic ultrasound image. *Case Reports in Gastroenterology*. 2013;7(2):202–7.
- [29] Wilson NA, Wakeman D, Utterson EC, Vogel AM. Intraoperative endoscopic treatment of Mirizzi syndrome in a pediatric patient. *Journal of Pediatric Surgery Case Reports*. 2016;5:8–11.
- [30] Aarts M, Engels L. Mirizzi's syndrome. *Netherlands Journal of Medicine*. 2006;64(7):252–3.
- [31] Rafailidis V, Varelas S, Kotsidis N, Rafailidis D. Two congenital anomalies in one: an ectopic gallbladder with phrygian cap deformity. *Case Reports in Radiology*. 2014;2014.
- [32] Shaffer E, Romagnuolo J, Thomson A, Shaffer E. The biliary system. Thomson ABR, Shaffer EA *First Principles of Gastroenterology: The Basis of Disease and an Approach to Management*. Fifth Edition Janssen-Ortho. 2007:460–90.
- [33] Carbajo MA, Martín del Omo J, Blanco JL, Cuesta C, Martín F, Toledano M, et al. Congenital malformations of the gallbladder and cystic duct diagnosed by laparoscopy: high surgical risk. *JLS*. 1999;3(4):319–21.
- [34] Al Rawahi A, Al Azri Y, Al Jabril S, Al Fadlil A, Al Aghbaril S. Duplicate Gallbladder: overview and Management Challenges. *Clinical Surgery*. 2016;1:1016.
- [35] Mittal AK, Saxena D, Kadam R, Garg P, Kankaria J, Jenaw R. Agenesis of gallbladder: a diagnostic dilemma. *International Journal of Case Reports and Images (IJCRI)*. 2015;6(5):296–300.

- [36] Mohamed AE, Al Karawi MA, Ghandour Z. Parasitic disease of the liver and biliary tree. *Saudi Journal of Gastroenterology*. 1997;3(1):22.
- [37] Reddy D, Kumar Y. Endoscopic diagnosis and management of biliary parasitosis. UpToDate com. 1999.
- [38] Rana SS, Bhasin DK, Nanda M, Singh K. Parasitic infestations of the biliary tract. *Current Gastroenterology Reports*. 2007;9(2):156–64.
- [39] Osman M, Bach Lausten S, El-Sefi T, Boghdadi I, Rashed M-Y, Lindkær Jensen S. Biliary parasites. *Digestive Surgery*. 1998;15(4):287–96.
- [40] Ha JS, Choi HJ, Moon JH, Lee YN, Tae JW, Choi MH, et al. Endoscopic extraction of biliary fascioliasis diagnosed using intraductal ultrasonography in a patient with acute cholangitis. *Clinical Endoscopy*. 2015;48(6):579.
- [41] Sriram PV, Tandon M, Rao GV, Reddy DN. Endoscopic ultrasound features of biliary ascariasis. *Indian Journal of Gastroenterology*. 2006;25(1):50.
- [42] Sotoudehmanesh R, Yoonessi A. Diagnosis of *Fasciola hepatica* by endoscopic ultrasound. *Endoscopy*. 2003;35(12):1088.
- [43] Xu M-M, Kahaleh M. EUS-guided transmural gallbladder drainage: a new era has begun. *Therapeutic Advances in Gastroenterology*. 2015;1756283X15618178.
- [44] Pinto A, Reginelli A, Cagini L, Coppolino F, Ianora AAS, Bracale R, et al. Accuracy of ultrasonography in the diagnosis of acute calculous cholecystitis: review of the literature. *Critical Ultrasound Journal*. 2013;5(1):1.
- [45] Kahaleh M, Perez-Miranda M, Artifon EL, Sharaiha RZ, Kedia P, Peñas I, et al. International collaborative study on EUS-guided gallbladder drainage: are we ready for prime time? *Digestive and Liver Disease: Official Journal of the Italian Society of Gastroenterology and the Italian Association for the Study of the Liver*. 2016;48(9):1054.
- [46] Choi J-H, Park DH, Lee SS, Seo D-W, Lee SK, Kim M-H. Can endoscopic ultrasound help to drain the gallbladder? *Gastrointestinal Intervention*. 2013;2(1):30–5.
- [47] Khan MA, Atiq O, Kubiliun N, Ali B, Kamal F, Nollan R, et al. Efficacy and safety of endoscopic gallbladder drainage in acute cholecystitis: is it better than percutaneous gallbladder drainage? *Gastrointestinal Endoscopy*. 2016.
- [48] Itoi T, Coelho-Prabhu N, Baron TH. Endoscopic gallbladder drainage for management of acute cholecystitis. *Gastrointestinal Endoscopy*. 2010;71(6):1038–45.

