

We are IntechOpen, the world's leading publisher of Open Access books Built by scientists, for scientists

6,900

Open access books available

186,000

International authors and editors

200M

Downloads

Our authors are among the

154

Countries delivered to

TOP 1%

most cited scientists

12.2%

Contributors from top 500 universities



WEB OF SCIENCE™

Selection of our books indexed in the Book Citation Index
in Web of Science™ Core Collection (BKCI)

Interested in publishing with us?
Contact book.department@intechopen.com

Numbers displayed above are based on latest data collected.
For more information visit www.intechopen.com



Human Immunodeficiency Virus (HIV) Infection and Cancer

Lorena Loarca, Joseph A. Fraietta, Vanessa Pirrone,
Zsafia Szep and Brian Wigdahl

Additional information is available at the end of the chapter

<http://dx.doi.org/10.5772/67162>

Abstract

Human immunodeficiency virus type 1 (HIV-1) infection confers an increased risk for the development of many cancers. Although the incidences of acquired immunodeficiency syndrome (AIDS)-defining malignancies have declined since the advent of anti-retroviral therapy (ART), a number of non-AIDS-defining cancers appear more common in HIV-1-infected individuals relative to the general population. ART-treated HIV-1-infected subjects are also aging, leading to an increased cancer burden in these populations. However, longevity alone is not sufficient to explain these epidemiologic trends. A causative link between HIV-1-induced immune suppression and elevated cancer risk is well defined in certain malignancies; however, the direct role of HIV-1 replication products in oncogenesis remains unclear. Nevertheless, it is evident that cooperation between HIV-1 and co-infecting viruses in targeting immune compartments as well as nonimmune microenvironments can regulate both the development and progression of cancer. Treating cancer in HIV-1-infected patients remains challenging due to drug interactions, compounded side effects and intensified immunosuppression from chemotherapy and/or radiation. While survival of HIV-1-infected patients with certain cancers now rivals that of their uninfected counterparts, a better understanding of HIV-1-induced oncogenesis, viral mechanisms of immune perturbation, nonimmune microenvironmental abnormalities and outcomes of therapy will provide the basis for better diagnosis and management of cancer.

Keywords: HIV-1, cancer, non-AIDS-defining cancer, AIDS-defining cancer, coinfection

1. Introduction

The acquired immune deficiency syndrome (AIDS) caused by chronic infection with the human immunodeficiency virus type 1 (HIV-1) leads to severe immunosuppression and death from immunologic and neurologic dysfunction as well as a number of opportunistic infections

if left untreated. Prior to the introduction of anti-retroviral therapy (ART), the risk of AIDS patients developing Kaposi's sarcoma (KS), non-Hodgkin's lymphoma (NHL) and cervical cancer was enhanced by several fold. These three cancers have been referred to as AIDS-defining cancers (ADCs). Since 1996, when ART became readily available, the incidence of ADCs dramatically decreased and this was attributed to the partial restoration of immune function [1]. With the HIV-1-infected patient population now living longer, however, these individuals exhibit an increased risk of developing other types of cancers that are referred to as non-AIDS-defining cancers (NADCs) [2]. NADCs can be classified as either virus or nonvirus related. Although many of these cancers are directly linked to HIV-1 infection, many are not. Several factors have been associated with the elevated number of cases of NADCs observed in the last couple of decades, including low CD4⁺ T-cell counts, chronic inflammation, tobacco usage, alcohol exposure, long-term ART exposure, advanced age and co-infection with oncogenic viruses. Some of the viruses associated with the development of NADCs include human papillomavirus (HPV), Epstein-Barr virus (EBV), human T-cell leukemia virus type 1 (HTLV-1), hepatitis B virus (HBV) and hepatitis C virus (HCV).

Several lines of evidence have established an association between chronic HIV-1 infection and the development of cancer. In this review, we examine the epidemiology, etiology and pathological characteristics of cancer in the setting of chronic HIV-1 infection. We also discuss the direct participation of HIV-1 proteins such as the transactivator of transcription (Tat) protein and the envelope glycoprotein (gp)120 in potentiating tumorigenesis as well as cooperation between HIV-1 and co-infecting viruses in inducing cell transformation. In addition, we discuss the interactions between HIV-1 and immune as well as nonimmune microenvironments and their involvement in driving oncogenesis and cancer progression. Finally, challenges to the management of cancer in HIV-1-infected patients will be investigated, with a focus on the development of evidence-based treatment approaches that combine ART with effective cancer treatment plans.

2. Types of cancers observed in HIV-1-infected patients

The success of ART has extended the life span of many HIV-1-infected patients; however, with an improved life span comes an increased risk of developing a number of chronic conditions and malignancies such as cardiovascular disease, neurologic syndromes and cancer [3]. The latter accounts for approximately 25–35% of HIV-1-associated deaths, with lymphoma being the most common cause of cancer among HIV-1-infected individuals [4]. As previously indicated, the cancers that affect these individuals have been generally divided into two main categories: ADCs and NADCs.

2.1. AIDS-defining cancers (non-Hodgkin's lymphoma, Kaposi's sarcoma and cervical cancer)

2.1.1. Non-Hodgkin's lymphoma (NHL)

The Center for Disease Control and Prevention (CDC) classified non-Hodgkin's lymphoma (NHL), Kaposi's sarcoma (KS) and cervical cancer as ADCs. The occurrence of any of these

cancers in HIV-1-infected individuals indicates the progression of HIV-1 infection to AIDS [5]. After the introduction of the ART in 1996, a dramatic improvement in immunologic function in HIV-1-infected subjects was observed as well as a rapid decline in the number of AIDS-related deaths [3].

NHL originates from malignant transformation of the precursor and mature forms of B, T and natural killer (NK) cells that mainly migrate to the lymphoid organs and the hematopoietic tissues but also to other organs [6]. There are 35 types of NHL, which can be differentiated based on histology. The CDC initially classified four of these as ADCs, which include diffuse large B cell lymphoma (DLBCL) with centroblastic characteristics, DLBCL with immunoblastic features, primary nervous system lymphoma (PNSL) and Burkitt's lymphoma [1]. In the setting of HIV-1 infection, EBV has been linked to the etiology of NHL [7]. Even though the number of cases of NHL associated with HIV-1 infection initially declined following the introduction of ART, the incidence of NHL in the HIV-1-infected population remains elevated and is 4–23 times higher than uninfected individuals [8]. A study conducted by Achenbach et al. demonstrated that the incidence of NHL remains high even in HIV-1-infected patients on ART. For instance, the incidence of NHL in HIV-1-infected individuals with HIV-1 viral loads of 51–500 RNA copies/ml and those individuals with CD4⁺ T-cell counts >200 cells/ μ l remains elevated. By the year 2000, NHL accounted for 11% of deaths among HIV-1-infected individuals and that number had only decreased by 1% five years later [8].

A study conducted by Gopal et al. established the mortality and predictive indicators of death in a cohort of 23,050 HIV-1-infected patients from 1996 to 2010. Of the total patients enrolled in this study, 476 patients developed lymphoma, of which 79 patients were diagnosed with Hodgkin's lymphoma (HL), 201 patients with DLBCL, 54 patients with PNSL and the remaining 86 patients were diagnosed with other types of NHL. Furthermore, in 223 patients, lymphoma appeared despite ART. The 5-year survival rate was 50% for patients with BL, 44.1% for those with DLBCL, 22.8% for those with primary brain lymphoma and 43.3% of patients with other types of NHL. The overall identification of risk factors for mortality included increased age, lymphoma diagnosis while on ART, a low CD4⁺ T-cell count and high viral load [4].

Another study in which results from a number of AIDS registries was linked to several cancer registries demonstrated that there were differences in the clinical presentation of NHL pre- and post-ART. In the pre-ART era (1983–1995), 33% and 38% of patients were presented with intermediate- and high-grade systemic NHL, respectively. Following the introduction of ART, the percentage of patients with intermediate-grade NHL increased to 49%, whereas the percentage of patients with high-grade NHL decreased to 19% [9]. Additionally, the survival rate of patients with systemic NHL increased significantly in the post-ART era relative to the pre-ART era, with a rise from 4 months as seen pre-ART to 9 months post-ART. There was also a change in the proportion of patients who had NHL of CNS origin, with a decrease from 28% pre-ART to 17% post-ART. However, this decrease in incidence did not correlate with an increase in survival rate [9].

2.1.2. Kaposi's sarcoma (KS)

KS is a neoplasm that arises from mesenchymal cells at multiple foci and involves the recruitment of inflammatory cells, malignant transformation of endothelial cells and neoangiogenesis

[10]. In the context of HIV-1 infection, KS development is linked to co-infection with human herpes virus 8 (HHV-8). The formation of KS lesions is associated with immunosuppression, reactivation of a latent HHV-8 infection and activation of the immune response [11]. Before the onset of the AIDS pandemic, KS was a very rare cancer. In the United States, the incidence of KS between 1973 and 1978 within the white male population was 0.3 per 100,000 person-years. This trend dramatically increased with the onset of the AIDS epidemic, peaking by 1985–1986. It has been estimated that by 1989–1991, the occurrence of KS was 8.9 per 100,000 person-years [1]. Between 1990 and 1995, KS was the most prevalent AIDS-defining cancer in the United States. During this time, HIV-1-infected individuals were at a 53,000 fold-increased risk of developing KS compared to the general population [1]. Following the introduction of ART, however, the incidence of KS decreased considerably due to three factors: (i) decreased HIV-1 replication; (ii) improvement in the HHV-8-specific immune response; and (iii) the angiogenesis inhibitory effects associated with protease inhibitors used to treat HIV-1 infection [12]. Accordingly, the immune status of patients plays a large role in the development of KS. In fact, patients who developed KS while on ART began with low CD4 counts and usually developed KS within 6 months of beginning therapy [13]. Other studies have also shown that while ART did decrease the risk of KS, those who proceeded to develop KS while on ART exhibited evidence of virologic failure [14]. These collective observations underscore the important link between decreased immune function due to HIV-1 infection and the development of KS.

2.1.3. Cervical cancer

Cervical cancer is a neoplastic condition that originates in the cervix. In 1993, invasive cervical cancer began to be included as an AIDS-defining diagnosis. Epidemiological evidence suggests that the precursor lesions, cervical intraepithelial neoplasia, or squamous intraepithelial lesion occur more frequently in women with HIV-1 [15]. In HIV-1-infected females, co-infection with the HPV is associated with invasive cervical cancer. Notably, it is estimated that HPV accounts for 70% of all cervical cancer cases [16]. However, not all women living with HPV infection develop cervical cancer. Factors that may influence the development of cervical cancer include a high level of HPV DNA, sustained HPV infection and infection with certain “high-risk” subtypes of HPV, including HPV 16 and 18. In the context of co-infection with HIV-1, a reduced CD4⁺ T-cell count is associated with an elevated risk of developing cervical cancer [17]. Furthermore, cervical cancer presents in a more aggressive form with a lower survival time in HIV-1-infected women compared to women who are not infected with HIV-1. Even though ART leads to partial restoration of immune function in HIV-1-infected patients, it remains uncertain whether the incidence of cervical cancer among HIV-1-infected women has been affected by ART.

Studies of patient cohorts in which individual subject data concerning ART use were examined have generated conflicting results, with reduced risk attributed to this therapy reported in some but not in all cases [18]. In contrast, other groups have documented an increased risk for developing invasive cervical cancer following the introduction of ART (e.g., relative risk: 1.46 with a 95% confidence interval of 1.09–1.94) [19, 20]. These discordant results could have several explanations including the increased life expectancy of HIV-1-infected female patients and/or inadequate screening programs for these women [21]. Nevertheless, it is

evident that ART may not prevent the appearance of invasive cervical cancer as it was previously thought. A more recent study which focused on assessing prevalence and identifying associated risk factors for developing precancerous cervical lesions among HIV-1-infected women in Kenya demonstrated that subjects who were not treated with ART were 2.21 times more likely to present with precancerous lesions than ART patients [22]. Although the mechanisms underlying how ART-mediated immune reconstitution affects HPV-induced lesions are unclear, the regular screening of HIV-1-infected women remains critically important. In this regard, the initiation of ART could act as leverage for cancer screening in resource-limited settings [22].

2.2. Non-AIDS-defining cancers: Virus related (EBV, HPV, HBV, HCV, and HTLV-1)

With the improvement in morbidity, mortality and life expectancy linked to the introduction of ART, the incidence of ADCs has declined, whereas the incidence of NADCs has paradoxically increased. Examples of NADCs include lung cancer, hepatocellular carcinoma (HCC), colorectal cancer, anal cancer and Hodgkin's lymphoma (HL) among others [3]. While ADCs have been demonstrated to potentially be associated with viral co-infection (i.e., KS linked to infection with HHV-8), NADCs can also be further categorized as either virus or nonvirus related. Unfortunately, HIV-1-infected patients have an increased risk of exposure and subsequent infection with oncogenic viruses, including hepatitis B and C virus (HBV and HCV), human papillomavirus (HPV), Epstein-Barr virus (EBV) and human T-cell leukemia virus type 1 (HTLV-1). This elevated risk of exposure lies on a continuum with the development of cancer as a direct result of infections with these tumorigenic viruses, even in the post-ART era [23].

2.2.1. Epstein-Barr virus (EBV): Hodgkin's lymphoma (HL)

In individuals not infected with HIV-1, between 20% and 50% of HL cases have been attributed to EBV infection; however, 75–100% of the HL cases observed in HIV-1-infected patients have been etiologically attributed to EBV infection. It has been postulated that aberrant CD4⁺ T-cell responses specific to EBV in HIV-1-infected patients are risk factors for developing HL [24]. After the introduction of ART, lymphoma became the major cause of cancer-related death in the HIV-1-infected patient population. It was reported in a study of 23,050 HIV-1-infected patients enrolled between 1996 and 2010 that 476 (2.1%) individuals were diagnosed with lymphoma, of which 79 patients (16.6%) developed HL. At the time of diagnosis, the mean age was 42.1 years with a mortality rate for HL reported at 7.9% and a 5-year survival of 61.6% [4].

The incidence of HL may be increasing since the advent of ART [25–32], which is likely due to the improvement in the level of immune function [33]. However, the increased relative risk of HL is lower than that observed for aggressive B-cell lymphoma [33]. Prior to the advent of ART, the prognosis of HIV-1-associated HL was poor, with very few individuals cured of their disease [34]. In accordance with these observations, the importance of ART has been demonstrated in the context of improving responses to chemotherapy and prolonging overall survival [35, 36]. Furthermore, HIV-1-infected patients with HL who do not respond to ART have poor outcomes resembling those of the pre-ART era [36]. Additional retrospective and

prospective clinical results strongly imply that HIV-1-infected patients with HL who are treated with full-dose chemotherapy and concurrent cART have a significantly improved and comparable prognosis as the uninfected population [37, 38]; gradual recovery of immune function occurs over the course of 6–9 months from the completion of treatment [37, 39].

2.2.2. Chronic viral hepatitis (HBV and HCV): Hepatocellular carcinoma (HCC)

It is estimated that 480–540 million people worldwide are currently affected by chronic viral hepatitis. Of these individuals, 350–370 million are infected with HBV and 130–170 million with HCV [40]. In the United States, approximately 25% and 10% of HIV-1-infected persons are co-infected with HCV and HBV, respectively. HCC, a malignancy that arises from hepatocytes, is the fifth leading cause of cancer-related deaths worldwide. An excess of alcohol consumption and viral hepatitis caused by infection with HBV or HCV are the main etiological factors of HCC [41]. In chronic HIV-1 infection, the development of HCC is mainly associated with co-infection with HBV and HCV [42]. Furthermore, liver diseases account for 50% of the mortality in the HIV-1-infected patient population, representing one of the three major causes of non-AIDS-associated deaths [41, 43], with HCC remaining the second leading cause of death in these people [42].

HIV-1 infection increases the risk of developing HCC by seven fold [44]. Indeed, HIV-1 co-infection with HBV or HCV accelerates the progression of either of these infections to liver cirrhosis and ultimately the induction of HCC [42]. In addition to other complications stemming from co-infection, ART has been linked to hepatotoxicity, the effects of which are exacerbated in patients chronically co-infected with HBV or HCV [42]. Additionally, a recent study demonstrated significant differences in the course of HCC progression between HIV-1-infected individuals co-infected with HBV and/or HCV compared to non-HIV-1 co-infected subjects. For instance, HIV-1-infected individuals were diagnosed with HCC at a younger age relative to HIV-1 seronegative subjects (48.03 ± 7.4 versus 67.54 ± 9.6). Even though the rate of HCC reappearance following treatment was similar in both groups, HIV-1-infected patients were re-treated more times and had shorter overall survival rates than in the absence of HIV-1 infection [45].

2.2.3. Human papilloma virus (HPV): anal cancer

Anal cancer rarely occurs in the general population. In contrast, the incidence of anal cancer has been increasing since the introduction of ART in HIV-1-infected patients [3]. The risk of developing anal cancer among HIV-1-infected people is 33- to 222-fold higher compared to their uninfected counterparts [46]. Anal cancer particularly affects men who have sex with men between the ages 45–50 [3]. In addition, there have been reports of HIV-1-infected women with abnormal anal cytology, accompanied by the presence of high-risk HPV types [47, 48]. Squamous cell carcinoma (SCC), which originates from the anal canal, is the most prevalent type of anal cancer and its incidence has increased 96% in men and 39% in women over recent decades [3, 46].

Although not all anal cancers are associated with HPV infection, co-infection with HPV 16 is linked to the pathogenesis of SCC. The prevalence of anal HPV 16 co-infection is three to

fivefold higher in HIV-1-infected individuals compared to individuals without HIV-1 infection. Low levels of CD4⁺ T cells correlate with the persistence of HPV infection and predispose individuals to the formation of premalignant anal lesions. Notably, HIV-1-infected females with a history of cervical disease are at an increased risk for developing high-grade anal intraepithelial neoplasia [48–50]. Progression of these lesions into invasive anal cancer occurs as the life span of HIV-1-infected patient populations has been extended due to ART [3]. Screening and treatment protocols are not yet well established for these types of malignancies, which underscore the need for research on anal HPV-associated disease, particularly in the setting of HIV-1 infection.

2.2.4. Human T-cell leukemia virus (HTLV-1): adult T-cell leukemia/lymphoma (ATL and ATLL)

Leukemia is a hematologic cancer characterized by the expansion of immature or abnormal leukocytes [51]. HTLV-1 infects CD4⁺ T cells, which leads to a malignancy that affects 20 million people worldwide. In less than 5% of the infected patients, HTLV-1 infection can cause adult T-cell leukemia (ATL) or adult T-cell leukemia/lymphoma (ALL) [52]. In the context of HIV-1 infection, co-infection with HTLV-1 is linked to the etiology of leukemia and lymphoma [51]. HIV-1/HTLV-1 co-infection is frequently encountered in areas where HTLV-1 infection is more prevalent, particularly among high risk groups such as intravenous drug users. In areas where HIV-1 infection is high, 10% of HIV-1-infected patients are also co-infected with HTLV-1 [52]. The worldwide incidence of leukemia/lymphoma in individuals co-infected with HIV-1 and HTLV-1 is currently unclear [52]. In a cohort of 21,000 patients residing in the United States, Poiesz et al. studied the prevalence of HTLV-1-induced T-cell lymphoma and found eight patients with lymphoma who tested positive for HTLV-1. One of these patients was also co-infected with HIV-1, presenting with a stage IV lymphoma [53]. In a case study of a 43-year-old African American male with ATL and HIV-1/HTLV-1 co-infection, it was reported that a period of remission after treatment with chemotherapeutic agents and zidovudine was achieved demonstrating, at least in this patient, that co-infection with HIV-1 may not prevent effective cancer treatment [52].

2.3. Non-AIDS-defining cancers: Nonvirus related (lung cancer, colorectal cancer, and prostate cancer)

2.3.1. Lung cancer

Malignant transformation of lung cells results in the development of lung cancer. Lung cancer is responsible for the majority of cancer-related deaths in men and women in the United States. In 2013, approximately 156,176 people in the United States died from lung cancer [54]. Cigarette smoking or the use of other tobacco products is the main cause of lung cancer development in the general population and also in HIV-1-infected patients. Other risk factors for lung cancer among HIV-1-infected patients include immunosuppression, intravenous drug use, the presence of opportunistic lung infections and aging [2]. HIV-1-infected patients exhibit a twofold increased risk of developing lung cancer relative to the general population [3]. Importantly, it has been reported that HIV-1 infection increases the risk of lung cancer development, even in the absence of smoking [55, 56]. The non-small cell

lung cancer types account for 80% of the cases of lung cancer in HIV-1-infected patients. In the United States, squamous cell carcinoma, adenocarcinoma and small cell carcinoma collectively account for the most frequent NADC among HIV-1-infected people, preferentially affecting males over females [3].

The clinical presentations of lung cancer in HIV-1-infected patients pre- and post-ART appear to be the same. Lung cancer appears at a younger age (38–49 years) in HIV-1-infected patients as compared to uninfected individuals (68 years) [57, 58]. There are conflicting reports, however, regarding the clinical outcomes of lung cancer in HIV-1-infected versus uninfected subjects. Some studies have shown that the cancer presents more aggressively, with more severe clinical disease course and a shorter overall survival rate in HIV-1-infected patients relative to uninfected individuals [2].

2.3.2. Colorectal cancer

Colorectal cancer is the third most frequently occurring cancer among men and women and the second leading cause of cancer-associated deaths in the United States [59]. The incidence of colorectal cancer among HIV-1-infected patients has been increasing since the introduction of ART [60]. A study conducted by Patel et al. demonstrated that the incidence rate of colorectal cancer among HIV-1-infected individuals from 1992 to 1995 and from 1996 to 1999 was 39.9 and 39.7 per 100,000 person years, respectively. However, this number increased to 66.2 per 100,000 person years from 2000 to 2003. In contrast, the incidence rate of colorectal cancer among the general population was 20.4, 20.5 and 21.2 per 100,000 person years for the same three time frames [60].

A case controlled study of HIV-1-infected patients with colorectal cancer diagnosed from 1994 to 2003 revealed that this malignancy occurred at a younger age in the HIV-1-infected group compared to the general population in the absence of HIV-1 infection [61]. Furthermore, at the time of diagnosis, 90% of the HIV-1-infected patients presented with advanced stage cancer (stage III/IV) compared to 57% in the uninfected group [61]. These observations were confirmed by Berretta et al. who reported differences in the clinical outcome between 27 HIV-1-infected patients and 54 patients with colorectal cancer in the absence of HIV-1 infection studied from 1985 to 2003. This malignancy presented more aggressively in the HIV-1-infected group, as indicated by more advanced disease staging at the time of diagnosis and a shorter survival time as compared to the uninfected patient cohort [44].

The highest incidence of colorectal cancer in the United States is found in African Americans. Even though African Americans represent only 12% of the total population in the United States, these individuals comprise 50% of HIV-1-infected people in this country. Colorectal cancer develops in HIV-1-infected African American at an earlier age compared to the general population. Kumar et al. studied the clinical presentations of colorectal cancer in a retrospective study of 17 HIV-1-infected African Americans and 42 uninfected matched controls. The mean age of colorectal cancer diagnosis in the HIV-1-infected population was 50.70 versus 59.42 years in the control group [62]. Furthermore, 29.4% of the HIV-1-infected patients in this study were diagnosed with colorectal cancer at a younger age (<45 years) versus 6.35% for the control group. At the time of diagnosis, 52.94% of the HIV-1-infected patients and 43.84% of

the uninfected controls had already presented with advanced stage colorectal cancer. Interestingly, the survival time was similar for both groups in this study [62].

2.3.3. Prostate cancer

Prostate cancer is the second most frequently occurring cancer in men in the United States [63] and will likely affect 6% of these individuals at an age of 60 within the next decade [64]. There are conflicting data, however, regarding the incidence of prostate cancer in the HIV-1-infected patient population. In a retrospective, multi-institutional study of HIV-1-infected patients conducted in the United States from 1996 to 2006, Pantanowitz et al. showed that the mean age for prostate cancer diagnosis in their cohort was 59 years. Additionally, more than half of the patients already presented stage II–IV prostate cancer, with a mean of CD4⁺ T-cell count of 336 cells/μl and HIV-1 viral load of 17,319 copies/ml. The majority of these patients became long-term survivors after hormonal treatment, radiation and/or prostatectomy [65]. In terms of risk groups, African American men are particularly susceptible to developing prostate cancer. Furthermore, in the setting of HIV-1 infection, it has been reported that prostate cancer might present more aggressive in African American men [66, 67]. A retrospective study of 54 HIV-1-infected males and 1496 uninfected patients with prostate cancer from 2000 to 2011 was conducted to study the clinical presentation and outcome of the cancer between the two groups. In this study, 92% of the HIV-1-infected patients were African American. At the time of cancer diagnosis, 82% of the HIV-1-infected patients were taking ART and the remaining 14% initiated ART after cancer diagnosis. The median age was 60.7 years for the HIV-1-infected patients and 64 years for the general population. In the HIV-1-infected group, the median CD4⁺ T-cell levels were 391 cells/μl and the viral titers in 76% of these patients were ≤400 copies/ml. At the time of cancer diagnosis, 73 and 14% of the uninfected group presented with cancer stage I/II and stage III/IV, respectively, whereas 63 and 36% of the HIV-1-infected patient group were categorized as stage I/II and III/IV, respectively. Furthermore, HIV-1 infection was associated with a greater likelihood of presenting with advanced stage cancer at the time of diagnosis as well as greater mortality overall [68].

3. Trends in HIV-1-associated cancers

3.1. Incidence and epidemiology

Prior to the advent of ART, KS and NHL accounted for 99% of all ACDs [69]. Following the introduction of this therapy, however, there was an 84 and 54% decrease in the number of KS and NHL cases, respectively. During this same time period, a 70% reduction in the incidence of all ADCs was observed [25, 69]. Despite this dramatic decline, from 1991–1995 to 2001–2005 when ART was introduced, ADCs continue to be a major problem. For example, more than 2000 cases of ADCs were diagnosed annually in the United States between 2001 and 2005, these cancers were more recently attributed to 15–19% of all deaths in HIV/AIDS patients [70, 71]. As previously stated, one of the most important risk factors for KS and NHL is suppression of the immune system as determined by CD4⁺ T-cell decline [72–74]. A low CD4⁺ T-cell count (<50 cells/μl) remains a risk for developing KS, even for HIV-1-infected patients who

receive ART [75]. Additional risk factors include advanced age and immune reconstitution inflammatory syndrome resulting from restored immunity to specific infectious or noninfectious antigens following the initiation of ART [76].

In contrast, the frequency of NADCs such as melanoma, HL, anal, prostate and colorectal cancers has been steadily increasing over the past two decades [60]. The overall risk for all NDACs in HIV-1-infected persons is approximately twofold higher than in the general population of the same sex and age [77]. It is estimated that NADCs are currently responsible for 28% of deaths in the HIV-1-infected patient population [12]. Indeed, the frequency of NADCs now exceeds the number of AIDS-defining cancers [78]. Using regression analysis, Coghill et al. established an association between HIV-1 infection and cancer-related mortality of cases reported in six states in the United States from 1996 to 2010. This study included 1,816,461 patients with cancer of whom 6459 were infected with HIV-1 and demonstrated an increased incidence and specific mortality particularly for colorectal, lung and other NDACs [64]. Co-infections with oncogenic viruses account for the largest number of NDACs in HIV-1-infected individuals, but NDACs with a nonviral etiology (e.g., lung cancer) also play an important role. The growing proportion of aged HIV-1-infected individuals, co-infections, immune deficits not controlled by ART and/or risky lifestyle factors place HIV-1-infected subjects at higher risk for developing NDACs compared to the general population [23, 79, 80].

3.2. Risk factors (examples include age, chronic inflammation, immunosuppression, smoking, alcohol use, long-term ART)

HIV-1-infected individuals are exposed to a number of cancer risk factors, including smoking, older age, immunosuppression, viremia and long-term ART (**Figure 1**). It is estimated that in the United States, 50% of HIV-1-infected individuals smoke cigarettes, a 2.5-fold higher prevalence than in the general population [81]. A study conducted by Krishnan et al. identified the risk factors for developing NADCs in a cohort of 3158 treatment-naïve HIV-1-infected individuals in the United States who started ART at the initiation of the study. The results indicated that smoking and CD4⁺ T-cell counts (<350 cells/μl) at study entry were associated with increased risk of developing a NADCs. Anal cancer, basal cell carcinoma, HL and lung cancer were the most common cancers reported in this study [78]. The influence of smoking on cancer development among HIV-1-infected individuals was studied in a Danish cohort of 3503 HIV-1-infected patients and 19,979 matched control subjects. The majority of HIV-1-infected patients (77%) had been on ART for a median of 3.3 years at study entry and their median baseline CD4⁺ T-cell counts were 450 cells/μl. In the HIV-1-infected group, 67% and 76% of patients reported never or actively smoking, respectively, compared to 53% and 39% in the uninfected group. Smoking and virus-associated cancers were most prevalent among HIV-1-infected patients. Indeed, there was a higher risk of developing these types of cancers in the HIV-1-infected group compared to the control population [82]. Furthermore, a recent study showed that HIV-1-infected homosexual male smokers were at higher risk of developing HPV-related anal cancer compared to the nonsmoker control group. Smoking was also associated with higher HPV DNA levels, the development of high-grade anal intraepithelial lesions and anal dysplasia [83].

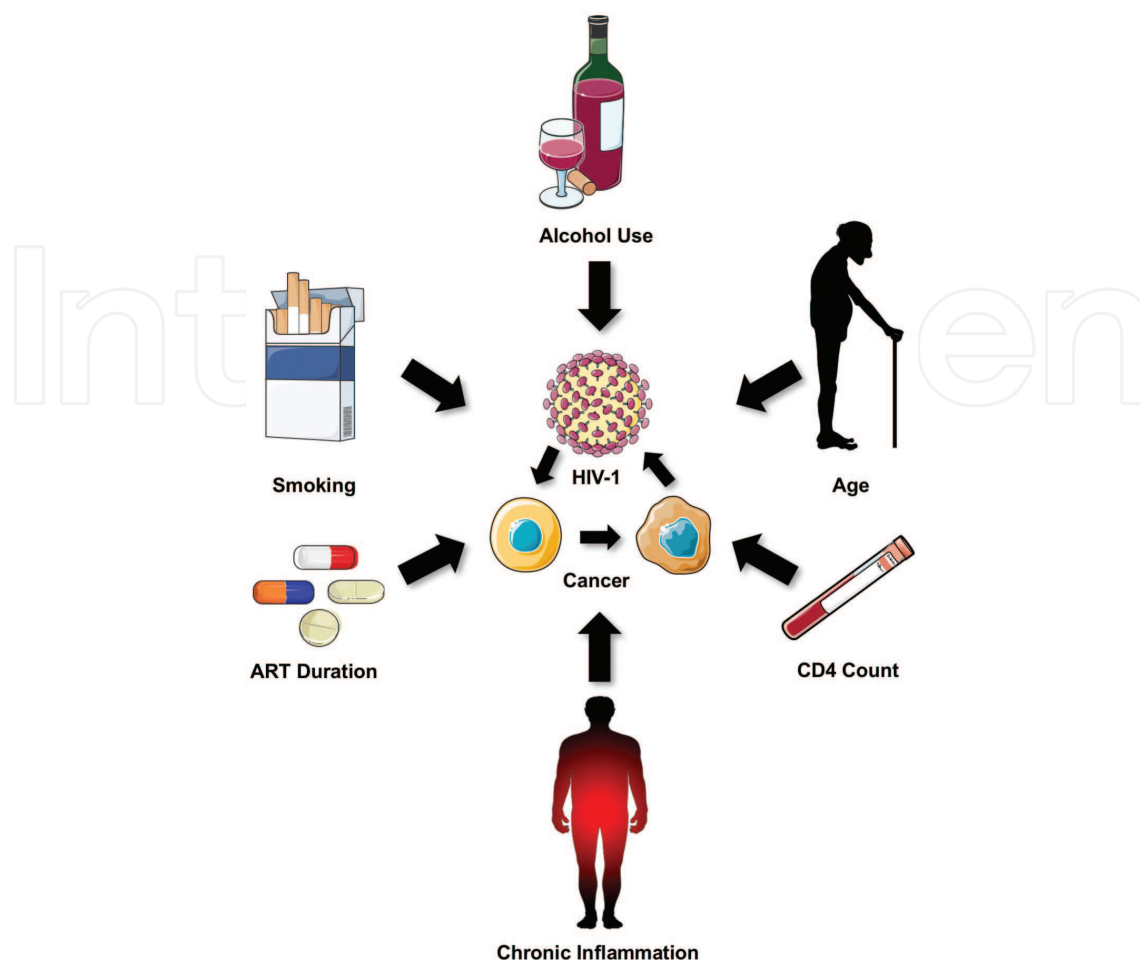


Figure 1. Risk factors for developing cancer in the setting of HIV-1 infection. Factors that may increase the likelihood of developing cancer in HIV-1-infected individuals include alcohol consumption, smoking, the duration of ART, a chronic immunoinflammatory state, CD4 count and/or advanced age. The complex interactions between ART use, HIV-1 replication, aging and other risk factors that are dynamic over time may influence tumor biology in patients with HIV-1 infection.

It has been suggested that the increased number of NADCs in the ART era is due in part to the increased life expectancy following the introduction of this therapy to the HIV-1-infected patient population [12]. A systematic review conducted by Oliveira et al. evaluated the role of ART on the frequency of NADCs among people living with HIV-1. In this study, 21 reports were reviewed, analyzing a total of 2 million person-years and 10,891 new cases of NADCs. The results show that after the introduction of ART, the rate of KS and NHL decreased, whereas the rate of cervical cancer increased. The risk of developing NADCs increased, particularly anal, colorectal, HL, liver, lung and prostate cancers [12].

The role of immunosuppression and viremia in the development of NADCs was evaluated in a cohort of 11,459 HIV-1-infected patients on ART in the Netherlands. Of the total number of patients, 236 patients were diagnosed with NADCs, 102 were infection-related and 134 were not associated with infection. The most common cancer in the infection-related group was anal cancer (37 patients), followed by laryngeal cancer (21) and HCC (16). At the time of cancer

diagnosis, the median CD4⁺ T-cell count was 340 cells/ μ l (range: 210–540 cells/ μ l). Furthermore, the longer that a patient spent with a low CD4⁺ T-cell count (<200 cells/ μ l), their likelihood of developing an NADC, particularly with infectious etiology increased. Additional risk factors for the development of NADCs in this patient cohort included longevity and developing AIDS before the initiation of ART [84].

A study conducted in Portugal with HIV-1-infected patients showed that the most prevalent NADCs in this group were skin and lung cancers and HCC. KS (32%), NHL (16%) and cervical cancer (4%) accounted for the cases involving ADCs. Importantly, factors such as a longer interval of HIV-1 infection and ART, as well as high CD4⁺ T-cell counts and HIV type 2 (HIV-2) infection were linked to developing NADCs, whereas impaired immunity, HBV co-infection, cigarette smoking and alcohol consumption were associated with the emergence of ADCs [85].

In a randomized clinical trial of 5472 HIV-1-infected patients, Silverberg et al. studied the effects of discontinuing ART on cancer development. There were two groups of patients studied based on treatment status as continuous ART and discontinuous ART. In the discontinuous ART arm, the treatment was interrupted when the CD4⁺ T-cell counts were >350 cells/ μ l and resumed when the counts were <250 cells/ μ l. Of the total number of patients, 70 developed cancer. There was an increased rate of KS and NHL in the discontinuous ART group, with low CD4⁺ T-cell counts and the detection of HIV-1 RNA defined as risk factors. According to these variables, the risk of developing NADCs was similar in both groups [86].

The effects of long-term use of ART on cancer development were evaluated in a cohort of 12,872 HIV-1-infected patients who were followed from 1996 to 2008. The incidence of ADC, particularly KS and NHL, decreased as the time on ART increased. This trend was partially attributed to the effects of ART in decreasing HIV-1 RNA levels and restoring CD4⁺ T cell counts. Interestingly, there was no association between the use of ART and the risk of developing NADCs. However, there was a lower incidence of noninfectious-related NADCs as the ART intervals were increased over time, particularly in the case of prostate cancer [87].

Increased plasma levels of interleukin (IL)-6 and C-reactive protein (CRP), two markers of inflammation, are closely associated with cancer induction. In a prospective study of a cohort of 5023 HIV-1-infected patients, Borges et al. examined the link between the presence of inflammatory factors (IL-6 and CRP) and coagulation markers (e.g., D-dimer) and cancer risk. After a follow up of 24,000 person-years, 172 patients were diagnosed with cancer. The most frequent infection-related malignancies were NHL, HL and anal cancer; the malignancies most often encountered and unrelated to infection were lung, prostate and colorectal cancer. Importantly, there was a significant association between elevated serum levels of IL-6, CR and D-dimer and the risk of cancer development, with high levels of IL-6 exhibiting the strongest correlation [88].

4. Mechanisms of HIV-1-associated cancer

Although an unequivocal link exists between HIV-1 infection and the development of certain cancers, it remains unclear whether HIV-1 acts directly as an oncogenic agent. In the context of

HIV-1 infection, viral-induced tumorigenesis appears to rely on multiple factors, which typically involve cooperation between co-infecting viruses as well as aberrations in immune and nonimmune microenvironments. In this regard, we will describe the mechanisms underlying HIV-1-associated oncogenesis with a focus on both the direct tumor-promoting capacities of viral products on cells and indirect causes of the cooperative induction of cancer that are instead related to the ability of HIV-1 disease to cause profound immune dysregulation. Notably, the importance of viral co-factor cooperation in malignant transformation is underscored in HIV-1-infected individuals due to a high degree of immunodeficiency and/or the chronic immune activation/inflammatory state that increases susceptibility to infection and numerous replicative and oncogenic pathways with multiple tumor viruses [89].

The increased incidence of aggressive B-cell lymphomas in HIV-1-infected subjects compared to individuals with other forms of immune suppression has been documented [90, 91], but remains poorly understood. While this phenomenon may be attributed to the failure of immune surveillance due to direct and bystander T-cell depletion and/or microenvironment changes that define pathogenic HIV-1 infections, it stands to reason that HIV-1 replication products may also contribute to oncogenesis. In further support of this idea, it has been shown that HPV-induced cervical dysplasia and cancer are frequent complications of HIV-1 infection [92–94], with no clear association between occurrence and the degree of host immune suppression [93, 95]. Thus, while this malignancy has been shown to be aggressive, less responsive to treatment and often recurrent in HIV-1-infected women, there appears to be no difference in the severity of neoplasia in asymptomatic patients with HIV-1 infection compared to those who have progressed to AIDS [95]. These collective clinical observations indicate that immunodeficiency may not be the sole mediator of cancer development during the course of HIV-1 disease and implicate a more direct role for HIV-1 with respect to potentiating neoplasia.

The contributions of HIV-1-induced molecular alterations in inducing neoplastic transformation independently of immune system perturbation have been demonstrated, primarily through the use of *in vitro* cell line models. In the context of KS, a direct cooperative role of HIV-1 in mediating tumorigenesis has been observed. In a cell line model derived from a primary effusion lymphoma (PEL), HIV-1 infection triggers reactivation of Kaposi's sarcoma herpesvirus (KSHV) or HHV-8 and this effect was the direct action of the HIV-1 transactivator protein Tat [96]. Tat has been shown to be released from HIV-1-infected cells and may bind to and enter uninfected cells, including endothelial cells through its protein transduction domain [97–99]. Tat-mediated signaling has been shown to promote endothelial cell migration and matrix invasion *in vitro* as well as angiogenesis *in vivo* [100–103]. In addition, human KS cells grow more aggressively in HIV-1 Tat transgenic CD4⁺ T-cell depleted mice compared to nontransgenic control animals [104], although the direct role of Tat in KS development remains controversial [105]. Furthermore, when HIV-1 and KSHV genomes are present in the same cellular environment, bilateral positive transcription of genes from both viruses has been observed. Notably, HIV-1 Tat and Vpr independently activate KSHV transcription, whereas the KSHV KIE2 protein induces activation of HIV-1 LTR-driven transcription [106]. Finally, it has been suggested that by regulating a number of cellular targets, HIV-1 Tat may be involved in altering DNA repair in host cells, potentially leading to genomic instability which may give rise to mutations and contribute to oncogenesis [107]. In particular, Tat induces expression of

the DNA polymerase beta gene, which codes for a central mediator in the DNA base-excision repair pathway [108]; HIV-1 Tat has also been implicated in playing a direct role in double-strand break DNA repair, as cellular extracts containing Tat possess a reduced capacity to rejoin linearized DNA [109]. These observations may explain at least in part why HIV-1 and KSHV co-infected individuals possess a higher risk for developing KS.

As mentioned earlier in this review, similar to KS, NHL in AIDS patients is associated with another co-infecting virus, in this case, EBV. While current evidence suggests that the chronic immunoinflammatory state associated with HIV-1 disease contributes to B cell activation and ultimately to lymphomagenesis, HIV-1 replication products may also directly contribute to lymphoma induction. HIV-1 envelope protein gp120 has the ability to directly activate B cells through its interaction with DC-SIGN, leading to immunoglobulin gene class-switch recombination, interleukin secretion and activation-induced cytidine deaminase (AID) expression [110]. Because the HIV-1 envelope interfaces with a number of cellular proteins with diverse functions including adhesion molecules, major histocompatibility complex (MHC) components as well as macrophage, B- and T-cell surface proteins, it would be interesting to determine which of these constituents contribute(s) to B-cell activation and consequential lymphomagenesis [111]. It has also been demonstrated that Tat alters the proliferative capacity and apoptosis sensitivity of EBV-immortalized cell lines, suggesting that cells expressing Tat may have a selective growth advantage, thereby potentially giving rise to clones with enhanced oncogenicity [112]. An interaction between HIV-1 Tat and the pRb2/p130 oncosuppressor protein has also been observed, but the effects of Tat on the cell cycle are conflicting, which may be attributed to its dose- as well as cell type-dependent activities [113–115].

Viral cooperativity in the potentiation of cancer induction may involve more than two agents. In fact, one of the most relevant examples of this type of viral cooperation exists between HIV-1, EBV and KSHV in promoting the development of PEL, a prototypic lymphoma that arises in EBV and KSHV co-infected tumor cells in HIV-1-infected patients [116]. Reciprocal molecular interactions between EBV and KSHV promote each other latency in PEL cells, which may contribute to the establishment and maintenance of tumors [117]. Because HIV-1 can induce KSHV transcription (i.e., through Tat and Vpu) and EBV as well as KSHV replication products (EBNA-2 [118] and ORF45 [119], respectively) activate the HIV-1 LTR, viral cooperation appears to be a potential mechanism underlying lymphomagenesis in this setting.

As previously indicated, the occurrence of HPV-induced cervical cancer is independent of immune suppression, unlike a number of other AIDS-associated neoplasms. However, the molecular underpinnings of a more aggressive malignancy in HIV-1-infected women with cervical cancer are poorly understood. In this regard, HIV-1 Tat has been shown to increase the expression of HPV E6 and E7 oncoproteins [120, 121]; the E6-p53 interaction and E7-Rb complex formation result in functional inactivation and aberrant cell cycle control, which is a critical regulator of HPV-induced cervical carcinogenesis [122]. Rb and its family members such as pRb2/p130 may be affected by HIV-1 expression; HIV-1 Tat may block pRb2/p130 mRNA expression, but it is unclear whether or not Tat changes the architecture of the pRb2/p130-E7 interaction [123]. Furthermore, HIV-1 Tat expression has been shown to decrease the

mRNA levels of cyclin-dependent kinase inhibitors p21 and p17 [123] that have been implicated in the control of the G₀/G₁ transition and are inactivated by the HPV E7 protein [124, 125]. However, the end result in cervical carcinogenesis and disease progression of these Tat-induced oncogene and tumor suppressor changes remains unclear.

The tumor microenvironment includes a number of immune cellular components, including activated T cells, B cells and macrophages. Over the past several years, the importance of HIV-1 interactions within the microenvironment has gained increasing recognition. HIV-1 disease results in a profound perturbation of cytokine/chemokine levels, which facilitates the development of antiviral immunity as previously reviewed [126]. However, these mediators can also have a detrimental effect on the host by limiting the development of potent immune responses elicited against infection [127] and directly or indirectly affecting cancer development. In fact, studies of cytokines in HIV-1-infected patients were among the earliest reports of aberrant cytokine levels being associated with lymphoma risk [128, 129]. Elevated levels of IL-6, IL-10, CXCL13 and TNF α are associated with increased risk for the development of NHL in HIV-1-infected individuals [128–131]. The induction of pro-inflammatory mediators by HIV-1 infection likely alters the elaboration of other immunomodulatory factors, thus influencing cellular proliferation, apoptosis sensitivity and other physiologic functions associated with the microenvironment [89].

HIV-1-dependent skewing from T helper (h)1 to Th2 CD4⁺ T-cell subpopulations has been considered an important step in immune dysregulation as previously reviewed [132]. Increased Th2 differentiation likely precedes the development of AIDS-related NHL and may also play a role in Th17 upregulation [111]. Th17 cells are present in the microenvironment of a number of different murine and human tumors [133]. Furthermore, in the context of AIDS-NHL pathogenesis, Th2 or Th17 cytokines are known to drive AID expression [134].

The dysregulation of cytokine/chemokine pathways in the HIV-1-infected patient may also promote neoangiogenesis. In addition to the aforementioned role of Tat in stimulating capillary formation [135], the HIV-1 matrix protein, p17, has been shown to promote angiogenesis through a different mechanism involving the ligation of chemokine receptors [136]. More specifically, the release of p17 from HIV-1-infected cells binds to CXCR1, which subsequently drives human monocytes into the microenvironment in an IL-8 chemokine-like manner resulting in sustained inflammation [137]. Increased levels of IL-6 and TNF α in the plasma of HIV-1-infected patients can induce COX-2 and PGE₂ synthesis, which have been linked to the development of AIDS-related cervical cancer [138], an effect that could be related to the promotion of angiogenesis [139, 140]. The precise role of HIV-1-driven angiogenic mechanisms in the development and progression of cancer has not been elucidated and warrants further investigation.

Finally, the nonimmune microenvironment may drive the development and/or progression of AIDS-related cancers and this may also involve mechanisms of viral cooperation [89]. In lymphomas, the nonimmune microenvironment is largely composed of endothelia, stromal cells and fibroblasts that contribute to tumorigenicity. In AIDS-associated NHLs, studies on nonimmune microenvironmental components have focused on neoangiogenesis, although it is

presently debated whether HIV-1 may influence this process through productive infection of endothelial cells [89]. Interestingly, Liapis et al. recently demonstrated that the amount of neovasculature was consistently increased in AIDS-NHL compared to sporadic NHLs. In these patients, AIDS-NHL microvessel density in virus-infected tissue was directly correlated with EBV expression [135]. While neovascular abnormality may be considered a common process observed in a number of viral diseases, the identification of biomarkers in nonimmune microenvironments and the precise mechanisms of viral oncogenesis in these settings may prove to be important in the diagnosis and management of HIV-1–associated lymphomas.

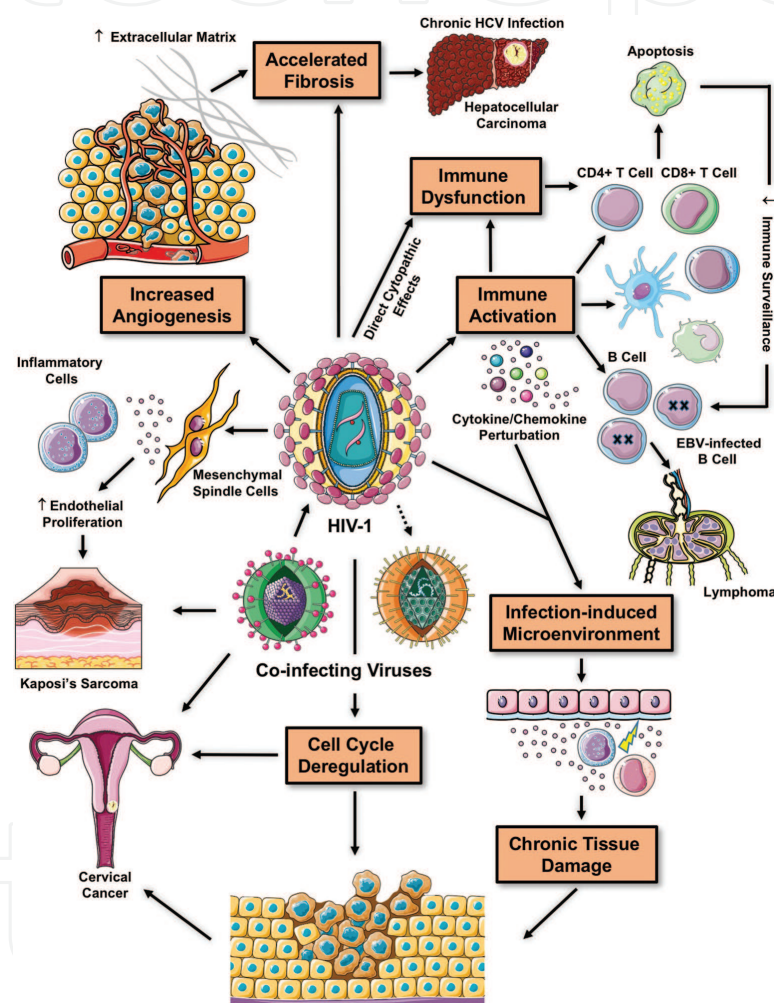


Figure 2. Mechanisms of HIV-1-associated cancer. Increased oncogenesis in the setting of HIV-1 disease usually involves co-infection with other viruses and immune dysfunction, accompanied by decreased immune surveillance. Persistent immune activation as a consequence of HIV-1 infection may lead to chronic tissue damage and the formation of infection-induced microenvironments that potentiate cancer induction. HIV-1 and its products may also influence oncogenesis (usually in the context of viral cooperativity) independently of immune suppression through cell cycle deregulation and/or influencing the nonimmune microenvironment (e.g., increased extracellular matrix, pro-fibrogenic factors and blood vessel formation).

The mechanistic underpinnings of HIV-1 co-infection in accelerating the progression of HCC by HCV may be related to direct effects of HIV-1 on activated hepatic stellate cells (HSCs), the

primary fibrogenic cell type in the liver. HSCs are permissive for HIV-1 infection, support viral gene expression and are capable of transmitting infectious virus [141]. Other than induction of pro-inflammatory cytokines, productive infection of HSCs promotes fibrogenic collagen I expression [141]. Similarly, exposing hepatocytes to HIV-1 results in increased production of reactive oxygen species (ROS), collagen and tissue inhibitor of metalloproteinase 1 (TIMP1), an effect that is amplified by concurrent HCV exposure [142]. Another proposed way by which HIV-1 promotes fibrosis is through induction of apoptosis in response to envelope proteins [143, 144] and/or expression of tumor necrosis factor-related apoptosis-inducing ligand (TRAIL) and its cognate death receptors DR4 and DR5 [145, 146]. Taken together, an increase in fibrous tissue with the concomitant destruction of liver cells provides the “soil” for development of cancerous nodules following long periods of chronic liver diseases [147–149]. In addition to highly profibrotic proteins and extracellular matrix constituents, characterization of other nonimmune microenvironment components in the context of HIV-1 infection as well as co-infection conditions is required for the elucidation of well-defined pathophysiological pathways to inform mechanism-based approaches directed against HIV/AIDS-related tumors.

Mechanisms of HIV-1-associated oncogenesis and cancer progression are summarized in **Figure 2**.

5. Management of cancer in HIV-1-infected patients

HIV-1-infected individuals with cancer have lower rates of survival relative to individuals not infected with HIV-1 [150]. While this may be attributed to the aggressive nature of malignancies in the setting of HIV-1-driven immune dysfunction, alternative explanations include the decreased efficacy or increased toxicity of cancer therapy [150–152]. In addition, the disparity between HIV-1-infected and uninfected patients following cancer diagnosis could potentially be a consequence of inadequate cancer treatment due to a survival decrement [153]. Indeed, many HIV-1-infected patients are excluded from clinical trials of cancer therapies and this may contribute to the lack of evidence-based strategies for the management of these patients, especially if treatments are perceived to have diminished effectiveness and/or enhanced toxicity in the background of HIV-1 infection [154].

The absence of cancer treatment for HIV-1-infected participants in a recent study with colon cancer, DLBCL and non-small-cell lung cancer further underscores treatment disparities and raises concern, particularly considering the curative potential of therapy for early-stage cancer [154]. Reduced treatment rates of cancer in the HIV-1-infected population may also be attributed to the limited experience of healthcare providers in managing these cases. Ideal cancer therapy regimens for individuals on ART remain unknown due to a lack of published data to guide clinical decision-making. Furthermore, treatment can be challenging because of drug interactions between antineoplastic agents and antiretrovirals as well as increased immunosuppression from chemotherapy and/or radiation [155, 156]. Notably, some chemotherapeutic agents and ART drugs are metabolized by a similar cytochrome p450 enzyme pathway, which could influence the clearance of these agents and affect toxicity as well as efficacy [157]. Thus, when the concurrent use of ART and radio/chemotherapy is anticipated,

overlap in toxicity and drug-drug interactions may influence the optimal choice of cancer treatments [158].

In some cancers, such as DLBCL and anal cancer, results are available to inform the treatment of HIV-1-infected patients [159–163]. Prior to the introduction of ART, low-dose and risk-adapted intensive chemotherapeutic regimens as well as infusional chemotherapy were evaluated for HIV-1-associated NHLs [164, 165]. Outcomes were poor regardless of the type of therapy used and were accompanied by substantial toxicity and the occurrence of opportunistic infections [166–172]. However, since the introduction of ART, a paradigm shift has taken place in the treatment of HIV-1-infected lymphoma patients with survival approaching that of HIV-1-negative subjects [116, 165, 172, 173]. Immunotherapy with anti-CD20 monoclonal antibody (rituximab) and/or standard full-dose chemotherapy can now be safely administered to HIV-1-infected patients in the presence of ART with supportive care including hematopoietic growth factors and prophylaxis for opportunistic infections [173–177]. High-dose chemotherapy and peripheral autologous stem-cell transplantation (ASCT) can be used as salvage therapy in patients with HIV-1 who present with relapsed and refractory lymphoma, including HL [178–183].

Some lymphomas in the setting of HIV-1 infection require special considerations when selecting the most appropriate cancer treatment plan. For example, HIV-1-associated Burkitt lymphoma remains controversial, with the CHOP (cyclophosphamide, doxorubicin, vincristine and prednisone) regimen not currently recommended [175, 184, 185]. The results of small retrospective and phase II clinical trials suggest that intensive chemotherapy for ART-treated Burkitt lymphoma patients with HIV-1 may be acceptable [184, 186, 187].

For other cancers, HIV-1-infected individuals have been largely excluded from clinical trials because they are considered to be vulnerable patients and, therefore, randomized data related to treatment outcomes are unavailable [188]. Nevertheless, case reports and retrospective studies conducted after the introduction of ART have suggested similar treatment toxicity with standard therapy [38, 57, 154, 189–193]. For example, cervical cancer is very common in HIV-1-infected women with an aggressive course and poor treatment outcome [194, 195]. Treatment options for cervical cancer include surgery, radiotherapy and chemotherapy either alone or in combination. In regions with a high prevalence of cervical cancer, the majority of patients receive chemoradiotherapy, which can impair immunity [196]. A number of different therapeutic modalities and modifications have been used to improve outcome of treatment in HIV-1-infected patients with cervical cancer. However, there are no standard guidelines for the management of HIV-1-infected patients diagnosed with cervical cancer and the outcome of standard therapy remains poor. A recent systematic review of cervical cancer management in HIV-1-infected individuals along with their treatment outcomes [197] revealed that patients who started ART early exhibited higher rates of completion of their cancer treatment protocol, suggesting that ART should be commenced early after cervical cancer diagnosis to ensure less toxicity and better compliance with therapy [198–201]. Thus, as it currently stands, HIV-1-infected cervical cancer patients should be managed like their uninfected counterparts [197].

Similarly, recommended treatment options for prostate cancer in HIV-1-infected men are the same as those individuals without HIV-1 infection [191]. Some patients may choose to defer therapy for an extended period of monitoring known as active surveillance. In the ART era,

prostate-specific antigen (PSA) kinetics and prostate cancer behavior do not seem to differ between HIV-1-infected and uninfected subjects [191, 202]. Thus, although long-term treatment outcomes in HIV-1-infected patients remain uncertain, these individuals should be offered all screening and treatment options as men in the general population [202].

ART is a main component of treatment for all patients with KS and is an effective anti-KS therapy for approximately 60–70% of patients with limited cutaneous lesions [203–205]. In cases of advanced stage visceral KS or aggressive disease, systemic chemotherapy should be combined with ART. First-line chemotherapy includes combination regimens or pegylated liposomal (L) doxorubicin, which has been shown to be better tolerated [205–207] (with an objective response rate of 59–82%). Second-line chemotherapy consists of low-dose paclitaxel for patients who are resistant to anthracyclines (with an objective response rate of 60–70%) [208]. The emergence of immune reconstitution inflammatory syndrome in ART-treated HIV-1-infected patients, which may lead to the development of KS or accelerate its progression, undoubtedly poses a major challenge to current disease management options [209, 210].

In the era of ART, HIV-1-infected patients with cancer can be treated with more aggressive regimens, including intensive chemotherapy with concomitant stem cell transplants in the case of hematologic malignancies and/or combined chemotherapeutic protocols [116]. Due to the potential risk of adverse drug-drug interactions, the simultaneous use of antineoplastic drugs with antiretroviral agents has been debated [53, 156, 211]. However, contemporary guidelines support the use of ART during chemotherapy [173, 212]. With regard to the management of most HIV-1-associated cancers, treatments that achieve the highest rates of progression-free survival in uninfected individuals are becoming increasingly applicable to HIV-1-infected patients [116]. Nevertheless, additional prospective studies are urgently required to define toxicities associated with the concurrent use of ART and chemotherapy. Such reports should be instrumental in developing evidence-based treatment criteria for these patients [158]. Until this is achieved, healthcare providers should individualize cancer treatment plans (e.g., chemotherapy, surgery, radiation therapy) for HIV-1-infected patients based on laboratory results, the presence of renal or liver dysfunction and the risk of potential drug-related toxicities.

6. Conclusions

Although the management of HIV-1 infection has improved considerably in the last few decades, HIV-1-infected patients are still at high risk compared to the general population, with respect to the development of a spectrum of life-threatening malignancies. There are a number of cancers that present in HIV-1-infected patients at a younger age, more aggressively and with a shorter survival time than a comparable uninfected population. This implies that despite the partial restoration of the immune system in HIV-1-infected patients due to efficacious ART protocols, HIV-1 infection has been identified as a risk factor for the development of cancer, particularly NADCs. Indeed, the oncogenic potential of Tat and gp120 has been examined in various cell lines as well as the cooperation between these proteins with co-infecting viruses to enhance cell transformation. A better understanding of the interactions between HIV-1 and a number of oncogenic viruses in conjunction with immune and nonimmune cells

may lead to the development of better therapeutic approaches for the management of cancer in HIV-1-infected patients. Furthermore, there are few randomized studies that have addressed the management of cancer in HIV-1-infected patients. Some of the challenges in the treatment of cancer in HIV-1 infection include increased immunosuppression induced by chemotherapy and/or radiation, as well as the potential for synergistic toxicity caused by antiretrovirals and antioncogenic treatments. Thus, it is imperative that HIV-1-infected patients are included in studies to determine the proper therapeutic approaches that these patients need when diagnosed with cancer.

Author details

Lorena Loarca^{1,†}, Joseph A. Fraietta^{2,3,†}, Vanessa Pirrone^{4,5,6}, Zsafia Szep^{5,7} and Brian Wigdahl^{4,5,6*}

*Address all correspondence to: bwigdahl@drexelmed.edu

1 Division of Gastroenterology and Hepatology, Mayo Clinic Center for Signaling in Gastroenterology, Mayo Clinic, Rochester, MN, USA

2 Center for Cellular Immunotherapies, University of Pennsylvania, Philadelphia, PA, USA

3 Department of Pathology and Laboratory Medicine, University of Pennsylvania, Philadelphia, PA, USA

4 Department of Microbiology and Immunology, Drexel University College of Medicine, Philadelphia, PA, USA

5 Center for Clinical and Translational Medicine, Institute for Molecular Medicine and Infectious Disease, Drexel University College of Medicine, Philadelphia, PA, USA

6 Sidney Kimmel Cancer Center, Thomas Jefferson University, Philadelphia, PA, USA

7 Division of Infectious Diseases and HIV Medicine, Department of Medicine, Drexel University College of Medicine, Philadelphia, PA, USA

† These authors contributed equally.

References

- [1] Blattner WA, Nowak RG. Cancers in People with HIV and AIDS. In: Yarchoan R, editor. *Epidemiology of AIDS-Defining Malignancies*: Springer: New York; 2014. p. 17–30.

- [2] Chiao EY. Epidemiology and Clinical Characteristics of Non-AIDS-Defining Malignancies. In: Dittmer DP, Krown SE, editors. *Molecular Basis for Therapy of AIDS-Defining Cancers*. Springer: New York; 2010. p. 17–40.
- [3] Brugnaro P, Morelli E, Cattelan F, Petrucci A, Panese S, Esemé F, Cavinato F, Barelli A, Raise E. Non-AIDS defining malignancies among human immunodeficiency virus-positive subjects: Epidemiology and outcome after two decades of HAART era. *The World Journal of Virology* 2015 4:209–218.
- [4] Gopal S, Patel MR, Yanik EL, Cole SR, Achenbach CJ, Napravnik S, Burkholder GA, Reid EG, Rodriguez B, Deeks SG, Mayer KH, Moore RD, Kitahata MM, Eron JJ, Richards KL. Temporal trends in presentation and survival for HIV-associated lymphoma in the antiretroviral therapy era. *Journal of the National Cancer Institute* 2013;105:1221–1229.
- [5] Castro KG, Ward JW, Slutsker SL, Buehler JW, Jaffe HW, Berkelman RL. 1993 revised classification system for HIV infection and expanded surveillance case definition for AIDS among adolescents and adults. *MMWR Recommendations and Reports* 1992;41:1–19.
- [6] Krol AD, le Cessie S, Snijder S, Kluin-Nelemans JC, Kluin PM, Noordijk EM. Primary extranodal non-Hodgkin's lymphoma (NHL): the impact of alternative definitions tested in the Comprehensive Cancer Centre West population-based NHL registry. *Annals of Oncology*. 2003;14(1):131–139.
- [7] Ansell SM. Non-Hodgkin lymphoma: Diagnosis and treatment. *Mayo Clinic Proceedings* 2015;90:1152–1163.
- [8] Achenbach CJ, Buchanan AL, Cole SR, Hou L, Mugavero MJ, Crane HM, Moore RD, Haubrich RH, Gopal S, Eron JJ, Hunt PW, Rodriguez B, Mayer K, Saag MS, Kitahata MM; for the Centers for AIDS Research (CFAR) Network of, (CNICS) ICS. HIV viremia and incidence of non-Hodgkin lymphoma in patients successfully treated with antiretroviral therapy. *Clinical Infectious Diseases*. 2014;58:1599–1606.
- [9] Diamond C, Taylor TH, Aboumrad T, Anton-Culver H. Changes in acquired immunodeficiency syndrome-related non-Hodgkin lymphoma in the era of highly active antiretroviral therapy: incidence, presentation, treatment and survival. *Cancer*. 2006;106(1):128–135. DOI: 10.1002/cncr.21562
- [10] Ganem D. KSHV and the pathogenesis of Kaposi sarcoma: listening to human biology and medicine. *The Journal of Clinical Investigation*. 2010;120(4):939–949. DOI: 10.1172/JCI40567
- [11] Robey RC, Bower M. Facing up to the ongoing challenge of Kaposi's sarcoma. *Current Opinion in Infectious Diseases* 2015;28:31–40.
- [12] Cobucci RN, Lima PH, de Souza PC, Costa VV, Cornetta Mda C, Fernandes JV, Goncalves AK. Assessing the impact of HAART on the incidence of defining and non-defining AIDS cancers among patients with HIV/AIDS: A systematic review. *Journal of Infection and Public Health*. 2015;8:1–10.

- [13] Mocroft A, Kirk O, Clumeck N, Gargalianos-Kakolyris P, Trocha H, Chentsova N, Antunes F, Stellbrink HJ, Phillips AN, Lundgren JD. The changing pattern of Kaposi sarcoma in patients with HIV, 1994–2003: the EuroSIDA Study. *Cancer*. 2004;100(12):2644–2654. DOI: 10.1002/cncr.20309
- [14] Portsmouth S, Stebbing J, Gill J, Mandalia S, Bower M, Nelson M, Gazzard B. A comparison of regimens based on non-nucleoside reverse transcriptase inhibitors or protease inhibitors in preventing Kaposi's sarcoma. *AIDS*. 2003;17(11):F17-F22. DOI: 10.1097/01.aids.0000076309.76477.f1
- [15] Ellerbrock TV, Chiasson MA, Bush TJ, Sun XW, Sawo D, Brudney K, Wright TC, Jr. Incidence of cervical squamous intraepithelial lesions in HIV-infected women. *JAMA*. 2000;283(8):1031–1037.
- [16] Frazier EL, Sutton MY, Tie Y, McNaghten AD, Blair JM, Skarbinski J. Screening for Cervical Cancer and Sexually Transmitted Diseases Among HIV-Infected Women. *Journal of Women's Health*. 2016;25:124–132.
- [17] Williamson AL. The interaction between human immunodeficiency virus and human papillomaviruses in heterosexuals in Africa. *Journal of Clinical Medicine* 2015;4:579–592.
- [18] Grulich AE. Cancer: the effects of HIV and antiretroviral therapy and implications for early antiretroviral therapy initiation. *Curr Opinion in HIV and AIDS*. 2009;4(3):183–187. DOI: 10.1097/COH.0b013e328329c5b2
- [19] Gingues S, Gill MJ. The impact of highly active antiretroviral therapy on the incidence and outcomes of AIDS-defining cancers in Southern Alberta. *HIV Medication*. 2006;7(6):369–377. DOI: 10.1111/j.1468-1293.2006.00395.x
- [20] Cobucci RN, Lima PH, de Souza PC, Costa VV, Cornetta Mda C, Fernandes JV, Goncalves AK. Assessing the impact of HAART on the incidence of defining and non-defining AIDS cancers among patients with HIV/AIDS: a systematic review. *Journal of Infection and Public Health*. 2015;8(1):1–10. DOI: 10.1016/j.jiph.2014.08.003
- [21] Dorrucchi M, Suligoi B, Serraino D, Tirelli U, Rezza G. Incidence of invasive cervical cancer in a cohort of HIV-seropositive women before and after the introduction of highly active antiretroviral therapy. *Journal of Acquired Immune Deficiency Syndromes*. 2001;26(4):377–380.
- [22] Memiah P, Mbuthia W, Kiiru G, Agbor S, Odhiambo F, Ojoo S, Biadgilign S. Prevalence and risk factors associated with precancerous cervical cancer lesions among HIV-infected women in resource-limited settings. *AIDS Research and Treatment* 2012;2012:953743. DOI: 10.1155/2012/953743
- [23] Deeken JF, Tjen ALA, Rudek MA, Okuliar C, Young M, Little RF, Dezube BJ. The rising challenge of non-AIDS-defining cancers in HIV-infected patients. *Clinical Infectious Diseases*. 2012;55(9):1228–1235. DOI: 10.1093/cid/cis613
- [24] Deeken JF, Tjen-A-Looi A, Rudek MA, Okuliar C, Young M, Little RF, Dezube BJ. The rising challenge of non-AIDS-defining cancers in HIV-infected patients. *Clinical Infectious Diseases* 2012;55:1228–1235.

- [25] Shiels MS, Pfeiffer RM, Gail MH, Hall HI, Li J, Chaturvedi AK, Bhatia K, Uldrick TS, Yarchoan R, Goedert JJ, Engels EA. Cancer burden in the HIV-infected population in the United States. *The Journal of the National Cancer Institute*. 2011;103(9):753–762. DOI: 10.1093/jnci/djr076
- [26] Powles T, Robinson D, Stebbing J, Shamash J, Nelson M, Gazzard B, Mandelia S, Moller H, Bower M. Highly active antiretroviral therapy and the incidence of non-AIDS-defining cancers in people with HIV infection. *Journal of Clinical Oncology*. 2009;27(6):884–890. DOI: 10.1200/JCO.2008.19.6626
- [27] Bedimo RJ, McGinnis KA, Dunlap M, Rodriguez-Barradas MC, Justice AC. Incidence of non-AIDS-defining malignancies in HIV-infected versus noninfected patients in the HAART era: impact of immunosuppression. *Journal of Acquired Immune Deficiency Syndromes*. 2009;52(2):203–208. DOI: 10.1097/QAI.0b013e3181b033ab
- [28] Marin B, Thiebaut R, Bucher HC, Rondeau V, Costagliola D, Dorrucchi M, Hamouda O, Prins M, Walker S, Porter K, Sabin C, Chene G. Non-AIDS-defining deaths and immunodeficiency in the era of combination antiretroviral therapy. *AIDS*. 2009;23(13):1743–1753. DOI: 10.1097/QAD.0b013e32832e9b78
- [29] Franceschi S, Lise M, Clifford GM, Rickenbach M, Levi F, Maspoli M, Bouchardy C, Dehler S, Jundt G, Ess S, Bordoni A, Konzelmann I, Frick H, Dal Maso L, Elzi L, Furrer H, Calmy A, Cavassini M, Ledergerber B, Keiser O. Changing patterns of cancer incidence in the early- and late-HAART periods: the Swiss HIV Cohort Study. *British Journal of Cancer*. 2010;103(3):416–422. DOI: 10.1038/sj.bjc.6605756
- [30] Simard EP, Pfeiffer RM, Engels EA. Spectrum of cancer risk late after AIDS onset in the United States. *Archives of Internal Medicine*. 2010;170(15):1337–1345. DOI: 10.1001/archinternmed.2010.253
- [31] Hessol NA, Katz MH, Liu JY, Buchbinder SP, Rubino CJ, Holmberg SD. Increased incidence of Hodgkin disease in homosexual men with HIV infection. *Annals of Internal Medicine*. 1992;117(4):309–311.
- [32] Serraino D, Carbone A, Franceschi S, Tirelli U. Increased frequency of lymphocyte depletion and mixed cellularity subtypes of Hodgkin's disease in HIV-infected patients. Italian Cooperative Group on AIDS and Tumours. *European Journal of Cancer*. 1993;29A(14):1948–1950.
- [33] Kaplan LD. Management of HIV-associated Hodgkin lymphoma: how far we have come. *Journal of Clinical Oncology*. 2012;30(33):4056–4058. DOI: 10.1200/JCO.2012.44.8373
- [34] Jacobson CA, Abramson JS. HIV-associated Hodgkin's lymphoma: Prognosis and therapy in the era of cART. *Advances in Hematology* 2012;2012:507257. DOI: 10.1155/2012/507257
- [35] Gerard L, Galicier L, Boulanger E, Quint L, Lebrette MG, Mortier E, Meignin V, Oksenhendler E. Improved survival in HIV-related Hodgkin's lymphoma since the introduction of highly active antiretroviral therapy. *AIDS*. 2003;17(1):81–87. DOI: 10.1097/01.aids.0000042593.93174.23

- [36] Hoffmann C, Chow KU, Wolf E, Faetkenheuer G, Stellbrink HJ, van Lunzen J, Jaeger H, Stoehr A, Plettenberg A, Wasmuth JC, Rockstroh J, Mosthaf F, Horst HA, Brodt HR. Strong impact of highly active antiretroviral therapy on survival in patients with human immunodeficiency virus-associated Hodgkin's disease. *British Journal of Haematology*. 2004;125(4):455–462. DOI: 10.1111/j.1365-2141.2004.04934.x
- [37] Hentrich M, Berger M, Wyen C, Siehl J, Rockstroh JK, Muller M, Faetkenheuer G, Seidel E, Nickelsen M, Wolf T, Rieke A, Schurmann D, Schmidmaier R, Planker M, Alt J, Mosthaf F, Engert A, Arasteh K, Hoffmann C. Stage-adapted treatment of HIV-associated Hodgkin lymphoma: results of a prospective multicenter study. *Journal of Clinical Oncology*. 2012;30(33):4117–4123. DOI: 10.1200/JCO.2012.41.8137
- [38] Montoto S, Shaw K, Okosun J, Gandhi S, Fields P, Wilson A, Shanyinde M, Cwynarski K, Marcus R, de Vos J, Young AM, Tenant-Flowers M, Orkin C, Johnson M, Chilton D, Gribben JG, Bower M. HIV status does not influence outcome in patients with classical Hodgkin lymphoma treated with chemotherapy using doxorubicin, bleomycin, vinblastine and dacarbazine in the highly active antiretroviral therapy era. *Journal of Clinical Oncology*. 2012;30(33):4111–4116. DOI: 10.1200/JCO.2011.41.4193
- [39] Bower M, Stebbing J, Tuthill M, Campbell V, Krell J, Holmes P, Ozzard A, Nelson M, Gazzard B, Powles T. Immunologic recovery in survivors following chemotherapy for AIDS-related non-Hodgkin lymphoma. *Blood*. 2008;111(8):3986–3990. DOI: 10.1182/blood-2007-10-115659
- [40] Koh HK. Viral Hepatitis: The Secret Epidemic: <http://www.hhs.gov/asl/testify/2010/06/t20100617b.html>; 2010.
- [41] Di Benedetto F, Tarantino G, Ercolani G, Baccarani U, Montalti R, De Ruvo N, Berretta M, Adani GL, Zanella M, Tavio M, Cautero N, Tirelli U, Pinna AD, Gerunda GE, Guaraldi G. Multicenter italian experience in liver transplantation for hepatocellular carcinoma in HIV-infected patients. *Oncologist*. 2013;18:592–599.
- [42] Nunnari G, Berretta M, Pinzone MR, Di Rosa M, Berretta S, Cunsolo G, Malaguarnera M, Cosentino S, De Paoli P, Schnell JM, Cacopardo B. Hepatocellular carcinoma in HIV positive patients. *European Review for Medical and Pharmacological Sciences* 2012;16:1257–1270.
- [43] Mallet V, Vallet-Pichard A, Pol S. The impact of human immunodeficiency virus on viral hepatitis. *Liver Int*. 2011;31:135–139.
- [44] Berretta M, Cappellani A, Di Benedetto F, Lleshi A, Talamini R, Canzonieri V, Zanet E, Bearz A, Nasti G, Lacchin T, Berretta S, Fisichella R, Balestreri L, Torresin A, Izzi I, Ortolani P, Tirelli U. Clinical presentation and outcome of colorectal cancer in HIV-positive patients: a clinical case-control study. *Onkologie*. 2009;32:319–324.
- [45] Berretta M, Garlassi E, Cacopardo B, Cappellani A, Guaraldi G, Cocchi S, De Paoli P, Lleshi A, Izzi I, Torresin A, Di Gangi P, Pietrangelo A, Ferrari M, Bearz A, Berretta S,

Nasti G, Di Benedetto F, Balestreri L, Tirelli U, Ventura P. Hepatocellular carcinoma in HIV-infected patients: check early, treat hard. *Oncologist*. 2011;16:1258–1269.

- [46] Chiao EY, Giordano TP, Richardson P, El-Serag HB. Human immunodeficiency virus–associated squamous cell cancer of the anus: Epidemiology and outcomes in the highly active antiretroviral therapy era. *Journal of Clinical Oncology*. 2008;26:474–479.
- [47] Cambou MC, Luz PM, Lake JE, Levi JE, Coutinho JR, de Andrade A, Heinke T, Derrico M, Veloso VG, Friedman RK, Grinsztejn B. Anal human papillomavirus (HPV) prevalences and factors associated with abnormal anal cytology in HIV-infected women in an urban cohort from Rio de Janeiro, Brazil. *AIDS Patient Care STDS*. 2015;29(1):4–12. DOI: 10.1089/apc.2014.0166
- [48] Heard I, Etienney I, Potard V, Poizot-Martin I, Moore C, Lesage AC, Ressiot E, Crenn-Hebert C, Flejou JF, Cubie H, Costagliola D, Darragh TM. High prevalence of anal human papillomavirus-associated cancer precursors in a contemporary cohort of asymptomatic HIV-infected women. *Clinical Infectious Diseases*. 2015;60(10):1559–1568. DOI: 10.1093/cid/civ049
- [49] Ravenda PS, Magni E, Botteri E, Manzotti M, Barberis M, Vacirca D, Trovato CM, Dell'Acqua V, Leonardi MC, Sideri M, Fazio N, Zampino MG. Prognostic value of human papillomavirus in anal squamous cell carcinoma. *Cancer Chemother Pharmacol*. 2014;74(5):1033–1038. DOI: 10.1007/s00280-014-2582-x
- [50] Williamson AL. The interaction between human immunodeficiency virus and human papillomaviruses in heterosexuals in Africa. *Journal of Clinical Medicine*. 2015;4(4):579–582.
- [51] Whitman AG, Bryan BA, Dyson OF, Patel DK, Ramasamy D, Anantharaman S, Reber AJ, Akula SM. AIDS related viruses, their association with leukemia and Raf signaling. *Current HIV Research* 2005;3:319–327.
- [52] Loarca, L., Sullivan, N., Pirrone, V., and B. Wigdahl. “Leukemia and retroviral disease” in *Leukemia – Various Types*.” (eds), InTech Open, Rijeka, Croatia, 2015. ISBN 978-953-51-4319-2.
- [53] Poiesz BJ, Papsidero LD, Ehrlich G, Sherman M, Dube S, Poiesz M, Dillon K, Ruscetti FW, Slamon D, Fang C, Williams A, Duggan D, Glaser J, Gottlieb A, Goldberg J, Ratner L, Phillips P, Han T, Friedman-Kien A, Siegal F, Rai K, Sawitsky A, Sheremata LW, Dosik H, Cunningham C, Montagna R. Prevalence of HTLV-I-associated T-cell lymphoma. *American Journal of Hematology* 2001;66:32–38.
- [54] Group USCSW. United States Cancer Statistics: 1999–2013 Incidence and Mortality Web-based Report. Department of Health and Human Services, Centers for Disease Control and Prevention and National Cancer Institute: Atlanta, USA. 2016.
- [55] Engels EA, Brock MV, Chen J, Hooker CM, Gillison M, Moore RD. Elevated incidence of lung cancer among HIV-infected individuals. *Journal of Clinical Oncology*. 2006;24:1383–1388.
- [56] Patel P, Tong T, et al., editors. Incidence of non-AIDS-defining malignancies in the HIV outpatient study (HOPS). 11th Conference on Retroviruses and Opportunistic Infections.

Proceedings of the 11th Conference on Retroviruses and Opportunistic Infections, San Francisco, CA; 2004.

- [57] Tirelli U, Spina M, Sandri S, Serraino D, Gobitti C, Fasan M, Sinicco A, Garavelli P, Ridolfo AL, Vaccher E. Lung carcinoma in 36 patients with human immunodeficiency virus infection. The Italian Cooperative Group on AIDS and Tumors. *Cancer*. 2000;88(3):563–569.
- [58] Ricaurte JC, Hoerman MF, Nord JA, Tietjen PA. Lung cancer in HIV-infected patients: a one-year experience. *International Journal of STD & AIDS*. 2001;12(2):100–102.
- [59] Division of Cancer Prevention and Control, Centers for Disease Control and Prevention (June 2016). Retrieved from: <https://www.cdc.gov/cancer/colorectal/statistics/>
- [60] Patel P, Hanson DL, Sullivan PS, Novak RM, Moorman AC, Tong TC, Holmberg SD, Brooks JT. Incidence of types of cancer among HIV-infected persons compared with the general population in the United States, 1992–2003. *Annals of Internal Medicine* 2008;148:728–736.
- [61] Wasserberg N, Nunoo-Mensah JW, Gonzalez-Ruiz C, Beart RWJ, Kaiser AM. Colorectal cancer in HIV-infected patients: a case control study. *International Journal of Colorectal Disease* 2007;22:1217–1221.
- [62] Kumar A, Shah N, Modi Y, Shaaban HS, DePasquale J, DeBari VA, Yerrabothala S, Maroules M, Guron GK. Characteristics of colorectal cancer in the human immunodeficiency virus-infected African American population. *Medical Oncology* 2012;29:1773–1779.
- [63] Prostate Cancer Statistics: <http://www.cdc.gov/cancer/prostate/statistics/index.htm>; 2015.
- [64] Coghill AE, Shiels MS, Suneja G, Engels EA. Elevated cancer-specific mortality among HIV-infected patients in the United States. *Journal of Clinical Oncology*. 2015;33:2376–2383.
- [65] Pantanowitz L, Bohac G, Cooley TP, Aboulafia D, Dezube BJ. Human immunodeficiency virus-associated prostate cancer: clinicopathological findings and outcome in a multi-institutional study. *BJU International* 2008;101:1519–1523.
- [66] Jones J. African-Americans and prostate cancer: why the discrepancies? *The Journal of the National Cancer Institute*. 2001;93(5):342–344.
- [67] Hoffman RM, Gilliland FD, Eley JW, Harlan LC, Stephenson RA, Stanford JL, Albertson PC, Hamilton AS, Hunt WC, Potosky AL. Racial and ethnic differences in advanced-stage prostate cancer: The Prostate Cancer Outcomes Study. *The Journal of the National Cancer Institute*. 2001;93(5):388–395.
- [68] Riedel DJ, Cox ER, Stafford KA, Gilliam BL. Clinical presentation and outcomes of prostate cancer in an urban cohort of predominantly African-American, HIV-infected patients. *Urology*. 2015;85:415–422.
- [69] Eltom MA, Jemal A, Mbulaiteye SM, Devesa SS, Biggar RJ. Trends in Kaposi's sarcoma and non-Hodgkin's lymphoma incidence in the United States from 1973 through 1998. *The Journal of the National Cancer Institute*. 2002;94(16):1204–1210.

- [70] Antiretroviral Therapy Cohort Collaboration. Causes of death in HIV-1-infected patients treated with antiretroviral therapy, 1996–2006: collaborative analysis of 13 HIV cohort studies. *Clin Infect Dis*. 2010;50(10):1387–1396. DOI: 10.1086/652283
- [71] Rodger AJ, Lodwick R, Schechter M, Deeks S, Amin J, Gilson R, Paredes R, Bakowska E, Engsig FN, Phillips A. Mortality in well controlled HIV in the continuous antiretroviral therapy arms of the SMART and ESPRIT trials compared with the general population. *AIDS*. 2013;27(6):973–979. DOI: 10.1097/QAD.0b013e32835cae9c
- [72] Clifford GM, Polesel J, Rickenbach M, Dal Maso L, Keiser O, Kofler A, Rapiti E, Levi F, Jundt G, Fisch T, Bordoni A, De Weck D, Franceschi S. Cancer risk in the Swiss HIV Cohort Study: Associations with immunodeficiency, smoking and highly active antiretroviral therapy. *The Journal of the National Cancer Institute*. 2005;97(6):425–432. DOI: 10.1093/jnci/dji072
- [73] International Collaboration on HIV and Cancer. Highly active antiretroviral therapy and incidence of cancer in human immunodeficiency virus-infected adults. *The Journal of the National Cancer Institute*. 2000;92(22):1823–1830.
- [74] Frisch M, Biggar RJ, Engels EA, Goedert JJ. Association of cancer with AIDS-related immunosuppression in adults. *JAMA*. 2001;285(13):1736–1745.
- [75] Franceschi S, Maso LD, Rickenbach M, Polesel J, Hirschel B, Cavassini M, Bordoni A, Elzi L, Ess S, Jundt G, Mueller N, Clifford GM. Kaposi sarcoma incidence in the Swiss HIV Cohort Study before and after highly active antiretroviral therapy. *British Journal of Cancer*. 2008;99(5):800–804. DOI: 10.1038/sj.bjc.6604520
- [76] Blattner WA, Nowak RG. Epidemiology of AIDS-Defining Malignancies. In: Yarchoan R, editor. *Cancers in People with HIV and AIDS: Progress and Challenges*. Springer Science +Business Media, New York 2014. p. 17–30.
- [77] Vaccher E, Serraino D, Carbone A, De Paoli P. The evolving scenario of non-AIDS-defining cancers: challenges and opportunities of care. *Oncologist*. 2014;19(8):860–867. DOI: 10.1634/theoncologist.2014–0024
- [78] Krishnan S, Schouten JT, Jacobson DL, Benson CA, Collier AC, Koletar SL, Santana J, Sattler FR, Mitsuyasu R. Incidence of non-AIDS-defining cancer in antiretroviral treatment-naïve subjects after antiretroviral treatment initiation: An ACTG Longitudinal Linked Randomized Trials Analysis. *Oncology*. 2011;80:42–49.
- [79] Engels EA. Non-AIDS-defining malignancies in HIV-infected persons: etiologic puzzles, epidemiologic perils, prevention opportunities. *AIDS*. 2009;23(8):875–885. DOI: 10.1097/QAD.0b013e328329216a
- [80] Silverberg MJ, Chao C, Leyden WA, Xu L, Tang B, Horberg MA, Klein D, Quesenberry CP, Jr., Towner WJ, Abrams DI. HIV infection and the risk of cancers with and without a known infectious cause. *AIDS*. 2009;23(17):2337–2345. DOI: 10.1097/QAD.0b013e3283319184
- [81] Park LS, Hernández-Ramírez RU, Silverberg MJ, Crothers K, Dubrow R. Prevalence of non-HIV cancer risk factors in persons living with HIV/AIDS: a meta-analysis. *AIDS*. 2016;30:273–291.

- [82] Helleberg M, Gerstoft J, Afzal S, Kronborg G, Larsen CS, Pedersen C, Bojesen SE, Nodestgaard BG, Obel N. Risk of cancer among HIV-infected individuals compared to the background population: impact of smoking and HIV. *AIDS*. 2014;28:1499–1508.
- [83] Wieland U, Hellmich M, Wetendorf J, Potthoff A, Swoboda J, Fuchs W, Brockmeyer N, Pfister H, Kreuter A. Smoking and anal high-risk human papillomavirus DNA loads in HIV-positive men who have sex with men. *Indian Journal of Medical Microbiology* 2015;305:689–696.
- [84] Kesselring A, Gras L, Smit C, van Twillert G, Verbon A, de Wolf F, Reiss P, Wit F. Immunodeficiency as a risk factor for non-AIDS-defining malignancies in HIV-1-infected patients receiving combination antiretroviral therapy. *CID*. 2011;52.
- [85] Fernandes LS. Human immunodeficiency virus and cancer. A population of HIV-infected patients at Hospital de Santa Maria and predictors of cancer. *Germes*. 2012;2.
- [86] Silverberg MJ, Neuhaus J, Bower M, Gey D, Hatzakis A, Henry K, Hidalgo J, Lourtou L, Neaton JD, Tambusi G, Abrams DI. Risk of cancers during interrupted antiretroviral therapy in the SMART study. *AIDS*. 2007;21:1957–1963.
- [87] Chao C, Leyden WA, Xu L, Horberg MA, Klein D, Towner WJ, Quesenberry CP, Abrams DI, Silverberg MJ. Exposure to Antiretroviral Therapy and Risk of Cancer in HIV-infected Persons. *AIDS*. 2012;26:2223–2231.
- [88] Borges ÁH, Silverberg MJ, Wentworth D, Grulich AE, Fätkenheuer G, Mitsuyasu R, Tambussi G, Sabin CA, Neaton JD, Lundgren JD. Predicting risk of cancer during HIV infection: the role of inflammatory and coagulation biomarkers. *AIDS*. 2013;27:1433–1441.
- [89] De Paoli P, Carbone A. Microenvironmental abnormalities induced by viral cooperation: Impact on lymphomagenesis. *Seminars in Cancer Biology*. 2015;34:70–80. DOI: 10.1016/j.semcancer.2015.03.009
- [90] Gaidano G, Carbone A, Dalla-Favera R. Pathogenesis of AIDS-related lymphomas: molecular and histogenetic heterogeneity. *The American Journal of Pathology*. 1998;152(3):623–630.
- [91] Knowles DM. Immunodeficiency-associated lymphoproliferative disorders. *Modern Pathology: an official journal of the United States and Canadian Academy of Pathology, Inc.* 1999;12(2):200–217.
- [92] Sitas F, Pacella-Norman R, Carrara H, Patel M, Ruff P, Sur R, Jentsch U, Hale M, Rowji P, Saffer D, Connor M, Bull D, Newton R, Beral V. The spectrum of HIV-1 related cancers in South Africa. *International Journal of Cancer; Journal international du cancer*. 2000;88(3):489–492.
- [93] Tweddel G, Heller P, Cunnane M, Mulhaupt H, Roth K. The correlation between HIV seropositivity, cervical dysplasia and HPV subtypes 6/11, 16/18, 31/33/35. *Gynecologic Oncology*. 1994;52(2):161–164. DOI: 10.1006/gyno.1994.1024

- [94] Cappiello G, Garbuglia AR, Salvi R, Rezza G, Giuliani M, Pezzotti P, Suligoi B, Branca M, Migliore G, Formigoni Pomponi D, D'Ubaldo C, Ippolito G, Giacomini G, Benedetto A. HIV infection increases the risk of squamous intra-epithelial lesions in women with HPV infection: an analysis of HPV genotypes. DIANAIDS Collaborative Study Group. *International Journal of Cancer; Journal international du cancer*. 1997;72(6):982–986.
- [95] Maiman M, Fruchter RG, Serur E, Remy JC, Feuer G, Boyce J. Human immunodeficiency virus infection and cervical neoplasia. *Gynecologic Oncology*. 1990;38(3):377–382.
- [96] Merat R, Amara A, Lebbe C, de The H, Morel P, Saïb A. HIV-1 infection of primary effusion lymphoma cell line triggers Kaposi's sarcoma-associated herpesvirus (KSHV) reactivation. *International Journal of Cancer; Journal international du cancer*. 2002;97(6):791–795.
- [97] Ensoli B, Buonaguro L, Barillari G, Fiorelli V, Gendelman R, Morgan RA, Wingfield P, Gallo RC. Release, uptake and effects of extracellular human immunodeficiency virus type 1 Tat protein on cell growth and viral transactivation. *Journal of Virology*. 1993;67(1):277–287.
- [98] Vendeville A, Rayne F, Bonhoure A, Bettache N, Montcourrier P, Beaumelle B. HIV-1 Tat enters T cells using coated pits before translocating from acidified endosomes and eliciting biological responses. *Molecular Biology of the Cell*. 2004;15(5):2347–2360. DOI: 10.1091/mbc.E03-12-0921
- [99] Wu RF, Gu Y, Xu YC, Mitola S, Bussolino F, Terada LS. Human immunodeficiency virus type 1 Tat regulates endothelial cell actin cytoskeletal dynamics through PAK1 activation and oxidant production. *Journal of Virology*. 2004;78(2):779–789.
- [100] Albini A, Barillari G, Benelli R, Gallo RC, Ensoli B. Angiogenic properties of human immunodeficiency virus type 1 Tat protein. *Proceedings of the National Academy of Sciences of the United States of America*. 1995;92(11):4838–4842.
- [101] Albini A, Soldi R, Giunciuglio D, Giraudo E, Benelli R, Primo L, Noonan D, Salio M, Camussi G, Rockl W, Bussolino F. The angiogenesis induced by HIV-1 tat protein is mediated by the Flk-1/KDR receptor on vascular endothelial cells. *Nature Medicine*. 1996;2(12):1371–1375.
- [102] Mitola S, Soldi R, Zanon I, Barra L, Gutierrez MI, Berkhout B, Giacca M, Bussolino F. Identification of specific molecular structures of human immunodeficiency virus type 1 Tat relevant for its biological effects on vascular endothelial cells. *Journal of Virology*. 2000;74(1):344–353.
- [103] Scheidegger P, Weiglhofer W, Suarez S, Console S, Waltenberger J, Pepper MS, Jaussi R, Ballmer-Hofer K. Signalling properties of an HIV-encoded angiogenic peptide mimicking vascular endothelial growth factor activity. *The Biochemical Journal*. 2001;353(Pt 3):569–578.
- [104] Prakash O, Tang ZY, He YE, Ali MS, Coleman R, Gill J, Farr G, Samaniego F. Human Kaposi's sarcoma cell-mediated tumorigenesis in human immunodeficiency type 1 tat-expressing transgenic mice. *The Journal of the National Cancer Institute*. 2000;92(9):721–728.

- [105] Weiss R, Boshoff C. Addressing controversies over Kaposi's sarcoma. *The Journal of the National Cancer Institute*. 2000;92(9):677–679.
- [106] Huang CC, Liang YC, Hsu KS. Characterization of the mechanism underlying the reversal of long term potentiation by low frequency stimulation at hippocampal CA1 synapses. *The Journal of Biological Chemistry*. 2001;276(51):48108–48117. DOI: 10.1074/jbc.M106388200
- [107] Nunnari G, Smith JA, Daniel R. HIV-1 Tat and AIDS-associated cancer: targeting the cellular anti-cancer barrier? *Journal of Experimental & Clinical Cancer Research: CR*. 2008;27:3. DOI: 10.1186/1756-9966-27-3
- [108] Srivastava DK, Tendler CL, Milani D, English MA, Licht JD, Wilson SH. The HIV-1 transactivator protein Tat is a potent inducer of the human DNA repair enzyme beta-polymerase. *AIDS*. 2001;15(4):433–440.
- [109] Chipitsyna G, Slonina D, Siddiqui K, Peruzzi F, Skorski T, Reiss K, Sawaya BE, Khalili K, Amini S. HIV-1 Tat increases cell survival in response to cisplatin by stimulating Rad51 gene expression. *Oncogene*. 2004;23(15):2664–2671. DOI: 10.1038/sj.onc.1207417
- [110] He B, Qiao X, Klasse PJ, Chiu A, Chadburn A, Knowles DM, Moore JP, Cerutti A. HIV-1 envelope triggers polyclonal Ig class switch recombination through a CD40-independent mechanism involving BAFF and C-type lectin receptors. *Journal of Immunology*. 2006;176(7):3931–3941.
- [111] Epeldegui M, Vendrame E, Martinez-Maza O. HIV-associated immune dysfunction and viral infection: role in the pathogenesis of AIDS-related lymphoma. *Immunologic Research*. 2010;48(1–3):72–83. DOI: 10.1007/s12026-010-8168-8
- [112] Colombrino E, Rossi E, Ballon G, Terrin L, Indraccolo S, Chieco-Bianchi L, De Rossi A. Human immunodeficiency virus type 1 Tat protein modulates cell cycle and apoptosis in Epstein-Barr virus-immortalized B cells. *Experimental Cell Research*. 2004;295(2):539–548. DOI: 10.1016/j.yexcr.2004.01.018
- [113] Regulier EG, Reiss K, Khalili K, Amini S, Zagury JF, Katsikis PD, Rappaport J. T-cell and neuronal apoptosis in HIV infection: implications for therapeutic intervention. *International Reviews of Immunology*. 2004;23(1–2):25–59.
- [114] Luker GD, Leib DA. Luciferase real-time bioluminescence imaging for the study of viral pathogenesis. *Methods in Molecular Biology*. 2005;292:285–296.
- [115] Bettaccini AA, Baj A, Accolla RS, Basolo F, Toniolo AQ. Proliferative activity of extracellular HIV-1 Tat protein in human epithelial cells: expression profile of pathogenetically relevant genes. *BMC Microbiology*. 2005;5:20. DOI: 10.1186/1471-2180-5-20
- [116] Carbone A, Vaccher E, Gloghini A, Pantanowitz L, Abayomi A, de Paoli P, Franceschi S. Diagnosis and management of lymphomas and other cancers in HIV-infected patients. *Nature Reviews Clinical Oncology*. 2014;11(4):223–238. DOI: 10.1038/nrclinonc.2014.31
- [117] Xu D, Coleman T, Zhang J, Fagot A, Kotalik C, Zhao L, Trivedi P, Jones C, Zhang L. Epstein-Barr virus inhibits Kaposi's sarcoma-associated herpesvirus lytic replication in

- primary effusion lymphomas. *Journal of Virology*. 2007;81(11):6068–6078. DOI: 10.1128/JVI.02743-06
- [118] Scala G, Quinto I, Ruocco MR, Mallardo M, Ambrosino C, Squitieri B, Tassone P, Venuta S. Epstein-Barr virus nuclear antigen 2 transactivates the long terminal repeat of human immunodeficiency virus type 1. *Journal of Virology*. 1993;67(5):2853–2861.
- [119] Karijolic J, Zhao Y, Peterson B, Zhou Q, Glaunsinger B. Kaposi's sarcoma-associated herpesvirus ORF45 mediates transcriptional activation of the HIV-1 long terminal repeat via RSK2. *Journal of Virology*. 2014;88(12):7024–7035. DOI: 10.1128/JVI.00931-14
- [120] Strickler HD, Palefsky JM, Shah KV, Anastos K, Klein RS, Minkoff H, Duerr A, Massad LS, Celentano DD, Hall C, Fazzari M, Cu-Uvin S, Bacon M, Schuman P, Levine AM, Durante AJ, Gange S, Melnick S, Burk RD. Human papillomavirus type 16 and immune status in human immunodeficiency virus-seropositive women. *The Journal of the National Cancer Institute*. 2003;95(14):1062–1071.
- [121] La Ruche G, You B, Mensah-Ado I, Bergeron C, Montcho C, Ramon R, Toure-Coulibaly K, Wellfens-Ekra C, Dabis F, Orth G. Human papillomavirus and human immunodeficiency virus infections: relation with cervical dysplasia-neoplasia in African women. *International Journal of Cancer; Journal international du cancer*. 1998;76(4):480–486.
- [122] Wang HL, Lu DW. Detection of human papillomavirus DNA and expression of p16, Rb and p53 proteins in small cell carcinomas of the uterine cervix. *The American Journal of Surgical Pathology*. 2004;28(7):901–908.
- [123] Nyagol J, Leucci E, Onnis A, De Falco G, Tigli C, Sanseverino F, Torricelli M, Palummo N, Pacenti L, Santopietro R, Spina D, Gichangi P, Muchiri L, Lazzi S, Petraglia F, Leoncini L, Giordano A. The effects of HIV-1 Tat protein on cell cycle during cervical carcinogenesis. *Cancer Biology & Therapy*. 2006;5(6):684–690.
- [124] Polyak K, Kato JY, Solomon MJ, Sherr CJ, Massague J, Roberts JM, Koff A. p27Kip1, a cyclin-Cdk inhibitor, links transforming growth factor-beta and contact inhibition to cell cycle arrest. *Genes & Development*. 1994;8(1):9–22.
- [125] Snyder EL, Meade BR, Dowdy SF. Anti-cancer protein transduction strategies: reconstitution of p27 tumor suppressor function. *Journal of Controlled Release : official journal of the Controlled Release Society*. 2003;91(1–2):45–51.
- [126] Reuter MA, Pombo C, Betts MR. Cytokine production and dysregulation in HIV pathogenesis: lessons for development of therapeutics and vaccines. *Cytokine & Growth Factor Reviews*. 2012;23(4–5):181–191. DOI: 10.1016/j.cytogfr.2012.05.005
- [127] Katsikis PD, Mueller YM, Villinger F. The cytokine network of acute HIV infection: a promising target for vaccines and therapy to reduce viral set-point? *PLoS Pathogens*. 2011;7(8):e1002055. DOI: 10.1371/journal.ppat.1002055
- [128] Breen EC, Boscardin WJ, Detels R, Jacobson LP, Smith MW, O'Brien SJ, Chmiel JS, Rinaldo CR, Lai S, Martinez-Maza O. Non-Hodgkin's B cell lymphoma in persons with acquired immunodeficiency syndrome is associated with increased serum levels

- of IL10, or the IL10 promoter -592 C/C genotype. *Clinical Immunology*. 2003;109(2):119–129.
- [129] Schroeder JR, Saah AJ, Hoover DR, Margolick JB, Ambinder RF, Martinez-Maza O, Breen EC, Jacobson LP, Variakojis D, Rowe DT, Armenian HK. Serum soluble CD23 level correlates with subsequent development of AIDS-related non-Hodgkin's lymphoma. *Cancer Epidemiology, Biomarkers & Prevention: a publication of the American Association for Cancer Research, cosponsored by the American Society of Preventive Oncology*. 1999;8(11):979–984.
- [130] Hussain SK, Zhu W, Chang SC, Breen EC, Vendrame E, Magpantay L, Widney D, Conn D, Sehl M, Jacobson LP, Bream JH, Wolinsky S, Rinaldo CR, Ambinder RF, Detels R, Zhang ZF, Martinez-Maza O. Serum levels of the chemokine CXCL13, genetic variation in CXCL13 and its receptor CXCR5 and HIV-associated non-hodgkin B-cell lymphoma risk. *Cancer Epidemiology, Biomarkers & Prevention : a publication of the American Association for Cancer Research, cosponsored by the American Society of Preventive Oncology*. 2013;22(2):295–307. DOI: 10.1158/1055-9965.EPI-12-1122
- [131] Breen EC, Hussain SK, Magpantay L, Jacobson LP, Detels R, Rabkin CS, Kaslow RA, Variakojis D, Bream JH, Rinaldo CR, Ambinder RF, Martinez-Maza O. B-cell stimulatory cytokines and markers of immune activation are elevated several years prior to the diagnosis of systemic AIDS-associated non-Hodgkin B-cell lymphoma. *Cancer Epidemiology, Biomarkers & Prevention: a publication of the American Association for Cancer Research, cosponsored by the American Society of Preventive Oncology*. 2011;20(7):1303–1314. DOI: 10.1158/1055-9965.EPI-11-0037
- [132] Romagnani S, Maggi E. Th1 versus Th2 responses in AIDS. *Current Opinion in Immunology*. 1994;6(4):616–622.
- [133] Kryczek I, Wei S, Zou L, Altuwaijri S, Szeliga W, Kolls J, Chang A, Zou W. Cutting edge: Th17 and regulatory T cell dynamics and the regulation by IL-2 in the tumor microenvironment. *Journal of Immunology*. 2007;178(11):6730–6733.
- [134] Fiorentino DF, Bond MW, Mosmann TR. Two types of mouse T helper cell. IV. Th2 clones secrete a factor that inhibits cytokine production by Th1 clones. *The Journal of Experimental Medicine*. 1989;170(6):2081–2095.
- [135] Liapis K, Clear A, Owen A, Coutinho R, Greaves P, Lee AM, Montoto S, Calaminici M, Gribben JG. The microenvironment of AIDS-related diffuse large B-cell lymphoma provides insight into the pathophysiology and indicates possible therapeutic strategies. *Blood*. 2013;122(3):424–433. DOI: 10.1182/blood-2013-03-488171
- [136] Caccuri F, Giagulli C, Bugatti A, Benetti A, Alessandri G, Ribatti D, Marsico S, Apostoli P, Slevin MA, Rusnati M, Guzman CA, Fiorentini S, Caruso A. HIV-1 matrix protein p17 promotes angiogenesis via chemokine receptors CXCR1 and CXCR2. *Proceedings of the National Academy of Sciences of the United States of America*. 2012;109(36):14580–14585. DOI: 10.1073/pnas.1206605109

- [137] Giagulli C, Caccuri F, Cignarella F, Lougaris V, Martorelli D, Bugatti A, Rusnati M, Dolcetti R, Vitali M, Plebani A, Fiorentini S, Caruso A. A CXCR1 haplotype hampers HIV-1 matrix protein p17 biological activity. *AIDS*. 2014;28(16):2355–2364. DOI: 10.1097/QAD.0000000000000423
- [138] Fitzgerald DW, Bezak K, Ocheretina O, Riviere C, Wright TC, Milne GL, Zhou XK, Du B, Subbaramaiah K, Byrt E, Goodwin ML, Rafii A, Dannenberg AJ. The effect of HIV and HPV coinfection on cervical COX-2 expression and systemic prostaglandin E2 levels. *Cancer Prevention Research*. 2012;5(1):34–40. DOI: 10.1158/1940-6207.CAPR-11-0496
- [139] Tsujii M, Kawano S, Tsuji S, Sawaoka H, Hori M, DuBois RN. Cyclooxygenase regulates angiogenesis induced by colon cancer cells. *Cell*. 1998;93(5):705–716.
- [140] Ben-Av P, Crofford LJ, Wilder RL, Hla T. Induction of vascular endothelial growth factor expression in synovial fibroblasts by prostaglandin E and interleukin-1: a potential mechanism for inflammatory angiogenesis. *FEBS Letters*. 1995;372(1):83–87.
- [141] Tuyama AC, Hong F, Saiman Y, Wang C, Ozkok D, Mosoian A, Chen P, Chen BK, Klotman ME, Bansal MB. Human immunodeficiency virus (HIV)-1 infects human hepatic stellate cells and promotes collagen I and monocyte chemoattractant protein-1 expression: implications for the pathogenesis of HIV/hepatitis C virus-induced liver fibrosis. *Hepatology*. 2010;52(2):612–622. DOI: 10.1002/hep.23679
- [142] Lin W, Wu G, Li S, Weinberg EM, Kumthip K, Peng LF, Mendez-Navarro J, Chen WC, Jilg N, Zhao H, Goto K, Zhang L, Brockman MA, Schuppan D, Chung RT. HIV and HCV cooperatively promote hepatic fibrogenesis via induction of reactive oxygen species and NFkappaB. *The Journal of Biological Chemistry*. 2011;286(4):2665–2674. DOI: 10.1074/jbc.M110.168286
- [143] Munshi N, Balasubramanian A, Koziel M, Ganju RK, Groopman JE. Hepatitis C and human immunodeficiency virus envelope proteins cooperatively induce hepatocytic apoptosis via an innocent bystander mechanism. *The Journal of Infectious Diseases*. 2003;188(8):1192–1204. DOI: 10.1086/378643
- [144] Vlahakis SR, Villasis-Keever A, Gomez TS, Bren GD, Paya CV. Human immunodeficiency virus-induced apoptosis of human hepatocytes via CXCR4. *The Journal of Infectious Diseases*. 2003;188(10):1455–1460. DOI: 10.1086/379738
- [145] Jang JY, Shao RX, Lin W, Weinberg E, Chung WJ, Tsai WL, Zhao H, Goto K, Zhang L, Mendez-Navarro J, Jilg N, Peng LF, Brockman MA, Chung RT. HIV infection increases HCV-induced hepatocyte apoptosis. *Journal of Hepatology*. 2011;54(4):612–620. DOI: 10.1016/j.jhep.2010.07.042
- [146] Zheng SJ, Wang P, Tsbary G, Chen YH. Critical roles of TRAIL in hepatic cell death and hepatic inflammation. *The Journal of Clinical Investigation*. 2004;113(1):58–64. DOI: 10.1172/JCI19255
- [147] Delhay M, Louis H, Degraef C, Le Moine O, Deviere J, Gulbis B, Jacobovitz D, Adler M, Galand P. Relationship between hepatocyte proliferative activity and liver functional

- reserve in human cirrhosis. *Hepatology*. 1996;23(5):1003–1011. DOI: 10.1053/jhep.1996.v23.pm0008621125
- [148] Caillot F, Derambure C, Bioulac-Sage P, Francois A, Scotte M, Gorla O, Hiron M, Daveau M, Salier JP. Transient and etiology-related transcription regulation in cirrhosis prior to hepatocellular carcinoma occurrence. *World Journal of Gastroenterology*. 2009;15(3):300–309.
- [149] Sanyal AJ, Yoon SK, Lencioni R. The etiology of hepatocellular carcinoma and consequences for treatment. *Oncologist*. 2010;15 Suppl 4:14–22. DOI: 10.1634/theoncologist.2010-S4-14
- [150] Biggar RJ, Engels EA, Ly S, Kahn A, Schymura MJ, Sackoff J, Virgo P, Pfeiffer RM. Survival after cancer diagnosis in persons with AIDS. *Journal of Acquired Immune Deficiency Syndromes*. 2005;39(3):293–299.
- [151] Brock MV, Hooker CM, Engels EA, Moore RD, Gillison ML, Alberg AJ, Keruly JC, Yang SC, Heitmiller RF, Baylin SB, Herman JG, Brahmer JR. Delayed diagnosis and elevated mortality in an urban population with HIV and lung cancer: implications for patient care. *Journal of Acquired Immune Deficiency Syndromes*. 2006;43(1):47–55. DOI: 10.1097/01.qai.0000232260.95288.93
- [152] Spano JP, Atlan D, Breau JL, Farge D. AIDS and non-AIDS-related malignancies: a new vexing challenge in HIV-positive patients. Part II. Cervical and anal squamous epithelial lesions, lung cancer, testicular germ cell cancers and skin cancers. *European Journal of Internal Medicine*. 2002;13(4):227–232.
- [153] Suneja G, Shiels MS, Melville SK, Williams MA, Rengan R, Engels EA. Disparities in the treatment and outcomes of lung cancer among HIV-infected individuals. *AIDS*. 2013;27(3):459–468. DOI: 10.1097/QAD.0b013e32835ad56e
- [154] Suneja G, Shiels MS, Angulo R, Copeland GE, Gonsalves L, Hakenewerth AM, Macomber KE, Melville SK, Engels EA. Cancer treatment disparities in HIV-infected individuals in the United States. *Journal of Clinical Oncology*. 2014;32(22):2344–2350. DOI: 10.1200/JCO.2013.54.8644
- [155] Antoniou T, Tseng AL. Interactions between antiretrovirals and antineoplastic drug therapy. *Clinical Pharmacokinetics*. 2005;44(2):111–145. DOI: 10.2165/00003088-200544020-00001
- [156] Rudek MA, Flexner C, Ambinder RF. Use of antineoplastic agents in patients with cancer who have HIV/AIDS. *The Lancet Oncology*. 2011;12(9):905–912. DOI: 10.1016/S1470-2045(11)70056-0
- [157] Rubinstein PG, Aboulafia DM, Zloza A. Malignancies in HIV/AIDS: from epidemiology to therapeutic challenges. *AIDS*. 2014;28(4):453–465. DOI: 10.1097/QAD.0000000000000071
- [158] Torres HA, Mulanovich V. Management of HIV infection in patients with cancer receiving chemotherapy. *Clinical Infectious Diseases*. 2014;59(1):106–114. DOI: 10.1093/cid/ciu174
- [159] Kaplan LD, Lee JY, Ambinder RF, Sparano JA, Cesarman E, Chadburn A, Levine AM, Scadden DT. Rituximab does not improve clinical outcome in a randomized phase 3 trial

- p>of CHOP with or without rituximab in patients with HIV-associated non-Hodgkin lymphoma: AIDS-Malignancies Consortium Trial 010.
- Blood*
- . 2005;106(5):1538–1543. DOI: 10.1182/blood-2005-04-1437
- [160] Hocht S, Wiegel T, Kroesen AJ, Berdel WE, Runkel N, Hinkelbein W. Low acute toxicity of radiotherapy and radiochemotherapy in patients with cancer of the anal canal and HIV-infection. *Acta Oncologica*. 1997;36(8):799–802.
 - [161] Edelman S, Johnstone PA. Combined modality therapy for HIV-infected patients with squamous cell carcinoma of the anus: outcomes and toxicities. *International Journal of Radiation Oncology, Biology, Physics*. 2006;66(1):206–211. DOI: 10.1016/j.ijrobp.2006.03.049
 - [162] Cleator S, Fife K, Nelson M, Gazzard B, Phillips R, Bower M. Treatment of HIV-associated invasive anal cancer with combined chemoradiation. *European Journal of Cancer*. 2000;36(6):754–758.
 - [163] Wexler A, Berson AM, Goldstone SE, Waltzman R, Penzer J, Maisonet OG, McDermott B, Rescigno J. Invasive anal squamous-cell carcinoma in the HIV-positive patient: outcome in the era of highly active antiretroviral therapy. *Diseases of the Colon and Rectum*. 2008;51(1):73–81. DOI: 10.1007/s10350-007-9154-7
 - [164] Tirelli U, Spina M, Gaidano G, Vaccher E, Franceschi S, Carbone A. Epidemiological, biological and clinical features of HIV-related lymphomas in the era of highly active antiretroviral therapy. *AIDS*. 2000;14(12):1675–1688.
 - [165] Mounier N, Spina M, Gisselbrecht C. Modern management of non-Hodgkin lymphoma in HIV-infected patients. *British Journal of Haematology*. 2007;136(5):685–698. DOI: 10.1111/j.1365-2141.2006.06464.x
 - [166] Errante D, Tirelli U, Gastaldi R, Milo D, Nosari AM, Rossi G, Fiorentini G, Carbone A, Vaccher E, Monfardini S. Combined antineoplastic and antiretroviral therapy for patients with Hodgkin's disease and human immunodeficiency virus infection. A prospective study of 17 patients. The Italian Cooperative Group on AIDS and Tumors (GICAT). *Cancer*. 1994;73(2):437–444.
 - [167] Levine AM, Li P, Cheung T, Tulpule A, Von Roenn J, Nathwani BN, Ratner L. Chemotherapy consisting of doxorubicin, bleomycin, vinblastine and dacarbazine with granulocyte-colony-stimulating factor in HIV-infected patients with newly diagnosed Hodgkin's disease: a prospective, multi-institutional AIDS clinical trials group study (ACTG 149). *Journal of Acquired Immune Deficiency Syndromes*. 2000;24(5):444–450.
 - [168] Kaplan LD, Straus DJ, Testa MA, Von Roenn J, Dezube BJ, Cooley TP, Herndier B, Northfelt DW, Huang J, Tulpule A, Levine AM. Low-dose compared with standard-dose m-BACOD chemotherapy for non-Hodgkin's lymphoma associated with human immunodeficiency virus infection. National Institute of Allergy and Infectious Diseases AIDS Clinical Trials Group. *The New England Journal of Medicine*. 1997;336(23):1641–1648. DOI: 10.1056/NEJM199706053362304

- [169] Ratner L, Lee J, Tang S, Redden D, Hamzeh F, Herndier B, Scadden D, Kaplan L, Ambinder R, Levine A, Harrington W, Grochow L, Flexner C, Tan B, Straus D, Consortium AM. Chemotherapy for human immunodeficiency virus-associated non-Hodgkin's lymphoma in combination with highly active antiretroviral therapy. *Journal of Clinical Oncology*. 2001;19(8):2171–2178.
- [170] Mounier N, Spina M, Gabarre J, Raphael M, Rizzardini G, Golfier JB, Vaccher E, Carbone A, Coiffier B, Chichino G, Bosly A, Tirelli U, Gisselbrecht C. AIDS-related non-Hodgkin lymphoma: final analysis of 485 patients treated with risk-adapted intensive chemotherapy. *Blood*. 2006;107(10):3832–3840. DOI: 10.1182/blood-2005-09-3600
- [171] Sparano JA, Lee S, Chen MG, Nazeer T, Einzig A, Ambinder RF, Henry DH, Manalo J, Li T, Von Roenn JH. Phase II trial of infusional cyclophosphamide, doxorubicin and etoposide in patients with HIV-associated non-Hodgkin's lymphoma: an Eastern Cooperative Oncology Group Trial (E1494). *Journal of Clinical Oncology*. 2004;22(8):1491–1500. DOI: 10.1200/JCO.2004.08.195
- [172] Little RF, Pittaluga S, Grant N, Steinberg SM, Kavlick MF, Mitsuya H, Franchini G, Gutierrez M, Raffeld M, Jaffe ES, Shearer G, Yarchoan R, Wilson WH. Highly effective treatment of acquired immunodeficiency syndrome-related lymphoma with dose-adjusted EPOCH: impact of antiretroviral therapy suspension and tumor biology. *Blood*. 2003;101(12):4653–4659. DOI: 10.1182/blood-2002-11-3589
- [173] Barta SK, Xue X, Wang D, Tamari R, Lee JY, Mounier N, Kaplan LD, Ribera JM, Spina M, Tirelli U, Weiss R, Galicier L, Boue F, Wilson WH, Wyen C, Oriol A, Navarro JT, Dunleavy K, Little RF, Ratner L, Garcia O, Morgades M, Remick SC, Noy A, Sparano JA. Treatment factors affecting outcomes in HIV-associated non-Hodgkin lymphomas: a pooled analysis of 1546 patients. *Blood*. 2013;122(19):3251–3262. DOI: 10.1182/blood-2013-04-498964
- [174] Levine AM, Noy A, Lee JY, Tam W, Ramos JC, Henry DH, Parekh S, Reid EG, Mitsuyasu R, Cooley T, Dezube BJ, Ratner L, Cesarman E, Tulpule A. Pegylated liposomal doxorubicin, rituximab, cyclophosphamide, vincristine and prednisone in AIDS-related lymphoma: AIDS Malignancy Consortium Study 047. *Journal of Clinical Oncology*. 2013;31(1):58–64. DOI: 10.1200/JCO.2012.42.4648
- [175] Lim ST, Karim R, Nathwani BN, Tulpule A, Espina B, Levine AM. AIDS-related Burkitt's lymphoma versus diffuse large-cell lymphoma in the pre-highly active antiretroviral therapy (HAART) and HAART eras: significant differences in survival with standard chemotherapy. *Journal of Clinical Oncology*. 2005;23(19):4430–4438. DOI: 10.1200/JCO.2005.11.973
- [176] Lim ST, Karim R, Tulpule A, Nathwani BN, Levine AM. Prognostic factors in HIV-related diffuse large-cell lymphoma: before versus after highly active antiretroviral therapy. *Journal of Clinical Oncology*. 2005;23(33):8477–8482. DOI: 10.1200/JCO.2005.02.9355

- [177] Miralles P, Berenguer J, Ribera JM, Rubio R, Mahillo B, Tellez MJ, Lacruz J, Valencia E, Santos J, Rodriguez-Arondo F, Pintado V, Grupo de Estudio del SROSA-RL. Prognosis of AIDS-related systemic non-Hodgkin lymphoma treated with chemotherapy and highly active antiretroviral therapy depends exclusively on tumor-related factors. *Journal of Acquired Immune Deficiency Syndromes*. 2007;44(2):167–173. DOI: 10.1097/QAI.0b013e31802bb5d0
- [178] Re A, Michieli M, Casari S, Allione B, Cattaneo C, Rupolo M, Spina M, Manuele R, Vaccher E, Mazzucato M, Abbruzzese L, Ferremi P, Carosi G, Tirelli U, Rossi G. High-dose therapy and autologous peripheral blood stem cell transplantation as salvage treatment for AIDS-related lymphoma: long-term results of the Italian Cooperative Group on AIDS and Tumors (GICAT) study with analysis of prognostic factors. *Blood*. 2009;114(7):1306–1313. DOI: 10.1182/blood-2009-02-202762
- [179] Diez-Martin JL, Balsalobre P, Re A, Michieli M, Ribera JM, Canals C, Conde E, Rosselet A, Gabriel I, Varela R, Allione B, Cwynarski K, Genet P, Espigado I, Biron P, Schmitz N, Hunter AE, Ferrant A, Guillermin G, Hentrich M, Jurado M, Fernandez P, Serrano D, Rossi G, Sureda A, European Group for Blood and Marrow Transplantation Lymphoma Working Party. Comparable survival between HIV+ and HIV– non-Hodgkin and Hodgkin lymphoma patients undergoing autologous peripheral blood stem cell transplantation. *Blood*. 2009;113(23):6011–6014. DOI: 10.1182/blood-2008-12-195388
- [180] Balsalobre P, Diez-Martin JL, Re A, Michieli M, Ribera JM, Canals C, Rosselet A, Conde E, Varela R, Cwynarski K, Gabriel I, Genet P, Guillermin G, Allione B, Ferrant A, Biron P, Espigado I, Serrano D, Sureda A. Autologous stem-cell transplantation in patients with HIV-related lymphoma. *Journal of Clinical Oncology*. 2009;27(13):2192–2198. DOI: 10.1200/JCO.2008.18.2683
- [181] Krishnan A, Palmer JM, Zaia JA, Tsai NC, Alvarnas J, Forman SJ. HIV status does not affect the outcome of autologous stem cell transplantation (ASCT) for non-Hodgkin lymphoma (NHL). *Biology of Blood and Marrow Transplantation: journal of the American Society for Blood and Marrow Transplantation*. 2010;16(9):1302–1308. DOI: 10.1016/j.bbmt.2010.03.019
- [182] Michieli M, Mazzucato M, Tirelli U, De Paoli P. Stem cell transplantation for lymphoma patients with HIV infection. *Cell Transplantation*. 2011;20(3):351–370. DOI: 10.3727/096368910X528076
- [183] Bayraktar UD, Ramos JC, Petrich A, Gupta N, Lensing S, Moore PC, Reid EG, Aboulafia DM, Ratner L, Mitsuyasu R, Cooley T, Henry DH, Barr P, Noy A. Outcome of patients with relapsed/refractory acquired immune deficiency syndrome-related lymphoma diagnosed 1999–2008 and treated with curative intent in the AIDS Malignancy Consortium. *Leukemia & Lymphoma*. 2012;53(12):2383–2389. DOI: 10.3109/10428194.2012.697559
- [184] Carbone A, Cesarman E, Spina M, Gloghini A, Schulz TF. HIV-associated lymphomas and gamma-herpesviruses. *Blood*. 2009;113(6):1213–1224. DOI: 10.1182/blood-2008-09-180315

- [185] Levine AM. Management of AIDS-related lymphoma. *Current Opinion in Oncology*. 2008;20(5):522–528. DOI: 10.1097/CCO.0b013e3283094ec7
- [186] Galicier L, Fieschi C, Borie R, Meignin V, Daniel MT, Gerard L, Oksenhendler E. Intensive chemotherapy regimen (LMB86) for St Jude stage IV AIDS-related Burkitt lymphoma/leukemia: a prospective study. *Blood*. 2007;110(8):2846–2854. DOI: 10.1182/blood-2006-10-051771
- [187] Wang ES, Straus DJ, Teruya-Feldstein J, Qin J, Portlock C, Moskowitz C, Goy A, Hedrick E, Zelenetz AD, Noy A. Intensive chemotherapy with cyclophosphamide, doxorubicin, high-dose methotrexate/ifosfamide, etoposide and high-dose cytarabine (CODOX-M/IVAC) for human immunodeficiency virus-associated Burkitt lymphoma. *Cancer*. 2003;98(6):1196–1205. DOI: 10.1002/cnccr.11628
- [188] Persad GC, Little RF, Grady C. Including persons with HIV infection in cancer clinical trials. *Journal of Clinical Oncology*. 2008;26(7):1027–1032. DOI: 10.1200/JCO.2007.14.5532
- [189] Spano JP, Massiani MA, Bentata M, Rixe O, Friard S, Bossi P, Rouges F, Katlama C, Breau JL, Morere JF, Khayat D, Couderc LJ. Lung cancer in patients with HIV Infection and review of the literature. *Medical Oncology*. 2004;21(2):109–115. DOI: 10.1385/MO:21:2:109
- [190] Vyzula R, Remick SC. Lung cancer in patients with HIV-infection. *Lung Cancer*. 1996;15(3):325–339.
- [191] Wosnitzer MS, Lowe FC. Management of prostate cancer in HIV-positive patients. *Nature Reviews Urology*. 2010;7(6):348–357. DOI: 10.1038/nrurol.2010.61
- [192] Berretta M, Lleshi A, Cappellani A, Bearz A, Spina M, Talamini R, Cacopardo B, Nunnari G, Montesarchio V, Izzi I, Lanzafame M, Nasti G, Basile F, Berretta S, Fisichella R, Schiantarelli CC, Garlassi E, Ridolfo A, Guella L, Tirelli U. Oxaliplatin based chemotherapy and concomitant highly active antiretroviral therapy in the treatment of 24 patients with colorectal cancer and HIV infection. *Current HIV Research*. 2010;8(3):218–222.
- [193] Chapman C, Aboulafia DM, Dezube BJ, Pantanowitz L. Human immunodeficiency virus-associated adenocarcinoma of the colon: clinicopathologic findings and outcome. *Clinical Colorectal Cancer*. 2009;8(4):215–219. DOI: 10.3816/CCC.2009.n.036
- [194] Prabha Devi K, Bindhu Priya N. Conventional Pap Smear Screening in HIV Seropositive Women in South India. *Journal of Obstetrics and Gynaecology of India*. 2013;63(1):55–58. DOI: 10.1007/s13224-012-0204-2
- [195] Massad LS, Seaberg EC, Watts DH, Minkoff H, Levine AM, Henry D, Colie C, Darragh TM, Hessel NA. Long-term incidence of cervical cancer in women with human immunodeficiency virus. *Cancer*. 2009;115(3):524–530. DOI: 10.1002/cnccr.24067
- [196] Lissoni P, Meregalli S, Bonetto E, Mancuso M, Brivio F, Colciago M, Gardani G. Radiotherapy-induced lymphocytopenia: changes in total lymphocyte count and in lymphocyte subpopulations under pelvic irradiation in gynecologic neoplasms. *Journal of Biological Regulators and Homeostatic Agents*. 2005;19(3–4):153–158.

- [197] Ntekim A, Campbell O, Rothenbacher D. Optimal management of cervical cancer in HIV-positive patients: a systematic review. *Cancer Medicine*. 2015;4(9):1381–1393. DOI: 10.1002/cam4.485
- [198] Gichangi P, De Vuyst H, Estambale B, Rogo K, Bwayo J, Temmerman M. HIV and cervical cancer in Kenya. *International Journal of Gynaecology and Obstetrics: the official organ of the International Federation of Gynaecology and Obstetrics*. 2002;76(1):55–63.
- [199] Moodley M, Mould S. Invasive cervical cancer and human immunodeficiency virus (HIV) infection in KwaZulu-Natal, South Africa. *Journal of Obstetrics and Gynaecology: the journal of the Institute of Obstetrics and Gynaecology*. 2005;25(7):706–710. DOI: 10.1080/01443610500294599
- [200] Shrivastava SK, Engineer R, Rajadhyaksha S, Dinshaw KA. HIV infection and invasive cervical cancers, treatment with radiation therapy: toxicity and outcome. *Radiotherapy and Oncology: journal of the European Society for Therapeutic Radiology and Oncology*. 2005;74(1):31–35. DOI: 10.1016/j.radonc.2004.11.006
- [201] Gichangi P, Bwayo J, Estambale B, Rogo K, Njuguna E, Ojwang S, Temmerman M. HIV impact on acute morbidity and pelvic tumor control following radiotherapy for cervical cancer. *Gynecologic Oncology*. 2006;100(2):405–411. DOI: 10.1016/j.ygyno.2005.10.006
- [202] Ong WL, Manohar P, Millar J, Royce P. Clinicopathological characteristics and management of prostate cancer in the human immunodeficiency virus (HIV)-positive population: experience in an Australian major HIV centre. *BJU International* 2015;116 Suppl 3:5–10. DOI: 10.1111/bju.13097
- [203] Bower M, Weir J, Francis N, Newsom-Davis T, Powles S, Crook T, Boffito M, Gazzard B, Nelson M. The effect of HAART in 254 consecutive patients with AIDS-related Kaposi's sarcoma. *AIDS*. 2009;23(13):1701–1706. DOI: 10.1097/QAD.0b013e32832d080d
- [204] Cattelan AM, Calabro ML, Gasperini P, Aversa SM, Zanchetta M, Meneghetti F, De Rossi A, Chieco-Bianchi L. Acquired immunodeficiency syndrome-related Kaposi's sarcoma regression after highly active antiretroviral therapy: biologic correlates of clinical outcome. *Journal of the National Cancer Institute Monographs*. 2001(28):44–49.
- [205] Martin-Carbonero L, Barrios A, Saballs P, Sirera G, Santos J, Palacios R, Valencia ME, Alegre M, Podzamczar D, Gonzalez-Lahoz J, Caelyx KSSG. Pegylated liposomal doxorubicin plus highly active antiretroviral therapy versus highly active antiretroviral therapy alone in HIV patients with Kaposi's sarcoma. *AIDS*. 2004;18(12):1737–1740.
- [206] Lichterfeld M, Qurishi N, Hoffmann C, Hochdorfer B, Brockmeyer NH, Arasteh K, Mauss S, Rockstroh JK, German Clinical AWG. Treatment of HIV-1-associated Kaposi's sarcoma with pegylated liposomal doxorubicin and HAART simultaneously induces effective tumor remission and CD4+ T cell recovery. *Infection*. 2005;33(3):140–147. DOI: 10.1007/s15010-005-4099-z

- [207] Esdaile B, Davis M, Portsmouth S, Sarker D, Nelson M, Gazzard B, Bower M. The immunological effects of concomitant highly active antiretroviral therapy and liposomal anthracycline treatment of HIV-1-associated Kaposi's sarcoma. *AIDS*. 2002;16(17):2344–2347.
- [208] Tulpule A, Groopman J, Saville MW, Harrington W, Jr., Friedman-Kien A, Espina BM, Garces C, Mantelle L, Mettinger K, Scadden DT, Gill PS. Multicenter trial of low-dose paclitaxel in patients with advanced AIDS-related Kaposi sarcoma. *Cancer*. 2002;95(1):147–154. DOI: 10.1002/cncr.10634
- [209] Ablanedo-Terrazas Y, Alvarado-De La Barrera C, Reyes-Teran G. Towards a better understanding of Kaposi sarcoma-associated immune reconstitution inflammatory syndrome. *AIDS*. 2013;27(10):1667–1669. DOI: 10.1097/QAD.0b013e328360106b
- [210] French MA. HIV/AIDS: immune reconstitution inflammatory syndrome: a reappraisal. *Clinical Infectious Diseases*. 2009;48(1):101–107. DOI: 10.1086/595006
- [211] Pham PA, Flexner C. Emerging antiretroviral drug interactions. *The Journal of Antimicrobial Chemotherapy*. 2011;66(2):235–239. DOI: 10.1093/jac/dkq448
- [212] Antinori A, Marcotullio S, Ammassari A, Andreoni M, Angarano G, Armignacco O, Carosi G, Cinque P, d'Arminio Monforte A, Di Perri G, Ensoli B, Floridia M, Galli M, Mastroianni C, Matteelli A, Mazzotta F, Moroni M, Pal G, Puoti M, Puro V, Rizzardini G, Sagnelli E, Vella S, Vullo V, Lazzarin A, Italian HIVGWG. Italian guidelines for the use of antiretroviral agents and the diagnostic-clinical management of HIV-1 infected persons. Update 2011. *The New Microbiologica*. 2012;35(2):113–159.