

We are IntechOpen, the world's leading publisher of Open Access books Built by scientists, for scientists

6,900

Open access books available

186,000

International authors and editors

200M

Downloads

Our authors are among the

154

Countries delivered to

TOP 1%

most cited scientists

12.2%

Contributors from top 500 universities



WEB OF SCIENCE™

Selection of our books indexed in the Book Citation Index
in Web of Science™ Core Collection (BKCI)

Interested in publishing with us?
Contact book.department@intechopen.com

Numbers displayed above are based on latest data collected.
For more information visit www.intechopen.com



Angiography and Endovascular Therapy for Aortoiliac Artery Disease

Keisuke Fukuda

Additional information is available at the end of the chapter

<http://dx.doi.org/10.5772/67178>

Abstract

The treatment of aortoiliac occlusive disease has shifted to endovascular therapy. Even in complex lesion, precise angiography enables successful treatment in endovascular work. However, complications-related endovascular intervention of these lesions is catastrophic. Accurate angiographic assessment is mandatory to complete the procedure. This article reviews angiographic approach for aortoiliac artery disease in diagnosis, endovascular intervention, and complications.

Keywords: aortoiliac occlusive disease, TASC II classification, access

1. Introduction

Aortoiliac occlusive disease results from the common cardiovascular condition atherosclerosis, accounting for approximately one-third of all symptomatic peripheral artery disease (PAD) [1]. Most cases of aortoiliac artery disease presents with lower limb claudication and can potentially progress to critical limb ischemia. In revascularization for aortoiliac disease, endovascular therapy is increasingly being employed instead of surgical bypass. Even in complex aortoiliac artery diseases such as bifurcation disease, long segment occlusion, and aortic occlusion, endovascular therapy is being employed with the application of stents [2, 3]. The most commonly quoted classification of iliac lesions has been set forth by the Trans-Atlantic Inter-Society Consensus (TASC II) group with recommended treatment options [4]. These classifications of their morphology have finally been defined by assessment in accurate detail with angiography. Therefore, precise angiographic assessment is vital to success in aortoiliac artery interventions. This article reviews an angiographic approach to aortoiliac artery disease presenting various detailed images and analyses pre- and postrevascularization.

2. Angiographic technique for the aortoiliac artery

2.1. Vascular anatomy of the aortoiliac artery

A solid understanding of the vascular anatomy of the aortoiliac artery in angiography is indispensable to diagnostic or interventional work. The vasculature within range from the infra-renal artery to the common femoral artery is shown in **Figure 1**.

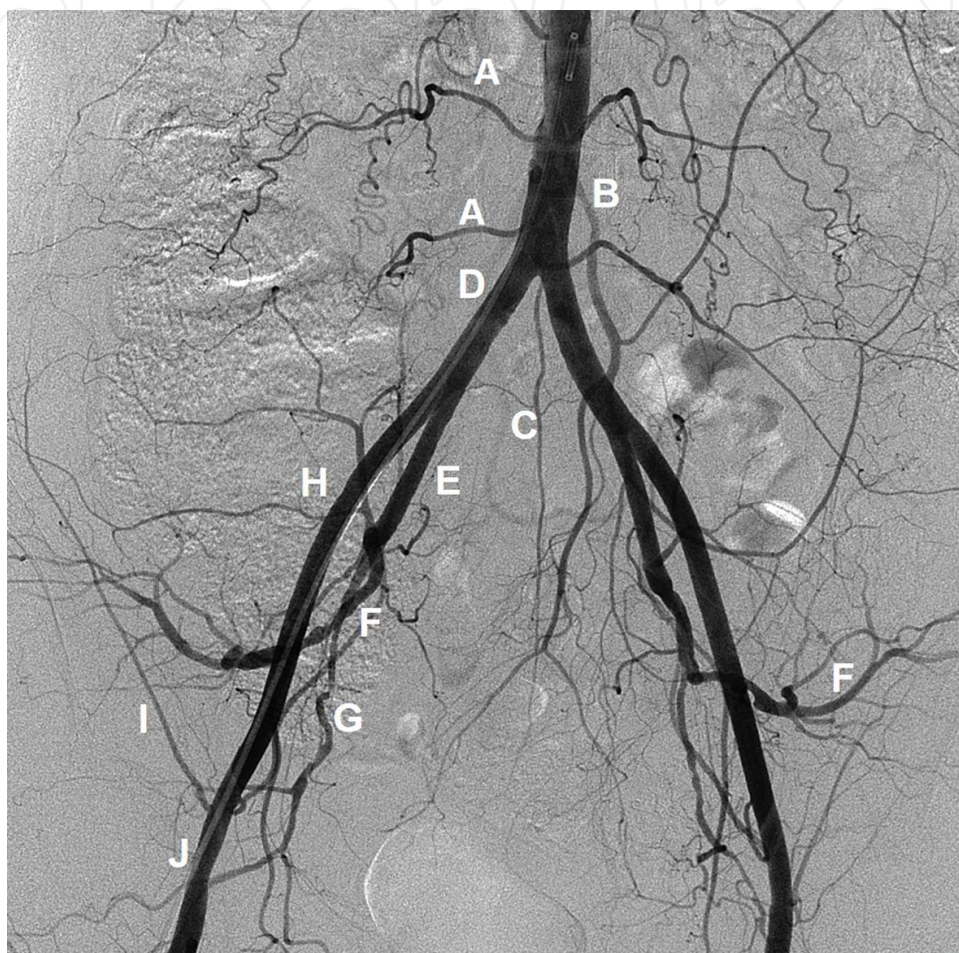


Figure 1. Anatomy in aortoiliac artery angiography. Aortoiliac angiography image includes abdominal aorta, lumbar branch (A), inferior mesenteric artery (B), median sacral artery (C), common iliac artery (D), internal iliac artery (E), superior (F) and inferior (G) gluteal arteries, external iliac artery (H), deep circumflex iliac artery, (I) and common femoral artery (J).

Commonly, the aortoiliac angiographic image includes the abdominal aorta, lumbar branch, inferior mesenteric artery, median sacral artery, common iliac artery (CIA), internal iliac artery (IIA), superior and inferior gluteal arteries, external iliac artery (EIA), deep circumflex iliac artery, and common femoral artery (CFA). Safe and successful procedures are accomplished by meticulous manipulation of a wire and/or catheter to a target vessel. Particularly, in the case of complex aortoiliac disease with total occlusion or calcification, a wire or catheter is more likely to stray unintentionally into unexpected vessels. Therefore, a thorough understanding of the vasculature including a normal vasculature, anomalies, and complex collateral networks is required before any intervening procedure.

2.2. Image size and optimal view

To visualize aortoiliac disease, an image field of more than 30 cm is required. Information on the vessel size and lesion length is needed as well. The wide 30 cm image could not confirm the precise morphology of the lesion, while a 20 cm image was better suited (**Figure 2**).

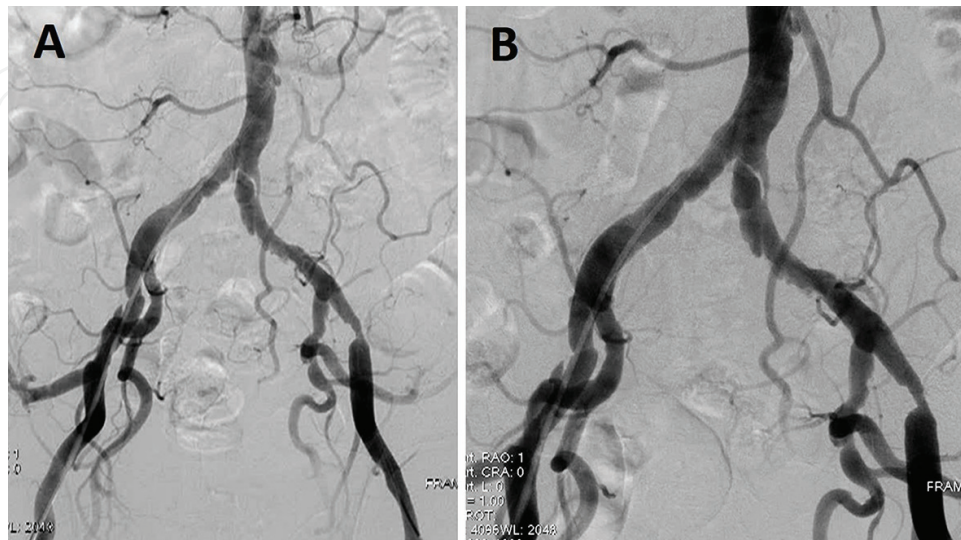


Figure 2. Aortoiliac artery angiography by 30 and 20 cm image size. (A) By 30 cm DSA image, whole aortoiliac disease is visualized. (B) By 20 cm DSA image, the precise morphology of left common iliac artery ulcerated lesion and tight stenosis of left external iliac artery are well visualized.

Unlike femoropopliteal or below the knee arteries, the aortoiliac arteries are located in the intraperitoneal space and form three-dimensionally from the terminal aorta to the common femoral artery (**Figure 3**).

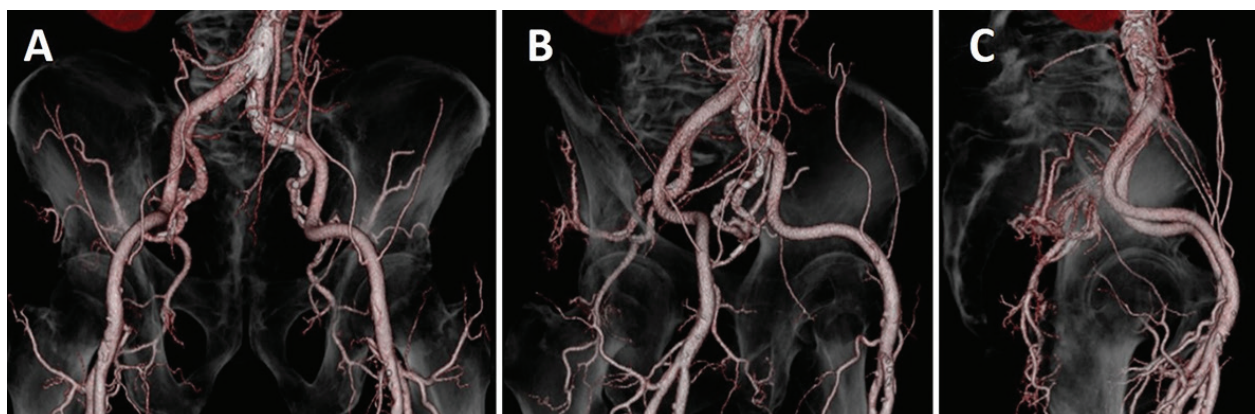


Figure 3. Aortoiliac artery by 3D CT angiography. (A) AP view, (B) RAO 45° view, (C) lateral view. RAO view and lateral view show that aortoiliac arterial system located in intraperitoneal space with three-dimensional CT angiography.

Multidirectional projection in angiography is also useful to achieve successful endovascular revascularization. The optimal view for interventional work is commonly obtained by magnification and various oblique projections. Not only anterior-posterior views but also a contralateral view is important (**Figure 4**).

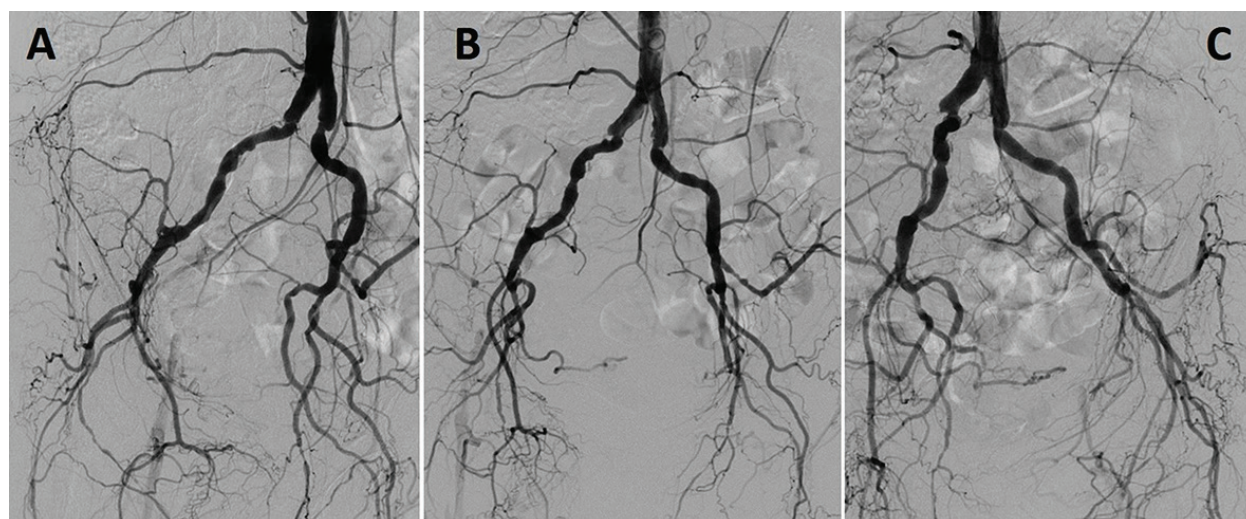


Figure 4. Basic three aortographic views. (A) DSA in LAO view. (B) DSA in AP view. (C) DSA in RAO view.

If a lesion could not be identified or is not well visualized, angiography should be performed using a contralateral oblique (20° – 30°) projection. Particularly in EIA lesions, this angled view is imperative in obtaining accurate information on a lesion (**Figure 5**).

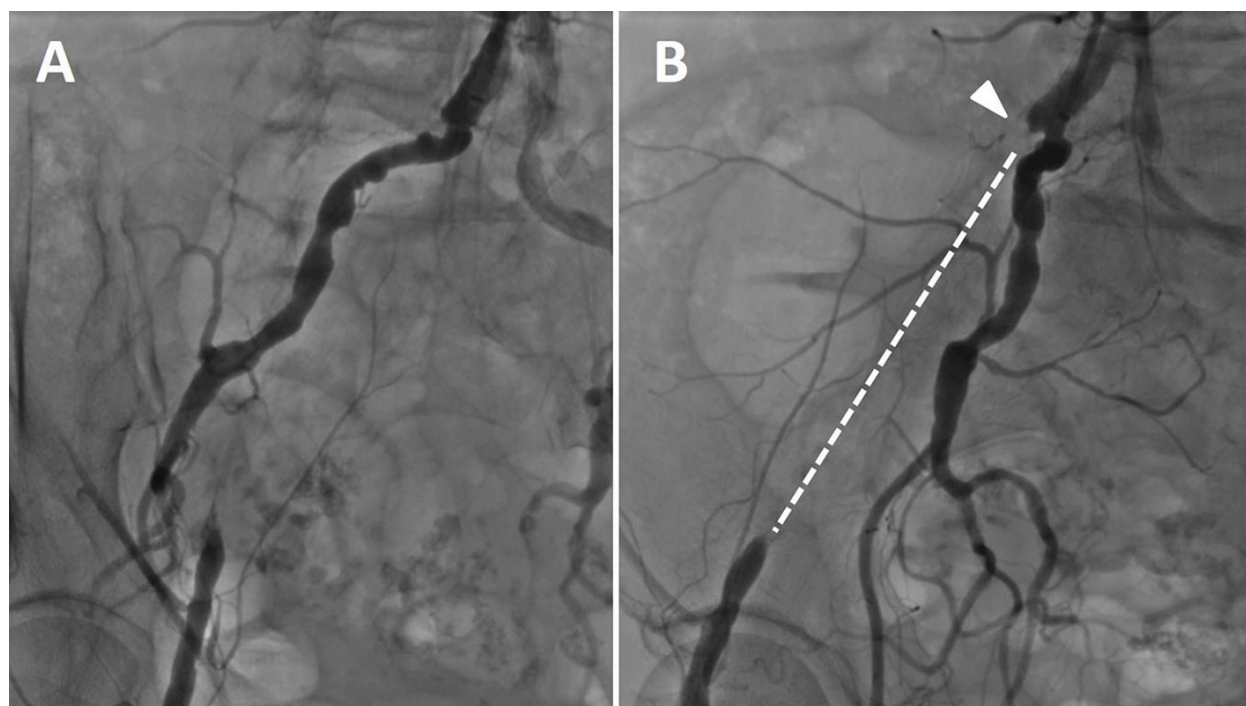


Figure 5. Right EIA occlusion in LAO and RAO views. (A): in LAO view, stump is hidden and occluded lesion overlaps with internal iliac artery. (B): In RAO view, stump (arrow head) can be clearly visualized and occluded lesion is well-isolated (white dot line).

Digital subtracted angiography (DSA) images are considered to be the standard modality for iliac artery disease, but visualization of the pelvic vessels is often interfered by bowel movement and gas in a 30 cm image. Breath holding during contrast injection is requested in conscious

patients. With recent advanced digital angiography (DA), similar images to DSA can be obtained. Moreover, to take excellent images for diagnostic angiography, the 5-Fr pigtail catheter is preferred over a 4-Fr system. Decisions for intervention are thus made after diagnostic angiography. We exchange to a 6-Fr system if intervention is indicated.

2.3. Access

2.3.1. Antegrade upper limb access

Upper limb access including the brachial or radial artery has several advantages compared to conventional femoral access in terms of anatomical reasons, fewer bleeding complications, and/or patient preference [5]. In common iliac artery disease, the contralateral femoral artery approach may encounter difficulty when crossing the contralateral common iliac artery lesion. Left brachial or radial artery access can be employed for aortography [6]. This approach is useful in cases with suspected or known total occlusion in aortoiliac artery lesions [7]. Generally speaking, the left brachial or radial artery approach is anatomically suited to reach the terminal aorta through the aortic arch due to the shorter length and more linear route from the access site to the terminal aorta, so that catheter manipulation of the catheter and wire is much easier as compared to the right upper limb approach (**Figure 6**).

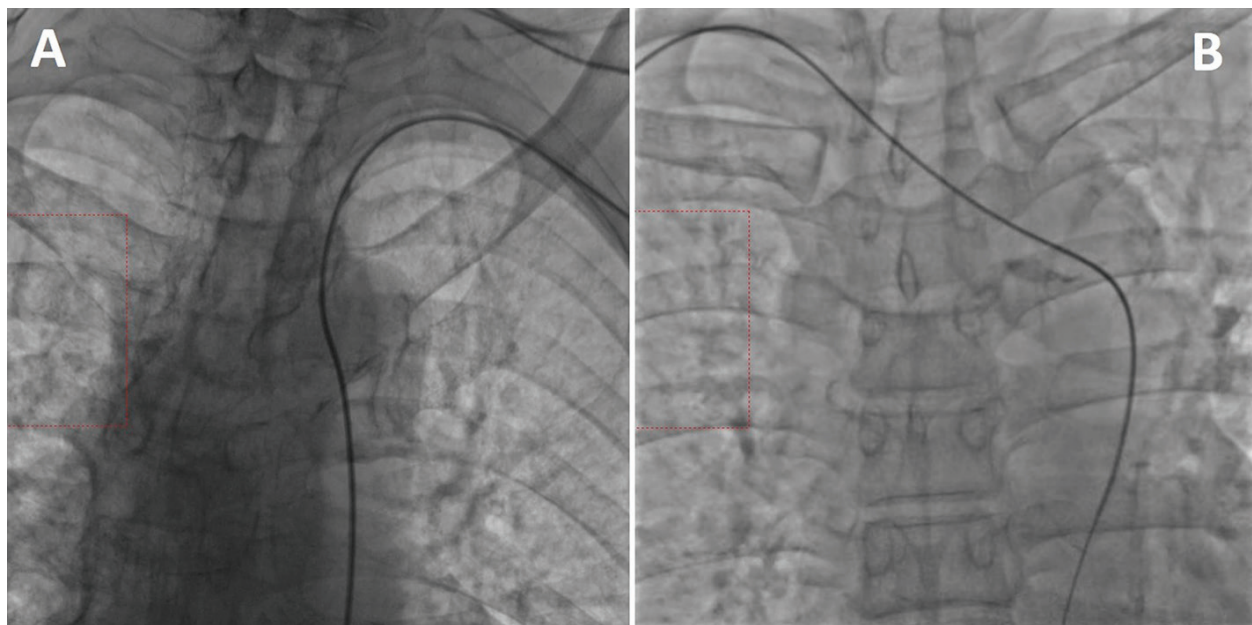


Figure 6. Difference between left and right upper limb approach. (A) From left arm approach, the shape of the wire is in linear form with shorter length. (B) From right arm approach, the wire and catheter have to pass through the aortic arch.

In complex aortic bifurcation or proximal CIA occlusions, the antegrade approach is necessary and effective in conjunction with the femoral approach for successful intervention. Additionally, this approach is vital in cases when the crossover technique cannot be employed due to previous kissing stenting at the aortic bifurcation or when CFA access is hindered due to severe stenosis or anastomosis for a bypass graft. A lesion may be easily

crossed with a wire through a 6-Fr-long sheath from the left brachial artery, and ballooning or stenting can then be performed by this approach. In recent endovascular devices for PAD, there are systems with long shafts of between 130 and 150 cm in length and these devices enable an upper limb approach. However, these are limited to balloons and stents. Large diameter size devices such as those for atherectomy are not advised for a brachial or radial artery approach.

2.3.2. Retrograde ipsilateral CFA access

The retrograde ipsilateral CFA approach is most frequently used as a standard technique. For a precise CFA puncture, we routinely use echo with fluoroscopy guidance. After confirming no CFA disease, an ipsilateral approach is selected for iliac artery intervention. If there is no CFA disease, we advance a 4-Fr or 5-Fr pigtail catheter to the terminal aorta. By power injection of the contrast dye at the terminal aorta, we inject 13 cc/s for a total of 26 cc by a 4-Fr pigtail and 16–18 cc/s for a total of 25 cc by a 5-Fr pigtail catheter. Manual contrast injection is not recommended at the aortoiliac artery. In TASC II A or B lesions, retrograde sheath injection can be performed. In bilateral iliac lesions, if a contralateral CIA ostial lesion is not involved, treatment can proceed by a retrograde and crossover antegrade technique at one femoral artery access site (**Figure 7**).

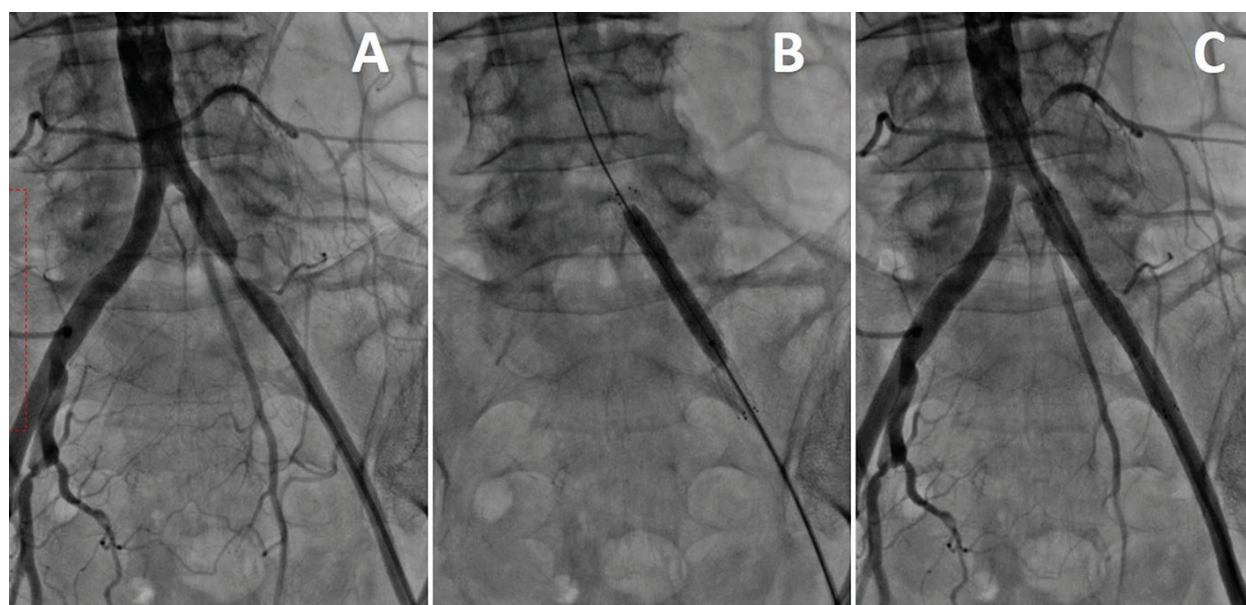


Figure 7. Angiography and treatment from ipsilateral CFA sheath. (A) Angiography from retrograde sheath injection shows severe stenosis of left EIA. (B) Ballooning and stenting performed from retrograde sheath. (C) Completion of angiography from retrograde sheath shows good results.

In intervention for total occlusion of the common iliac artery with or without distal EIA disease, a bidirectional wiring technique is the key to successful recanalization. Therefore, ipsilateral retrograde intervention in conjunction with an antegrade approach from the contralateral femoral side or from the brachial or radial artery is essential for successful wiring.

2.3.3. Retrograde contralateral CFA access

Retrograde contralateral CFA access is an indispensable technique for interventions of peripheral artery disease at each level of the lower extremity, including the iliac, femoropopliteal, and below the knee arteries. For interventions from the iliac artery to below the knee, the crossover technique is requisite. Mastering the crossover technique is required of every interventionist since, in patients with CFA, proximal SFA, and/or distal EIA disease, this approach is mainly selected. Operators who are experienced and skillful in this technique can freely select any access site, leading to safer procedures and more successful outcomes. Total occluded iliac artery interventions commonly require a bidirectional approach from both CFA access sites. To cross the guidewire to the contralateral iliac artery, we generally use a JR diagnostic (4 or 5 Fr) catheter placed to the bifurcation of the terminal aorta. If there is an acute angle at the bifurcation of the iliac artery, the 4-Fr IMA catheter can be used. We do not use a pigtail catheter for crossover purposes since the movement of the wire is unpredictable and may damage the vessel wall. Exchange to a stiff guidewire was performed to advance the crossover sheath (5 or 6 Fr). In the case of heavily tortuous or calcified CIA, it is very difficult to advance the sheath to the contralateral side. In such a case, the balloon anchor technique is helpful to crossover the sheath (**Figure 8**) [8].

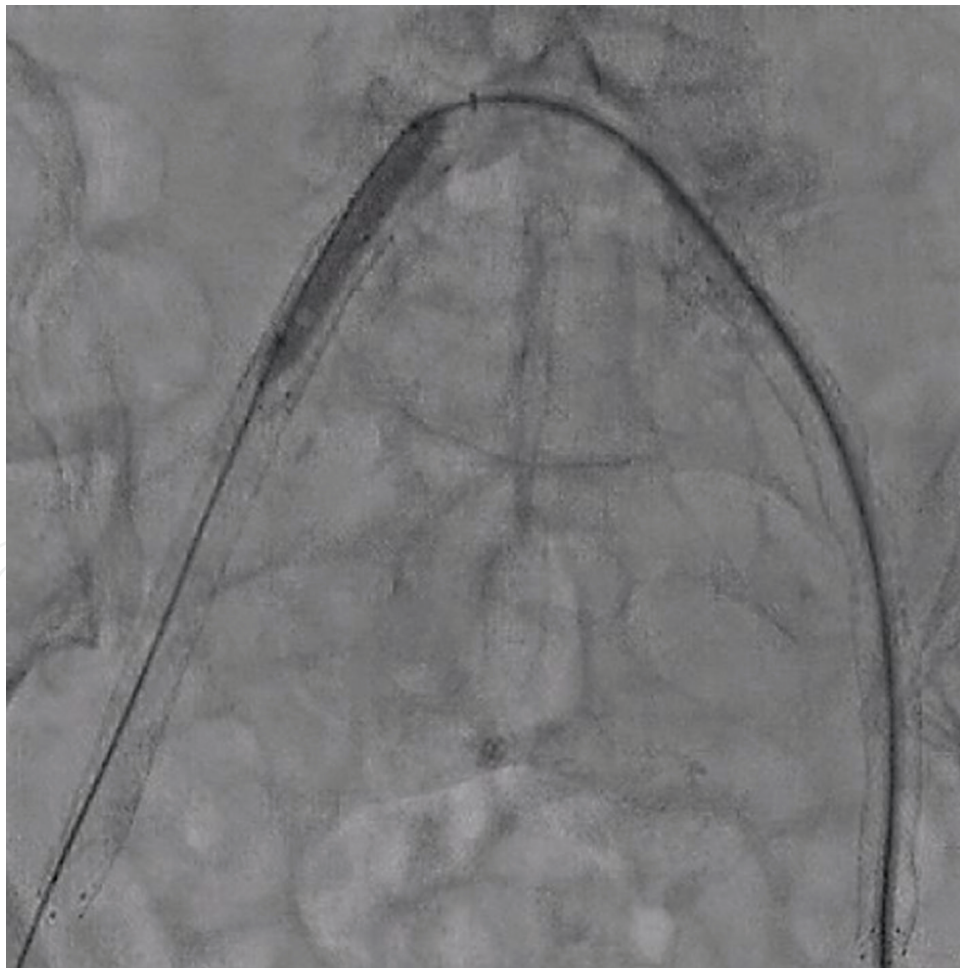


Figure 8. Using balloon anchor technique, the crossover sheath was advanced to contralateral iliac artery.

However, there are some cases when crossover at the bifurcation is not possible (**Figure 9**), for example, with a sharp-angled isthmus, poststent graft, or postkissing stent. Therefore, detailed reinterventional planning is essential.

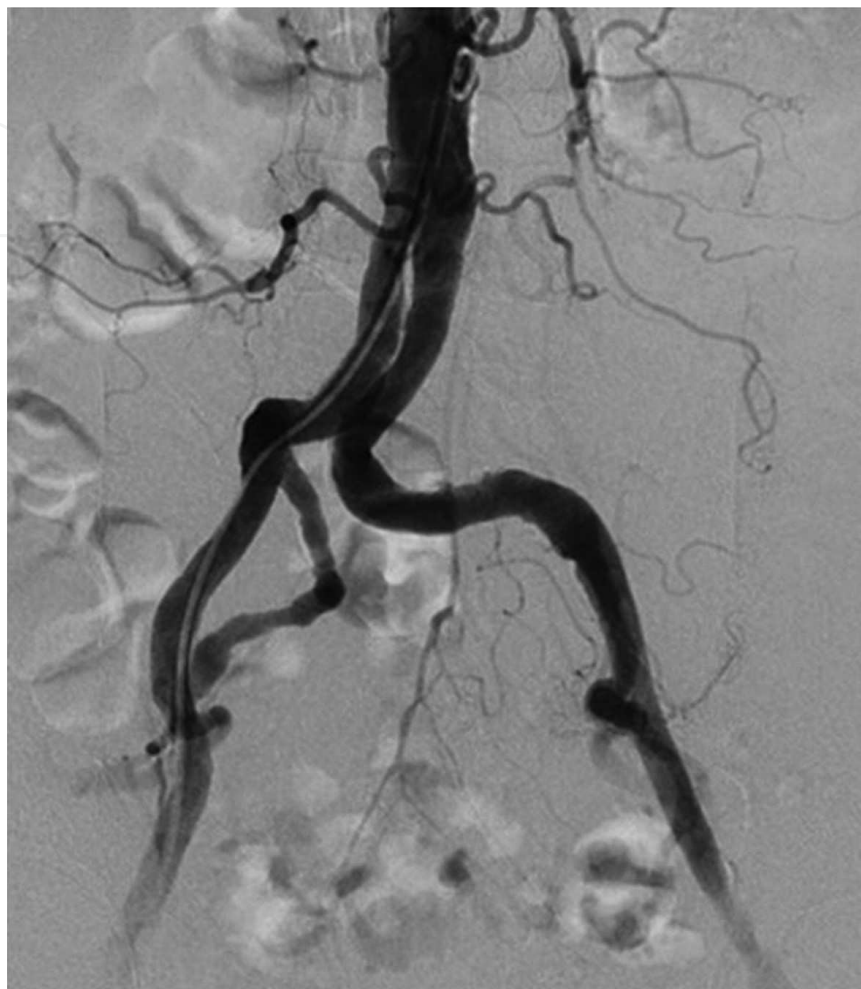

Figure 9. Crossover technique is not indicated in the case of sharp-angled isthmus, poststent graft, or postkissing stent.

3. Aortic stenosis and aortic occlusion

Many studies have demonstrated that endovascular therapy for extensive aortoiliac occlusive disease shows better long-term patency and clinical outcomes [9–11]. The main strategy of endovascular therapy for this field has increasingly shifted to primary stenting [12–14]. Balloon expandable stents, self-expanding stents, or covered stents are basic treatment options. In iliac artery stenting, a self-expandable stent is preferred to a balloon expandable system. The self-expandable stent is compatible with a 6-Fr sheath, and sizes up to 10–12 mm are available. Selection of the stent type may be left to the operator based on lesion location and characteristics. In the treatment of aortic occlusion, catastrophic complications may occur. Operators need to keep in mind the risks of rupture, dissection or emboli to the renal, mesenteric artery or distally to the pelvic arteries, or lower limb arteries. There are

reports that aortic occlusion can be treated with an endovascular technique using the three way access sites including the upper limb or both CFAs [15–18].

Infra-renal aortic stenosis of less than 3 cm and a focal lesion is classified as TASC II B which is considered a good indication for endovascular intervention as first line therapy. Isolated infra-renal aortic stenosis is shown in **Figure 10A**. To clearly visualize and identify aortic stenosis, a lateral view is useful (**Figure 10B**) and measurement of the pressure gradient across the lesion is a factor in making the final decision.

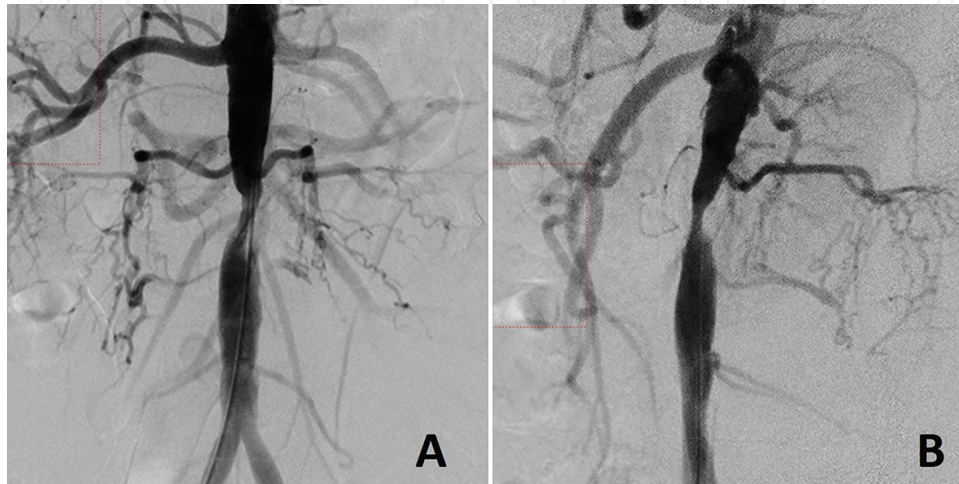


Figure 10. Isolated infra-renal aortic stenosis. (A) DSA image in AP view shows aortic stenosis of less than 3 cm. (B) In lateral view, stenosis is more visible.

Aortic stenosis is mostly treated with a self-expandable stent and postdilatation because of the large vessel size (**Figure 11**).

Aggressive postdilatation is not recommended in order to avoid the above mentioned complications. Even if moderate residual stenosis remains, reducing the pressure gradient across the lesion (<10 mmHg) is acceptable. In the case of aortoiliac occlusion involving bilateral CIAs (**Figure 12A**), upper limb and bilateral CFA access is required. Wiring is performed from the upper limb through a long sheath with simultaneous retrograde angiography from the CFA to guide the direction of the wiring (**Figure 12B**). Kissing stent insertion and kissing ballooning resulted in excellent recanalization on this complex occlusion at the terminal aorta (**Figure 12C and D**). Stenting above the aortic bifurcation combined with the kissing stent technique can be considered an effective alternative option to open surgical reconstruction for extensive aortoiliac occlusive disease.

Complex distal aortic occlusive disease often involves either the CIA or EIA (**Figure 13A**). A retrograde 0.035 wire carefully passed through the bifurcation to the abdominal aorta, and initial stent was placed at the aorta (**Figure 13B**). After the first stenting, the next wire was carefully crossed inside the aortic stent from the other side of the CFA access. After the two wires were crossed inside the aortic stent, a kissing stent technique was performed (**Figure 13C**), and the final angiogram was taken (**Figure 13D**). In this poststenting DSA, care must be taken to check for any perforations or residual thrombi.

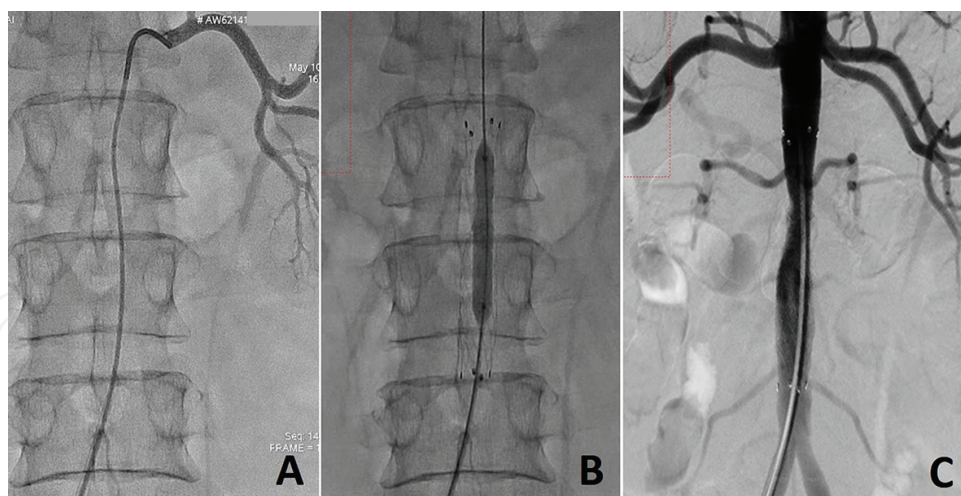


Figure 11. EVT for isolated infra-renal aortic stenosis. (A) Ostium of renal artery is confirmed by selective renal artery angiography. (B) After stenting, postdilatation is performed by lower diameter balloon at relatively lower pressure. (C) Final angiography shows acceptable dilatation of the lesion and no complications.

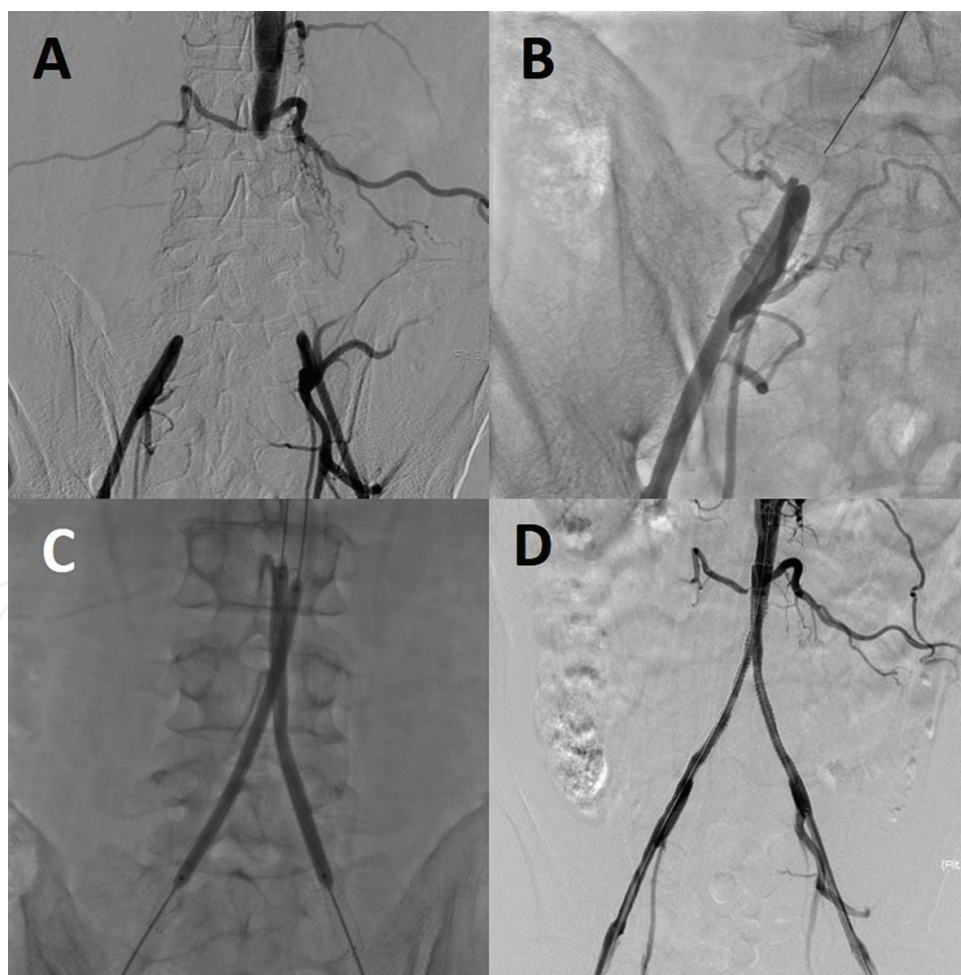


Figure 12. Aortic occlusion involving bilateral CIA. (A) DSA injected from three ways access can clearly visualize total occlusion of aortic bifurcation. (B) Simultaneous retrograde angiography from CFA in order to direct wiring from upper limb. (C) Kissing stent technique and kissing postdilatation are performed from bilateral CFA. (D) Completion of DSA angiography shows excellent recanalization.

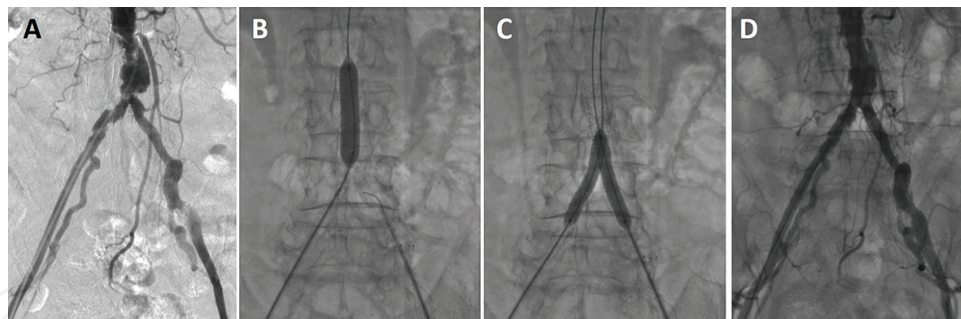


Figure 13. Complex distal aortic occlusive disease involving either CIA or EIA. (A) The 30 cm DSA image shows aortic stenosis extending to both CIAs and the left EIA. (B) Final angiogram is taken in DA, which shows complete recanalization. (C) Initial stent is placed at aorta, and postdilatation at lower pressure was performed. (D) After two wires are carefully crossed inside the initial stent from both CFA sheaths, a kissing stent is implanted.

4. Iliac artery disease: TASC II A-C

Endovascular treatment has become a major part of revascularization of iliac artery occlusive disease [19–21]. Among the various interventional devices, stent is main stay of treatment strategy. From TASCII A to TASCII C, the stent implantation is now the standard technique and shows reasonable good long-term outcome with low reinterventions rate. In TASCII D, the basic strategy is considered to be surgical approach. However, recent development of endovascular technique enabled endovascular first approach, and in experienced hands, fairly high success rate can be achieved.

The iliac stent choice can be largely categorized into choosing either a balloon expandable or self-expanding stent based on lesion characteristics. It depends on introducer size, access site, vessel tortuosity, and lesion location. However, we are using self-expandable stent in every iliac artery lesion. Newer-generation nitinol self-expanding stents exhibit minimal foreshortening and have a more predictable length with 12 mm in size by 6-Fr sheath.

In image size for iliac artery intervention, 20 cm size with DA image is preferred to 30 cm image because position adjustment and determination of stent size or length. In recanalization of aortoiliac occlusive lesion, measurement of pressure gradient across the lesion should be checked pre- and postprocedure. This hemodynamic assessment can be helpful to make the final decision to terminate the procedure even after angiographic moderate stenosis remained [22]. This section shows that typical TASCII A-C iliac artery lesion underwent endovascular therapy.

4.1. TASC II A lesion

Case 1: In **Figure 14A**, a typical lesion of the left CIA is presented. The DSA image (30 cm) of aortography with a 5-Fr pigtail catheter is taken from a 6-Fr sheath placed at the ipsilateral left CFA. Isolated severe stenosis with ulceration of the left CIA can be observed. For intervention of this lesion, a DA image by a contralateral right anterior oblique (RAO) view with a 20 cm image size is employed as the standard method (**Figure 14B**). Compared to a 30 cm image, more precise information on lesion characteristics can be obtained. After diagnostic

angiography, the lesion was crossed by a 0.035-inch wire through a diagnostic pigtail catheter. After visual reference of the bony landmarks on the DA image, a self-expanding stent was implanted followed by postdilatation by balloon (**Figure 14C**). The final angiogram is shown in **Figure 14D**. To avoid vessel rupture and dissection, aggressive postdilatation is not recommended. We usually use a smaller balloon of up to 7 or 8 mm in diameter and inflation with lower pressure. When considering a balloon size of more than 8 mm for postdilatation, careful vessel size assessment is required.

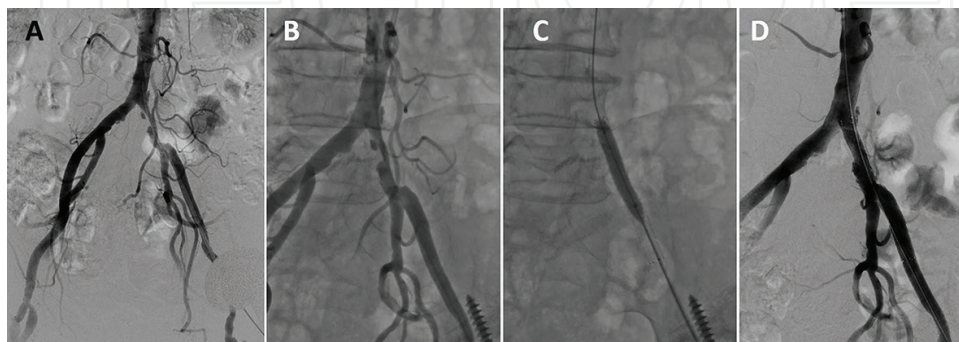


Figure 14. Left CIA stenosis classified as TASCII type A. (A) DSA image in 30 cm size of aortography in AP view shows unilateral left CIA stenosis. (B) DA in larger size (20 cm) and in contralateral oblique (RAO) view more clearly revealed lesion. (C) Stenting and ballooning are performed in reference to visual bony landmark. (D) Final angiogram shows complete recanalization.

Case 2: Aortography of a bilateral short EIA lesion is shown in **Figure 15A**. However, this 30 cm image size and AP projection failed to visualize the precise characteristics of each EIA lesion. The 20 cm size image with contralateral oblique angiography could identify the EIA lesions (**Figure 15B** and **C**). Endovascular intervention was performed by the right CFA approach. First, from the right CFA sheath, a 0.035-inch guidewire was used to cross the right EIA lesion followed by stenting and ballooning. After confirmation of a good expanded stent on the right EIA lesion, a crossover approach was introduced to treat the left EIA lesion. For the left EIA lesion, a RAO view is generally taken. This left lesion was also treated by stenting and ballooning (**Figure 15D** and **E**). These views could clearly visualize the lesion in high tortuosity in the EIA. Generally, a TASC II A lesion is treated from only one access site by employing a crossover approach. The advantage of this technique is that both the right and left lesions can be treated through a single-access site, minimizing access site complications.

4.2. TASC II B lesion

Case 3: EIA stenosis between 3 and 10 cm not extending into the CFA (TASC II B) could be treated by an endovascular technique (**Figure 16A**). In cases of EIA lesions, either an antegrade crossover approach or retrograde sheath approach is taken. Selecting the approach site depends on the distance from the lesion to the CFA and/or configuration of the terminal

aorta when unable to use a crossover technique. When both approaches are not feasible, radial or brachial access is another option. The CFA is a so-called no stenting zone. To avoid CFA stenting, angiography should include the femoral head. Intervention should be performed based on the final control angiogram (**Figure 16B** and **C**). When we see the reference angiogram, the table should not be moved until stent expansion. The antegrade approach allows the stent to be placed more accurately close to the CFA as compared to the retrograde approach.

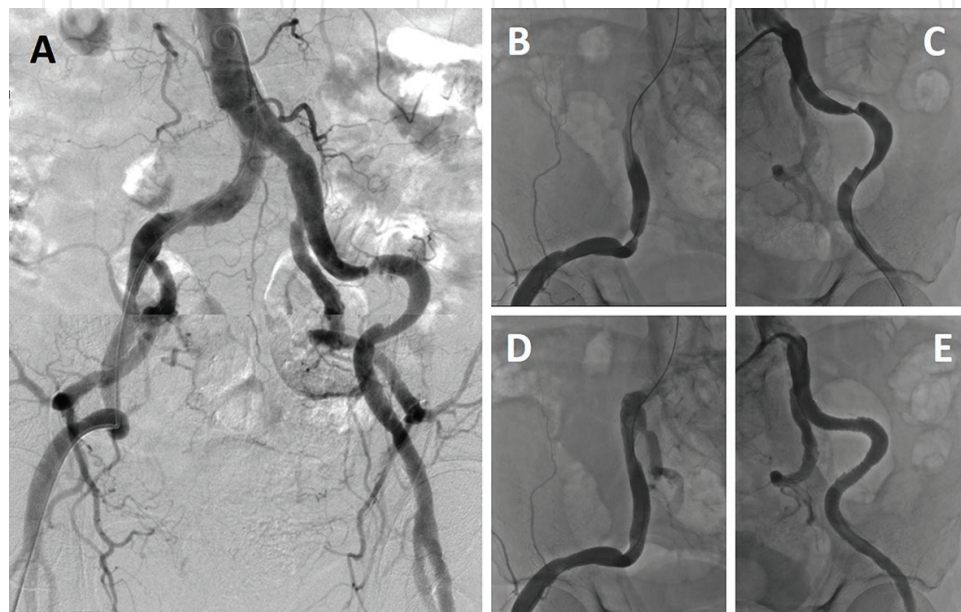


Figure 15. Bilateral short EIA lesion. (A) DSA in AP view could not reveal bilateral EIA stenosis due to severe iliac tortuosity. (B and C) Angiography in deep LAO (B) and RAO (C) can precisely reveal right EIA stenosis and left EIA stenosis, respectively. (D and E) Both lesions can be treated with stent placement using crossover technique from one access site.

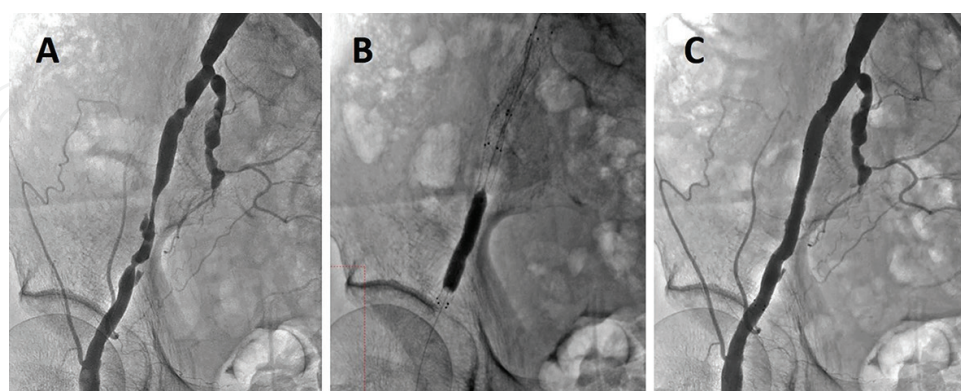


Figure 16. Multiple EIA lesions treated without changing the working view. In the crossover approach from the left CFA, angiography shows multiple stenotic lesions of the right EIA not extending to the right CFA (A). Keeping working view including the femoral head, the stent position is carefully determined so as not to implant in "no stenting zone" (B). Final result also confirmed with this view (C).

Case 4: Unilateral CIA occlusion is classified as TASC II B (**Figure 17A**). This aortography is performed from the left brachial artery and shows occlusion of the left CIA orifice. Seemingly, the total occluded part looks quite long; however, delayed-phase angiography revealed a patent external iliac artery, and only occlusion of the CIA was found (**Figure 17B**). Viewing up to the delayed phase, in particular for total occlusion, is very important to identify the actual occluded segment. The ipsilateral left CFA was punctured by echo guidance, and a 6-Fr sheath was positioned. Angiography by a 20 cm image was performed by simultaneous injection from the terminal aortography with hand injection from the left CFA sheath, more clearly revealing an image of the target lesion (**Figure 17C**). From the left CFA sheath, a 0.035-inch wire with a 5-Fr multipurpose catheter is carefully advanced with the knuckle wire technique (**Figure 17D**). After crossing the CTO lesion, a self-expandable stent was implanted, followed by postdilatation at low pressure with the same size balloon as predilatation. The final angiogram from the terminal aorta shows successful and complete recanalization of the total occlusion of the CIA (**Figure 17E**). Finally, we checked the pressure gradient between the left CFA and aorta. No pressure gradient was found across the stented segments.

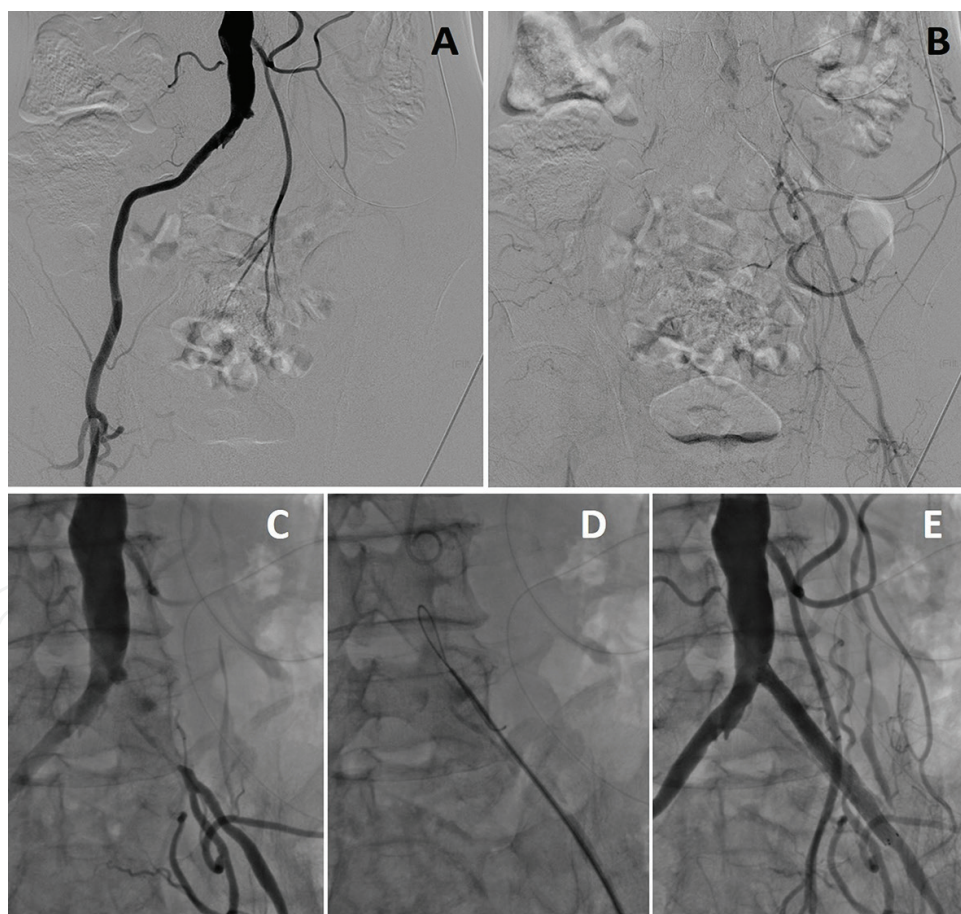


Figure 17. Left CIA occlusion. (A) Unilateral CIA occlusion is clearly found in angiogram from upper limb access. (B) Delayed phase of this angiogram reveals patent EIA supplied from collateral vessels. (C) DA (20 cm) performed by simultaneous injection from terminal aorta, while left CIA sheath reveals more precise lesion characteristics. (D) From left CFA sheath, 0.035-inch wire by knuckle wire technique supported with 5-Fr multipurpose catheter successfully used to pass the lesion. (E) Final angiography from terminal aorta shows successful recanalization.

4.3. TASC II C lesion

Case 5: Long total occlusion of the EIA with CFA involvement is classified as TASC II C which is relatively safe and can be effectively treated with endovascular therapy. For successful recanalization, angiographic work plays a crucial role. The first image to understand is the whole view of both iliac arteries with a 30 cm DSA image (**Figure 18**).

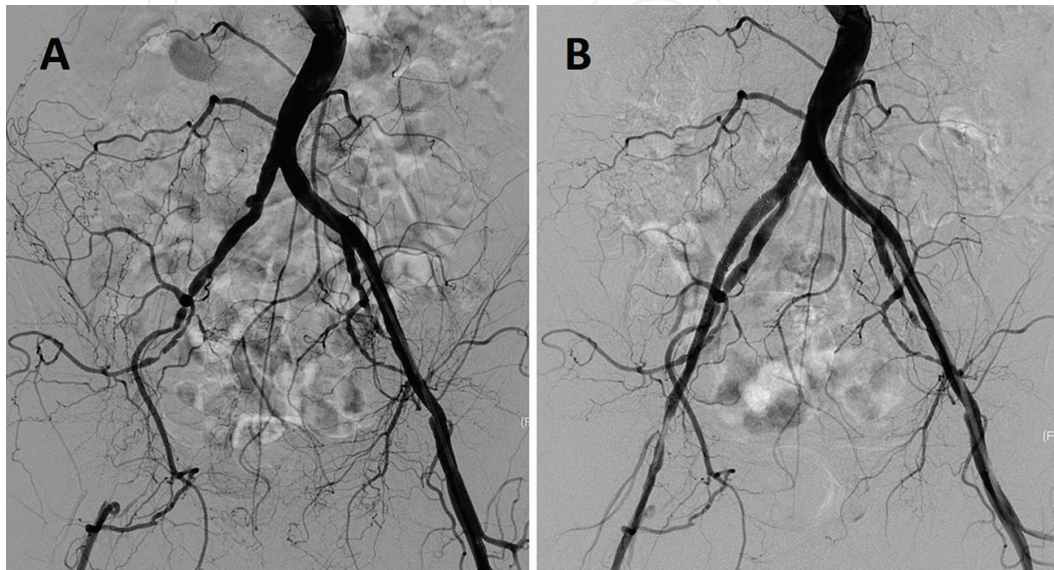


Figure 18. Long total occlusion of right EIA with involvement of CFA. (A) 30 cm DSA shows long EIA occlusion with involvement of CFA. (B) Complete recanalization is shown compared to initial diagnostic angiography.

In the delayed phase, the left CFA is visualized. After confirmation of an occluded EIA, the 20 cm contralateral DA image was positioned for working view. A 20 cm DA image in a contralateral left anterior oblique (LAO) view is actually used for interventions (**Figure 19**).

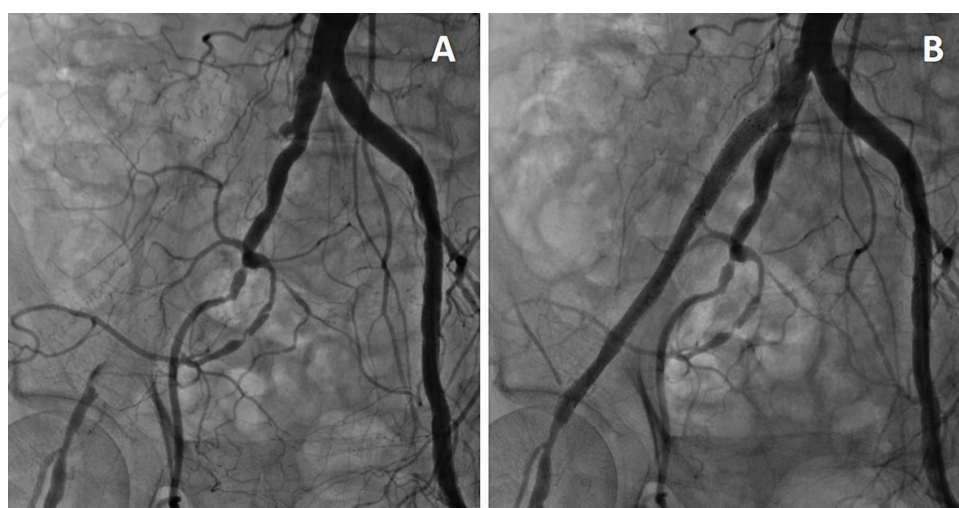


Figure 19. EVT for long total occlusion of right EIA with involvement of CFA. (A) 20 cm DA image in contralateral LAO view is actually used for interventions. (B) Final angiography is taken in working view.

For the bidirectional approach, an ipsilateral CFA puncture is performed under angiographic guidance where the 6-Fr sheath is placed (**Figure 20A**). From the crossover sheath, a 0.035-inch J-tip wire supported with a 5-Fr diagnostic catheter is advanced by antegrade access with the knuckle wire technique through the lesion (**Figure 20B**). Generally speaking, a bidirectional approach has a higher chance of wire crossing than a one way approach. When the antegrade wire fails to cross the lesion, retrograde wiring is the next step. After successfully crossing the occlusion, the wire position should constantly be monitored to see that it is in the distal true lumen. Predilatation should be performed by an undersized balloon, and a self-expandable stent should be placed. Careful attention is necessary to confirm that the distal stent does not extend to the CFA (**Figure 20C**). Adjunctive postdilatation by balloon at lower pressure was performed and the completion of angiography achieved.

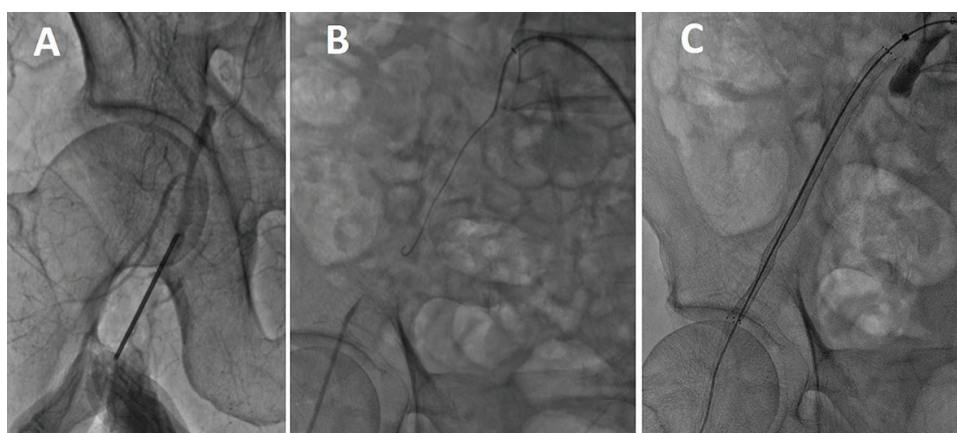


Figure 20. Long total occlusion of right EIA with involvement of CFA. (A) Ipsilateral CFA puncture is performed under angiographic guidance for bidirectional approach. (B) 0.035-inch J-tip wire supported with 5-Fr diagnostic catheter advanced with knuckle wire technique from the crossover sheath. (C) Self-expanded stent is carefully implanted not to cover the CFA.

5. Approach to complex iliac artery disease

Advanced atherosclerotic disease of the iliac artery oftentimes involves an abdominal aortic aneurysm or extensive aortic bifurcation with or without unilateral or bilateral long total occlusions of the iliac artery. Most cases are classified as TASC II D, and in some cases, no TASC classification can be applied. Moreover, patients with these complex iliac artery diseases are commonly not candidates for surgical revascularization due to comorbidities. These patients benefit by an endovascular approach by employing various tools or angiographic techniques. In some medical centers, endovascular therapy for TASC II D is considered to be first line revascularization with safe and effective treatment by experienced interventionists [23–25]. When total occlusion is involved, aortography should be performed up to the delayed phase in which the distal patent flow could be visualized through the collateral flow (**Figure 21**). Additionally, angiography taken from multiple angles is important to navigate the guidewire correctly.

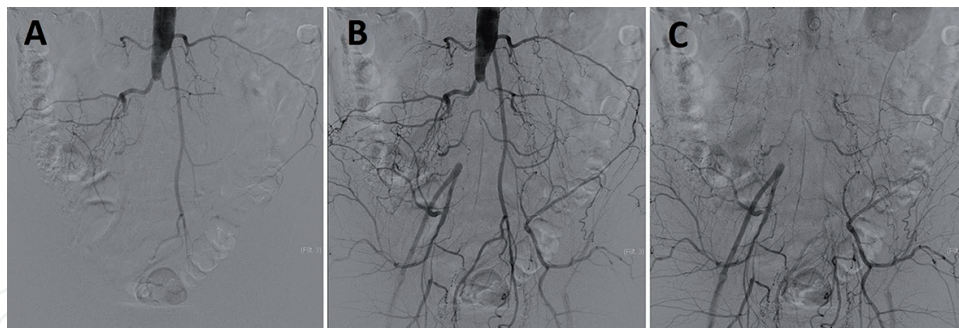


Figure 21. Aortography of aortic occlusion in the early phase (A), middle phase (B), and delayed phase (C), which can visualize distal arterial flow via collateral vessels.

Case 6: This patient has right EIA occlusion and left severe EIA stenosis. Both the right EIA occlusion and left EIA stenosis could be treated with a contralateral crossover technique from left CFA access. Both EIA lesions were successfully treated by only the left anterior oblique (LAO) projection as the working image. First, aortography revealed right EIA total occlusion and left EIA stenosis (**Figure 22A**). In the delayed phase, the right CFA is slightly visible (**Figure 22B**). **Figure 22C** is the angiogram for simultaneous injection from the terminal aorta and right CFA sheath in the LAO projection. In this image, the occluded lesion can be visualized precisely. From the left CFA, a 6-Fr crossover sheath is advanced to the right CIA after a 0.035-inch J-tip Radifocus wire is used to cross the right internal iliac artery. The 0.035-inch J-tip wire with a 4-Fr support catheter could cross the occluded EIA to the right superficial femoral artery (SFA) (**Figure 22D**). Predilatation by a balloon was performed followed by the implantation of a self-expandable stent (**Figure 22E**). Postdilatation was performed by the same balloon and successful recanalization was confirmed by angiography from the crossover sheath. After opening the occluded right EIA, stenting and ballooning were performed for the left EIA stenosis (**Figure 22F**) and the final angiogram showed complete revascularization of both EIA lesions (**Figure 22G**).

Case 7: In **Figure 23A**, aortography shows an infra-renal aortic aneurysm, heavily calcified stenosis of the right CIA, and moderate stenosis of the left CIA. From the right CFA, a 0.035-inch J-tip wire was advanced, however, this wire could not cross the right CIA stenosis and was exchanged to a 0.014-inch wire. This 0.014-inch wire succeeded in crossing the lesion. The 4-Fr diagnostic catheter was gently advanced through the aneurysm, and the 0.014-inch wire was then exchanged to a 0.035-inch spring wire. After predilatation by a balloon at the right CIA, kissing stenting with a self-expandable stent was performed (**Figure 23B** and **C**). The final angiography in 20 cm DSA shows excellent results (**Figure 23D**) and pressures at both CFA sheaths showed equalized systemic arterial pressure.

Case 8: Extensive heavily calcified stenosis from the aortic bifurcation to both iliac arteries is treated by endovascular techniques (**Figure 24**). In a heavily calcified lesion, 3D CTA is not suited for diagnosis of the stenosis (**Figure 24D**).

Compared to angiography, these 3D CTA images are completely different. Patients with heavily calcified lesions are at high risk for open surgical treatment, especially those on

hemodialysis, and endovascular reconstruction is often required. In this case, an upper limb approach is not available due to the AV shunt and left CFA access is unfeasible because of a pulseless or indeterminable blood flow by ultrasound. Viewing the angiography from the right CFA sheath, left CFA access could be obtained. Wire crossing by a retrograde approach from the right CFA sheath was successful but failed from the left side due to heavily calcified stenosis of the left CIA (**Figure 25A**). Using a snare device to pull the wire into the left sheath, a microcatheter was advanced to the abdominal aorta (**Figure 25B**). Kissing stenting and mild postdilatation was performed, and an adjunctive overlap stent in both iliac arteries was placed (**Figure 25C and D**). Successful recanalization is confirmed in **Figure 25E**.

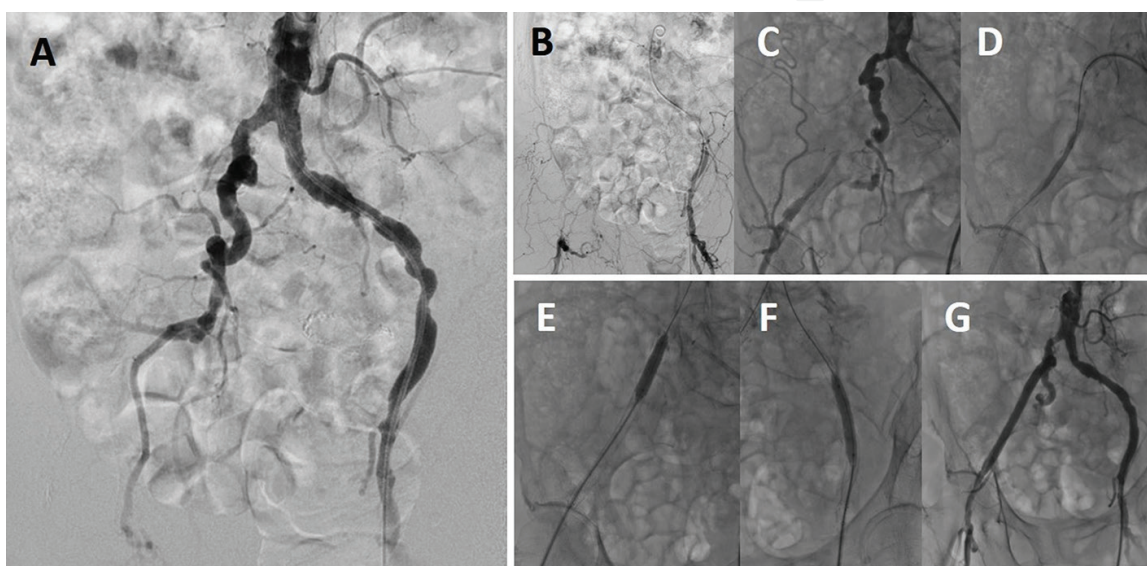


Figure 22. Right EIA occlusion with diffuse stenosis from right CIA to EIA. (A) Initial diagnostic DSA reveals right EIA total occlusion and multiple stenosis from left CIA to EIA. (B) In delayed phase, right CFA is slightly visible. (C) Simultaneous angiography from terminal aorta and right CFA sheath in deeper LAO view used for intervention, clearly revealing lesion morphology. (D) 0.018-inch wire with 4-Fr support catheter could cross the occluded EIA. (E) Stenting for distal EIA is performed from crossover sheath and, for proximal CIA, stenting is performed from retrograde ipsilateral CFA sheath. (F) After treatment for right iliac lesion, left side lesions are treated with stenting and ballooning. (G) Final angiogram shows complete revascularization of both CIA and EIA.

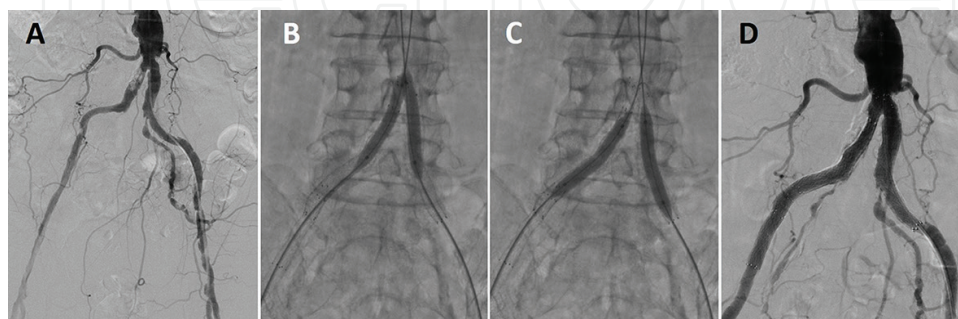


Figure 23. CIA stenosis with severe calcification and abdominal aortic aneurysm. (A) Aortography shows infra-renal aortic aneurysm, heavily calcified stenosis of right CIA, and moderate stenosis of left CIA. (B and C) Kissing stenting at aortic bifurcation (B) and postdilatation of both CIA (C) are carefully performed due to heavily calcified lesion. (D) Final angiography taken in DSA and 20 cm image shows good expansion and no complications such as rupture, dissection, or embolism.

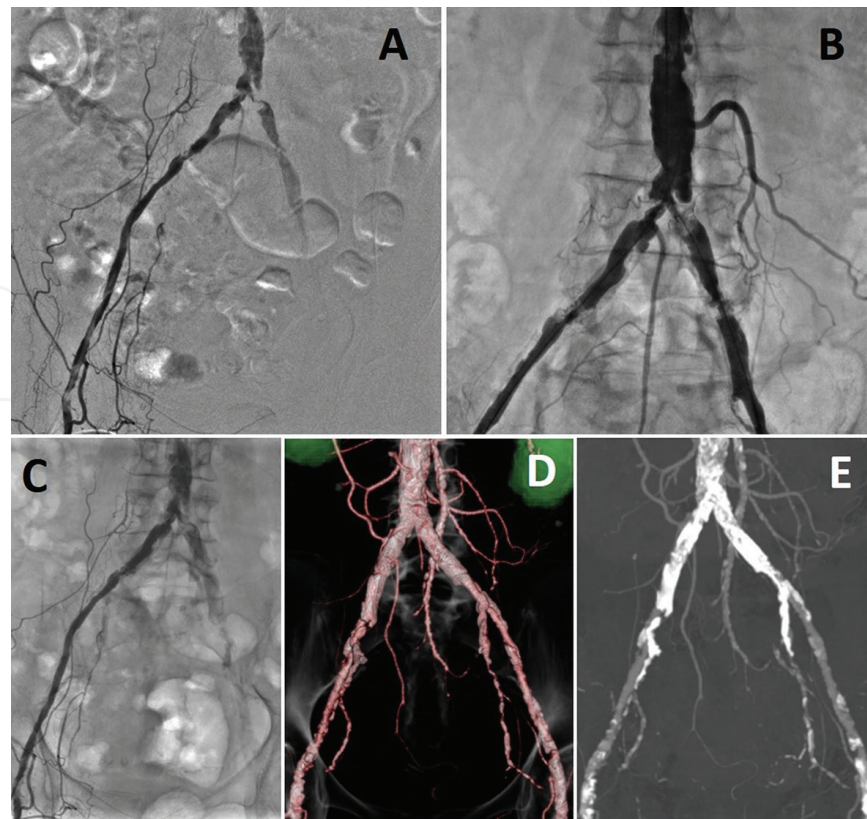


Figure 24. Heavily calcified aortic bifurcation disease involving orifices of bilateral CIA. (A) Extensive heavily calcified stenosis from aortic bifurcation to both CIAs is shown in 30 cm DSA. (B) More precise information of lesion can be obtained from 20 cm DA. (C–E) In case with severe calcification, CT angiogram is not suited as diagnostic or assessment tool since details of intravascular conditions due to calcification not visualized.

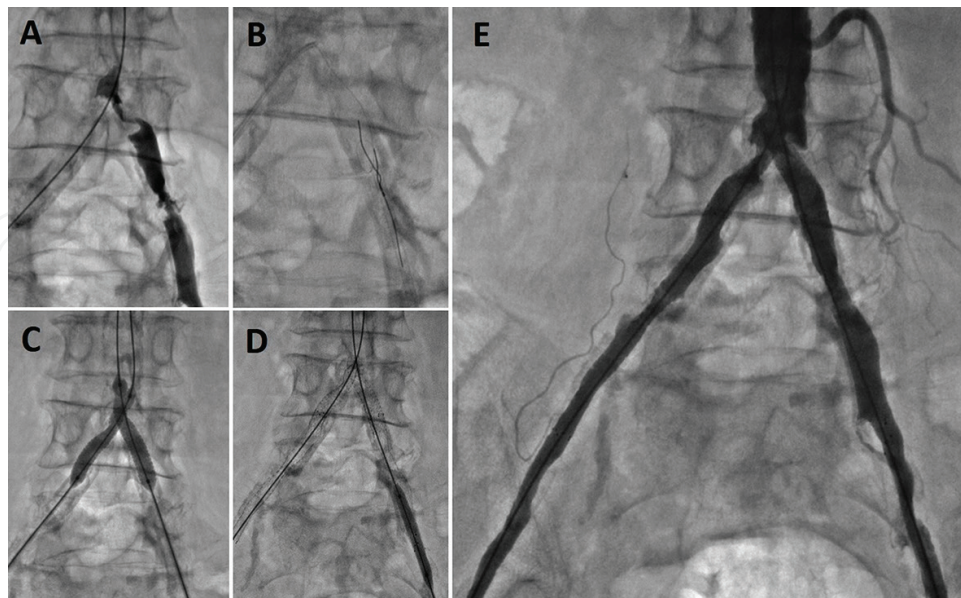


Figure 25. Heavily calcified aortic bifurcation disease involving orifices of bilateral CIA. (A) Wire crossing by retrograde from right CFA sheath is successful but due to heavily calcified stenosis of left CIA, unable to cross the wire. (B) Snare device pulls the wire from right iliac artery into the left CFA sheath. (C) Kissing stenting and mild postdilatation are performed at aortic bifurcation. (D) Adjunctive overlapping stents placed in both iliac arteries. (E) Successful recanalization is clearly visualized in final angiography.

6. Complications related to aortoiliac artery intervention

Complications in iliac artery intervention, especially bleeding due to perforation, are the most serious. Iliac artery perforation immediately causes hemorrhagic shock which may result in cardiac arrest. The iliac artery runs in the posterior abdominal cavity, and therefore, bleeding cannot be controlled with manual compression to establish hemostasis. Too much time is required to convert to open surgical repair so this is not a practical solution. Immediate endovascular repair should be attempted, and a covered stent should be positioned at the perforation site [26].

Wire perforation of the EIA is shown in **Figure 26A**. From another angle, the perforation site could not be detected (**Figure 26B**). Extravasation is clearly visualized in DSA. When suspecting perforation, DSA should be taken in several projections. The covered stent should be prepared at the same time as balloon inflation is being carried out to minimize bleeding (**Figure 26C**). After implantation of the covered stent, extravasation is not seen and complete shielding has succeeded (**Figure 26D**). To repair a perforation, aneurysm, or the other vessel injury, the covered stent is the most useful device and should be prepared along with the appropriate catheter.

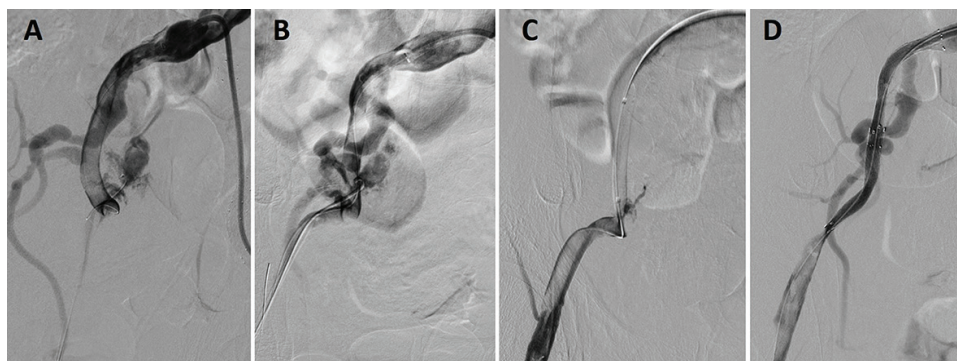


Figure 26. Wire perforation and extravasation. (A) Wire perforation of EIA is clearly detected in DSA. (B) In another angle view, perforation site could not be detected. (C) Balloon inflation can minimize bleeding. (D) After implantation of covered stent, extravasation is not seen in DSA.

Dissection caused by intervention may cause acute occlusion or stop the flow to the distal vessel. In **Figure 27A**, the large dissection is caused by sheath placement due to a tortuous external iliac artery. This dissection was successfully wired to the true lumen and treated by self-expandable stent placement (**Figure 27B**). The dissection could be commonly repaired by a self-expandable stent to support the dissected flap to the vessel wall. After crossing the true lumen, we preferred a 0.014-inch wire since it is more atraumatic compared to a 0.035-inch wire.

In dealing with an aortoiliac artery bifurcation lesion with either ballooning or stenting, the potential complication is plaque shift. Therefore, a kissing stent or balloon technique has been widely employed. **Figure 28A** and **B** is typical images of plaque shift at the aortoiliac bifurcation. A large plaque shifted to the contralateral iliac artery where acute occlusion may cause acute limb ischemia on the contralateral limb. Therefore, precise information on the aortoiliac bifurcation lesion is essential, especially on the inward position of the plaque and/or large plaque burden by various different angled views before interventions.

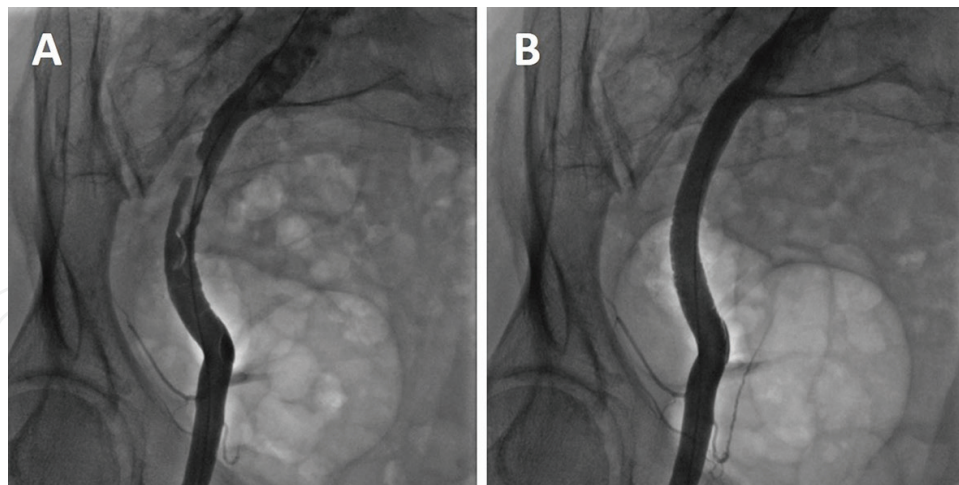


Figure 27. The large dissection caused by sheath. (A) Large dissection by sheath with flap is found in DA. (B) Complete repair is achieved with stent implantation.

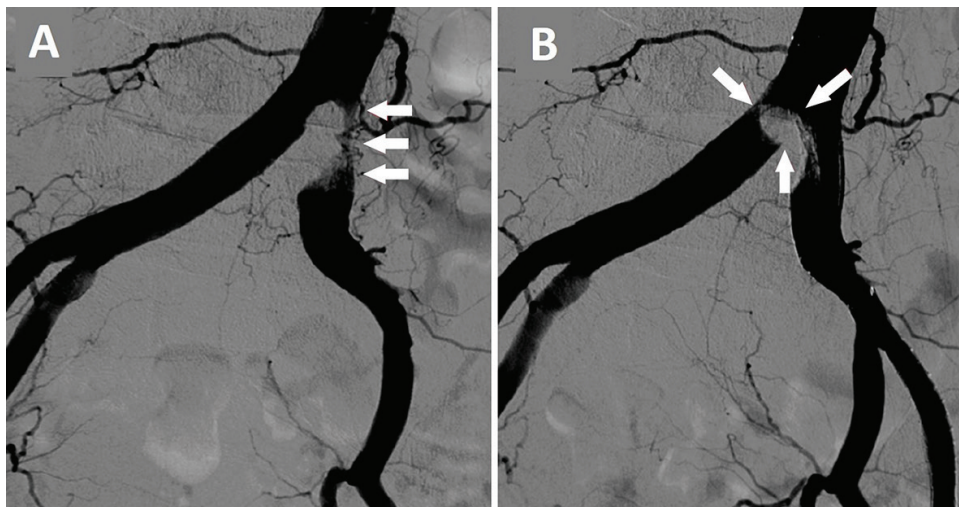


Figure 28. Unfavorable plaque shift. Right CIA stenosis with large burden of plaque (A; white arrow) is shifted to contralateral left CIA (B; white arrow) after ballooning (Special Courtesy by Dr. Yoshito Kadoya).

Recently, transcatheter aortic valve replacement (TAVR) has emerged as a promising procedure, and a transfemoral approach is the standard technique. However, vascular complications, in particular iliac artery injury, are the major clinical problem [27]. A large profile sheath in TAVR often injures the iliac artery. The DSA image clearly visualizes the injured EIA (**Figure 29A**). This complication can immediately cause catastrophic bleeding and shock. In this case, a 0.035-inch wire is carefully advanced from the ipsilateral CFA sheath for TAVR and successfully used to cross the ruptured site of the EIA followed by deployment of a covered stent (**Figure 29B**). Complete and successful repair could be achieved. The final angiogram by DSA showed no extravasation and established a TIMI 3 flow (**Figure 29C**).

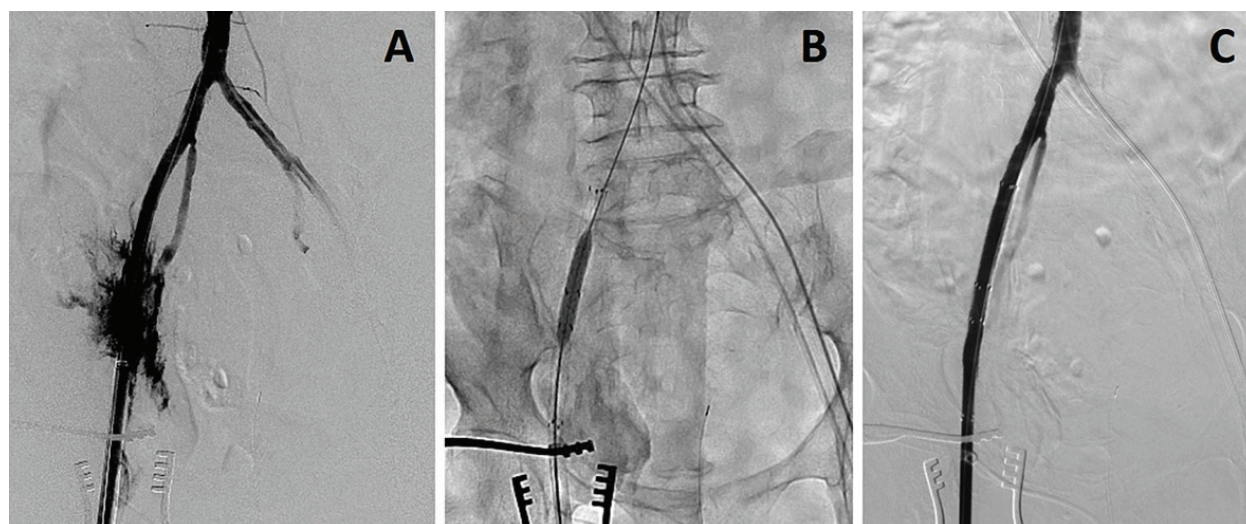


Figure 29. Ruptured EIA in TAVR. (A) DSA image can clearly visualize the ruptured EIA caused by large profile sheath for TAVR. (B) 0.035-inch wire was carefully advanced from ipsilateral sheath for TAVR and successfully crossed the ruptured site of EIA followed by deployment covered stent. (C) Successful endovascular repair is completely achieved. The final angiogram by DSA showed no extravasation and established TIMI 3 flow.

7. Conclusion

No randomized controlled trials (RCTs) have definitively established the magnitude and durability of the benefit of open surgical vs endovascular strategies. However, there has been an increase in the adoption of the endovascular first strategy for even the most complex anatomies up to TASC II D in clinical practice. In aortoiliac artery disease, a 12-month primary patency for TASC D lesions treated with stents was considered to be fairly high. Therefore, the trend for the “endovascular first” approach will not change in addition to patient preference. And more complex TASC C-D aortoiliac lesions will be treated by stent. To succeed in treating complex lesions, careful angiographic assessment is of vital importance and unless a clear image of the lesion is not obtained, complex aortoiliac artery lesions cannot be revascularized, resulting in high complication rates.

Author details

Keisuke Fukuda

Address all correspondence to: fukudateam54@gmail.com

Kishiwada Tokushukai Hospital, Osaka, Japan

References

- [1] Aboyans V, Desormais I, Lacroix P, Salazar J, Criqui MH, Laskar M. The general prognosis of patients with peripheral arterial disease differs according to the disease localization. *J Am Coll Cardiol.* 2010;55:898–903.

- [2] Kashyap VS, Pavkov ML, Bena JF, et al. The management of severe aortoiliac occlusive disease: endovascular therapy rivals open reconstruction. *J Vasc Surg.* 2008;48:1451–1457, 1457.e1–e3.
- [3] Indes JE, Mandawat A, Tuggle CT, Muhs B, Sosa JA. Endovascular procedures for aorto-iliac occlusive disease are associated with superior short-term clinical and economic outcomes compared with open surgery in the inpatient population. *J Vasc Surg.* 2010;52:1173–1179.
- [4] Norgren L, Hiatt WR, Dormandy JA, Nehler MR, Harris KA, Fowkes FG; TASC II Working Group. Inter-Society Consensus for the Management of Peripheral Arterial Disease (TASC II). *J Vasc Surg.* 2007;45 Suppl S:S5–67
- [5] Staniloae CS, Korabathina R, Coppola JT. Transradial access for peripheral vascular interventions. *Catheter Cardiovasc Interv.* 2013;81(7):1194–203
- [6] Stavroulakis K, Usai MV, Torsello G, Schwindt A, Stachmann A, Beropoulos E, Bisdas T. Efficacy and safety of transbrachial access for iliac endovascular interventions. *J Endovasc Ther.* 2016;23(3):454–60
- [7] Millon A, Della Schiava N, Brizzi V, Arsicot M, Boudjelit T, Herail J, Feugier P, Lermusiaux P. The antegrade approach using transbrachial access improves technical success rate of endovascular recanalization of TASC C-D aortoiliac occlusion in case of failed femoral access. *Ann Vasc Surg.* 2015;29(7):1346–52
- [8] Grenon SM1, Reilly LM, Ramaiah VG. Technical endovascular highlights for crossing the difficult aortic bifurcation. *J Vasc Surg.* 2011;54(3):893–6.
- [9] Jongkind V1, Akkersdijk GJ, Yeung KK, Wisselink W. A systematic review of endovascular treatment of extensive aortoiliac occlusive disease. *J Vasc Surg.* 2010;52(5):1376–83.
- [10] Leville CD1, Kashyap VS, Clair DG, Bena JF, Lyden SP, Greenberg RK, O'Hara PJ, Sarac TP, Ouriel K. Endovascular management of iliac artery occlusions: extending treatment to TransAtlantic Inter-Society Consensus class C and D patients. *J Vasc Surg.* 2006;43(1):32–9.
- [11] Sixt S1, Krankenberg H, Möhrle C, Kaspar M, Tübler T, Rastan A, Brechtel K, Macharzina R, Neumann FJ, Zeller T. Endovascular treatment for extensive aortoiliac artery reconstruction: a single-center experience based on 1712 interventions. *J Endovasc Ther.* 2013;20(1):64–73
- [12] Haulon S, Mounier-Véhier C, Gaxotte V, Koussa M, Lions C, Haouari BA, Beregi JP. Percutaneous reconstruction of the aortoiliac bifurcation with the “kissing stents” technique: long-term follow-up in 106 patients. *J Endovasc Ther.* 2002;9(3):363–8.
- [13] Simons PC, Nawijn AA, Bruijninx CM, Knippenberg B, de Vries EH, van Overhagen H. Long-term results of primary stent placement to treat infrarenal aortic stenosis. *Eur J Vasc Endovasc Surg.* 2006;(6):627–33.
- [14] Klonaris C, Katsargyris A, Tsekouras N, Alexandrou A, Giannopoulos A, Bastounis E. Primary stenting for aortic lesions: from single stenoses to total aortoiliac occlusions. *J Vasc Surg.* 2008;47(2):310–7.

- [15] Ivarez-Tostado JA, Clair DG, Greenberg RK, Lyden SP, Srivastava SD, Eagleton M, Sarac TS, Kashyap VS, Moise MA. Endovascular management of chronic infrarenal aortic occlusion. *J Endovasc Ther.* 2009;16(1):84–928.
- [16] Kim TH, Ko YG, Kim U, Kim JS, Choi D, Hong MK, Jang Y, Shim WH. Outcomes of endovascular treatment of chronic total occlusion of the infrarenal aorta. *J Vasc Surg.* 2011;53(6):1542–9.
- [17] Lun Y, Zhang J, Wu X, Gang Q, Shen S, Jiang H, Duan Z, Xin S. Comparison of midterm outcomes between surgical treatment and endovascular reconstruction for chronic infra-renal aortoiliac occlusion. *J Vasc Interv Radiol.* 2015;26(2):196–204.
- [18] Setacci C, Galzerano G, Setacci F, De Donato G, Sirignano P, Kamargianni V, Cannizzaro A, Cappelli A. Endovascular approach to Leriche syndrome. *J Cardiovasc Surg (Torino).* 2012;53(3):301–6.
- [19] Aihara H, Soga Y, Iida O, Suzuki K, Tazaki J, Shintani Y, Miyashita Y; REAL-AI Registry Investigators. Long-term outcomes of endovascular therapy for aortoiliac bifurcation lesions in the real-AI registry. *J Endovasc Ther.* 2014;21(1):25–33.
- [20] Kasemi H, Marino M, Dionisi CP, Di Angelo CL, Fadda GF. Seven-year approach evolution of the aortoiliac occlusive disease endovascular treatment. *Ann Vasc Surg.* 2016;30:277–85.
- [21] Rossi M, Iezzi R. Cardiovascular and Interventional Radiological Society of Europe guidelines on endovascular treatment in aortoiliac arterial disease. *Cardiovasc Intervent Radiol.* 2014;37(1):13–25.
- [22] Udoff EJ, Barth KH, Harrington DP, Kaufman SL, White RI. Hemodynamic significance of iliac artery stenosis: pressure measurements during angiography. *Radiology.* 1979;132(2):289–93.
- [23] Ye W, Liu CW, Ricco JB, Mani K, Zeng R, Jiang J. Early and late outcomes of percutaneous treatment of TransAtlantic Inter-Society Consensus class C and D aorto-iliac lesions. *J Vasc Surg.* 2011;53(6):1728–37.
- [24] Wressnegger A, Kinstner C, Funovics M. Treatment of the aorto-iliac segment in complex lower extremity arterial occlusive disease. *J Cardiovasc Surg (Torino).* 2015;56(1):73–9.
- [25] Klein AJ, Feldman DN, Aronow HD, Gray BH, Gupta K, Gigliotti OS, Jaff MR, Bersin RM, White CJ; Peripheral vascular disease committee for the society for cardiovascular angiography and interventions. SCAI expert consensus statement for aorto-iliac arterial intervention appropriate use. *Catheter Cardiovasc Interv.* 2014;84(4):520–8.
- [26] Kufner S, Cassese S, Groha P, Byrne RA, Schunkert H, Kastrati A, Ott I, Fusaro M. Covered stents for endovascular repair of iatrogenic injuries of iliac and femoral arteries. *Cardiovasc Revasc Med.* 2015;16(3):156–62.
- [27] Toggweiler S, Leipsic J, Binder RK, Freeman M, Barbanti M, Heijmen RH, Wood DA, Webb JG. Management of vascular access in transcatheter aortic valve replacement: part 2: vascular complications. *JACC Cardiovasc Interv.* 2013;6(8):767–76.