

We are IntechOpen, the world's leading publisher of Open Access books Built by scientists, for scientists

6,900

Open access books available

186,000

International authors and editors

200M

Downloads

Our authors are among the

154

Countries delivered to

TOP 1%

most cited scientists

12.2%

Contributors from top 500 universities



WEB OF SCIENCE™

Selection of our books indexed in the Book Citation Index
in Web of Science™ Core Collection (BKCI)

Interested in publishing with us?
Contact book.department@intechopen.com

Numbers displayed above are based on latest data collected.
For more information visit www.intechopen.com



Anatomy and Physiology of Hair

Bilgen Erdoğan

Additional information is available at the end of the chapter

<http://dx.doi.org/10.5772/67269>

Abstract

Hair is one of the characteristic features of mammals and has various functions such as protection against external factors; producing sebum, apocrine sweat and pheromones; impact on social and sexual interactions; thermoregulation and being a resource for stem cells. Hair is a derivative of the epidermis and consists of two distinct parts: the follicle and the hair shaft. The follicle is the essential unit for the generation of hair. The hair shaft consists of a cortex and cuticle cells, and a medulla for some types of hairs. Hair follicle has a continuous growth and rest sequence named hair cycle. The duration of growth and rest cycles is coordinated by many endocrine, vascular and neural stimuli and depends not only on localization of the hair but also on various factors, like age and nutritional habits. Distinctive anatomy and physiology of hair follicle are presented in this chapter. Extensive knowledge on anatomical and physiological aspects of hair can contribute to understand and heal different hair disorders.

Keywords: hair, follicle, anatomy, physiology, shaft

1. Introduction

The hair follicle is one of the characteristic features of mammals serves as a unique miniorgan (**Figure 1**). In humans, hair has various functions such as protection against external factors, sebum, apocrine sweat and pheromones production and thermoregulation. The hair also plays important roles for the individual's social and sexual interaction [1, 2].

The hair follicle serves as a reservoir for epithelial and melanocyte stem cells and it is capable of being one of the few immune privileged sites of human body. Hair follicle development is related to the interactions between epithelial and mesenchymal cells. Many genes play substantial role in this interaction and also in hair follicle cycling [3–5].

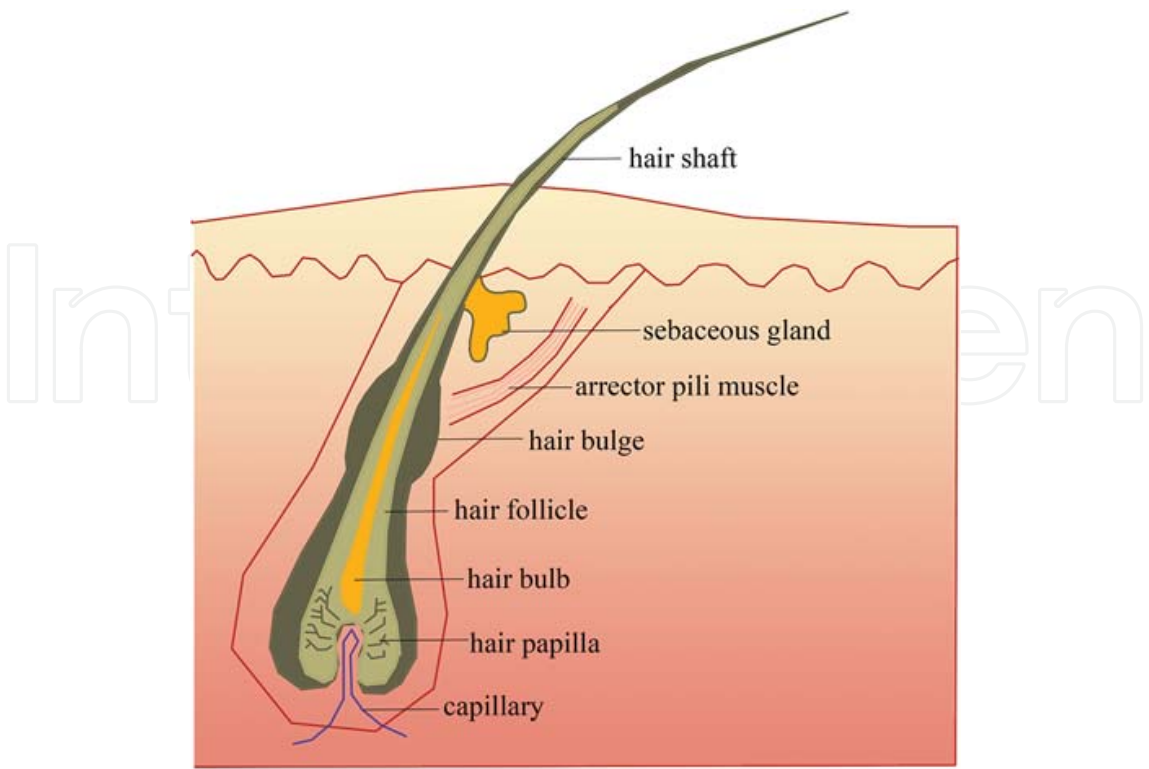


Figure 1. Diagram of an anagen follicle.

The aim of this chapter is to enhance the knowledge of the complex anatomy and physiology of the hair in a simple manner (**Table 1**) [2, 5].

Anagen	Growth stage of hair follicle cycle
Catagen	Regression and involution stage of hair follicle cycle
Telogen	Resting stage of hair follicle cycle
Exogen	Active hair shaft shedding stage of hair follicle cycle
Kenogen	Telogen follicle without club hair form
Club hair	Fully keratinized, dead hair formed at telogen stage
Lanugo hair	Fine hairs on the fetus body; shed in utero or within the first weeks after birth
Vellus hair	Non-pigmented, and generally non-medullated; short hairs
Terminal hairs	Large and pigmented hairs
Hair matrix	Consists of rapidly proliferating keratinocytes that move upwards to produce the hair shaft
Follicular dermal papilla (DP)	Onion-shaped portion of hair bulb surrounded by hair matrix cells, consists of mesenchymally derived tissues
Hair bulb	Lowermost portion of the hair follicle, includes the follicular dermal papilla and the hair matrix
Isthmus	The lower portion of the upper part of hair follicle between the opening of the sebaceous gland and the insertion of arrector pili muscle

Infundibulum	Uppermost portion of the hair follicle extending from the opening of the sebaceous gland to the surface of the skin
Bulge	Segment of the outer root sheath located at insertion of arrector pili muscle
Inner root sheath (IRS)	Guides the hair shaft and helps to take a shape; coats the hair shaft up to the isthmus level
Outer root sheath (ORS)	Extends along from the hair bulb to the infundibulum and epidermis serves as a reservoir of stem cells
Connective tissue sheath (CTS)	Significant mesenchymal follicular layer that adheres to the basement membrane of the hair follicle and interacts with the follicular dermal papilla

*Data from Refs. [2, 5].

Table 1. Glossary of terms for hair anatomy and physiology.

2. Hair and follicle morphology

In utero, type and distribution of each hair follicle over the entire body are determined. The genes that are expressed before the signs of hair follicle formation constitute the precise spacing and distribution of the follicles. The protein products of these genes are presented during the different phases of hair cycle, indicating that they are so important for the normal development and distribution of follicles as well as for the ongoing growth process [4, 5].

The initial “message” for the development of all types of skin appendages is from the dermal mesenchyme (stage 0) and hair follicle development begins with the accumulation of epithelial cells to form epithelial placode after the initial mesenchymal signals (stage 1). Thereafter, the epithelial placode expands and generates the primary hair germ (stage 2). The second signal arises from epithelial placode and constitutes a cluster of adjacent mesenchymal cells which later develops the dermal papilla (DP). The ultimate signal from this primitive dermal papilla to the epithelial placode cells indicates a rapid proliferation and differentiation. This consecutive signaling process finally leads to the production of the mature follicle.

In the second stage of development, hair germ elongates into a cord of epithelial cells and forms the hair peg (stages 3 and 4). It is surrounded by mesenchymal cells that eventually transformed to the fibrous sheath. Derived from the epithelial cells of the hair peg, hair matrix cells form the hair shaft and inner root sheath (IRS). Outer root sheath (ORS) generates two bulges along the side of the hair follicle, the proximal bulge serves as a reservoir for epithelial stem cells and the distal bulge evolves to sebaceous glands. During the development of bullous peg (stages 5–8), the hair bulb and the main cell layers of the mature hair follicle are also formed [2–4, 6].

Several molecular pathways, growth factors, proteins and genes play substantial roles for the development of the hair follicle. Canonical (β -catenin dependent) WNT (wingless-type integration site) signals are candidates for the initial dermal message, and it is believed that they precede other activators and regulators of appendage development. β -Catenin is the downstream mediator of WTN signaling. Activation of this β -catenin pathway seems to be essential for the epithelial ability of the hair follicle production [7].

Ectodysplasin (EDA) and its receptor (EDAR) are another important pathways involved in the placode stage of hair morphogenesis. The mouse EDAR mRNA is expressed in the epithelium before placode formation, and then becomes restricted to placodes, whereas the EDA mRNA is still expressed even after placode formation [3, 6, 8]. In the placode stage, activated WNT and EDAR control the localized accumulation of sonic hedgehog (SHH), which is essential for the downgrowth of the hair germ [2]. In contrast to EDA and EDAR, members of the bone morphogenic protein (BMP) family of secreted signaling molecules seem to be inhibitors of placode formation. The antagonist named Noggin neutralizes BMP activity via regulation of lymphoid enhancer factor 1 (LEF1) expression [4]. EDAR is necessary for placode development in primary hair follicles but not for induction of secondary hair follicles, which utilize signaling pathways that involve Noggin and SRY-box 18 (SOX18) expression within the dermal papilla [9, 10].

In summary, the formation of placodes in response to the first dermal signal involves activation of EDA/EDAR signaling in the epithelium, followed by epithelial WNT signaling, and subsequent activation of BMP signaling. The actions of EDA/EDAR and WNT promote placode formation, whereas BMP signaling represses placode fate in adjacent skin [6].

Human hair follicle morphogenesis occurs only once. Lanugo, vellus and terminal hairs follow the same basic architectural principles. The first “coat” that is formed is fine, long, variably pigmented lanugo hair, which is shed in an anterior to posterior wave during last trimester of gestation. A second coat of fine, shorter, unpigmented lanugo hair then grows in all areas except the scalp and is shed 3–4 months after birth. After these first two cycles, hair starts to grow in an asynchronous “mosaic” pattern rather than in waves [2].

3. Hair anatomy

3.1. Classification of the hair

Nearly whole body surface is coated with the hairs except a few areas like palms, soles and mucosal regions of lips and external genitalia. Most of these are tiny, colorless vellus hairs. The ones located in several areas like scalp, eyebrows and eyelashes are thicker, longer and pigmented and are called terminal hairs. Humans have approximately 5 million hair follicles and 100,000 of them are located on the scalp [11] (**Table 2**) [2].

Basically terminal hairs are found on scalp, eyebrows and eyelashes at birth while the rest of the body is covered with vellus hairs. In puberty, some vellus hairs (i.e. beard, trunk, axilla and genital area) by the influence of androgens differentiate to terminal hairs, which are long (>2 cm), thick (>60 μm), pigmented and medullated. The bulb of the terminal hairs is located in the subcutaneous fat; however, the bulb of vellus hairs is in the reticular dermis. Vellus hairs are thin (<30 μm), short (<2 mm) and mostly nonmedullated.

The hair is classified into three main ethnic subgroups (Asian, African and European). However in a recent study, this classification is expanded to eight main subgroups by considering three parameters: curve diameter, curl index and number of waves [12].

Total count	Almost 5,000,000
Scalp hair count	80,000–150,000
Hair cycle ratios of scalp hair	Anagen: 85–90% Catagen: 1% Telogen: 10–15%
Duration of hair cycle phase	Anagen: 2–6 years Catagen: 2–3 weeks Telogen: 3 months
Physiologic hair shedding rate (scalp)	~100–200/day
Hair shaft production rate (scalp)	~0.35 mm/day, 1 cm/month
Hair shaft diameter and length	Vellus: 0.06 mm; 1–2 mm Terminal: >0.06 mm; 1–50 cm
Hair patterns	Scalp hair Pubic and axillary hair Phalangeal hair
Hair shaft pigmentation	Dark hair: predominance of eumelanin Blond/red hair: predominance of pheomelanin

*Data from Ref. [2].

Table 2. Basic data of human hair follicles.

Structural features of the hair follicle have to be considered during the classification process. Hair shaft diameters, hair follicle density and follicular infundibulum volume are some of them. Hair shaft diameters represent little variations and hairs are found to be thicker in androgen dependent areas. Hair follicle density is much more condense in the forehead and follicular infundibular volume is also bigger. It is important just because of the large follicular infundibular volume that is associated with more follicular reservoir ability [1, 13].

3.2. Structure of the hair

Hair is consisted of two distinct structures: follicle—the living part located under the skin and hair shaft—fully keratinized nonliving part above the skin surface. The arrector pili muscle, takes place between the hair bulge area and dermoepidermal junction. Above the insertion of the arrector pili muscle, sebaceous glands and, in some certain regions, apocrine glands are opened into the follicle.

Hair shaft is consisted of three layers: cuticle, cortex and in certain cases medulla. Flat and square-shaped cuticle cells are adhered tightly to the cortex cells proximally. Peripheric movements of cuticle cells make the direction of the distal free edge upward and cause extensive overlapping. These imbrications are crucial. By interlocking with the cuticle cells of inner root sheath, they contribute to the follicular anchorage of the growing hair. These

imbricated surfaces also facilitate removal of dirt and desquamated cells from the scalp. Cuticle has also important protective properties and barrier functions against physical and chemical insults [14–16].

During the migration of the cells from the hair bulb to compose the cortex, the shapes of them become more fusiform. These cells coalesce tightly and are placed parallel to the axis of the shaft. Axial keratin filaments (microfibrils) that are formed from multiple hard α -keratin intermediate filaments (α -KIF) molecules, packs each cortex cells. Several microfibrils come together to form larger units called macrofibril which represents almost 50% of the cortex material. The cortex comprises the bulk of the shaft and also contains melanin [2, 15, 16]

Medulla is located in the center of the hair shaft preferably presented in coarser fibers. The hair medulla contains structural proteins that are markedly different from other hair keratins and eosinophilic granules that are filled by an amino acid, citrulline and eventually form internal coatings within the membranes of mature cells [14, 16, 17].

The follicle is the essential growth structure of the hair and basically has two distinct parts: upper part consisting of infundibulum and isthmus whereas the lower part comprising of hair bulb and suprabulbar region. The upper follicle remains constant, while the lower part has continuous cycles of regeneration [1, 2, 16, 18].

The infundibulum, the uppermost portion of the hair follicle extending from the opening of the sebaceous gland to the surface of the skin, is a funnel-shaped structure filled with sebum, the product of the sebaceous glands. The upper part named acroinfundibulum, the keratinization of epithelium turns into the “epidermal mode”, with formation of stratum granulosum and stratum corneum like a similar manner to epidermis [1, 14, 16].

The isthmus is the lower portion of the upper part of hair follicle between the opening of the sebaceous gland and the insertion of arrector pili muscle. At the isthmus level, epithelium keratinization begins with the lack of granular layer named “trichilemmal keratinization” [14, 16]. Only few differentiated corneocytes remain and the invagination of the epidermis in this area must be considered as highly permeable for topically applied compounds [19]. Hair follicle stem cells are thought to reside in the bulge area on the isthmus close to the insertion of the arrector muscle [20]. Lineage studies have proven that bulge cells are multipotent and that their progeny generate the new lower anagen hair follicle [21]. One of the most distinguishing features of stem cells is their slow-cycling nature, presumably to conserve their proliferative potential and to minimize DNA errors that could occur during replication. They migrate in a downward direction. On entering the hair bulb matrix, they proliferate and undergo terminal differentiation to form the hair shaft and inner root sheath. They also migrate distally to form sebaceous glands and to proliferate in response to wounding [16, 20, 22].

The suprabulbar region of the follicle, below the isthmus and above the hair bulb, is comprised of three layers from outermost to innermost: outer root sheath, inner root sheath and hair shaft (Figure 2).

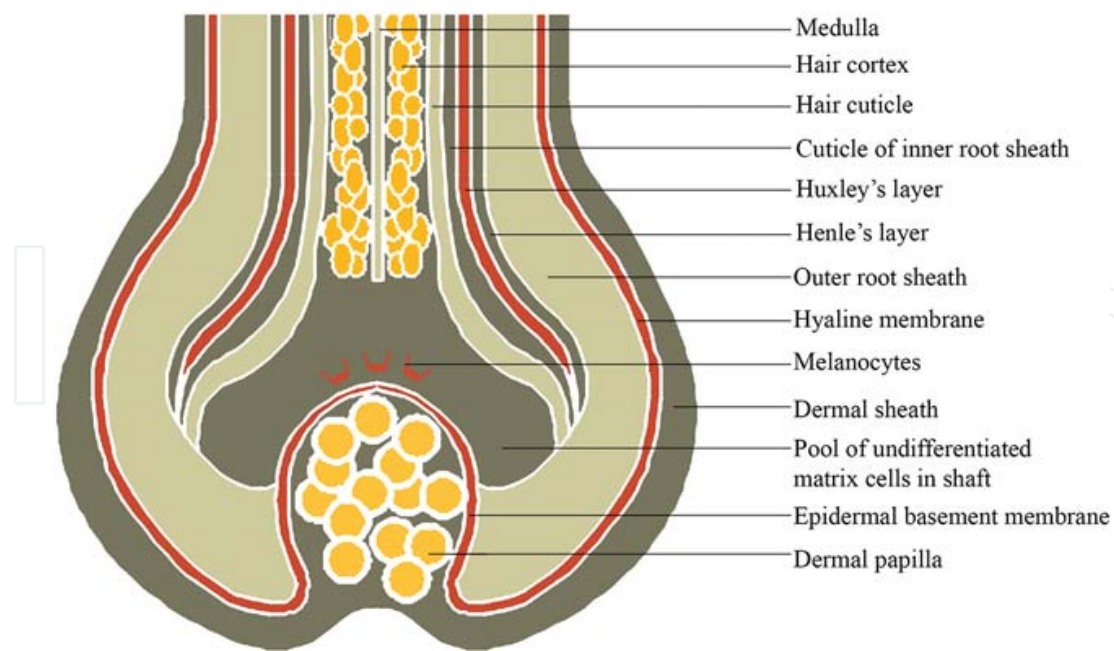


Figure 2. Diagram of proximal hair follicle.

Outer root sheath (ORS) extends from the epidermis at the infundibulum and continues to the hair bulb and its cells change considerably throughout the follicle. In the infundibulum, it resembles epidermis, whereas in the isthmus level, ORS cells begin to keratinize in a trichilemmal mode. Keratinocytes in the ORS form the bulge area at the base of the isthmus. At the lower tip of the hair bulb it consists of a single layer of cuboidal cells, becoming multilayered in the region of the upper hair bulb. In some follicles, there is a distinct single cell layer interposed between the outer and inner root sheaths, known as the companion layer [23]. Companion layer cells show numerous intercellular connections to the inner root sheath and are thought to migrate distally along with the inner root sheath to the isthmus region and to form the plane of slippage between the inner and outer root sheaths [1, 3, 14, 16]. The ORS of the hair follicle also contains melanocytes, Langerhans cells and Merkel cells. These cells take place in certain functions of the follicle such as acting as a sensory organ and serving as an immunologic sentinel for the skin [5].

Inner root sheath (IRS) contains three layers: Henle's layer, Huxley layer and cuticle layer. The innermost layer is the cuticle of IRS whose cells interlock with those of the hair cuticle. This connection, anchoring the hair shaft to the hair follicle, is so tight. The inner root sheath hardens before the presumptive hair within it, and so it is thought to control the definitive shape of the hair shaft. Each of the three layers of IRS undergoes abrupt keratinization. This occurs at different levels in each layer; however, the patterns of change are similar. Keratinization first appears in Henle's layer, the outermost. Huxley layer is keratinized above the Henle's layer at the region known as Adamson's fringe. The IRS coats and supports the hair shaft up to the isthmus level where the IRS disintegrates [3, 14, 16].

The expanded onion-shaped portion of the lower hair follicle, including the hair matrix and the follicular papilla is known as the hair bulb which is the active reproductive portion of the hair follicle. The hair bulb encloses follicular dermal papilla, mucopolysaccharide-rich stroma, nerve fiber and capillary loop. The matrix cells are localized to the lowermost portion of the follicle and surround all sides of the follicular papilla. The hair shaft and IRS are derived from the matrix cells. The IRS is derived from the lower and laterally located matrix cells, whereas the hair shaft is originated from upper and centrally located cells. In addition to producing the main structural components of hair, they also produce the hair keratins, and their associated proteins (KAPs) [24]. Melanocytes reside among matrix stem cells to produce the pigment of the hair. During their differentiation phase, matrix cells phagocytose melanin or pheomelanin from the dendritic elongations of melanocytes. The hair assumes its color via the amount and the type of the phagocytized major pigment [1, 3, 16, 25].

Follicular papilla, which is derived from a condensation of mesenchymal cells at the early stages of follicular embryogenesis, is one of the most important players during the induction and maintenance of the follicular epithelial differentiation. It is responsible for determining the follicle type. The volume and secretory activity of follicular papilla and also the number of matrix stem cells determine the size of the anagen hair bulb, the duration of anagen phase and the diameter of the hair shaft [11, 26, 27]. Moreover the follicular papilla is an essential source of growth factors [1, 3, 16, 28].

3.3. Molecular structure

Keratin proteins can be divided into two major families: the type I (acidic) keratins and the type II (basic-neutral) keratins. About 54 functional keratin genes (28 type I and 26 type II keratins) have been identified to date. There are 11 type I hair keratins, designated K31–K40, and 6 type II hair keratins, designated K81–K86, and the remainder are epithelial keratins [24].

The keratin-associated proteins (KAP), is a large group of proteins which constitutes the matrix of the keratin. The matrix proteins are separated to three major subgroups according to their amino acid compositions [29]. Different hair and epithelial keratins are expressed in the various concentric layers of the hair follicle, with hair keratins found primarily in the cortex and hair cuticle [1, 2].

3.4. Hair follicle innervation and vascularization

Nerves related to the hair follicle are identical to the dermal nerve network including sensory afferents and autonomic sympathetic nerves. Smaller nerve fibers form a circular layer around the bulge area of terminal follicles and the bulb area of vellus follicles. There are several types of nerve endings associated with the hair follicle: free nerve endings, lanceolate nerve endings, Merkel cells and pilo-Ruffini corpuscles. Each nerve ending responds to distinct stimulus. Free nerve endings transmit pain, lanceolate nerve endings detect acceleration, Merkel cells responsible of pressure sensation and pilo-Ruffini corpuscles detect tension. Perifollicular nerves related neuromediator and neuropeptides,

that is, substance P, calcitonin gene-related peptide influence follicular keratinocytes and hair follicle cycling [1, 3, 16].

Cutaneous vascularization is provided by arterioles, which are concentrated at the lower portion of the hair follicle and compose vascular network. During the hair cycle phases, there are some alterations in the density of perifollicular vascularization due to the upregulation of vascular endothelial growth factor expression [1].

3.5. Immunology of hair follicle

The immunology of hair is very amazing and complicated. The hair follicle represents an immune privileged (IP) site, which is defined basically as a location in the body where foreign tissue grafts can survive for longer periods of time without immune rejection. This specialized immune environment of IP is required to prevent destructive immune reactions in critical regions. Other immune privileged sites include the anterior chamber of the eye, testis, brain and placenta. Hair follicle IP has a unique characteristic of recurring in a cyclic pattern.

Until recently, the IP of the hair follicle is considered to be restricted to the matrix region during the anagen phase. However, evidence has accumulated that the IP of the hair follicle extends to the bulge region and is present at this site during the entire hair cycle. Since the bulge represents the hair follicle stem cell niche, sustained IP in this region may be essential for the survival of the follicle.

Hair follicle IP occurs during anagen [30]. Thus hair follicle IP is limited to the proximal epithelium of anagen hair follicles. During anagen, melanogenesis is activated in the hair bulb and suggests that hair follicle melanocyte autoantigens play a key role as potential immune targets [28, 31].

The hair follicle IP is maintained by several factors [32]:

- Downregulation of MHC class I expression in the proximal ORS and matrix cells.
- Local production of potent immunosuppressants like TGF- β 1, IL-10 and α -MSH.
- Functional deterioration of antigen presenting cells.
- Absence of lymphatics.
- Establishment of extracellular matrix barriers to hinder immune cell trafficking.
- Expression of non-classical MHC class 1.
- Expression of fas ligand.

3.6. Pigmentation of hair follicle

Hair shaft pigmentation ensures multiple benefits including UV protection, thermoregulation and sexual perceptions. Furthermore, the hair pigment, melanin, is a potent free-radical scavenger. Melanin production inside the active anagen hair bulb may, therefore, help to buffer cell stress induced by reactive oxygen species.

In contrast to the continuous melanogenesis observed in epidermal melanocytes, follicular melanogenesis is a cyclic phenomenon. It is ceased in early the anagen-catagen transition, restarted with the down-regulation of key enzymes of melanogenesis, followed by hair follicle melanocyte apoptosis.

Hair follicle melanocytes and their precursors reside in the hair matrix and along the outer root sheath of anagen hair follicles. However, production of hair pigment (black eumelanin and/or the reddish pheomelanin) only occurs in the specialized hair follicle pigmentary unit, located above and around the dermal papilla during anagen III–VI. Melanin synthesis is established in lysosome-related organelles named melanosomes. In the precortical matrix, these melanosomes are transferred to the hair shaft keratinocytes and formed a pigmented hair shaft. The hair follicle also contains melanocyte stem cells, which are located in the bulge and in the secondary hair [33–35].

4. Physiology of the hair

4.1. Hair growth cycle

Hair development is a continuous cyclic process and all mature follicles go through a growth cycle consisting of growth (anagen), regression (catagen), rest (telogen) and shedding (exogen) phases (**Figure 3**). The duration of the phases changes based on the location of the hair and also personal nutritional and hormonal status and age [15, 33].

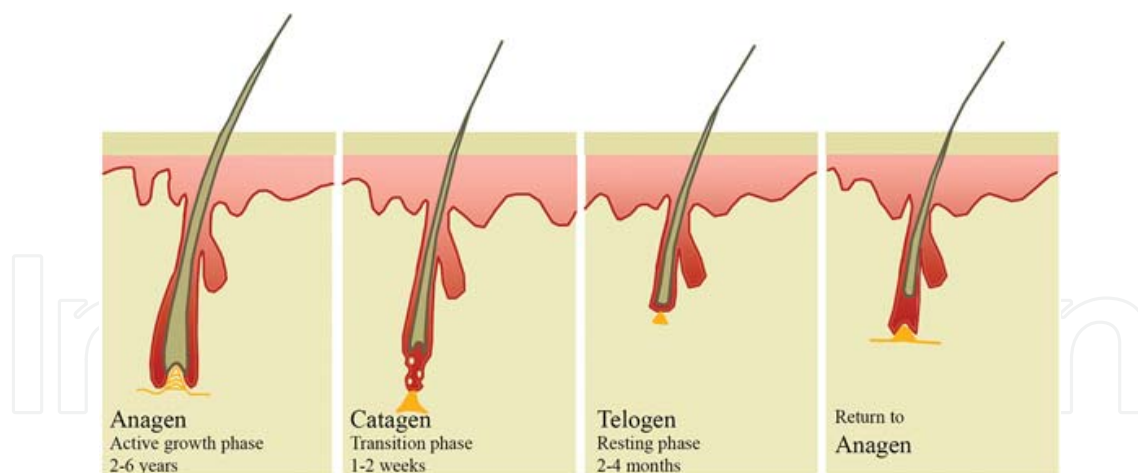


Figure 3. The hair cycle.

4.1.1. Anagen

The inception of anagen phase is presented by the onset of the mitotic activity in the secondary epithelial germ located between the club hair and dermal papilla in telogen hair follicle [5, 16]. The anagen is the active growth phase in which the follicle enlarges and takes the original shape and the hair fiber is produced. Almost 85–90% of all scalp hairs are in anagen.

Six portion of the anagen stage is demonstrated. Through the anagen I–V, hair stem cells proliferate, encloses the dermal papilla, grow downwards to the skin and begin to proliferate hair shaft and IRS, respectively. Subsequently, hair matrix melanocytes begin to develop pigment and the form of the hair shaft begins to arise; in anagen VI, hair bulb and adjacent the dermal papilla formation is realized and the new hair shaft appears from the skin. This phase can last up to 6–8 years in hair follicles [1, 11, 18].

Hair shaft synthesis and pigmentation only take place in anagen [11]. The degree of axial symmetry within the hair bulb determines the curvature of the final hair structure [35]. Fiber length is often dependent on the duration of the anagen or actively growing phase of the follicle [17]. The featured regulatory proteins in anagen phase are BMPs, sonic hedgehog, several WNT proteins and receptors. Insulin like growth factor-1 (IGF-1), fibroblast growth factor-7 hepatic growth factor (HGF), and vascular endothelial growth factor (VEGF) are thought to be important for anagen maintenance [36].

4.1.2. Catagen

At the end of anagen, mitotic activity of the matrix cells is diminished and the follicle enters a highly controlled involutionary phase known as catagen. Catagen lasts approximately 2 weeks in humans, regardless of the site and follicle type [37]. During catagen the proximal of the hair shaft is keratinized and forms the club hair, whereas the distal part of the follicle is involuted by apoptosis [16, 38].

Catagen phase is consisted of eight different stages. The first sign of catagen is the termination of melanogenesis in the hair bulb. Follicular epithelium, mesenchyme, neuroectodermal cell populations and also perifollicular vascular and neural systems demonstrates cyclic changes in differentiation and apoptosis. However, any apoptosis is occurred in dermal papilla due to the expression of suppressor bcl-2 [11]

Catagen is a process of bulbar involution. The perifollicular sheath collapses and vitreous membrane thickens. Eventually, the lower hair follicle becomes reduced to an epithelial strand, bringing the dermal papilla into close proximity of the bulge [36]. The epithelial strand begins to elongate and finally reaches to just below the insertion of pilar muscle. After the keratinization of the presumptive club hair, the epithelial strands begin to involute and shorten progressively followed by the papilla which condenses, moves upward and locates to rest below the bulge. The column eventually reduces to a nipple and forms secondary hair germ below the club. The club hair itself is formed from cortical and cuticle cells only, and it is characterized by a lack of pigmentation [2, 37]. The presence of hairless gene mutation contributes to the failure of dermal papilla migration toward the bulge area in catagen phase [3]. FGF5 is a key inducer of catagen and FGF5-deficient mice have a prolonged anagen phase. In addition to FGF5, TGF- β 1, IL-1b, the neurotrophins NT-3, NT-4 and BMP2/4 and TNF- α have been described to induce catagen [36].

4.1.3. Telogen

The telogen stage is defined as the duration between the completion of follicular regression and the onset of the next anagen phase. Telogen stage lasts for 2–3 months. Approximately 10–15% of all hair is in telogen stage. During the telogen stage, the hair shaft is transformed to club

hair and finally shed. The follicle remains in this stage until the hair germ which is responsive to anagen initiating signals from the dermal papilla, starts to show enhanced proliferative and transcriptional activity in late telogen, leading to the initiation of anagen [2, 39].

Telogen is one of the main targets of hair cycle which is influenced by several modulatory agents like androgens, prolactin, ACTH, retinoids and thyroid hormones [40]. No unique molecular markers associated with the telogen follicle are determined yet; however, estrogen receptor expression is reported to be limited to the telogen papilla fibroblasts. Germ cells of telogen follicles also express basonuclin and FGF-5 [33]. The bone morphogenic protein-4 (BMP-4) as a growth factor plays an essential role in suppressing follicular growth and differentiation at telogen stage [16].

The macro-environment surrounding the hair follicle also takes part in regulating cycle transitions. BMPs in the subcutaneous fat are capable of maintaining follicles in a “refractory” telogen, and cessation of this inhibitory activity by BMPs enables the follicle to progress to a “competent” telogen with a hair germ that is responsive to anagen-initiation signals and capable of entering a new anagen phase [2, 41].

4.1.4. *Exogen*

There is less interest for the mechanism of the hair shedding but from the patient’s perspective it is probably the most important part of the hair growth. It is not unusual for human telogen hairs to be retained from more than one follicular cycle and this suggests that anagen and exogen phases are independent. The shedding period is believed to be an active process and independent of telogen and anagen thus this distinct shedding phase is named exogen [16, 33].

4.2. Hair cycle clock

Based on the observations: the hair follicle has no need for intact innervation, vascularization or other extrafollicular components to maintain cycling, and the basic oscillator system which controls hair cycling is located presumably in the follicle [42]. The principal challenge is to define the underlying “oscillator” system. Probably, the hair cycle clock is controlled by regulating the balance of the interactions between the follicle epithelium and the surrounding mesenchyme. This might be provided by the rhythmic secretions of growth/modulatory signals from follicle epithelium or mesenchyme as well as the rhythmic alterations in the expressions of corresponding receptors [40].

5. Conclusion

In this chapter, the basic anatomy and the amazing and complicated biology of the hair follicle is reviewed. Enhanced knowledge on the normal dynamics of the hair provides understanding the basis of how the follicle behaves during a disease. However recent progress in our understanding of the biology and pathology of hair follicles should lead more effective therapies for hair disorders.

Acknowledgements

I very much thank Seda Bilir Aksu for the excellent work of the figures in this chapter.

Author details

Bilgen Erdoğan

Address all correspondence to: bcakil@hotmail.com

Bakırköy Dr. Sadi Konuk Research and Training Hospital, İstanbul, Turkey

References

- [1] Buffoli B, Rinaldi F, Labanca M et al. The human hair: from anatomy to physiology. *Int J Dermatol* 2014;53: 331–341.
- [2] De Berker D, Higgins CA, Jahoda C et al. Biology of hair and nails. In: Bolognia JL, Jorizzo JL, Schaffer JV, editors. *Dermatology*. 3 ed. Elsevier Saunders Ltd. 2012. pp. 1075–1092.
- [3] Cotseralis G, Botchkarev V. Biology of hair follicle. In: Wollf K, Goldsmith LA, Katz SI, editors. *Fitzpatrick's Dermatology in General Medicine*. 7th ed. New York: Mc Graw Hill. 2008. pp. 739–749.
- [4] Hardy MH. The secret life of the hair follicle. *Trends Genet* 1992;8:55–61.
- [5] Paus R, Cotseralis G. The biology of hair follicle. *N Engl J Med* 1999;341:491–497.
- [6] Miller SE. Molecular mechanisms regulating hair follicle development. *J Invest Dermatol* 2002;118:216–225.
- [7] Andl T, Reddy ST, Gaddapara T et al. WNT signals are required for the initiation of hair follicle development. *Dev Cell* 2002;2:643–653.
- [8] Headon DJ, Overbeek PA. Involvement of a novel Tnf receptor homologue in hair follicle induction. *Nat Genet* 1999; 22:370–374.
- [9] Laurikkala J, Pispä J, Jung HS et al. Regulation of hair follicle development by the TNF signal ectodysplasin and its receptor Edar. *Development*. 2002;129:2541–2553.
- [10] Botchkarev VA, Botchkareva NV, Sharov AA et al. Modulation of BMP signaling by noggin is required for induction of the secondary (nonyllotrich) hair follicles. *J Invest Dermatol* 2002;118:3–10.
- [11] Krause K, Foitzik K. Biology of hair follicle: the basics. *Semin Cutan Med Surg* 2006;25:2–10.

- [12] De La Mettrie R, Saint-Leger D, Loussouarn G et al. Shape variability and classification of human hair: a worldwide approach. *Hum Biol* 2007;79:265–281.
- [13] Otberg N, Richter H, Schaefer H et al. Variation of hair follicle size and distribution in different body sites. *J Invest Dermatol* 2004;122:14–19.
- [14] Sperling LC: Hair anatomy for the clinician. *J Am Acad Dermatol* 1991;25:1–17.
- [15] Wolfram LJ. Human hair: a unique physicochemical composite. *J Am Acad Dermatol* 2003;48:S106–S114.
- [16] Messenger AG, De Berker DAR, Sinclair RD. Disorders of hair. In: Burns T, Breathnach S, Cox N, editors. *Rook's Textbook of Dermatology*. 8 ed. Oxford: Wiley-Blackwell. 2010. pp. 66.1–66.16.
- [17] Jones LN. Hair structure anatomy and comparative anatomy. *Dermatol Clin* 2001;19:95–103.
- [18] Randal VA, Botchkareva NV. The biology of hair growth. In: Ahluwalia GS, editor. *Cosmetic Application of Laser and Light based system*. Norwich, NY: William Andrew Inc. 2009. pp. 3–35.
- [19] Blume-Peytavi U, Vogt A. Human hair follicle: reservoir function and selective targeting. *Br J Dermatol* 2011;165:13–17.
- [20] Oshima H, Rochat A, Kedzia C et al. Morphogenesis and renewal of hair follicles from adult multipotent stem cells. *Cell* 2001;104:233–245.
- [21] Ito M, Kizawa K, Hamada K et al. Hair follicle stem cells in the lower bulge form the secondary germ, a biochemically distinct but functionally equivalent progenitor cell population, at the termination of catagen. *Differentiation* 2004;72:548–557.
- [22] Cotterrell G, Sun TT, Lavker RM. Label-retaining cells reside in the bulge area of pilosebaceous unit: implications for follicular stem cells, hair cycle, and skin carcinogenesis. *Cell* 1990;61:1329–1337.
- [23] Rothnagel JA, Roop DR. Hair follicle companion layer: reacquainting an old friend. *J Invest Dermatol* 1995; 104: 42S–43S.
- [24] Rogers MA, Langbein L, Praetzer-Wundel S et al. Human hair keratin associated proteins (KAPs). *Int Rev Cytol* 2006;251:209–263.
- [25] Jankovic SM, Jankovic SV. The control of hair growth. *Dermatol Online J* 1998;4:2.
- [26] Jahoda CA, Reynolds AJ. Dermal-epidermal interactions. Adult follicle derived cell populations and hair growth. *Dermatol Clin* 1996;14:573–583.
- [27] Paus R, Müller-Röver S, Botchkarev VA. Chronobiology of the hair follicle: hunting the “hair cycle clock”. *J Invest Dermatol Symp Proc* 1999;4:338–345.
- [28] Peus D, Pittelkow MR. Growth factors in hair organ development and the hair growth cycle. *Dermatol Clin* 1996;14:559–572.

- [29] Roger GE. Hair follicle differentiation and regulation. *Int J Dev Biol* 2004;48:163–170.
- [30] Christoph T, Müller-Röver S, Audring H et al. The human hair follicle immune system: cellular composition and immune privilege. *Br J Dermatol* 2000;142:862–873.
- [31] Ito T. Hair follicle is a target of stress hormone and autoimmune reactions. *J Dermatol Sci* 2010;60:67–73.
- [32] Paus R, Ito N, Takigawa M et al. The hair follicle and immune privilege. *J Invest Dermatol Symp Proc* 2003;8:188–194.
- [33] Stenn KS, Paus R. Controls of hair follicle cycling. *Physiol Rev* 2001;81:449–494.
- [34] Slominski A, Wortsman J, Plonka PM et al. Hair follicle pigmentation. *J Invest Dermatol* 2005; 124: 13–21.
- [35] Thibaut S, Gaillard O, Bouhanna P et al. Human hair shape is programmed from the bulb. *Br J Dermatol* 2005;152:632–638.
- [36] Schneider MR, Schmidt-Ulrich R, Paus R. The hair follicle as a dynamic miniorgan. *Curr Biol* 2009;19:R132–R142.
- [37] Kligman AM. The human hair cycle. *J Invest Dermatol* 1959;33:307–316.
- [38] Paus R, Foitzik K. In search of the “hair cycle clock”: a guided tour. *Differentiation* 2004;72:489–511.
- [39] Greco V, Chen T, Rendl M et al. A two-step mechanism for stem cell activation during hair regeneration. *Cell Stem Cell* 2009;4:155–169.
- [40] Paus R. Principles of hair cycle control. *J Dermatol* 1998;25:793–802.
- [41] Plikus MV, Mayer JA, de la Cruz D et al. Cyclic dermal BMP signalling regulates stem cell activation during hair regeneration. *Nature* 2008;451:340–344.
- [42] Sten KS, Nixon J, Jahoda CAB et al. What controls hair follicle cycling? *Exp Dermatol* 1999; 8:229–233.

