

We are IntechOpen, the world's leading publisher of Open Access books Built by scientists, for scientists

6,900

Open access books available

185,000

International authors and editors

200M

Downloads

Our authors are among the

154

Countries delivered to

TOP 1%

most cited scientists

12.2%

Contributors from top 500 universities



WEB OF SCIENCE™

Selection of our books indexed in the Book Citation Index
in Web of Science™ Core Collection (BKCI)

Interested in publishing with us?
Contact book.department@intechopen.com

Numbers displayed above are based on latest data collected.
For more information visit www.intechopen.com



Basics of Angiography for Peripheral Artery Disease

Yoshiaki Yokoi

Additional information is available at the end of the chapter

<http://dx.doi.org/10.5772/67177>

Abstract

Angiography has been historically used to image the peripheral artery system and still remains the gold standard for diagnostic and endovascular treatment. There is no standardized method for lower limb artery angiography. In this chapter, the basic standard technique for angiography of peripheral artery is described from aortoiliac, femoropopliteal and below the knee arteries. To obtain a good image, adequate contrast dose and image size must be determined with the appropriate catheter. For puncture, echo-guided approach is becoming popular; each lab needs to have echo machine to minimize the vascular complication. In cases of renal dysfunction, CO₂ angiography is suited. However, care must be taken to deliver gas into arterial system and to know the merit and demerit of CO₂ angiography.

Keywords: peripheral artery, peripheral artery disease, contrast angiography, echo-guided puncture, CO₂ angiography

1. Angiography-suite for endovascular therapy of peripheral artery disease (PAD)

1.1. Detector size

High resolution, accurate imaging is the key to success in endovascular therapies. In recent years, most machines provide fairly good images. An important point is the detector size of the angiography machine. Some physicians still use a coronary lab for peripheral artery intervention, however, when considering the vessel length and area, at least a 30 cm detector is needed. In **Figure 1**, two types of detectors are shown.

In peripheral artery angiography, the 30 cm system on the left (INNOVA 3100, 30 cm, GE healthcare, Uppsala, Sweden) (**Figure 1A**) is basically used while the 20 cm coronary system (INNOVA IGS620, 20 cm, GE healthcare, Uppsala, Sweden) (**Figure 1B**) is too small for peripheral artery angiography. For example, the superficial femoral artery (SFA) is the longest vessel and difficult to visualize in its entirety. In **Figures 1** and **2**, two SFA short lesions are shown.

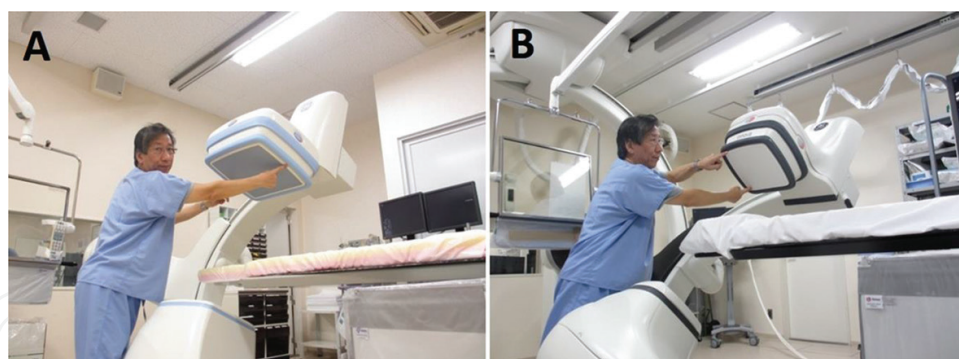


Figure 1. Detector size: (A) 30 cm × 30 cm, (B) 20 cm × 20 cm. In peripheral artery angiography, at least a 30 cm image size is needed. The 20 cm image size is too small for peripheral artery angiography.

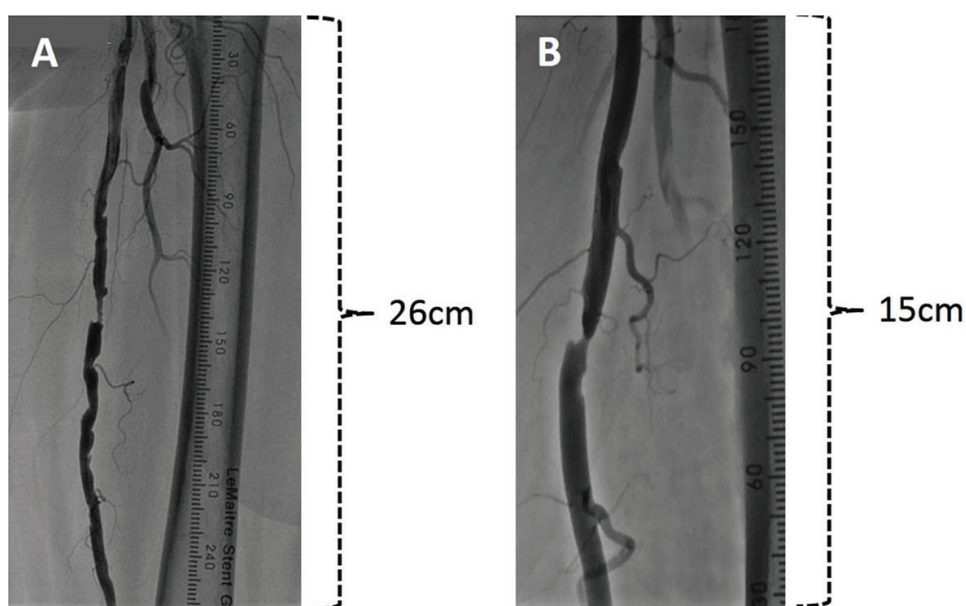


Figure 2. Image field of 20 cm and 30 cm detector in SFA. (A) In the 30 cm detector, about 26 cm of SFA is visualized. (B) In the 20 cm detector, only 13 cm of SFA is seen.

In the 30 cm panel, about 26 cm of the SFA can be visualized and intermediate stenosis around the culprit lesion (**Figure 2A**) can be discerned. On the other hand, the coronary detector could visualize only 13 cm of the SFA in 20 cm mode (**Figure 2B**). In a coronary lab, to visualize the SFA or below the knee (BK) arteries, the table is panned but a good static image of the lesion is difficult to obtain.

1.2. Extra monitor

In an angiographic suite, operators usually stand on the right side of the table. Most labs use one monitor and all medical staffs rely on this one screen. In right limb angiography via the left femoral artery approach, the operator who is standing on the right side has difficulty manipulating the catheter. In this situation, one operator needs to stand on the left side of the table to manipulate the catheter and hold the sheath. For this purpose, an extra-monitor should be installed (**Figure 3**).

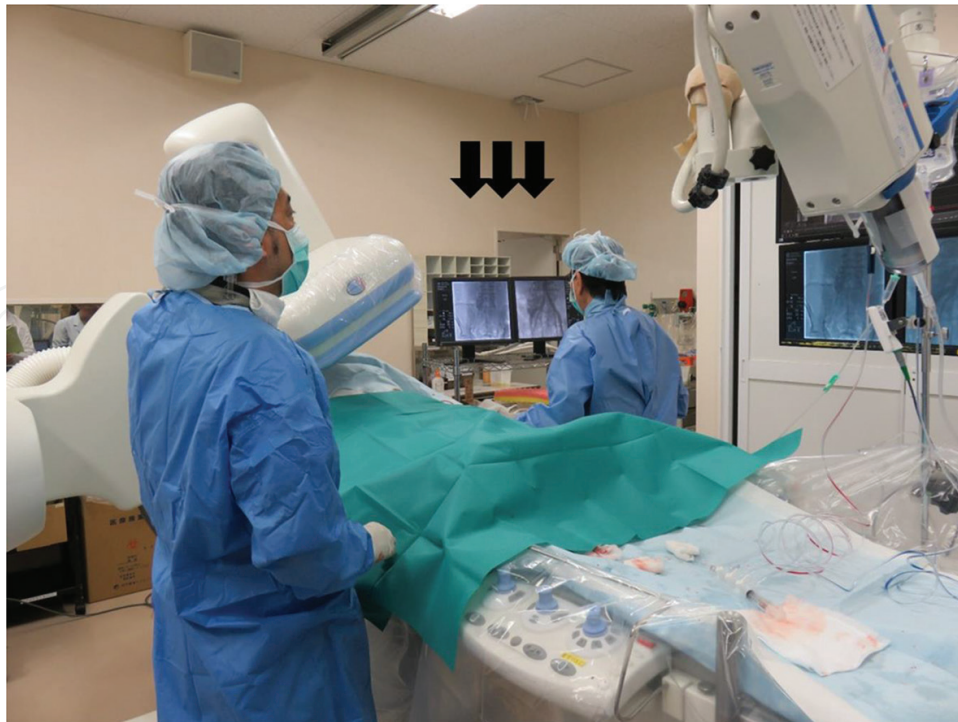

Figure 3. Extra-monitor. In right superficial artery (SFA) intervention, the main operator stands on the left side of the table watching the extra-monitor while the assisting operator watches the central monitor. Without moving the central image monitor, the main operator can manipulate the catheter from the left side.

A typical right superficial artery (SFA) intervention is shown in **Figure 3**. The main operator is standing on the left side of the table and watching the extra-monitor while the assisting operator keeps an eye on the central monitor. Without moving the central image monitor, the main operator is able to perform the procedure. This extra-monitor is useful in the left brachial approach as well. It is a convenient way to intervene in the right femoropopliteal artery or cross-over approach for right below the knee arteries. In the left below the knee artery procedure via the cross-over approach, the C-arm is rotated to the left side. The cranial side operator may not see the central image. In this situation, the extra monitor can be placed on the left cranial side.

1.3. Injector

For most of the small vessels in selective angiography, hand injection of the contrast dye is adequate. However, for optimal opacification of high-flow blood vessels like the aorta, the use of a power injector is mandatory. A constant and high volume of dye should be injected through an electronically calibrated power injector. There are two types of injectors: one is a conventional power injector and the other is an assisted device that introduces small or large amounts of dye by an injector attached to the catheter table. The contrast volume is adjusted manually so that even a small dose of dye can be injected. However, the space on the left side of the table is occupied by this assisted device. Thus, a conventional power injector mounted to the ceiling is preferable since it affords more space around the catheter table. Furthermore, the distance allows a significant reduction in radiation exposure during dye injection. With the assisted device, radiation exposure is difficult to prevent since the operator has to be beside the table during dye injection (**Figure 4**).

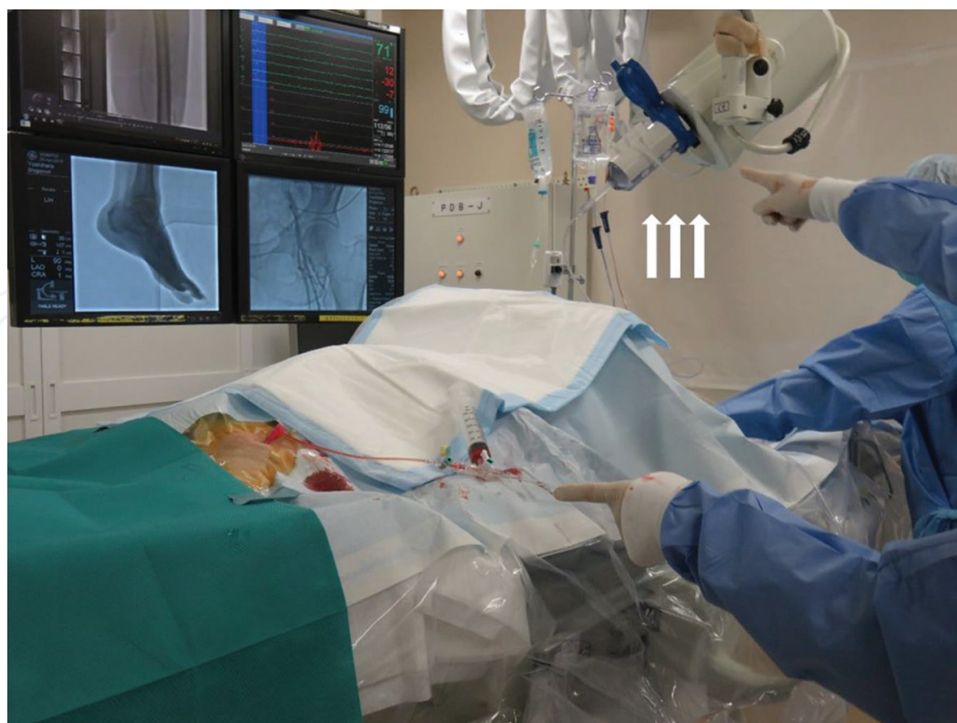

Figure 4. Power injector mounted to the ceiling. The ceiling-mounted injector allows more space around the catheter table.

1.4. Contrast dose

Contrast-related factors include the vascular access site, injection time duration, injection rate, contrast volume and dye concentration. The key factor is the injection rate. An increased rate of injection can induce a greater extent of vascular opacification but the safety and total volume of the contrast dose must be carefully monitored. The contrast volumes for opacification of the major arteries are shown in **Table 1**. These are the injection volumes mainly used in our catheter laboratory although the actual contrast volume depends on the patient's condition, the catheter size, amount of contrast and speed of injection. Therefore, the contrast dose should be individualized for each case.

Location	Catheter	Injection rate (ml/s)	Total volume (ml)
Aortoiliac	5Fr Pig tail	14–16	15–25
CFA-SFA-Pop A	4–5Fr MP	5–7	16–20
Run: CFA-BTK	4–5Fr MP	4	9–12
SFA	4–5Fr MP	4–5	8–10
Run: BTK	4Fr MP	3–4	10–12
BTK	4Fr MP	3–4	5–7
Below the ankle	4Fr MP	3–4	5–7

Table 1. Contrast injection rate and injection volume.

There is no universally agreed upon threshold in the degree of renal dysfunction beyond which intravascular iodinated contrast medium should not be administered. We use Visipaque 320 [2]. Contrast-induced nephropathy (CIN) is an infrequent adverse reaction to iodinated contrast agents [3]. In endovascular procedures, particular complex procedures are associated with CIN and larger doses of contrast are considered a risk factor. Thus, as a precaution against CIN, the use of contrast media at the lowest dosage possible is advised. To minimize the contrast dose, we dilute Visipaque 320 by adding 30 cc of saline solution in a 100 cc bottle. The key factor is the injection rate which indicates the amount of dye per second. In our experience, 1/3rd diluted contrast does not decrease image quality.

1.5. Radiation safety

Angiography machines which use fluoroscopy for endovascular work are equipped with pulsed fluoroscopy instead of continuous fluoroscopy and this, to a large extent, helps to reduce the radiation dose (three radiation pulse mode). During this procedure, both the patient and physician are exposed to a certain degree of radiation so that its dose needs to be minimized. Constant measurement of radiation doses in patients and personnel is vital. Above all, the shielding in the room is particularly important. We use a suspended ceiling shield as well as a floor installed shield (**Figure 5**). During digital subtraction angiography (DSA) imaging, other comedical staffs are outside the angiosuite. The main operator besides the patient is protected by a ceiling-mounted radiation shielding glass. After the procedure, radiation exposure levels must be routinely recorded and archived.

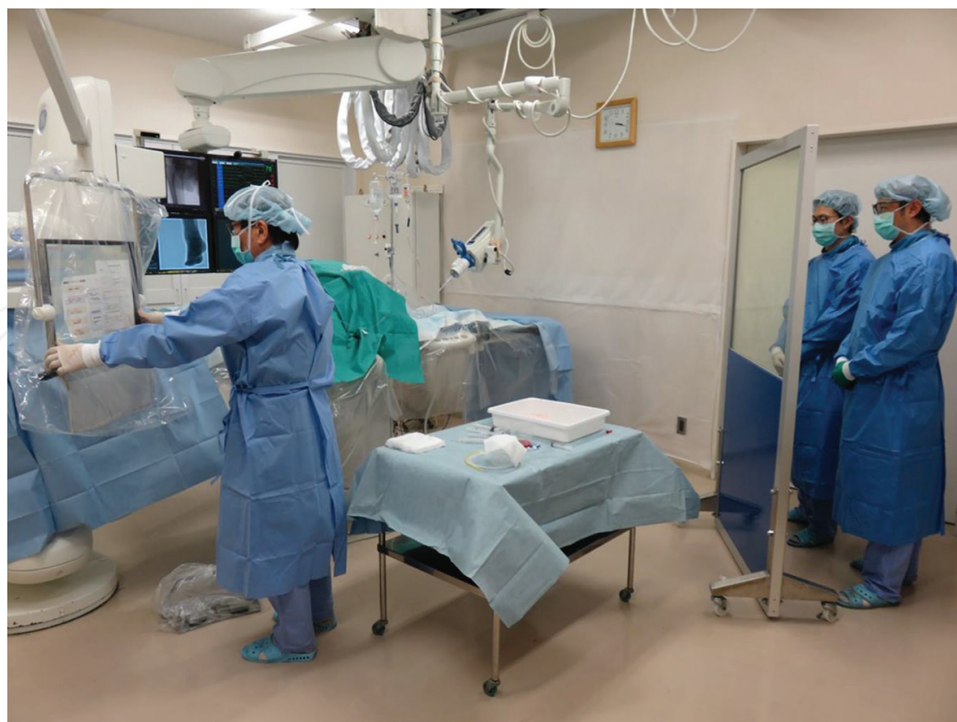

Figure 5. Radiation shield. Operator uses the ceiling-mounted radiation shield and the assistant is behind the shield during contrast injection.

2. Imaging techniques

2.1. Sheath

2.1.1. 4Fr sheath

The 4Fr sheath is mainly used for the antegrade femoral approach. For initial access, a 4Fr sheath is placed from the common femoral artery (CFA) to the SFA. The reason is that an antegrade puncture is technically more demanding and if we fail to make the puncture, the sheath can be withdrawn or repositioned. While keeping the 4Fr sheath in the profunda femoris artery (PFA), we can even place an additional 4Fr sheath into the CFA. The long 4Fr sheath is for below the knee work. However, it is easily kinked and there may be an increased risk of hematoma formation. In interventions below the knee arteries, most occlusion balloons accept the 4Fr sheath with the use of a 0.014 or 0.018 in. guidewires. And to minimize sheath size in the ipsilateral CFA approach, a 4Fr long sheath is ideal for patients with critical limb ischemia (CLI) (**Figure 6A**).

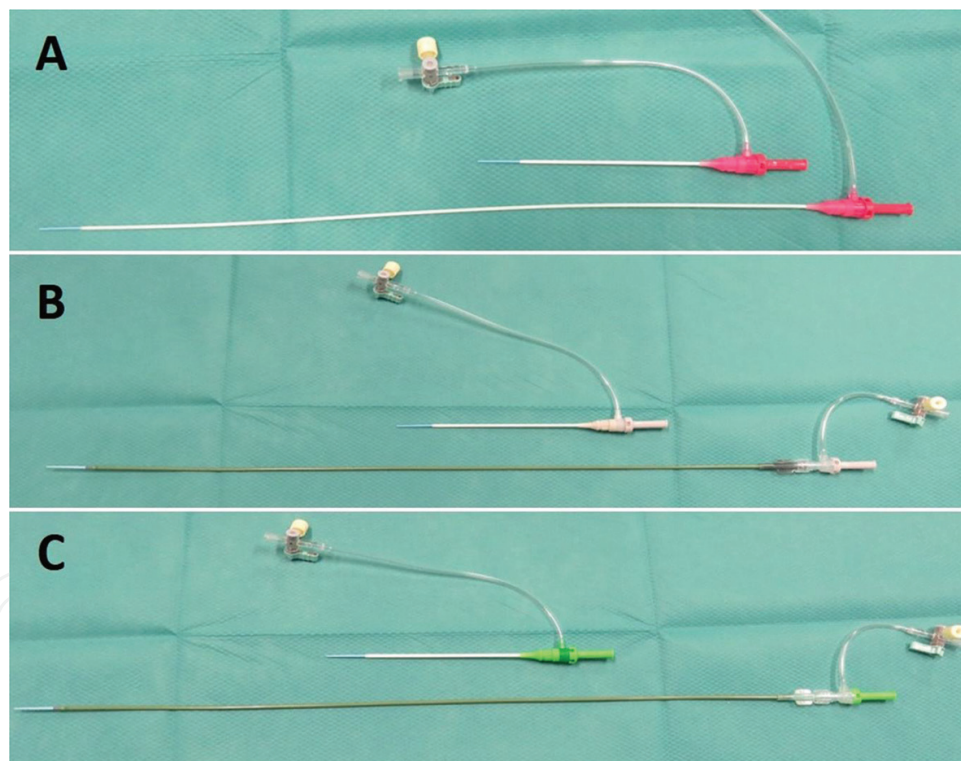


Figure 6. Sheath. (A) 4Fr sheath, (B) 5Fr sheath, (C) 6Fr sheath.

2.1.2. 5Fr sheath

In ad hoc interventions, we have standardized the 5Fr sheath for the initial retrograde CFA approach. When stent implantation is planned, we start with a 6Fr sheath. Either

a 4Fr or 5Fr pigtail catheter can be used for aortography. With a 4Fr pigtail catheter, the amount of dye is limited to around 10–13 cc/s. To opacity the terminal aorta to both the iliac and common femoral arteries, the rate of injection should be 15–20 cc/s and this flow rate can be achieved with at least a 5Fr pigtail catheter. Introducer sheaths are used for all angiography and endovascular procedures. The 5Fr 45 cm cross-over sheath is used for either the retrograde or antegrade approach. In a contralateral SFA intervention, a 5Fr 45 cm crossover sheath is used. However, when stenting is performed, the sheath should be replaced with a 6Fr crossover sheath. In the antegrade approach for BK interventions, a 5Fr 45 cm crossover sheath gives more back-up support to intervene on the tibial arteries (**Figure 6B**).

2.1.3. 6Fr sheath

When an iliac artery stent is already planned, a 6Fr short sheath should be placed in a retrograde manner. In a cross-over approach, a 6Fr 45 cm cross-over sheath is employed. The advantage of the 6Fr system is that the closure device can be applied after the procedure. In some medical centers, the antegrade 6Fr short sheath is placed for SFA stenting. However, we do not routinely use the 6Fr sheath for antegrade work (**Figure 6C**) (**Table 2**).

Advantage	Disadvantage
Better wire control with short wire	Complication related to antegrade common femoral artery (CFA) puncture
Short distance to the lesion	Might miss proximal superficial femoral artery (SFA) lesion
Precise stent placement	Need caution of proximal end of stent
Access to below the knee arteries	Compression of ischemic side after procedure

Table 2. Advantage and disadvantage of ipsilateral antegrade approach.

2.2. Wires

2.2.1. 0.035 in. wire

There are three types of tips for the 0.035 wire. We do not use a regular J-tip Radifocus wire (Terumo, Tokyo, Japan) (**Figure 7A**). The initial wire is always a 1.5 mm J-type Radifocus wire (Terumo, Tokyo, Japan) (**Figure 7B**). The tip of this wire has a 1.5 mm round shape and is quite safe when the wire migrates into the small branches or other vessels. Once the guidewire crosses the lesion, we change to a regular 0.035 in. spring wire (**Figure 7C**). The Radifocus wire is slippery and is difficult to keep in place while regular spring wires tend to stay in place. Thus, for stability, the wire should be changed to a spring wire once the lesion is crossed. These three types of 0.035 in. wires should always be at hand.

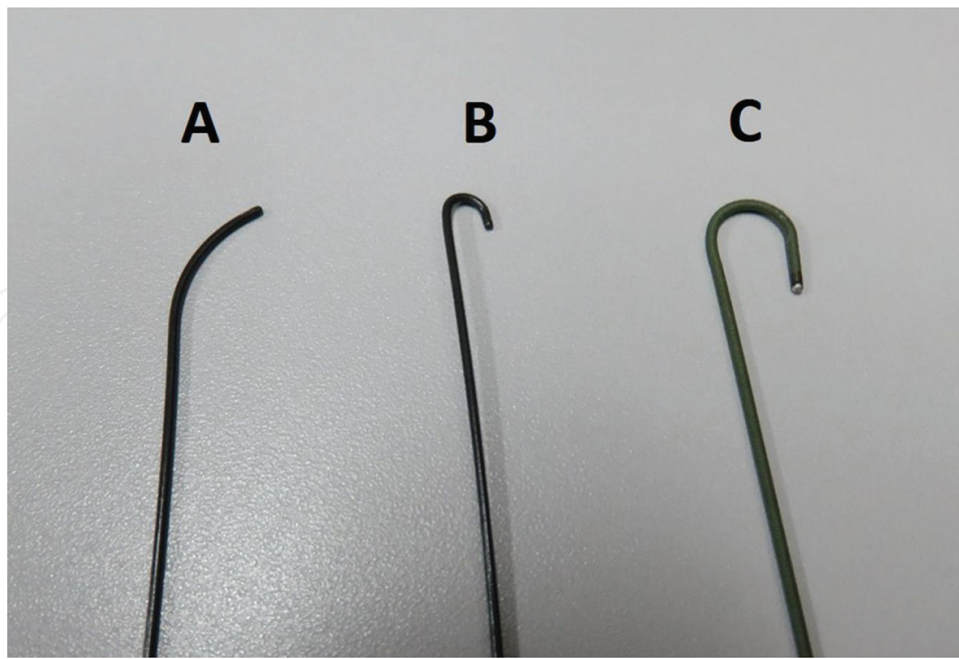


Figure 7. 0.035 in. guidewires. There are three types of tips for the 0.018 in. wire. We do not use regular a J-tip Radifocus wire (A). The initial wire is always a 1.5 mm J-type Radifocus wire (B). Once used to cross the lesion, it is exchanged to a 0.018 in. spring wire (C).

2.2.2. 0.018, 0.014 in. wires

Basically, we do not use the 0.018 in. wire as a regular wire. Chronic total occlusion (CTO), a 0.018 in. Treasure 12-g (Asahi Intec, Nagoya, Japan) wire is initially selected. It has a 12-g tip load and is best suited as a peripheral CTO wire. The V 18 (Boston Scientific, Cambridge, MA, USA) wire has a strong main shaft with a soft tip and can be used for cross-over ballooning or stent implantation. There are many 0.014 in. wires and their purposes vary. For below the knee artery work, the 0.014 in. wire is the basic wire used.

2.3. Digital subtraction angiography (DSA) vs. digital angiography (DA)

Digital subtraction angiography (DSA) has long been the gold standard for evaluation of atherosclerotic lesions in patients with PAD. Image quality has been further improved by replacing traditional image intensifiers with flat panel detectors so that regular digital angiography (DA) is now replacing DSA. When considering the high radiation doses, not all cases need imaging by DSA. Above all, critical limb ischemia is difficult to manage and some patients have difficulty staying still during injection of the contrast dye. Thus, adequate optimization with either DSA or DA should be employed to obtain accurate imaging of the diseased segments.

2.3.1. Aortoiliac artery

A typical DSA image of the iliac artery is shown in **Figure 8**. In the 30 cm image, we can see from the terminal aorta to both common femoral arteries (**Figure 8A**). In the 20 cm image, a clearer view can be seen (**Figure 8B**).

In our routine, we first take a 30 cm image by DSA (**Figure 9A**). Next, we take a 20 cm image by DA for the purpose of intervention (**Figure 9B**).

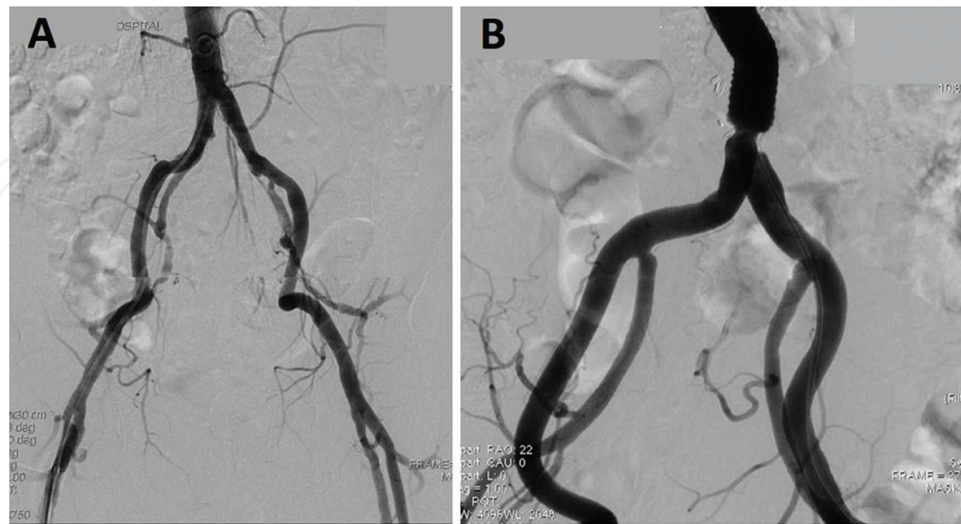


Figure 8. Iliac artery angiography, 30 cm vs. 20 cm image. (A) 30 cm image, we could see from the terminal aorta to both common femoral arteries. (B) 20 cm image, a clearer view is obtained.

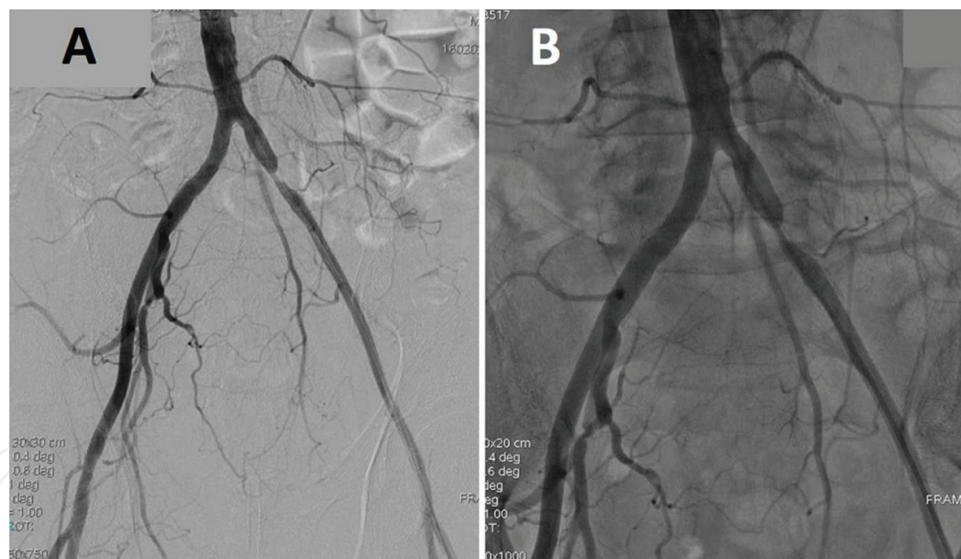


Figure 9. DSA vs. DA image of the iliac artery. (A) 30 cm image by DSA for diagnostic purposes. (B) 20 cm image by DA for interventions. DSA, digital subtraction angiography; DA, digital angiography.

DA is more practical for stent implantation since it provides the background image. In the aortoiliac artery segment, the image is hampered by bowel and gas movements. Aortoiliac artery angiography is basically taken by DSA, however, due to bowel and gas movements, the image is blurred (**Figure 10A**). In such a circumstance, we change to the DA image (**Figure 10B**). In **Figure 10**, a left common iliac aneurysm with distal stenosis can be seen; the DSA image is blurred while the DA image clearly reveals stenosis.

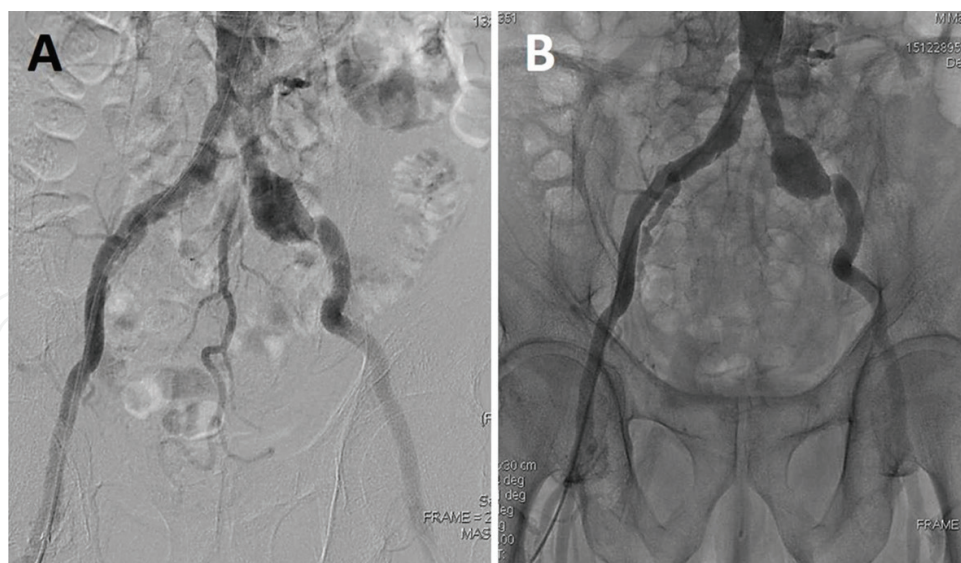


Figure 10. DSA vs. DA image of the iliac artery. (A) DSA image is blurred by bowel gas. (B) DA image shows clear image of left common iliac aneurysm with distal stenosis. DSA, digital subtraction angiography; DA, digital angiography.

2.3.2. Femoropopliteal artery

The initial angiographic image is the ipsilateral angled view. Either DSA or DA can provide a reasonable image (**Figure 11**), although the DSA image (**Figure 11A**) is shown to be better than the DA image (**Figure 11B**). In the DA image, the background is shown and can be used as reference (**Figure 11B**).

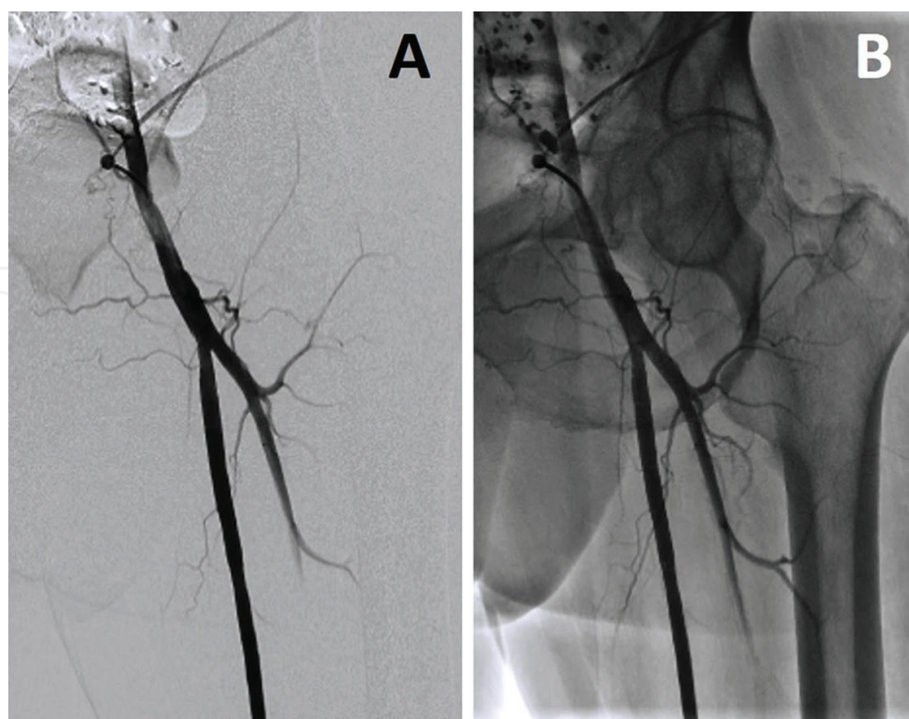


Figure 11. Proximal femoral artery. (A) DSA image for ipsilateral angled view of the left proximal femoral artery. (B) DA image shows the background and identifies bifurcation point.

A calcified lesion is often seen in the common femoral artery. In such cases, DSA provides a clearer view than the DA image (**Figure 12**). DSA clearly shows the calcified lesion (**Figure 12A**) while, in contrast, the lesion could not be determined in the DA image due to low contrast (**Figure 12B**).

For the SFA, we use either the DSA or DA image. For a calcified lesion, DSA is preferable (**Figure 13A**), but in most cases, DA provides a reasonably good image (**Figure 13B**).

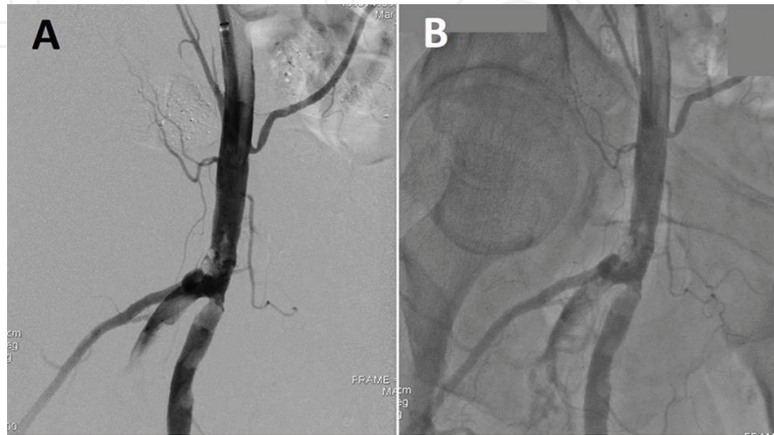


Figure 12. Calcified common femoral artery. (A) DSA clearly shows calcified lesion. (B) DA image could not determine lesion due to low contrast.

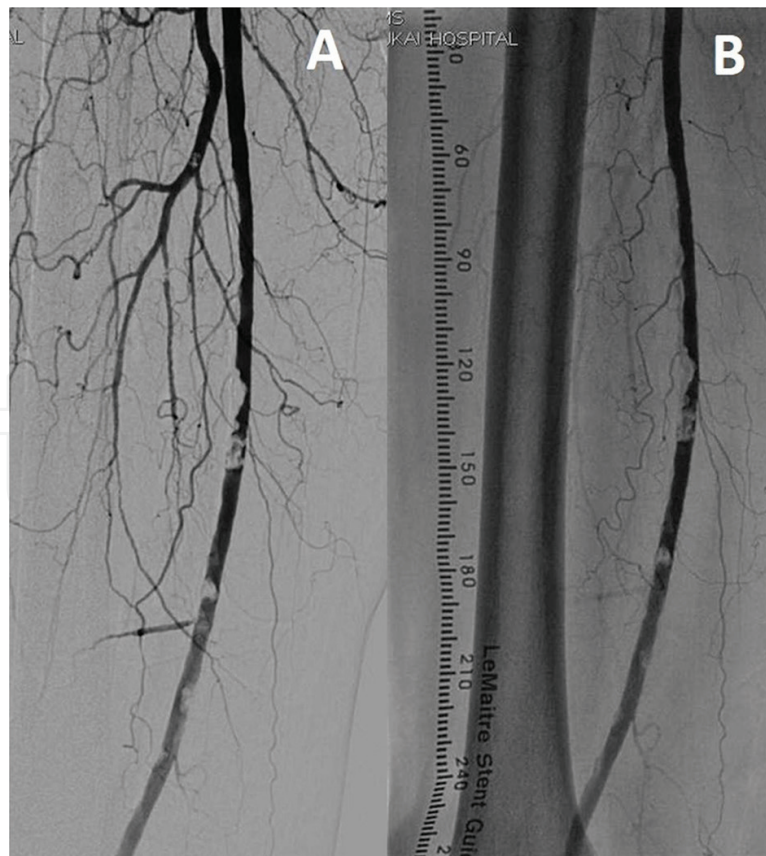


Figure 13. SFA angiography, DSA vs. DA. (A) DSA shows clearer image and branches are well seen. (B) DA gives reasonably good image.

In a SFA lesion, measurement of the lesion length is important to decide the interventional strategy and we prefer a DA image for the pre-interventional angiogram. The popliteal artery is located deep in the posterior fossa of the knee joint. Surrounded by a bony structure, the popliteal artery is very difficult to visualize by DA. Basically, a DSA image is taken for the popliteal artery (**Figure 14A**). In **Figure 14A**, tight stenosis of the mid-popliteal artery is well visualized with rich collateral circulation. In the DA view, stenosis is well observed but most of the collateral vessels are not visualized (**Figure 14B**).

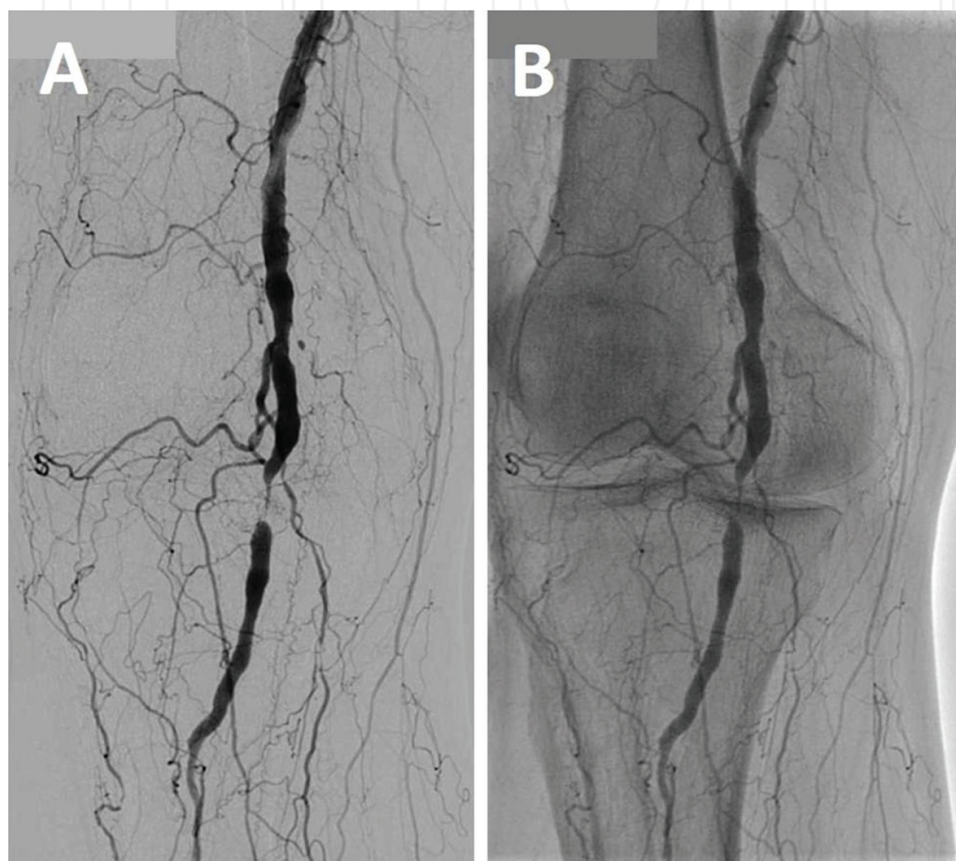


Figure 14. Popliteal artery angiography, DSA vs. DA. (A) Popliteal artery surrounded by bone and basically taken with DSA. (B) DA view shows well visualized stenosis but most collateral vessels unclear.

2.3.3. Below the knee arteries

Diseases of below the knee arteries are closely associated with critical limb ischemia (CLI) and detailed anatomical information is required to plan intervention. Compared to other limb arteries, angiography remains the imaging method of choice in most cases of CLI. How to take a good image is the cornerstone of successful endovascular therapy. DSA is a must for imaging of below the knee arteries. In **Figures 2–10**, comparisons of the DSA and DA images of the left proximal tibial arteries are shown. In the DSA image, posterior tibial artery occlusion is well observed (**Figure 15A**). On the other hand, the DA image failed to show the tibio-peroneal trunk and occlusion of the posterior tibial artery (**Figure 15B**).

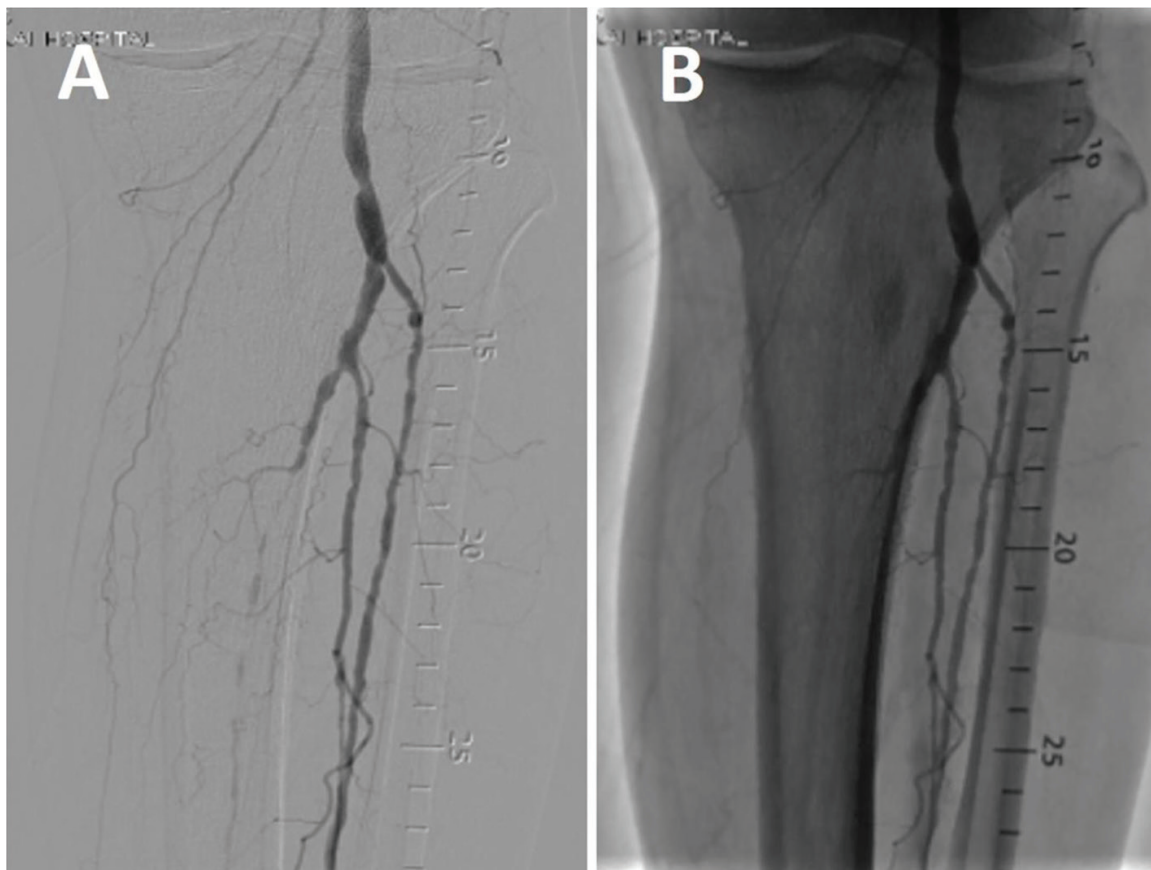


Figure 15. Proximal below the knee angiography, DSA (A) vs. DA (B).

A similar case of the left proximal below the knee artery is shown in **Figure 16**. In the DSA image, three tibial arteries are shown with multiple stenosis (**Figure 16A**). In the DA image, precise diagnosis cannot be made (**Figure 16B**).

Assessment of the distal tibial arteries is vital in evaluating below the ankle disease. Continuation from the anterior tibial artery to the dorsal artery and the posterior tibial artery to the plantar artery must be clarified. However, due to the bony structure, the DA image could not show these distal tibial and below the ankle arteries (**Figure 17**). In **Figure 17A**, the planter artery is not clearly visualized in the DSA image. In the DA image, most of the vessels remain un-visualized (**Figure 17B**).

2.4. Basic angiography for PAD

2.4.1. Angiography from the terminal aorta to below the knee artery

In an angiographic approach for PAD diagnosis, we need to assess three segments of the lower limb artery, that is, the aortoiliac, femoropopliteal and below the knee arteries. In **Figure 18**, the basic angiography is shown. First, angiography of the aortoiliac artery was taken (**Figure 18A**). The second angiography is an ipsilateral view of the proximal femoral artery (**Figure 18B**). In the right leg, a 30° right anterior oblique (RAO) view was chosen to separate the proximal SFA and PFA. Third, angiography from the CFA to the distal below the

ankle artery was taken by running the table (**Figure 18C**). After observing these three angiograms, we could assess in which segment stenosis or occlusion was located.

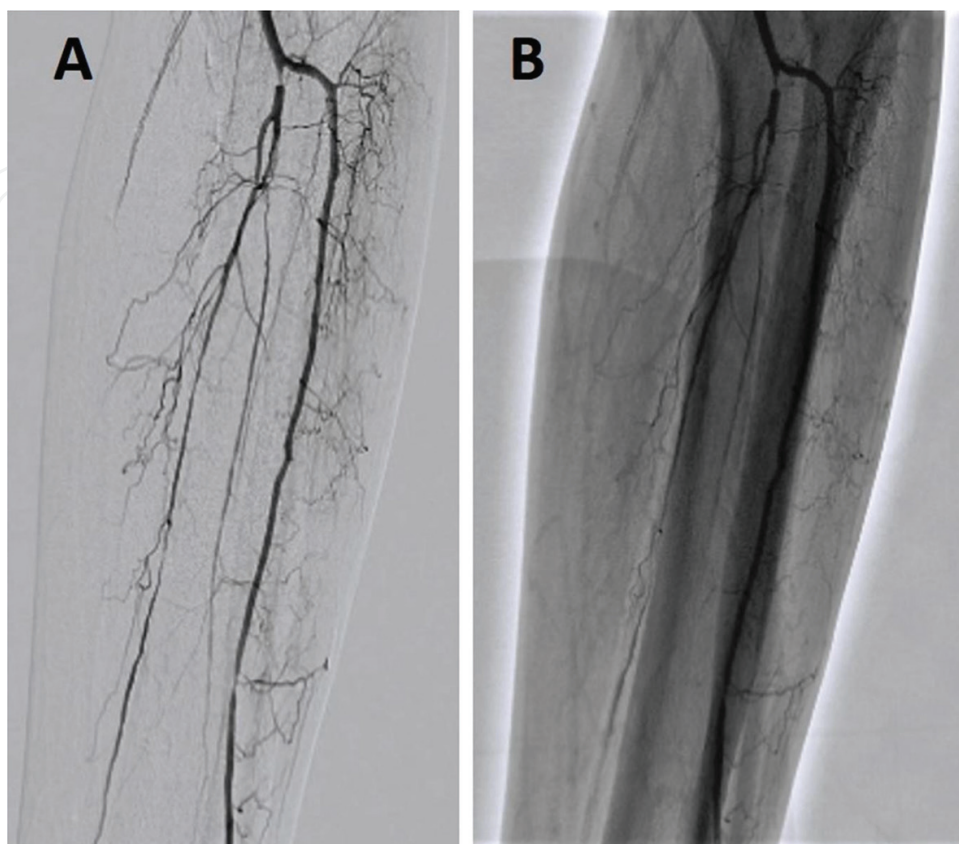


Figure 16. Mid-below the knee angiography, DSA (A) vs. DA (B).

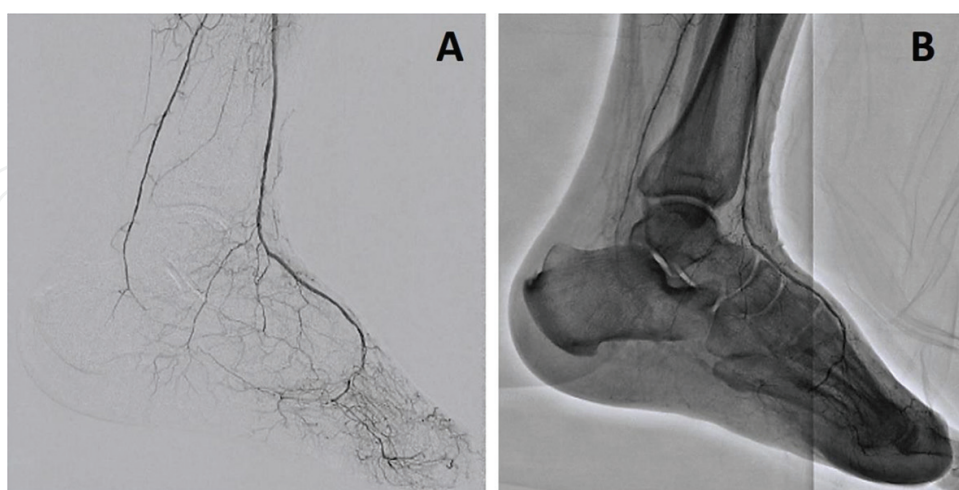


Figure 17. Below the ankle angiography, DSA (A) vs. DA (B).

A typical claudication with SFA disease is shown in **Figure 19**. Aortoiliac artery angiography showed no significant stenosis (**Figure 19A**). In the proximal femoral artery, there was no stenosis in the SFA and PFA (**Figure 19B**). Left limb angiography showed focal stenosis in the

mid-SFA while the left anterior tibial artery was not visualized (**Figure 19C**). By using DA, left SFA angiography was taken and revealed focal tight stenosis in the mid-SFA (**Figure 19D**). This DA image was used as reference in interventional work (**Figure 19D**).

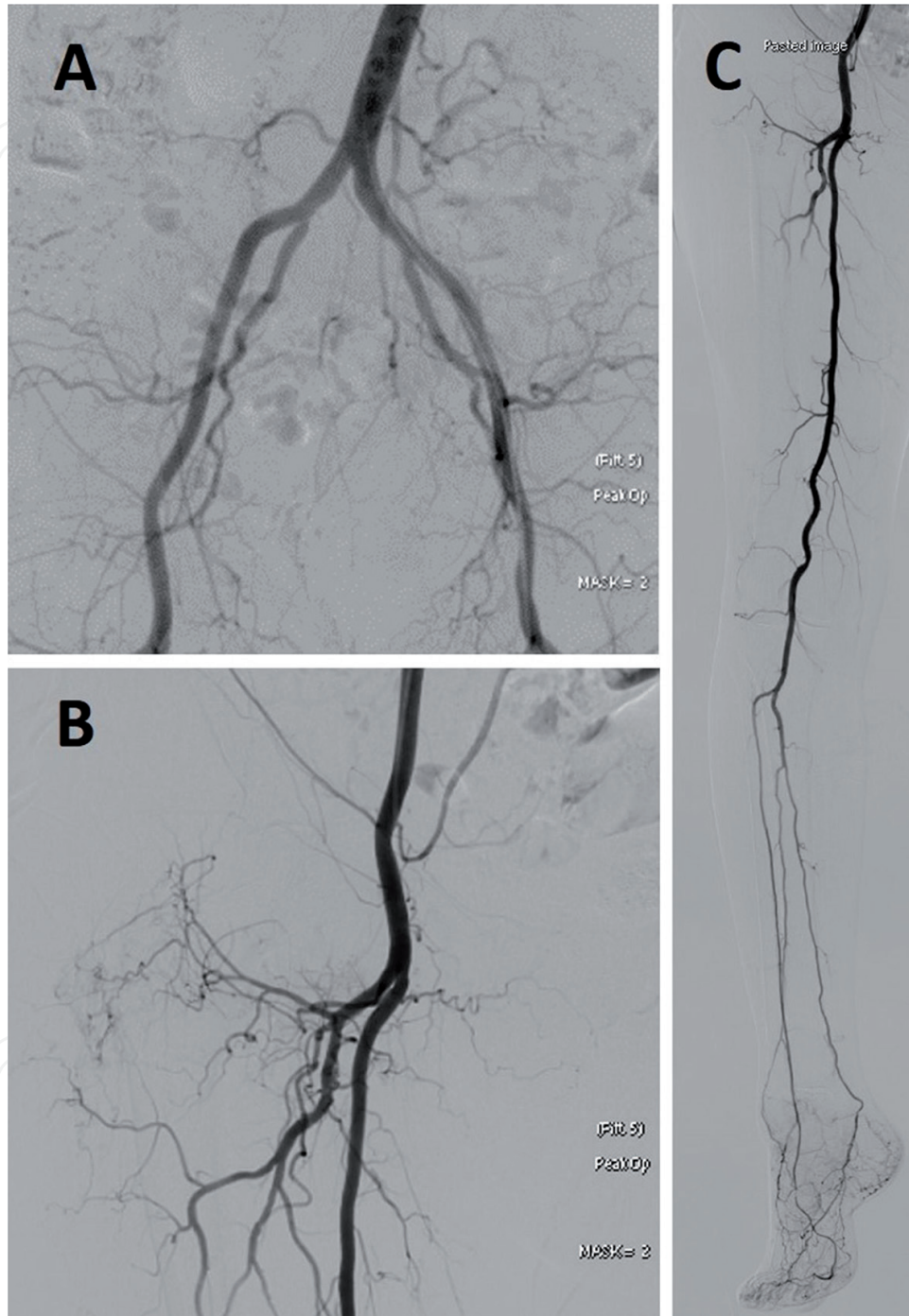


Figure 18. Basic lower limb artery angiography. (A) Aortoiliac artery angiography. (B) Proximal femoral artery by a 30° right anterior oblique view. (C) From the right common femoral artery to the distal below the ankle artery.

Figure 20 shows isolated below the knee artery disease. From the iliac to femoropopliteal artery level, no atherosclerotic changes could be observed (**Figure 20A** and **20B**). A lesion is located in the right below the knee arteries. Below the knee arteries showed a stenotic lesion

of the anterior tibial artery, and the posterior tibial artery and peroneal artery are occluded (**Figure 20C**). This type of lesion, that is, “isolated below the knee artery disease” is often found in patients with critical limb ischemia.

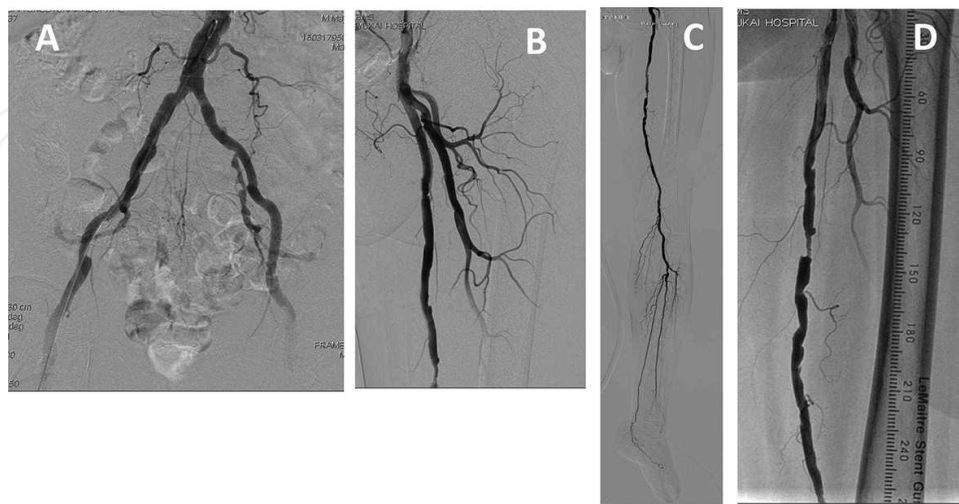


Figure 19. A typical claudication with SFA disease (A) Aortoiliac artery angiography showed no significant stenosis. (B) In the proximal femoral artery, there was no stenosis in the SFA and PFA. C: Left limb angiography showed focal stenosis in the mid-SFA. (D) Left SFA angiography revealed focal tight stenosis in the mid-SFA.

2.4.2. Magnification of images

The image size has two purposes: one is to see the whole vessel, for example, in the aortoiliac artery, visualization from the terminal aorta to both the right and left CFA (**Figure 21A**). The other is to better intervene on the target lesion utilizing appropriate magnification of the image size (**Figure 21B**). For wiring to this lesion, a 20 cm magnified image was taken and successful wiring was carried out using a 0.014 in. wire (**Figure 21B**).

In **Figure 22**, right SFA stent restenosis was visualized with a 30 cm image (**Figure 22A**). Moreover, using the 20 cm magnified mode, stent restenosis was well observed (**Figure 22B**).

In below the knee arteries, the whole image shows which vessels are diseased (**Figure 23A**). However, this running image does not give detailed information on the three tibial arteries. In the 30 cm image, the three proximal tibial arteries are well observed, and the peroneal and posterior tibial arteries are diffusely diseased (**Figure 23B**). The further magnified 20 cm image revealed that there is tight stenosis at the ostium of the right anterior tibial artery (**Figure 23C**).

2.4.3. Pre- and postinterventional image

Basically, all interventional work requires two images to be taken, that is, pre- and postintervention. These two images reveal the angiographic changes pre and post procedure. In **Figure 24A**, the femorofemoral bypass was occluded and a long total occlusion of the right iliac artery is seen. After successful recanalization and stenting, angiography of the exact same iliac artery was taken (**Figure 24B**).

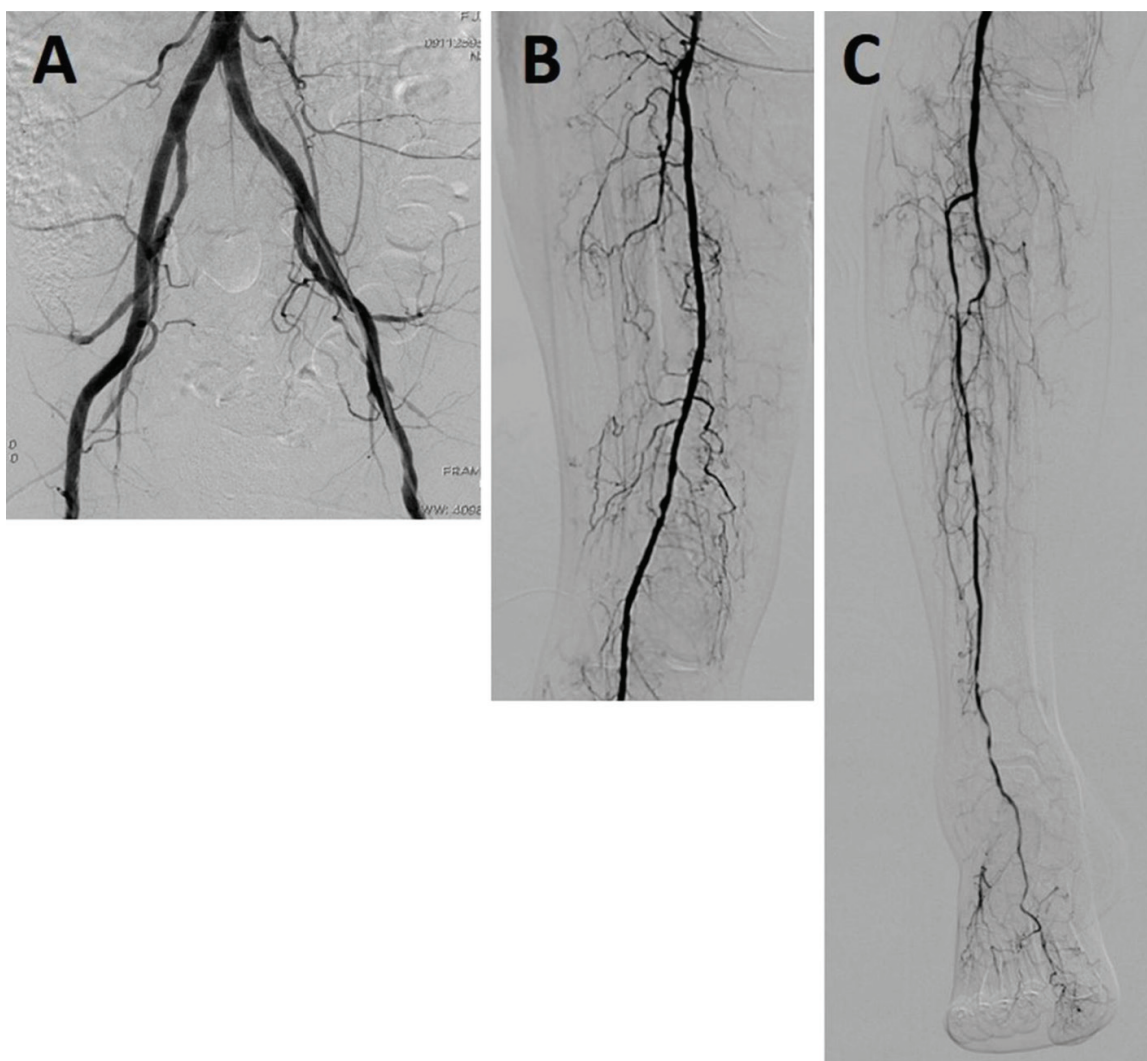


Figure 20. Basic lower limb artery angiography. Isolated below the knee artery disease. (A) Aortoiliac artery showed no disease. (B) Right femoropopliteal artery showed no disease. (C) Right below the knee arteries showed a stenotic lesion of the anterior tibial artery, and the posterior tibial artery and peroneal artery are occluded.

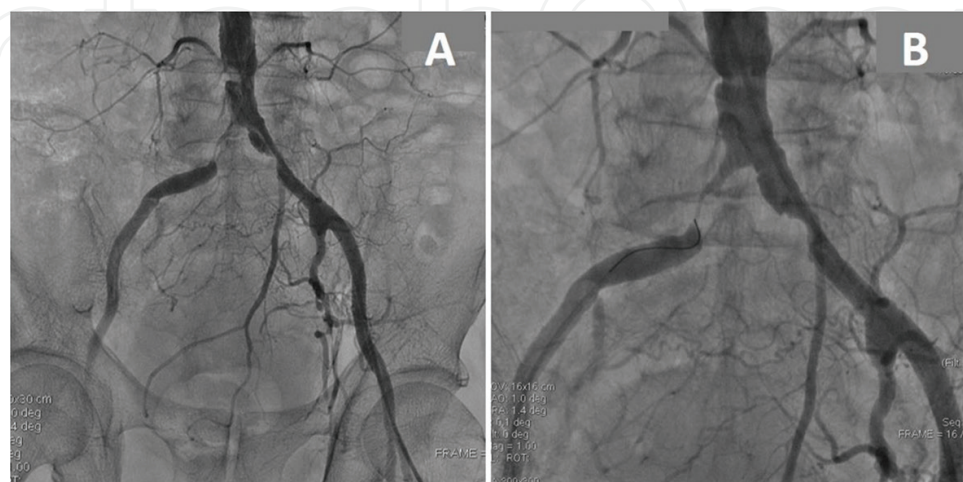


Figure 21. Iliac artery angiography, 30 cm (A) vs. 20 cm image (B).

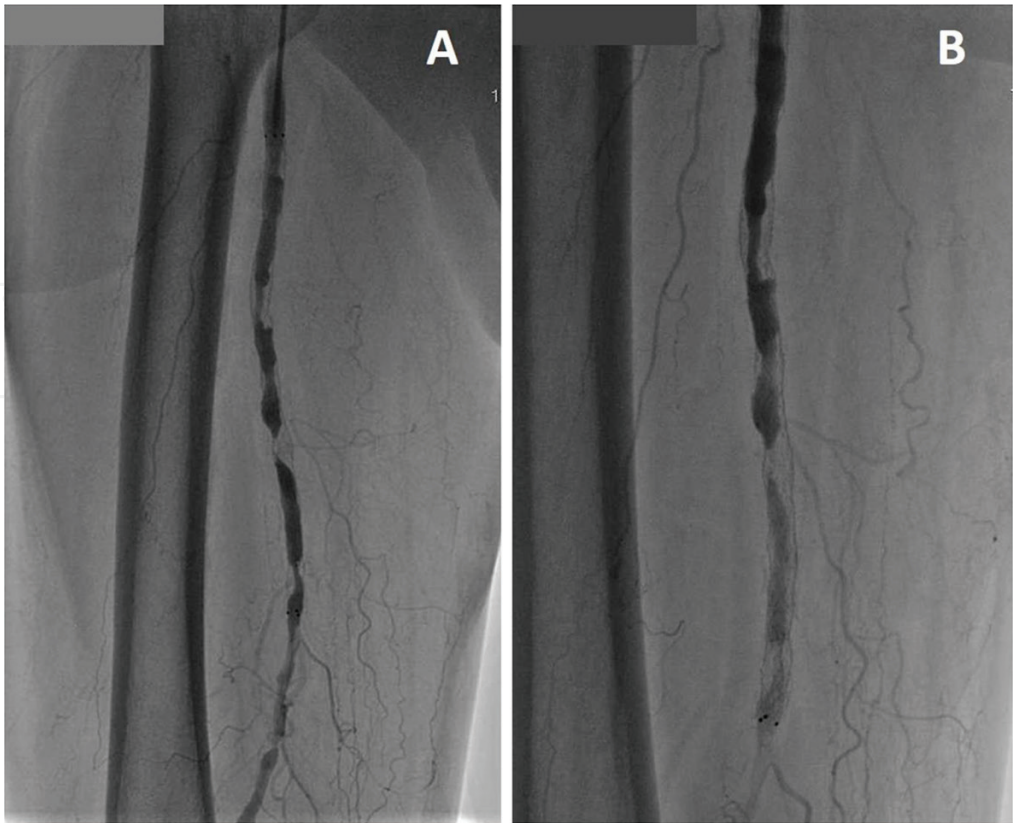


Figure 22. SFA angiography, 30 cm (A) vs. 20 cm image (B).

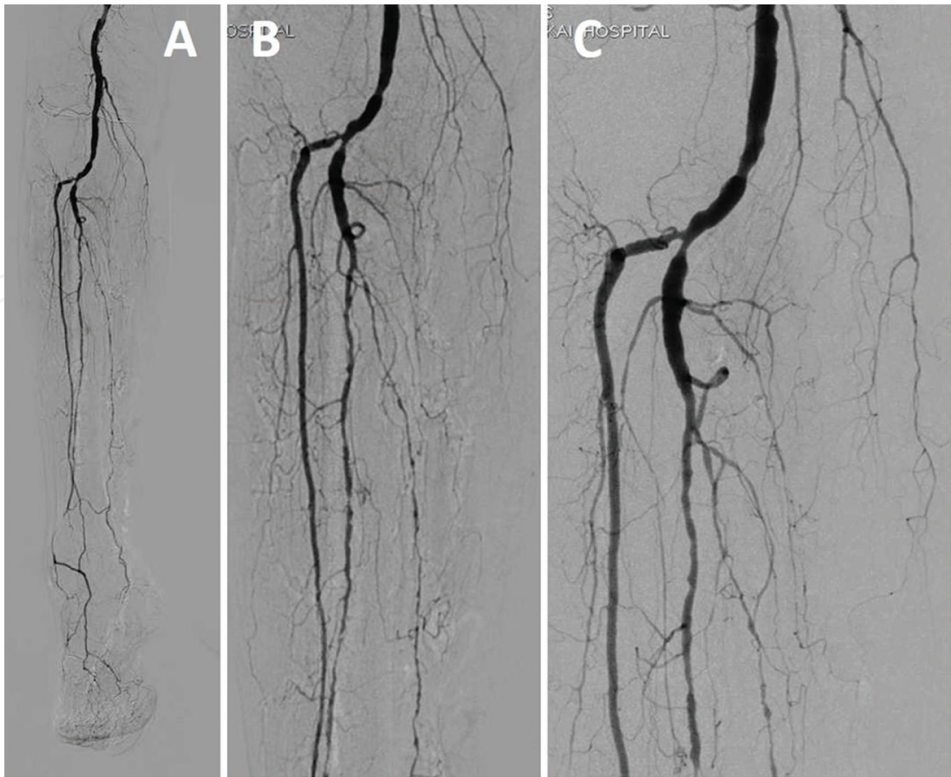
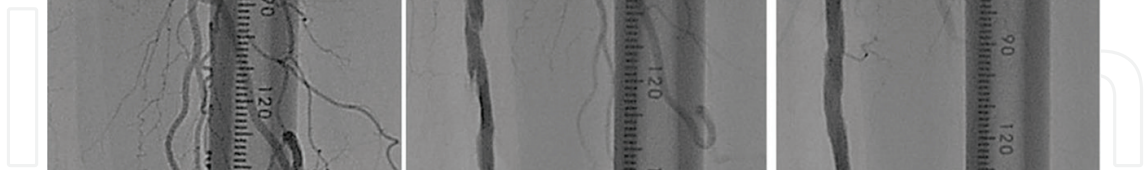


Figure 23. Below the knee angiography, 30 cm (A), 20 cm (B) and 16 cm images (C).



In **Figures 2–20**, typical left SFA occlusion was seen (**Figure 25A**). After balloon angioplasty, dissection and incomplete dilatation were observed (**Figure 25B**). Post stent angiography showed excellent dilatation of the left SFA lesion (**Figure 25C**). During the procedure, the table was frequently moved and oftentimes, post angiographic images were not taken in the different positions, giving a false impression of the postinterventional image.

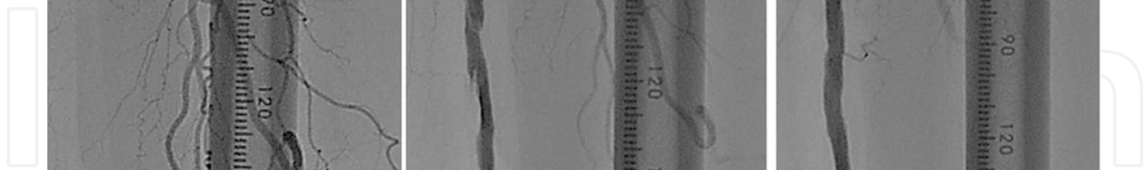


Figure 25. A case of SFA occlusion. Pre (A) and post SFA angiography (B).

3. Echo-guided puncture femoral artery puncture

The common femoral artery (CFA) remains the most widely accepted site for endovascular artery access. Vascular access site-related complications are a major cause of periprocedural morbidity among patients undergoing percutaneous endovascular intervention. In particular, patients with PAD may be more likely to have atherosclerosis affecting the CFA. Ultrasound guidance is an emerging trend for all percutaneous procedures and its use for femoral artery puncture has decreased vascular complications and improved first-pass success rates [4–6].

3.1. Retrograde common femoral artery puncture

The CFA is the main access site for angiography and interventional procedures. Among the various puncture sites, the retrograde CFA puncture is the most commonly employed and the basis of arterial punctures. We have described a safe and echo-guided technique for avoiding femoral access site complications.

3.1.1. Puncture point

The inferior border and upper border of the femoral head should be realized by fluoroscopy (**Figure 26A**). After checking the maximum arterial pulse (**Figure 26B**), Xylocaine is given 1 cm below the middle of the femoral head (**Figure 26C**).

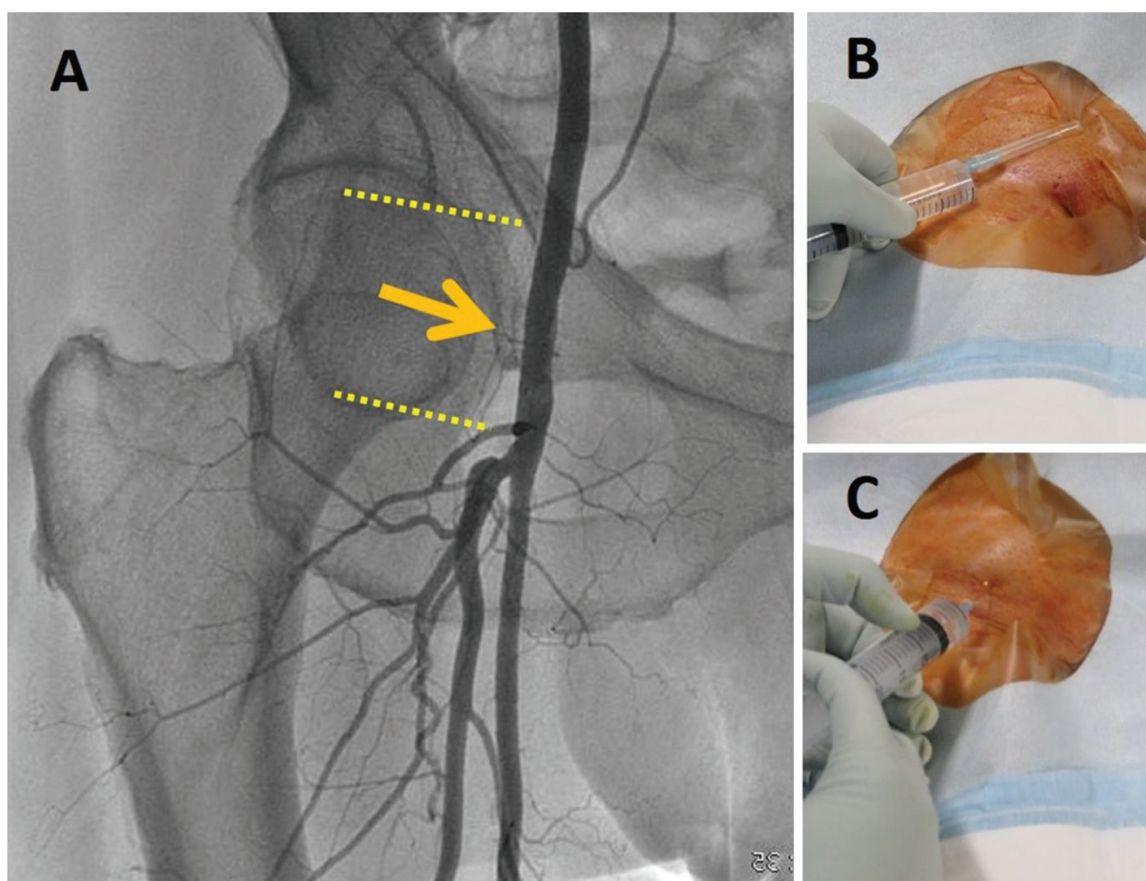


Figure 26. Puncture point of common femoral artery. (A) Realizing the inferior border and upper border of the femoral head by fluoroscopy. (B) Marking middle of femoral head. (C) Xylocaine to be given 1–2 cm below.

3.1.2. Preparation

A sheath and two types of wires were prepared. Once a puncture is performed, the wire should be ready to be inserted and if there is resistance, change to a different kind of wire is advised (**Figure 27**).

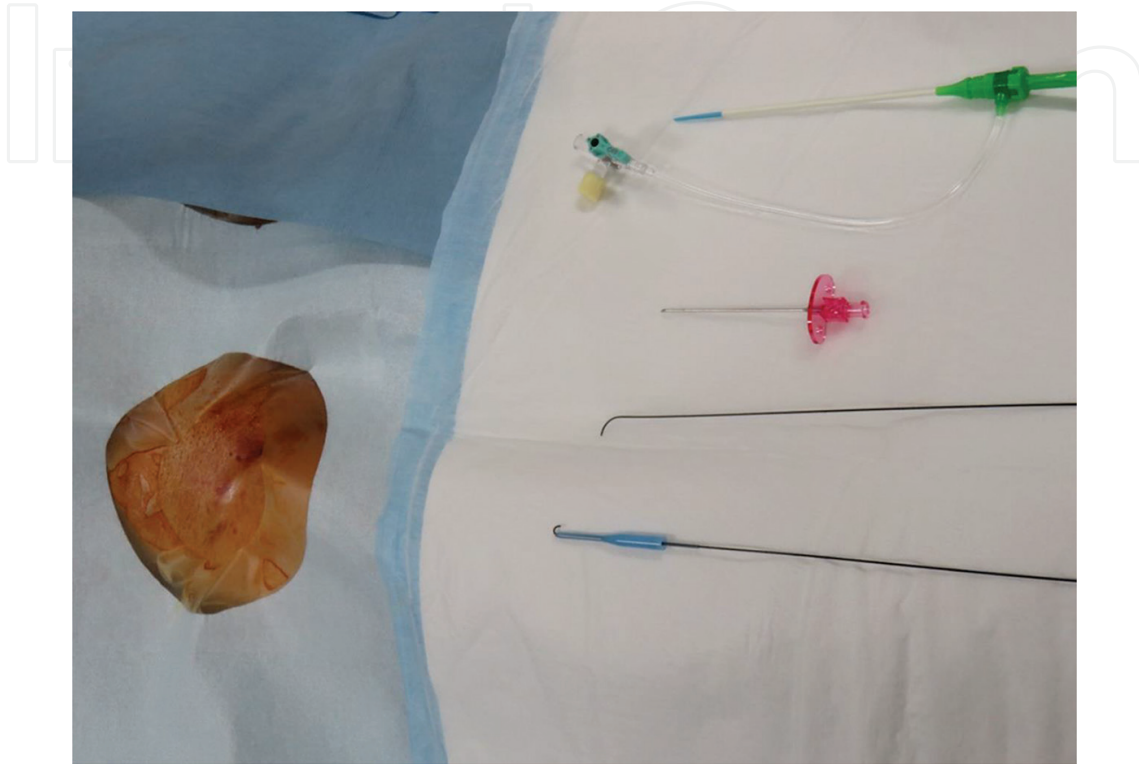


Figure 27. Preparation of sheath and two types of wire. Prepare sheath and two type wires close to puncture site. Once puncture completed, insert wire and if resistance encountered, change to different shape wire.

3.1.3. Echo scanning

For an echo-guided puncture (NEMIO MS, Toshiba, Tochigi, Japan), first, echo scanning was carried out from the upper CFA to proximal SFA (**Figure 28**). We could identify where the bifurcation is located. Either a long axis (**Figure 28A**) or short axis can be obtained (**Figure 28B** and **C**). A scan is basically made by a short-axis view. The ideal puncture site of the CFA can then be located (**Figure 28B**) and the bifurcation site can be identified (**Figure 28C**).

An echo image is best seen from the upper common femoral artery to the distal external iliac artery. When total reliance is on echo guidance, the puncture site locates higher than the middle femoral head. To avoid too low or high punctures, rechecking the puncture site by fluoroscopy is advised (**Figure 26A**).

3.1.4. Puncture

Arterial access was obtained with an 18-G needle (COOK Medical, Bloomington, Indiana) using the modified Seldinger technique. The needle was inserted at an angle of about 45° from the skin at a level just below the center of the femoral head. In viewing the short axis, the aim

should be for the top of the vessel. During flash backs of blood, a gentle wire insertion must be made. When resistance is felt, change from a straight wire to round shaped wire is advised (**Figure 29**). When the plaque in the CFA is found, a normal CFA puncture site should be located. In **Figure 29A**, the long-axis view showed the plaque in the CFA.

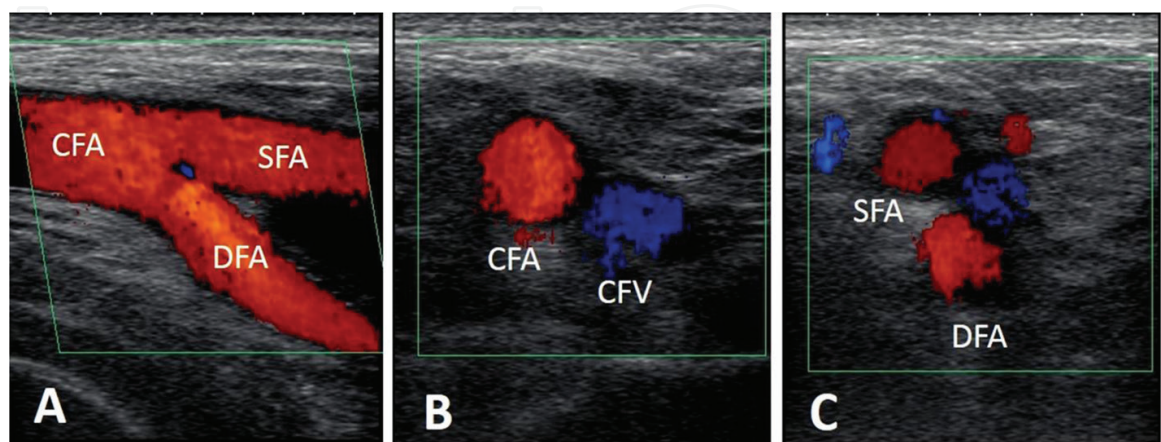


Figure 28. Color Doppler scanning from CFA to SFA and PFA. (A) Long-axis view of CFA and SFA. (B) Short-axis view of CFA. (C) Short-axis view of SFA and PFA. Using color Doppler, scan from upper CFA to SFA and PFA. Locate the ideal puncture site of CFA and identify the bifurcation point. CFA, common femoral artery; SFA, superficial femoral artery; PFA, profunda femoral artery.

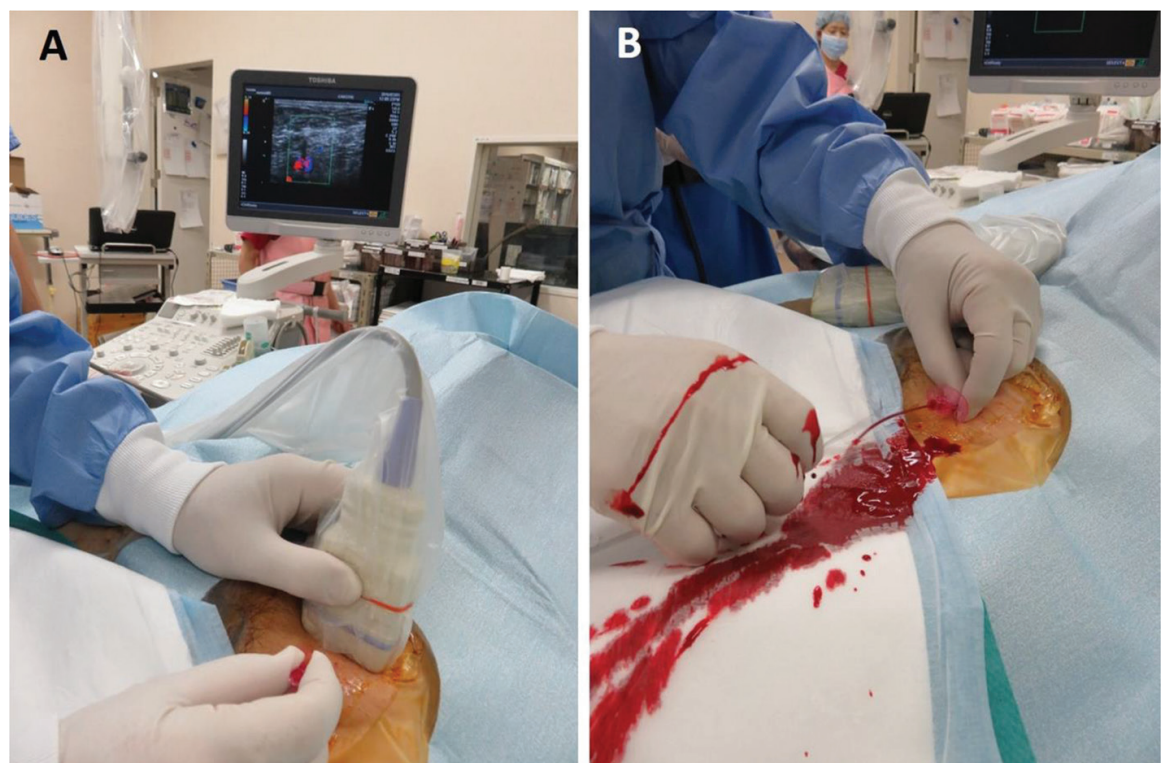


Figure 29. Puncture. (A) Echo guidance. (B) 18G needle puncture. In viewing short axis, aim for top of the vessel. During flash-back of blood, gentle wire insertion should be made. If resistance encountered, change straight wire to round shaped wire.

In this situation, a plaque free zone within the CFA should be located (**Figure 30B–D**).

In **Figure 31**, a puncture was made at the site of CFA disease and the wire went into false lumen, resulting in the total occlusion of the CFA.

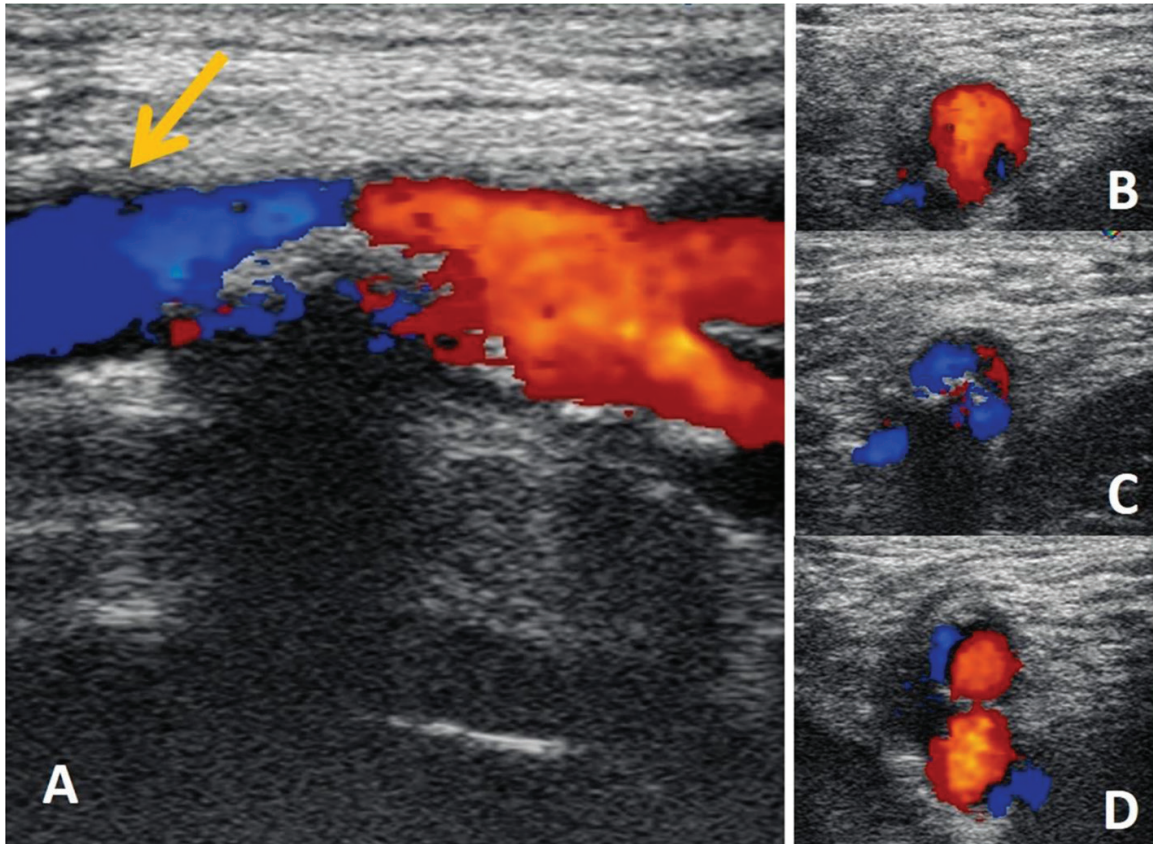


Figure 30. Presence of CFA plaque. (A) Long-axis view of CFA and SFA. Note CFA plaque. (B) Plaque free site of CFA in short axis. (C) Presence of plaque. Should not be punctured. (D) SFA and PFA level. When finding plaque in the CFA (A), should look for normal CFA puncture site. Must find plaque free zone within CFA. CFA, common femoral artery; SFA, superficial femoral artery; PFA, profunda femoral artery.

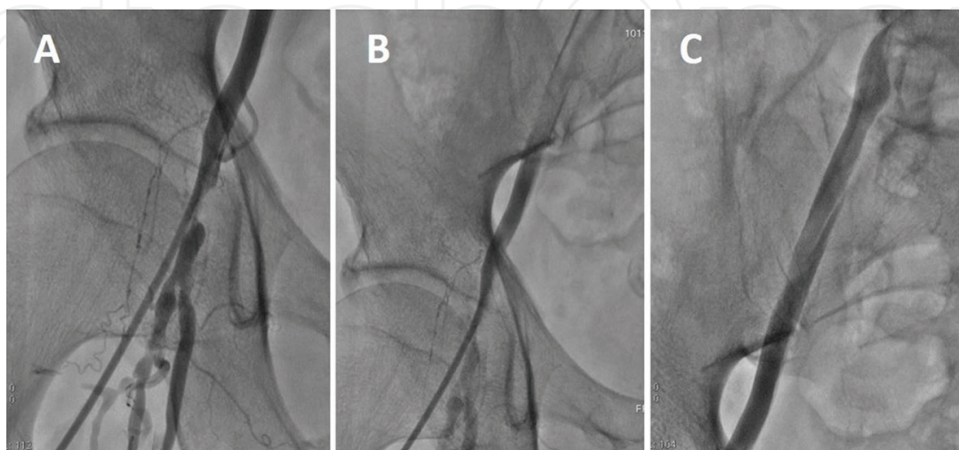


Figure 31. Puncture of common femoral artery plaque. (A) Puncture into CFA plaque. Creates false lumen. (B) TIMI 0 flow. (C) Dissection of iliac artery. Without knowledge of CFA disease, puncture was made. Wire went into false lumen and ended up in total occlusion of CFA.

3.2. Antegrade common femoral artery puncture

For treatment of femoropopliteal artery disease, the standard approach has been to access the contralateral common femoral artery (CFA). However, an ipsilateral, antegrade CFA approach has certain advantages. Compared to the contralateral approach, access to the lesion distance is short which in turn improves the responsiveness of the wire handling used to perform the intervention. In other clinical situations such as post aorto-bi-femoral surgical bypass, deployment of iliac kissing stents, post stent grafting and for aortoiliac occlusive disease, an antegrade approach is the method of choice to reach the lesion. The advantages and disadvantages are shown in **Table 2**.

The CFA is approximately 4–5 cm in length and arises from the external iliac artery (EIA) as it passes below the inguinal ligament. It then bifurcates into the PFA and SFA. An anatomical knowledge of the level of origin for the PFA is important in avoiding retroperitoneal bleeding, iatrogenic femoral arterial-venous fistula and/or formation of a pseudo aneurysm. The most lethal complication of femoral access remains retroperitoneal hemorrhaging due to a high puncture. Thus, the best first step toward reducing the incidence of retroperitoneal bleeding is to prevent high punctures.

3.2.1. Preparation of an antegrade puncture

As we perform in a retrograde puncture, two kinds of wires should be at hand. The initial sheath we place is always the 4Fr size sheath (**Figure 32**).

The main reason is, when obtaining access to the CFA fails, the sheath can be easily withdrawn or left in the PFA. Once placing the sheath in the SFA is successful, it can be changed to any sheath as desired. Pointing to the middle of the femoral head, local xylocaine should be given around the inguinal ligamentum (**Figure 33**).

Echo was applied in the same way. However, the proximal CFA to external iliac artery is well observed by echo and may result in a very high puncture site. Under fluoroscopic guidance with echo assistance, point to the middle of the CFA.

3.2.2. Puncture

A puncture should be made by aiming an imaginary line over the center of the femoral head. The maximum level of bifurcation should be at or below the inferior border of the femoral head (**Figure 34A**). In about 1/4th of cases, bifurcation locates in the CFA (**Figure 34B**). In **Figure 34B**, the bifurcation point is in the middle of the CFA and there is a short margin for the antegrade puncture site.

3.2.3. Two-wire technique

Even when the puncture site is above the bifurcation, the wire may go to the PFA. In this situation, we use a two-wire technique (**Figure 35**). If the wire goes to the PFA, the first step is to place a 4Fr sheath into the PFA. Two short 0.025 in. wires are inserted into the RFA (**Figure 35A**). Withdrawing the sheath, one 0.025 in. wire should be manipulated into the SFA

(**Figure 35B**). Once the SFA is accessed, leaving one wire in the PFA, the other wire should be advanced to the SFA (**Figure 35C**). After confirming the wire in the SFA, the other PFA wire is withdrawn and a 4Fr sheath should be placed into the SFA (**Figure 35D**). If the sheath comes out, it can be repositioned back into the PFA by a 0.025 in. wire.

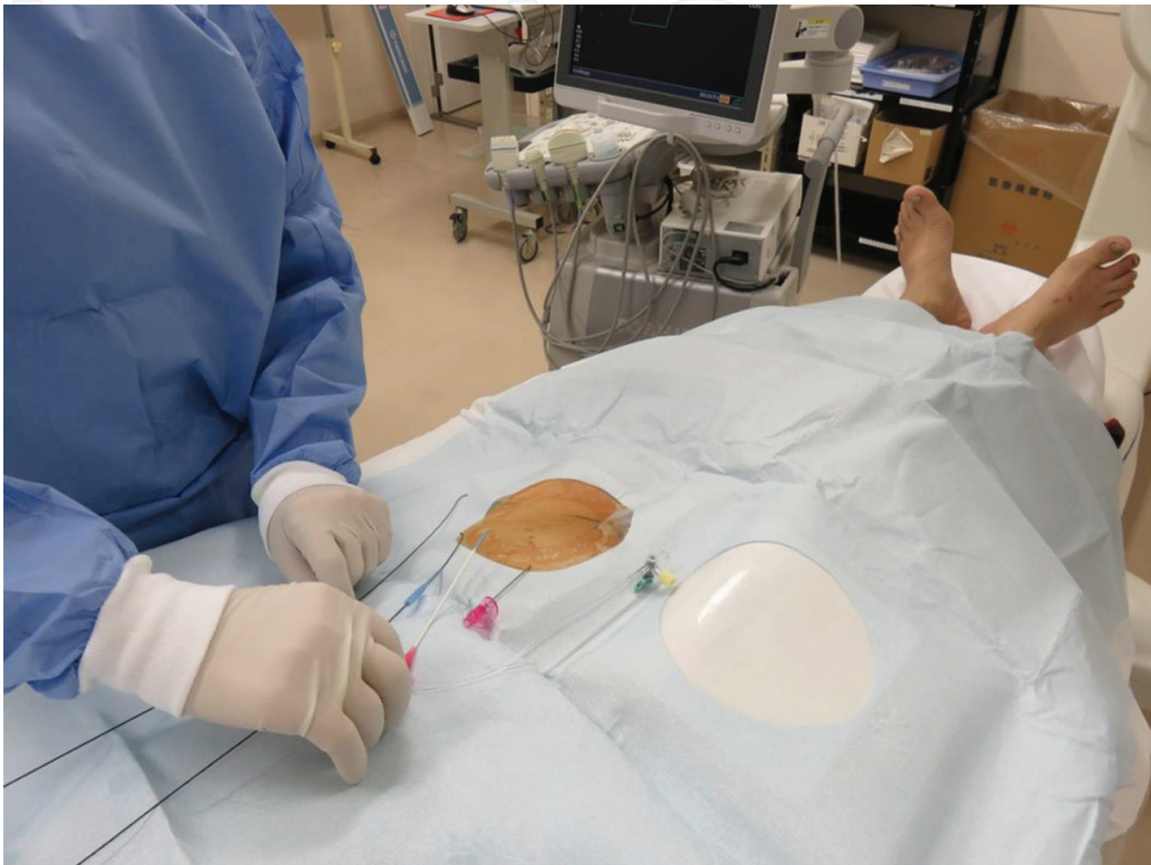

Figure 32. Preparation of antegrade puncture. 18G needle, 4Fr sheath and two kinds of wire at hand.

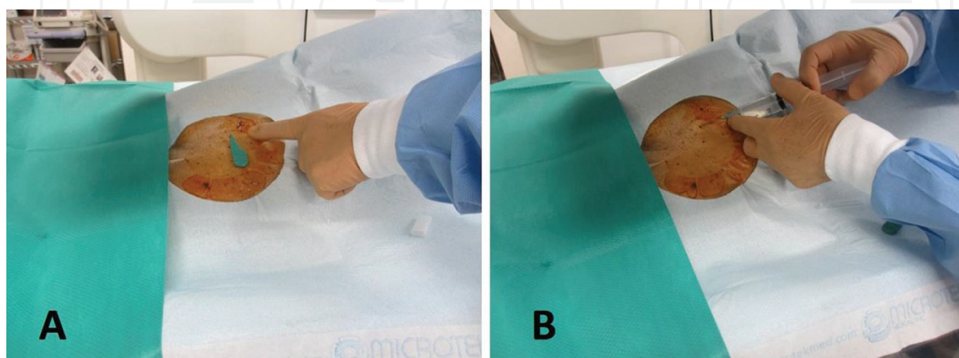


Figure 33. Antegrade puncture of common femoral artery. Puncture site. (A) Locate middle of femora; head. (B) Local xylocaine to be given at inguinal ligamentum.

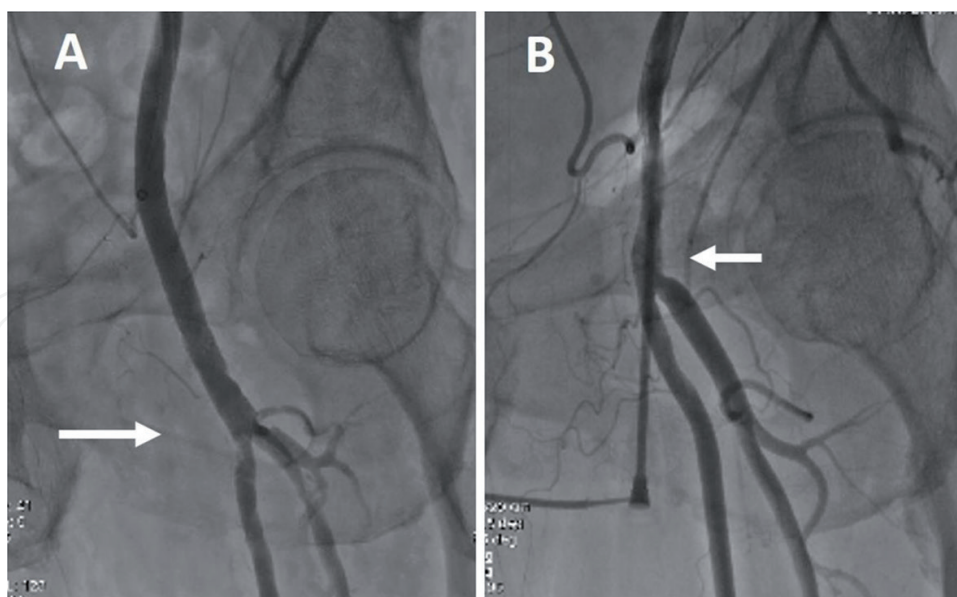


Figure 34. Bifurcation point of CFA to SFA. (A) Level of the bifurcation is below the inferior border of the femoral head. (B) The bifurcation point is in the middle of CFA and only short margin for ideal puncture site. CFA, common femoral artery.

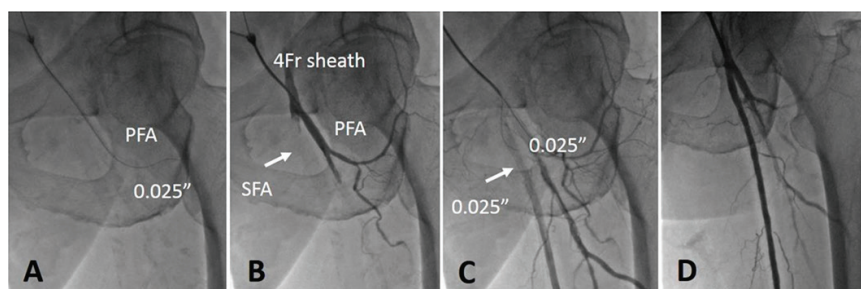


Figure 35. Two wire technique. (A) If wire goes to PFA, the first step is to place a 4Fr sheath into PFA. Two short 0.025 in. wires are inserted into PFA. (B) Withdrawing sheath, one 0.025 in. wire to find SFA leaving another wire in PFA (**Figure 10B**). (C) Once SFA obtained, wire advanced to SFA (**Figure 10C**). (D) After confirming wire in SFA, other PFA wire withdrawn and 4Fr sheath placed into SFA. SFA, superficial femoral artery; PFA, profunda femoral artery.

3.2.4. High bifurcation case

After surveying the CFA by echo, we may find high bifurcation of the SFA and PFA. In these cases, high puncture carries the risk of retroperitoneal bleeding. The puncture point should be in the range of the femoral head. In this situation, puncturing the SFA is one option. In **Figure 36**, there is high bifurcation and a CFA puncture is almost impossible. In this case, we decided to puncture the proximal SFA.

3.2.5. Sheath kinking

The angle of puncture should be more than 60° and almost vertical. After sheath insertion, care to avoid sheath kinking is advised. Once a hematoma is observed with sheath kinking, change to a larger size anti-kink sheath is necessary. In **Figure 37**, the initial 4Fr sheath was kinked (**Figure 37A**) and hematoma formation was detected. After the 4Fr sheath was replaced with a 6Fr sheath, the hematoma was stabilized (**Figure 37B**).

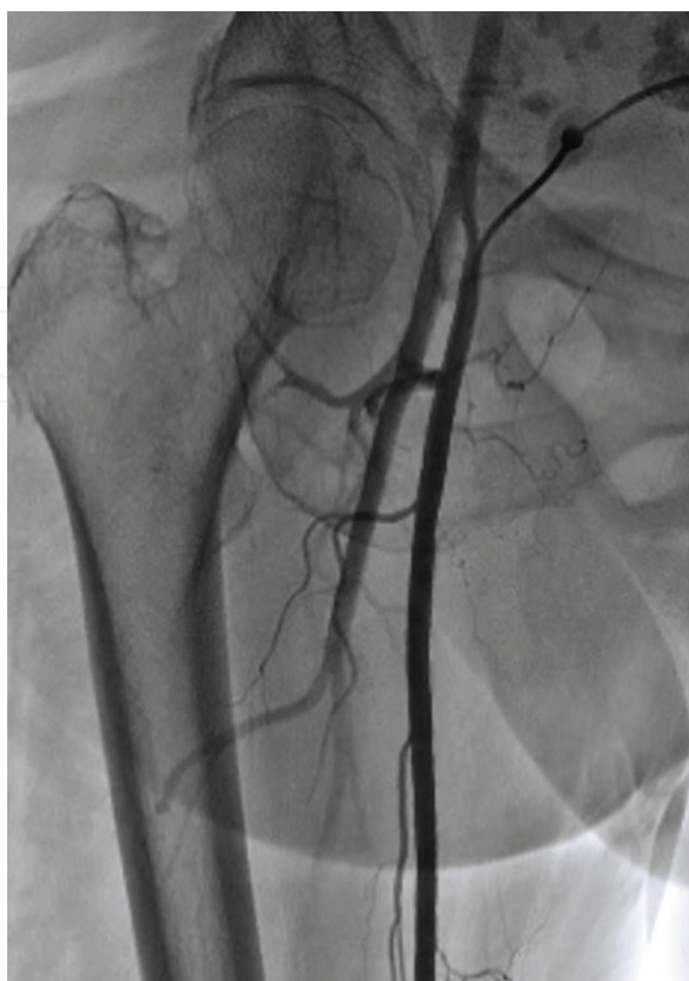


Figure 36. SFA puncture in high bifurcation case. After surveying CFA by echo, observed high bifurcation of SFA and PFA. In this situation, puncturing SFA is one option.

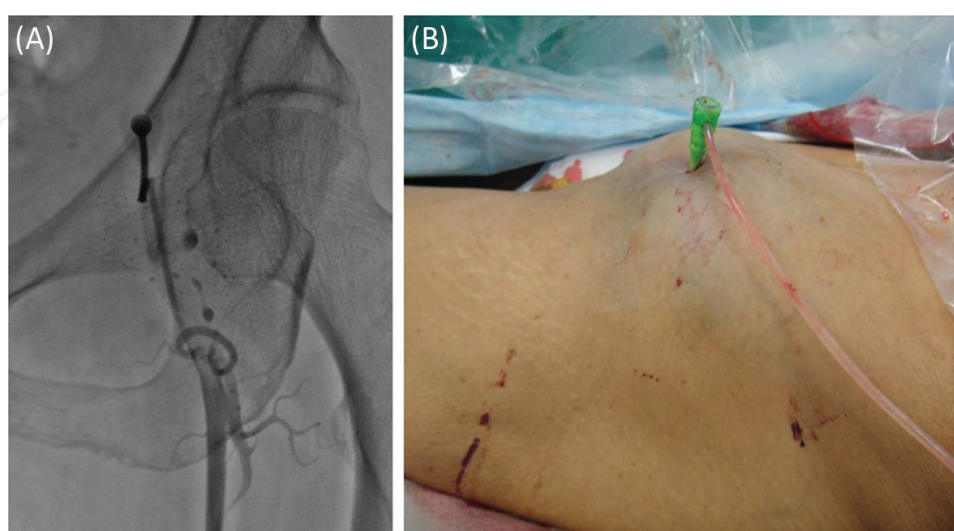


Figure 37. Sheath kinking during antegrade puncture. (A) Angle of puncture is more than 60° and almost vertical. After inserting sheath, observed sheath kinking. (B) 4Fr sheath replaced with 6Fr sheath and hematoma stabilized.

4. CO₂ angiography

The number of patients with chronic kidney disease (CKD) complicated with PAD is significantly increasing. In these patients, iodinated contrast may enhance the risk of contrast-induced nephropathy (CIN). CIN is an acute renal injury and may lead to irreversible loss of renal function. Carbon dioxide (CO₂) gas angiography is indicated for those with renal insufficiency and high-risk patients who are allergic to iodinated contrast material [7]. CO₂ is imaged using digital subtraction equipment with a CO₂ software program. Modern DSA equipment has a software program that allows integration of multiple images into a single composite image.

4.1. CO₂ delivery system

The system consists of a medical grade CO₂ gas cylinder with a regulator, a disposable sterile plastic tube with a bacteria-removal filter, and a 50-ml delivery syringe (**Figure 38**).

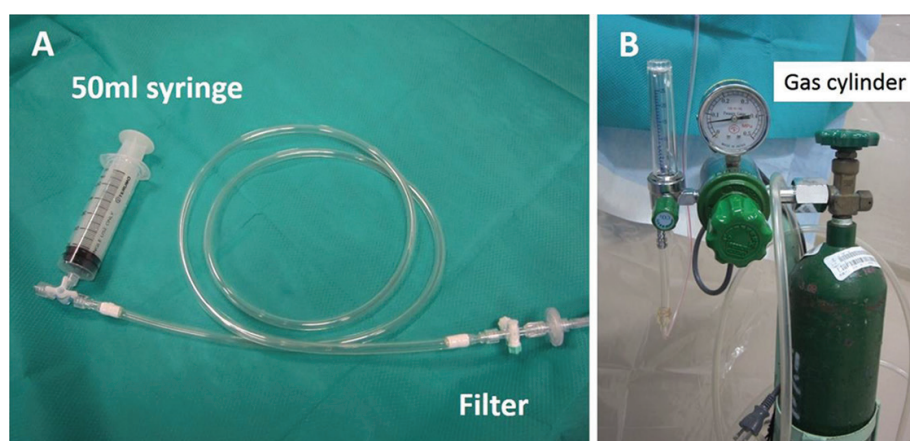


Figure 38. CO₂ delivery system. (A) A disposable, sterile plastic tube with a bacteria-removal filter and a 50-ml delivery syringe; (B) a medical grade CO₂ gas cylinder with a regulator.

Collection of CO₂ to the syringe and injection system should be separated to avoid erroneous gas injection to an artery (**Figure 39**).

The gas should be purged three to four times during collection to prevent room air contamination from the tube and delivery syringe in the circuit and then filled with gas at a stationary flow of 2 l/min. About 40 cc of aspirated gas was filled into the delivery syringe and 30–40 cm³ of CO₂ gas was manually injected into the vessel leaving about 5 cm³ in the injection syringe (**Figure 40**).

After gas injection, the remaining gas and blood were carefully aspirated into the syringe. Gas injections were spaced at least 30 s apart. Although we do not have experience in mechanical injection, manual injection is sufficient to inject 30–40 cc of CO₂. However, the safety of injecting large amounts of CO₂ is not guaranteed [8]. If a patient complains of abdominal pain, further CO₂ injection should be avoided. And if the angiogram shows a slow flow, further CO₂ delivery by syringe should also be stopped (**Table 3**).

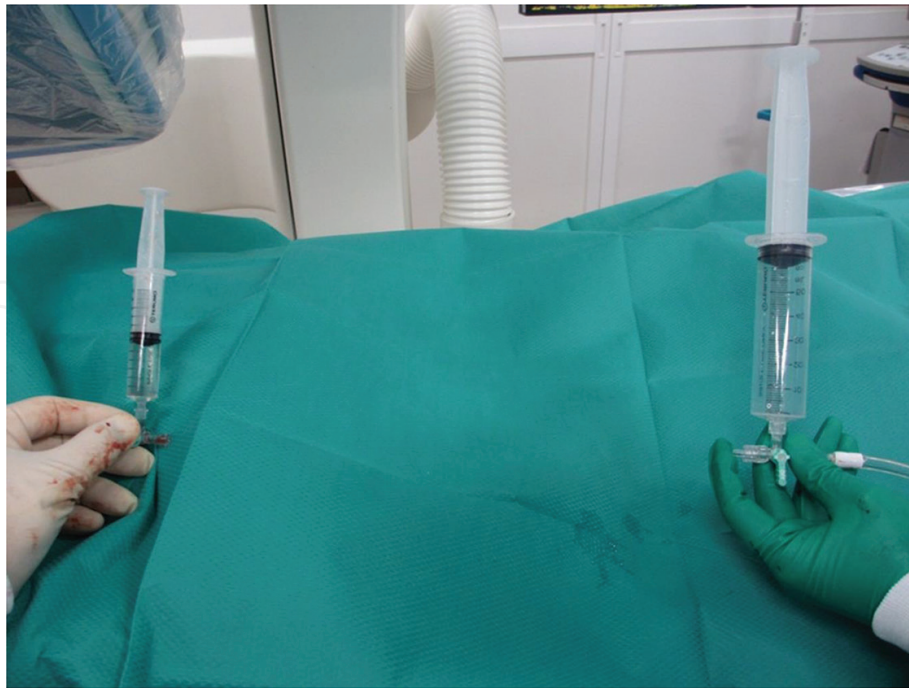

Figure 39. Separate system between CO₂ suction and injection. Collection of CO₂ to syringe (left) and injection system (right) should be separated to avoid erroneous gas injection to artery.

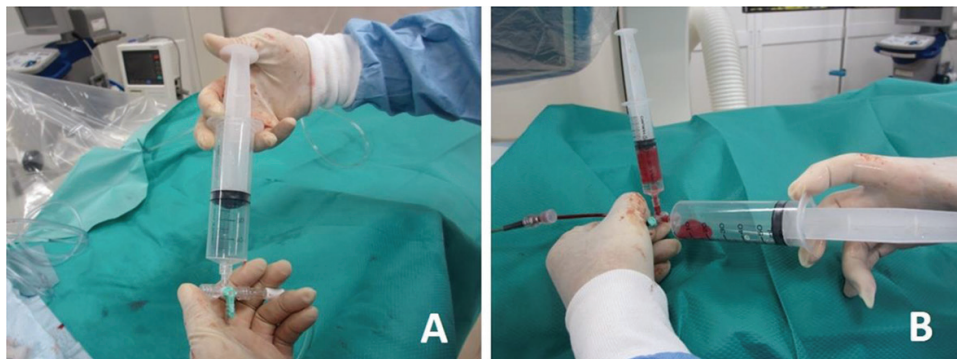


Figure 40. Infusion and injection of CO₂ gas by 50 cc syringe. (A) Gas was purged 3–4 times during collection to exclude room air contamination from the tube and delivery syringe in circuit. Filled with gas at a stationary flow of 2 l/min. (B) 40 cc of aspirated gas filled into delivery syringe, 30–40 cm³ of CO₂ gas manually injected into the vessel, leaving about 5 cm³ in the injection syringe.

4.2. Iliac artery angiography by CO₂

The iliac artery is a large sized vessel and its inflow is the larger abdominal aorta. Moreover, there are two internal iliac arteries and two femoral arteries. CO₂ angiography requires displacement of all or most of the blood to achieve adequate images. Due to such anatomical reasons, the iliac artery is not well suited for CO₂ angiography. In **Figure 41A**, CO₂ was administered from a 5Fr pigtail catheter at the terminal aorta and, in the left external iliac artery, CO₂ was unfilled and there appears to be stenosis. With contrast angiography, no stenotic lesion is seen in the left external iliac artery (**Figure 41B**).

- Make a separate system with CO₂ cylinder
- Average dose of CO₂ is about 30 ml by using 50 ml syringe
- Be sure complete air excretion
- Manual injection not a mechanical injection
- If patient complains of abdominal pain, avoid further injection
- When a slow flow are observed, avoid an further CO₂ injection

Table 3. Setup of CO₂ delivery system and CO₂ injection.

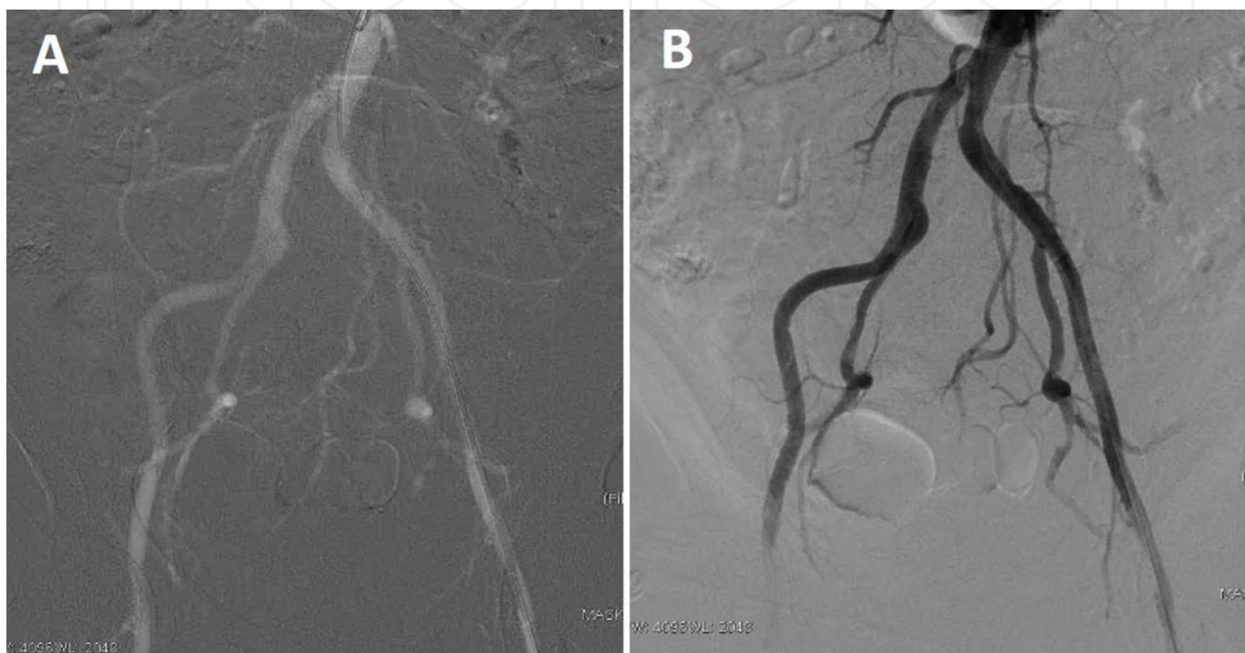

Figure 41. Iliac artery angiography by CO₂ and DSA. (A) CO₂ administered from 5Fr pigtail catheter at the terminal aorta, in left external iliac artery, CO₂ unfilled and stenosis suspected. (B) In DSA, no stenotic lesion in left external iliac artery observed.

In **Figure 42A**, total occlusion of the left external iliac artery is observed. CO₂ injection from the terminal aorta shows chronic total occlusion (CTO) of the left external iliac artery. To confirm CTO, a crossover sheath was positioned at the left common iliac artery and CO₂ injection was repeated at a right anterior oblique (RAO) projection of 30° (**Figure 42B**). In this angiogram, CTO is clearly visualized and the left common femoral artery is well observed via the collateral flow from the deep circumflex artery. In CO₂ angiography of the iliac artery, the angiogram is hampered by bowel and gas movements.

In **Figure 43A**, the left iliac artery is not seen, but contrast angiography shows a clear picture of the entire iliac arteries (**Figure 43B**).

Generally speaking, when the iliac artery is not well visualized by CO₂ angiography, increasing the volume of CO₂ in the iliac abdominal aorta might be considered. However, there are important visceral vessels and the risk of various complications due to the injection of gas in these vessels must also be considered.

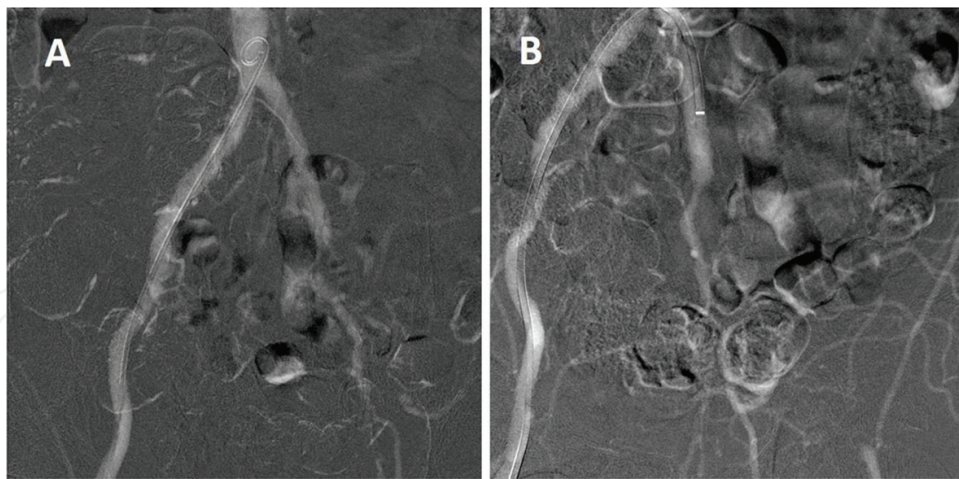


Figure 42. Left external iliac artery occlusion by CO₂ angiography. (A) CO₂ injection from terminal aorta in AP view. Total occlusion of left external iliac artery. (B) CO₂ injection from left common iliac artery by RAO 30.

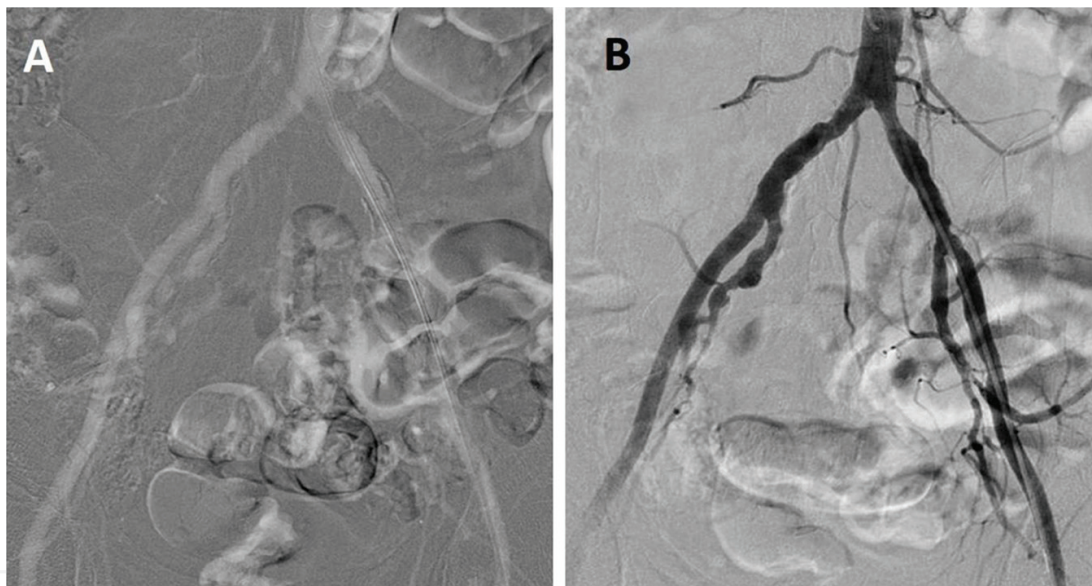


Figure 43. Bowel gas in iliac artery angiography. (A) In CO₂ angiography, left external iliac artery is hampered by bowel gas. (B) DSA shows a clear picture of whole iliac arteries.

4.3. Femoropopliteal artery angiography by CO₂

Visualization by CO₂ angiography is best suited for the femoropopliteal artery segment. The main reason is that the superficial femoral artery (SFA) is a straight vessel with small branches. The vessels sizes are about 4–7 mm and could easily be filled by CO₂ gas. In **Figure 44**, there are three kinds of SFA angiograms for the same patient. Digital angiography enabled visualization of the background (**Figure 44A**) while DSA could obtain the highest quality angiogram (**Figure 44B**). CO₂ angiography has poor visibility of small distal branches. However, it could visualize SFA fairly well and can be used as a substitute for contrast angiography (**Figure 44C**).

Similarly, the popliteal artery could be well observed even with the CO₂ angiogram (**Figure 45**).

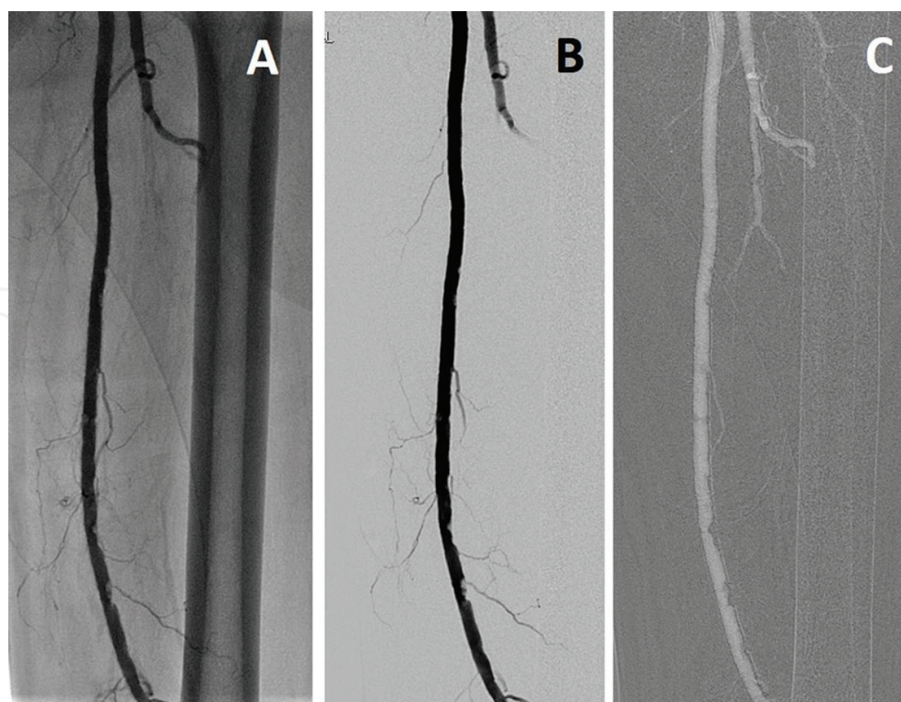


Figure 44. SFA angiography by digital, DSA and CO₂. (A) Digital angiography could visualize background to be used as reference. (B) DSA obtained most accurate image. (C) CO₂ angiography cannot replace digital angiography, but can be used as a substitute for contrast angiography.

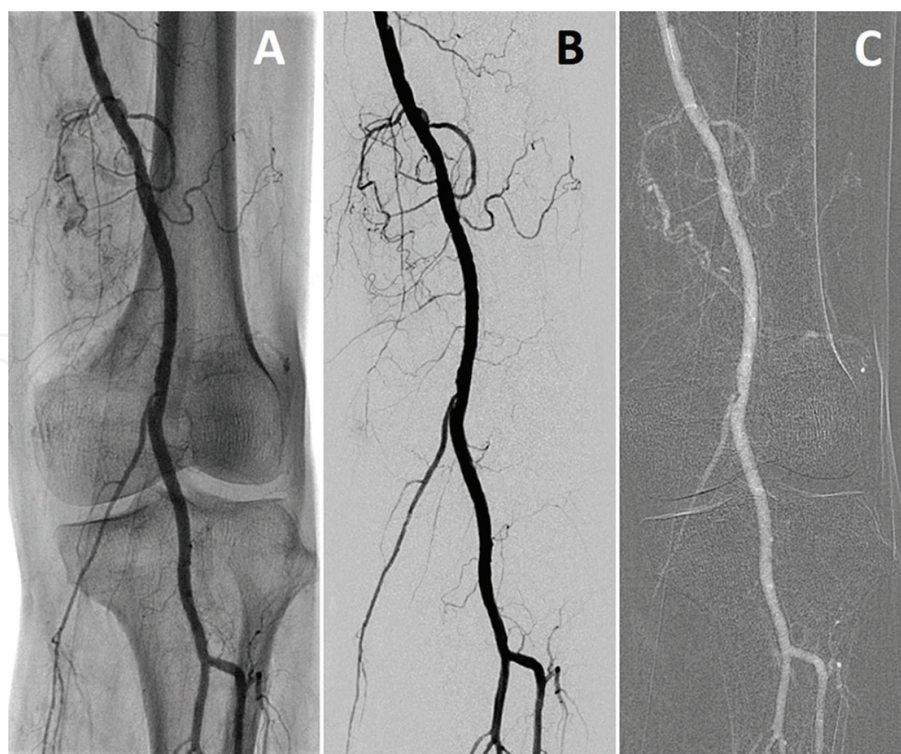


Figure 45. Popliteal artery angiography by digital, DSA and CO₂. (A) Digital angiography could visualize background to be used as reference. (B) DSA obtained most accurate image. (C) CO₂ angiography obtained similar image to DSA.

In the DA angiogram, distal SFA is not well visualized compared to the DSA image (**Figure 45A**). In fact, a perfect image was obtained by DSA (**Figure 45B**). The CO₂ angiogram shows a fairly clear picture of the distal SFA and popliteal artery (**Figure 45C**) while the right femoropopliteal artery was visualized by CO₂ (**Figure 46**). In proximal SFA, separation between the SFA and deep femoral artery (DFA) is well observed (**Figure 46A**). In the mid-SFA, no stenosis is seen (**Figure 46B**). In the distal SFA and popliteal artery, moderate stenosis is detected (**Figure 46C**).

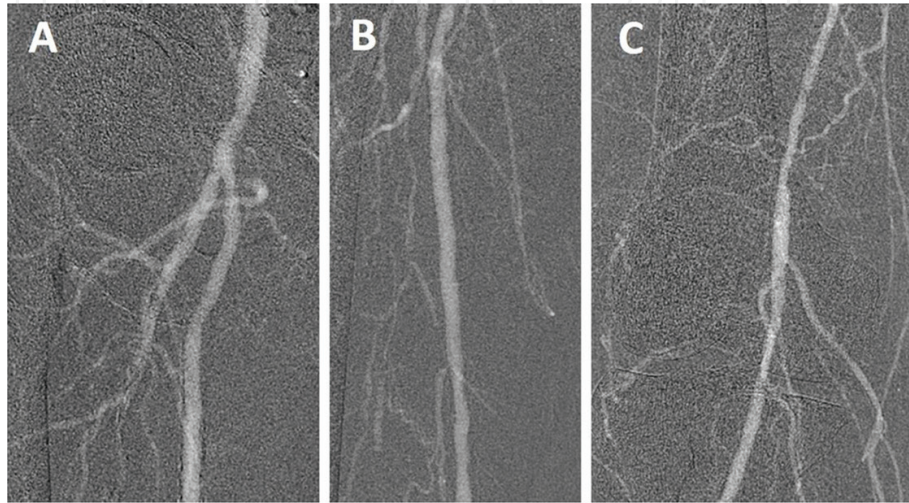


Figure 46. CO₂ angiography for right femoropopliteal artery. (A) In proximal SFA, separation between SFA and deep femoral artery (DFA) is well shown by RAO view. (B) In mid-SFA, there is no stenosis. (C) In distal SFA and the popliteal artery, there is moderate stenosis.

Comparisons between CO₂ angiography and digital angiography for the diseased SFA are shown in **Figures 47** and **48**. Stenosis is seen in the distal SFA in **Figure 47**. Both CO₂ (**Figure 47A**) and DA images (**Figure 47B**) could identify distal SFA stenosis.

The totally occluded left SFA was well visualized by CO₂ angiography (**Figure 48A**). Although DSA shows a clearer image with a rich collateral network (**Figure 48B**), the CO₂ image can also be used for interventional work.

The CTO of the left SFA was intervened using CO₂ angiography (**Figure 49**) in a patient with stage 4 CKD. The CO₂ angiogram showed typical CTO of the SFA (**Figure 49A**). After successful wiring, balloon angioplasty was performed (**Figure 49B**). Contrast was only used in the final angiogram (**Figure 49C**).

4.4. Below the knee angiography by CO₂

CO₂ angiography cannot be applied in below the knee (BK) work. The arterial vessel size below the knee is between 1.5 and 3 mm in diameter and the accuracy of CO₂ angiography is insufficient. Above all, in BK cases, most of the patients have critical limb ischemia and cannot tolerate large amounts of gas injection. In **Figure 50**, proximal right below the knee angiogra-

phy was performed by CO₂ (**Figure 50A**) and DSA (**Figure 50B**). In the CO₂ angiogram, stenosis of the peroneal trunk could be seen; however, the right anterior tibial artery and posterior tibial artery are not well visualized when compared to DSA.

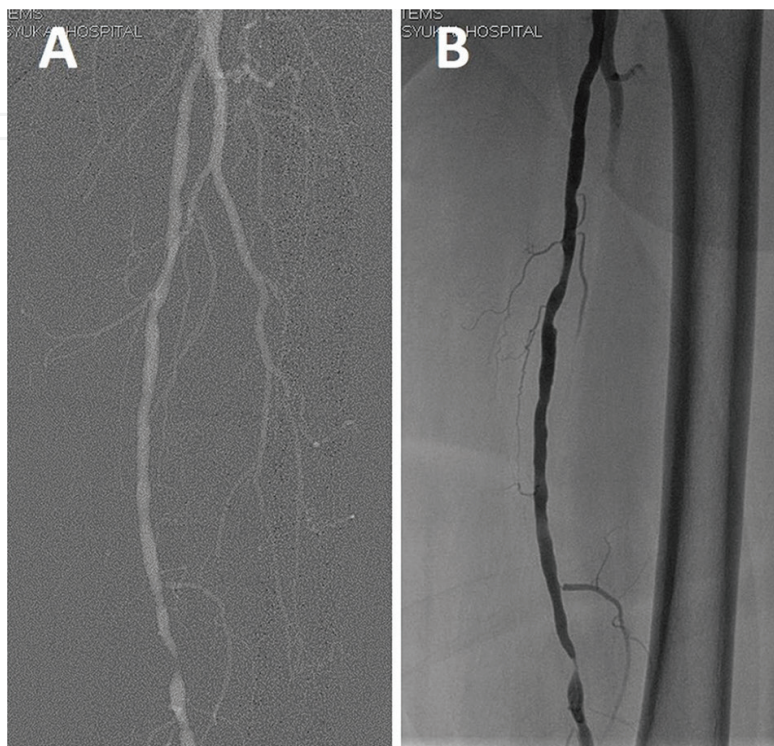


Figure 47. Left SFA stenosis by CO₂ and digital angiography. (A) CO₂ angiography shows moderate stenosis in mid SFA and tight stenosis in distal SFA. (B) Digital angiography confirmed these two lesions. Image quality is similar between CO₂ and digital angiography.

4.5. Problems of CO₂ angiography

CO₂ angiography can be performed with minimal or no contrast media and can be used on CKD patients. However, CO₂ angiography carries several potential risks (8). Gas delivery into the vessel is basically contraindicated. Moreover, erroneous injection of excessive volumes may result in catastrophic clinical consequences. There are many reports about transient lower limb pain and transient abdominal pain. Fujihara et al. have conducted a multi-center prospective CO₂ study and have reported that two patients (2%) developed CO₂-related non-occlusive mesenteric ischemia which resulted in death. These non-occlusive mesenteric ischemia cases were caused by the trapping of CO₂ gas in the celiac, superior and/or inferior mesenteric arteries [8]. The quality of CO₂ angiography is still not clear enough in the iliac artery and should not be employed in below the knee arteries. It should be used for the femoropopliteal artery although, even in the femoropopliteal artery, precise lesion evaluation may be difficult in some cases. Other complementary modalities such as surface echo, IVUs and/or pressure measuring should also be employed to confirm lesion severity (**Table 4**).

In treating claudication, safety is the first priority so that CO₂ use may be limited for most patients except those who have anaphylaxis to iodinated contrast media.

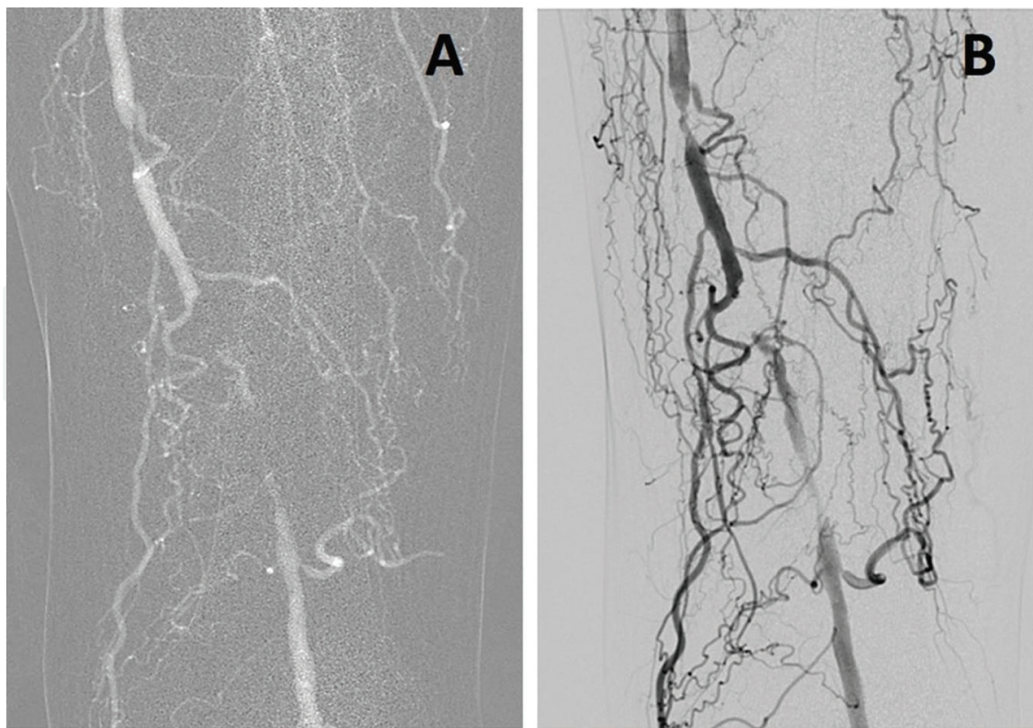


Figure 48. Left SFA occlusion by CO₂ and DSA. (A) CO₂ angiography shows totally occluded left SFA. (B) DSA shows clearer image with more collateral visualization.

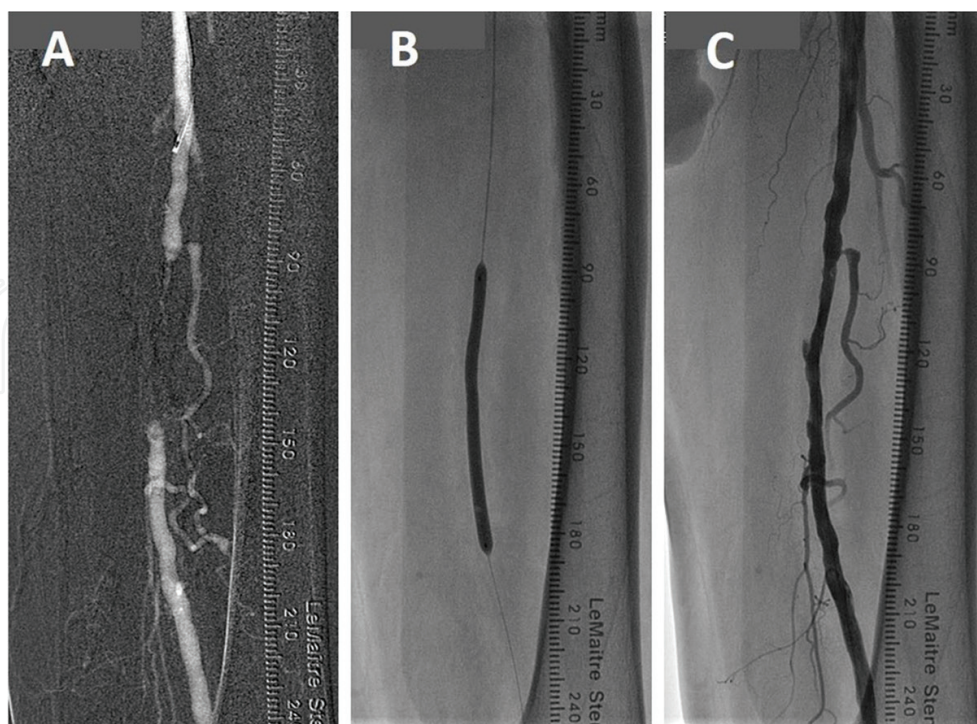


Figure 49. Left SFA CTO intervention by CO₂ angiography. (A) CO₂ angiography showed typical SFA CTO. (B) After wiring, balloon angioplasty was performed. (C) Contrast used only in final angiogram.

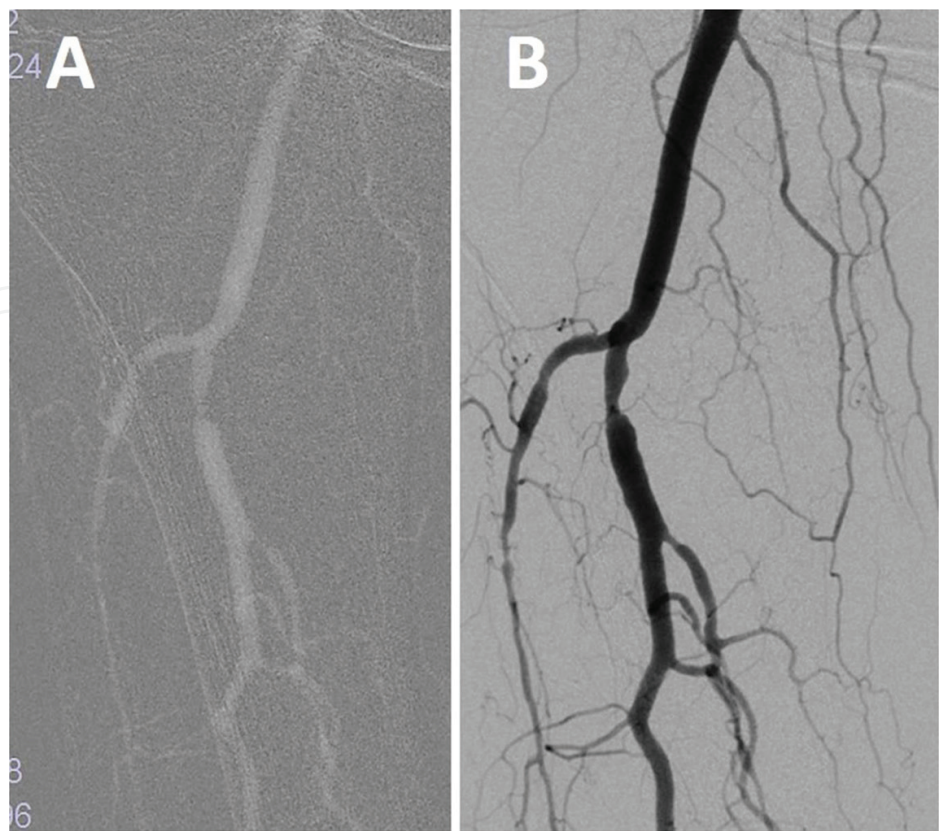


Figure 50. Below the knee angiography by CO₂ and DSA. (A) Proximal below the arteries by CO₂ angiography. Stenosis of peroneal trunk could be seen, otherwise, unable to identify right anterotibial and posterior tibial artery. (B) DSA shows detail of proximal below the knee arteries with small branches.

-
- Cause abdominal pain and leg pain
 - Poor quality angiogram in iliac artery by bowel gas and movement
 - Not applicable to below knee artery
 - Rapid transition to venous circulation
 - Risks of cerebral infarction
 - Risk of nonobstructive mesenteric ischemia
-

Table 4. Problems of CO₂ angiography.

Author details

Yoshiaki Yokoi
Address all correspondence to: smt yokoi@gmail.com
Kishiwada Tokushukai Hospital, Osaka, Japan

References

[1] Grynne BH, Nossen JO, Bolstad B, Borch KW. Main results of the first comparative clinical studies on Visipaque. *Acta Radiol Suppl.* 1995;399:265–70.

- [2] Nicola R, Shaqdan KW, Aran K, Mansouri M, Singh A, Abujudeh HH. Contrast-induced nephropathy: identifying the risks, choosing the right agent, and reviewing effective prevention and management methods. *Curr Probl Diagn Radiol*. 2015;44(6):501–4.
- [3] Gedikoglu M, Oguzkurt L, Gur S, Andic C, Sariturk U, Ozkan C. Comparison of ultrasound guidance with the traditional palpation and fluoroscopy method for the common femoral artery puncture. *Catheter Cardiovasc Interv*. 2013;82(7):1187–92
- [4] Lo RC, Fokkema MT, Curran T, Darling J, Hamdan AD, Wyers M, Martin M, Schermerhorn ML. Routine use of ultrasound-guided access reduces access site-related complications after lower extremity percutaneous revascularization. *J Vasc Surg*. 2015;61(2):405–12.
- [5] Fujihara M, Haramitsu Y, Ohshimo K, Yazu Y, Izumi E, Higashimori A, Yokoi Y. Appropriate hemostasis by routine use of ultrasound echo-guided transfemoral access and vascular closure devices after lower extremity percutaneous revascularization. *Cardiovasc Interv Ther*. 2016. [Epub ahead of print] PubMed PMID: 27430637.
- [6] Cho KJ. Carbon dioxide angiography: scientific principles and practice. *Vasc Specialist Int*. 2015;31(3):67–80.
- [7] Kawasaki D, Fujii K, Fukunaga M, Masutani M, Nakata A, Masuyama T. Safety and efficacy of endovascular therapy with a simple homemade carbon dioxide delivery system in patients with ileofemoral artery diseases. *Circ J*. 2012;76(7):1722–8.
- [8] Fujihara M, Kawasaki D, Shintani Y, Fukunaga M, Nakama T, Koshida R, Higashimori A, Yokoi Y. Endovascular therapy by CO₂ angiography to prevent contrast-induced nephropathy in patients with chronic kidney disease: a prospective multicenter trial of CO₂ angiography registry. *Catheter Cardiovasc Interv*. 2015;85:870–7.

