

We are IntechOpen, the world's leading publisher of Open Access books Built by scientists, for scientists

6,900

Open access books available

185,000

International authors and editors

200M

Downloads

Our authors are among the

154

Countries delivered to

TOP 1%

most cited scientists

12.2%

Contributors from top 500 universities



WEB OF SCIENCE™

Selection of our books indexed in the Book Citation Index
in Web of Science™ Core Collection (BKCI)

Interested in publishing with us?
Contact book.department@intechopen.com

Numbers displayed above are based on latest data collected.
For more information visit www.intechopen.com



The Evolution of Minimally Invasive Techniques in Restoration of Colonic Continuity

Stefan H.E.M. Clermonts, Laurents P.S. Stassen and
David D.E. Zimmerman

Additional information is available at the end of the chapter

<http://dx.doi.org/10.5772/66720>

Abstract

Restoration of bowel continuity after Hartmann's procedure is considered technically challenging and is associated with high morbidity and mortality. This is the main reason why restoration of intestinal continuity is often not attempted. Over the past decade, considerable international experience has gained on this topic with new minimally invasive techniques being developed. This review details the evolution of minimally invasive techniques in restoration of colonic continuity after Hartmann's procedure. A comprehensive search of PubMed and Embase was done. Different restoration modalities were included. Eight studies, from six different countries, in which multiport laparoscopic restoration of continuity was compared to conventional open restoration of bowel continuity, were included. In the total of 254 patients, continuity was restored laparoscopically compared with 255 patients in which continuity was performed in open fashion. Restoration of bowel continuity via trephine access was also reported; three studies including 37 patients were included in this review. Single-port restoration of bowel continuity after Hartmann's procedure is a natural evolution of multiport laparoscopy and trephine access. Six studies reporting on single-port reversal of Hartmann's procedure were included with a total of 75 patients. Single-port access in combination with a trans-anal approach has also been reported; however, data are extremely limited as there is only one study in the published literature. Success of restoration of bowel continuity with less morbidity and mortality has been demonstrated throughout the evolution of the different surgical techniques. In this review advantages of different approaches for restoration of bowel continuity after Hartmann's procedure are discussed. Furthermore, surgical techniques are described, pictorial guides are added for some techniques, and flowcharts are given for easy use during clinical decision-making.

Keywords: Hartmann's procedure, restoration, intestinal continuity, surgical techniques, laparoscopic, minimal invasive, single-port laparoscopy

1. Introduction

In this chapter we would like to focus on the restoration of intestinal continuity after Hartmann's procedure in general and highlight emerging minimally invasive techniques in specific.

Historically, restoration of bowel continuity after Hartmann's procedure has been considered technically challenging and is associated with high morbidity and mortality rates even despite modern surgical techniques. This is the main reason why restoration of intestinal continuity is often not attempted. Intraoperative difficulties during laparotomy or multi-port laparoscopy are mainly caused by the formation of adhesions at the laparotomy site and lower part of the abdomen after active inflammation and/or infection and previous surgery.

The use of the former colostomy site as access to the abdominal cavity has gained some popularity recently. Placing a single-port access system in the former colostomy site combines the potential benefits of minimally invasive surgery (shorter postoperative recovery time, minimal postoperative hospital stay, and lower morbidity rates) with the advantages of Hartmann's reversal through the colostomy site (the absence of new incisions and decreased necessity of midline adhesiolysis).

2. Hartmann's procedure: historical perspective

Henri Albert Hartmann was born on June 16, 1860. Hartmann finished his medical school at the University of Paris on December 19, 1881.

Hartmann starts his internship with Felix Terrier at Hôpital Bichat, who was considered to be one of the most authoritative surgeons at that time [1]. After finishing his surgical training in 1887, Hartmann was appointed as an assistant professor in 1895 and in 1909 as a professor and chairman of the Department of Surgery in 1892. In 1914, Hartman became the chief of Surgery at l'Hôtel-Dieu hospital in Paris (**Figure 1**) [2]. During his lengthy and extraordinary career, Hartmann meticulously recorded each operation he performed. Upon his retirement he had documented around 30,000 cases [3].

Hartmann's procedure was first described in 1921 [4, 5]. In his first patients with obstructive carcinoma of the sigmoid, he performed a proximal colostomy and then a sigmoid resection with closure of the rectal stump via an abdominal approach. He developed this technique in response to high mortality rates in his patients who underwent an abdominoperineal resection, as first described by Miles in 1908 [1]. In 1931 Hartmann described the procedure in detail in his book *Chirurgie du Rectum* (**Figure 2**).

Although Hartmann developed his technique mainly for rectal cancer, in present times, Hartmann's procedure is often the preferred procedure for severe diverticulitis of the sigmoid. Despite Hartmann never intended restoration of bowel continuity, recent publications showed that a direct reconstruction is feasible in selected patients [6].



Figure 1. Henri Hartmann (second from the right) and his three assistants, Drs. Bergeret, Gouverneur, and Huet, at the Hotel-Dieu, Paris. Source image: <http://wellcomeimages.org>.

2.1. Reversal of Hartmann's procedure

Hartmann never attempted to reanastomose the bowel in his patients. He believed this would result in unnecessarily high morbidity and mortality [3].

Restoring intestinal continuity after Hartmann's operation is a difficult operation that is associated with a high morbidity rate, with anastomotic leakage rates ranging from 4% to 16% and an operative mortality reported as high as 10% [7–10].

The high incidence of morbidity and mortality is the main reasons why surgeons are reluctant to restore intestinal continuity in approximately 40% of the patients undergoing Hartmann's procedure [10, 11].

2.2. Indications and contraindications

The primary indication for reversal of Hartmann's procedure is curing people of the discomforts that are caused by the end colostomy. Patients with stomas face many physical and psychological challenges, including leakage, skin rashes, lifestyle alterations, and sexual dysfunction [12, 13].

Literature defines no contraindications for reversal of Hartmann's procedure. However, a review of the literature covering restoration after Hartmann's procedure shows that advanced age, ASA grade 3, or higher and fecal peritonitis at the time of Hartmann's procedure are

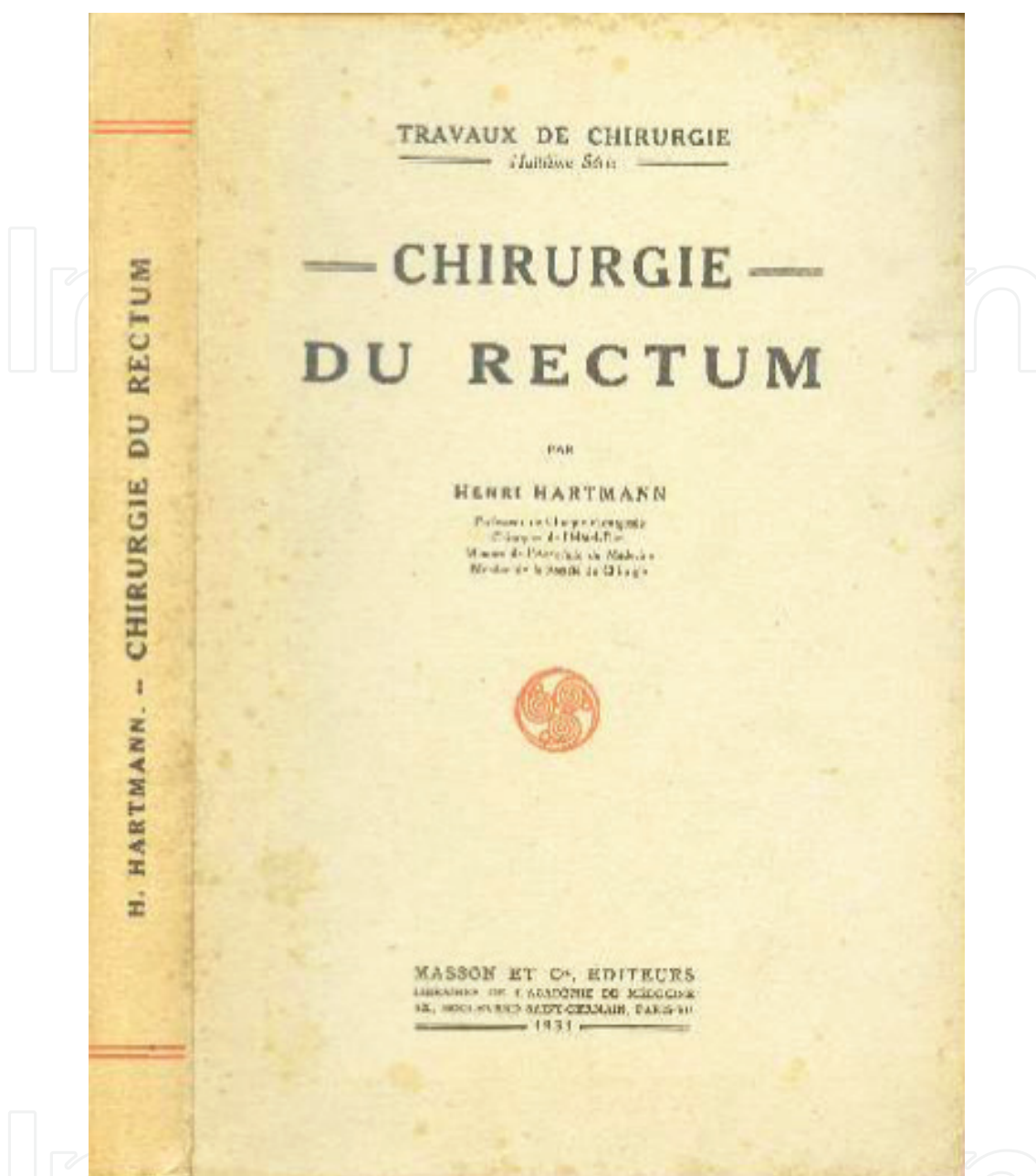


Figure 2. Cover of the book *Chirurgie du rectum* by Henri Hartmann. Published 1931. Source image: <http://archive.org>.

often considered relevant contraindications. Roque-Castellano and colleagues analyzed factors related to the decision of restoring intestinal continuity. They found that female sex and neoplastic disorders are relative contraindications for restoration of intestinal continuity [14]. Furthermore, we believe there must be some reluctance to perform conventional restoration of bowel continuity by laparotomy in patients with an incisional hernia. The reason for this statement is the need for repair of the incisional hernia and the restoration of the bowel continuity at the same time. This reluctance is following the dictum that abdominal wall prostheses must be avoided during contaminated operations [15]. The authors advocate

the use of single-port laparoscopic reversal of Hartmann's procedure in case of an incisional hernia. With this modality the midline can be left unchanged rendering concomitant repair of the incisional hernia unnecessary. The single-port laparoscopic technique will be discussed in detail in Section 5.1.

2.3. Preoperative workup

Prior to the restoration of the intestinal continuity, routine evaluation of the rectal stump and descending colon is often performed in order to detect stump leakage, cavity formation, or strictures and establish the length of the rectal stump. The integrity and patency of the rectal stump are evaluated by physical examination, flexible endoscopy and/or radiographically by contrast proctography CT scan. Despite these routine practices, little data exist to support this in case of restoration of bowel continuity after Hartmann's procedure. Data do exist on the routine use of contrast enema prior to the closure of a defunctioning ileostomy in patients with low pelvic anastomosis is inconsistent when its sole purpose is detecting leaks or cavity formation [16–18]. These studies show that strictures or narrowing of the bowel lumen is seldom detected. In cases where strictures are detected, dilatation is performed without the need for cancelation the reversal of the – ostomy. When extrapolating these findings, it is questionable whether routine contrast studies are necessary in the case of Hartmann's reversal. Moreover, usually patients who develop an anastomotic leak of the rectal stump present with clinical symptoms long before restoration of the bowel continuity is scheduled. However, in patients where initial Hartmann's procedure was acutely performed for neoplastic disorders, direct visualization of the rectal stump and remaining colon is mandatory to exclude recurrence of the malignancy or other neoplastic lesions. Based on these limited data, the authors advocate performing flexible rectoscopy to ensure viability of the rectal stump and the absence of remaining diverticular disease or local recurrence in case of prior malignancy. Data on routinely performing X-ray or contrast enema is limited to expert opinions and therefore not mandatory. Authors' recommendations are summarized in the algorithm in **Figure 3**.

2.4. Timing of surgery

There is limited data available concerning the optimal timing of restoration of continuity. Most surgeons will postpone surgery for at least 6 months after the initial operation, obviously depending on the current health and recuperation of the patient. It has been suggested by Keck and coworkers that a waiting period of 15 weeks may be beneficial [19]. It is however noteworthy that reversing Hartmann's procedure after a shorter period did not influence morbidity or mortality, but did seem to lengthen the duration of hospitalisation and increase the perceived operative difficulty (and thus the risk). Other authors have also suggested there is no indication to delay closure for longer than 16 weeks [20]. Based on these limited data, the authors advocate a minimal waiting period of 4 months between the initial operation and restoration of continuity in order to maximize the possibility of minimally invasive techniques for restoring continuity.

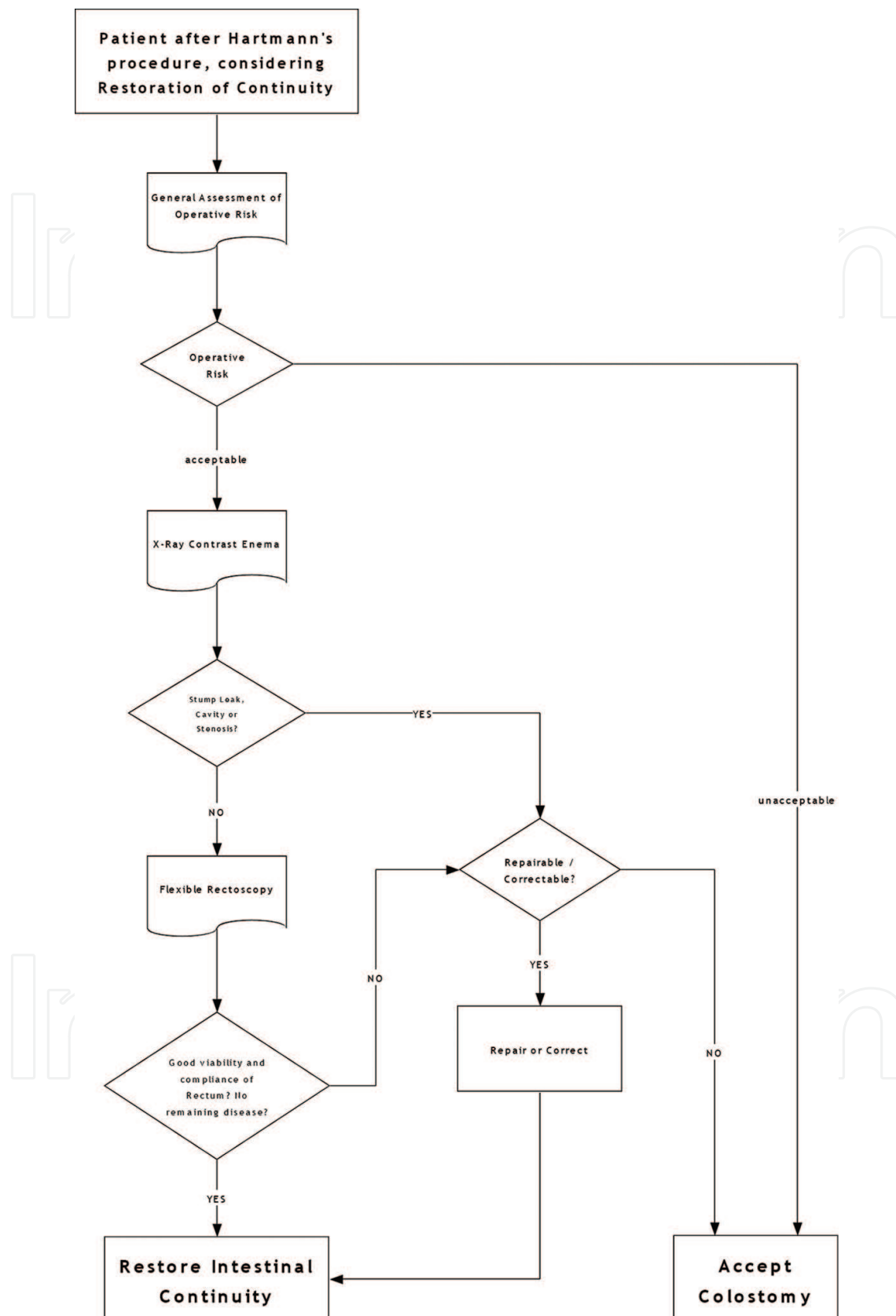


Figure 3. Algorithm advocated to be used during decision-making and the preoperative workup for restoration of bowel continuity after Hartmann's procedure.

3. Surgical techniques for restoration of intestinal continuity after Hartmann's procedure

Reestablishing bowel continuity after Hartmann's procedure is considered a major surgical procedure that is accompanied by considerable morbidity and mortality. Multiport laparoscopy was the first technique in a sequence of attempts to reduce the high morbidity and mortality that is associated with this procedure.

3.1. Multiport laparoscopic reversal of Hartmann's procedure

The patient is placed in a supine position. Next, there are two different ways to continue the procedure. In one option the procedure is initiated with mobilization of the stoma to the level of the abdominal wall and then freeing the ostomy from the fascia. The alternative procedure starts by insertion of a 10 mm camera trocar and a working trocar when needed (**Figure 4**), establishing the pneumoperitoneum, and perform a prior inspection for factors that could potentially cause abortion later on in the procedure. We advocate starting the procedure in the latter fashion, since this technique facilitates early decision-making by the surgeon on continuing or aborting the procedure when a potential unsuccessful bowel restoration is anticipated. Consequently, there is no need for refashioning of the end colostomy.

In both techniques the next step is transecting the colon using a linear stapler to remove the end of the colostomy and securing the anvil of a circular stapler is secured with a purse-string suture, in the proximal colon. The descending colon is then returned into the abdominal cavity. Any adhesions in the abdominal cavity are freed to enable insertion of the other ports. The colostomy site is closed using a wound protector/retractor device with a laparoscopic cap so that it can function as an additional working port. The pneumoperitoneum is then established. Additional 5 mm working trocars are placed in the right upper quadrant and right iliac fossa. Extensive dissection of adhesions from the anterior abdominal wall in the midline is mandatory with this multi-port technique in order to cross the midline (**Figure 4**).

The small bowel is mobilized from the left iliac fossa and out of the pelvis. The proximal descending colon would have been mobilized to a varying extent at the initial Hartmann's procedure, and this will need to be redone, including the splenic flexure. A rectal probe or circular stapler sizer is used to identify the rectal stump. In order to perform an end-to-end anastomosis, further mobilization and adhesiolysis of the rectal stump are sometimes necessary. Alternatively, if mobilization is difficult and the anterior rectal wall can clearly be identified and adequate length of the descending colon is available to allow a tension-free anastomosis, an side-to-side anastomosis can be performed. A circular stapler is introduced into the rectum to fashion the anastomosis. The stapler is deployed and the donuts are checked. Next, we advocate performing an additional leak test as this is associated with reduced rates of postoperative adverse events in literature [21]. The pneumoperitoneum is released, and the trocars are removed under direct visualization. The fascia is then closed in apertures equal to or larger than 10 mm.

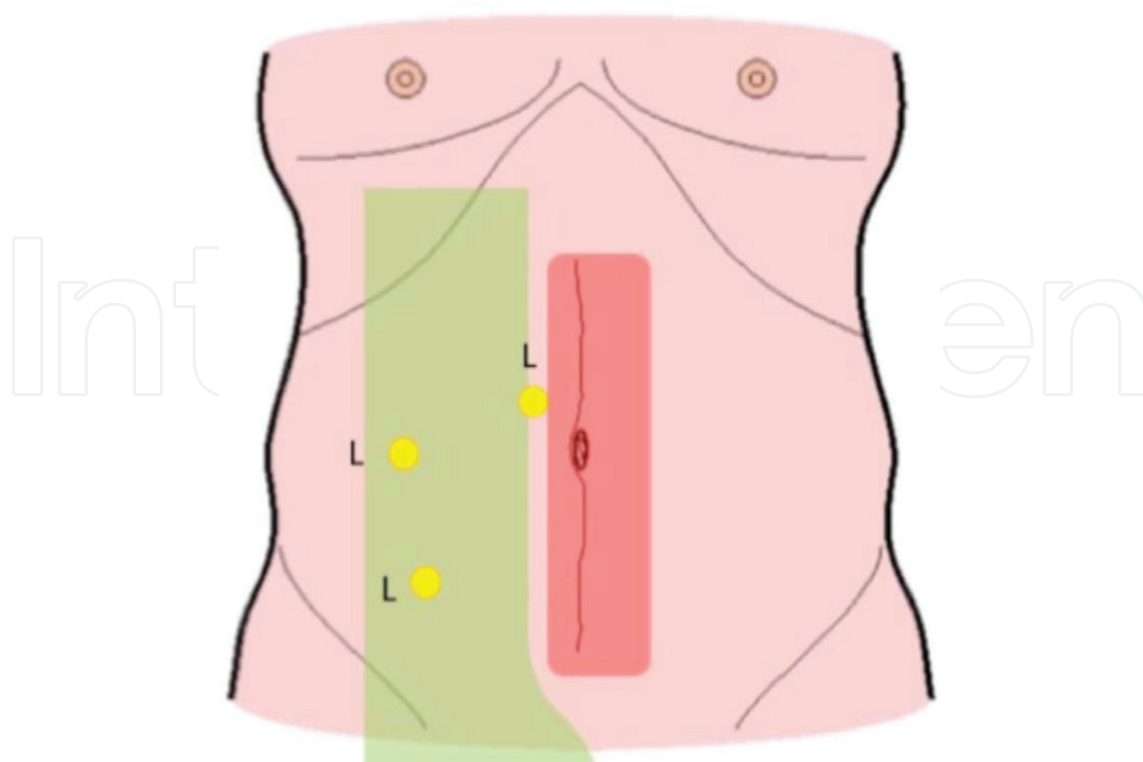


Figure 4. Port positions for multiport laparoscopic Hartmann's reversal. L = laparoscopic trocar position. Red-shaded area: area of maximal adhesion formation after previous laparotomy. Green-shaded area: area of range of action that is relatively free of adhesions. Note that in this technique the midline has to be crossed.

3.2. The open technique compared to multiport laparoscopic restoration technique: an appraisal of the literature

In recent literature a limited amount of studies compared an open approach with the multiport laparoscopic technique [22–31]. In **Table 1** a summary of studies on multiport laparoscopic versus conventional Hartmann's reversal is presented.

As expected, for the minimal invasive technique, the total length of hospital stay was shorter with 6.9 days when compared to the open approach that shows a mean of 10.4 days. Furthermore, for patients in whom bowel continuity was restored laparoscopically, overall morbidity rates seemed lower when compared to patients who were treated conventionally. In the laparoscopic group, mean morbidity rates were 12% versus 20% in the open group. The main and foremost complications after bowel restoration for both modalities are summarized in **Table 2**.

In the reviewed literature, mortality seems comparable for both techniques, with a mean mortality of 0.9% in the laparoscopic group and 1.2% in the conventional group. No statistically significant differences were found for mean total operation time, 150 minutes for the laparoscopic technique and 172 minutes for conventional procedures. A possible explanation for the relative long operation duration for both techniques is the extensive adhesiolysis that is required. 80 percent of the conversions from laparoscopy to the conventional technique arises for this reason [33], resulting in an average conversion rate of 12 percent. In the opinion of the authors, there is no place for primary open restoration of continuity after Hartmann's

Study	Country	Year of publication	Procedure	Number of patients	Morbidity (%)	Mortality (%)	Operation time (mean min)	Hospital stay (days)	Control group (number of patients)	Morbidity (%)	Mortality (%)	Operation time (mean min)	Hospital stay (days)
Rosen et al. [24]	USA	2005	Laparoscopic	20	3 (14)	0 (0)	158	4.2	No				NS
Faure et al. [25]	FR	2007	Laparoscopic	14	2(14.2)	0 (0)	143	9.5	Conventional (20)	6 (30)	0 (0)	180	11
Haughn et al. [26]	USA	2008	Laparoscopic	61	8 (13)	0 (0)	154	NS	Conventional (61)	11 (18)	0(0)	210	NS
Vermeulen et al. [27]	NL	2008	Laparoscopic	3	(15.8)*	(5)*	NS	NS	Conventional(48)	(15.8)*	(5)*	NS	NS
Mazeh et al. [28]	IL	2009	Laparoscopic	82	15 (17.6)	0 (0)	193	6.5	Conventional (41)	15 (36.5)	0 (0)	209	8.1
Di Carlo et al. [29]	IT	2010	Laparoscopic	3	0 (0)	0 (0)	95.6	NS	Conventional (3)	0 (0)	0 (0)	136.6	NS
De'angelis et al. [30]	FR	2013	Laparoscopic	28	3 (10.7)	0 (0)	171.1	6.7	Conventional (18)	6 (33.6)	0 (0)	235.8	11.2
Yang et al. [31]	AU	2014	Laparoscopic	43	6 (14)	0 (0)	276.4	6.7	Conventional (64)	20 (31)	0 (0)	242	10.8

AU, Australia; FR, France; IT, Italy; IL, Israel; NL, the Netherlands; USA, United States of America; NS, not stated. In the study by Vermeulen et al. [32]. Subdivision is made for laparoscopic or conventional reversal; therefore, only overall morbidity and mortality are given for this study.

Table 1. Summary of current literature that compares multiport laparoscopic Hartmann's reversal versus the conventional open technique.

	Type of intestinal continuity restoration	
	Multiport laparoscopy	Laparotomy
Hemorrhage	1.7	3
Wound infection	10.6	14
Anastomotic leakage	1.2	5
Reoperation	4	7
Cardiopulmonary	3.6	7
Values are derived from the literature. Values are in mean percentages.		

Table 2. Morbidity rates depicted for multiport laparoscopic reversal of Hartmann’s procedure compared with conventional reversal.

procedure, due to unnecessary morbidity, mortality, and trauma to the abdominal wall. We advocate selection of a minimally invasive procedure.

4. Trephine access: using the former colostomy site as access point

Although laparoscopic restoration of the intestinal continuity has many advantages, in laparoscopic reversal of Hartmann’s procedure, an extended adhesiolysis in the midline and pelvis is still needed. This adhesiolysis may increase postoperative paralytic ileus and the risk of inadvertent bowel lacerations.

The use of the colostomy site as an even less invasive method for access to the abdominal cavity and restoration of the intestinal continuity was first described by Vermeulen and colleagues in 2008 [32]. In this technique manual access is gained through the stoma site in combination with a blindly performed adhesiolysis without laparoscopic assistance (Figure 5). This procedure was called the SIR method “stoma incision reversal” procedure.

4.1. SIR procedure: surgical technique

The patient is positioned in the lithotomy. The stoma is released, taking a small amount of surrounding skin with it. Then the colostomy is closed provisionally with a running suture. The length of the incision at the stomal site must be large enough to fit the surgeon’s hand. The descending colon stump is brought outside the abdomen; visible adhesions connected to the left colon are sharply dissected. Further adhesiolysis of the left colon is performed manually between the thumb and index finger in order to create enough length for the descending colon to reach the pelvic cavity. If enough bowel length is created. The anvil of a circular stapler is placed intraluminal. The stump is closed using a linear stapler. The tip of the stapler anvil is brought through the colon the staple line and tied by a purse-string suture. The descending colon with the anvil is returned intra-abdominally. For the next step, the surgeon’s right hand is placed intra-abdominally through the former colostomy side. The left hand is used to transanally introduce a rigid sizer to identify and manipulate the rectal stump. Adhesions between the rectal stump and adjacent small bowels are loosened manually and blindly with the surgeon’s right hand. Consecutively, the circular stapler is introduced into

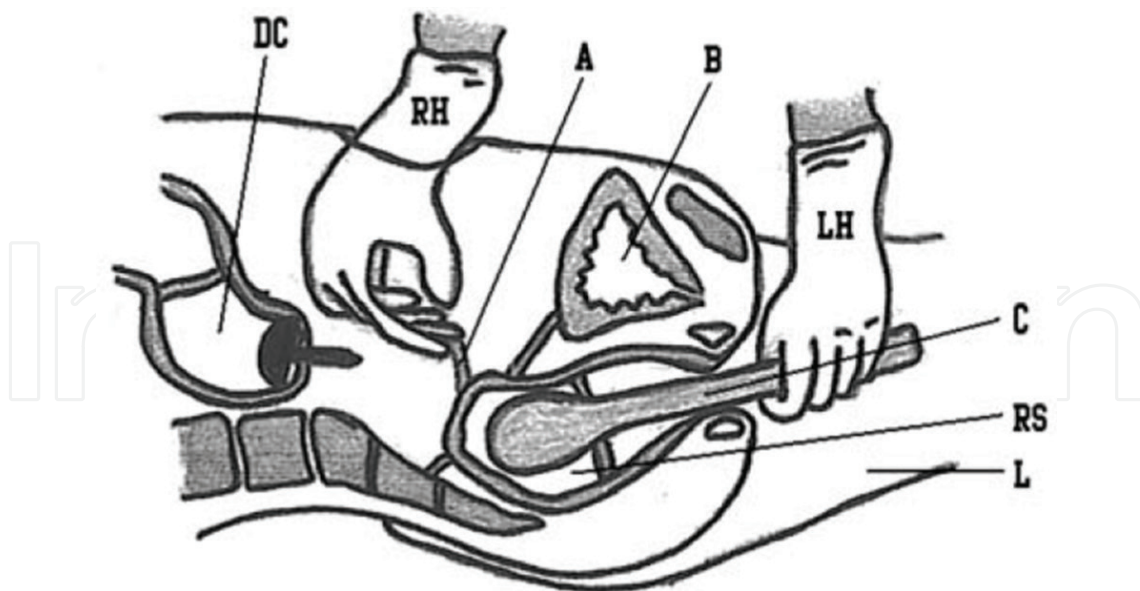


Figure 5. Manual lysis of adhesions at the tip of the rectal stump, which was identified using a rigid club. Previously, the anvil of a circular stapler was placed intraluminal of the descending colon. DC, descending colon with anvil; RH, right hand; A, adhesions; B, bladder; LH, left hand; C, rigid club; RS, rectal stump; L, left leg. Source: Ref. [34].

the rectal stump. The pin of the circular stapler is passed through the rectal wall, and the anvil is attached. Before firing the circular stapler, the proximal bowel segment is manually checked for rotation and interposition. After firing the stapler, the integrity of the doughnuts of the anastomosis is inspected, and a leak test is performed. The fascia is closed with a PDS suture, and the skin as deemed appropriate.

4.2. Appraisal of the literature

A review of the literature shows three studies [32, 34–36] on the SIR technique. **Table 3** summarizes the results. Vermeulen and colleagues described the first pilot study in 2010. They attempted the procedure in 13 consecutive patients with a median age of 56 years (range 35–81 years). Indications for initial surgery were iatrogenic bowel perforation ($n = 3$), intestinal bowel obstruction due to complicated diverticulitis ($n = 3$), and diverticulitis ($n = 7$). Median delay of reversal was 7 months.

Of the 13 patients assigned for reversal of Hartmann's procedure through the stomal site, two patients needed direct conversion to laparotomy due to firm adhesions. Of the 11 patients in which the procedure was accomplished through the stoma site, mean operation time was 81 min (range 58–109 min) with a mean hospital stay of 4.2 days. No anastomotic leaks occurred. In 2010 Vermeulen and colleagues published the results of their "stoma incision reversal" procedure in 22 patients and compare the results with matched cases in which restoration of the intestinal continuity was performed by laparotomy. In the "SIR" group, five procedures were converted to laparotomy due to firm adhesions ($n = 2$), doubt about the quality of the doughnuts ($n = 2$), or iatrogenic small bowel lacerations ($n = 1$).

In this study the mean operation time was significantly shorter when performing the SIR procedure (75 min (58–208)) compared to the open group (141 min (85–276)) ($p < 0.001$). Patients

Study	Country	Year of publication	Number of patients	Procedure	Control group (number of patients)	Morbidity (%)	Mortality (%)	Operation time (mean min)	Hospital stay (days)
Vermeulen et al. [32]	NL	2008	13	Trephine access	No (0)	0 (0)	0 (0)	81	4.2
Vermeulen et al. [34]	NL	2010	16	Trephine access	Yes (32)	4 (25)	0 (0)	75	4
Aydin et al. [35]	TR	2011	8	Trephine access	No (0)	0 (0)	0	65	5.5

NL, the Netherlands; TR, Turkey.

Table 3. Summary of “trephine access” technique reversal of Hartmann’s procedure in the current literature.

	Type of intestinal continuity restoration	
	"SIR"	Laparotomy
Total complications	4	16
Anastomotic leakage	1	2
Ileus	0	1
Wound infections	1	5
Urine retention	1	0
Incisional hernia	1	8
Mortality	0	1

Vermeulen et al. 2010 [35].

Table 4. Postoperative complications after restoration of bowel continuity depicted for the "SIR" procedure (trephine access) and conventional technique.

who underwent the SIR procedure had a shorter postoperative hospital stay (SIR group range 2-7 days) ($p < 0.001$). The total postoperative number of complications was not significantly different between both procedures. Twenty-five percent for the SIR patients versus 50% of the patients that were treated by the conventional technique. Postoperative complications after bowel continuity restoration are depicted in **Table 4**.

In 2011 Aydin and colleagues perform the aforementioned technique in eight patients. Indications for the initial Hartmann's procedure were sigmoid volvulus ($n = 4$), obstructive sigmoid cancer ($n = 2$), rectal trauma ($n = 2$), and Fournier's gangrene ($n = 1$). The mean duration between the primary procedure and reversal of the Hartmann's procedure was 5 months (range 2–8 months). All patients included had a body mass index of less than 30 kg/m^2 and a rectal stump of at least 5 cm. In two patients the incision was extended from the stoma site for better visualization of the rectal stump in one patient and due to injury of the intestine in one patient. Mean duration of the operation was 65 min (range 45–80 min). No postoperative complications were observed. Patients were discharged after a mean of 5.5 days (range 4–9 days). Aydin and coworkers note that this technique should ideally be used in non-obese patients with long rectal stumps of sufficient length.

The SIR technique originated in the Netherlands and met criticism due to the blind nature of the dissection phase of the procedure. Regarding the risk of blind dissection as well as the availability of improved access platforms that enable adequate vision and control, the authors do not advocate the use of the SIR technique in present times.

5. Single-port restoration of the intestinal continuity through the stoma trephine site

Single-port restoration of intestinal continuity with access through the formal site of the colostomy is a relatively new technique. The main goal for the development of this method is

introducing a minimally invasive technique that further reduces the morbidity and mortality of a procedure that is technically demanding and complex.

5.1. Surgical technique

The patient is placed in lithotomy position. Primarily, the colostomy is mobilized and freed from the fascia (**Figure 6**). The mobilized descending colon is then pulled out of the abdomen and exposed (**Figure 7**). Next, the colon is transected using a linear stapler to remove the end colostomy, and the anvil of a circular stapler is secured with a purse-string suture, in the proximal colon. Either a terminal or lateral position can be chosen (**Figure 8**). The descending colon is returned into the abdominal cavity. Any adhesions close to the wound in the abdominal cavity on direct view are freed. The single-port access platform is then placed in the fascial defect at the colostomy site, and the pneumoperitoneum is then established (**Figure 9**). A rigid 30-degree laparoscope is introduced and a diagnostic laparoscopy is performed. Subsequently, the patient

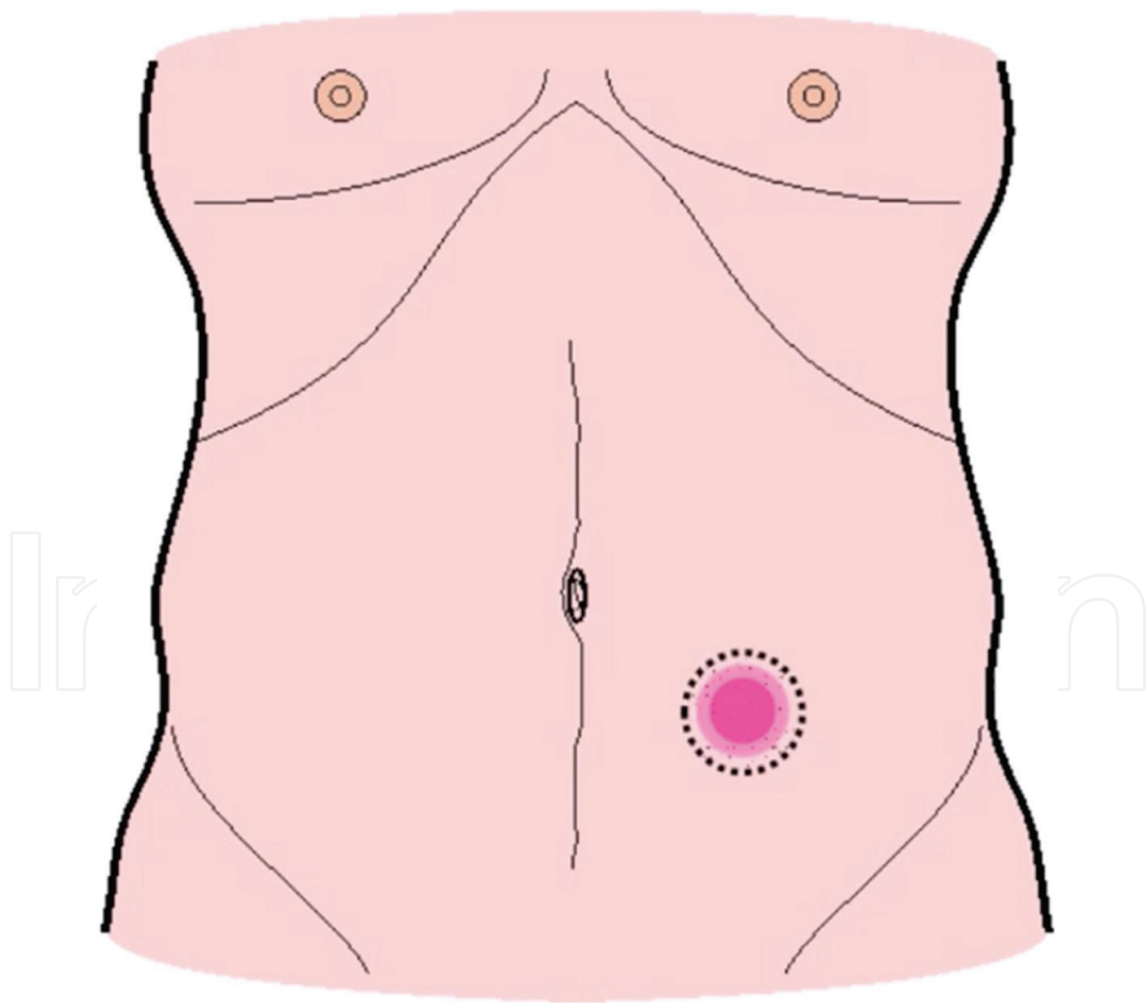


Figure 6. Release of the colostomy.

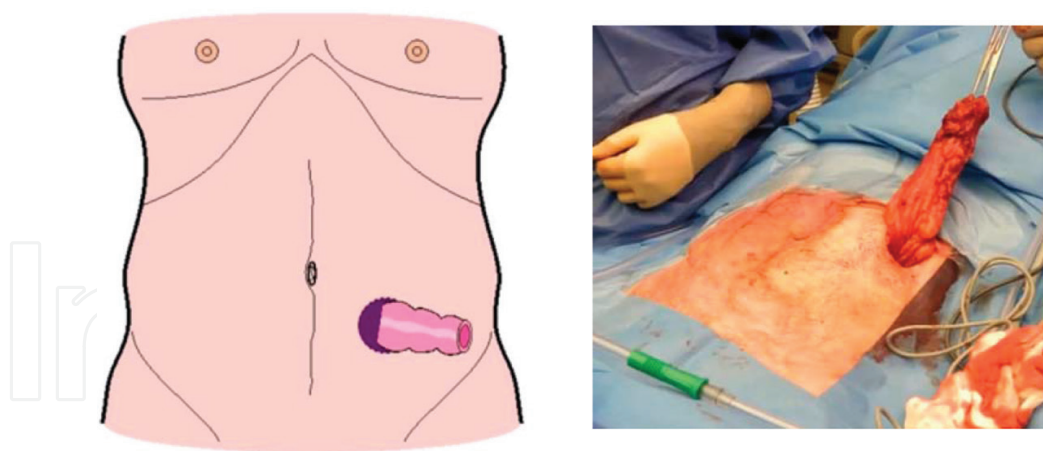


Figure 7. Mobilization of the descending colon with sufficient length.

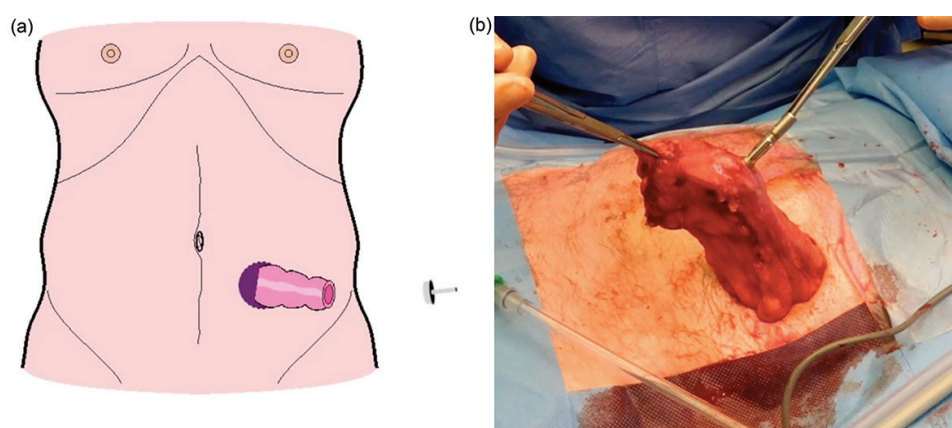


Figure 8. Insertion of the anvil of the circular stapler. Left picture shows a terminal position. Right picture shows a lateral positioning of the anvil for side-to-end configuration.

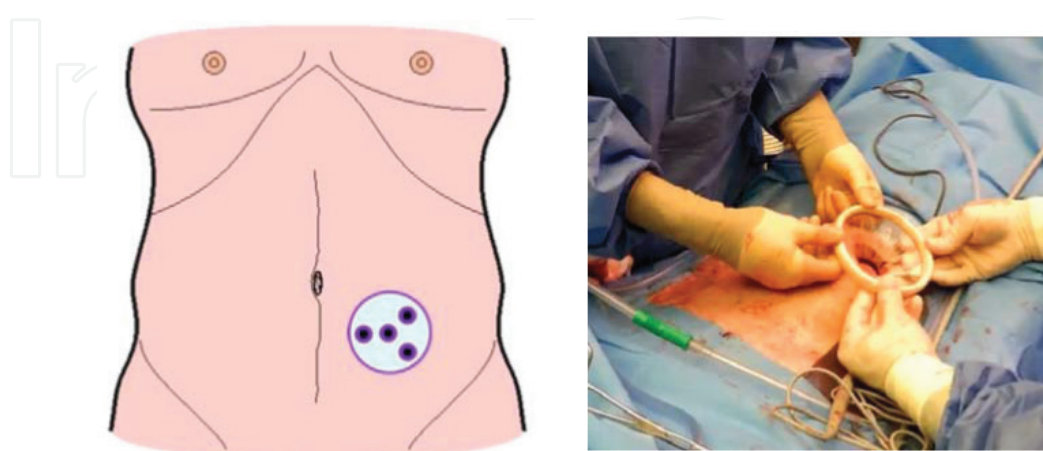


Figure 9. Placement of the single-port access device in the fascia defect at the formal stoma site. Right picture shows the placement of the flexible wound protector.

is positioned in anti-Trendelenburg position making the small pelvis visible. Adhesiolysis is performed using two 5 mm working trocars.

Dissection of adhesions and scar tissue surrounding the rectal stump is performed extensively, by either sharp dissection with laparoscopic scissors or ultrasonic dissection devices, until the rectal stump is as bare as possible (**Figure 10**). Adhesions formed at the previous midline incision can be left unchanged at this stage, reducing the risk of iatrogenic bowel perforation and reducing total operation time. Next, the circular stapler is advanced via the anus, and the descending colon is identified and checked if adequate length is available to allow a tension-free anastomosis. If necessary, the splenic flexure of the colon can be mobilized (**Figure 11**). The stapler is deployed and the donuts are checked. The pneumoperito-

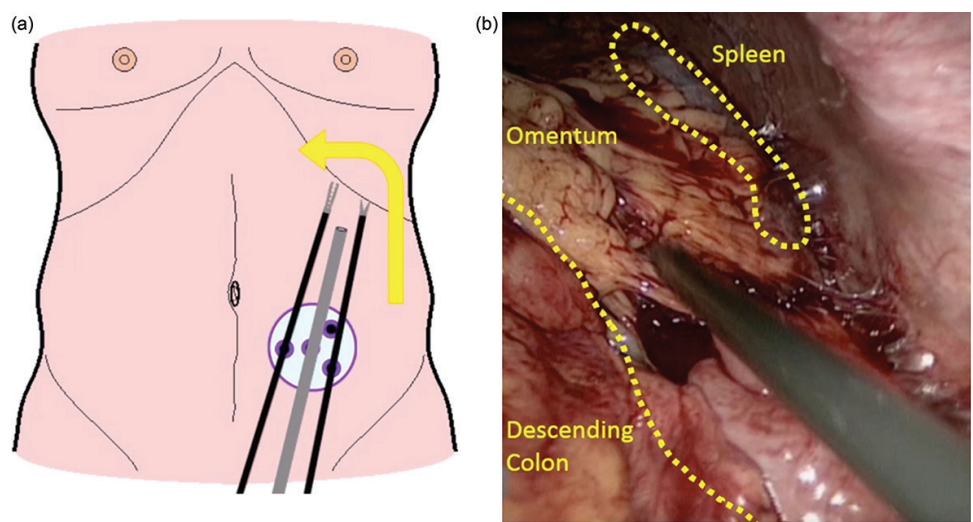


Figure 10. Adhesiolysis and mobilization of the splenic flexure.

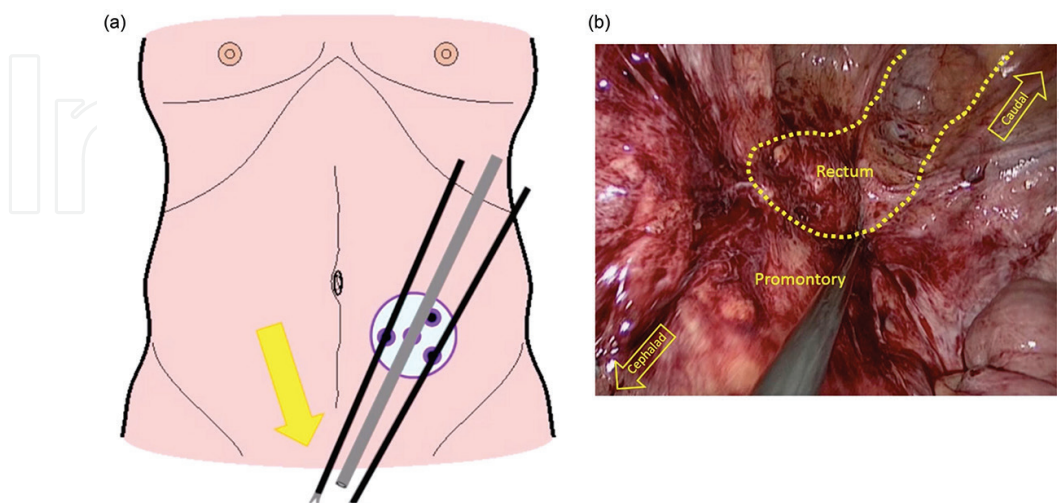


Figure 11. Dissection of adhesions and scar tissue surrounding the rectal stump.

Study	Country	Year of publication	Number of patients	Procedure	Control group (number of patients)	Morbidity (%)	Mortality (%)	Hospital stay(days)
Smith et al. [42]	USA	2011	1	Stoma site. Single port	No (0)	0(0)	0(0)	5
Carus et al. [39]	GE	2011	8	Stoma site. Single port	No (0)	1 (12.5)	0 (0)	4
Borowski et al. [38]	UK	2011	5	Stoma site. Single port	No (0)	1 (20)	0	4.2
Joshi et al. [41]	UK	2013	14	Stoma site. Glove port	No (0)	3 (21)	0 (0)	5.5
Choi et al. [40]	KR	2015	22	Stoma site. Glove port. Single port	No (0)	4 (18.2)	0(0)	8
Clermonts et al. [37]	NL	2016	25	Stoma site. Single port	Yes (16)	8 (32)	0 (0)	4

KR, Korea; NL, the Netherlands; UK, the United Kingdom; GE, Germany; USA, the United States of America.

Table 5. Summary of single-port reversal of Hartmann's procedure in the current literature.

neum is released and the trocars are removed under direct visualization. The fascia is then closed in apertures equal to or larger than 10 mm.

5.2. Appraisal of the literature

A review of the literature reveals that only a few small case series have been published on this technique. At the moment no randomized controlled trials were published [37–42]. **Table 5** summarizes the results of the available literature. The technique was first described by Smith and colleagues [42]; in this case single-port restoration of the intestinal continuity was performed in a 56-year-old patient with a history of perforated diverticulosis. Their total operation time was 104 min. The patient started a clear liquid diet on postoperative day 2 and was discharged after 5 days. The largest study without control patients was that of Choi et al. [40] and consisted of 23 patients. In one patient closure of the colostomy was aborted due to intraoperative difficulties. The median age of their patients was 62 years (range 21–87 years), with an overall ASA grade of II. Median time to reversal was 153.5 days (range 99–1028). Main indications for Hartmann's procedure were: complicated diverticulitis (27.3%), colorectal carcinoma (27.3%), and sigmoid volvulus (18.2%). They reported a median operation time of 165 minutes (range 100–340 minutes) and a total hospital stay of 8 days (range 4–31 days). There morbidity rate was 18.2% with two reoperations, one for anastomotic dehiscence and one for rectovesical fistula. No mortality was reported. Carus and colleagues' study consisted of 8 patients with a median age of 60.4 years (range 36–84). Hartmann's procedure was performed for complicated diverticulitis (five laparoscopic,

three open). The reversal was performed 2–4 months after the primary procedure. No conversions were reported in one procedure; they had to play one extra trocar had to be placed during adhesiolysis; and one patient with a superficial wound infection (morbidity 12.5%). No mortality was reported. Patients were discharged after a median of 6.4 days (range 4–8 days). The series by Clermonts et al. [37] was the only study that included a control group. They included a total of 25 patients (median age, 52.2 years). Indications for primary surgery consisted of complicated diverticulitis (60%) and malignancy in 28% of the cases. Median time to reversal was 16 months. These patients were compared with a control group in which closure of the colostomy was performed in an open method. In the open group, all primary Hartmann’s procedures were performed by laparotomy; in the single-port group, 88% was performed by laparotomy. No statistical significant differences were observed between the two groups. Median operation time in the single-port group

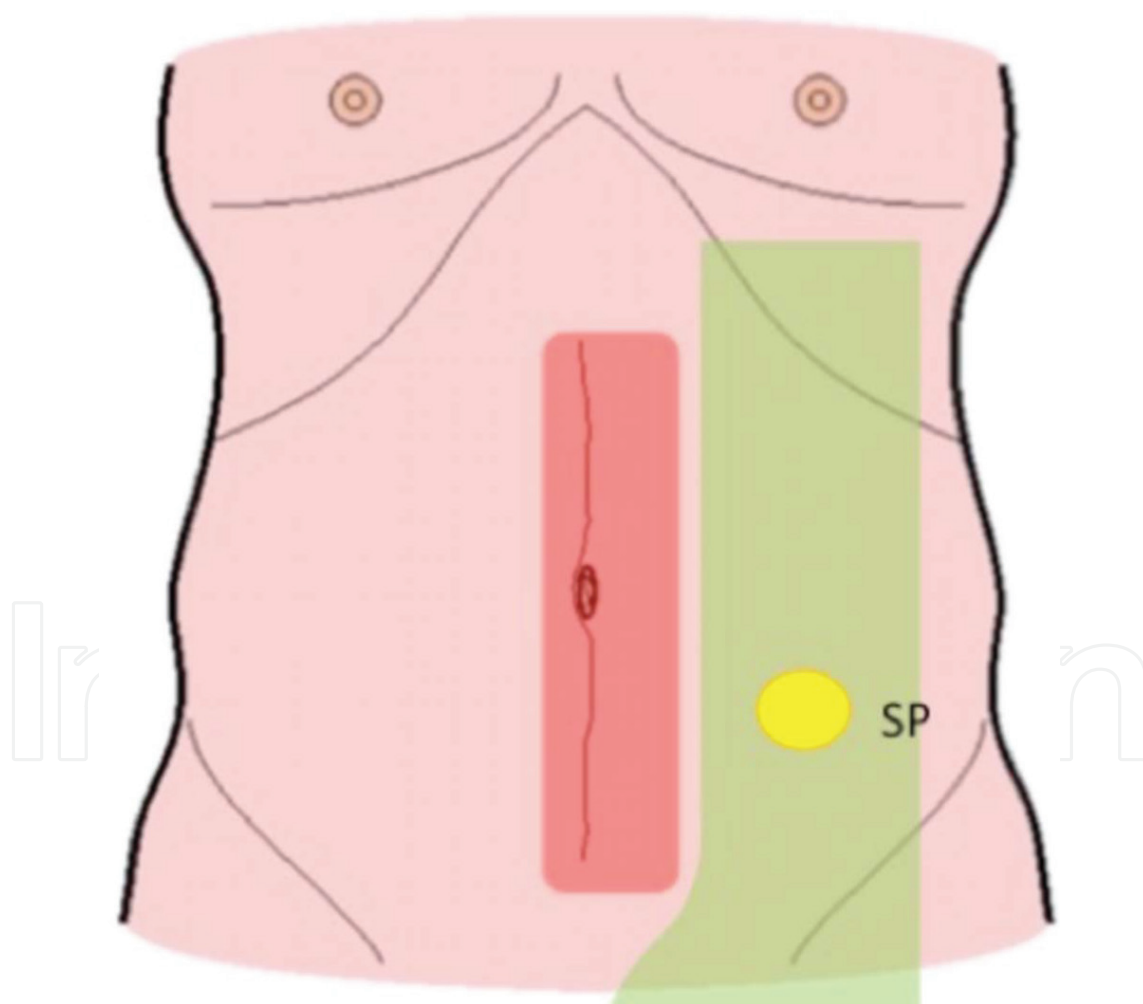


Figure 12. Port position for single-port Hartmann’s reversal. SP = single-port trocar position. *Red-shaded area:* area of maximal adhesion formation after previous laparotomy. *Green-shaded area:* area of range of action that is relatively free of adhesions.

was 153.5 min (range: 73–332 minutes) and 184.4 min (range 29–377 minutes) in the open group. One single-port procedure was converted to laparotomy and two procedures to multiport laparoscopy due to difficulties during the adhesiolysis. In the single-port group, a total of eight complications were observed compared with 33 complications in the open group. Wound infections, 5 (20 %) versus 12 (75 %), accounted for the largest number of complications in the SPHR and OHR groups. One patient died after anastomotic leakage and sepsis in the control group; no mortality was observed in the single-port group. The median hospital stay was 4 days in the single-port group compared to a mean of 16 days in the open group.

5.3. Advantages of this technique

Single port restoration of the intestinal continuity has some major advantages over the previously mentioned techniques. The minimally invasive technique has the usual advantages of this technique with less pain and faster recovery. Specifically, in Hartmann's reversal also a shorter operation time is observed. The single port variant using the formal stoma site as an access point has the additional advantage that crossing the midline is avoided, rendering an extensive adhesiolysis unnecessary as **Figure 12** schematically shows.

Another big advantage of minimalizing the access trauma is shown in the very short hospital stay compared to the open and laparoscopic techniques. The small incision, almost no blood loss, and short operation time could be the main reasons.

6. Single-port trephine access and transanal access combined for restoration of the intestinal continuity

In Section 5 we already described the advantages of single-port restoration of intestinal continuity with access through the formal site of the colostomy. Recently, a new technique that combines the single-port trephine access with single-port transanal access was presented [43]. It is suggested the transanal approach will aid in the technically challenging dissection of the rectal stump and perform a pelvic adhesiolysis in a safer manner.

6.1. Surgical technique

Patients receive mechanical bowel and rectal stump cleansing. Patients are placed in lithotomy position. The procedure is performed by two surgeons starting simultaneously; one surgeon starts the abdominal trephine access approach (Section 5). The second surgeon places a single-port transanal access platform through the anal canal with three working trocars. The pneumorectum is created. Next, circular dissection next to the stapler line in the proximal part of the rectal stump is performed into the avascular presacral plane posteriorly. This plane of dissection is extended medially, laterally, and interiorly to achieve the desired circumferential rectal mobilization. Finally, the peritoneal reflection

was visualized and divided to achieve the proximal rectal stump removal, with both surgeons working together. The previous stapler line with the resected tissue can be extracted transanally. Next, a Prolene purse-string suture is used to close the distal rectal stump. In order to complete the end-to-end anastomosis, a circular stapler is inserted via the anal canal and connected to the anvil in the proximal descending colon. After firing the circular stapler and completing the anastomosis, the integrity of the anastomosis can be evaluated with an air test, as well as an intraluminal examination through the transanal access platform.

6.2. Critical appraisal of literature

A review of the literature reveals one study by Bravo and colleagues [43]. The study group describes a technique that is easily adopted and mastered by surgeons already trained in transanal colorectal surgery. They report no postoperative morbidity and a quick recovery and discharge from the hospital (no exact numbers given). Furthermore, a shorter total operation time is mentioned when compared to a multiport laparoscopic approach.

Advantages of this technique mentioned by the authors are first of all the safe dissection of the rectal stump because most of the work is done in a surgical plane not touched during the initial surgery and thus without adhesions. This gives the ability to precisely identify structures with adherence to the rectal stump like small bowel or ureter. The main difficulty of this technique can be performing the transanal dissection in patients with hard adhesions to the rectal stump after perforation or peritonitis. Furthermore, a very short rectal stump makes positioning the transanal single-port access difficult and without adequate workspace impossible.

7. Authors' recommendation

The authors believe that the minimally invasive technique is an attractive approach for reversal of Hartmann's procedure. So far, reports are promising. The technique may reduce the substantial morbidity known from open reversal. The SIR technique may be considered to be obsolete, especially in the era of laparoscopy. Most patients will be best suited by use of laparoscopic techniques. We would like to emphasize that laparoscopy is a means to an end and not a goal in itself. If minimally invasive techniques are deemed unsafe or unsuitable, conversion to open technique may be utilized at any time. We believe that. The recently developed technique of single port restoration of continuity seems especially promising, as contralateral access that can be cumbersome due to the adhesions from a previous laparotomy is avoided and a ventral hernia defect when present can be avoided. We believe Trephine access in combination with the transanal approach as primary surgical approach is not always necessary. We recommend this technique to be used as a step-up approach or back-up when pelvic dissection is proving technically challenging

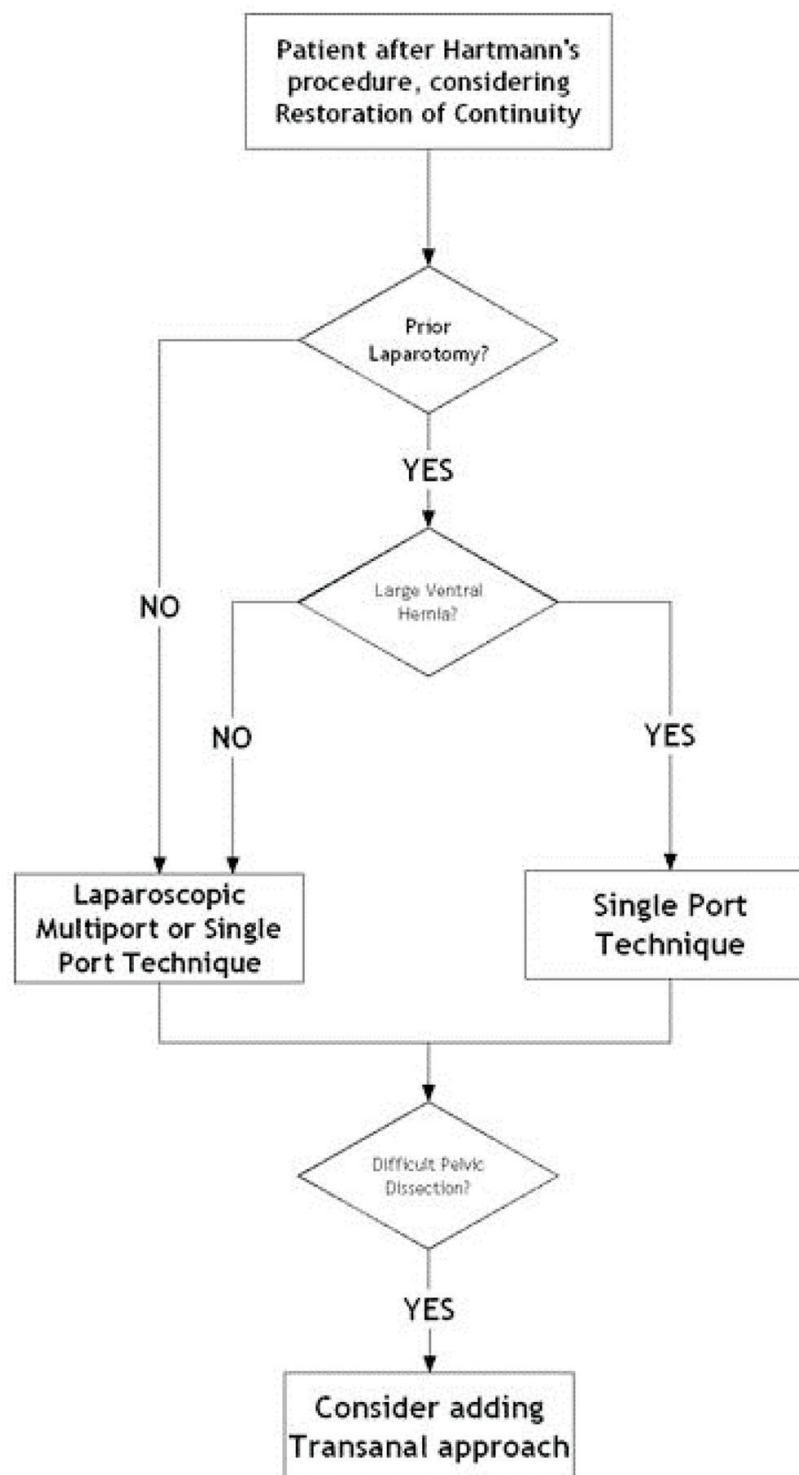


Figure 13. Algorithm to be used during the decision-making which technique is best suited for the restoration of bowel continuity after Hartmann's procedure.

or unsafe during initial trephine or multiport access. Authors recommendations are summarized in the algorithm in **Figure 13**.

8. Conclusion

The reversal of Hartmann's procedure carries a high operative morbidity and mortality rate. Therefore this is only performed in a selected group of patients. A considerable group of patients, with advanced age, or expected high operative risk, are left with a permanent end colostomy. This chapter gives an overview of the development less invasive techniques, that may reduce morbidity and therefore be offered to a larger group of patients.

Conventional laparoscopic reversal of Hartmann's procedure was the first technique with the primary goal of reducing morbidity and mortality. This technique reduced surgical access trauma resulting in a shorter post operative hospital stay and avoiding the negative consequences of relaparotomy. In the quest for even less invasive ways of restoring the bowel continuity the Trephine access technique was developed. This technique received criticism on the fact that the adhesiolysis was performed mainly in a blind fashion. This is probably the reason why this technique has not gained wide popularity and acceptance. This technique however gave birth to the development of the single-port access technique. This minimally invasive laparoscopic technique has our preference. We recommend using this technique for the major reduction in access trauma. Avoiding crossing the midline reduces the need for adhesiolysis, with its potential hazards like iatrogenic bowel injury. When proven safe in larger series, reversal of Hartmann's procedure may be offered to a larger proportion of patients then is presently routine.

Author details

Stefan H.E.M. Clermonts¹, Laurents P.S. Stassen² and David D.E. Zimmerman^{1,*}

*Address all correspondence to: d.zimmerman@etz.nl

1 Department of Surgery, Elisabeth-TweeSteden Hospital, Tilburg, The Netherlands

2 Department of Surgery, Maastricht University Medical Center, Maastricht, The Netherlands

References

- [1] Van Gulik TM, Mallonga ET, Taat CW. Henri Hartmann, Lord of the Hotel-Dieu. *Nether J Surg.* 1986(3):45–7.
- [2] JP. Portraits de Chirurgiens de l'Hotel-Dieu. *Presse Med.* 1959(60):2317–20.
- [3] Ronel DN, Hardy MA. Henri Albert Hartmann: labor and discipline. *Curr Surg.* 2002;59(1):59–64.
- [4] HH. Nouveau procede d'ablation des cancers de la partie terminale du colon pelvien. *Strasbourg: Trentienne Congres de Chirurgie*, 1921:411–3.

- [5] HH. Note sur un procede nouveau d'extripation des cancers de la partie terminale du colon. Bulletin et Memoires de la Societe Chirurgique de Paris. 1923;1474–7.
- [6] Abbas S. Resection and primary anastomosis in acute complicated diverticulitis, a systematic review of the literature. *Int J Colorectal Dis.* 2007;22(4):351–7.
- [7] Pearce NW, Scott SD, Karran SJ. Timing and method of reversal of Hartmann's procedure. *Br J Surg.* 1992;79(8):839–41.
- [8] Wigmore SJ, Duthie GS, Young IE, Spalding EM, Rainey JB. Restoration of intestinal continuity following Hartmann's procedure: the Lothian experience 1987–1992. *Br J Surg.* 1995;82(1):27–30.
- [9] Albarran SA, Simoens C, Van De Winkel N, da Costa PM, Thill V. Restoration of digestive continuity after Hartmann's procedure: ASA score is a predictive factor for risk of postoperative complications. *Acta Chir Belg.* 2009;109(6):714–9.
- [10] Banerjee S, Leather AJ, Rennie JA, Samano N, Gonzalez JG, Papagrigoriadis S. Feasibility and morbidity of reversal of Hartmann's. *Colorectal Dis: Off J Assoc Coloproctol G B Irel.* 2005;7(5):454–9.
- [11] Maggard MA, Zingmond D, O'Connell JB, Ko CY. What proportion of patients with an ostomy (for diverticulitis) get reversed? *Am Surg.* 2004;70(10):928–31.
- [12] Nugent KP, Daniels P, Stewart B, Patankar R, Johnson CD. Quality of life in stoma patients. *Dis Colon Rectum.* 1999;42(12):1569–74.
- [13] Mols F, Lemmens V, Bosscha K, van den Broek W, Thong MS. Living with the physical and mental consequences of an ostomy: a study among 1–10-year rectal cancer survivors from the population-based PROFILES registry. *Psychooncology.* 2014. Sep;23(9):998–1004.
- [14] Roque-Castellano C, Marchena-Gomez J, Hemmersbach-Miller M, Acosta-Merida A, Rodriguez-Mendez A, Farina-Castro R, et al. Analysis of the factors related to the decision of restoring intestinal continuity after Hartmann's procedure. *Int J Colorectal Dis.* 2007;22(9):1091–6.
- [15] Machairas A, Liakakos T, Patapis P, Petropoulos C, Tsapralis D, Misiakos EP. Prosthetic repair of incisional hernia combined with elective bowel operation. *Surgeon: J R Coll Surg Edinb Irel.* 2008;6(5):274–7.
- [16] Seo SI, Lee JL, Park SH, Ha HK, Kim JC. Assessment by using a water-soluble contrast enema study of radiologic leakage in lower rectal cancer patients with sphincter-saving surgery. *Ann Coloproctol.* 2015;31(4):131–7.
- [17] Kalady MF, Mantyh CR, Petrofski J, Ludwig KA. Routine contrast imaging of low pelvic anastomosis prior to closure of defunctioning ileostomy: is it necessary? *J Gastrointest Surg.* 2008;12(7):1227–31.
- [18] Hong SY, Kim do Y, Oh SY, Suh KW. Routine barium enema prior to closure of defunctioning ileostomy is not necessary. *J Korean Surg Soc.* 2012;83(2):88–91.

- [19] Keck JO, Collopy BT, Ryan PJ, Fink R, Mackay JR, Woods RJ. Reversal of Hartmann's procedure: effect of timing and technique on ease and safety. *Dis Colon Rectum*. 1994;37(3):243–8.
- [20] Roe AM, Prabhu S, Ali A, Brown C, Brodribb AJ. Reversal of Hartmann's procedure: timing and operative technique. *Br J Surg*. 1991;78(10):1167–70.
- [21] Kwon S, Morris A, Billingham R, Frankhouse J, Horvath K, Johnson M, et al. Routine leak testing in colorectal surgery in the Surgical Care and Outcomes Assessment Program. *Arch Surg*. 2012;147(4):345–51.
- [22] Aydin HN, Remzi FH, Tekkis PP, Fazio VW. Hartmann's reversal is associated with high postoperative adverse events. *Dis Colon Rectum*. 2005;48(11):2117–26.
- [23] Carcoforo P, Navarra G, Di Marco L, Occhionorelli S, Rocca T, Pollinzi V. Reversal of Hartmann's procedure. Our experience. *Ann Ital Chir*. 1997;68(4):523–7; discussion 7–8.
- [24] Rosen MJ, Cobb WS, Kercher KW, Sing RF, Heniford BT. Laparoscopic restoration of intestinal continuity after Hartmann's procedure. *Am J Surg*. 2005;189(6):670–4.
- [25] Faure JP, Doucet C, Essique D, Badra Y, Carretier M, Richer JP, et al. Comparison of conventional and laparoscopic Hartmann's procedure reversal. *Surg Laparosc Endosc Percutan Tech*. 2007;17(6):495–9.
- [26] Haughn C, Ju B, Uchal M, Arnaud JP, Reed JF, Bergamaschi R. Complication rates after Hartmann's reversal: open vs. laparoscopic approach. *Dis Colon Rectum*. 2008;51(8):1232–6.
- [27] Vermeulen J, Coene PP, Van Hout NM, van der Harst E, Gosselink MP, Mannaerts GH, et al. Restoration of bowel continuity after surgery for acute perforated diverticulitis: should Hartmann's procedure be considered a one-stage procedure? *Colorectal Dis*. 2009;11(6):619–24.
- [28] Mazeh H, Greenstein AJ, Swedish K, Nguyen SQ, Lipskar A, Weber KJ, et al. Laparoscopic and open reversal of Hartmann's procedure—a comparative retrospective analysis. *Surg Endosc*. 2009;23(3):496–502.
- [29] Di Carlo I, Toro A, Pannofino O, Patane E, Pulvirenti E. Laparoscopic versus open restoration of intestinal continuity after Hartmann procedure. *Hepatogastroenterology*. 2010;57(98):232–5.
- [30] De'angelis N, Brunetti F, Memeo R, Batista da Costa J, Schneck AS, Carra MC, et al. Comparison between open and laparoscopic reversal of Hartmann's procedure for diverticulitis. *World J Gastrointest Surg*. 2013;5(8):245–51.
- [31] Yang PF, Morgan MJ. Laparoscopic versus open reversal of Hartmann's procedure: a retrospective review. *ANZ J Surg*. 2014;84(12):965–9.
- [32] Vermeulen J VW, Mannaerts GH, . Reversal of Hartmann's procedure through the stomal side: a new even more minimal invasive technique. *Surg Endosc* 2008;22(10):2319–22.

- [33] van de Wall BJ, Draaisma WA, Schouten ES, Broeders IA, Consten EC. Conventional and laparoscopic reversal of the Hartmann procedure: a review of literature. *J Gastrointest Surg.* 2010;14(4):743–52.
- [34] Vermeulen J., LJWA, Mannaerts GH. Reversal of Hartmann's procedure after perforated diverticulitis through the stomal side without additional incisions: the SIR procedure. *Dig Surg.* 2010;27:391–6.
- [35] Aydin C, Olmez A, Isik S, Sumer F, Kayaalp C. Reversal of the Hartmann procedure through only a stomal orifice. *Am Surg.* 2011;77(6):694–6.
- [36] Parkin E, Khurshid M, Ravi S, Linn T. Surgical access through the stoma for laparoscopic reversal of Hartmann procedures. *Surg Laparosc Endosc Percutan Tech.* 2013;23(1):41–4.
- [37] Clermonts SH, de Ruijter WM, van Loon YT, Wasowicz DK, Heisterkamp J, Maring JK, et al. Reversal of Hartmann's procedure utilizing single-port laparoscopy: an attractive alternative to laparotomy. *Surg Endosc.* 2016;30(5):1894–901.
- [38] Borowski DW, Kanakala V, Agarwal AK, Tabaqchali MA, Garg DK, Gill TS. Single-port access laparoscopic reversal of Hartmann operation. *Dis Colon Rectum.* 2011;54(8):1053–6.
- [39] Carus T, Emmert A. Single-port laparoscopic reversal of Hartmann's procedure: technique and results. *Minim Invasive Surg* 2011;2011:356784.
- [40] Choi BJ, Jeong WJ, Kim YK, Kim SJ, Lee SC. Single-port laparoscopic reversal of Hartmann's procedure via the colostomy site. *Int J Surg* 2015;14:33–7.
- [41] Joshi HM, Gosselink MP, Adusumilli S, Cunningham C, Lindsey I, Jones OM. Incisionless reversal of Hartmann's procedure. *Tech Coloproctol.* 2014;18(9):843–6.
- [42] Smith BM, Bettinger DA. Single-incision laparoscopic reversal of Hartmann procedure via the colostomy site only: first report. *Surg Innov.* 2011;18(4):NP5–7.
- [43] Bravo R, Fernandez-Hevia M, Jimenez-Toscano M, Flores LF, de Lacy B, Quaresima S, et al. Transanal Hartmann reversal: a new technique. *Surg Endosc.* 2016;30(6):2628–31.

