

We are IntechOpen, the world's leading publisher of Open Access books Built by scientists, for scientists

6,900

Open access books available

185,000

International authors and editors

200M

Downloads

Our authors are among the

154

Countries delivered to

TOP 1%

most cited scientists

12.2%

Contributors from top 500 universities



WEB OF SCIENCE™

Selection of our books indexed in the Book Citation Index
in Web of Science™ Core Collection (BKCI)

Interested in publishing with us?
Contact book.department@intechopen.com

Numbers displayed above are based on latest data collected.
For more information visit www.intechopen.com



Isolated Aortic Root Aneurysms

Kaan Kırallı and Deniz Günay

Additional information is available at the end of the chapter

<http://dx.doi.org/10.5772/66963>

Abstract

The aortic root has a complex anatomy due to a combination of several anatomical structures based on simple and consistent work in it. It is a hollow cylinder with three bulges, which have the main functional effect on the aortic valve opening-closing cycle and coronary circulation. Aneurysm is defined as a dilation of a blood vessel segment having $\geq 50\%$ increase in diameter, whereas annuloaortic ectasia represents a diffuse dilation $< 50\%$ of the normal diameter of the related vessel segment. Aortic root aneurysms mostly occur by degenerative processes as compared with primarily atherosclerotic changes in the descending and abdominal aortas: medial fragmentation, smooth muscle cells necrosis, and elastic fiber fragmentations with cystic spaces in the media filled with mucoid material. Because of the elevated mortality risk associated with complications, an effective aortic root aneurysm management depends on reduction the risk of death, rupture, and dissection. Conventional open heart surgery is the essential procedure for isolated aortic root replacement and a type of procedure (valve replacement or sparing) could be selected due to the pathology. An extensive aortic root replacement technique is the only option to rebuild the left ventricular outflow tract due to the reconstruction of the neo aortoventricular continuity in the aortic root abscess.

Keywords: aortic root, root aneurysm, annuloaortic ectasia, aortic root replacement, aortic valve sparing, Bentall, Flanged, Cabrol, remodeling, reimplantation, extensive root replacement

1. Introduction

The aortic root is the first anatomical part of the aorta and also a functional bridge between the left ventricular outflow tract and ascending aorta, which lies between the ventriculoaortic junction (VAJ) and sinotubular junction (STJ). The aortic root has a complex anatomy due to a combination of several anatomical structures based on simple and consistent work in it. This complex combination provides several unique functional futures. On the other hand, several

pathological processes disrupting this anatomico-physiological structure lead to functional, morphological, and hemodynamic disturbances. Detailed understanding of the complex anatomy of the aortic root leads to the development of many sophisticated, but functional and artistic surgical techniques. This chapter focuses only on the abnormal enlargement of the aortic root caused by different pathologies, complicated or not, and surgical treatment options.

2. Definition

Generally, two terms are used to describe the aortic root enlargement: aneurysm and annuloaortic ectasia. Aneurysm is defined as a dilation of a blood vessel segment having $\geq 50\%$ increase in diameter compared with the expected normal diameter. True aneurysm involves all three layers of the arterial wall, but a pseudoaneurysm does not involve any anatomical layer of the aortic wall and is surrounded by thrombosis and/or surrounding tissues. Annuloaortic ectasia represents a diffuse dilation $< 50\%$ of the normal diameter of the related vessel segment. The aortic root does not have a tubular or cylindrical shape with the same diameter at all levels; on the contrary, it has variable diameters at different levels. Normal dimensions of the aortic root are different between genders and they also varies depending on age and body surface area (BSA): annulus diameter is approximately 26 ± 3 and 23 ± 2 mm, sinus Valsalva diameter is 34 ± 3 and 30 ± 3 mm, and STJ diameter 29 ± 3 and 27 ± 4 mm in male and female population, respectively [1]. Calculated normal aortic diameter indexes (diameter/BSA) can be useful during surgical treatment to choice a patient-appropriate tubular graft, especially to prevent any patient-prosthesis mismatch: annular diameter index is approximately 13 ± 1 mm/m², sinus Valsalva diameter index 19 ± 1 mm/m², and STJ diameter index 15 ± 1 mm/m² [2].

3. Functional anatomy

The aortic root has a truncated corn shape with the semilunar attachments of the leaflets, sinuses, interleaflet triangles, and commissures (**Figure 1**). The top of the aortic root is created by the distal circumferential plane joining the crests of three commissures and named as the STJ. The bulged mid-portion of the aortic root has three sinuses of Valsalva and it is like a three-leaflet clover in two-dimensional view (**Figure 2**): left coronary sinus (LCS), right coronary sinus (RCS), and noncoronary sinus (NCS). The base of the aortic root is shaped as a zone between the left ventricle and aorta because there is not a true single-circular annular attachment of three aortic leaflets. This anatomic VAJ is a circular zone between lower and upper rings: *The basal ring* or anatomic aortic annulus is the circular ring at the nadirs of three sinuses of Valsalva which is supported by the left ventricular muscle beneath the RCS and $\frac{1}{2}$ anterior LCS, and by the fibrous aortic-mitral curtain beneath the NCS and $\frac{1}{2}$ posterior LCS. This level is the narrowest circular level of the aortic valve. *The ventriculo-arterial ring* or the hemodynamic aortic annulus is the circular ring at the top of the muscular structure of the sinuses of Valsalva, which is supported only by the aortic wall. The interleaflet triangles

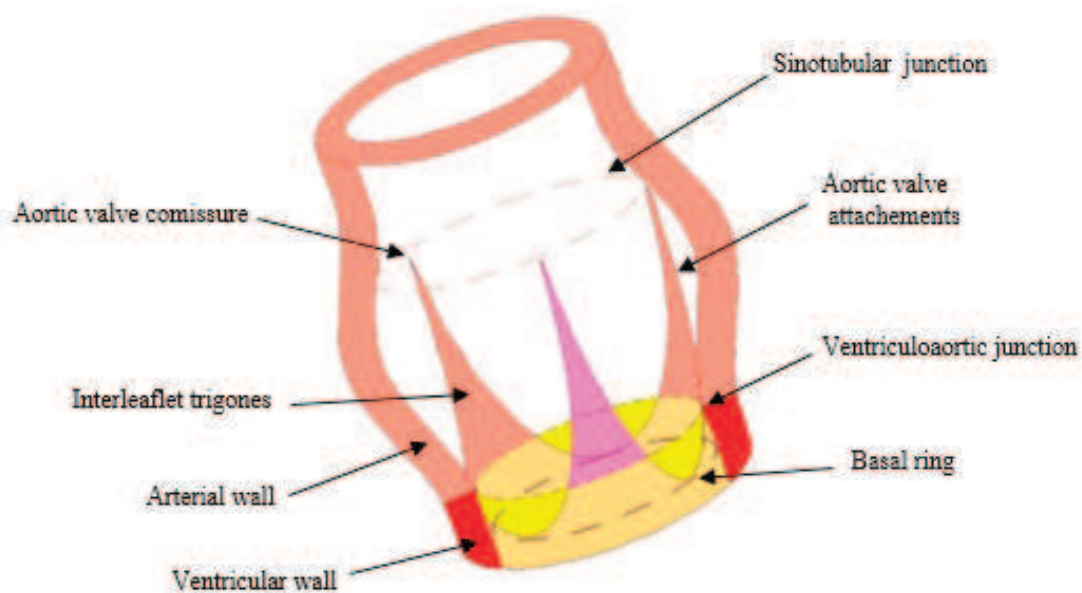


Figure 1. Aortic root.

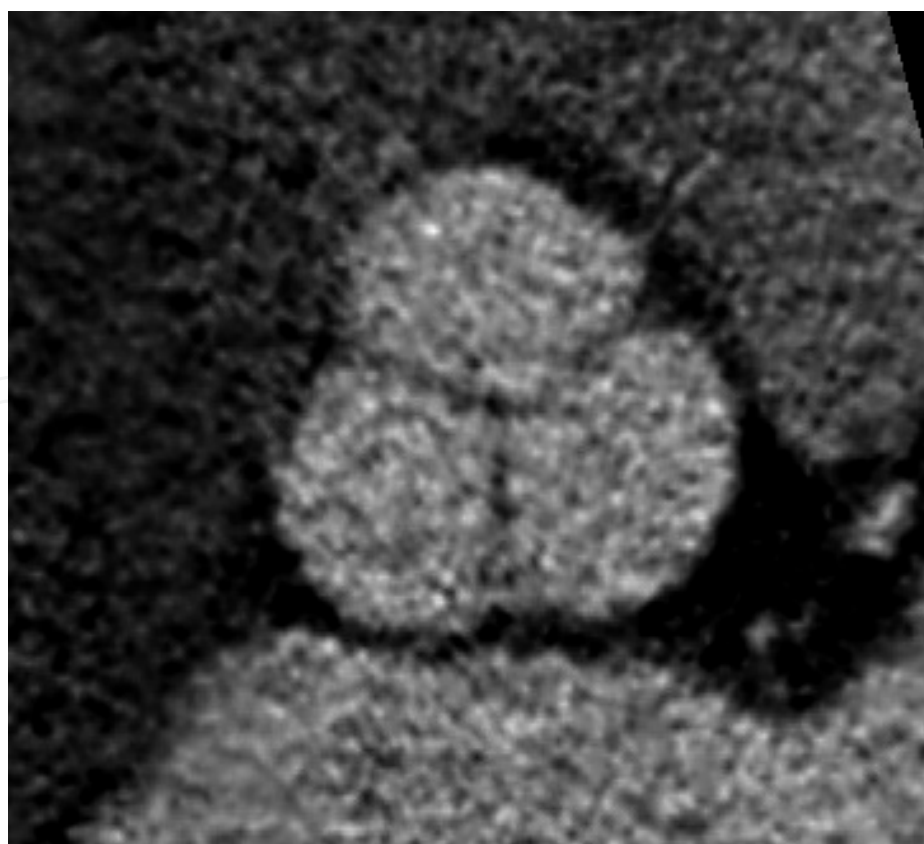


Figure 2. Two-dimensional computed tomographic view of three sinuses of Valsalva like a three-leaflet clover.

have special features because of their anatomical neighborhood relationships. The right interleaflet triangle separates RCS and NCS, it has continuity with the membranous septum and both built the right fibrous trigone. The most important anatomic structure in this area is His bundles, which lie just below the triangle. The posterior interleaflet triangle separates NCS and LCS, it has continuity with aortico-mitral valvular curtain and both built the left fibrous trigone, where guides to posterior aortic root enlargement techniques. The left interleaflet triangle has muscular structure and separates LCS and RCS, which is the closest part of the aortic root to the pulmonary trunk.

The aortic root is a hollow cylinder with three bulges, which have the main functional effect on the aortic valve opening-closing cycle and coronary circulation. In fact, the aortic root has two-sided asymmetrical structure [3]. *The first asymmetry* is in the longitudinal axis, and the mean heights of each sinus of Valsalva ($NCS > RCS > LCS$) and each interleaflet triangle ($posterior \geq right > left$) are not same, and the free margin lengths of the leaflets correspond this asymmetry [4]. This asymmetry shapes the aortic root as a conic cuff, whereas the NCS is slightly larger, and this pattern determines an angle of upper tilt (from the posterior interleaflet triangle to the NCS) between the plane at the VAJ and STJ with a mean value of 11° [5]. *The second asymmetry* is in the circumferential axis and the diameters of the aortic root are different ($sinus\ of\ Valsalva > VAJ > STJ \approx 1.34 > 1.1 > 1$). The diameter of the STJ is 10–12% smaller than those of the VAJ; however, the upper parts of the commissures attach just below the STJ and make a virtual ring with the same diameter of the VAJ.

The aortic root changes its overall configuration from a cone to a cylinder and from a cylinder to an inverted cone according to left ventricular filling and contraction [6]. Because the aortic leaflets attach in the shape of a three-pointed crown spanning the entire vertical extent of the aortic root from the VAJ to the STJ, it is more meaningful to discuss “the aortic valve apparatus” (**Table 1**). This functional apparatus organizes ventricular and arterial hemodynamics, and it works with an elegant mechanism. Every part of this apparatus has own function during the cardiac cycle. The aortic valve passively opens and closes in response to pressure differences between the left ventricle and aorta. The expansion of the VAJ at the preejectional phase before aortic valve opening helps to decrease the coaptation area among the leaflets

1.	Ascending aorta
2.	Sinotubular ring (junction)
3.	Sinuses of Valsalva
4.	Commissures
5.	Interleaflet triangles
6.	Aortic leaflets
7.	Ventriculoaortic ring (junction)
8.	Left ventricle

Table 1. Aortic valve apparatus.

and to separate the leaflets under minimal stresses (20% of total opening), and the aortic valve opening is completed rapidly by the ejection phase. The STJ expands approximately 12% during systole and the aortic root gets more cylindrical shape in the longitudinal axis, where inflow and outflow effective orifice areas of the aortic root become similar, and this configuration allows a zero resistance to flow throughout the aortic root during every ejection. Sinuses of Valsalva have the main effect on the coronary blood circulation, whereas they permit aortic valve opening during systole without blocking of the coronary artery ostia and simplify aortic valve closing at the end of systole without any tension.

The aortic root with this complex structure maintains the functional capacity of the aortic valve and the conversion of intermittent and irregular high blood volume from the left ventricle to regular and laminar blood flow even in variable hemodynamic conditions. Both the STJ and VAJ provide aortic valve coaptation, but the outflow part of the aortic root is the main structure that promotes aortic valve coaptation, whereas it hangs all three commissures during the diastole. Any significant dilatation of these rings can cause aortic regurgitation, whereas enlargement of the STJ more than 110% of the VAJ diameter results severe aortic insufficiency.

4. Histology and pathohistology

The aortic leaflets are covered by a continuous layer of endothelial cells with a smooth surface on the ventricular side and numerous ridges on the arterial side. The aortic leaflets are attached to the sinus wall via a very dense collagenous meshwork hinged to the annulus, so they transmit the stress on the leaflets to the aortic wall during diastole. The right and posterior interleaflet triangles consist of a thinned fibrous wall of the aorta, whereas the left interleaflet triangle is supported by muscular tissue and only fibrous at its apex. Interleaflet triangles contain primary collagen fibers; in contrast, sinuses of Valsalva contain concentric elastic lamella.

The aortic wall has three layers: tunica intima, tunica media, and tunica externa (adventitia), which are separated from each other with a thin membrane: membrana elastica interna (between intima and media) and membrana elastica externa (between media and adventitia). The intima is composed of single layers of endothelial cells arranged in the direction of the vessel. The subendothelial connective tissue is arranged in the same manner as the endothelial cells. The media is composed of circular arranged structures: smooth muscle cells, elastic fibers, collagen, and proteoglycans. The adventitia is arranged in a longitudinal fashion and composed of collagen fibers of type I. Although the wall of the sinuses is principally arranged in this manner, the thickness of its wall is significantly thinner compared with the ascending aorta and STJ [7].

The tunica media of the aortic root comprises concentric layers around the lumen, which consist two elastic lamellae and intervening tissue between them. The elastic lamellae include collagen fibers (type I-III-V) and fibronectin, and they are interconnected by a network of

elastic and collagen fibers, and proteoglycans. Smooth muscle cells are also in contact with fibrillin-1 and type VI collagen containing bundles of microfibrils (oxytalan fibers), and they have a basal lamina-like layer connecting them to each other and oxytalan fibers [8]. There are many types of proteoglycans in vascular walls such as collagen-associated dermatan sulfate proteoglycan, cell-associated heparin sulfate proteoglycan, and interstitial chondroitin sulfate proteoglycan. The constituents of the arterial wall are responsible for mechanical properties, and the ability of the arterial vessel is essential to prevent or limit any permanent deformation. Elastic fibers providing the elasticity and compliance of the arterial wall comprise elastin and microfibrils such as fibulins, fibrillins, and microfibril-associated glycoproteins.

Aortic root aneurysms mostly occur by degenerative processes as compared with primarily atherosclerotic changes in the descending and abdominal aortas. The elastin content of the aorta decreases distally and in the abdominal aorta it is less than half of that in the ascending aorta. Degenerative processes mean medial fragmentation, smooth muscle cells necrosis, and elastic fiber fragmentations with cystic spaces in the media filled with mucoid material. There is a disorganization and breakdown of the elastin network and its interconnections with the collagen network and other components of the aortic wall. The collagen structure also alters specifically and significantly: collagens type I and III decrease, while collagens alpha-1 (XI) and V increase [9]. Smooth muscle cell impairment and increased amounts of the vacuolated basophilic material are prominent.

Matrix metalloproteinases play an important role in connective tissue homeostasis, and in fragmentation of extracellular matrix elements via digestion of elastin and collagen fibers [10, 11]. Disharmony of matrix metalloproteinases activity causes connective tissue impairment. Blockade of plasmin formation by overexpression of plasminogen activator inhibitor-1 prevents the formation of aneurysms by inhibiting metalloproteinase activation. And also, local overexpression of the tissue inhibitor of matrix metalloproteinases can prevent aneurysmal degeneration and rupture. Inflammation characterized with leukocyte and lymphocyte infiltration is greater in the aneurysmal aortic wall compared to non-aneurysmal aortas, especially in some inflammatory disorders. Many inflammatory mediators (interferon- γ , interleukin-1 β , TNF- α , IL-6, TGF- β) increase in degenerative aortic aneurysms and their disharmony stimulates aneurysm formation [12, 13]. Genetic abnormalities can also cause this disharmony that results abnormal functions and structures in aortic wall. These disorganizations can cause early degeneration of the vascular wall and aneurysmal formation. Some genetic defects or mutations causing specific diseases are well described: *gene ACTA2* to familial thoracic aortic aneurysm; *gene TGFB1* to Loeys-Dietz syndrome; *gene TGFB2* to familial thoracic aortic aneurysm, Marfan syndrome, and Loeys-Dietz syndrome; *gene FBN1* to Marfan syndrome; *gene COL3A1* to Ehlers-Danlos syndrome.

5. Pathophysiology

Aortic root aneurysm occurs due to decreased connective tissue strength or elevated pressure in the aorta. High content of an elastic fiber in the medial layer of the aortic root provides

expansion during systole acting as a reservoir and stores kinetic energy resulting by left ventricular contraction as potential energy in the aortic wall. In diastole, elastic recoil returns the aortic root to its original form back and transforms the stored potential energy back to kinetic energy to start aortic wave motion for forward blood flow. Several pathological changes lead to degenerative processes in the elastic media and decreasing the strength of the aortic wall connective tissue.

The coupling between mechanical stress and the biochemical changes leading an aneurysmal formation is not well elucidated. Several adversely changed mechanisms such as decreased aortic wall compliance, broken cross-sectional symmetry, and disrupted stress-strain relationships increase intraluminal systolic impulse stress and aortic wall tension, which active predate dilatation formation (tension = pressure \times radius). Because the inner curvature of the aortic root is adherent to the pulmonary artery, the NCS is the most affected part of the root and the typical enlargement occurs at the STJ level, especially in aortic root dilatation associated with ascending aortic aneurysm. Synchronously involvement of three sinuses causes a symmetrical aneurysmal dilatation (resembling a pear).

6. Etiology

There are different specific etiologies causing aortic root aneurysm (**Table 2**). Most of them have genetic origin, but the most common etiology is *bicuspid aortopathy*. The prevalence of aortic dilation ranges from 20 to 84% in bicuspid aortic valve (BAV) disease [14]. In patients with BAV disease, three enlargement patterns are described according to whether the maximal aortic diameter is at the level of the sinuses of Valsalva, the STJ, or the ascending aorta. Four subtypes of BAV disease are identified with different forms of aortic dilation: aortic root alone (13%), ascending aorta alone (10%), ascending aorta and proximal transverse arch (28%), and from the aortic root to the proximal transverse arch (45%) [15]. There is a relationship between the morphology of the ascending aorta and the valve fusion pattern: left coronary cusp-right coronary cusp type associated with ascending aorta and aortic root dilation; right coronary cusp-noncoronary cusp type associated with only ascending aorta dilatation. Isolated *sinuses of Valsalva aneurysm* develop because of either a congenital defect or acquired pathologies such as endocarditis, aortic dissection, or iatrogenic causes [16]. The most common cause is weakness between the media and the annulus fibrosus of the aorta, which can cause aneurysmal enlargement. The RCS is most frequently affected, followed by the NCS. The aneurysm can rupture into any of low-pressure cardiac chambers, especially into the right-sided ones, to form an aortico-cardiac fistula. Aortic valve abnormalities and incompetence occur especially after rupture. Genetic diseases with autosomal dominant penetrance usually involve multiple organ systems, and their common involvement is the aorta. The most common genetic disease with an aortic root aneurysm is the **Marfan's syndrome**, which is associated with mutations in the FBN-1 gene and has autosomal dominant heredity [17]. Approximately 3/4 of patients with Marfan's syndrome have aortic root dilatation with or without aortic valve regurgitation and 1/2 mitral regurgitation.

-
1. Bicuspid aortic valve disease
 2. Sinus of Valsalva aneurysm
 3. Genetic diseases
 - a. Marfan's syndrome
 - b. Ehlers-Danlos syndrome
 - c. Loeys-Dietz syndrome
 - d. Turner syndrome
 - e. Aneurysm-osteoarthritis syndrome
 - f. Nonsyndromic familial thoracic aneurysms
 4. Familial aneurysms
 5. Infection
 6. Inflammatory diseases
 - a. Takayasu's arteritis
 - b. Giant cell arteritis
 - c. Behçet's disease
 - d. Ankylosing spondylitis
 - e. Wegener's granulomatosis
 - f. Rheumatoid arthritis
-

Table 2. Etiology for aortic root aneurysm.

7. Diagnosis

Although clinical symptoms (retrosternal pain, hoarseness, breathless, etc.), examination (aortic valve murmur), and several laboratory testing play a minor role in the diagnosis of the aortic root aneurysms, noninvasive imaging techniques have a major role yielding a view of the total intrathoracic aorta [18]. In the daily practice, transthoracic echocardiography associated with transoesophageal echocardiography is the most frequently used technique for the diagnosis, which should be completed with thoracic computed tomography and/or magnetic resonance imaging, as well as ultrasonography and/or computed tomography for the abdominal aorta. It is recommended to measure diameters at anatomical landmarks perpendicular to the longitudinal axis (antegrade flow in the aortic root and ascending aorta) and to use the same imaging modality with a similar method of measurement in the case of repetitive imaging of the aorta. The aortic annulus should be measured at midsystole from the inner-edge-to-inner edge and all other aortic root measurements (i.e., maximal diameter of the sinuses of Valsalva, the sinotubular junction, and the proximal ascending aorta) should be made at end-diastole. Measurements of maximal diameters of the aortic root should be compared with age- and BSA-related nomograms or to values calculated from specific allometric equations (**Table 3**).

Aortic root	Absolute values (cm)		Indexed values (cm/m ²)	
	Men	Women	Men	Women
Annulus	2.6 ± 0.3	2.3 ± 0.2	1.3 ± 0.1	1.3 ± 0.1
Sinuses of Valsalva	3.4 ± 0.3	3.0 ± 0.3	1.7 ± 0.2	1.8 ± 0.2
Sinotubular junction	2.9 ± 0.3	2.6 ± 0.3	1.5 ± 0.2	1.5 ± 0.2
Proximal ascending aorta	3.0 ± 0.4	2.7 ± 0.4	1.5 ± 0.2	1.6 ± 0.3

Table 3. Aortic root dimensions in normal adults.

Aneurysm surveillance in asymptomatic patients includes ongoing clinical evaluation, the development of symptoms, signs of aneurysm complications, and serial imaging to evaluate the diameter and structure of the aneurysm. Ideally, the serial studies should be performed using the same technique (echocardiography, computed tomographic angiography or magnetic resonance angiography) in the same center for consistency with future comparisons. Aortic valve function and morphology should be evaluated during follow-up; therefore, echocardiographic assessment should be considered in aortic root aneurysm. The surveillance program may be modified based upon the etiology, site, and diameter of the aneurysm at presentation. In general, imaging at 6 months after the initial diagnosis could ensure the stability of the aneurysm and expansion rate. The thoracic aorta expands slowly with the age at a rate of 0.7 mm in women and 0.9 mm in men per decade of life. The expansion rate of the aortic aneurysms is much higher than these values, and a larger diameter of aortic root aneurysms could expand more rapidly than smaller ones like other segments of the aorta: the rate of expansion for large aneurysms (>5 cm) was about 8 mm per year while 2 mm per year for smaller aneurysms (<5 cm).

8. Indications

Once the aortic root aneurysm detected patient should be examined for concomitant diseases, genetically mediated disorders and risk factors. Major life threatening complications are dissection, rupture, and aortic valve regurgitation. Because of the elevated mortality risk associated with complications, an effective aortic root aneurysm management depends on reduction the risk of death, rupture, and dissection. The most important determinant is the diameter of the aneurysm. Other factors, such as a rapidly expanding aortic diameter, concomitant bicuspid aortic valve, or connective tissue disease also increase the risk of rupture.

Medical treatment depends on reducing aortic wall stress and slow down medial degeneration. Lifestyle modifications contain smoking cessation, avoiding intensive exercise, and patient education. Aggressive antihypertensive therapy is the mainstay of pharmacologic management to prevent increased wall stress. If tolerated, a goal of the therapy is

-
- A. Presence of elastopathy
 - 1. Without risk factors
 - a. ≥ 50 mm
 - b. Diameter increase > 3 mm/year
 - 2. With family history of aortic dissection and/or aortic diameter increase
 - a. ≥ 45 mm
 - b. Diameter increase > 3 mm/year
 - B. Presence of BAV
 - 1. ≥ 55 mm
 - 2. ≥ 50 mm associated with
 - a. Diameter increase > 3 mm/year
 - b. Family history of dissection
 - c. Coarctation of the aorta
 - d. Systemic hypertension
 - e. Moderate AI and/or AS
 - 3. > 45 mm when AVR is scheduled
 - C. Presence of significant aortic valve insufficiency and/or stenosis
 - 1. ≥ 50 mm
 - 2. Diameter increase > 3 mm/year
 - D. Absence of elastopathy or any risk factor
 - 1. ≥ 55 mm
 - 2. Diameter increase > 5 mm/year

Note: AI = aortic insufficiency; AS = aortic stenosis; AVR = aortic valve replacement; BAV = bicuspid aortic valve.

Table 4. Surgical indications for asymptomatic aortic root aneurysms without dissection.

maintaining a systolic pressure below 120 mmHg. Beta-blockers reduce the contractility of the heart, decrease shear stress, and the impact force of ejected blood on the aorta. Although these beneficial effects, it should be noted that the β -blocker therapy will block the compensatory tachycardia and could precipitate clinical deterioration in aortic regurgitation. Reduction in heart rate is also associated with an even higher stroke volume, which contributes to the elevated systolic pressure in patients with chronic severe aortic regurgitation. On the other hand, patients treated with β -blockers have a significantly lower growth rate (1.2 mm/year) than those without β -blocker treatment (4.2 mm/year), which shows the beneficial effect and the importance of β -blocker medical therapy on aneurysm stabilization [19].

Surgical indication is dependent on the presence of symptoms and diameter measurements of several parts of the ascending aorta. In general, surgical repair of asymptomatic aortic root aneurysm is not recommended until the risk of dissection, rupture or other complications exceeds the risks associated with surgery (**Table 4**). In general, asymptomatic aortic root aneurysms without dissection must be directed to surgical treatment depending upon an aortic diameter (≥ 5 cm) and speedy expansion rate (≥ 5 mm/year); however, in the presence of underlying special contributing etiologies these limits should be decreased (≥ 4.5 cm or ≥ 3 mm/year or the presence of acute or chronic aortic dissection). Aneurysms can cause symptoms especially in larger diameters. Symptoms could be pioneers of fatal complications, therefore surgery should be considered for symptomatic patients either at smaller diameters of aneurysm.

9. Surgery

Aortic valve replacement (AVR) with supracoronary ascending aorta replacement is the first aortic root surgery operation. The Bentall technique is the first true total aortic root replacement (ARR) procedure, which contains en bloc replacement of the ascending aorta. The modified Bentall technique eliminates wrapping of the native aortic wall over the tubular graft. The Button technique eliminates most of problems regarding to coronary ostial anastomoses via end-to-side reimplantation of the coronary ostia. A interposition graft between the coronary ostia and the composite graft to prevent coronary malposition is especially useful when mobilization of the coronary buttons is often difficult or impossible. Other modifications include leaving a small part of the tubular graft below the prosthetic valve to simplify and secure aortic annular anastomosis [20–22], To simplify proximal annular anastomosis, a prefabricated composite graft with sinus of Valsalva can be chosen [23].

Conventional open heart surgery is the essential procedure for isolated ARR. Urgent surgery is usually preferred for life-threatening pathologies of the aortic root, and standard approaches should initially be used for emergent situations or with concomitant cardiac procedures. Some more recent approaches toward more noninvasive surgery can be considered in elective, noncomplicated-isolated aortic root surgery. General anesthesia with full median sternotomy is the standard approach for aortic root surgery, and transesophageal echocardiography is mandatory in cases of aortic valve-sparing procedures. Awake cardiac surgery offers several advantages over general anesthesia, including the absence of tracheal intubation, reduced stress response, lower postoperative arrhythmias, and improved pulmonary outcome [24–26]. This approach may be more beneficial and safer in patients with chronic obstructive pulmonary disease who are frequently rejected for cardiac surgery [27, 28]. This approach should be only used in elective cases with noncomplicated aortic root surgery, whereas general anesthesia remains the preferred option in aortic valve-sparing procedures or in emergency situations. Full median sternotomy is the versatile and most reliable option

to reach all sites of the heart, but minimal invasive incisions may be preferred in order to reduce invasivity and adverse effects of full median sternotomy. The full median sternotomy can be restricted only to perform aortic root surgery in the presence of other concomitant cardiac pathologies, otherwise limited median sternotomy techniques are the best approach for isolated aortic root surgery due to shorter hospitalization periods, improved lung functions, reduced trauma effects, and early mobilization. There are two most preferred minimal invasive incision techniques for access into the mediastinum: *J sternotomy* is the most preferred ministernotomy incision in isolated AVR operations [29, 30], but only *upper reverse-T ministernotomy* is an appropriate approach to reach the aortic root and to perform all varieties of aortic root surgeries [31, 32]. After the usual preparations, standard central arterial cannulation is established through the distal ascending aorta or the lateral wall of the mid aortic arch. If any dissection is present at the ascending aorta, the arterial cannulation should be performed through a patent peripheral artery [33]. Venous cannulation is prepared using a thinner single two-staged venous cannula through the right atrial appendage or an appropriate venous cannula through the femoral vein, and venous return is maintained via a negative vacuum venous drainage system. A negative vacuum system is very effective in emptying the heart and can achieve left heart decompression without the use of a vent cannula. A vent cannula is passed through the right upper pulmonary vein into the left atrium. Cardiopulmonary bypass is established at 32°C, but if an extended operation time is predicted, perfusate temperature decreases to 28°C. After cardioplegic arrest is accomplished, myocardial protection is achieved via an antegrade (direct coronary ostia) or a retrograde (through the coronary sinus) route.

Conventional open heart surgery is the essential procedure for isolated ARR and a type of procedure could be selected due to the pathology (**Table 5**). It is always a good idea to keep in mind that the ARR surgery is a life-saving procedure and there are not many drawbacks to the conventional procedures. On the other hand, less invasive or aggressive interventions may be chosen in elective and selective cases [34]. The first goal during ARR is to spare the competent aortic valve if possible. If not possible, the use of a composite graft to replace whole ascending aorta seems the most preferred option during ARR. The first choice of a prosthetic valve for ARR is a mechanical valve due to its simple handling, easy sizing, lower profile, long-term durability, and resistance to mechanical stress. Composite grafts with stentless bioprosthetic valves can be chosen in older patients to avoid valve-related late reoperations. But, using mechanical valve conduits could be changed to the use of bioprosthetic composite grafts in all age groups if the transcatheter methods offer similar or better results when compared to reoperative ARR procedures. Although allografts can be the best option for the total ARR, their availability is very limited in most countries.

9.1. Total aortic root replacement procedures with aortic valve replacement

The modified Bentall technique with mechanical or stentless biological valve is the gold standard for the total ARR (**Figure 3**). The “modified” procedure describes the discontinuation of the practice of wrapping the aortic wall over the graft and the button anastomosis of the

-
- A. Total aortic root replacement
 - I. With aortic valve replacement
 - 1. Modified Bentall procedure
 - 2. Cabrol procedure
 - 3. Flanged procedure
 - 4. Biologic Bentall procedure
 - a. Allograft
 - b. Xenograft
 - 5. Ross procedure
 - II. Without aortic valve replacement (valve-sparing aortic root replacement)
 - 1. Remodeling (Yacoub procedure)
 - 2. Reimplantation (David V procedure)
 - B. Subtotal aortic root replacement (without aortic valve)
 - 1. One sinus replacement
 - 2. Double sinus replacement
 - 3. Sinus of Valsalva aneurysm repair
 - C. Extensive aortic root replacement (with aortoventricular base)
-

Table 5. Aortic root replacement techniques.

coronary ostia rather than as required in the originally described technique. After aortic cross-clamping, a 2 cm transverse aortotomy is performed just above the STJ to visualize the aortic root and leaflets, and then the ascending aorta is divided completely. The second step is resection of aortic sinuses and leaflets, which remains 3–5 mm over from the transected tissues. Preparing the coronary buttons with a 1.5 cm diameter cuff of the aortic wall and mobilizing over a short length to facilitate reimplantation is the last step before composite graft implantation. All other necessary concomitant procedures such as distal anastomosis of coronary bypass grafts and/or valvular repair/replacement are performed before the ARR. To prevent postoperative bleeding from the proximal anastomosis, a reinforcement suture joining the incised edge of the aortic wall and the prosthetic sewing ring can be used [35]. The miniskirt technique has been developed to secure proximal bleeding, where first all interrupted mattress sutures enter the aortic annulus, the sewing ring of the prosthesis and the vascular graft leaving a short segment, and then proximal hemostasis is secured with a running suture by buttressing the aortic remnants and graft edge [20]. Alternatively, a short skirt of Dacron tube can be added to the proximal end of a standard composite graft and sewn to the remaining native aortic wall to wrap the proximal annular anastomosis after the completion of the implantation of this modified composite graft on the aortic annulus [36].

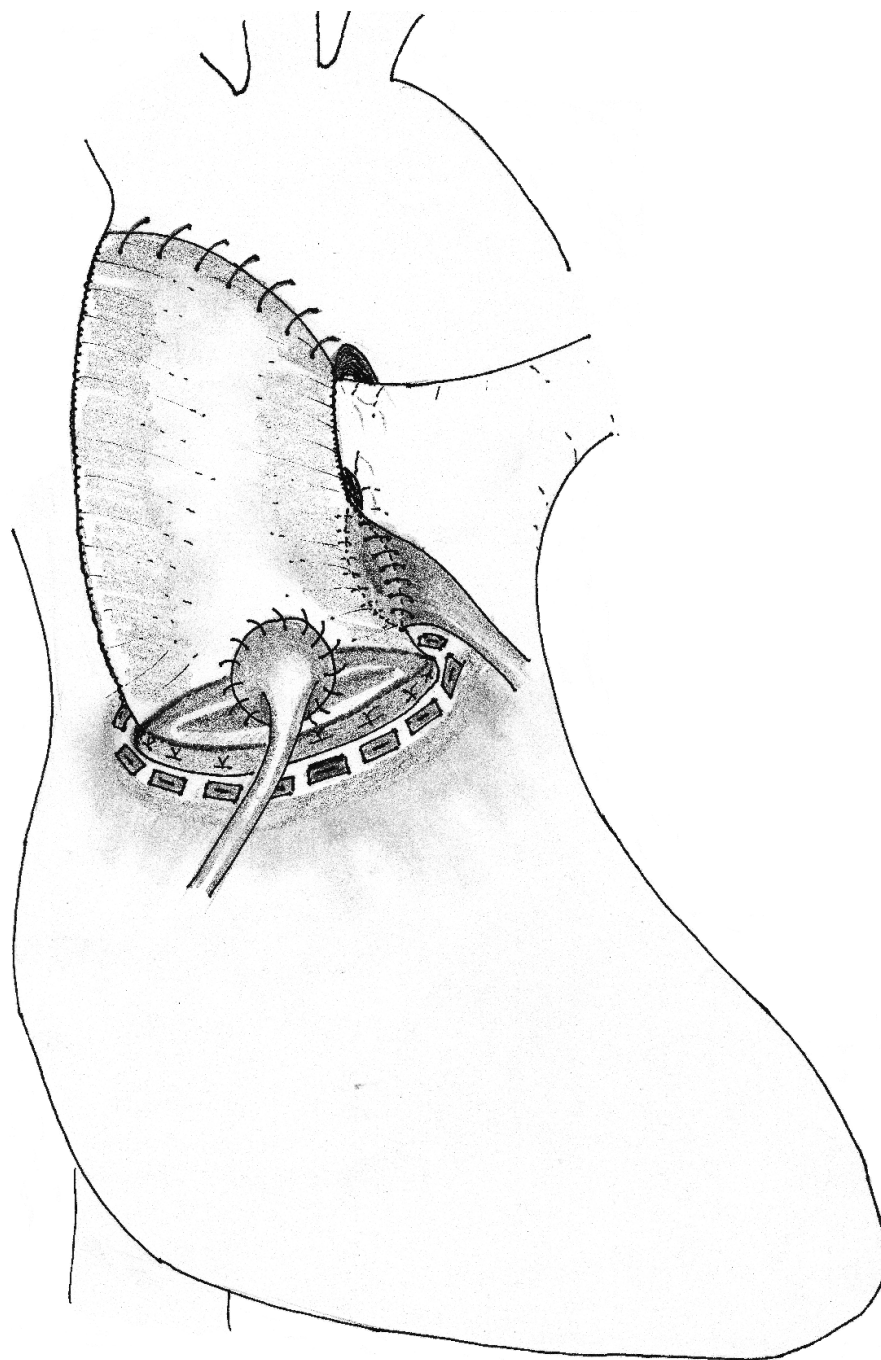


Figure 3. Modified Bentall procedure.

The *Cabrol technique* is carried out using a “moustache-shaped” interposition tubular graft (8 mm) between coronary ostia and aortic graft (**Figure 4**). This technique can be very useful in reoperation procedures, where the mobilization of the coronary buttons is difficult, and also in severely calcified coronary ostia. Except coronary ostium anastomoses, all operative steps are similar to the modified Bentall procedure, as described in detail above. In some cases with an extremely large aortic diameter at the level of sinuses, the right coronary button anastomosis can be challenging if the mobilization of the right coronary button is not adequate to reach the relatively small prosthetic neoaorta. Because this technique has worse outcomes

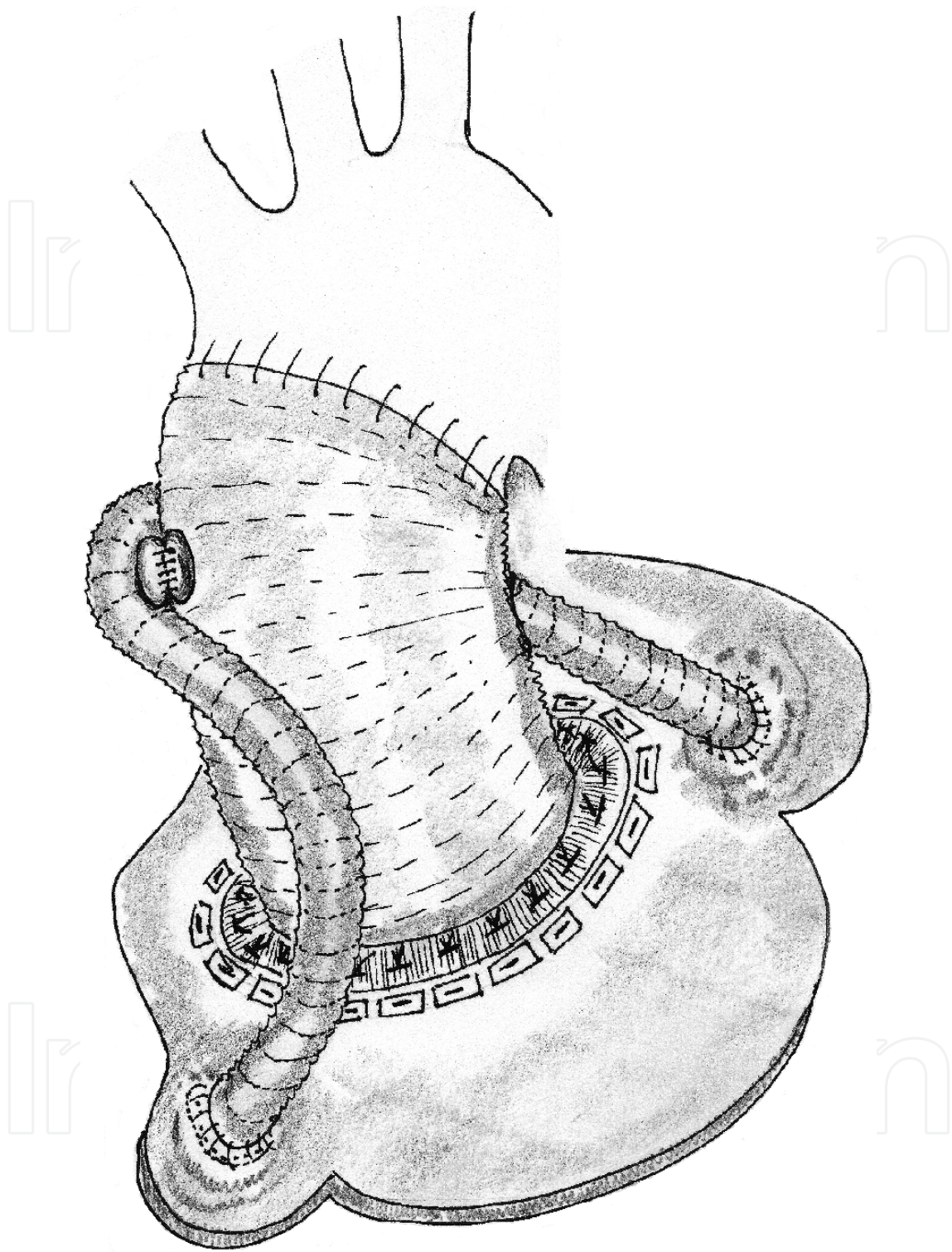


Figure 4. Cabrol procedure.

due to stenosis, thrombosis, and occlusion of the longer interposition graft, several modifications of this classic technique have been developed to mitigate these problems [37, 38]. There are three alternatives: an interposition graft can be anastomosed conjointly to coronary ostia; two small interposition grafts can be anastomosed between each coronary ostium and aortic

graft separately; one coronary ostium can be anastomosed directly and the second ostium is anastomosed with a separate interposition graft to the aortic graft.

The Flanged technique prevents anastomotic difficulties of the proximal end of the composite graft, bleeding or dehiscence at the annular anastomosis (**Figure 5**). This technique provides the continuance of the flexibility and elasticity of the proximal end of the composite graft [39]. This method may be the best alternative for tailoring the aortic root in all aortic root pathologies, especially in patients with a small aortic root requiring posterior annular enlargement, calcified aortic annulus, aortic root abscess, or subannular defects. The length of the flange (1–3 cm long)

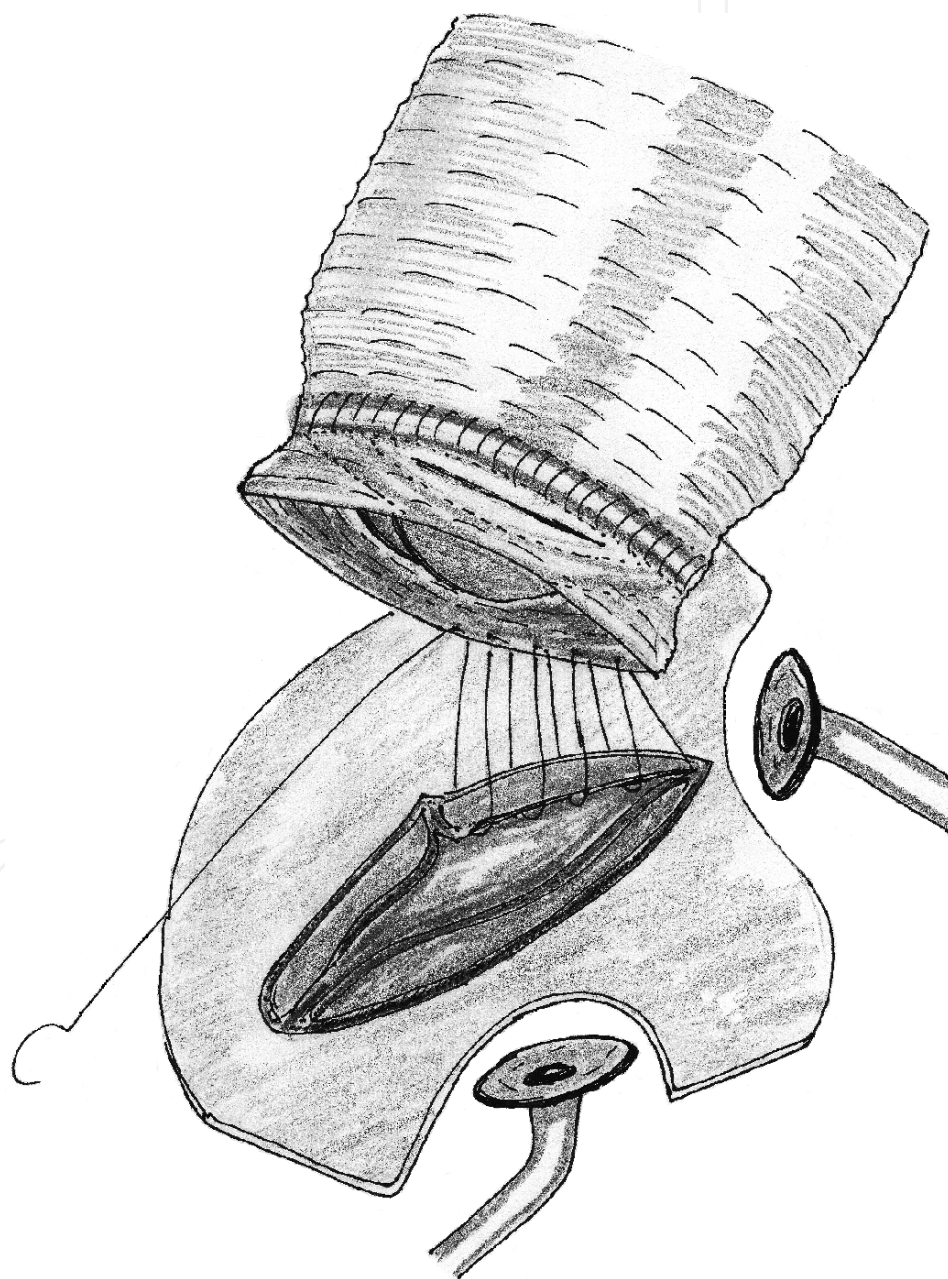


Figure 5. Flanged technique.

is adjusted depending on these procedures. The flange of the composite graft is implanted to the aortic annulus, where remained 3–5 mm aortic valve and the ascending aortic tissues are used as a double-sided strip (the free end of the tubular graft is interposed between these tissues) to prevent surgical bleeding and late pseudoaneurysm. In nondestroyed aortic annulus, sequential pledged mattress sutures can be incorporated to prevent postoperative bleeding through intersutures gaps. The newly created pseudosinus tubular graft is the main preventive maneuver of this technique against stretching or kinking of the button anastomosis. The distal anastomosis of the composite tubular graft is performed in the same way as in the modified Bentall procedures.

The biologic Bentall technique with tissue composite graft provides an excellent hemodynamic profile similar to the native aortic root, very low transvalvular gradient, no anticoagulation, and very low risk of infection; however, the main disadvantage is structural degeneration. *Allograft* implantation is a reliable solution for the total ARR instead of prosthetic composite conduit options. The main indications are active destructive aortic valve endocarditis with root abscess, small aortic root in older patients, and contraindications against anticoagulation. But the use of allografts is infrequent because of limited availability of donors and the larger size roots. The root replacement technique has several advantages such as no distortion of the commissural positions, no asymmetry for the size mismatch, and the total exclusion of the native root pathology. In the case of a need of a patch or tissue below the aortic annulus, the mitral anterior leaflet of the allograft is also trimmed at this stage. Resection of the native aortic root with preparation of coronary buttons is similar in the Bentall procedure. *Xenograft* is a useful option for biologic Bentall because of the large availability of different sizes, improved durability, stentless structure, and reduced cost. Implantation of xenografts is very similar to aortic allograft [40].

The Ross technique is based on transferring the pulmonary root to the aortic position and the replacement of the pulmonary root with a pulmonary allograft or stentless porcine roots [41]. The pulmonary root can be an optimum substitute to the native aortic root, with a similar physiology and hemodynamic profile. The size difference between aortic and pulmonary annulus should not be more 2 mm, otherwise the diameter of the dilated aortic annulus should be reduced. The main advantages of the Ross technique are resistance to infection, no need for anticoagulation, and capability for somatic growth. However, the technical complexity of the operation and the risk of reintervention of the biologic grafts have limited widespread usage of the Ross procedure [42].

9.2. Total aortic root replacement with aortic valve sparing procedures

Aortic root pathologies with normal anatomic structure of the aortic leaflets causing significant aortic regurgitation are the primary indication for sparing aortic valve with/without aortic valve repair during the total ARR. Aortic valve sparing procedures allow avoidance of anticoagulation, prosthetic material, and postoperative transvalvular gradient. There are two major techniques with own advantages and disadvantages. The remodeling technique is preferred if any annular stabilization is not necessary, while the reimplantation technique is essential if annular stabilization is inevitable. The proximal anastomosis is completely different from valvular composite graft procedures, but coronary and distal anastomoses have similar surgical technical details to the modified Bentall procedure.

The remodeling technique (Yacoub procedure) does not touch the aortic annulus and/or subannular area (**Figure 6**). The ascending aorta is transected 2 cm above the sinotubular junction and then three sinuses of Valsalva are resected, leaving approximately 5 mm of aortic wall above the annulus for suturing of the tubular graft. The three commissures are hung up until the aortic

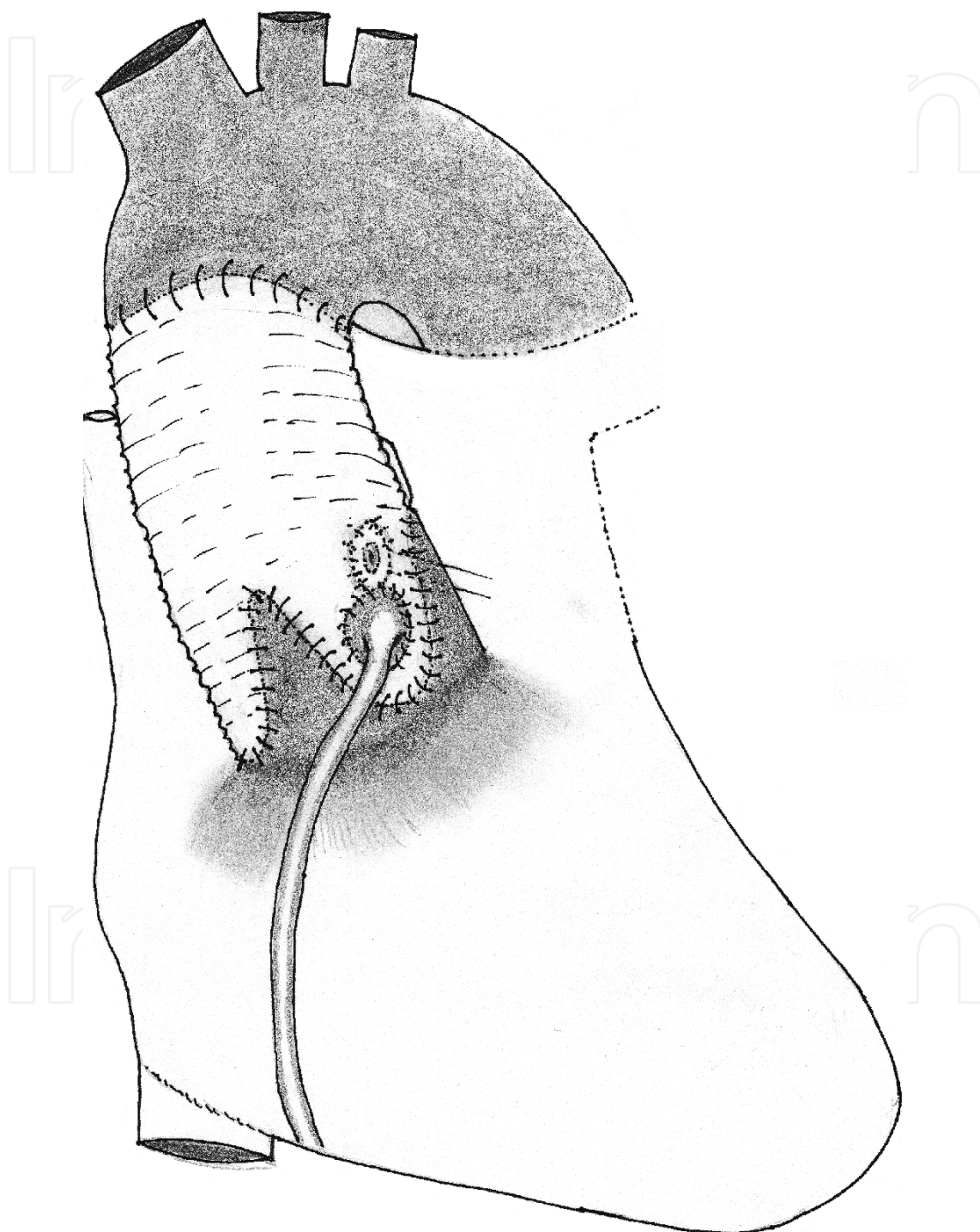


Figure 6. Remodeling technique (Yacoub).

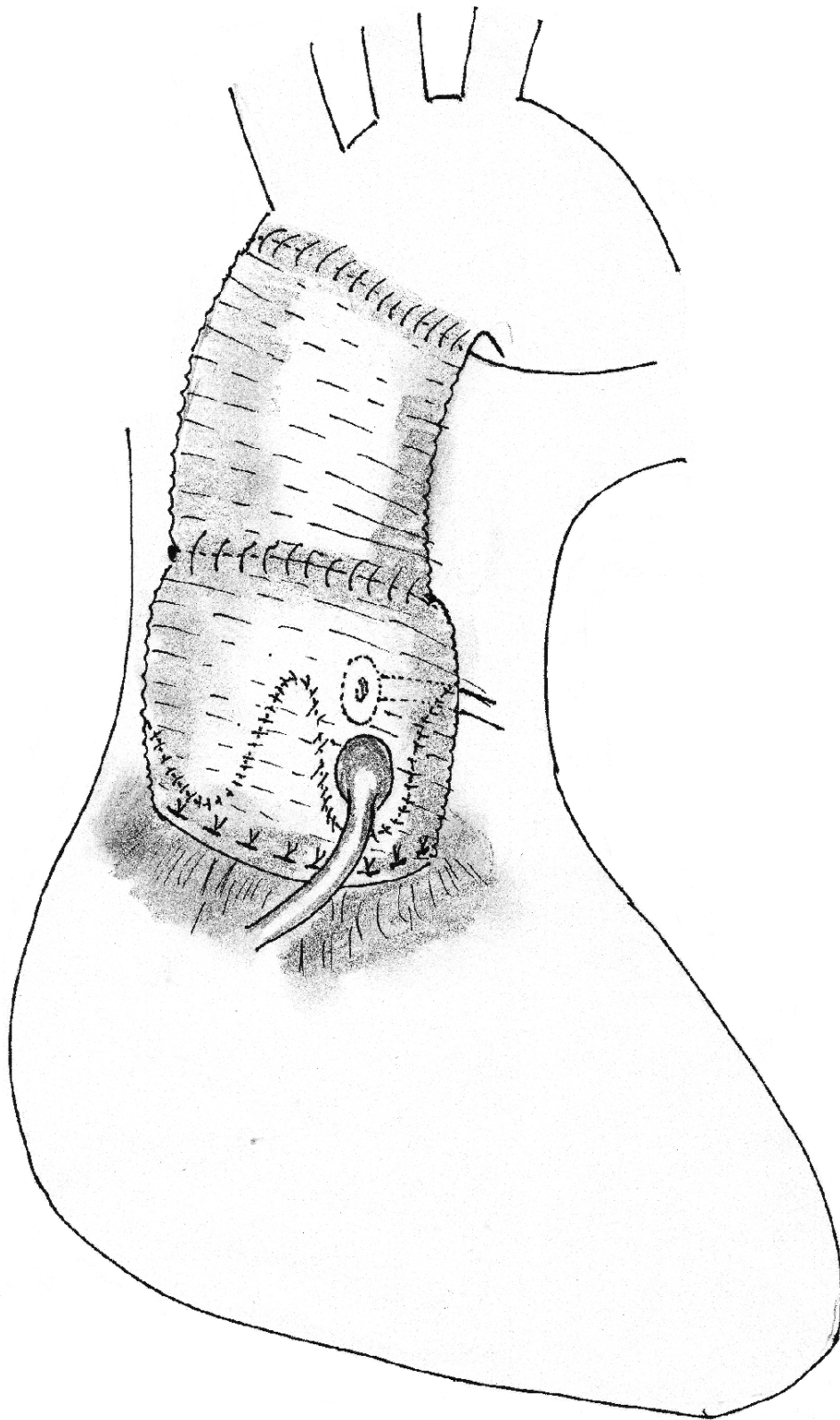


Figure 7. Reimplantation technique (David V).

leaflets coapt, and then appropriate sizing is performed to select the suitable graft. The stentless valve seizer is the easiest way to measure the annular diameter, and the number of seizer is the true graft size when it fills the aortic annulus. Three commissures are marked on the tubular graft and it is tailored to make three neo aortic sinuses, and their heights should be equal to the diameter of the graft. The graft with three tongues is sutured to the aortic wall at the annulus.

The *reimplantation technique (David-V procedure)* is useful for annular stabilization (**Figure 7**). The resection of the aortic root is similar to the remodeling technique, except graft preparing and suturing. If the ascending aorta dilatation causes aortic regurgitation with normal aortic annulus, the graft size must be equal to the annular diameter. In all other situations with aortic annular dilatation, the graft size should be decided very carefully. Because the straight graft causes native aortic valve deterioration, pseudosinuses are essential for avoidance of late valve degeneration. The larger graft is preferred for neo aortic root with neo pseudosinuses and the smaller graft is used for neo ascending aorta. To measure and decide the appropriate proximal tubular graft size, intra- or supra-annular seizers for stented bioprosthetic valves can be used [43]. If an *intra-annular seizer* is used, the appropriate graft size must be equal to the number of seizer (= inner diameter) + 5–6 mm. If a *supra-annular seizer* is used, the seizer is placed onto the aortic annulus and the base of three trigons should be visible through the supra-annular seizer. The appropriate graft size must be the number of seizer (= inner diameter) + 1–2 mm. When Valsalva graft is used for the reimplantation technique the graft size must be equal the height of the NCC-LCC commissure, which is equal to the external diameter of the sinotubular junction [44]. All mattress sutures with or without pledgets are passed from the inside of the left ventricle to the outside just below the aortic valve and then through the base of the graft and tied. That achieves annular reduction in patients with annular dilatation. The other important step is creating the correct position and height of commissures within the graft, which is the main mechanism to prevent leaflet prolapses and to secure competence of the aortic valve. After three placement sutures are tied, the aortic wall in each sinus is sutured continuously to the inside of the graft. The coronary artery reimplantations are performed by using the same procedure as described for the total ARR. The second smaller graft is anastomosed to the first graft, which helps to build a neo sinotubular junction and the crown-shaped aortic annulus. The key point during the anastomosis of both grafts together is to take the equal distance from both grafts for each bite at the commissural levels and longer from the proximal graft between commissures. This maneuver narrows intercommissural distance, which has been created by the larger proximal graft, to create an equal ring as a reduced annular ring [45].

9.3. Subtotal aortic root replacement procedures

These techniques are subtypes of the standard remodeling technique and popularized to avoid either a total composite or aortic valve sparing root replacement procedure. The aortic root seems more or less intact, and may distort aortic valve functions. Subtotal aortic root remodeling techniques can be preferred if all three sinuses are not involved without an aortic annular dilatation. Significant aortic annular dilatation requiring annular fixation is a contraindication for these approaches. Another indication is supra-annular stenosis, which can be congenital or acquired, and the repair option of this pathology depends on

its involvement: single [46], double [47], or triple [48] sinus replacement. Isolated sinus involvement usually affects NCS, especially in a bicuspid aortic valve. Aortic root enlargement is not diffuse and both coronary sinuses seem normal. The other rare pathology is restricted aortic dissection with/without involving the ascending aorta and chronic healing surrounds the dissection tear. The affected sinus can be replaced with a patch or with prosthetic tubular graft having a tongue-shape extension. If ascending aorta replacement is not necessary, a Dacron patch is tailored as a new sinus and sutured to the annulus of the resected sinus of Valsalva. The shape of the patch should be appropriate to the sinus, but the width should be <10 mm more than the diameter between two commissures and the height <10 mm more than the diameter from the annulus to the sinotubular junction. Subtotal root remodeling on the two sinuses can be chosen for acute aortic dissection without left coronary ostial involvement if aortic root dilatation is not greater than 35 mm, which can prevent the reimplantation of the left coronary ostium. On the contrary, if both coronary sinuses are involved or the presence of aortic annular dilatation requires aortic annular stabilization, any total ARR is more meaningful.

9.4. Sinus of Valsalva aneurysm repair techniques

Repair is recommended for ruptured aneurysms, significant aortic valve regurgitation, associated intracardiac abnormalities, or symptomatic unruptured or enlarging aneurysm. Rupture of sinus of Valsalva aneurysm is a life-threatening complication and requires immediate surgical or interventional closure. Surgical closure is the gold standard treatment, but percutaneous closure can be chosen in very sick patients [49]. Different surgical approaches can be used: transaortic, double-chamber, or involved chamber. The transaortic approach is used for isolated sinus of Valsalva aneurysm with/without aortic regurgitation, especially in unruptured cases. The double-chamber approach is chosen mostly in ruptured aneurysms because of closing defect from both sides or the presence of any intracardiac pathology [50]. The last approach is used very seldom because of possible bacterial colonization or thrombus formation inside the aneurysm, or recurrent fistula formation or rupture of aneurysmal sac. The goals of repair are removing the aneurysmal sac, closing the defect primary or with a patch or with valve replacement, and repairing any associated defects. Patch closure at the aortic end is the most preferred technique, which minimizes aortic leaflet distortion, with/without a concomitant surgery for aortic valve repair.

9.5. The extensive aortic root replacement technique

Aortic root abscess continues to challenge cardiovascular surgeons, because uncontrolled aortic root abscess can manifest itself as a burrowing pathology destroying the whole aortic annulus and extending proximally into the left ventricular outflow tract, a cardiac fistula or a rupture into a cardiac chamber, a pseudoaneurysm, or an arrhythmia leading to hemodynamic instability. Early and extensive surgical intervention of aortic root abscesses is essential, and the complexity of the surgical treatment ranges from partial resection of the aortic annulus and surrounding tissues to radical removal of the base of the heart—including the entire aortic root, the intervalvular fibrous body, and part of the interventricular septum.

The extensive ARR technique is the only option to rebuild the left ventricular outflow tract due to the reconstruction of the neo aortoventricular continuity in the isolated aortic root abscess. The flanged technique with the elongated tubular graft below the prosthetic valve is the best option for solving this life-threatening sequel and reconstructing the aortic root [51]. A larger (3 cm) segment of the proximal end of the tubular graft is implanted in a circular manner with 2–0 interrupted sutures supported by large Teflon pledgets placed subannularly on healthy tissue at the native left ventricular outflow tract. Both ends of the sutures are passed through the proximal free end of the flanged portion of the conduit in order to use that part as a strip between knots and the myocardial aortic wall.

Author details

Kaan Kırallı^{1,2*} and Deniz Günay¹

*Address all correspondence to: imkbkiralı@yahoo.com

1 Department of Cardiovascular Surgery, Kartal Kosuyolu YI Education and Research Hospital, Istanbul, Turkey

2 Department of Cardiovascular Surgery, Faculty of Medicine, University of Sakarya, Sakarya, Turkey

References

- [1] Lang RM, Badano LP, Mor-Avi V, Afilalo J, Armstrong A, Ernande L, Flachskampf FA, Foster E, Goldstein SA, Kuznetsova T, Lancellotti P, Muraru D, Picard MH, Rietzschel ER, Rudski L, Spencer KT, Tsang W, Voigt JU. Recommendations for cardiac chamber quantification by echocardiography in adults: An update from the American Society of Echocardiography and the European Association of Cardiovascular Imaging. *J Am Soc Echocardiogr* 2015;28(1):1–39.
- [2] Evangelista A, Flachskampf FA, Erbel R, Antonini-Canterin F, Vlachopoulos C, Rocchi G, Sicari R, Nihoyannopoulos P, Zamorano J. Echocardiography in aortic diseases: EAE recommendations for clinical practice. *Eur J Echocardiogr* 2010;11(8):645–658.
- [3] Hal-Ali R, Marom G, Zekry SB, Rosenfeld M, Raanani E. A general three-dimensional parametric geometry of the native aortic valve and root for biomechanical modeling. *J Biomech* 2012;45(14):2392–2397.
- [4] Khelil N, Sleilaty G, Palladino M, Fouda M, Escande R, Debauchez M, Di Cesta I, Lansac E. Surgical anatomy of the aortic annulus: Landmarks for external annuloplasty in aortic valve repair. *Ann Thorac Surg* 2015;99(4):1220–1227.
- [5] Choo SJ, McRae G, Olomon JP, St George G, Davis W, Burleson-Bowles CL, Pang D, Luo HH, Vavra D, Cheung DT, Oury JH, Duran CM. Aortic root geometry: Pattern of differences between leaflets and sinuses of Valsalva. *J Heart Valve Dis* 1999;8(4):407–415.

- [6] Contino M, Mangini A, Lemma MG, Romagnoni C, Zerbi P, Gelpi G, Antona C. A geometric approach to aortic root surgical anatomy. *Eur J Cardiothorac Surg* 2016;49(1):93–100.
- [7] Martin M, Sievers HH. Heart valve macro-and microstructure. *Philos Trans R Soc Lond B Biol Sci* (2007); 362(1484):1421–1436.
- [8] Rabkin SW. Accentuating and opposing factors leading to development of thoracic aortic aneurysms not due to genetic or inherited conditions. *Front Cardiovasc Med* 2015;2:21.
- [9] Toumpoulis IK, Oxford JT, Cowan DB, Anagnostopoulus CE, Rokkas CK, Chamogeorgakis TP, Angouras DC, Shemin RJ, Navab M, Ericsson M, Federman M, Levitsky S, McCully JD. Differential expression of collagen type V and XI α -1 in human ascending thoracic aortic aneurysms. *Ann Thorac Surg* 2009;88(2):506–513.
- [10] Huusko T, Salonurmi T, Taskinen P, Liinamaa J, Juvonen T, Pääkkö P, Savolainen M, Kakko S. Elevated messenger RNA expression and plasma protein levels of osteopontin and matrix metalloproteinase types 2 and 9 in patients with ascending aortic aneurysms. *J Thorac Cardiovasc Surg* 2013;145(4):1117–1123.
- [11] Jackson V, Olsson T, Kurtovic S, Folkersen L, Paloschi V, Wågsäter D, Franco-Cereceda A, Ericsson M. Matrix metalloproteinase 14 and 19 expression is associated with thoracic aortic aneurysms. *J Thorac Cardiovasc Surg* 2012;144(2):459–466.
- [12] Zhang L, Liao MF, Tian L, Zou SL, Lu QS, Bao JM. Overexpression of interleukin-1 β and interferon- γ in type I thoracic aortic dissections and ascending thoracic aortic aneurysms: Possible correlation with matrix metalloproteinase-9 expression and apoptosis of aortic media cells. *Eur J Cardiothorac Surg* 2011;40(1):17–22.
- [13] Gillis E, Van Laer L, Loeys BL. Genetics of thoracic aortic aneurysm: at the crossroad of transforming growth factor- β signaling and vascular smooth muscle cell contractility. *Circ Res* 2013;113(3):327–340.
- [14] Verma S, Siu SC. Aortic dilatation in patients with bicuspid aortic valve. *N Engl J Med* 2014;370(20):1920–1929.
- [15] Fazel SS, Mallidi HR, Lee RS. The aortopathy of bicuspid aortic valve disease has distinctive patterns and usually involves the transverse aortic arch. *J Thorac Cardiovasc Surg* 2008;135(4):901–907.
- [16] Kirali K, Guler M, Daglar B, Yakut N, Mansuroglu D, Balkanay M, Berki T, Gürbüz A, Isik O, Yakut C. Surgical repair in ruptured congenital sinus of Valsalva aneurysms: A 13-year experience. *J Heart Valve Dis* 1999;8(4):424–429.
- [17] Kirali K, Yakut N, Güler M, Mansuroğlu D, Ömeroğlu S, Akıncı E, Gürbüz A, Yakut C. Surgical treatment of siblings with Marfan syndrome. *Asian Cardiovasc Thorac Ann* 1999;7(2):138–141.
- [18] Erbel R, Aboyans V, Boileau C, Bossone E, Bartolomes RD, Eggebrecht H, Evangelista A, Falk V, Frank H, Gaemperli O, Grabenwöger M, Haverich A, Iung B, Manolis AJ, Meijboom F, Nienaber CA, Roffi M, Rousseau H, Sechtem U, Sirnes PA, von Allmen RS, Vrints CJM. 2014 ESC Guidelines on the diagnosis and treatment of aortic diseases. The

task force for the diagnosis and treatment of aortic diseases of the European Society of Cardiology (ESC). *Eur Heart J* 2014;35:2873–2926.

- [19] Garg V, Ouzounian M, Peterson MD. Advances in aortic disease management: A year in review. *Curr Opin cardiol* 2016;31(2):127–131.
- [20] Michielon G, Salvador L, Da Col U, Valfrè C. Modified button-Bentall operation for aortic root replacement: The miniskirt technique. *Ann Thorac Surg* 2001;72:S1059–1064.
- [21] Suzuki A, Amano J, Tanaka H, Sakamoto T, Sunamori M. Surgical consideration of aortitis involving the aortic root. *Circulation* 1989;80(3):I222–232.
- [22] Yakut C. A new modified Bentall procedure: The flanged technique. *Ann Thorac Surg* 2001;71(6):2050–2052.
- [23] De Paulis R, De Matteis GM, Nardi P, Scaffa R, Colella DF, Chiarello L. A new aortic Dacron conduit for surgical treatment of aortic root pathology. *Ital Heart J* 2000;1(7):457–463.
- [24] Kirali K. Technique of awake off-pump coronary artery bypass grafting. In: Raja SG, Amrani M, editors. *Off-pump Coronary Artery Bypass Grafting*. New York: Nova Science Publishers Inc; 2012, pp. 175–211.
- [25] Chakravarthy M, Jawali V, Patil TA, Jayaprakash K, Kolar S, Joseph G, Das JK, Maheswari U, Sudhakar N. Conscious cardiac surgery with cardiopulmonary bypass using thoracic epidural anesthesia without endotracheal general anesthesia. *J Cardiothorac Vasc Anesth* 2005;19(3):300–305.
- [26] Bottio T, Bisleri G, Piccoli P, Negri A, Manzato A, Muneretto C. Heart valve surgery in a very high-risk population: A preliminary experience in awake patients. *J Heart Valve Dis* 2007;16(2):187–194.
- [27] Porizka M, Stritesky M, Semrad M, Dobias M, Dohnalova A, Korinek J. Standard blood flow rates of cardiopulmonary bypass are adequate in awake on-pump cardiac surgery. *Eur J Cardiothorac Surg* 2011;39(4):442–450.
- [28] Kirali K, Kayalar N, Özen Y, Sareyyüpoğlu B, Güzelmeriç F, Koçak T, Yakut C. Reversed-J inferior versus full median sternotomy: Which is better for awake coronary bypass surgery. *J Card Surg* 2005;20(5):463–468.
- [29] Lentini S, Specchia L, Nicolardi S, Mangia F, Rasovic O, Di Eusanio G, Gregorini R. Surgery of the ascending aorta with or without combined procedures through an upper ministernotomy: Outcomes of a series of more than 100 patients. *Ann Thorac Cardiovasc Surg* 2006;22(1):44–48.
- [30] Ozer T, Akbulut M, Altas O, Mataraci I, Tuncer MA, Kirali MK. Partial upper sternotomy for concomitant with ascendant aorta replacement or isolated aortic valve implantation (abstract). *Aortic Symposium*, 2016, May 12–13. New York, NY, USA.
- [31] Russo MJ, Gnezda J, Merlo A, Johnson EM, Hashmi M, Raman J. The arrowhead ministernotomy with rigid sternal plate fixation: A minimally invasive approach for surgery of the ascending aorta and aortic root. *Minim Invasive Surg* 2014, 681371.

- [32] Özer T, Altaş Ö, Sarıkaya S, Özen Y, Yerlikhan EO, Günay D, Hançer H, Kırallı K. Double reverse incisions make aortic valve surgery lesser invasive (abstract). 12th International Congress of Update in Cardiology and Cardiovascular Surgery, 2016, March 10–13. Belek, Antalya, Turkey.
- [33] Tuncer A, Tuncer EY, Polat A, Mataracı İ, Keleş C, Alsalehi S, Boyacıoğlu K, Kara İ, Kırallı K. Axillary artery cannulation in ascending aortic pathologies. *Turkish J Thorac Cardiovasc Surg* 2011;19(4):539–544.
- [34] Kırallı K. Surgical strategy in aortic root aneurysms: Modified Bentall-aortic valve sparing surgery. *Türkiye Klinikleri J Cardiovasc Surg-Special Topics* 2012;4(1):7–17.
- [35] Copeland JG 3d, Rosado LJ, Snyder SL. New technique for improving hemostasis in aortic root replacement with composite graft. *Ann Thorac Surg* 1993;55(4):1027–1029.
- [36] Chen LW, Dai XF, Wu XJ. A modified composite valve Dacron graft for prevention of postoperative bleeding from the proximal anastomosis after Bentall procedure. *Ann Thorac Surg* 2009;88(5):1705–1707.
- [37] Kourliouros A, Soni M, Rasoli S, Grapsa J, Nihoyannopoulos P, O'Regan D, Athanasiou T. Evolution and current applications of the Cabrol procedure and its modifications. *Ann Thorac Surg* 2011;91(5):1636–1641.
- [38] Ziganshin BA, Williams FE, Tranquilli M, Elefteriades JA. Midterm experience with modified Cabrol procedure: Safe and durable for complex aortic root replacement. *J Thorac Cardiovasc Surg* 2014;147(4):1233–1239.
- [39] Kırallı K, Mansuroğlu D, Ömeroğlu SN, Erentuğ V, Mataracı I, İpek G, Akıncı E, Işık Ö, Yakut C. Five-year experience in aortic root replacement with the flanged composite graft. *Ann Thorac Surg* 2002;73(4):1130–1137.
- [40] Yıldırım T, Güler M, Kırallı K, Ömeroğlu SN, Eren E, Toker ME, Balkanay M, Dağlar B, Akıncı E, İpek G, Yakut C. Stentless bioprostheses in aortic root surgery: Mid-term results. *Türk Kardiyol Dern Ars* 2000;28(10):630–634.
- [41] Juthier F, Vincentelli A, Hysi I, Pinçon C, Rousse N, Banfi C, Prat A. Stentless porcine bioprosthesis in pulmonary position after Ross procedure: Midterm results. *Ann Thorac Surg* 2015;99(4):1255–1259.
- [42] Reece TB, Welke KF, O'Brien S, Grau-Sepulveda MV, Grover FL, Gammie JS. Rethinking the Ross procedure in adults. *Ann Thorac Surg* 2014;97(1):175–181.
- [43] Kırallı K, Sarıkaya S, Elibol A, Göçer S, Özer T, Altaş Ö, Ünal ÜS, Şişmanoğlu M. Aortic root replacement with the reimplantation procedure: Simplifying the sizing of tubular graft (abstract). 20th Annual Meeting for Asian Society for Cardiovascular and Thoracic Surgery, 2012, March 7-12. Bali, Indonesia.
- [44] de Kerchove L, Boodhwani M, Glineur D, Noirhomme P, El Khoury G. A new simple and objective method for graft sizing in valve-sparing root replacement using the reimplantation technique. *Ann Thorac Surg* 2011;92(2):749–751.

- [45] Kırali K, Altas O, Ozer T, Gunay D, Hancer H, Sarıkaya S, Ozen Y. David-V aortic valve sparing procedure: Mid-term results (abstract). Aortic Symposium 2016. 2016, May 12–13. New York, NY, USA.
- [46] Dağlar B, Kırali K, Yakut N, Tuncer A, Balkanay M, İpek G, Akıncı E, Yakut C. The surgical repair of congenital supra-ventricular aortic stenosis by single sinus aortoplasty technique: Mid-long term results. *Turkish J Thorac Cardiovasc Surg* 1999;7(3):223–228.
- [47] Katayama A, Uchida N, Sutoh M, Sueda T. Partial root remodeling on the two sinuses for acute type a aortic dissection with right coronary arterial dissection. *Ann Vasc Dis* 2013;6(3):666–669.
- [48] Yokoyama S, Nagato H, Yoshida Y, Nagasaka S, Kaneda K, Nishiwaki N. Novel three-sinus enlargement technique for supra-ventricular aortic stenosis without aortic transection. *J Cardiothorac Surg* 2016;11(4), doi: 10.1186/s13019-016-0403-5.
- [49] Kuriakose EM, Bhatla P, McElhinney DB. Comparison of reported outcomes with percutaneous versus surgical closure of ruptured sinus of Valsalva aneurysm. *Am J Cardiol* 2015;115(3):39392–39398.
- [50] Sarıkaya S, Adademir T, Elibol A, Büyükbayrak F, Onk A, Kırali K. Surgery for ruptured sinus of Valsalva aneurysm: 25-year experience with 55 patients. *Eur J Cardio-Thorac Surg* 2013;43(3):591–596.
- [51] Kırali K, Sarıkaya S, Ozen Y, Sacli H, Basaran E, Yerlikhan OA, Aydın E, Rabus MB. Surgery for aortic root abscess: 15-year experience. *Tex Heart Inst J* 2016;43(1):20–28.