

# We are IntechOpen, the world's leading publisher of Open Access books Built by scientists, for scientists

6,900

Open access books available

186,000

International authors and editors

200M

Downloads

Our authors are among the

154

Countries delivered to

TOP 1%

most cited scientists

12.2%

Contributors from top 500 universities



WEB OF SCIENCE™

Selection of our books indexed in the Book Citation Index  
in Web of Science™ Core Collection (BKCI)

Interested in publishing with us?  
Contact [book.department@intechopen.com](mailto:book.department@intechopen.com)

Numbers displayed above are based on latest data collected.  
For more information visit [www.intechopen.com](http://www.intechopen.com)



---

# Aspects of Immediate and Delayed Alloplastic Breast Reconstruction After Mastectomy

---

Michael Friedrich and Stefan Kraemer

Additional information is available at the end of the chapter

<http://dx.doi.org/10.5772/66876>

---

## Abstract

Seventy percent of patients with early breast cancer can be treated by breast-conserving surgery, while the remaining 30% are forced to receive mastectomy. Nearly 30% of these patients choose breast reconstruction. In the last decade, new alternative techniques and improved surgical devices have significantly improved techniques for breast reconstruction that especially include immediate or delayed breast reconstruction with silicone implants as an excellent option. In general, implant reconstruction may be single- or two-stage procedures. Single-stage reconstruction is the preferred technique for patients with small breasts and minimal ptosis, while large breasts with ptosis require reduction mastopexy either combined with dermoglandular flap or with titane net for covering the caudal pole of the implant. Thus, excellent cosmetic results can be achieved. Recent studies showed a significant survival benefit for postmastectomy irradiation in nodal-positive patients, so that many candidates for breast reconstruction are irradiated with a higher probability of wound-healing complications after breast reconstruction and increased rates of other complications like capsular fibrosis.

**Keywords:** immediate reconstruction, delayed reconstruction, mastectomy

---

## 1. Introduction

Breast cancer affects many women, but with advances in detection and treatment, survival rates have increased. The reconstruction of partial mastectomy defects during breast-conserving surgery and of the whole female breast after mastectomy is an integral part of the surgical treatment of breast cancer [1, 2]. If it is necessary for oncologic reasons and if there are contraindications for breast-conserving therapy, methods of breast reconstruction can contribute significantly to the restoration of physical integrity, including an improvement of life quality for the affected women. Besides an improvement or restoration of the physical image and of

the self-esteem, breast reconstruction leads to a processing of an oncologically necessary mastectomy from a psychooncological and rehabilitative point of view [3].

Thus, it is important to understand that there are many reconstructive options available to help ease the psychological burden of mastectomy. Reconstructive options include tissue expander/implants, biologics, and several autologous tissue options, including pedicled latissimus and Transverse Rectus Abdominis Muscle (TRAM) flaps, free TRAM flaps, and perforator flaps.

Breast reconstruction using prosthetic devices (alloplastic reconstruction) is the most commonly performed procedure in women following mastectomy [2]. The goal is to provide an outcome that is predictable and reproducible while minimizing complications and optimizing esthetics. There are various strategies by which this can be achieved. It begins with proper patient selection because most adverse events occur in high-risk patients. This in turn is related to the timing of the reconstruction that can be performed immediately following the mastectomy (primary) or on a delayed basis (secondary). The radiated patient poses additional challenges and limitations that must be understood to achieve a desired outcome.

## 2. Development of expander and implant technology

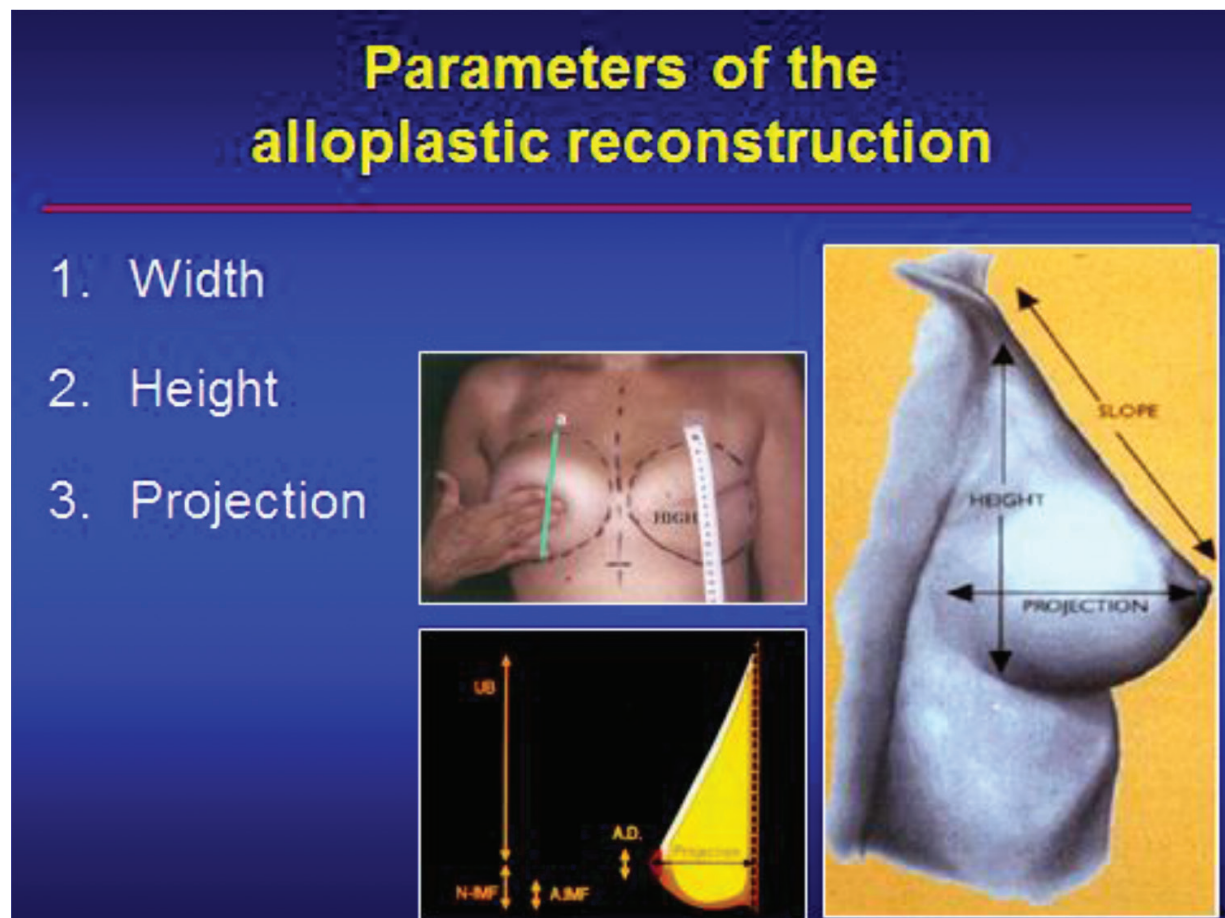
The era of modern breast reconstruction started in the early 1960s of the last century with the introduction of silicone-filled implants. Implants of the old generation have a round shape and a smooth surface. Smooth implants tend to have an increased rate of intense capsular contractions, dislocations, and therefore often a bad, asymmetric overall result with a frequent need of correcting surgery such as capsulotomy, capsulectomy, change of implant, explantation surgery, and autologous conversion. Furthermore, implants with a round shape are suitable only for a small breast up to 300 g without contralateral ptosis and little projection, a type of breast that is found *most often* in Asia [4, 5].

Implants of the new generation reflect the developments of implant technology *during* the last years and lead, provided that the medical indications are respected, to very good symmetric reconstructions with long-term stability of the results. By texturizing the surface of the implant, the rate of capsular contractions and the need for correcting surgery declined significantly.

It can actually not be finally judged whether surfacing the implant with polyurethane leads to the same long-term results. In conditions of thin soft tissue, combining *polyurethane* surfacing and surrounding tissue can cause surgical difficulties in case of a necessary change of implants, or it can be a contraindication for reimplanting [2, 6]. The filling of the implants with cohesive silicone gel in combination with an enforced coat of the implant *leads* to significantly higher safety of the implants. Because of their fluid consistency and instability of their form, implants with sodium chloride filling can only be recommended limitedly in regard of the esthetic overall result. The decisive progress in alloplastic breast reconstruction is based on the development and introduction of anatomically shaped implants. This shape of implants facilitates the reconstruction of a natural, symmetrical breast as it is found in Europe and America [2, 6, 7].

In the 1970s, Radovan introduced the expander technology in breast reconstruction [8]. Various progresses in design and technology of expanders lead to more consistent and better results in expansion and therefore made alloplastic breast reconstruction more predictable and safer [9]. Texturizing of the surface of the expanders simplifies the process of expansion and leads to less capsular contractures (especially in combination with textured implants), dislocation, and deformation of the chest wall. The introduction of anatomically shaped expanders enables the expansion of the lower breast pole, which is preferred in most cases, in order to prepare a *symmetric* reconstruction. By integrating a valve directly *into* the expander, the placement of a distant port for filling is unnecessary and increases the comfort for patients and doctors during the expansion phase.

According to our experience, the best results of alloplastic breast reconstruction are achieved by the use of anatomically shaped, textured implants filled with cohesive gel and, in the case of need of tissue expansion, in combination with anatomically shaped, textured expanders [2, 10] (Figure 1).



**Figure 1.** Parameters of alloplastic reconstruction. The preoperative marking of the subpectoral expander-implant loge is performed on the chest wall and can be supported by so-called templates. The lower line of the loge should not be more than 1 cm below the inframammary crease. The submuscular in the caudolateral area subcutaneous loge should have the same extent as the chosen expander and should correspond to the basis and height of the contralateral breast.

### 3. Basics of alloplastic breast reconstruction

In order to achieve optimal cosmetic results of alloplastic breast reconstruction, these anatomic conditions need to be respected [11, 12]:

1. Conservation of the inframammary crease
2. Integrity of the *pectoralis major muscle*
3. Quality and tautness of the skin

The conservation of the inframammary crease during mastectomy is safe from an oncologic point of view, as only very rarely is there breast parenchyma to be found distal to the inframammary crease. The inframammary crease is formed by fusion of the superficial and the mammary fascia. Its contour is defined by the distribution of fine fibrous retinacula, which connect the dermal as well as the musculofascial layers to a superficial fascia. The mammary fascia represents the natural cover of the mammary gland. The loss of this structural network at the time of mastectomy will lead to an inferior cosmetic result.

Small lesions of the *pectoralis major muscle* present no problem for an alloplastic breast reconstruction. However, larger dehiscences within the muscle should be provided with absorbable sutures. Alloplastic breast reconstruction is planned geometrically according to three parameters: width of the breast (basis of the breast), height of the breast, and projection. The width and the height are defined by the measurements of the contralateral breast. They are then plotted on the side of the chest wall that *has* to be reconstructed precisely to where the planned localization of the expander is.

The projection of the breast can to some extent be predicted by the dimensions of the expander. Depending on the final volume, a permanent *anatomically shaped* implant with corresponding width, height, and projection can be chosen [13].

### 4. Indications for alloplastic breast reconstruction

Because of a higher overall complication rate in primary expander-implant reconstruction, secondary expander-implant reconstruction should be preferred if alloplastic reconstruction is indicated. For reconstruction of a smaller, non-ptotic breast after mastectomy without radiation of the chest wall, secondary expander-implant reconstruction is suitable to achieve a good cosmetic result, provided that a *subtle* planning and surgical technique are considered [14–16].

Secondary, combined expander-implant reconstruction is the most commonly used method of reconstruction of the female breast after mastectomy in these days. If performed with the most modern expander and implant technologies, this method has various advantages [17]:

1. It is a relatively simple and safe surgical technique, which is easy to be taught, understood, and standardized and thus also suitable for less highly specialized centers.
2. The only tissue of identical texture, color, and sensitivity is used for breast reconstruction.



3. As compared to *autologous* reconstruction with distant *tissue* flaps, there is no morbidity in the area of flap *mobilization and tissue harvest*.
4. Only a small incision with consequently little scarring is necessary.
5. The operation time is significantly reduced as compared to *autologous* reconstruction. The time of postoperative reconvalescence is short.

Generally speaking, a small, not ptotic contralateral breast is suitable for alloplastic breast reconstruction after mastectomy. Patients need to be informed that, in order to adjust symmetry or shape, mastopexy or reduction *mammoplasty* might be necessary. The risk of a secondary, adapting reduction *mammoplasty* increases with size and ptosis of the contralateral breast [2, 9, 16].

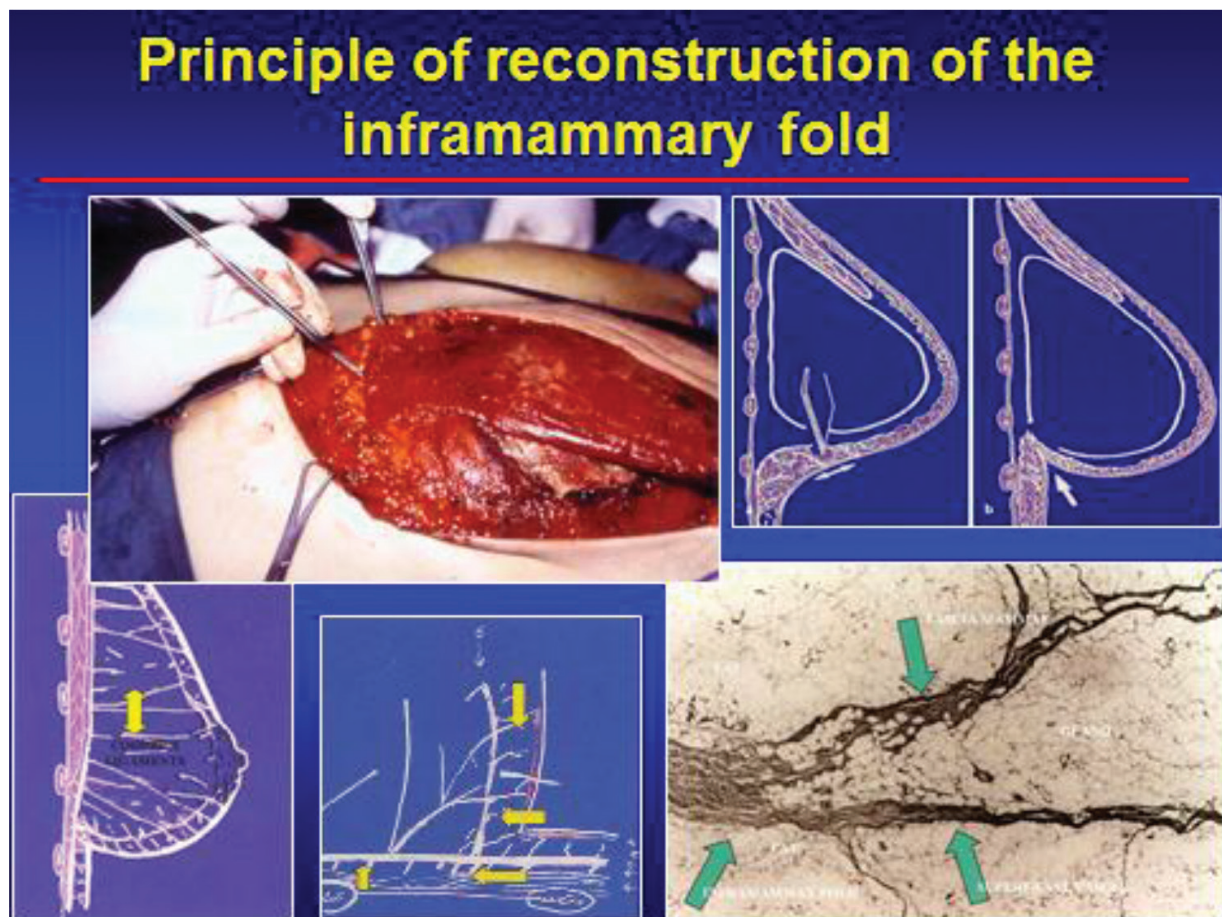
*Macromastia* and extreme ptosis of the contralateral breast are relative contraindications for a reconstruction with expander implant. The most important relative contraindication, however, is radiotherapy of the chest wall [18–21]. Since the indication for radiation of the chest wall has been extended in the last years and primarily depends on histopathologic parameters (tumor size, lymphangiosis, lymph node metastases), the indication for primary reconstruction with implant or expander implant has to be very restricted and well considered. After radiation therapy, fibrosis and interactions with the blood circulation of the skin increase the rate of complications in alloplastic reconstructions such as capsular contractures, necrosis of the skin, or deficient esthetic results. The eschewal of expander reconstruction is very often possible in skin-sparing mastectomy (SSM). Especially in cases of extended ductal carcinoma in situ, SSM is an increasingly common surgical alternative to modified radical mastectomy [22].

It is very important to inform patients about general methods of breast reconstruction. It is necessary to inform about advantages and disadvantages of alloplastic reconstruction as compared to autologous reconstruction including microsurgical *perforator flaps* (e.g., *deep inferior epigastric perforator*, *DIEP flaps*). When indicating alloplastic reconstruction, the wish of the patient to be intensely informed needs to be respected. Former surgery, age and comorbidity of the patients, previous or postoperative radiation therapy, size of the breast, shape of the breast, symmetry, the personal experience of the surgeon, and, last but not least, the wish of the patients are essential parameters when choosing the optimal method of breast reconstruction [2, 23].

## 5. Surgical procedure of alloplastic breast reconstruction

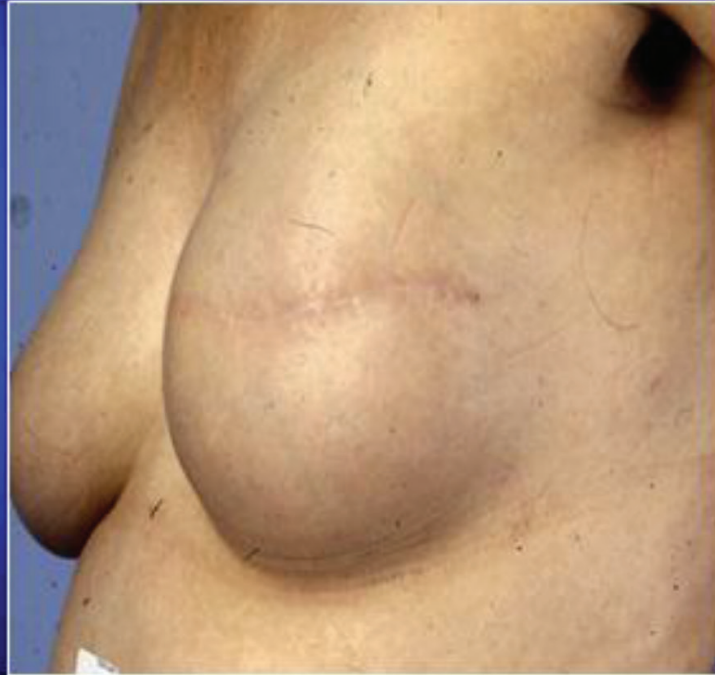When planning the surgical procedure, the incision line and the amount of skin that needs to be removed have to be considered from an oncological as well as a plastic-reconstructive point of view, already at the time of mastectomy. The dimension of the contralateral breast, especially the basis of the breast, defines the size of the expander. The preoperative marking of the subpectoral expander-implant loge is performed on the chest wall and can be supported by so-called templates. The lower line of the loge

should not be more than 1 cm below the inframammary crease. The submuscular in the caudolateral area subcutaneous loge should have the same extent as the chosen expander and should correspond to the basis and height of the contralateral breast. During the preparation of the submuscular loge, a consistent dissection is performed visually in cranial, caudal, and medial direction. The caudal and medial insertions of the *pectoralis major muscle* are cut through visually, coming from the subpectoral direction (**Figure 2**). The expander loge in the caudolateral area of the chest wall lies subcutaneously. This is especially important for secondary expander-implant reconstruction. When implanted in the loge, the expander is filled to 50% with a sodium chloride solution. Afterwards, the wound is closed layer by layer. The closing of the major pectoral muscle is especially important in order to achieve a sufficient coverage of the expander with soft tissue (**Figure 3**).



**Figure 2.** Principle of reconstruction of the inframammary fold. During the preparation of the submuscular loge, a consistent dissection is performed visually in cranial, caudal, and medial direction. The caudal and medial insertions of the *pectoralis major muscle* are cut through visually, coming from the subpectoral direction. The expander loge in the caudolateral area of the chest wall lies subcutaneously. This is especially important for secondary expander-implant reconstruction. When implanted in the loge, the expander is filled to 50% with a sodium chloride solution. Afterward, the wound is closed layer by layer. The closing of the major pectoral muscle is especially important in order to achieve a sufficient coverage of the expander with soft tissue.

## Sekundary Two-Stage Reconstruction



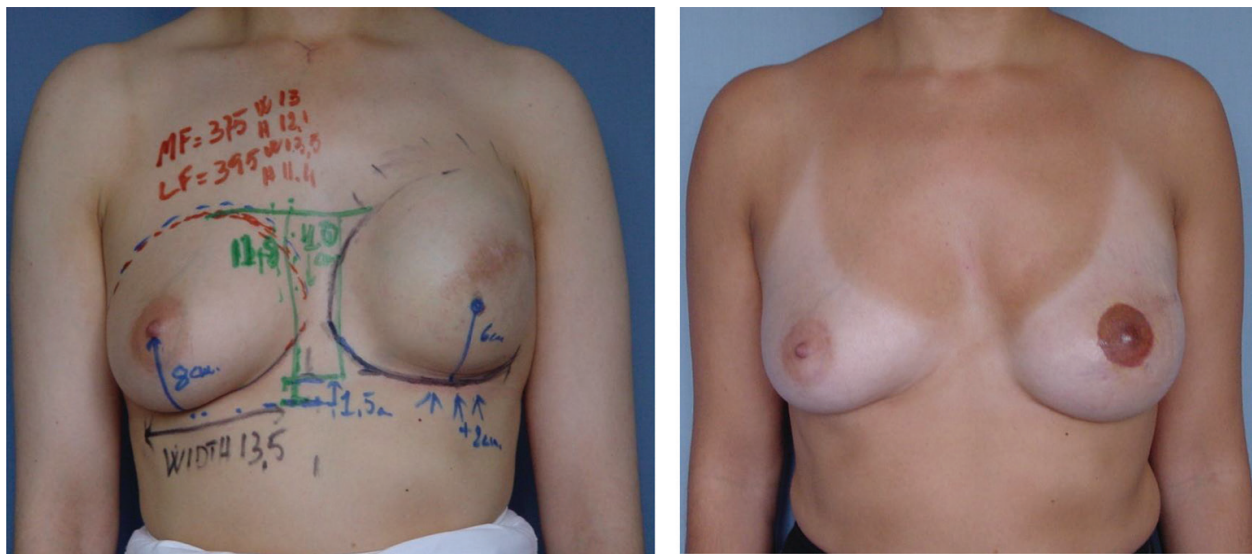
**Figure 3.** Postoperative result of secondary two-stage reconstruction. This figure demonstrates the postoperative result of a secondary two-stage reconstruction with a very nice shape of the reconstructed breast.

The further expansion starts 1 week after implantation in intervals of 3 days, in steps of 50–100 ml. Rapid expansion is necessary to avoid early development of a *fibrous capsule*.

The filling volume should be at least 70–80% of the possible expander volume. After another 3–6 months, the expander can be replaced by a suitably planned and chosen implant. The form and size of the chosen implant determine the quality of the result of the reconstruction. The implant loge can be optimized by targeted capsulotomy. If the inframammary crease is too high, it can be lowered by caudal capsulotomy. If the inframammary crease is too low, it can be reshaped and relocated by caudal capsulotomy, ellipsoid capsulectomy, and adaptation of the anterior to the posterior capsula with non-resorbable sutures [24, 25]. After insertion of a drain, the final anatomic implant is put in and the wound is closed in multiple layers. The positioning of the implant over the first two postoperative weeks is ensured by a special tape bandage.

An example for the surgical planning of secondary expander-implant reconstruction and the cosmetic result after nipple-areola reconstruction is demonstrated (**Figure 4**).





**Figure 4.** Secondary expander-implant reconstruction: surgical planning with markings and cosmetic result after nipple-areola reconstruction. The drawings show the measurements for the width, the height, and the projection and the markings of the inframammary fold.

## 6. Complications

The incidence of local complications is lower in primary implant and secondary expander-implant reconstruction than in autologous secondary reconstructions if the medical indications are respected [26, 27]. Early complications include hematoma, necrosis of the skin, infections, and pain. Adjuvant treatments including chemotherapy and radiation therapy can cause delayed wound healing. Delayed complications are infection, implant extrusion, and capsular contracture. Generally speaking, complications are more common after immediate reconstruction than after secondary reconstruction. This can be explained by the application of adjuvant therapies at the time of immediate reconstruction. Chemotherapy affects the immune system and therefore influences processes of regeneration and wound healing. Radiation therapy deteriorates the capacity of skin stretching and leads to excessive fibrosis. Furthermore, it reduces oxygenation of the tissue, which leads to excessive capsular reactions. Persistent infections often lead to removal of the implants. In this case, further reconstructive procedures can only be performed after the final healing of the infections [28].

## 7. Conclusions

Alloplastic methods of breast reconstruction are the most common methods of reconstructing the female breast after mastectomy. In order to obtain optimal results *for* reconstruction, the use of textured, anatomically shaped expander-implant systems is recommended. If adjuvant therapy is necessary, especially in the case of radiation therapy, an implant or expander-implant reconstruction is relatively contraindicated because of an insufficiently high rate of complication.

The patients need to be informed about the necessity of adapting mastopexy or reduction *mammoplasty* of the contralateral breast and about possible autologous methods for reconstruction. In our opinion, adjuvant postmastectomy radiation therapy is *the most important relative* contraindication for alloplastic reconstruction because of an unacceptable complication rate, especially if compared to *secondary* autologous reconstruction.

## Author details

Michael Friedrich<sup>1\*</sup> and Stefan Kraemer<sup>1,2</sup>

\*Address all correspondence to: [friedrichmichael@hotmail.com](mailto:friedrichmichael@hotmail.com)

1 Department of Obstetrics and Gynecology, HELIOS Medical Center, Krefeld, Germany

2 Department of Obstetrics and Gynecology, Breast Center, University Medical Center, Cologne, Germany

## References

- [1] Krämer S., Darsow M., Kümmel S., Kimmig R., Rezai M.: "Breast conserving treatment of breast cancer – oncological and reconstructive aspects". *Gynakol. Geburtshilfliche Rundsch.*, 2008, 48, 56.
- [2] Rezai M., Darsow M., Kümmel S., Krämer S.: "Autologous and alloplastic breast reconstruction – overview of techniques, indications and results". *Gynakol. Geburtshilfliche Rundsch.*, 2008, 48, 68.
- [3] Franchelli S., Leone M.S., Berrino P., Passarelli B., Capelli M., Baracco G., et al.: "Psychological evaluation of patients undergoing breast reconstruction using two different methods: autologous tissues versus prostheses". *Plast. Reconstr. Surg.*, 1995, 95, 1213.
- [4] Gabriel S.E., O'Faflon W.M., Kurland L.T., Beard C.M., Woods J.E., Melton L.J. 3rd.: "Risk of connective tissue diseases and other disorders after breast implantation". *N. Engl. J. Med.*, 1994, 330, 1697.
- [5] Jarrett J.R., Cutler R.G., Teal D.F.: "Subcutaneous mastectomy in small, large, or ptotic breasts with immediate submuscular placement of implants". *Plast. Reconstr. Surg.*, 1978, 62, 702.
- [6] Barone F.E., Perry L., Keller T., Maxwell G.P.: "The biomechanical and histopathologic effects of surface texturing with silicone and polyurethane in tissue implantation and expansion". *Plast. Reconstr. Surg.*, 1992, 90, 77.
- [7] Hakelius L., Ohlsen L.: "A clinical comparison of the tendency to capsular contracture between smooth and textured gel-filled silicone mammary implants". *Plast. Reconstr. Surg.*, 1992, 90, 247.

- [8] Radovan C.: "Breast reconstruction after mastectomy using the temporary expander". *Plast. Reconstr. Surg.*, 1982, 70, 153.
- [9] Becker H.: "Breast augmentation using the expander mammary prosthesis". *Plast. Reconstr. Surg.*, 1987, 79, 192.
- [10] Maxwell G.P., Falcone P.A.: "Eighty-four consecutive breast reconstruction using a textured silicone tissue expander". *Plast. Reconstr. Surg.*, 1992, 89, 1022.
- [11] Maillard G.F., Garey L.J.: "An improved technique for immediate retropectoral reconstruction after subcutaneous mastectomy". *Plast. Reconstr. Surg.*, 1987, 80, 396.
- [12] van Straalen W.H., Hage J.J., Bloemena E.: "The inframammary ligament: myth or reality?" *Ann. Plast. Surg.*, 1995, 35, 237.
- [13] Georgiade G.S., Riefkohl R., Cox E., McCarty K.S., Seigler H.F., Georgiade N.G., et al.: "Long-term clinical outcome of immediate reconstruction after mastectomy". *Plast. Reconstr. Surg.*, 1985, 76, 415.
- [14] Beasley M.E.: "Eighty-four consecutive breast reconstructions using a textured silicone tissue expander". *Plast. Reconstr. Surg.*, 1992, 89, 1035.
- [15] Pollock M.: "Capsular contracture: a retrospective study of the effects of textured silicone implants". *Plast. Surg. Forum*, 1991, 14, 250.
- [16] Spear S.L., Spittler C.J. "Breast reconstruction with implants and expanders". *Plast. Reconstr. Surg.*, 2001, 107, 177.
- [17] Beasley M.E.: "Two stage expander/implant reconstruction: delayed reconstruction". In: Spear S.L. (ed) *Surgery of the breast: Principles and art*. 1st edn. 1998, Lippincott-Raven, Philadelphia
- [18] Chawla A.K., Kachnic L.A., Taghian A.G., Niemierko A., Zapton D.T., Powell S.N.: "Radiotherapy and breast reconstruction: complications and cosmesis with TRAM versus tissue expander/implant". *Int. J. Radiat. Oncol. Biol. Phys.*, 2002, 54, 520.
- [19] Rosato R.M., Dowden R.V.: "Radiating as a cause of capsular contracture". *Ann. Plast. Surg.*, 1994, 32, 342.
- [20] Schuster R.H., Kuske R.R., Young V.L., Fineberg B.: "Breast reconstruction in women treated with radiation therapy for breast cancer: cosmesis, complications, and tumor control". *Plast. Reconstr. Surg.*, 1992, 90, 445.
- [21] Victor S.J., Brown D.M., Horwith E.M., Martinez A.A., Kini V.R., Pettinga J.E., et al.: "Treatment outcome with radiation therapy after breast augmentation or reconstruction in patients with primary breast carcinoma." *Cancer*, 1998, 82, 1303.
- [22] Kroll S.S., Ames F., Singletary S.E., Schustermann M.A.: "The oncologic risks of skin preservation at mastectomy when combined with immediate reconstruction of the breast". *Surg. Gynecol. Obstet.*, 1991, 172, 1.

- [23] Audretsch W., Rezai M., Kolotas C., Zamboglou N., Schnabel T., Bojar H.: "Tumor-specific immediate reconstruction (TSIR) in breast cancer patients". *Perspect. Plast. Surg.*, 1998, 11, 71.
- [24] Dowden R.V.: "Achieving a natural inframammary fold and ptotic effect in the reconstructed breast". *Ann. Plast. Surg.*, 1987, 19, 524.
- [25] Handel N., Jensen J.A.: "An improved technique for creation of the inframammary fold in silicone implant breast reconstruction". *Plast. Reconstr. Surg.*, 1992, 89, 558.
- [26] Evans G.R., Schustermann M.A., Kroll S.S., Miller M.J., Reece G.P., Robb G.L., et al.: "Reconstruction and the radiated breast: is there a role for implants?" *Plast. Reconstr. Surg.*, 1995, 96, 1111.
- [27] Kroll S.S., Schustermann M.A., Reece G.P., Miller M.J., Smith B.: "Breast reconstruction with myocutaneous flaps in previously irradiated patients". *Plast. Reconstr. Surg.*, 1994, 93, 460.
- [28] Spear S.L., Maxwell G.P.: "Invited discussion of reconstruction and the radiated breast: is there a role for implants?" *Plast. Reconstr. Surg.*, 1995, 96, 1116.



