

We are IntechOpen, the world's leading publisher of Open Access books Built by scientists, for scientists

6,900

Open access books available

186,000

International authors and editors

200M

Downloads

Our authors are among the

154

Countries delivered to

TOP 1%

most cited scientists

12.2%

Contributors from top 500 universities



WEB OF SCIENCE™

Selection of our books indexed in the Book Citation Index
in Web of Science™ Core Collection (BKCI)

Interested in publishing with us?
Contact book.department@intechopen.com

Numbers displayed above are based on latest data collected.
For more information visit www.intechopen.com



Follicular Unit Extraction (FUE) Hair Transplantation

Safvet Ors

Additional information is available at the end of the chapter

<http://dx.doi.org/10.5772/66837>

Abstract

Throughout the world, over 60% of men and 50% of women suffer from androgenetic alopecia and irreversible hair loss. This type of hair loss is a seminatural process, and medication can only temporarily inhibit it. At the moment, the solution for either androgenetic alopecia or other irreversible hair loss problems is the hair transplantation. Besides androgenetic alopecia, the many irreversible hair losses are being applied successfully by hair transplantation. In the past 10–15 years, a new hair restoration technique was introduced. This method is called follicular unit extraction (FUE) technique. FUE is an alternative which allows for quick extraction of follicular unit grafts. The hair transplantation can be used in various problems such as alopecia areata, congenital alopecia, burn sequelae, eyelash-eyebrow loss, beard loss, and mustache loss. In addition, it can camouflage the scars. The main objective of hair transplantation is to restore hair loss. We may not be able to recreate the appearance that the patients had in their early twenties; however, realistic expectations can be met with the help of technology. Based on our experience, FUE is the method that gives us the opportunity to best meet all patients' hair transplantation expectations.

Keywords: hair loss, baldness, hair transplantation, hair loss treatment, fue, fut, alopecia

1. Introduction

In recent years, hair loss has progressively increased because of the use of various chemical agents, environmental conditions, drugs, and inorganic foods [1, 2]. Androgenetic alopecia affects nearly half of the women and men around the world [3–5]. Hair loss at an early age can be quite traumatic, particularly among young men and women. Baldness can be also problematic in advanced ages, even over 50 years of age. Although there are many causes of hair loss, the most common is androgenetic alopecia. Patients and physicians primarily prefer medical treatment. However, medical treatment reveals successful results in a limited number

of patients. In many cases of hair loss, particularly in androgenetic alopecia, hair transplantation may be the single method to solve this problem. Hair transplantation is also successfully applied for the treatment of many types of hair losses other than the androgenetic alopecia. The hair transplant can be used in cases such as various cicatricial alopecias, alopecia areata, congenital alopecias, postburn sequelae and to camouflage various skin marks [6, 7]. Both inherent and acquired losses of the beard, mustache, and eyebrow can also be successfully treated with hair transplantation [6, 7]. As hair loss has progressively become a great problem in all populations, patients truly desire to regain their hair and therefore, they may be abused by individuals who are not physicians and who use paramedical methods, particularly topical and herbal treatments.

2. Hair transplantation

Hair transplantation has been applied for many years, and it has gained great progress within the past decade. The duration of operation has shortened, and the number of grafts transferred in one session has substantially increased. Consequently, it is currently possible to obtain excellent outcomes by transferring tremendous amounts of grafts in one session (Figures 1–5).

2.1. FUT (follicular unit transfer)

Nearly a decade ago, skin patches were obtained from the occipital region, manually separating it to grafts and then transferring them to the recipient area. This method is called follicular unit transfer (FUT), although it is not the most proper definition. In this method, a linear scar remained at the occipital region (Figure 6a), healing duration was prolonged, and the patients felt pain, particularly while lying on the side of the donor area [8, 9]. Moreover, with the FUT method, approximately 1000–1500 graft transplantations were able to be done at one session, which is insufficient for satisfactory outcomes in most patients. The main disadvantages of the FUT method were eliminated with the wide application of the follicular unit extraction (FUE) method within the past one decade [10].

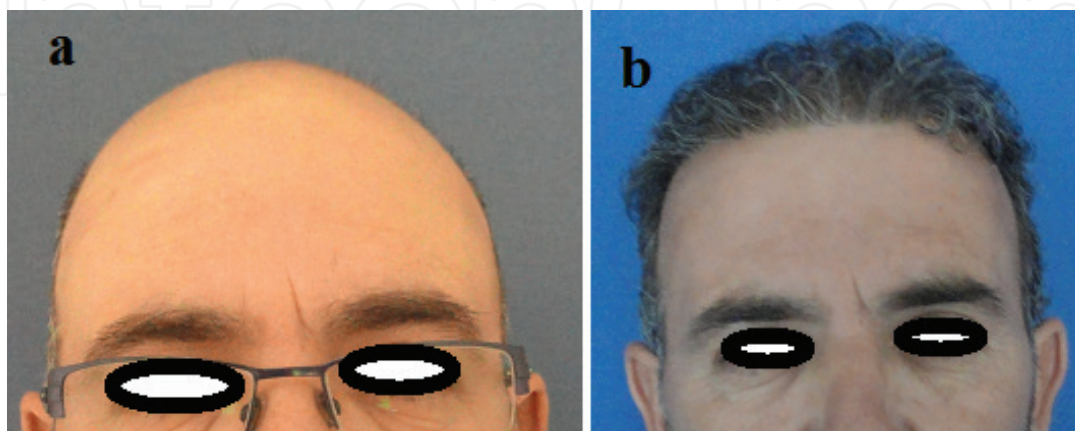


Figure 1. (a) Preoperative photos of androgenetic alopecia, (b) Postoperative photos.

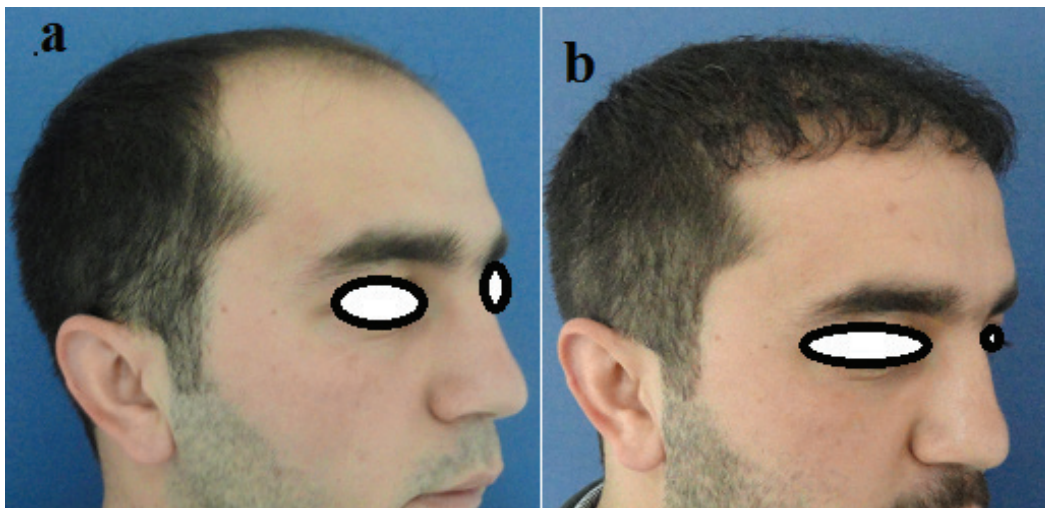


Figure 2. (a) Preoperative photos of androgenetic alopecia, (b) Postoperative photos.

2.2. Follicular unit extraction (FUE)

With the current frequent use of the FUE method, almost none of the patients receive the FUT method for hair transplantation. In particular, the use of a micromotor (**Figure 7**) for graft extraction within the past 5–6 years has made a breakthrough in hair transplantation [8, 9]. Before micromotor use, the grafts were only extracted by manual punches. Approximately 2000 grafts could be extracted in 3–4 h with the manual method, and the extraction of grafts greater than this number was difficult to achieve for the operators. With the wide application of the micromotor method, the number of transplanted grafts in 1 h has increased up to 5000–6000 [6]. The micromotor method has made the application of hair transplantation quite easy for the operators [6]. The ideal age is 30–35 years for hair transplantation. Nevertheless, in patients with hair loss at younger ages, hair concentrating transplantation procedures can be applied before the development of complete baldness. We consider that waiting for total hair loss is not absolutely essential, since individuals do not desire several radical changes to their image. In young men, frontal hair transplantation, particularly in the range of 20–25 years of age, is quite important for the patient's psychology. If the remaining hair is lost in

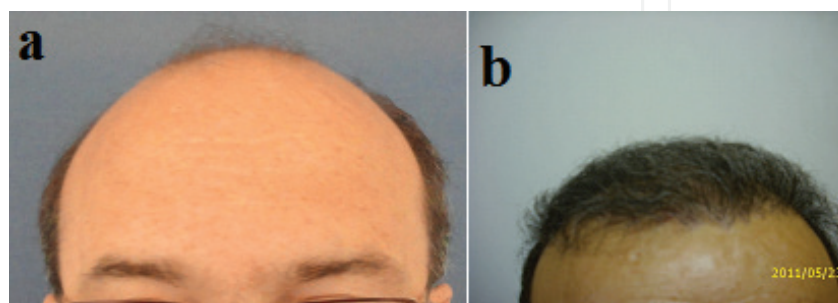


Figure 3. (a) Preoperative photos of androgenetic alopecia, (b) Postoperative photos.

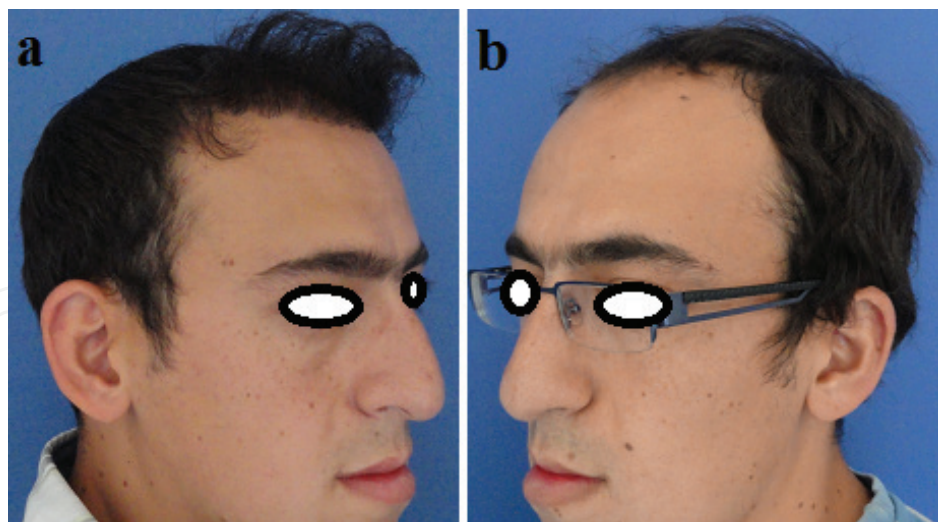


Figure 4. (a), Preoperative photos of androgenetic alopecia. (b), Postoperative photos.

the following years, transplantations can be applied in second and third sessions. It is not essential to wait for the advanced ages under these circumstances. It would also be useful to mention the surgical technique.

2.3. Surgical technique

Except for some unusual situations, the hair transplantation is applied under local anesthesia. It can also be performed under general anesthesia in children and in patients not accepting local anesthesia. Since the duration of the transplantation procedure is long, the patient must rest prior to the operation, must not drink alcoholic beverages several days prior to the procedure, must quit smoking if possible, and must not fast the morning before the operation, which are all important points. The hemoglobin analysis, and PT, PTT, INR, and ELISA tests, and other biochemical tests must absolutely be conducted preoperatively. In particular, local anesthetics may lead to hypotension and syncope in fasting state [11]. Lidocaine including adrenaline is used as a local anesthetic. A special care must be taken in the application of large numbers of graft transplantations with wide donor and recipient areas, since toxic doses of lidocaine can be reached in these situations. The dose must not exceed 5 mg/kg in the

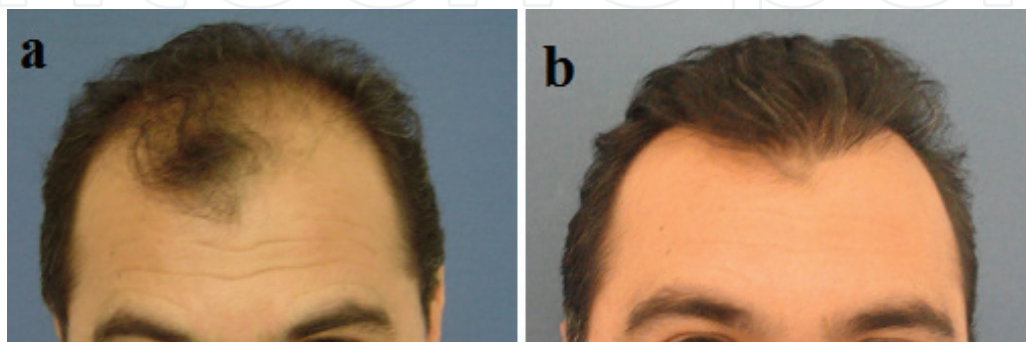


Figure 5. (a) Preoperative photos of androgenetic alopecia, (b) Postoperative photos.

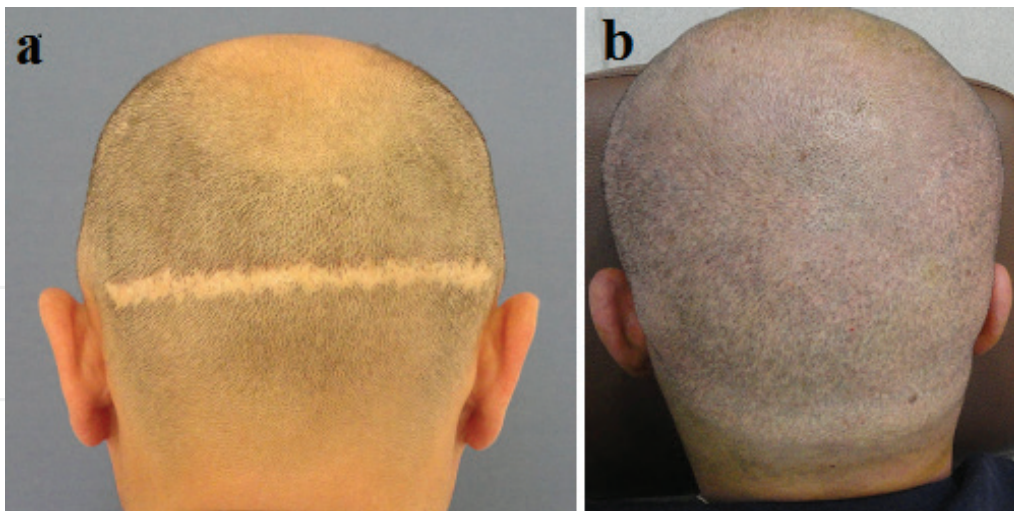


Figure 6. (a) After FUT hair transplant donor area seen, (b) After FUE hair transplant donor area seen.



Figure 7. Micromotor for hair transplant.

administration of preparations including adrenaline. The most serious side effect of lidocaine is confusion due to central nervous system toxicity [11–13]. Moreover, hypotension, nausea, vomiting, dizziness, and tinnitus are among the common side effects. The risk of toxicity would be decreased, if the grafts are extracted by initially anesthetizing the donor area, and when the graft extraction is completed, by administering local anesthetic to the recipient area after waiting for a certain time period. If the signs of toxicity appear despite this application, the administration of a 100 cl feeding solution (a solution of 10% lipid + 20% glucose + 5.5% amino acids) by IV pouch, followed by the infusion of the same solution for a certain duration, would eliminate the signs of toxicity immediately. The risks of hypotension and syncope would be lower, if all administrations of local anesthetics are done on the supine position.

The grafts are extracted with punches measuring approximately 0.8–0.9 mm in width. The punches are 5–6 mm in length. These punches are disposable materials assembled at the tip of the micromotor. The velocity of the micromotor is 5000/min. The punches used must always be sharp, since the blunt punches damage the tissue. The number one haircut would make the application quite easy. The hairs at the donor area must be visible at a length of 1 mm on the scalp. The punches internalize the hair over the scalp in a proper slope with the angle of hair growth, cut respectively the skin, connective tissue, and aponeurosis, and stop when the distance to the follicle is 1 mm. They are inserted into the skin in a depth of about 3–3.5 mm, as

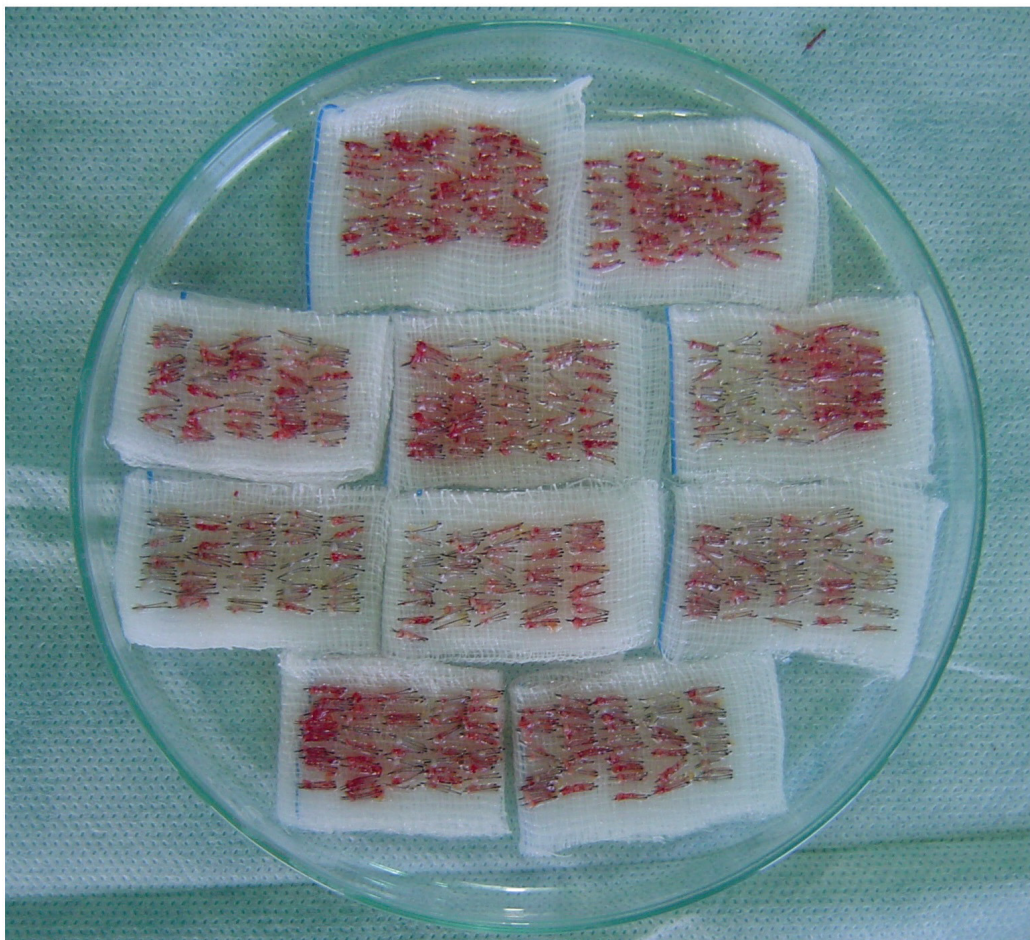


Figure 8. In FUE method, 500 hair graft ready for transplant.

deeper insertions may cause follicular damage. After the grafts are freed, they are collected by the aid of special collets. The collected grafts must be kept in isotonic saline solution (**Figure 8**).

The first extracted graft must initially be placed in the recipient area, and the last extracted graft must be transplanted at the final stage (**Figure 9**). Although it is reported that the grafts can be kept for longer times under suitable conditions, they should not be kept for longer than 4–5 h, if possible, as it would increase the possibility of their viabilities [6]. The depth of the follicles from the skin surface varies between 3.5 and 7 mm. The length of a graft is approximately 5 mm. Grafts shorter than 4 mm and those longer than 6 mm are both difficult to extract and to transplant [6]. The graft extraction is applied in prone position, while the transplantation has to be applied in a semi-seated position. This would lead to a lesser amount of bleeding, and the patient would also feel more comfortable.

Although it varies according to the patients and the number of hairs being transplanted, nearly 1–1.5 units of blood is lost during hair transplantation. Therefore, essential fluid support must be provided. Supratrochlear and supraorbital blocks must be done initially, after the patient is kept in the semi-seated position, and then, all the recipient area must be infiltrated with local anesthetic. Swelling the scalp slightly with a certain amount of physiological saline, after the local anesthetic infiltration, will decrease bleeding and would also make it easy to recognize the opened channels. For the procedure to open channels in the recipient area, razor blades of 1 mm in width and 5–6 mm in length are prepared by cutting. Opening a channel with a sharp razor blade is more advantageous compared to a scalpel blade No. 11. For a natural appearance, some degree of angulation must be formed, particularly when opening channels in the frontal and temporal regions. The grafts are placed at the recipient area one by one after channel opening. The epidermis must be kept outside during graft placement, in order to prevent a reaction. The graft should not be completely inserted into the channel. It takes 48 h for the grafts to be stabilized at the recipient area, by adhesion to the fibrin. Thus, the grafts may be removed from their places within the first 48 h, and therefore, they have to be protected carefully in this period. Since the hair transplantation is a composite tissue transfer, the duration of holding (penetration) is approximately days. After penetration, the grafts begin to grow soon, thereafter. The tissue growth usually takes place over 3–4 weeks; following the third week, the follicles remain within the skin, and the hair tips would be lost. Hair loss may

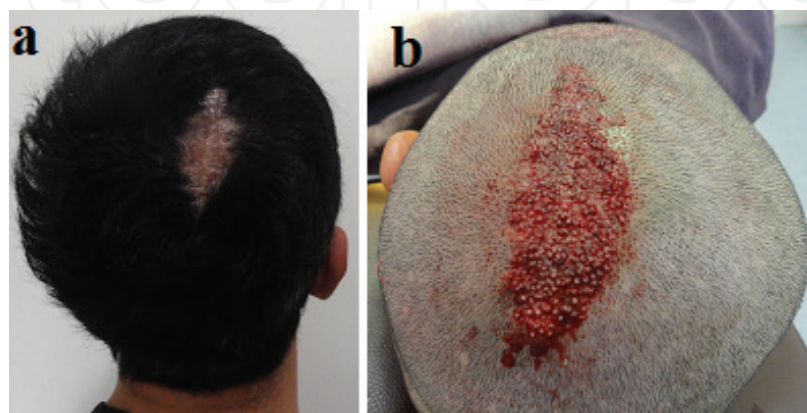


Figure 9. (a) photo of 14 years old boy Preoperative scarring alopecia, (b) intraoperative photo after transplant.

never occur in a very small number of patients. Even when there is no hair loss, 4–6 months are required for hair elongation. The transplanted hairs grow in approximately 6 months, and they gain volume within the following 1 year. The number of growing hairs in the frontal region is equal to the number of graft transplants, while only the 70% of transplanted hairs grow in the vertex. A great number of transplanted hairs do not grow sometimes, at a rate of one in 200 patients, and the cause is unknown. The grafts are very easily extracted in some patients, while this procedure is quite difficult in some cases. These patients are considered as not appropriate for the FUE method; nevertheless, a meticulous operation might reveal the extraction of a required number of grafts. What is the optimal number of graft transplants in one session? Our experiences reveal that the patients tolerate this operation well within the first 5–6 h; after 6 h, complaints frequently arise such as boredom, fatigue, dizziness, and nausea. Consequently, the hair transplantation procedure should be completed within 6 h, if possible. In other words, the number of graft transplants is based on the number that can be achieved in 6 h.

2.4. Hair transplantation in women

Androgenetic alopecia cases have been progressively increasing particularly in women [3]. Hormonal analyses usually reveal no pathological results. Hair transplantation within an area of 8–10 cm from the frontal hairline toward the vertex yields an excellent outcome in female patients with androgenetic alopecia (**Figure 10**). The main problem of hair transplantation in women is the obligatory “number one haircut.” Women can more easily camouflage it with the aid of accessories such as hair bands and toupees. The ratio of women to men is nearly 3/100 in hair transplantation [6].

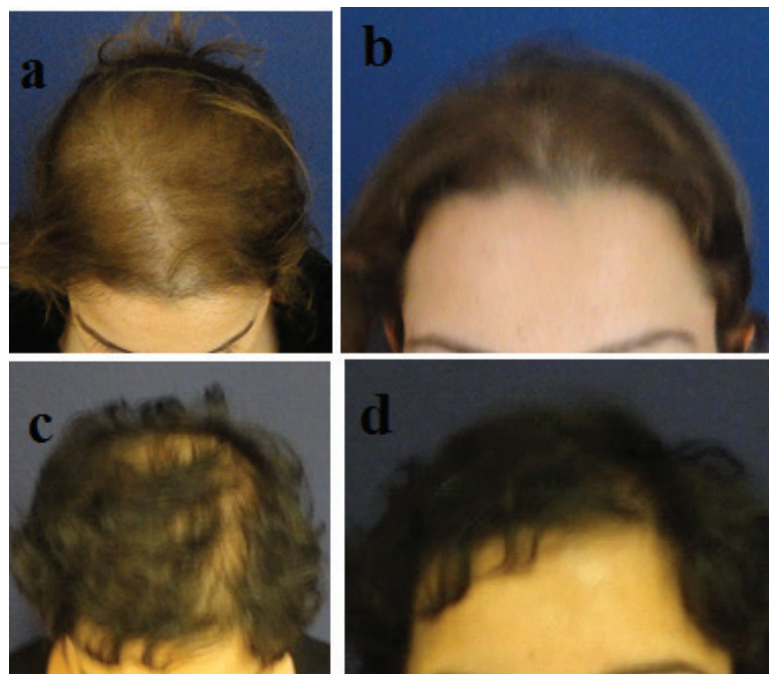


Figure 10. (a) frontal view; Preoperative photo of 35 years old woman has androgenetic alopecia, (b) top of head view Preoperative photo of 35 years old woman has androgenetic alopecia, (c) postoperative 1 year later, (d) postoperative 1 year later.

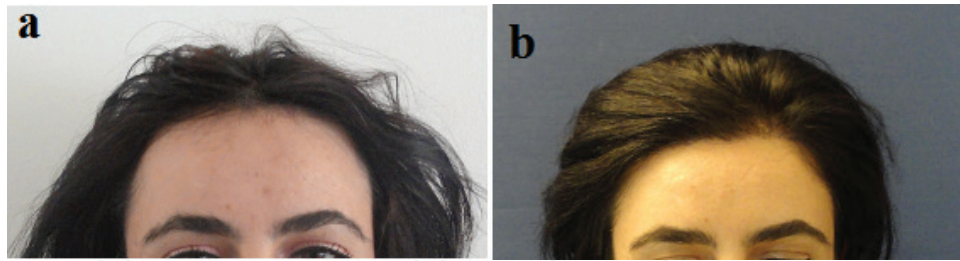


Figure 11. (a) Preoperative 30 years old women has large forehead, (b) 1 year later after hair transplant.

In women with genetically wide foreheads, the forehead can be narrowed with hair transplantation procedure. Deformities of the frontal bone and burn sequelae near the hairline can also be masked with hair transplantation (**Figure 12**). Since the women inherently have thinner hair, hair transplantation in women yields more natural outcomes than that in men [6].

2.5. Hair transplantation in adolescents

Hair loss due to alopecia areata and cicatricial alopecia is common at the ages of 14–15 years (**Figure 9**). Patchy areas of multiple alopecia exist as a result of burn sequelae, particularly in developing countries. The hair transplantation yields considerably successful results in these patients [6]. The subdermal soft tissue is quite insufficient in some of these patients. Despite this fact, the rate of graft penetration is substantially high. Expanders were previously used in these patients [14], while recently hair transplantation has become much more advantageous [6]. Although there is an insufficient number of studies about hair transplantation in children, this procedure can also be successfully applied in children, as in adults. The phases of hair transplantation, which are the penetration (holding) and hair growth, and their durations, are similar to those in adults [6]. Since the scalp is thin and the follicles are more superficial, hair transplantation in children requires a more meticulous operation.

2.6. Beard transplantation

Most patients admitted for beard transplantation often complain about a sparse beard. The burn sequelae rarely exist. Whatever the cause may be, the method in beard transplantation is similar to that of hair transplantation. The duration of beard growth is 6 months, as it is for hair. Due to the properties of subdermal soft tissue, the placement of grafts in beard transplantation is more difficult compared to that in hair transplantation (**Figures 15 and 16**).

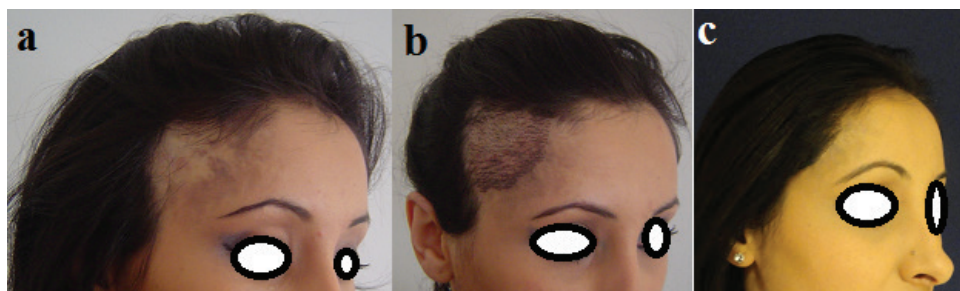


Figure 12. (a) 30 years old women; insufficient subcutaneous tissue due to burn Preoperative photos, (b) 2 years later hair transplant, (c) 2 years after hair transplantation.

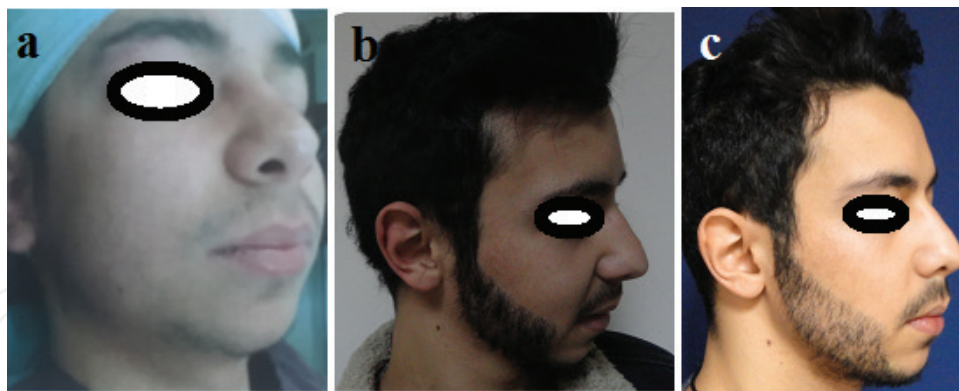


Figure 13. (a) Preoperative photo beard transplant, (b) Postoperative 1 year later, (c) postoperative 2 years later.

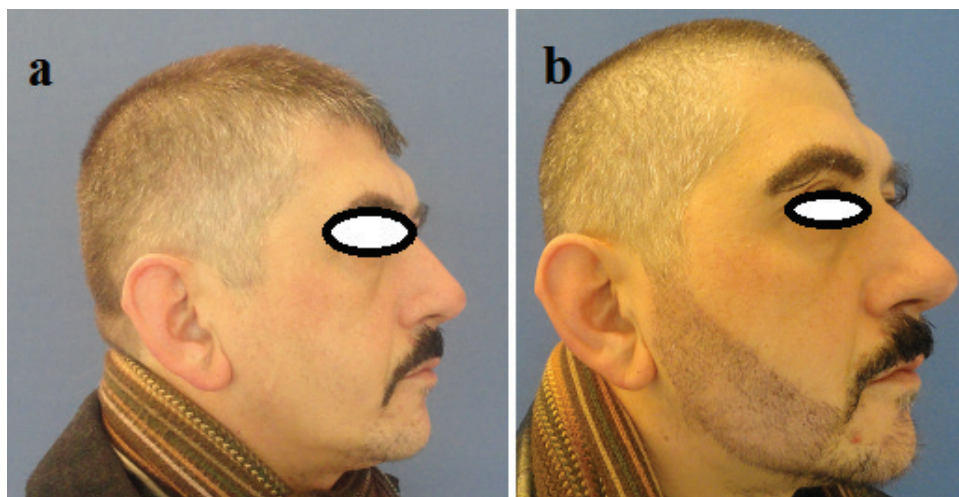


Figure 14. (a) Preoperative photo beard transplant, (b) 2 weeks later beard transplant.

2.7. Mustache transplantation

Mustache transplantation is sometimes applied in combination with beard transplantation, while it is also performed as an isolated mustache transplantation in some cases. Hair transplantation is also the almost single treatment of cicatricial alopecias characterized by burn-induced multiple patches (**Figure 17**). The general procedural principles are identical.

2.8. Eyebrow transplantation

Eyebrow transplantation was previously applied due to eyebrow losses resulting from burns and cicatricial tissue. Hair transplantation is also the almost single treatment of cicatricial alopecias characterized by burn-induced multiple patches (**Figures 18 and 19**), while it is mostly preferred today by women desiring more thick, wide, and bushy eyebrows. The outcomes of hair transplantation are more natural in women, while those of the eyebrow transplantation are more natural in men. Eyebrow intensifying transplants may require a second session in women. The problems in eyebrow transplantation are as follows: the rapidly growing eyebrows hairs, difficulty in producing a sufficient eyebrow slope, and rarely, a sparse eyebrow.

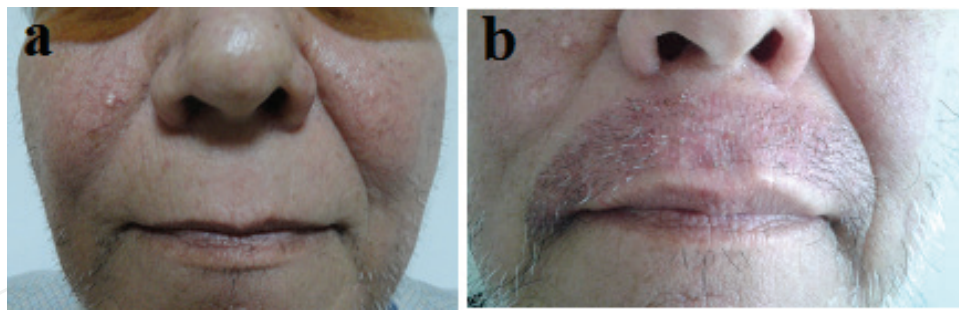


Figure 15. (a) 55 years old man Preoperative photo, (b) 10 days later after mustache transplant.

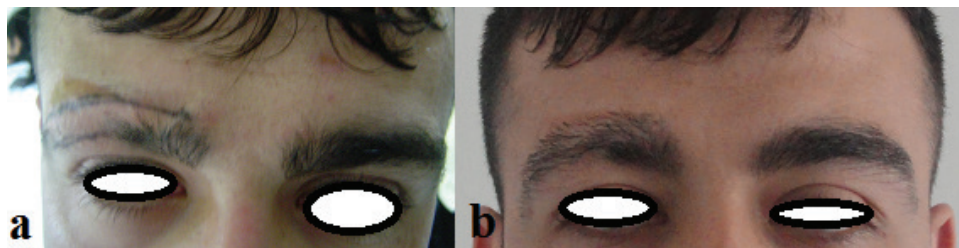

Figure 16. (a) Preoperative photo brow loss, (b) Postoperative photo brow transplant.

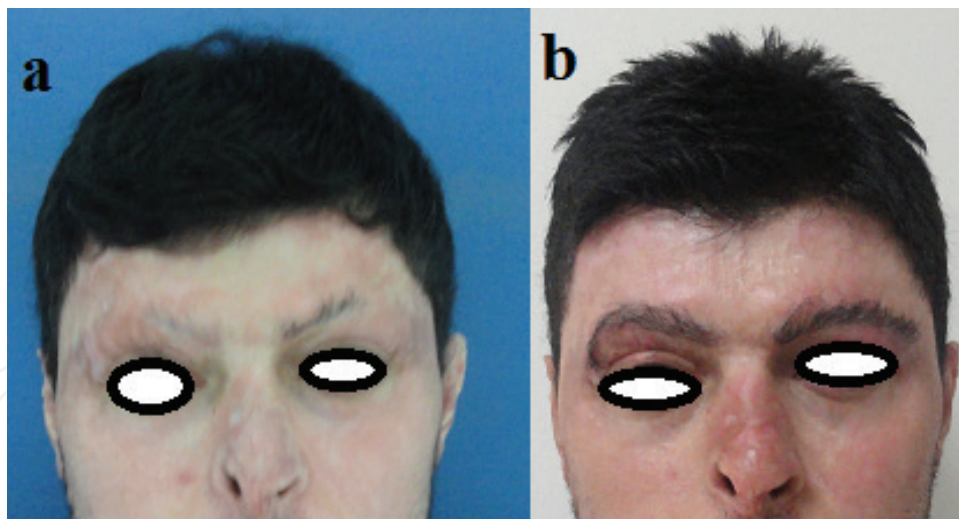


Figure 17. (a) Preoperative photo brow loss, (b) 2 years later brow transplant.

2.9. Cicatricial alopecias

Hair transplantation is also the almost single treatment of cicatricial alopecias characterized by burn-induced multiple patches (**Figures 9, 12, 13, and 14**). The hair transplant can be used in cases such as various cicatricial alopecias, alopecia areata, congenital alopecias, postburn sequelae, and in the camouflage of various skin marks [6, 7]. Hair transplantation is also the almost single treatment of cicatricial alopecias characterized by burn-induced multiple patches (**Figure 18**). Radiation-induced hair loss can be treated by hair transplantation (**Figure 19**).

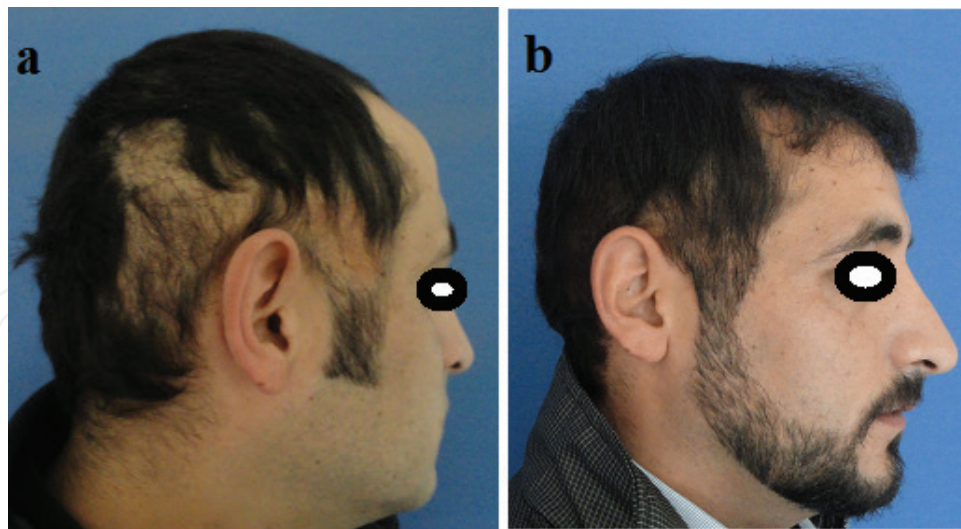

Figure 18. (a) Preoperative photo of burn scar patient, (b) 2 years later hair transplant.

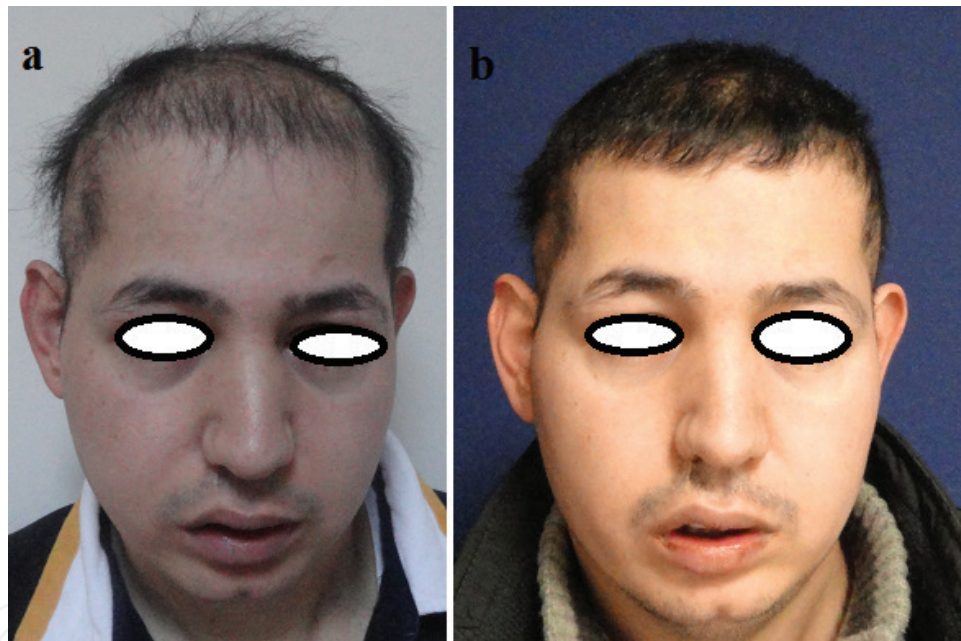


Figure 19. (a) Preoperative photo: 25 years old man, Radiation induced hair loss, (b) 1 year later hair transplant.

2.10. Unknown benefits of hair transplantation

Hair transplantation may be replaced with gene therapies and stem cell therapies in the future. However, the most effective method for treating irreversible hair losses is currently hair transplantation. Hair transplantation has many positive effects compared to the treatment of hair loss. Among these, one of the most important is the marked improvement of forehead wrinkles in the patients undergoing hair transplantation. The hair transplantation produces the effect of Botox on the forehead. Hair transplantation is also the almost single treatment of cicatricial alopecias characterized by burn-induced multiple patches (**Figure 13**). In the patients with migraines undergoing hair transplantation, the migraine attacks improve

markedly and the patients almost stop the use medications. Many unknown useful effects of hair transplantation will be discovered in the future. Better results can be obtained with the application of various supportive treatments, such as the mesotherapy following hair transplantation.

As a result, hair transplantation is perhaps the method that alters the image the most among all esthetic applications. Patients with baldness appear to be 10–15 years older than their real ages. Therefore, hair transplantation provides a type of psychotherapy by causing the patients to regain the images corresponding to their real ages. The positive attitudes of the patients after transplantation lead to an apparent optimism in their professional and private lives. In the patients without a sufficient donor area for hair transplantation, even hair transplantation in only the frontal region is sufficient to make them satisfied.

Acknowledgements

None of the authors has a financial interest in any of the products, devices, or drugs mentioned in this manuscript.

Author details

Safvet Ors

Address all correspondence to: saffetors@gmail.com

SO-EP Aesthetic and Plastic Surgery Clinic, Kayseri, Turkey

References

- [1] Gan DC, Sinclair RD: Prevalence of male and female pattern hair loss in Maryborough. *J Investig Dermatol Symp Proc* 2005;10:184–189.
- [2] Otberg N, Finner AM, Shapiro J: Androgenetic alopecia. *Endocrinol Metab Clin North Am* 2007;36:379–398.
- [3] Varothai S, Bergfeld WF: Androgenetic alopecia: an evidence-based treatment update. *Am J Clin Dermatol* 2014;15(3):217–230.
- [4] Bienova M, Kucerova R, Fiura skova M, Hajdu ch M, Kolar Z: Androgenetic alopecia and current methods of treatment. *Acta Dermatovenerol Alp Panonica Adriat* 2005;14(1):5–8
- [5] Baumann LS, Kelso EB: Selections from current literature: androgenetic alopecia: the science behind a new oral treatment. *Fam Pract* 1998;15(5):493–496
- [6] Ors S, Ozkose M, Ors S: Follicular unit extraction hair transplantation with micromotor: eight years experience. *Aesthetic Plast Surg* 2015;39(4):589–96.

- [7] Orentreich N: Autografts in alopecia and other selected dermatological conditions. *Ann N Y Acad Sci* 1959;83:463–479.
- [8] Bisaccia E, Scarborough D: Hair transplant by incisional strip harvesting. *J Dermatol Surg Oncol* 1994;20:443–448.
- [9] Bernstein RM, Rassman WR: Follicular transplantation: patient evaluation and surgical planning. *Dermatol Surg* 1997;23:771–784.
- [10] Rassman WR, Bernstein RM, McClellan R, Jones R, Worton E, Uyttendaele H: Follicular unit extraction: minimally invasive surgery for hair transplantation. *Dermatol Surg* 2002;28:720.
- [11] Dutton WA: Convulsions following pudendal block by lignocaine. *Lancet* 1955;269(6905):1368–9.
- [12] Deacock AR: The toxicity of lignocaine 2 percent. A case report. *Anaesthesia* 1961;16:363–5.
- [13] Wigand FT: Untoward reaction to lidocaine; report of case. *J Oral Surg (Chic)* 1958;16(4):334–6.
- [14] Guzey S, Alhan D, Şahin I, Aykan A, Eski M, Nişancı M: Our experiences on the reconstruction of lateral scalp burn alopecia with tissue expanders. *Burns* 2015;41(3):631–7.