

# We are IntechOpen, the world's leading publisher of Open Access books Built by scientists, for scientists

6,900

Open access books available

185,000

International authors and editors

200M

Downloads

Our authors are among the

154

Countries delivered to

TOP 1%

most cited scientists

12.2%

Contributors from top 500 universities



WEB OF SCIENCE™

Selection of our books indexed in the Book Citation Index  
in Web of Science™ Core Collection (BKCI)

Interested in publishing with us?  
Contact [book.department@intechopen.com](mailto:book.department@intechopen.com)

Numbers displayed above are based on latest data collected.  
For more information visit [www.intechopen.com](http://www.intechopen.com)



---

# Role of the Electrophysiologist in the Treatment of Tachycardia-Induced Cardiomyopathy

---

Cismaru Gabriel, Lucian Muresan, Puiu Mihai,  
Radu Rosu, Gabriel Gusetu, Dana Pop and  
Dumitru Zdrenghea

Additional information is available at the end of the chapter

<http://dx.doi.org/10.5772/66515>

---

## Abstract

Tachycardia-induced cardiomyopathy is a systolic cardiac dysfunction given by prolonged elevated heart rates in patients with incessant or frequent tachyarrhythmias. Arrhythmias associated with tachycardiomyopathy can be either supraventricular (atrial tachycardia, atrial flutter, atrial fibrillation, AVNRT, permanent junctional reciprocating tachycardia, high rates of atrial pacing) or ventricular (frequent premature ventricular complexes, right ventricular outflow tract tachycardia, LVOT, left ventricular fascicular tachycardia, bundle-branch reentry or high rate of ventricular pacing). Electrophysiological study confirms the clinical diagnosis of tachycardia-induced cardiomyopathy, reveals the arrhythmia mechanism and facilitates catheter ablation that results in complete recovery of ventricular function. This chapter has two parts: 1. **Theoretical insight** into the pathogenesis of tachycardia-induced cardiomyopathy, clinical manifestations and therapy. 2. **Practical issues**: we describe our EP lab's experience on electrophysiological study and ablation in patients with tachycardia-induced cardiomyopathy. We will present five cases of ablation: PVCs >30,000/24 h, antidromic tachycardia, 2:1 atrial flutter, persistent atrial fibrillation and RVOT PVCs with nonsustained VT.

**Keywords:** catheter ablation, tachycardia-induced cardiomyopathy, atrial fibrillation, ejection fraction, left ventricular dysfunction

---

## 1. Introduction

Cardiomyopathy is defined by a disease of the heart muscle that progressively worsens and ultimately leads to heart failure and death. Fortunately, there are some reversible cardiomyopathies that can show return to normal cardiac function with or without treatment: peripartum

cardiomyopathy, myocarditis with dilated cardiomyopathy, hyperthyroidism-induced cardiomyopathy, takotsubo cardiomyopathy and tachycardia-induced cardiomyopathy. The last one is a disease caused by a persistent tachycardia with return to normal cardiac function after correction of the arrhythmia.

Arrhythmias that are associated with this type of reversible cardiomyopathy include atrial fibrillation, atrial flutter, atrial tachycardia, atrioventricular node reentrant tachycardia, accessory pathway tachycardia, frequent ventricular ectopic beats and ventricular tachycardia.

## 2. Experimental studies on animals

Animal models helped us to better evaluate cellular and hemodynamic mechanisms underlying tachycardia-induced cardiomyopathy. Whipple et al. described it in an interesting experiment on dogs and pigs using cardiac pacing. Chronic rapid ventricular pacing leads to left biventricular dilatation and decreases in systolic function. When pacing at slower rate or for shorter duration, the degree of dilatation is not so important, as well as the decrease in ejection fraction. Mitral regurgitation appears as a consequence of left ventricular dilatation [1].

## 3. Clinical studies on humans

Multiple tachyarrhythmias have been associated with tachycardia-induced cardiomyopathy including supraventricular and ventricular. Additionally, premature ventricular beats have also been associated with the development of tachycardia-induced cardiomyopathy.

Gentlesk et al. noted that ablation of arrhythmia with restoration of sinus rhythm can improve LV function despite good rate control before the ablation procedure in patients with atrial fibrillation [2]. The most recent series of patients with incessant atrial tachycardia reported normalization of left ventricular function in 97% of the patients after successful ablation [3]. Incessant reentrant supraventricular tachycardias are less common, but tachycardia-induced cardiomyopathy has also been reported in the settings of atrioventricular node reentrant tachycardia, atrioventricular tachycardia using an accessory pathway and permanent junctional form of reentrant tachycardia [4]. When VT leads to tachycardia-induced cardiomyopathy, it is generally idiopathic, originating from RVOT, LVOT or coronary cusps. Premature ventricular contractions have also been associated with the disease.

Medi et al. identified variables associated with tachycardia-induced cardiomyopathy: incessant tachycardia, male gender, mean ventricular rate above 117 bpm and tachycardia originating from the pulmonary veins or left/right appendage [3].

In recent studies, electrical remodeling was demonstrated to precede structural remodeling with subsequent clinical adverse outcomes. In DAVID trial [5], ventricular pacing was associated with increased rate of heart failure hospitalization and cardiac mortality. The trial was designed to test the hypothesis that physiologic heart rates obtained with beta-blockers during ventricular pacing improve survival in patients with heart failure. Contrary to logical thinking,

ventricular pacing had higher incidence of heart failure and cardiac mortality as mentioned above. Recent therapeutic advances using biventricular pacing aim to synchronize electrical activation of the left and right ventricle and reverse structural remodeling. This approach may be of use for tachycardia-induced cardiomyopathy in patients with ventricular pacing or ventricular premature contractions (left ventricular pacing triggered by right ventricular PVCs) but not for tachyarrhythmias [6].

#### **4. Structural changes**

Sustained ventricular or atrial pacing leads to dilatation of all cardiac chambers with systolic and diastolic dysfunction. Cardiac dilatation is accompanied by ventricular wall thinning and elevated ventricular filling pressures with reduced cardiac output. Mitral valve regurgitation appears as a consequence of left ventricular dilatation and stretching of the mitral chordae and annulus [7].

#### **5. Neurohormonal changes**

Low cardiac output leads to neurohormonal activation with elevated plasma catecholamines, atrial natriuretic peptide, rennin and aldosterone [8].

#### **6. Cellular changes**

At the cellular level, it has been found that chronic rapid heart rate causes increase in myocyte length and disruption of the sarcolemmal membrane interface, impairing myocardial function [9]. Abnormalities of the sarcoplasmic reticulum calcium transport may appear at 24 h after initiation of rapid atrial pacing and persist 4 weeks after cessation of pacing. The lower availability of calcium to myocytes may reduce contractility [10]. Besides myocardial energy depletion, myocardial ischemia has been proposed as a possible mechanism for myocardial systolic dysfunction.

#### **7. Tachycardia-induced cardiomyopathy and post-tachycardia T-wave memory**

Both post-tachycardia T-wave memory and tachycardia-induced cardiomyopathy are two phenomenon characterized by electrical remodeling of the ventricles that occur after sustained episodes of tachyarrhythmias.

In cardiac memory, the hallmark is diffuse T-wave inversion. It also appears after persistent abnormal ventricular conduction such as ventricular pacing, intermittent bundle-branch block or ventricular preexcitation. This phenomenon was described in early 1940s in patients with ventricular tachyarrhythmias, but the term of cardiac memory was first introduced by Rosenbaum in 1982 [11]. Abnormal ventricular activation causes change in the action

potential duration in the early versus late activated regions of the myocardium that results in increased transmural repolarization gradient. The duration of inverse T-wave polarity is related to the duration of abnormal ventricular conduction and may have short-term or long-term persistence.

The time course of tachycardia-induced cardiomyopathy can be variable: days to months and even years. It is not known why some patients respond to persistent tachycardia with dilation of the heart chambers and others by negatization of T-waves.

T-wave inversion lasting minutes to hours are described as short-term memory and are observed after short episodes of tachyarrhythmias. Long-term memory lasts hours to days and occurs after temporary cessation of a permanent pacing or after a successful ablation of an accessory pathway. Previous reported cases of transient T-wave inversion following tachycardia failed to show an association between duration of the tachycardia and magnitude and duration of the T-wave changes. Freundlich reported an episode of ventricular tachycardia lasting 10 min and followed by T-wave inversion for 3 weeks [12]. Dubbs and Parmet described a case of VT lasting 21 days and followed by T-wave inversion for only 4 days [13]. Campbell reported a case of atrial tachycardia with a duration of 3 days followed by T-wave inversion for other 3 days [14].

## 8. Time course and recovery of the LV function

The time course of reversal can be variable and may vary from 1 day to several months and even years [15]. The factors that determine the improvement rate remain undefined. It is a combination of genetic and structural heart disease factors that determine the development of the tachycardia-induced cardiomyopathy.

Han et al. [15] reported a patient with dramatic improvement of the LV systolic function <24 h after ablation with improvement of symptoms of congestion the first day after ablation.

Chin et al. [16] reported a series of patients who had improvement of the ejection fraction after 6 months of rate control: two patients with atrial fibrillation treated for heart rate control, two patients with atrial tachycardia treated for heart rate control and two patients with severe systolic dysfunction EF < 20% and recovery of systolic function after adequate treatment. The “slower” the rate control of the tachycardia, the slower the rate of improvement of the systolic function of the left ventricle. In contrast, patients with very low ejection fraction <20% have a slower rate of improvement. Chin et al. evaluated systolic function using either echocardiography or radionuclide angiography [16]. Danadamudi et al. reported patients with ejection fraction normalization after 14 months, but elevated left ventricular end-systolic and end-diastolic volume indexes were still present at follow-up.

## 9. Risk of recurrence

In patients with prior history of tachycardia-induced cardiomyopathy, recurrence of the arrhythmia leads to a more severe form compared to the initial presentation [17].

## 10. Clinical features and diagnostic considerations

Arrhythmias associated with tachycardiomyopathy can be supraventricular (atrial tachycardia, atrial flutter, atrial fibrillation, AVNRT, permanent junctional reciprocating tachycardia, high rates of atrial pacing) or ventricular (frequent premature ventricular complexes, right ventricular outflow tract tachycardia, LVOT, left ventricular fascicular tachycardia, bundle-branch reentry or high rate of ventricular pacing).

The exact incidence of the disease is difficult to assess, as the most reports in medical literature are small retrospective series or case studies.

Tachycardia-induced cardiomyopathy occurs independent of the age: it is present in children [18], adolescents [19], adults [20] and aged persons [21]. In children and adolescents, it should be differentiated from dilated cardiomyopathy due to myocarditis. In this case, cardiac MRI and cardiac biopsy are required to confirm the diagnosis. In adults, other forms of reversible cardiomyopathies should be excluded as follows: peripartum cardiomyopathy, myocarditis with dilated cardiomyopathy, hyperthyroidism-induced cardiomyopathy and takotsubo cardiomyopathy. The time course of the cardiomyopathy and lack of arrhythmia can exclude tachycardia-induced cardiomyopathy. Paraclinical examinations contribute to the differential diagnosis. In aged persons, idiopathic dilated cardiomyopathy is the main differential diagnosis and the presence of a sustained arrhythmia other than sinus rhythm leads to the correct diagnosis.

There is no specific test for the diagnosis of tachycardia-induced cardiomyopathy. A clinical index of suspicion derives from history of symptoms and signs of heart failure and time course of arrhythmia. Therefore, a high index of suspicion should be considered in any patient with sustained tachyarrhythmia and dilated cardiomyopathy and depressed ejection fraction. Any prolonged rate above 120/min may be important for the diagnosis. Patients may develop tachycardia-induced cardiomyopathy even if well-controlled heart rates during rest and high ventricular rate during minimal activity [22]. Holter monitoring on 24 h may be useful in assessing heart rates during minimal exertion or daily physical activity in patients with persistent atrial fibrillation [23].

## 11. Imaging studies in tachycardia-induced cardiomyopathy

Echocardiography is the cornerstone of the noninvasive imaging of tachycardia-induced cardiomyopathy. Increase in ejection fraction after arrhythmia treatment with decrease in ventricular diameters is diagnostic for the disease.

Radionuclide ventriculography is another noninvasive diagnostic technique showing left and right ventricular dilatation and systolic dysfunction.

Cardiac MRI identifies areas of myocardial fibrosis. Hasdemir et al. demonstrated lack of fibrosis in 18 out of 19 patients with tachycardia-induced cardiomyopathy. They concluded that PVC-induced cardiomyopathy is less likely to evaluate with fibrosis [24]. This study is



consistent with the findings of Redfield et al. who demonstrated in a canine model that inflammation, fibrosis and mitochondrial apoptosis are absent in PVC-induced cardiomyopathy [25].

Myocardial biopsy reveals nonspecific findings with interstitial fibrosis and cellular hypertrophy like in other forms of cardiomyopathy [26].

## 12. Treatment

The cornerstone in this reversible cardiomyopathy is normalization of the heart rate either by medication, electrical cardioversion or catheter ablation. This results in decrease in the LV dimensions and increase in the LV ejection fraction [27, 28].

Antiarrhythmic drugs that can be used in patients, both pediatric and adults with tachycardia-induced cardiomyopathy, are the commonly used drugs in the Vaughan Williams classification: Ia, IB, Ic, II and III (both sotalol and amiodarone) as well as combinations. In the study of Moore et al. on pediatric population, most of the patients had amiodarone, beta-blockers or sotalol as treatment followed by Ic, Ia and lastly Ib. Ninety-two percent of patients treated with amiodarone had a positive response to this drug [29].

The catheter ablation technique depends on the principal mechanism of the arrhythmia: abnormal automaticity, triggered activity or reentry. Inappropriate sinus tachycardia is caused by enhanced normal automaticity, and ablation is performed in the region of the sinus node. Focal atrial tachycardia may be due to automaticity, triggered activity or microreentrant mechanism, and ablation is performed at the level of earliest atrial activation site. Typical atrial flutter has a macroreentrant circuit, where ablation is achieved at the level of cavo-tricuspid isthmus. Even though the mechanism of atrial fibrillation is still debated among electrophysiologists, drivers located at the level of pulmonary veins and rotors inside the left atrium are important in initiation and maintenance of the arrhythmia. Ablation for paroxysmal atrial fibrillation consists in pulmonary vein isolation (PVI) and for persistent atrial fibrillation PVI plus substrate modification. Atrioventricular nodal reentrant tachycardia is caused by a reentrant mechanism. The presence of two pathways within the AV node, slow pathway and fast pathway, makes the arrhythmia possible. Under normal condition, ablation is performed at the level of the slow pathway. Atrioventricular reentrant tachycardia mediated by an accessory pathway has also a macroreentrant mechanism. The circuit involves an accessory pathway that is usually ablated during the procedure.

In the absence of a structural heart disease, most ventricular tachycardias have an automatic mechanism or given by triggered activity. For outflow tract tachycardias, ablation is performed at the level of earliest ventricular activation site. Fascicular ventricular tachycardias are accepted to have a macroreentrant mechanism involving slow response fibers of the Purkinje network. Ablation is usually performed at this level or at the fascicular level (left postero-inferior or left antero-superior). Ventricular tachycardia in patients with old myocardial infarction, nonischemic cardiomyopathy or ventricular dysplasia has a reentry mechanism, but usually they are not responsible for tachycardia-induced cardiomyopathy.

We propose the following algorithm of treatment in patients suspected of tachycardia-induced cardiomyopathy: antiarrhythmic drugs should be started with the aim of normalization of the heart rate; in function of the arrhythmia and associated morbidities, beta-blockers can be initiated, then escalated to class IC (propafenone or flecainide) in case of no response in heart rate reduction. Amiodarone should be the last antiarrhythmic drug to be tested because of its side effects. In case of response to amiodarone with normalization of the heart rate and ejection fraction, a diagnosis of tachycardia-induced cardiomyopathy can be made and catheter ablation should be proposed. Catheter ablation aims to stop the long-term treatment with amiodarone.

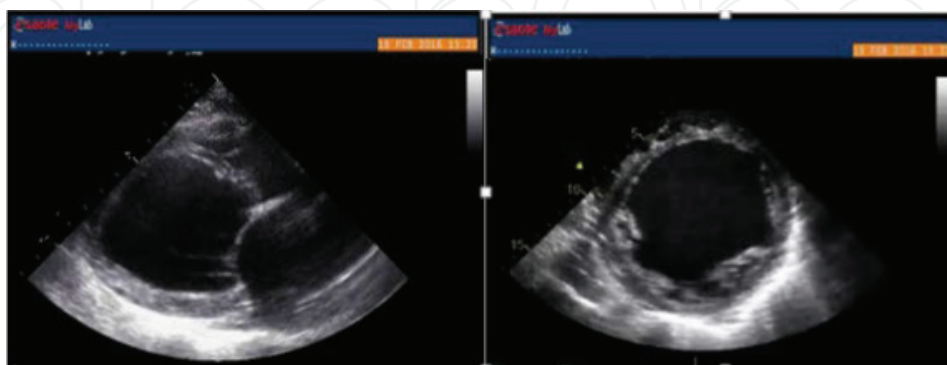
### 13. Clinical case reports

#### 13.1. Case report 1: PVCs >30,000/24 h

A 19-year-old male patient with >30% PVCs on 24 h was hospitalized for catheter ablation. Echocardiography confirmed tachycardia-induced cardiomyopathy with an EF of 35% (**Figure 1**). Cardiac MRI showed an EF of 37% with no sign of myocarditis or fibrosis. After ablation of monomorphic PVCs from the right ventricle (**Figure 2**), LV systolic function normalized with decrease in the dimensions of the heart chambers. At 3-month follow-up, the ejection fraction increased to 55%.

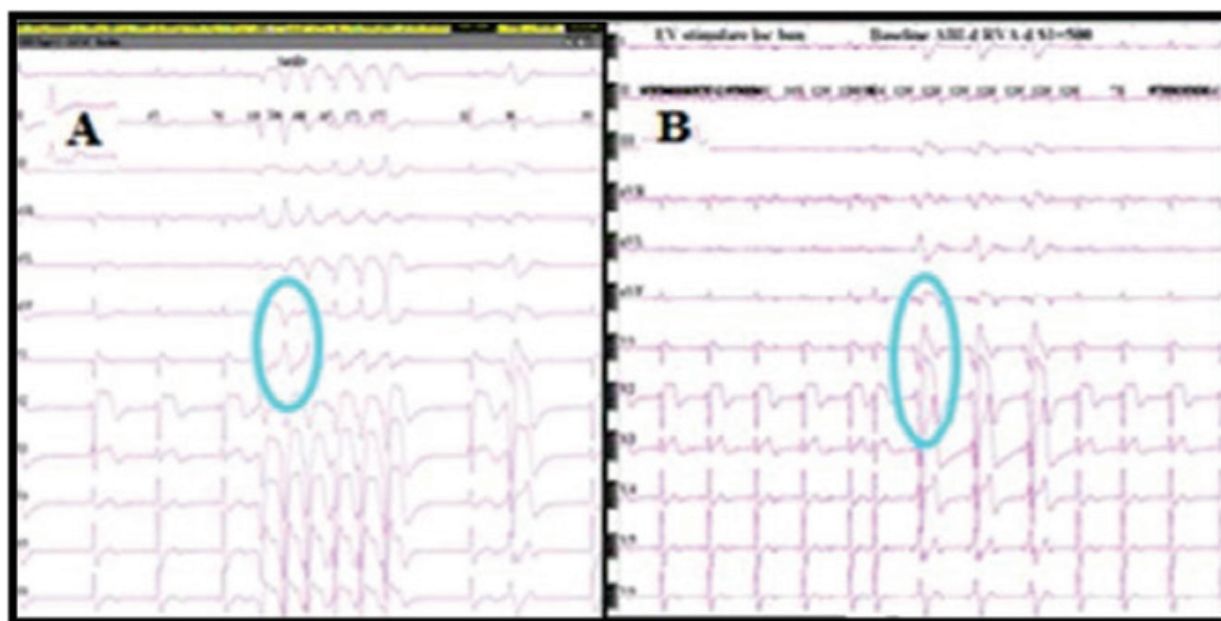
#### 13.2. Case report 2: antidromic tachycardia

A 26-year-old male patient presented episodes of wide QRS tachycardia with depressed ejection fraction of 40% and a dilated left ventricle (**Figure 3**). His resting ECG showed short PR interval and presence of the delta wave (**Figure 4**). The abnormal activation of the left ventricle with intraventricular dissynchronism led to dilated cardiomyopathy. Beta-blockers were ineffective in controlling tachycardia, and catheter ablation was proposed. At 4-week follow-up after ablation, left ventricular function recovered with normalization of the end-systolic and end-diastolic LV diameters.

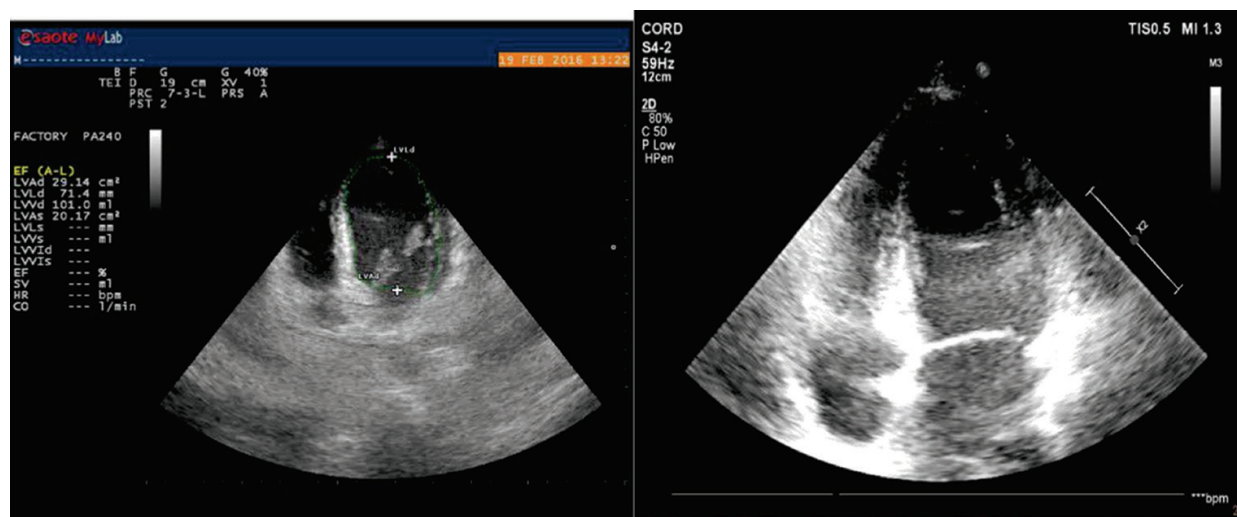


**Figure 1.** Bi-dimensional echocardiography apical view and parasternal short axis in a 19-year-old dilated left ventricle 63/54 with depressed ejection fraction of 35% in a patient with PVC-induced cardiomyopathy.





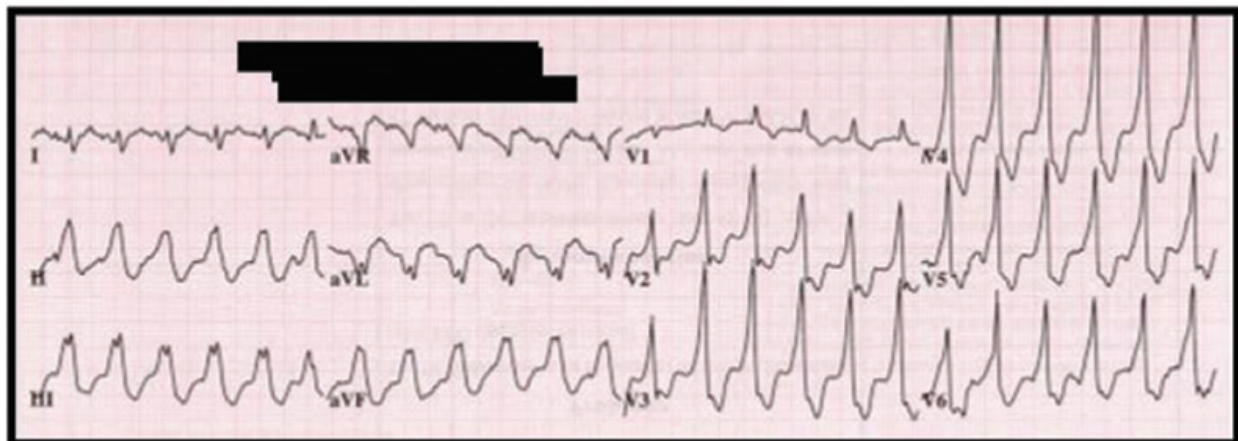**Figure 2.** Pacemap inside the right ventricle to identify the origin of PVCs. (A) poor correlation pacemap-clinical PVC; (B) good correlation 12/12 pacemap-clinical PVC. At this spot, RF ablation determined complete resolution of PVCs with no recurrence. Holter ECG identified 0 ExV/24 h.



**Figure 3.** Echocardiography apical view before and after ablation of a left lateral accessory pathway with frequent episodes of antidromic tachycardia.

### 13.3. Case report 3: 2:1 atrial flutter

A 52-year-old male patient presented to the cardiology department with dyspnea and leg edema. His heart rate was 150 bpm (**Figure 5**), and blood pressure was 110/50 mmHg. Echocardiography revealed depressed ejection fraction of 35% with dilated left ventricle 60/50 and mitral regurgitation grade 2. Antiarrhythmic drug was ineffective in reducing arrhythmia with persistence of high rates 150 bpm after amiodarone, metoprolol and digoxin. He was

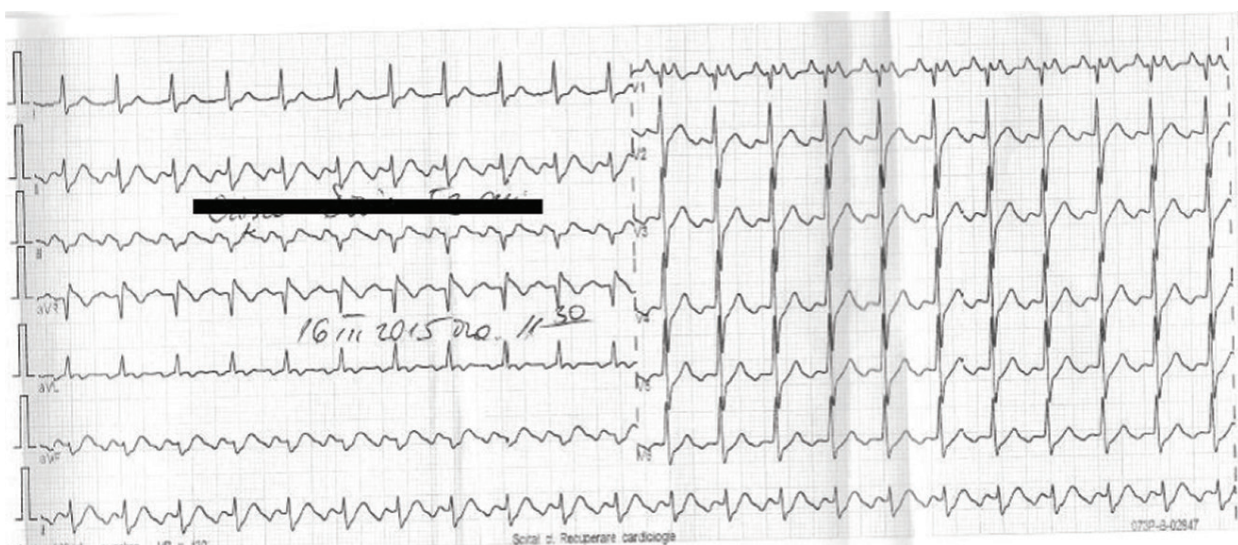


**Figure 4.** Twelve-lead ECG during antidromic tachycardia: wide QRS tachycardia 160/min with positive concordance in the precordial leads and negative QRS in lead I and aVL suggesting left lateral accessory pathway.

transferred in our department, and after ablation of the tricuspid isthmus sinus, rhythm was obtained. At 1-month follow-up, ejection fraction normalized >50% with left ventricular diameters of 45/25 and decrease in mitral regurgitation to grade 1 (**Figure 6**).

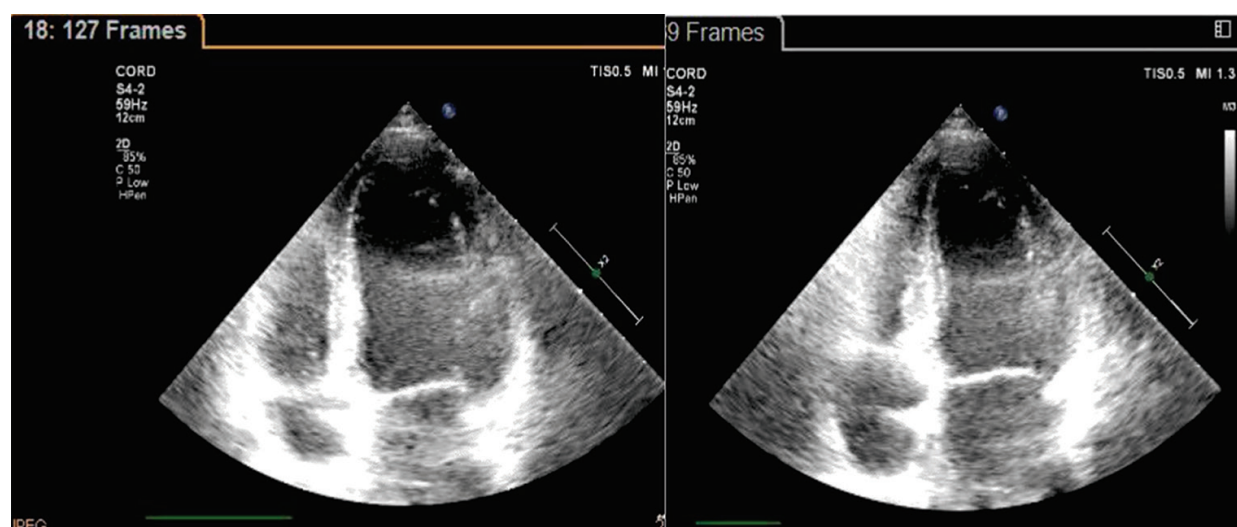
#### 13.4. Case report 4: persistent atrial fibrillation

A 63-year-old male patient presented to our cardiology department an episode of persistent atrial fibrillation and heart failure. At physical examination, we noticed a heart rate of 120 bpm (**Figure 7**), arrhythmic, with systolic murmur in the left ventricular area, a blood pressure of 140/80 mmHg and signs of right heart failure: bilateral edema and hepatomegaly.



**Figure 5.** Twelve-lead ECG during 2:1 atrial flutter in a 52-year-old male patient with tachycardiomyopathy. F waves are negative in inferior leads: D2, D3 and aVF and positive in lead V1.

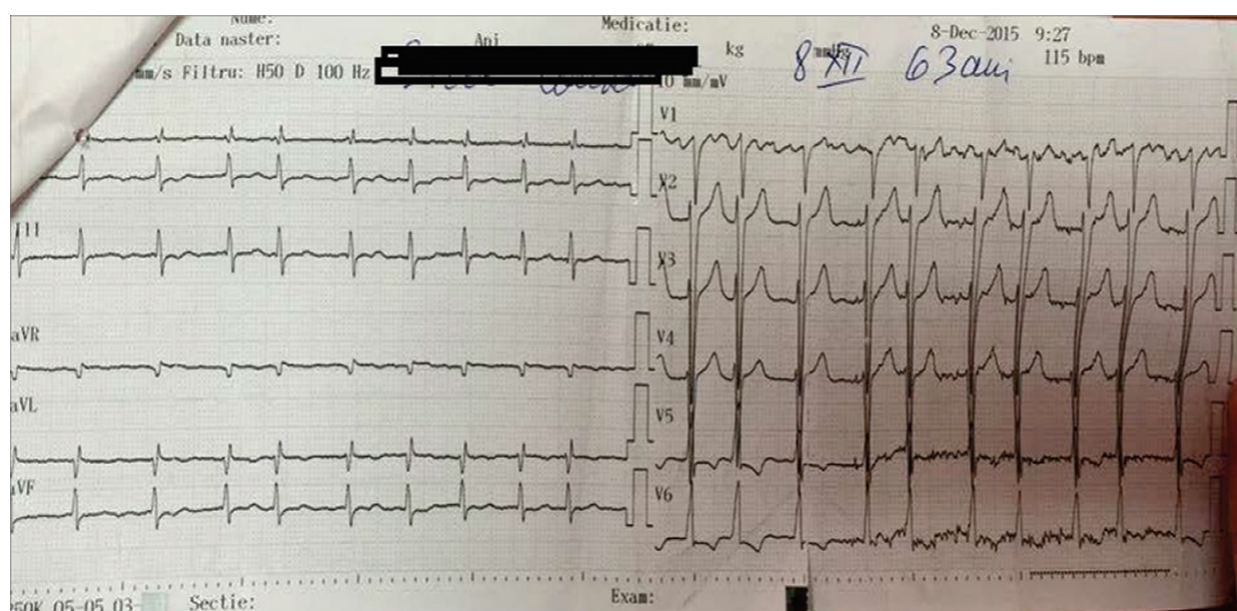




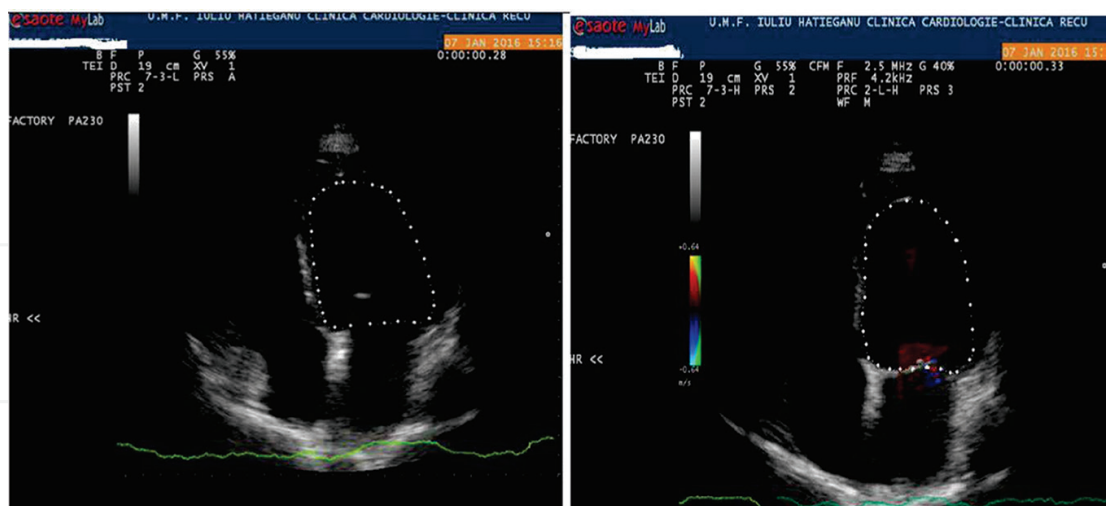
**Figure 6.** Echocardiography apical view before and after ablation of the cavo-tricuspid isthmus in a patient with dilated cardiomyopathy due to 2:1 typical atrial flutter.

Ejection fraction was 30% with mild dilatation of the left ventricle 65/55, mitral regurgitation grade II, left atrial dilation 53 mm and high pulmonary pressure 60 mmHg (**Figure 8**). Lab tests showed normal CBC, effective anticoagulation with an INR of 3.8, LDL = 53 mg% and triglycerides = 65 mg%, normal ASAT = 15 and normal ALAT = 12 mg%. Chest X-ray showed increased cardio-thoracic index (**Figure 9**).

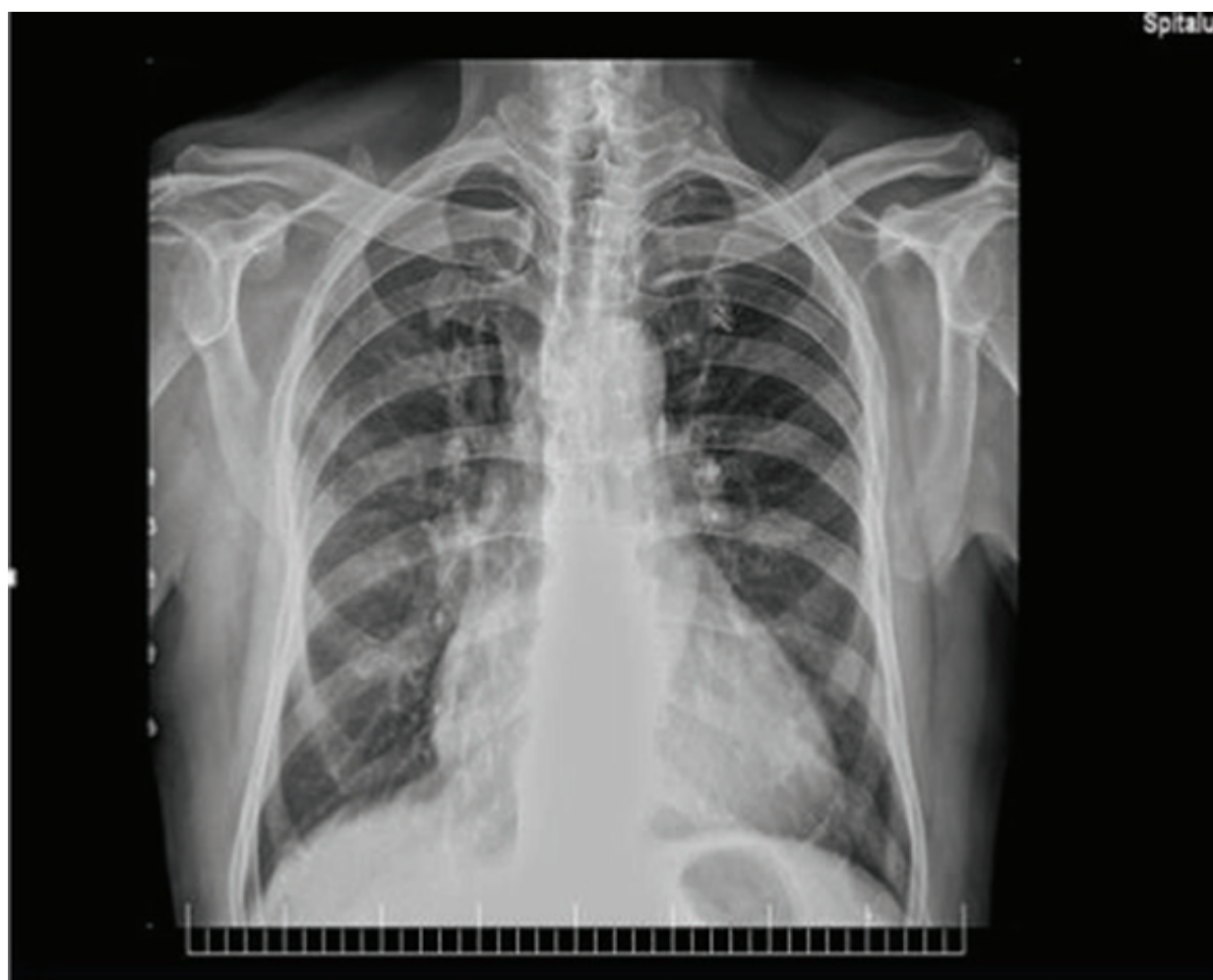
After isolation of the left pulmonary veins (**Figure 10**), sinus rhythm was obtained. No pulmonary vein potentials were observed at the level of the right pulmonary veins (**Figure 11**). No



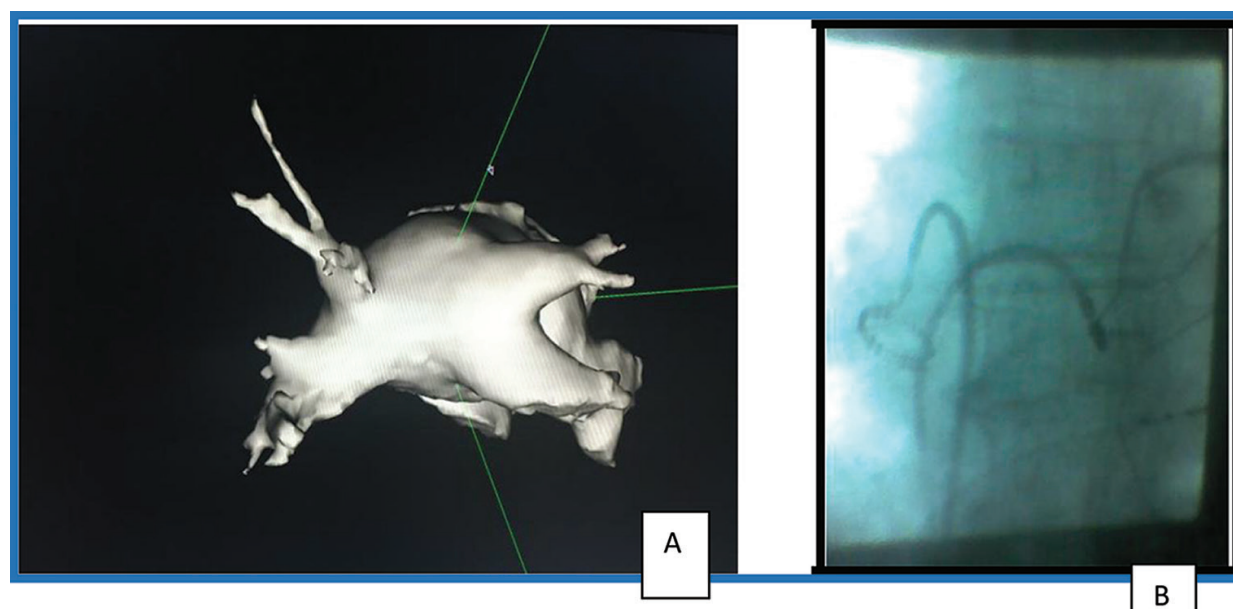
**Figure 7.** Twelve-lead ECG during atrial fibrillation in a 63-year-old male patient with tachycardiomyopathy. The amplitude of the f waves in lead V1 is in favor of a recent onset of atrial fibrillation.



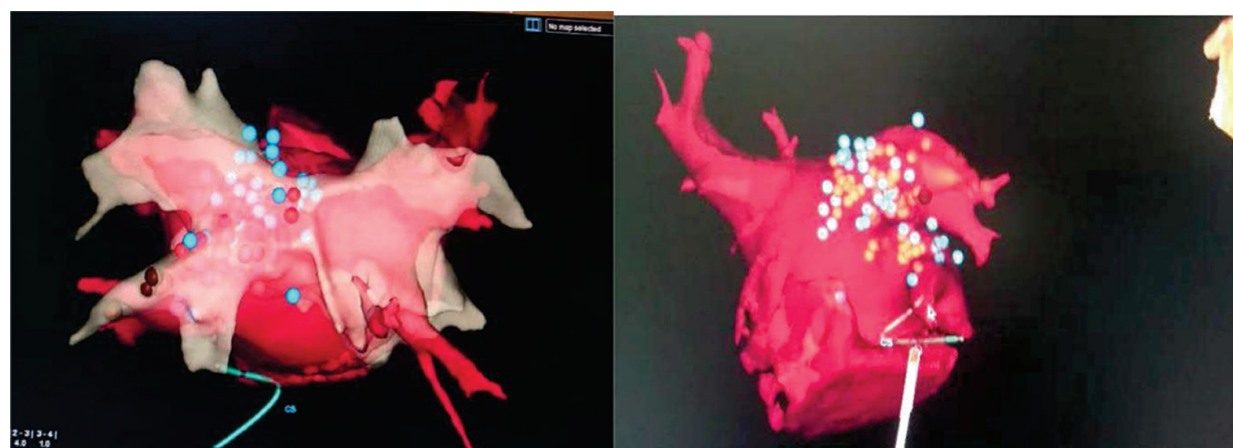
**Figure 8.** Echocardiography apical view before isolation of the pulmonary veins showing dilated left ventricle 65/55 mm with depressed ejection fraction of 30%, mitral regurgitation grade 2 and a dilated left atrium. Images after ablation at 3-month follow-up are not available.



**Figure 9.** Chest X-ray AP view before ablation showing increased cardio-thoracic index.



**Figure 10.** (A) Computed tomography with contrast shows four pulmonary veins: two on the left side and two on the right side and (B) X-ray during mapping of the right inferior pulmonary vein in the AP view. No PVPs were detected inside this vein.



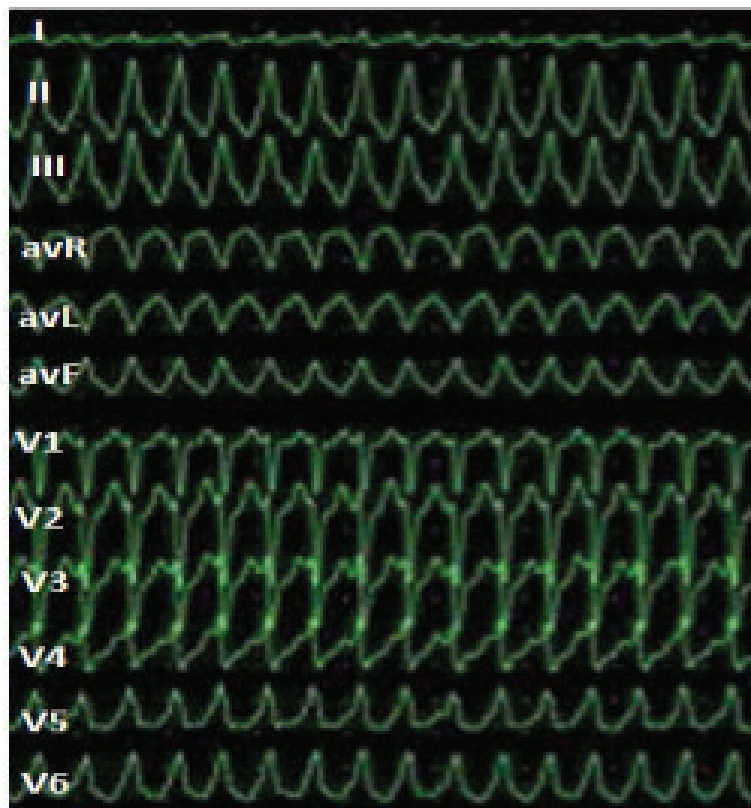
**Figure 11.** Images during the ablation procedure: only the left pulmonary veins were isolated because the right veins presented no PVP. On the left side: merge between scanner and NavX-Saint Jude mapped pulmonary veins.

left atrial substrate ablation was necessary for obtaining sinus rhythm. At 3-month follow-up, echocardiography in another cardiac department showed a normal ejection fraction of 50% with normal left ventricular diameters 52/26, mild dilatation of the left atrium 44 mm and mild mitral regurgitation.

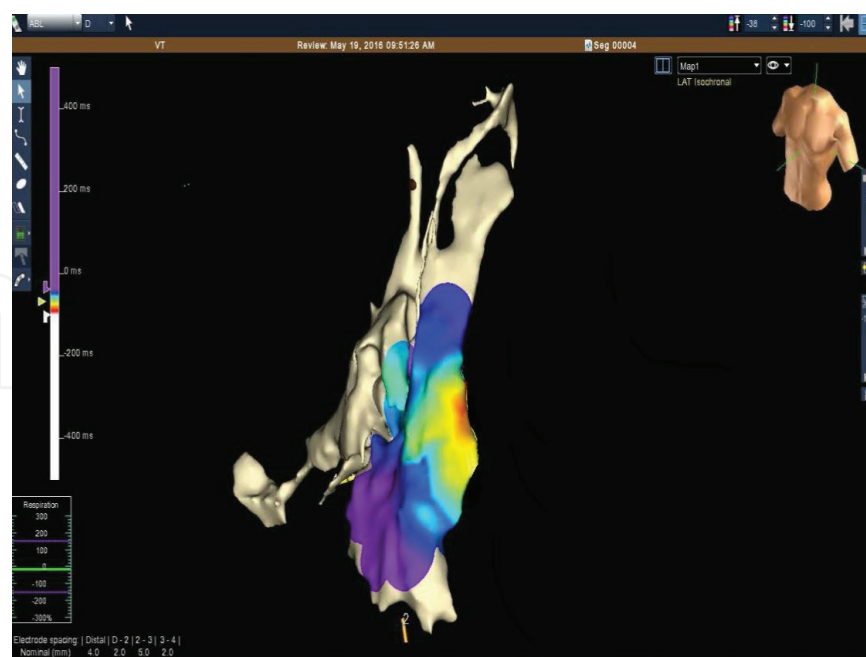
### 13.5. Case report 5: RVOT PVCs and NSVT

A 28-year-old male patient was referred to us because of LV dysfunction, frequent PVCs and episodes of nonsustained VT.





**Figure 12.** Nonsustained VT less than 30 s. The QRS morphology is compatible with RVOT origin: LBBB and inferior axis, transition in V4.



**Figure 13.** Three-dimensional activation mapping using the Navx-Saint Jude system. The earliest potential was recorded at the level of antero-septal RVOT (red color). RF ablation at this level stopped PVCs and rendered RVOT VT uninducible at stimulation after adrenalin infusion.



The patient's main complaint was palpitation with dyspnea during exertion. Echocardiography revealed an EF of 40% and mild dilation of the left ventricle. The QRS morphology was compatible with RVOT origin (**Figure 12**), and the high number of PVCs >35% on 24 h determined us to perform catheter ablation. After the ablation (**Figure 13**), no more PVC was present at follow-up and LV ejection fraction normalized with decrease in LV diameters to normal values.

## 14. Conclusion

Tachycardia-induced cardiomyopathy should be considered in all patients with depressed ejection fraction concomitant with a chronic tachyarrhythmia. It is a reversible cause of heart failure, and electrophysiological study and mapping should be considered early in the diagnosis and treatment algorithm of those patients. An aggressive approach by catheter ablation is important when this type of reversible cardiomyopathy is suspected.

As the clinical impact of ablation is substantial, we recommend it for the reversibility of both functional and structural changes induced by the tachyarrhythmia.

## Author details

Cismaru Gabriel\*, Lucian Muresan, Puiu Mihai, Radu Rosu, Gabriel Gusetu, Dana Pop and Dumitru Zdrengea

\*Address all correspondence to: gabi\_cismaru@yahoo.com

Iuliu Hatieganu University of Medicine and Pharmacy, 5th Dept. of Internal Medicine, Cardiology Rehabilitation, Cluj-Rapoca, Romania

## References

- [1] Whipple GH, Sheffield LT, Woodman EG, Theophilis C, Friedman S. Reversible congestive heart failure due to chronic rapid stimulation of the normal heart. *Proc N Engl Cardiovasc Soc* 1962;20:39–40.
- [2] Gentlesk PJ, Sauer WH, Gerstenfeld EP, Lin D, Dixit S, Zado E, et al. Reversal of left ventricular dysfunction following ablation of atrial fibrillation. *J Cardiovasc Electrophysiol* 2007;18:9–14.
- [3] Medi C, Kalman JM, Haqqani H, et al. Tachycardia-mediated cardiomyopathy secondary to focal atrial tachycardia: long term outcome after catheter ablation. *J Am Coll Cardiol* 2009;53:1791–1797.

- [4] Aguinaga L, Primo J, Anguera I, et al. Long-term follow-up in patients with the permanent form of functional reciprocating tachycardia treated with radiofrequency ablation. *Pacing Clin Electrophysiol* 1998;21:1073–1078.
- [5] Wilkoff BL, Cook JR, Epstein AE, Greene HL, Hallstrom AP, Hsia H, Kutalek SP, et al. Dual-chamber pacing or ventricular backup pacing in patients with an implanted defibrillator: the Dual Chamber and VVI Implantable Defibrillator (DAVID) trial. *JAMA* 2002;288(24):3115–3123.
- [6] Abraham WT, Fisher WG, Smith AL, Delrgio DB, Leon AR, Loh E, Kocovic DZ, et al. Cardiac resynchronization in chronic heart failure. *N Engl J Med* 2002;364(24):1845–1853.
- [7] Tanaka R, Spinale FG, Crawford FA, Zille MR. Effect of chronic supraventricular tachycardia on left ventricular function and structure in newborn pigs. *J Am Coll Cardiol* 1992;20:1650–1660.
- [8] Patel HJ, Pilla JJ, Polidori DJ, Pusca SV, Plappert TA, Sutton MS, Lankford EB, Acker MA. Ten weeks of rapid ventricular pacing creates a long-term model of left ventricular dysfunction. *J Thorac Cardiovasc Surg* 2000;119:834–841.
- [9] Zellner JL, Spinale FG, Eble DM, Hewett KW, Crawford FA Jr. Alteration in myocyte shape and basement attachment with tachycardia-induced heart failure. *Circ Res* 1991;69:590–600.
- [10] O'Brien PJ, Januzzo CD, Moe GW, Stoops TP, Armstrong PW. Rapid ventricular pacing of dogs to heart failure: biochemical and physiological studies. *Can J Physiol Pharmacol* 1990;68:34–39.
- [11] Rosenbaum MB, Blanco HH, Elizari MV, Lazzari JO, Davidenko JM. Electronic modulation of the T wave and cardiac memory. *Am J Cardiol* 1982;50:213–222.
- [12] Freundlich J. Paroxysmal ventricular tachycardia. *Am Heart J* 1946;31:557.
- [13] Dubbs AW, Parmet DH. Ventricular tachycardia stopped on the twenty-first day of giving quinidine sulfate intravenously. *Am Heart J* 1942;24:272.
- [14] Campbell M. Inversion of T waves after long paroxysms of tachycardia. *Br Heart J* 1942;4:49.
- [15] Han FT, Kiser R, Nixon JV, Wood MA, Ellenbogen KA. What is the time course of reversal of tachycardia-induced cardiomyopathy? *Europace* 2011;13:139–141.
- [16] Chin A, Ntusi BM, Badri M. Clinical, electrocardiographic and echocardiographic characteristics of tachycardia-induced cardiomyopathy. *Eur J Heart Fail Suppl* 2010;9(Suppl. 1):5251.
- [17] Nerheim P, Biger-Botkin S, Piracha L, Olhansky B. Heart failure and sudden cardiac death in patients with tachycardia-induced cardiomyopathy and recurrent tachycardia. *Circulation* 2004;110:247–252.

- [18] Juneja R, Shah S, Naik N, Kothari SS, Saxena A, Talwar KK. Management of cardiomyopathy resulting from incessant supraventricular tachycardia in infants and children. *India Heart J* 2002;54:176–180.
- [19] Walker NL, Coobe SM, Birnie DH. Tachycardiomyopathy: a diagnosis not to be missed. *Heart* 2004;90:e7.
- [20] Calo L, Sciarra L, Scioli R, Lamberti F, Loricchio ML, Pandozi C, Santini M. Recovery of cardiac function after ablation of atrial tachycardia arising from tricuspid annulus. *Ital Heart J* 2005;6:652–657.
- [21] Salemi VM, Arteaga E, Mady C. Recovery of systolic and diastolic function after ablation of incessant supraventricular tachycardia. *Eur J Heart Fail* 2005;7:1177–1179.
- [22] Rodrigues LM, Smees JL, Xie B. Improvement in left ventricular function by ablation of atrioventricular nodal conduction in selected patients with lone atrial fibrillation. *Am J Cardiol* 1993;72:1137–1141.
- [23] Redfield MM, Kay GN, Jenkins LS, Mianulli M, Jensen DN, Ellenbogen KA. Tachycardia-related cardiomyopathy: a common cause of ventricular dysfunction in patients with atrial fibrillation referred for atrioventricular ablation. *Mayo Clin Proc* 2000;75:790–795.
- [24] Hasdemir C, Yuksel A, Camil D et al. Late gadolinium enhancement CMR in patients with tachycardia-induced cardiomyopathy caused by idiopathic ventricular arrhythmia. *Pacing Clin Electrophysiol* 2012;35:465–470.
- [25] Redfield MM, Aarhus LL, Wright RS, Burnett JC Jr. Cardiorenal and neurohormonal function in a canine model of early left ventricular dysfunction. *Circulation* 1993;87:2016–2022.
- [26] Fenelon G, Wijns W, Andries E, Brugada P. Tachycardiomyopathy: mechanisms and clinical application. *Pacing Clin Electrophysiol* 1996;19:95–106.
- [27] Packer DL, Bardy GH, Worley SJ, Smith MS, Cobb FR, Coleman RE, Gallagher JJ, German LD. Tachycardia-induced cardiomyopathy: a reversible form of left ventricular dysfunction. *Am J Cardiol* 1986;57:563–570.
- [28] Kessler G, Roseblatt S, Friedman J, Kaplinsky E. Recurrent dilated cardiomyopathy reversed with cardioversion of atrial fibrillation. *Am Heart J* 1997;133:384–386.
- [29] Alessandrini RS, McPherson DD, Kadish AH, Kane BJ, Goldberger JJ. Cardiac memory: a mechanical and electrical phenomenon. *Am J Physiol* 1997 Apr;272(4 Pt 2):H1952–9.