

We are IntechOpen, the world's leading publisher of Open Access books Built by scientists, for scientists

6,900

Open access books available

186,000

International authors and editors

200M

Downloads

Our authors are among the

154

Countries delivered to

TOP 1%

most cited scientists

12.2%

Contributors from top 500 universities



WEB OF SCIENCE™

Selection of our books indexed in the Book Citation Index
in Web of Science™ Core Collection (BKCI)

Interested in publishing with us?
Contact book.department@intechopen.com

Numbers displayed above are based on latest data collected.
For more information visit www.intechopen.com



Surgical Management of Migraine Headaches

Michael Chung, Kyle Sanniec, Xingchen Li and
Bardia Amirlak

Additional information is available at the end of the chapter

<http://dx.doi.org/10.5772/66229>

Abstract

Although migraines are experienced by a significant portion of the population, current medical therapies often fail to completely alleviate the symptoms of many migraine sufferers, leading to significant residual disability. Within the last decade, migraine surgery has arisen as a viable option for patients who have exhausted all other medical treatments. Despite early resistance in the headache care community, it has become more accepted due to an increasing number of studies demonstrating efficacy and safety, and increasing evidence supporting the influence of peripheral nerves in the progression of migraine pathophysiology. Yet, it remains crucial to carefully select appropriate surgical candidates based on the assessment of various factors such as medication use, pain distribution, and any other medical conditions that may contribute to headache. It is equally important to ensure that the patient has a strong relationship with a neurologist for optimal medical management and postoperative medical support. After the appropriate trigger sites are identified, various techniques can be used to decompress the involved larger nerves, avulse the smaller nerves, and address any intranasal pathology that could be causing migraines.

Keywords: migraine surgery, chronic headache, nerve decompression, greater occipital nerve, lesser occipital nerve, occipital neuralgia, auriculotemporal nerve, zygomaticotemporal branch of the trigeminal nerve, supraorbital nerve, supratrochlear nerve

1. Introduction

Migraine headaches (MH) affect over 37 million people in the United States [1]. One in four households will have at least one person experienced migraines, as the prevalence for females reaches as high as 18%, and males 6% [2]. Sufferers can develop severe disability that takes away their ability to do even the most routine daily activities. Many do not seek treatment, and even if

they do, traditional medications often fail to completely treat patients, leaving them with significant residual disability. It is estimated that one-third of migraine patients are refractory to preventative and pharmacological treatments [3]. A common and effective option for these patients is surgical decompression, which may be the only treatment that can provide permanent relief.

2. Pathophysiology

Because migraine headache development seems to be complex and multifactorial, its exact pathophysiology is complicated and incompletely understood. Classically, migraine headaches were described as a central nervous system event, but recent publications have stressed the role of peripheral nerves [4, 5]. As the evidence for a peripheral explanation of migraine development continues to increase, so does the evidence for surgical decompression as an effective treatment [6–11].

There are four commonly accepted and experimentally substantiated theories that incorporate both central and peripheral nervous system activity. These include: *periaqueductal gray matter dysfunction*, *interictal cortical derangement*, *cortical spreading depression*, and *trigeminal nerve irritation*. The combined effect of these neural derangements is a cycle of nerve irritation, inflammation, and sensory hypersensitivity in the peripheral nerve [12–14]. In migraine headaches, these derangements occur in the areas of trigeminal innervation. A recent microscopic and proteomic analysis indicated that there are indeed biostructural differences in myelin between some peripheral nerves excised from migraine patients and peripheral nerves excised from patients without migraines [15].

One theory that explains the cycle of trigeminal irritation and hypersensitization is the anatomical relationship between peripheral nerves and surrounding musculature. Trigger points for nerve irritation are located at points of intersection between nerve and muscle. One specific example is the interaction between the supratrochlear and supraorbital nerve branches of the ophthalmic division of the trigeminal nerve and the corrugator and depressor supercilii muscle [16]. The observation that many patients with frontal migraines have supercilii hypertrophy supports the theory that muscle impaction on the nerve at least plays a role in inducing migraine pain [17]. Furthermore, the beneficial effect of onabotulinumtoxinA injection into this muscle group reinforces this notion [18, 19]. Other trigger sites of nerve and muscle interaction include the zygomaticotemporal branch of the maxillary division of the trigeminal nerve as it pierces the temporal muscle and the greater occipital nerve (GON) as it passes through the splenius capitis muscle.

3. Surgical treatment

3.1. Rationale and indication for surgical treatment

In the last century, several surgeons demonstrated the effects of operating on nerves to treat migraine headaches. From these studies, they noticed some beneficial results, but the

morbidity and adverse sequelae were unacceptable to further this practice. The first attempt to treat MH was conducted by Walter Dandy in 1931, who removed the inferior cervical and first thoracic sympathetic ganglions [20]. In 1946, Gardner resected the greater superficial petrosal nerve in 26 patients [21]. Despite having some reduction in symptoms, he reported complications such as nasal dryness, decreased tear production, and corneal ulceration. A few decades later, temporal neurovascular bundle resection and greater occipital nerve resection were reported by Murillo [22] and Murphy [23]. While innovative, these surgeries were radical and led to numerous side effects like numbness and muscle weakness. Despite the unwanted effects from surgery, these studies showed potential and provided the groundwork for modern surgical treatment of migraine headaches.

With better understanding of migraine pathophysiology and advancements in technology and surgical techniques within the last two decades, surgical methods of treating migraine headaches have been demonstrated to indeed be significantly useful [4]. As the pioneer of modern surgical decompression for migraine headaches, Guyuron observed that among his patients who underwent cosmetic forehead rejuvenation, a number of those with preoperative migraine headaches received complete elimination or significant reduction in headache symptoms [16]. In this forehead rejuvenation surgery, the glabellar muscle group (corrugator, depressor supercilii, and procerus) is resected. As anatomical studies show that the supraorbital and supratrochlear nerves are intimately associated with this muscle group. Therefore, if nerve irritation from this relationship contributes significantly to the pathophysiology of migraine headaches, resection of the muscle group at this site theoretically should resolve symptoms [24]. This led to a retrospective report, and eventually a prospective double-blinded sham-controlled study, as a protocol for surgical migraine treatment was developed [16, 24]. A five-year retrospective follow-up study confirmed that 88% of these patients, who underwent this prospective trial, experienced a positive response to the surgery. Specifically, 29% reported complete elimination of all migraine symptoms [9]. In time, the recognition of additional extracranial trigger sites and several retrospective studies demonstrated significant efficacy in reducing migraine symptoms [6, 8–11, 16, 24, 25]. The combination of numerous studies shows that on average success from decompression surgery, meaning at least 50% reduction in symptoms, nears 90% [4]. As many as 63% of patients report complete elimination of migraine symptoms [9, 26–28]. As mentioned earlier, there are structural differences in the myelin sheath of some of the nerves excised from migraine patients versus those without migraines [15]. This biostructural difference suggests a peripheral mechanism in migraine pathology and thus further supports the rationale for surgical removal or decompression of these nerves. Finally, the sham controlled study conducted by Guyuron provides evidence against the placebo effect explanation [9, 25].

3.2. Migraine trigger site decompression surgery: arguments for and against

Following the first successful report by Guyuron in 2002, migraine trigger site deactivation surgery has been received with some controversy in neurology. Our understanding of migraine headache's complex pathophysiology and how interactions between central and peripheral mechanisms influence the development of migraine headaches is an ongoing investigation. The unclear mechanism of action in the context of current migraine pathophysiology models,

and the potential for serious irreversible adverse events, causes uncertainty and hesitation among certain headache care providers. It is possible that procedures involving nerve avulsions or possible damage to nerves may result in numbness, paresthesias, dysesthesias, and exacerbated pain postoperatively [29, 30]. However, studies have shown few nonserious complications, often limited locally to the surgical site, and no complications requiring a return to the operating room [4]. Criticisms against surgical treatments also point to possible weaknesses and design flaws in early key studies that show significant efficacy from surgical deactivation [31]. Due to the nature of long-term surgical trials, it is very difficult to design studies that can both satisfy the biggest skeptics and also remain ethical in what patients are required to undergo through the course of the trial. Even so, evidence supporting the migraine decompression surgery is accumulating at a rapid pace. In addition to over 30 anatomical studies to date, there are 17 clinical studies, including a sham control prospective trial, showing the positive effect of decompression surgery and its long-term efficacy [4]. Nevertheless, migraine pathophysiology is complex and dynamic. It is unclear the role of surgical decompression in chronic migraine patients with triggers that may be predominantly central. In each study, certified neurologists were intimately involved throughout every step of each trial [32]. Therefore, it is critical that every patient being evaluated for migraine surgical decompression is also concurrently evaluated by a neurologist to ensure the best understanding of the unique mechanistic picture of their headaches. The cooperation between neurologists and plastic surgeons in each step of treatment for migraine patients is essential: from diagnosis to medication management to postoperative management.

3.3. Long-term results

A recent systematic review compiled the clinical results of all studies on migraine decompression across multiple institutions [4]. In all but one study in this review, follow-up of surgical decompression patients exceeded 1 year, with every study demonstrating sustained long-term benefits from surgery. In his review, Janis reported the average success rate of, meaning at least 50% reduction in migraine symptoms, about 90%. A five-year outcomes report on the Guyuron randomized-placebo-controlled study demonstrated both sustained benefits from surgery and a lack of serious long-term adverse complications [9]. While the placebo effect for migraine surgery is possible, it is unlikely that it is so significant 5 years after intervention. This five-year study, and the other studies reviewed by Janis, provides evidence for the sustained, long-term benefits of migraine decompression surgery, with minimal risk for serious complications [4, 9, 25, 28, 33].

3.4. Preoperative considerations

Before taking a migraine patient to undergo surgical intervention, there are several considerations that the headache care provider should use to identify the ideal candidate. It is of utmost importance for the patient to see a neurologist to confirm the diagnosis. A headache questionnaire and patient headache log can be very useful in identifying the migraine patient. Equally as important, the neurologist can help manage the numerous migraine medications that patients often take. It is important to control the use of narcotics to prevent medication overuse headache or even a reduced response to surgery. Narcotic users showed significantly less improvement in frequency, duration, and severity of migraines in a 2014 study [26]. On

Site I—Frontal headache	Site II—Temporal headache
Frontal pain	Temporal pain
Stress	Morning peak
Robust muscles for frowning	Stress
Eyebrow/eyelid ptosis	Clenching/grinding
Tenderness	Trigger point tenderness
Corrugator contraction triggered by intense and bright lights (sunglasses often needed)	TMJ pain
Site III—Rhinogenic headache	Site IV—Occipital headache
Retroorbital pain	Occipital pain
Early morning peak	No specific time when pain is worst
Change in weather related	Stress
Allergy related	Related to heavy exercise
Hormone related	Muscle tightness
Rhinorrhea	Trigger point tenderness
Cyclic	Radiation of pain to retroorbital area or area above the posterior superior part of the ear

Table 1. Constellation of symptoms for each common trigger site [36].

physical exam and history, there should be evidence of nerve irritation as evidenced by tenderness in the specific topographic compression sites. Additionally, there should be no other medical or neurological conditions that may likely explain another cause for their headache symptoms. Assess for any unacceptable surgical risk. Pregnant and nursing women are typically not considered for surgical intervention.

The headache care provider is led to suspect various trigger sites for the cause of the patient's pain by considering the constellation of symptoms. This is outlined in **Table 1**. The patient can usually give an idea of where the pain originates and where it spreads to. On palpation, tender areas often correspond with anatomically studied nerve compression sites. For intranasal sources of pain, the nose can be examined in office by a direct or indirect endoscopic approach to identify septal deviations or masses such as turbinate hypertrophy and concha bullosa. These findings can be confirmed by X-ray computed tomography. Typically, after confirmation of migraine by a neurologist, patients undergo BOTOX injections in each of the identified sites to temporarily relieve symptoms. Targeted chemodenervation by this toxin is also used to confirm the sites suspected to benefit from surgical excision [17, 34]. An alternative method is chemical nerve block. Local anesthesia is often used by surgeons to identify which sites will respond to decompression. Although chemodenervation is a useful prognostic indicator for surgical success, the constellation of symptoms based on physical exam and history is just as effective at predicting which sites will benefit [35].

4. Trigger sites

There are six major trigger sites identified by careful anatomical studies and experience with migraine surgery. **Site I** refers to the frontal area migraines, where the glabellar muscles, fascial bands, supraorbital and supratrochlear vessels, and at times supraorbital foraminal

anatomy (foramen versus notch) compress the supraorbital and supratrochlear nerves (**Figure 1**). **Site II** refers to headaches originating in the temple areas of the zygomaticotemporal branch of the trigeminal nerve (ZTBTN) (**Figure 2**). The zygomaticotemporal branch of the trigeminal nerve is irritated by the temporalis muscle and accompanying fascial elements. **Site III** refers to an intranasal origin. Septal deviation with boney spurs, turbinate pathology, or bullosa anomalies causes contact with the septum. This paranasal and retrobulbar type pain is caused by irritation of terminal branches of the trigeminal nerve via the sphenopalatine, anterior ethmoidal, and posterior ethmoidal nerves (**Figure 3**). **Site IV** refers to headaches originating around the greater occipital nerve in the occipital area of the neck. In this area, the semispinalis capitis muscle, accompanying fascia, trapezius fascia, and occipital vessels can irritate and compress the greater occipital nerve. **Site V** refers to auriculotemporal nerve irritation in the temple above the temporomandibular joint (TMJ) by fascial bands, and higher in the temple by the temporal artery. **Site VI** refers to pain originating lower in the neck from the lesser occipital nerve (LON) as it is compressed by fascial and vascular elements. Each of these sites is well understood, and multiple locations of potential compression have been elucidated. In addition to the six common sites, neurologists and plastic surgeons often

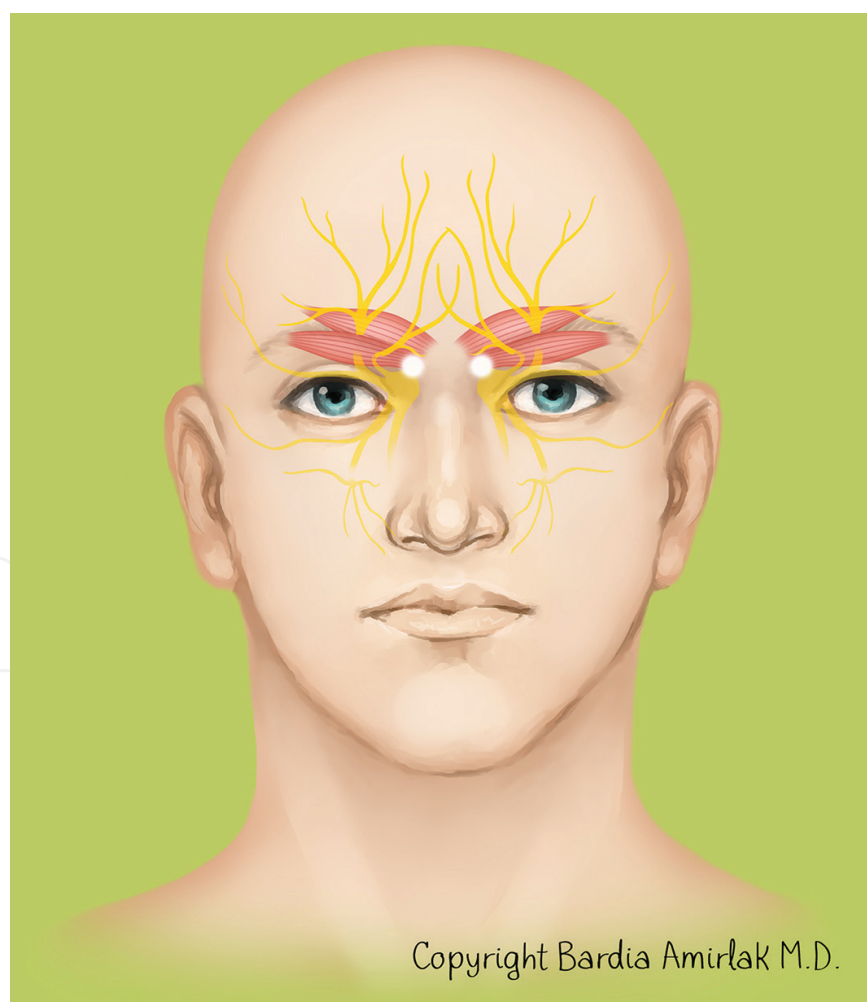


Figure 1. Site I trigger site. The supraorbital and supratrochlear nerves are found here along with the glabellar muscles, fascial bands, supraorbital and supratrochlear vessels, and possible supraorbital foramen.

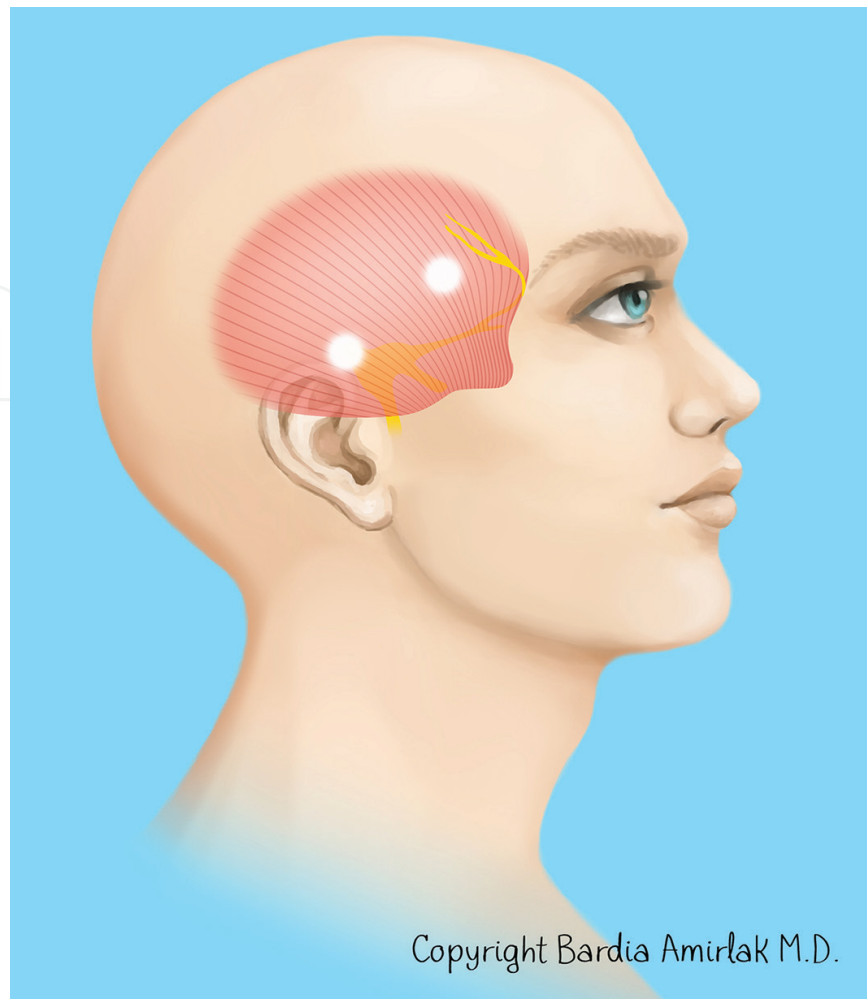


Figure 2. Site II trigger site. The zygomaticotemporal branch of the trigeminal nerve travels through the temporal muscle before piercing the deep temporal fascia 17 mm lateral and 0.6 mm superior to the lateral canthus.

encounter migraines originating from other less common sites, such as the third occipital nerve and distal tail ends of the greater and lesser occipital nerves.

4.1. Frontal triggers

Site I decompression can be approached endoscopically through multiple hairline incisions or directly through transpalpebral incision. Decompression at this site involves release of the corrugator myofascial unit by partial resection of the corrugator supercilii muscle (CSM) group. Alternatively, the entire glabellar muscle group can be excised, including the corrugator supercilii, depressor supercilii, and procerus muscles. Compressing fascial bands are lysed. Foraminotomy and vascular lysis are performed if necessary.

4.1.1. Transpalpebral approach

After initiation of anesthesia, the upper tarsal crease is marked on each eyelid. An incision of 1-inch length is made and extended through the orbicularis muscle. As the dissection plane is extended, several muscles come into view. Careful exposure of the depressor supercilii and

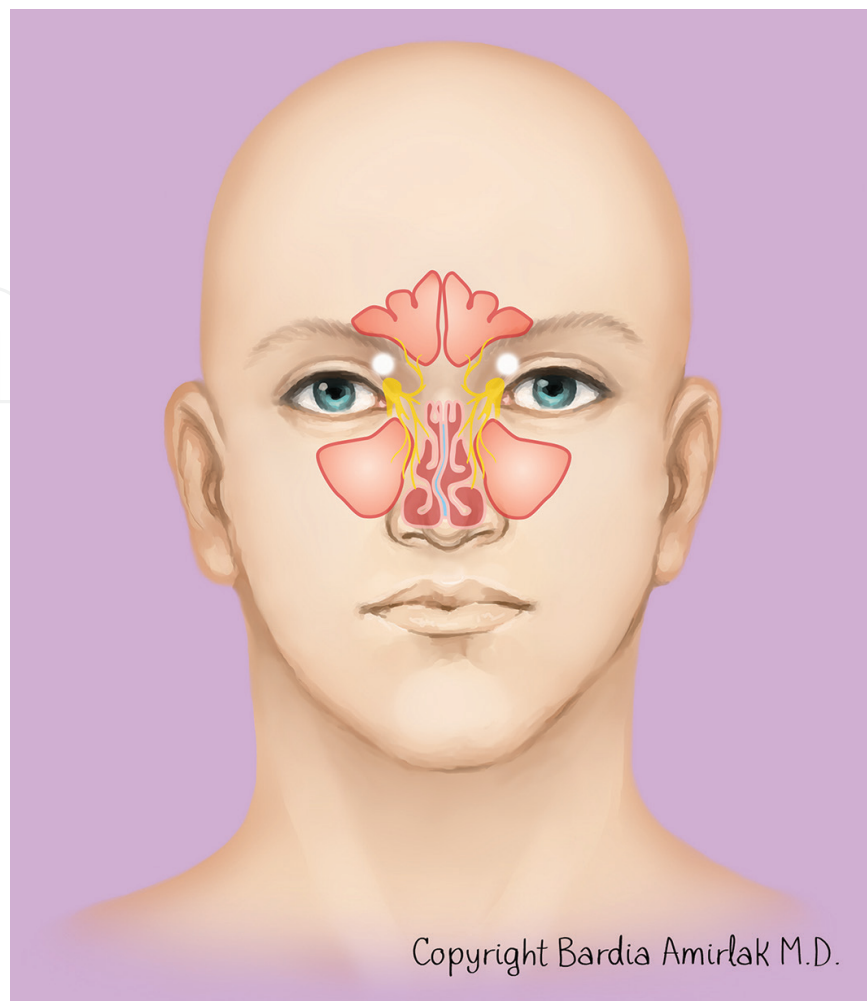


Figure 3. Site III trigger site, intranasal trigger site. The sphenopalatine, anterior ethmoidal, and/or posterior ethmoidal nerves can become irritated by structures such as a deviated septum with contact points, bony spurs with contact points to hypertrophied turbinates, or concha bullosa that lead to paranasal and retrobulbar pain.

corrugator supercilii muscles allow for thorough removal. The supraorbital nerve is encountered laterally and the supratrochlear nerve more medially. A branch of the supratrochlear artery is removed, as well as the procerus muscle. To fill the empty space, autologous fat is grafted and sutured in place.

Complications from this procedure include forehead and frontoparietal paresthesia. Although this is common, it will almost always resolve in time if the nerves are preserved in place. Even in cases of traction avulsion of the Supratrochlear nerve (STN), with the Supraorbital nerve (SON) preserved, incidents of painful neuroma are extremely rare.

4.1.2. Endoscopic approach

Five total incisions are made: one midline and two on either side of the temple. This approach allows for multiple procedures to be combined: frontal decompression and temporal ZTBTN avulsion. Therefore, this endoscopic approach is often preferred and in fact has a higher success

rate, which is likely due to increased visualization and the ability to address accessory nerves. Similar to the transpalpebral approach, dissection is extended to expose the SON, STN, and surrounding musculature. The corrugator should be adequately removed and fat grafted into the area.

Complications of this approach include alopecia at port sites, which is very rare. Paresthesia of the temporal and scalp region can occur, but most resolve over time. In this area, the temporal branch of the facial nerve can theoretically be injured, resulting in paralysis of the frontalis. However, there have been no reports of this potential complication among the endoscopic surgeons. Therefore, it is important that only a well-trained and seasoned endoscopic plastic surgeon attempt this operation.

4.2. Temporal triggers

Decompression at the temporal site can be part of the endoscopic approach. The dissection is extended in the plane of the periosteum and carried to the lateral part of the supraorbital rim, lateral orbital rim, and over the deep layer of temporal fascia to the zygomatic arch, and malar arch. The ZTBTN emerges from the temporalis muscle approximately 17 mm lateral and 6 mm superior to the lateral canthus. It is found superficial to the deep temporal fascia [37]. The ZTBTN can be avulsed or decompressed, each with similar rates of surgical success [33]. As mentioned, there are no reports of neuroma with traction avulsion.

Rarely, complications from this procedure include temporary paresthesia and anesthesia. Alopecia can occur at port sites and sites of local anesthetic injection. Facial nerve injury, as mentioned above, is a theoretical complication.

The auriculotemporal nerve (AT) is addressed by decompression with a small 1 cm incision in the high temple over the compression site of the temporal artery, with or without traction avulsion of the nerve in the periauricular area and ligation of the temporal artery (Amirlak's approach) [38]. Similarly, low rates of temporary paresthesia and minor anesthesia have been reported, without reports of facial nerve injury. However, this incision in the periauricular area possesses a higher likelihood of inadvertent injury to the temporal branch of the facial nerve. Therefore, a nerve stimulator is used during surgery confirm the identities of encountered nerves.

4.3. Occipital triggers

In the preoperative waiting room, markings are made at the midline, at the hairline, and at points of maximum tenderness. After initiation of anesthesia, the patient's hair is shaved to expose the surgical area. A midline incision is made. At this point, efforts should be made to keep the incision within hair-bearing areas to prevent visible scarring. As the dissection is extended, fibers of the trapezius and semispinalis capitis muscles are differentiated. In most cases, the third occipital nerve is encountered during dissection. Although this nerve is usually avulsed when encountered, evidence has shown that there is no difference in surgical success whether or not the nerve is taken [39]. The semispinalis is further exposed by retraction. The trunk of the greater occipital nerve (GON) is located roughly 3 cm below the occipital protuberance and 1.5 cm lateral from the midline. After the nerve and surrounding musculature

are identified and exposed, a full thickness section of the semispinalis is resected medial to the path of the GON. This excision is complete when the nerve is completely released, and no muscle tissue remains medial to the nerve. Superiorly, a portion of the trapezius fascia and muscle are removed, along with any fascial bands encountered on the nerve. The trapezium tunnel is opened and decompressed. An endoscopic modification of the Guyuron technique was described by the senior author (BA), which further elucidates the dynamic compression of the occipital vessels on the nerve (manuscript in preparation). Most of these vessels are lysed with no complications. Finally, a subcutaneous fat flap is passed underneath the nerve and sutured in place to protect the nerve from further compression. **Figure 4** shows the greater occipital nerve after partial decompression (opening of the trapezius fascia proximally and removal of the medial portion of the semispinalis muscle to expose the body of the nerve show that the right GON is more flat and compressed than the left).

The lesser occipital nerve (LON) is addressed similarly, but it possesses a more complicated and ill-defined anatomy. However, several approaches, including traction neurectomy, the decompression and crush technique, and the cut and burying in the muscle technique, have been described with no clear benefit of one over the other.

Temporary paresthesia and anesthesia have been reported, which improve over time.

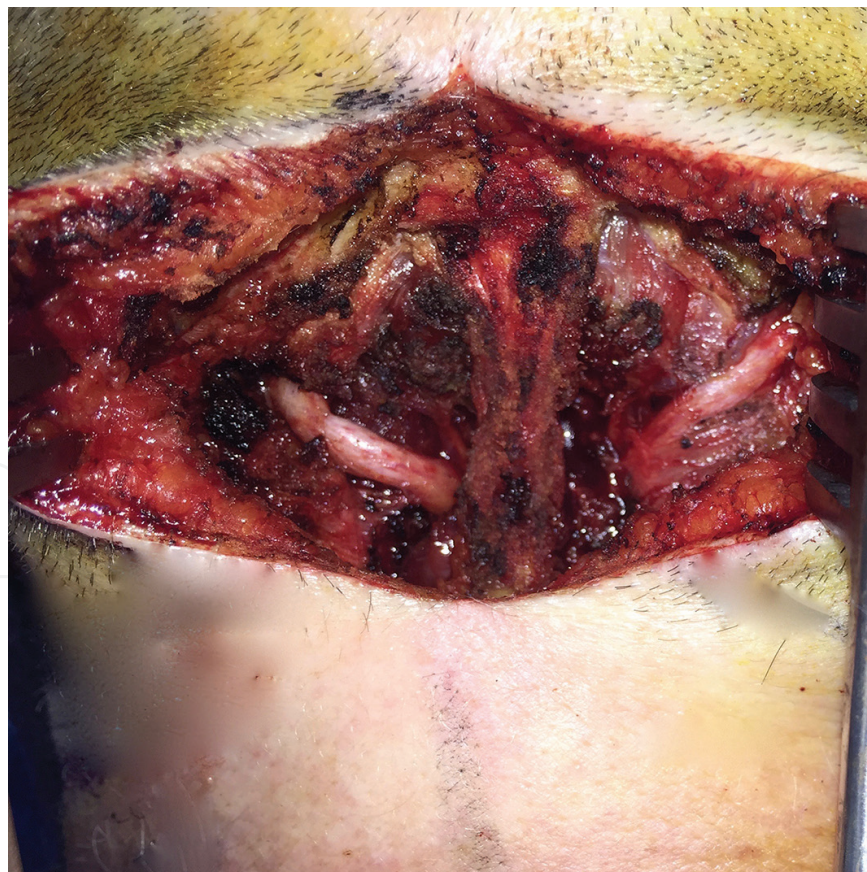

Figure 4. Intraoperative view of the greater occipital nerve (GON). The trapezius fascia has been opened proximally, and a minimal amount of the medial portion of the semispinalis muscle has been removed to expose the body of the nerve. In this patient, the right greater occipital nerve (GON) looks flatter and more compressed than the left.

4.4. Rhinogenic triggers

In patients with weather-related migraines, and incomplete results from Botox injections, septonasal triggers should be considered. This pain is often described as behind the eye and can be unmasked after other primary sites are relieved either with surgery, BOTOX, or nerve blocks. A CT scan and nasal endoscopy are required to confirm diagnoses and will show any contact points and any complicated nasal pathology. Intranasal injection or spray of lidocaine may be used to further enhance the diagnostic power. At the time of surgery, local lidocaine and epinephrine are injected into the nose. A routine open or endoscopic septoplasty is used to address any contact points. In the cases of concha bullosa or significant enlargement of turbinates, full or partial resection of the turbinates is required. In cases of superior turbinate contact, outfracture or shaving is done and should only be performed by an expert plastic surgeon or ear-nose-throat surgeon experienced in this area.

Complications of this procedure include temporary or long-term nasal dryness. Synechiae and sinus infections are rare. Cerebrospinal fluid (CSF) leaks or more serious complications have not been reported in plastic surgery literature.

Routine activity within 1 week, and heavy activity within 3 weeks, is routine for all migraine surgery patients. Paresthesia and itching should improve with frequent massage and use of special brushes.

5. Conclusions

Select migraine headache patients, occipital neuralgia patients, and NDPH (New Daily Persistent Headache) patients can be successfully treated by surgical intervention. However, they should also be simultaneously seen by a neurologist, who can manage medications and rule out other diagnoses apart from migraine headache. Typically, these patients also have failed multiple classes of traditional conservative treatments. Careful documentation, such as patient migraine diaries, should be kept to track changes. Upon confirmation of migraine headache, various trigger sites can be identified by a constellation of symptoms and chemical denervation. Patients with severe anxiety and depression, medication overuse, and narcotic use respond poorly to surgery. Therefore, maximizing medical treatment by neurology following surgery is essential. Surgical decompression for treatment of migraine pain has proven significantly useful by multiple studies, both controlled prospective and retrospective [7].

Currently, surgical intervention becomes a viable option after complete exhaustion of other treatment methods. Rates of complication are low and potential benefits are life-changing. This small group of patients who do not respond to the available preventative and abortive treatments are often left with a very low quality of life. As a result, surgery is often the last resort for an effective treatment and potential permanent relief from their symptoms. In the future, further multicenter randomized prospective trials can elucidate which patients may be better candidates and improve the response rate.

Author details

Michael Chung, Kyle Sanniec, Xingchen Li and Bardia Amirlak*

*Address all correspondence to: bardiaamirlak@gmail.com

UT Southwestern Department of Plastic Surgery, Dallas, TX, USA

References

- [1] Stewart, W.F., et al., *Cumulative lifetime migraine incidence in women and men*. *Cephalalgia*, 2008. **28**(11): pp. 1170–8.
- [2] Lipton, R.B., et al., *Migraine prevalence, disease burden, and the need for preventive therapy*. *Neurology*, 2007. **68**(5): pp. 343–9.
- [3] Dodick, D.W., *Triptan nonresponder studies: implications for clinical practice*. *Headache*, 2005. **45**(2): pp. 156–62.
- [4] Janis, J.E., et al., *A review of current evidence in the surgical treatment of migraine headaches*. *Plast Reconstr Surg*, 2014. **134**(4 Suppl 2): pp. 131S–41S.
- [5] Singh, M., et al., *Causal relation between nerve compression and migraine symptoms and the therapeutic role of surgical decompression*. *Plast Reconstr Surg Glob Open*, 2015. **3**(5): p. e395.
- [6] Dirnberger, F. and K. Becker, *Surgical treatment of migraine headaches by corrugator muscle resection*. *Plast Reconstr Surg*, 2004. **114**(3): pp. 652–7; discussion 658–9.
- [7] Ducic, I., J.M. Felder, 3rd, and S.A. Fantus, *A systematic review of peripheral nerve interventional treatments for chronic headaches*. *Ann Plast Surg*, 2014. **72**(4): pp. 439–45.
- [8] Guyuron, B., et al., *Comprehensive surgical treatment of migraine headaches*. *Plast Reconstr Surg*, 2005. **115**(1): pp. 1–9.
- [9] Guyuron, B., et al., *Five-year outcome of surgical treatment of migraine headaches*. *Plast Reconstr Surg*, 2011. **127**(2): pp. 603–8.
- [10] Janis, J.E., A. Dhanik, and J.H. Howard, *Validation of the peripheral trigger point theory of migraine headaches: single-surgeon experience using botulinum toxin and surgical decompression*. *Plast Reconstr Surg*, 2011. **128**(1): pp. 123–31.
- [11] Poggi, J.T., B.E. Grizzell, and S.D. Helmer, *Confirmation of surgical decompression to relieve migraine headaches*. *Plast Reconstr Surg*, 2008. **122**(1): pp. 115–22; discussion 123–4.
- [12] Goetz, C.G., *Textbook of clinical neurology*. 3rd ed. 2007, Philadelphia: Saunders Elsevier. xvii, 1364 p.
- [13] Moskowitz, M.A., *The neurobiology of vascular head pain*. *Ann Neurol*, 1984. **16**(2): pp. 157–68.

- [14] Welch, K.M., *Contemporary concepts of migraine pathogenesis*. Neurology, 2003. **61**(8 Suppl 4): p. S2–8.
- [15] Guyuron, B., et al., *Electron microscopic and proteomic comparison of terminal branches of the trigeminal nerve in patients with and without migraine headaches*. Plast Reconstr Surg, 2014. **134**(5): pp. 796e–805e.
- [16] Guyuron, B., et al., *Corrugator supercilii muscle resection and migraine headaches*. Plast Reconstr Surg, 2000. **106**(2): pp. 429–34; discussion 435–7.
- [17] Becker, D. and B. Amirlak, *Beyond beauty: onabotulinumtoxinA (Botox(R)) and the management of migraine headaches*. Anesth Pain Med, 2012. **2**(1): pp. 5–11.
- [18] Binder, W.J., et al., *Botulinum toxin type A (BOTOX) for treatment of migraine headaches: an open-label study*. Otolaryngol Head Neck Surg, 2000. **123**(6): pp. 669–76.
- [19] Whitcup, S.M., et al., *Development of onabotulinumtoxinA for chronic migraine*. Ann N Y Acad Sci, 2014. **1329**: pp. 67–80.
- [20] Dandy, W.E., *Treatment of hemicrania (migraine) by removal of the inferior cervical and first thoracic sympathetic ganglion*. Johns Hopkins Univ Bull, 1931. **48**: pp. 357–361.
- [21] Gardner, W.J., A. Stowell, and R. Dutlinger, *Resection of the greater superficial petrosal nerve in the treatment of unilateral headache*. J Neurosurg, 1947. **4**(2): pp. 105–14.
- [22] Murillo, C.A., *Resection of the temporal neurovascular bundle for control of migraine headache*. Headache, 1968. **8**(3): pp. 112–7.
- [23] Murphy, J.P., *Occipital neurectomy in the treatment of headache. Results in 30 cases*. Md State Med J, 1969. **18**(6): pp. 62–6.
- [24] Guyuron, B., T. Tucker, and J. Davis, *Surgical treatment of migraine headaches*. Plast Reconstr Surg, 2002. **109**(7): pp. 2183–9.
- [25] Guyuron, B., et al., *A placebo-controlled surgical trial of the treatment of migraine headaches*. Plast Reconstr Surg, 2009. **124**(2): pp. 461–8.
- [26] Adenuga, P., et al., *Impact of preoperative narcotic use on outcomes in migraine surgery*. Plast Reconstr Surg, 2014. **134**(1): pp. 113–9.
- [27] Gfrerer, L., et al., *Nonendoscopic deactivation of nerve triggers in migraine headache patients: surgical technique and outcomes*. Plast Reconstr Surg, 2014. **134**(4): pp. 771–8.
- [28] Liu, M.T., H. Chim, and B. Guyuron, *Outcome comparison of endoscopic and transpalpebral decompression for treatment of frontal migraine headaches*. Plast Reconstr Surg, 2012. **129**(5): pp. 1113–9.
- [29] Oturai, A.B., et al., *Neurosurgery for trigeminal neuralgia: comparison of alcohol block, neurectomy, and radiofrequency coagulation*. Clin J Pain, 1996. **12**(4): pp. 311–5.
- [30] Taha, J.M. and J.M. Tew, Jr., *Comparison of surgical treatments for trigeminal neuralgia: reevaluation of radiofrequency rhizotomy*. Neurosurgery, 1996. **38**(5): pp. 865–71.

- [31] Mathew, P.G., *A critical evaluation of migraine trigger site deactivation surgery*. Headache, 2014. **54**(1): pp. 142–52.
- [32] Guyuron, B., *A discussion of "critical evaluation of migraine trigger site decompression surgery"*. Headache, 2014. **54**(6): pp. 1065–72.
- [33] Guyuron, B., D. Harvey, and D. Reed, *A prospective randomized outcomes comparison of two temple migraine trigger site deactivation techniques*. Plast Reconstr Surg, 2015. **136**(1): pp. 159–65.
- [34] Amirlak, B., et al., *The Anatomical Regional Targeted (ART) BOTOX injection technique. A new injection paradigm for the treatment of chronic headaches and migraines*. Plast Reconstr Surg Glob Open, In Press 2016.
- [35] Liu, M.T., B.S. Armijo, and B. Guyuron, *A comparison of outcome of surgical treatment of migraine headaches using a constellation of symptoms versus botulinum toxin type A to identify the trigger sites*. Plast Reconstr Surg, 2012. **129**(2): pp. 413–9.
- [36] Guyuron B, B.D., *Plastic Surgery: Indications and Practice*. Surgical management of migraine headaches, ed. T.T. Guyuron B, Davis J. 2008: Saunders: Elsevier, Health Sciences Division.
- [37] Totonchi, A., N. Pashmini, and B. Guyuron, *The zygomaticotemporal branch of the trigeminal nerve: an anatomical study*. Plast Reconstr Surg, 2005. **115**(1): pp. 273–7.
- [38] Sanniec, K., E. Borsting, and B. Amirlak, *Decompression-avulsion of the auriculotemporal nerve for treatment of migraines and chronic headaches*. Plast Reconstr Surg Glob Open, 2016. **4**(4): p. e678.
- [39] Lee, M., et al., *The role of the third occipital nerve in surgical treatment of occipital migraine headaches*. J Plast Reconstr Aesthet Surg, 2013. **66**(10): pp. 1335–9.