

We are IntechOpen, the world's leading publisher of Open Access books Built by scientists, for scientists

6,900

Open access books available

185,000

International authors and editors

200M

Downloads

Our authors are among the

154

Countries delivered to

TOP 1%

most cited scientists

12.2%

Contributors from top 500 universities



WEB OF SCIENCE™

Selection of our books indexed in the Book Citation Index
in Web of Science™ Core Collection (BKCI)

Interested in publishing with us?
Contact book.department@intechopen.com

Numbers displayed above are based on latest data collected.
For more information visit www.intechopen.com



Endoluminal Ultrasonography of the Rectum and the Anal Canal

Lidia Ciobanu and Radu Badea

Additional information is available at the end of the chapter

<http://dx.doi.org/10.5772/66081>

Abstract

Ultrasonography of the anal canal, the rectum and the surrounding tissues using intraluminal transducers with transanal/rectal imaging provides high-resolution imaging with clearly distinguishable tissue-dependent echo signals. Endorectal ultrasonography depicts rectal wall layers and adjuvant structures with a high degree of precision. Anal endosonography is carried out to examine the sphincter muscles and the pelvic floor.

Detailed ultrasonographic anatomy is presented. Specific information is noted regarding the use of radial and linear scanning. The Doppler techniques depict the vascularization. Contrast-enhanced harmonic imaging and elastography are discussed in an integrative manner regarding their role in differentiating malignant from benign ano-rectal masses or lymph nodes. Three-dimensional endorectal ultrasonography provides superior visual images of tumor volume and the spatial relationships of tumor to surrounding anatomical structures.

Endorectal ultrasonography technique accurately measures the size, circumference and distance of the tumor from various anatomic landmarks. It is capable of examining the anal sphincters for tumor infiltration, allowing the surgeon to decide whether a sphincter-sparing resection might be indicated. It can depict the relationship of tumor to the pelvic peritoneal reflection, to determine whether local excision is possible.

Endorectal ultrasonography in benign pathology is emphasized.

Brief conclusions are given at the end of the chapter.

Keywords: endoluminal ultrasonography, rectum, anal canal, endorectal ultrasonography, anorectal cancer, rectal benign pathology

1. Introduction

The anorectal pathology is very frequent in clinical practice, the patients being addressed for anal fistula, fecal incontinence, hemorrhoidal disease, anal pain, anal fissure, rectocele, rectal prolapse, and rectal tumor. After the clinical and digital rectal exam, the ultrasonography represents the next step in the diagnostic procedure. To obtain reliable details, the transducers have to be as close to the organ of interest as possible. The conventional ultrasound of this region has several limitations considering the position of these organs in the pelvic cavity. The first ultrasound images of the bowel wall using an ultrasound transducer inside a body cavity were obtained in 1950 by Wild [1]. Nowadays the technical improvements of endorectal sonography provide very precise details of rectal wall layers and adjuvant structures, including the pelvic organs. There are two main approaches with corresponding equipment:

- Anorectal ultrasonography performed by clinicians and radiologists
- Endoscopic ultrasound using flexible endoscope-mounted systems performed by gastroenterologists

Understanding the anatomy of the anorectal region and the main clinical indications remain the cornerstone for this examination, independent of the approach and equipment.

2. Anatomy of the anorectal region

The rectum is the final part of the large intestine, which is about 12–14 cm long and has a diameter of 2–6 cm, related to the content [2]. It begins at the rectosigmoid junction, at the level of the third sacral vertebra and runs inferiorly along the curve of the sacrum to pass through the pelvic diaphragm, where it is continued with the anal canal [3]. The rectum is surrounded by fatty tissue that contains blood vessels, nerves, lymphatics, and small lymph nodes [3]. It is delineated posterior by sacro-coccygeal bone structure, inferior by the insertion of the levator ani muscles and superior by the peritoneum [2]. The superior one-third is covered anteriorly and laterally by the pelvic peritoneum. The middle one-third is covered with peritoneum only anteriorly, which curves onto the bladder in the male and onto the uterus in the female. The lower one-third lacks of peritoneum and is related anteriorly to the bladder base, ureters, seminal vesicles, and prostate in the male and to the lower uterus, cervix, and vagina in the female [3].

The internal sphincter, the longitudinal muscle layer, and the external sphincter surround the anal canal. It is delineated posterior by the levator ani muscles, laterally by the ischioanal fossa, and anterior by the apex of the prostate and the membranous urethra in male and posterior wall of the vagina in female [2, 3].

The sphincter anal complex is formed by the muscles that represent the continuation of circular layer of the muscularis propria of the rectum, the striated external anal sphincter, and puborectal muscles, which belong to the levator ani muscles [4]. The lowest point of the external anal

sphincter represents the upper anal margin; it is called the anal verge and is the principal landmark for rectal measurements [4]. The pectinate (dentate) line is located 1.5–2 cm upwards from the anus and separates the canal anal into the anatomical part located below the line and the surgical part located above the line [4]. The surgical anal canal extends from the pectinate line to the level of the puborectalis sling, which corresponds to the anorectal junction. The pectinate line is not detectable on radiological studies, representing the endoscopic view of the demarcation between the squamous epithelium (anoderm) and the columnar epithelium [4]. The anoderm is directly attached to the internal anal sphincter [4].

The mesorectum is represented by the connective tissue, located between the middle part of the rectum and the upper surface of the levator ani. The mesorectum contains lymph nodes and neurovascular bundles, fat and fibrous tissue. It is limited posterolaterally by the pelvic visceral fascia and ventrally by an upper continuation of the rectogenital membrane (Denonvilliers' fascia). In females, this dense band forms the rectovaginal septum and in males, the rectoprostatic fascia. Laterally a tiny structure is detected, known as mesorectal or perirectal fascia [4].

The rectal vascularization is provided by the rectal arteries (superior rectal artery from the inferior mesenteric artery, middle rectal artery from the internal iliac artery, and inferior rectal artery from the internal pudendal artery). The rectal venous drainage is realized by the superior rectal vein (that drains into the inferior mesenteric vein) and by the middle and inferior rectal veins (that drains into the iliac veins) [2].

The lymphatic drainage is realized into three circuits:

1. superior station—drains the lymph vessels corresponding to the inferior mesenteric vessels and superior rectal vessels. This circuit has intermediate lymph nodes localized posteriorly and laterally to the rectum.
2. middle station—drains the lymph vessels into the iliac lymph nodes.
3. inferior station—drains the lymph vessels into the superficial inguinal lymph nodes [2].

Ultrasonography of the anal canal, the rectum, and the surrounding tissues using intraluminal transducers with transanal/rectal imaging provides high-resolution imaging with clearly distinguishable tissue-dependent echo signals. Endorectal sonography is able to depict the rectal wall layers and the adjuvant structures, including the pelvic organs with a high degree of precision. Anal endosonography is carried out to examine the sphincter muscles and the pelvic floor.

3. Techniques and procedures used in endorectal ultrasonography

3.1. Conventional 2D ultrasound examination

The endoluminal ultrasonography is highly effective in most cases of anorectal pathology, as it provides accurate evaluation of rectal, perirectal, anal, and perianal pathology. It might be

performed without preparation, but an enema significantly improves the image quality, especially in the oncological patients with stool residues [5]. The examination is carried out in the left recumbent position. In patients with sphincter insufficiency, the knee-elbow position might be preferred [4].

The endoluminal ultrasound examination is mandatorily done after digital rectal exam and preferred after a proctoscopy examination. In case of an anal stricture, an inserted finger can appreciate the possible passage of the probe.

A mechanical or a biplanar transducer with a frequency of 10 MHz or higher is most frequently used [2, 4, 5]. Higher frequencies provide better resolution of the rectal wall and sphincter complex, while lower ones depict better, the components of the mesorectum [4].

A condom containing gel is placed over the probe and a thin layer of water-soluble lubricant is placed on the exterior of the condom [3]. The transducer is inserted in a blind gentle manner and the patient is informed about the potential discomfort or pain during the examination [2].

Some authors advice using a 3D 16 MHz probe for the spatial analysis of both the rectum and the surrounding tissues [6].

By convention, the transducer is placed to provide the following image: the anterior aspect of the anal canal will be at 12 o'clock on the screen, right lateral will be at 9 o'clock, left lateral will be at 3 o'clock and posterior will be at 6 o'clock [3]. The depiction of all layers is possible for the whole circumference of the anal canal. At the origin of the anal canal, the "U" shape of the puborectalis sling is the main landmark and must be always identified [3].

Five hypoechoic and hyperechoic layers are depicted corresponding to the anal canal wall [7, 8]. These five identified layers, from inner to outer are:

- the first hyperechoic layer corresponds to the interface between the transducer and the anal mucosal surface,
- the second hypoechoic layer is represented by the subepithelial tissues, being moderately reflective. The mucosa and the dental line are not identified by endoluminal ultrasound,
- the third hypoechoic layer corresponds to the internal sphincter, which is not completely symmetric, either in thickness or termination. It is continued superiorly with the circular muscle of the rectum. In elderly, this layer is inhomogeneous and more echoic [8],
- the fourth hyperechoic layer represents the longitudinal muscle, without constant thickness along the entire anal canal. The increased fibrous stroma is responsible for the echoic aspect of this smooth muscle. In the inter-sphincterian space, the longitudinal muscle and the striated muscles fibers from the levator ani forms "conjoined longitudinal layer" [9],
- the fifth mixed echoic layer corresponds to the external anal sphincter; it has three parts [10]: (1) – the deep part contains the puborectalis muscle, (2) the superficial part has a broad attachment to the underside of the coccyx via the anococcygeal ligament. (3) the subcutaneous part lies below the internal sphincter.

In the axial plane, the upper part of the anal canal corresponds to the puborectalis muscle sling, the deep part of the external anal sphincter, and the complete ring of the internal anal sphincter. The middle part of the anal canal is formed by the superficial part of the external anal sphincter, the conjoined longitudinal layer, the complete ring of the internal anal sphincter, and the transverse perineal muscles. The lower part of the anal canal contains the subcutaneous components of the external anal sphincter [7].

For the rectal examination, especially in oncological patients, special water-filled balloons might be used (**Figure 1**). These balloons filled with about 90 ml of water compress the lesions and remove air from the rectum [5].

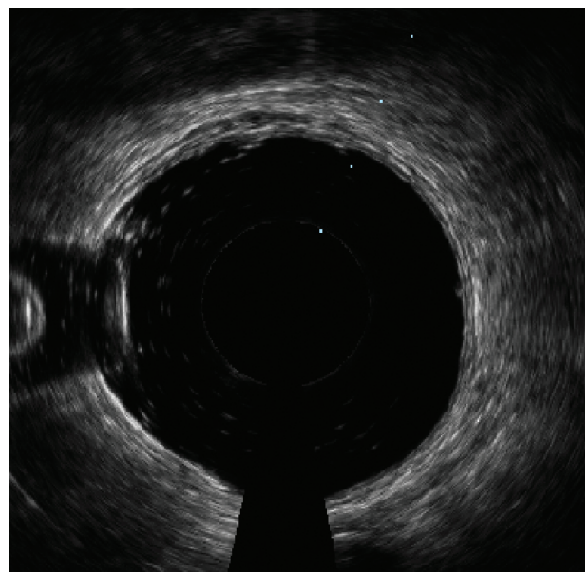


Figure 1. Endocavitary rectal examination – special water filled balloon.

The rectal wall consists of five layers surrounded by perirectal fat or serosa, measuring 2–3 mm. The five layers represent (**Figure 2**) [3]:

- the first hyperechoic layer depicts the interface between the balloon/transducer and the mucosal surface
- the second hypoechoic layer corresponds to the mucosa and the muscularis mucosa,
- the third hyperechoic layer represents the submucosa the fourth hypoechoic layer identifies the muscularis propria
- the fifth hyperechoic layer corresponds to the serosa or to the interface with the mesorectum. The mesorectum has an inhomogeneous pattern due to mixed anatomical structures: blood vessels, nerves, and lymphatic vessels.

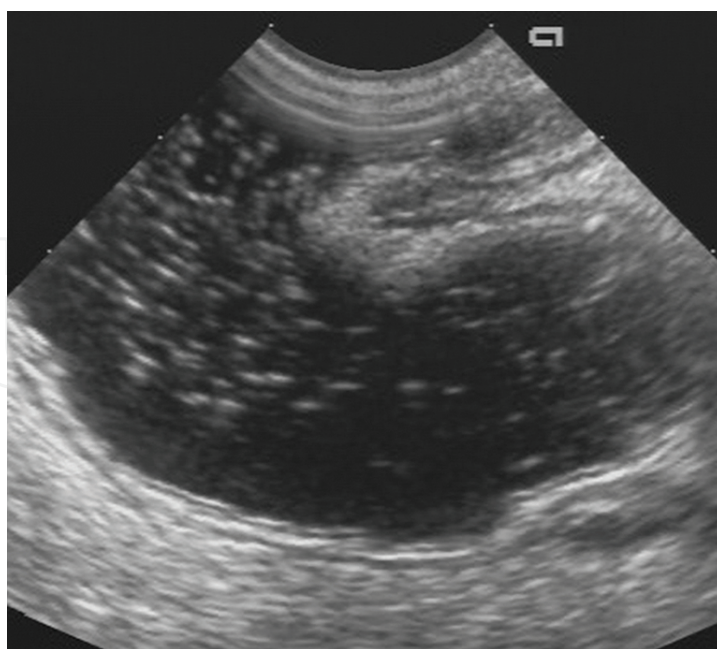


Figure 2. The rectal wall consists of five layers surrounded by perirectal fat or serosa.

Depending on the position of the probe, the surrounding muscles are identified. The external anal sphincter is detected in the lower third of the rectum. Slightly above, it is replaced by the fibers corresponding to the levator ani muscles, that form puborectalis muscle sling. Between the puborectalis muscle sling and caudally located external sphincter, there is an intersphincterian plane filled with the lowest, tapered part of the mesorectum [11]. This plane is important for surgery and for the staging of the anal cancer [11].

Endorectal ultrasound provides an accurate visualization of all pelvic organs adjacent to the rectum: the bladder, the intestinal loops, the seminal vesicles, and prostate in males, and the uterus, cervix, vagina, and urethra in females [3].

The endoscopic approach is nowadays frequently used by the gastroenterologist to assess the anorectal region by ultrasound. Initially, the standard radial endoscopic ultrasound scan was used. The rigid endoscopic ultrasound scan has been used since the early 1980s. Technical improvements provided different types of linear as well as radial scanning devices with frequency varying from 5 MHz to 15 MHz [12]. The echoendoscope is inserted and advanced beyond the lesion, under direct visualization to the rectosigmoid junction. The balloon is slowly inflated and the lumen is filled with water. From this position in the middle of the lumen, the scope is to achieve perpendicular imaging of the rectal wall layers. Once the bladder is identified, the image is mechanically rotated so the bladder is located at 12 o'clock position. Then the instrument is withdrawn slowly, with the transducer kept at the middle of the rectum. No torching of the instrument is recommended, as this causes tangential imaging and possible inaccurate assessment of the depth of tumor penetration. In males, upon withdrawing the probe at 12 o'clock position, the seminal vesicles and the prostate are displayed. In females, this manoeuvre brings in view the uterus and then the vagina, with a hyperechoic band in the center that represents air [13].

3.2. Contrast endoluminal ultrasonography of the rectum and the anal canal

Different ultrasound techniques improve daily practice in benign and malignant pathology. Local contrast agents facilitate the depiction of fistulas through direct administration (Figure 3). Intravenous contrast agents define vascular pattern for tumor pathology related to anorectal region or prostate (Figure 4).

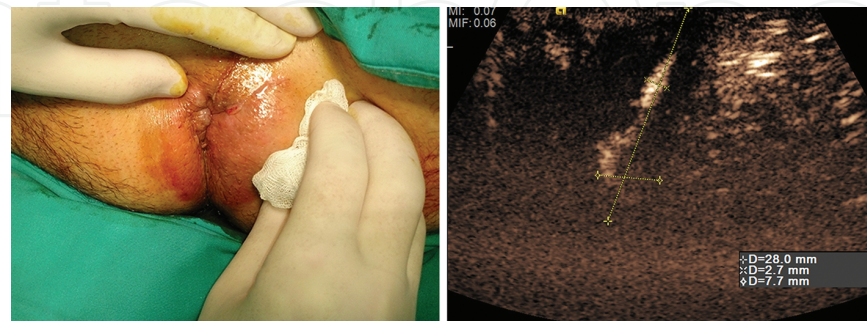


Figure 3. (a) Anal fistula—physical exam. (b) Local contrast agent (Sonovue in this particular case) was administered through the external end of the fistula for better delineation of the size and fistula tract.

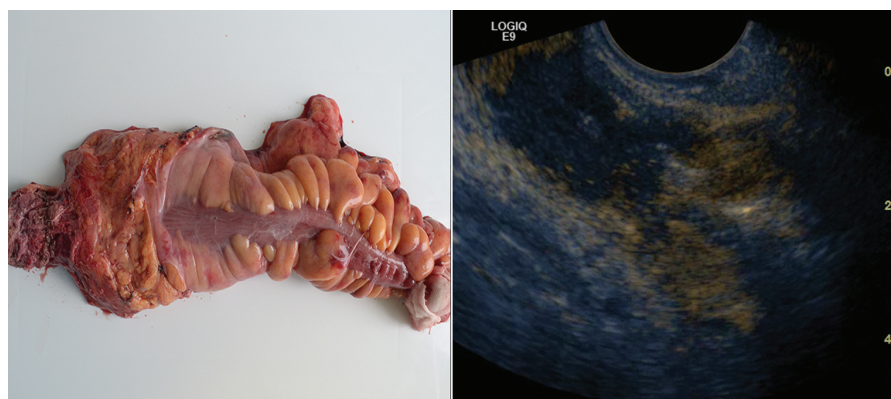

Figure 4. (a) Anorectal tumor—surgically removed. (b) Intravenous contrast agents (Sonovue) was administered. In the venous phase, the contrast agent was washed-out from the tumor (becoming hypoechoic), permitting a better delineation of the tumor from the adjacent organs.

Hydrogen peroxide was investigated as an image-enhancing contrast agent for improving the depiction and the characterization of the fistulas during endoanal ultrasonography [14]. After a conventional endoanal ultrasound is performed, external perianal openings are cannulated and approximately 1 ml of peroxide is administered. After reinsertion of the endoprobe, the entire course of the echogenic fistula, including its relation to the internal and external sphincters and the levator ani muscle are depicted in real time, which facilitates surgical planning [14].

The use of contrast agents within the bloodstream gained more and more applications in the last few years, as it enables the detection of very slow blood flow in vessels measuring as little as 40 μm . Contrast enhanced ultrasound (CEUS) provides valuable information regarding the

characterization of a circulatory bed and the evaluation of the neoangiogenesis process [15]. Quantitative parameters are determined during the passage of the contrast agents through a region of interest, mainly by analysis of the time-intensity curve parameters [15]. For rectal cancer, CEUS provides noninvasive biomarkers of tumor angiogenesis and might predict patient prognosis [16]. Contrast enhanced endorectal sonography increases the detection of prostate cancer and facilitates the target biopsies [17, 18].

3.3. Doppler ultrasonography

The Doppler ultrasonography provides information regarding the flow within large vessels. Doppler-guided hemorrhoidal ligation was introduced into clinical practice 20 years ago (**Figure 5**) [19]. Doppler-guided hemorrhoidal dearterialization is a safe and effective method to treat grades II–IV hemorrhoidal diseases, especially in those with previous anal surgeries or previous alterations of fecal continence, when an additional procedure might represent a risk of definitive incontinence [19].

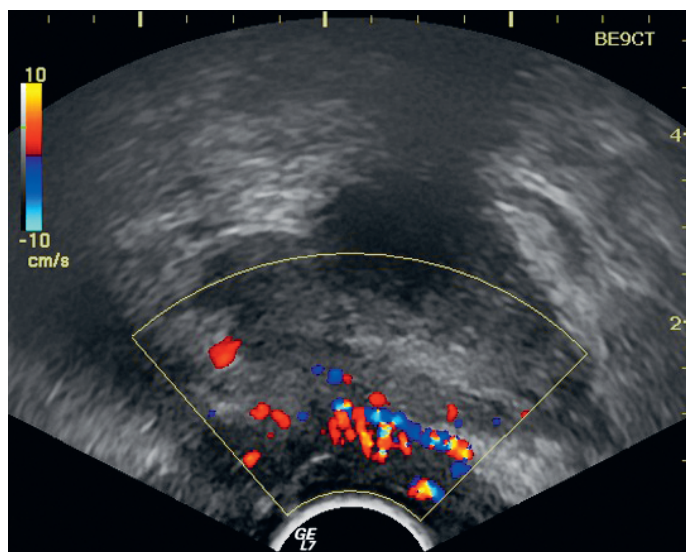


Figure 5. Doppler ultrasonography provides information regarding the flow within large vessels in the anorectal region.

3.4. Transanal real-time elastography

The transanal real-time elastography in rectal cancer ranges is between 80stography was demonstrated to yield valuable information regarding elastic properties of the anal sphincter, especially in patients with fecal incontinence. A pathological elastogram is considered, when predominantly hard elements are detected. This technique was investigated in different pathologies, anorectal surgery in irradiated and non-irradiated individuals and Crohn's disease. Based on studies conducted by Allgayer et al. [20, 21] the transanal real-time elastography with quantitation of sphincter elastic properties yields no further diagnostic and prognostic information compared to conventional endosonography.

3.5. Three-dimensional ultrasound

The three-dimensional ultrasound is provided from the synthesis of a high number of parallel transaxial two-dimensional images [3]. The image can be rotated, tilted, and sliced to allow the physician to analyze different section parameters, different angles and to assess accurately distances, areas, angles, and volumes [3]. Three-dimensional endorectal ultrasonography is useful for assessing the depth of submucosal invasion in early rectal cancer and for selecting therapeutic options [22].

4. Endorectal ultrasonography examination for diagnosis and staging of rectal and anal tumors

The management of patients with anorectal neoplasm requires specific information regarding:

- tumor spread (T features),
- detailed evaluation of mesorectal fascia,
- extramural venous invasion,
- lymph nodes involvement (N features),
- presence of distance metastasis (M features) [4].

The tumor-node-metastasis (TNM) system represents the standard of care for rectal and anal staging (**Table 1**) [23].

The ultrasound feature of rectal cancer is a hypoechoic lesion that disrupts the normal five-layer sonographic structures of the rectal wall. The distal border of the tumor must be precisely depicted in relation to the anterior peritoneal reflection (in males, the relation of the distal border of the tumor to the seminal vesicles and in females, to the cervix are determined) [24].

The ultrasound images relevant to T staging are:

- T_{is} corresponds to the first hypoechoic layer expended, but without the second hyperechoic layer involvement.
- T_1 invades the submucosa, but without muscularis propria involvement, it is detected in ultrasound when the second hyperechoic layer is stippled or broken in appearance, but generally intact.
- T_2 ultrasound appearance is depicted when the second hyperechoic layer is completely disrupted and the mass may extend into the second hypoechoic layer.
- T_3 corresponds to the perirectal fat or serosa invasion, the outer hyperechoic layer is disrupted.
- T_4 is easy diagnosed as the tumor is extended into neighboring organs [25].

	Anal carcinoma	Rectal carcinoma
T _x	Primary tumor cannot be assessed	Primary tumor cannot be assessed
T ₀	No evidence of primary tumor	No evidence of primary tumor
T _{is}	Carcinoma <i>in situ</i> , Bowen disease, high grade squamous intraepithelial lesion (HSIL), anal intraepithelial neoplasia II-III (AIN II-III)	Carcinoma <i>in situ</i> : intraepithelial or invasion of lamina propria
T ₁	Tumor 2 cm or less in the greatest dimension	Tumor invades submucosa
T ₂	Tumor more than 2 cm, but not more than 5 cm in the greatest dimension	Tumor invades muscularis propria
T ₃	Tumor more than 5 cm in the greatest dimension	Tumor invades subserosa or into non-peritonealized perirectal tissues
T ₄	Tumor of any size invades adjacent organ(s) (e.g., vagina, urethra, bladder)	Tumor perforates visceral peritoneum (T _{4a}) and/or directly invades other organs or structures (T _{4b})
N _x	Regional lymph node cannot be assessed	Regional lymph node cannot be assessed
N ₀	No regional lymph node metastasis	No regional lymph node metastasis
N ₁	Metastasis in the perirectal lymph nodes	Metastasis in 1 to 3 regional lymph nodes N _{1a} – Metastasis in 1 regional lymph node N _{1b} – Metastasis in 2–3 regional lymph nodes N _{1c} – Tumor deposit(s), i.e., satellites in the subserosa or in nonperitonealized pericolic or perirectal soft tissue without regional lymph node metastasis
N ₂	Metastasis in unilateral internal iliac and/or inguinal lymph nodes	Metastasis in 4 or more regional lymph nodes N _{2a} – metastasis in 4–6 regional lymph nodes N _{2b} – metastasis in more regional lymph nodes
N ₃	Metastasis in perirectal and inguinal lymph nodes and/or bilateral internal iliac and/or bilateral inguinal lymph nodes	
M ₀	No distal metastasis	No distal metastasis
M ₁	Distal metastasis	M _{1a} – metastasis confined to one organ M _{1b} – metastasis in more than one organ or the peritoneum

Table 1. TNM staging principle for the anal and rectal carcinoma according to the current classification of International Agency for Research on Cancer/World Health Organization [23].

The accuracy of T stage in rectal cancer ranges is between 80 and 95% [26, 27]. The T₂ tumors are frequently over-staged as T₃ tumors, because peritumoral inflammation cannot be accurately differentiated from desmoplastic reaction [28]. From the clinical point of view, this overstaging has no significant impact as T₂ tumors have the same prognosis as T₃ tumors with less than 1 mm spread [4] (**Figure 6**). The assessment of T₃ tumors is very important, especially the measurement of the depth of extramural spread in the mesorectal fat, since T₃ tumors with less

than 5mm mesorectal invasion have a 5-year survival rate of 85% and T₃ tumors with more than 5 mm mesorectal invasion have a 5-year survival rate of 54% [4, 29, 30]. Minimally invasive T₃ tumors present an invasion into the mesorectal fat less than 2 mm beyond the muscularis propria and advanced T₃ tumor is characterized by an invasion of more than 3 mm [24]. These measurements are difficult to be performed in lower anal canal tumors, on its anterior wall or in patients with a small amount of perirectal fat [4]. The endoscopic ultrasound sensitivity for T stage is highest for advanced disease (96.4% for T₃ and 95.4% for T₄) compared to early disease (87.8% for T₁ and 80.5% for T₂) [31].

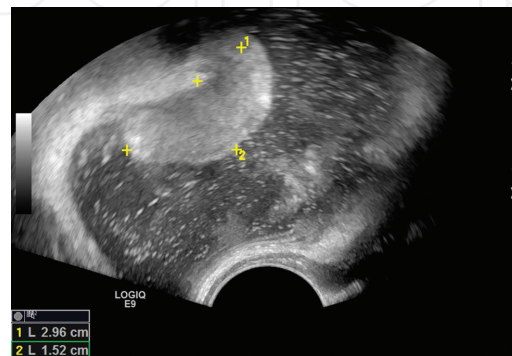


Figure 6. Rectal tumor staging. T₃ corresponds to the perirectal fat or serosa invasion, the outer hyperechoic layer is disrupted.

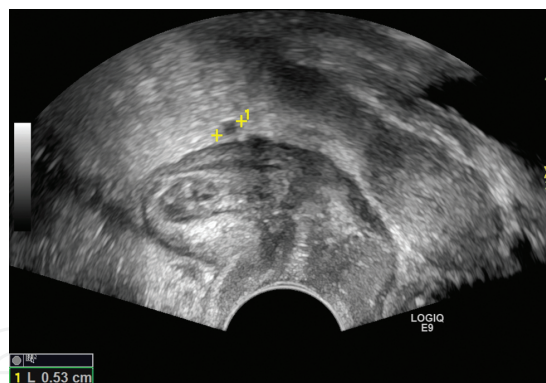


Figure 7. Rectal tumor staging T₃. A round hypoechoic lymph node, measuring 5 mm is detected.

The extramural venous invasion is detected by magnetic resonance imaging using a score proposed by Smith et al. [32] and represents an important prognostic factor since the detected venous invasion had a 3.7 times increased relative risk of metachronous metastatic disease [33].

The assessment of lymph node in patients with rectal cancer represents a debated issue. The ultrasound defines the size, border, shape, and echogenicity and enables tissue biopsy sampling. The features suggestive for malignancies are: enlarged nodes (≥ 1 cm in short axis), hypoechoic appearance, round shape, and smooth border (**Figures 7 and 8**) [24]. As the accuracy of the endocavitary ultrasound for N stage is moderate [31], fine needle aspiration

should be used when critical decision regarding neo-adjuvant chemotherapy is proposed [24].

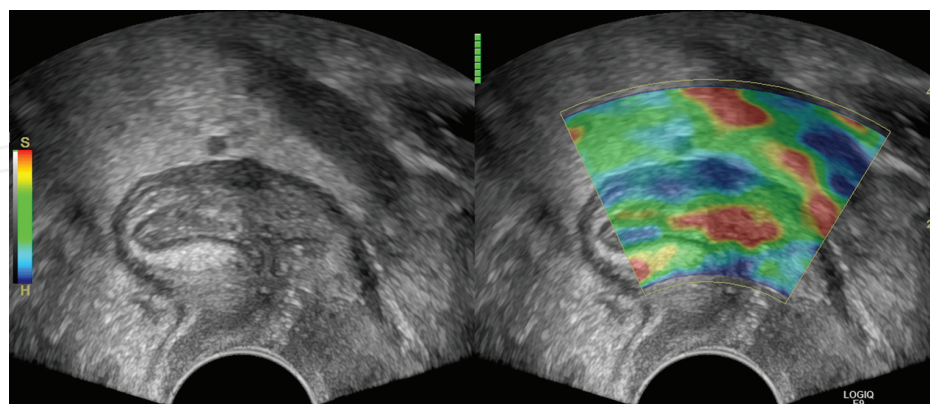


Figure 8. Rectal tumor. 2D ultrasound image and elastography. The rectal tumor is depicted stiffer than the tumor-free rectal wall and the perirectal fat tissue (colored in blue).

Different new ultrasound techniques has improved the diagnosis of the rectal and anal canal tumors.

3D-endocavitary ultrasound allows an accurate measurement of rectal tumors and identification of anatomical relationships, which assists the surgical planning procedure (**Figure 9**).

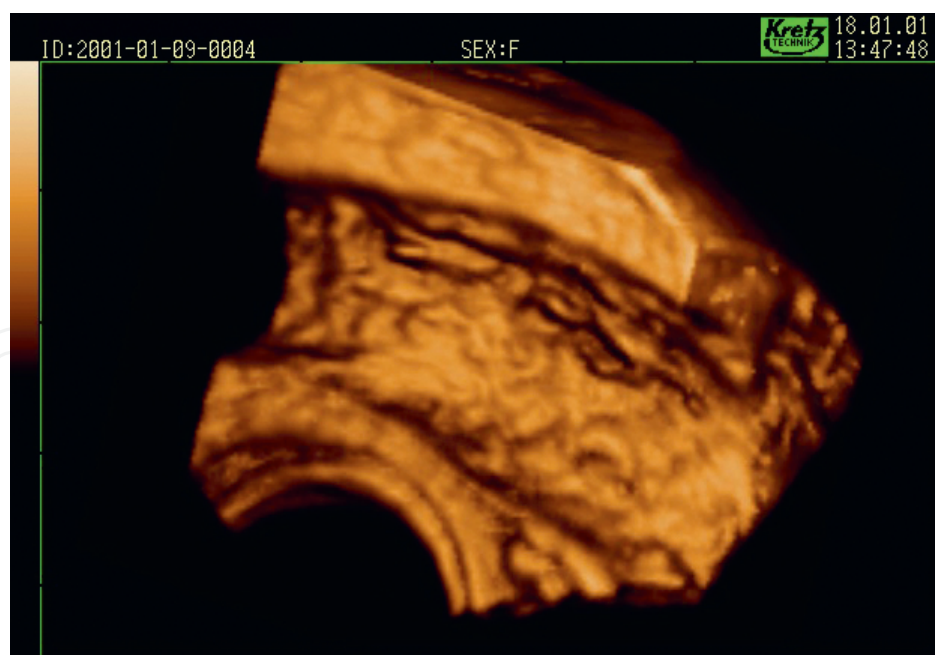


Figure 9. 3D endocavitary ultrasound offers a spatial assessment of the rectal tumor.

Contrast enhanced ultrasound depicts the vascular pattern for rectal lesions [15]. Quantitative parameters might be measured during the passage of the contrast agents through a region of

interest, mainly by analysis of the time-intensity curve parameters [15]. For rectal cancer, CEUS provides noninvasive biomarkers of the neoangiogenesis and might predict patient prognosis (Figure 10) [16].

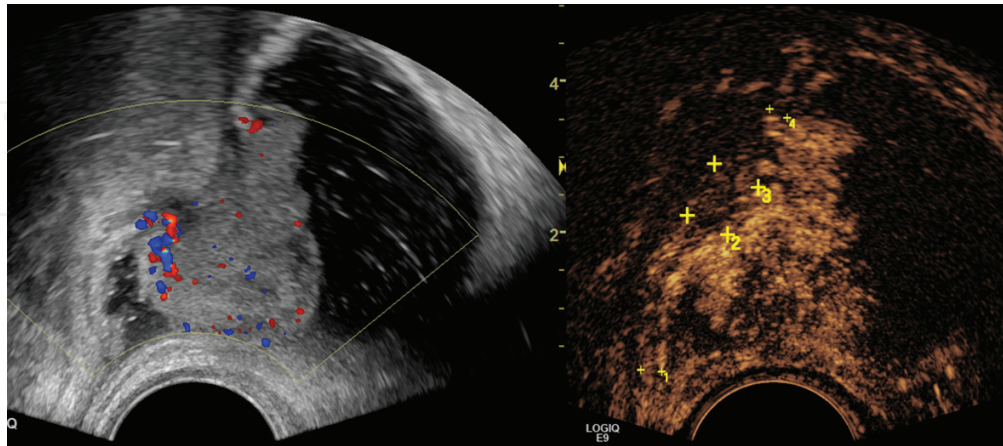


Figure 10. Contrast enhanced ultrasound (Sonovue administered intravenously) depicts the vascular pattern for rectal lesions.

The elastography become an “extension” of the clinical sense, strengthening and confirming the final diagnosis by its ability to measure the tissue elasticity. Different techniques are used: strain elastography imaging (SEI), shear wave imaging (acoustic radiation force impulse imaging (ARFI) and shear wave elasticity imaging (SWEI). ARFI and SWEI are quantitative methods. No data have been published so far concerning their use in the assessment of the rectal tumors. The rectal tumors are stiffer than the tumor-free rectal wall and the perirectal fat tissue. An optimal differentiation between benign and malignant lesions was obtained at a cut-off value of the mean strain ratio cut-off value of 1.25 [34] (Figures 11 and 12).

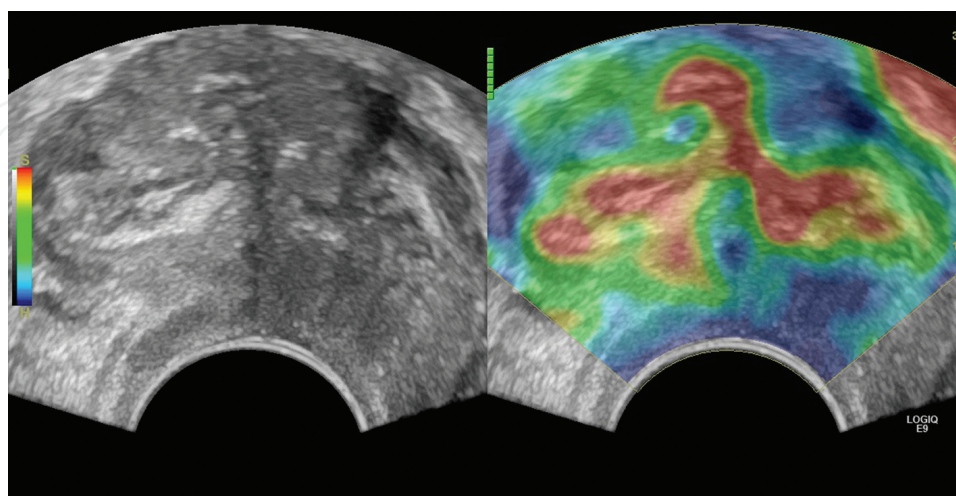


Figure 11. Rectal tumor. 2D ultrasound image and elastography. The rectal tumor is depicted stiffer than the tumor-free rectal wall and the perirectal fat tissue (colored in blue).

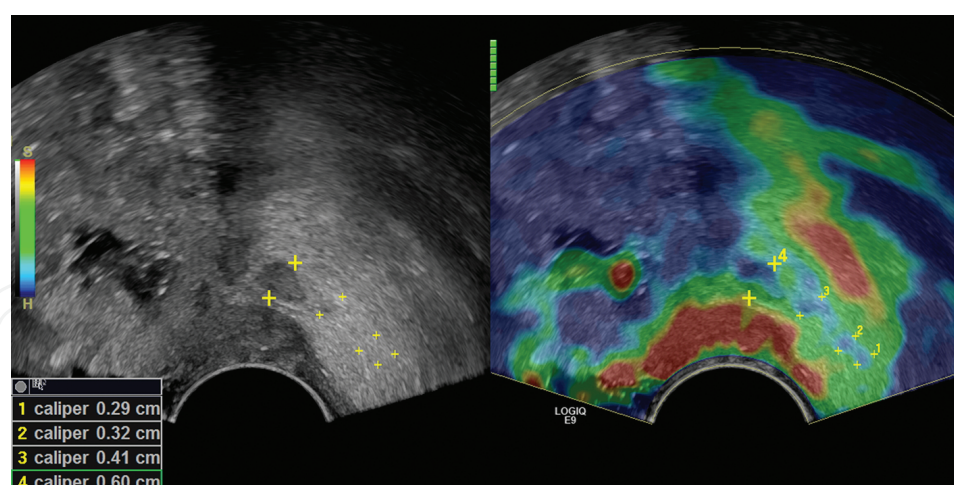


Figure 12. Lymph nodes involvement in a rectal tumor. 2D ultrasound image and elastography. The elastography identifies more malignant lymph nodes than detected by 2D ultrasound (stiffer than the tumor-free rectal wall and the perirectal fat tissue – colored in blue).

Preoperative neoadjuvant chemo-radiotherapy (N_{3-4} or lymph nodes involvement) is used to downstage rectal cancer in order to improve survival and to allow sphincter-preserving low anterior resection [12]. Considering the necrosis, inflammation, and fibrotic changes following neoadjuvant therapy, the assessment of tumor nodes through ultrasound might not be adequate. The T re-stage accuracy is 50% (**Figure 13**) [35–38]. The accuracy can be improved by depicting the intense and chaotic vasculature of residual tumor tissue through Doppler technique [39] or contrast-enhance ultrasound [40, 41].

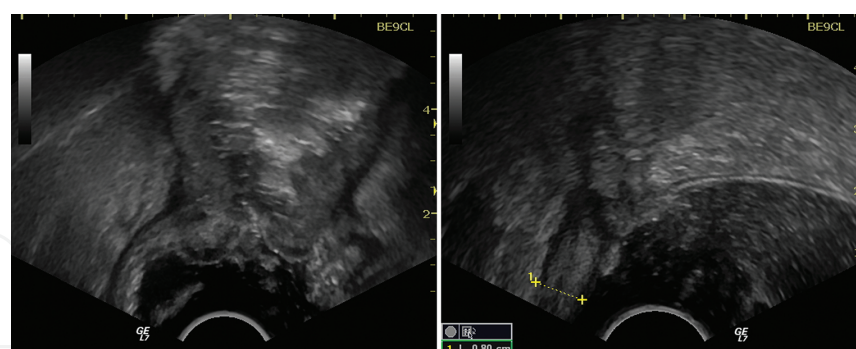


Figure 13. Rectal tumor. (a) In diagnosis the tumor was assessed as T3, invading the perirectal fat. (b) After neoadjuvant radiochemotherapy the tumor decreased in size (8 mm), but still invaded the perirectal fat.

Endoscopic ultrasonography of rectum can also be used for rectal cancer recurrence post-operatively with high accuracy [41, 42]. In some cases the ultrasound feature of tumor recurrence cannot be differentiate by post-surgery fibrosis or inflammation [24]. Obtaining biopsy samples through fine needle aspiration improves the detection of rectal recurrences. Also depiction of the vascularization through Doppler techniques or CEUS can considerably increase the specificity of transrectal ultrasound in differentiating tumor relapse from fibrosis

[39, 40, 43]. The endoscopic ultrasound is recommended for follow up after surgery at six months interval for two years [24]. The anastomotic sites might be revealed as cystic lesions with heterogeneous wall thickening and fine needle aspiration might detect mucin containing inflammatory cells in the absence of malignant cells [44].

5. Endorectal ultrasonography for benign pathology

5.1. Fecal incontinence

Patients with fecal incontinence frequently associate anal sphincter injury as a consequence of obstetrical trauma, anorectal surgery or accidental injury [45]. Endoanal ultrasonography can accurately depict the anal sphincter complex and surrounding perirectal tissues [45]. Anal sphincter tears are depicted as a discontinuity of the hypoechoic structure corresponding to the internal anal sphincter or of the more heterogeneous external anal sphincter [46]. Obstetric injury is located anterior and frequently involves both sphincters [46]. The accuracy of endoanal ultrasound for sphincters disruption is very high: 95% [47, 48].

5.2. Anal fistulae and abscesses

The main causes for anal fistulae and abscesses are: Crohn's disease, post-operative infection, radiotherapy. The Parks classification of perianal fistulae depicts four types: inter, trans, extra and suprasphincterian [49], according to their extension to the external anal sphincter and to the puborectalis muscles. The ultrasound appearance of the fistula is a hypoechoic linear structure with possible hyperechoic reflections (air) between anal canal or rectum or vagina. The use of hydrogen peroxide-enhanced anal endosonography provides better depiction of fistula and its relation to the internal and external sphincters and the levator ani muscles [50]. Alternative to hydrogen peroxide are represented by the new ultrasound contrast agents: Levovist or SonoVue [51]. The sonographic appearance of the abscess is a mass either anechoic or hypoechoic (with internal echoes corresponding to tissue debris) [52]. This technique is recommended for fistula diagnosis and monitoring in patients with Crohn's disease. The use of contrast agents and 3D techniques provides accurate assessment of complex fistula mapping before planning medical or surgery treatment. Also, it is useful for puncturing the abscesses in the operating room using an echoendoscopic approach or a surgery technique [52].

6. Conclusions

Endoluminal ultrasonography of the rectum and the anal canal is a valuable method for the assessment and staging of rectal and anal canal tumors. It is also frequently used for perianal fistulae mapping, anal sphincter tears depiction in patients with fecal incontinence and for abscesses identification and puncturing. Different ultrasound techniques provide morphological, functional and vascular pattern accurate assessment of rectal tumors before surgery, after radiotherapy/chemotherapy, and after surgery (for the detection of relapses).

Author details

Lidia Ciobanu* and Radu Badea

*Address all correspondence to: lidia.ciobanu@umfcluj.ro

University of Medicine and Pharmacy Iuliu Hațieganu, Regional Institute of Gastroenterology and Hepatology, Cluj-Napoca, Romania

References

- [1] Wild JJ. The use of ultrasonic pulses for the measurement of biologic tissues and the detection of tissue density changes. *Surgery* 1950;27:183–188.
- [2] Badea R, Dumitrascu DL. The digestive tract. In Badea R, Ducea SM, Mircea PA, Stamatian F, editors. *Clinic Ultrasonography Compendium*. Medical Publisher, Bucharest 2004. pp. 274–349 [Romanian].
- [3] Santoro GA, Di Falco G. Endoanal and endorectal ultrasonography: methodology and normal pelvic floor anatomy. In Santoro GA, Wiczorek AP, Bartram CI, editors. *Pelvic Floor Disorders*. Springer-Verlag, Italy 2010. pp. 91–102.
- [4] Burdan F, Sudol-Szopinska I, Staroslawska E, Kolodziejczak M, Klepacz R, Mocarska A, Caban M, Zelazowska-Cieslinska I, Szumilo J. Magnetic resonance imaging and endorectal ultrasound for diagnosis of rectal lesions. *Eur J Med Res*. 2015;20:4. DOI: 10.1186/s40001-014-0078-0.
- [5] Sudol-Szopinska I. Endosonographic examination of the anal canal and rectum. In Jakubowski W, editor. *Principles for ultrasound examination*. Roztoczanska Szkoła Ultrasonografii, Zamosc 2011. pp. 140–144.
- [6] Sudol-Szopińska I, Kołodziejczak M, Szopiński TR. The accuracy of a postprocessing technique—volume render mode—in three-dimensional endoanal ultrasonography of anal abscesses and fistulas. *Dis Colon Rectum*. 2011;54:238–244. DOI: 10.1007/DCR.0b013e3181ff44de.
- [7] Santorro GA, Di Falco G. Endosonographic anatomy of the normal anal canal. In Santorro GA, Di Falco G, editors. *Benign Anorectal Diseases. Diagnostic with Endoanal and Endorectal Ultrasonography and New Treatment Options*. Springer-Verlag, Milan Italy, 2006. pp. 35–54.
- [8] Starck M, Bohe M, Fortling B, Valentin L. Endosonography of the anal sphincter in women of different ages and parity. *Ultrasound Obstet Gynecol*. 2005;25:169–176.

- [9] Shafik A. A new concept of the anatomy of the anal sphincter mechanism and the physiology of defecation. III. The longitudinal anal muscle: anatomy and role in anal sphincter mechanism. *Invest Urol.* 1976;13:271–277.
- [10] Shafik A. A new concept of the anatomy of the anal sphincter mechanism and the physiology of defecation. The external anal sphincter: a triple-loop system. *Invest Urol.* 1975;12:412–419.
- [11] Hoeffel C, Mulé S, Laurent V, Bouché O, Volet J, Soyer P. Primary rectal cancer local staging. *Diagn Interv Imaging.* 2014;95:485–494. DOI: 10.1016/j.diii.2014.03.005.
- [12] Giovannini M, Ardizzone S. Anorectal ultrasound for neoplastic and inflammatory lesions. *Best Pract Res Clin Gastroenterol.* 2006;20:113–135.
- [13] Fockens P, Halligan S, Hawes RH, Varadarajulu S. How to perform anorectal EUS. In Hawes RH, Fockens P, Varadarajulu S, editors. *Endosonography, Third Edition.* Elsevier Saunders, Philadelphia 2015. pp. 257–259.
- [14] Kruskal JB, Kane RA, Morrin MM. Peroxide-enhanced anal endosonography: technique, image interpretation, and clinical applications. *Radiographics.* 2001;21 Spec No:S173–S189.
- [15] Badea R, Ciobanu L. Contrast enhanced and Doppler ultrasonography in the characterization of the microcirculation. Expectancies and performances. *Med Ultrason.* 2012;14:307–317.
- [16] Wang Y, Li L, Wang YX, Cui NY, Zou SM, Zhou CW, Jiang YX. Time-intensity curve parameters in rectal cancer measured using endorectal ultrasonography with sterile coupling gels filling the rectum: correlations with tumor angiogenesis and clinicopathological features. *Biomed Res Int.* 2014;2014:587806. DOI: 10.1155/2014/587806.
- [17] Roy C, Buy X, Lang H, Saussine C, Jacqmin D. Contrast enhanced color Doppler endorectal sonography of prostate: efficiency for detecting peripheral zone tumors and role for biopsy procedure. *J Urol.* 2003;170:69–72.
- [18] Mitterberger M, Pinggera GM, Horninger W, Bartsch G, Strasser H, Schäfer G, Brunner A, Halpern EJ, Gradl J, Pallwein L, Frauscher F. Comparison of contrast enhanced color Doppler targeted biopsy to conventional systematic biopsy: impact on Gleason score. *J Urol.* 2007;178:464–468.
- [19] Figueiredo MN, Campos FG. Doppler-guided hemorrhoidal dearterialization/transanal hemorrhoidal dearterialization: Technical evolution and outcomes after 20 years. *World J Gastrointest Surg.* 2016;8:232–237. DOI: 10.4240/wjgs.v8.i3.232.
- [20] Allgayer H, Ignee A, Dietrich CF. Endosonographic elastography of the anal sphincter in patients with fecal incontinence. *Scand J Gastroenterol.* 2010;45:30–38. DOI: 10.3109/00365520903383251.
- [21] Allgayer H, Ignee A, Zipse S, Crispin A, Dietrich CF. Endorectal ultrasound and real-time elastography in patients with fecal incontinence following anorectal surgery: a

- prospective comparison evaluating short- and long-term outcomes in irradiated and non-irradiated patients. *Z Gastroenterol.* 2012;50:1281–1286. DOI: 10.1055/s-0032-1313000.
- [22] Santoro GA, Gizzi G, Pellegrini L, Battistella G, Di Falco G. The value of high-resolution three-dimensional endorectal ultrasonography in the management of submucosal invasive rectal tumors. *Dis Colon Rectum.* 2009;52:1837–1843. DOI: 10.1007/DCR.0b013e3181b16ce9.
- [23] Bosman FT, Carneiro F, Hruban RH, Theise ND (Eds.). *WHO classification of Tumors of the Digestive System* (International Agency for Research on Cancer) 4th Edition. Lyon, 2010;132,184.
- [24] Gleeson FC. EUS in rectal cancer. In Hawes RH, Fockens P, Varadarajulu S, editors. *Endosonography*, 3rd Edition. Elsevier Saunders, Philadelphia 2015. pp. 260–268.
- [25] Edelman BR, Weiser MR. Endorectal ultrasound: its role in the diagnosis and treatment of rectal cancer. *Clin Colon Rectal Surg.* 2008;21:167–177. DOI: 10.1055/s-2008-1080996.
- [26] Kim NK, Kim MJ, Yun SH, Sohn SK, Min JS. Comparative study of transrectal ultrasonography, pelvic computerized tomography, and magnetic resonance imaging in preoperative staging of rectal cancer. *Dis Colon Rectum.* 1999;42:770–775.
- [27] Halefoglu AM, Yildirim S, Avlanmis O, Sakiz D, Baykan A. Endorectal ultrasonography versus phased-array magnetic resonance imaging for preoperative staging of rectal cancer. *World J Gastroenterol.* 2008;14:3504–3510.
- [28] Kauer WK, Prantl L, Dittler HJ, Siewert JR. The value of endosonographic rectal carcinoma staging in routine diagnostics: a 10-year analysis. *Surg Endosc.* 2004;18:1075–1078.
- [29] Pedersen BG, Moran B, Brown G, Blomqvist L, Fenger-Grøn M, Laurberg S. Reproducibility of depth of extramural tumor spread and distance to circumferential resection margin at rectal MRI: enhancement of clinical guidelines for neoadjuvant therapy. *AJR Am J Roentgenol.* 2011;197:1360–1366. DOI: 10.2214/AJR.11.6508.
- [30] Smith N, Brown G. Preoperative staging of rectal cancer. *Acta Oncol.* 2008;47:20–31.
- [31] Puli SR, Bechtold ML, Reddy JB, Choudhary A, Antillon MR, Brugge WR. How good is endoscopic ultrasound in differentiating various T stages of rectal cancer? Meta-analysis and systematic review. *Ann Surg Oncol.* 2009;16:254–265. DOI: 10.1245/s10434-008-0231-5.
- [32] Smith NJ, Barbachano Y, Norman AR, Swift RI, Abulafi AM, Brown G. Prognostic significance of magnetic resonance imaging-detected extramural vascular invasion in rectal cancer. *Br J Surg.* 2008;95:229–236.

- [33] Bugg WG, Andreou AK, Biswas D, Toms AP, Williams SM. The prognostic significance of MRI-detected extramural venous invasion in rectal carcinoma. *Clin Radiol.* 2014;69:619–623. DOI: 10.1016/j.crad.2014.01.010.
- [34] Waage JE, Havre RF, Odegaard S, Leh S, Eide GE, Baatrup G. Endorectal elastography in the evaluation of rectal tumours. *Colorectal Dis.* 2011;13:1130–1137. DOI: 10.1111/j.1463-1318.2010.02440.x.
- [35] Vanagunas A, Lin DE, Stryker SJ. Accuracy of endoscopic ultrasound for restaging rectal cancer following neoadjuvant chemoradiation therapy. *Am J Gastroenterol.* 2004;99:109–112.
- [36] Romagnuolo J, Parent J, Vuong T, Bélanger M, Michel RP, Belliveau PJ, Trudel JL. Predicting residual rectal adenocarcinoma in the surgical specimen after preoperative brachytherapy with endoscopic ultrasound. *Can J Gastroenterol.* 2004;18:435–440.
- [37] Maor Y, Nadler M, Barshack I, Zmora O, Koller M, Kundel Y, Fidder H, Bar-Meir S, Avidan B. Endoscopic ultrasound staging of rectal cancer: diagnostic value before and following chemoradiation. *J Gastroenterol Hepatol.* 2006;21:454–458.
- [38] Tankova LT, Penchev PI, Kovatchki D, Stoilov G, Hadjieva T. Endosonographic assessment of rectal cancer after neoadjuvant radiotherapy. *Med Ultrason.* 2012;14:19–23.
- [39] Badea R, Gersak MM, Dudea SM, Graur F, Hajjar NA, Furcea L. Characterization and staging of rectal tumors: endoscopic ultrasound versus MRI/CT. Pictorial essay. *Med Ultrason.* 2015;17:241–247. DOI: 10.11152/mu.2013.2066.172.mri.
- [40] Gersak MM, Badea R, Graur F, Hajja NA, Furcea L, Dudea SM. Endoscopic ultrasound for the characterization and staging of rectal cancer. Current state of the method. Technological advances and perspectives. *Med Ultrason.* 2015;17:227–234. DOI: 10.11152/mu.2013.2066.172.gsk.
- [41] Novell F, Pascual S, Viella P, Trias M. Endorectal ultrasonography in the follow-up of rectal cancer. Is it a better way to detect early local recurrence? *Int J Colorectal Dis.* 1997;12:78–81.
- [42] de Anda EH, Lee SH, Finne CO, Rothenberger DA, Madoff RD, Garcia-Aguilar J. Endorectal ultrasound in the follow-up of rectal cancer patients treated by local excision or radical surgery. *Dis Colon Rectum.* 2004;47:818–824.
- [43] Drudi FM, Giovagnorio F, Raffetto N, Ricci P, Cascone F, Santarelli M, Trippa F, Passariello R. Transrectal ultrasound color Doppler in the evaluation of recurrence of anal canal cancer. *Eur J Radiol.* 2003;47:142–148.
- [44] Honda K, Akahoshi K, Matsui N, Motomura Y, Kubokawa M, Higuchi N, Endo S, Taki K, Oya M. Role of EUS and EUS-guided FNA in the diagnosis of rectal implantation cyst at an anastomosis site after a previous low anterior resection for a rectal cancer

without evidence of cancer recurrence. *Gastrointest Endosc.* 2008;68:782–785. DOI: 10.1016/j.gie.2008.05.011.

- [45] Saranovic D, Barisic G, Krivokapic Z, Masulovic D, Djuric-Stefanovic A. Endoanal ultrasound evaluation of anorectal diseases and disorders: technique, indications, results and limitations. *Eur J Radiol.* 2007;61:480–489.
- [46] Halligan S. Evaluation of the anal sphincter by anal EUS. In Hawes RH, Fockens P, Varadarajulu S, editors. *Endosonography*, 3rd Edition. Elsevier Saunders, Philadelphia 2015; pp. 269–281.
- [47] Fuchsjäger MH, Maier AG. Imaging fecal incontinence. *Eur J Radiol.* 2003;47:108–116.
- [48] Deen KI, Kumar D, Williams JG, Olliff J, Keighley MR. Anal sphincter defects. Correlation between endoanal ultrasound and surgery. *Ann Surg.* 1993;218:201–205.
- [49] Parks AG, Gordon PH, Hardcastle JD. A classification of fistula-in-ano. *Br J Surg.* 1976;63:1–12.
- [50] Ortiz H, Marzo J, Jiménez G, DeMiguel M. Accuracy of hydrogen peroxide-enhanced ultrasound in the identification of internal openings of anal fistulas. *Colorectal Dis.* 2002;4:280–283.
- [51] Chew SS, Yang JL, Newstead GL, Douglas PR. Anal fistula: Levovist-enhanced endoanal ultrasound: a pilot study. *Dis Colon Rectum.* 2003;46:377–384.
- [52] Giovannini M, Bories E, Moutardier V, Pesenti C, Guillemin A, Lelong B, Delpéro JR. Drainage of deep pelvic abscesses using therapeutic echo endoscopy. *Endoscopy.* 2003;35:511–514.