

We are IntechOpen, the world's leading publisher of Open Access books Built by scientists, for scientists

6,900

Open access books available

186,000

International authors and editors

200M

Downloads

Our authors are among the

154

Countries delivered to

TOP 1%

most cited scientists

12.2%

Contributors from top 500 universities



WEB OF SCIENCE™

Selection of our books indexed in the Book Citation Index
in Web of Science™ Core Collection (BKCI)

Interested in publishing with us?
Contact book.department@intechopen.com

Numbers displayed above are based on latest data collected.
For more information visit www.intechopen.com



Endobronchial Ultrasound in Mediastinal Lymphadenopathy

Ilya V. Sivokozov, Olga. V. Lovacheva,
Irina. Y. Shabalina, Galina V. Evgushenko,
Tatyana A. Statsuk, Larisa N. Lepekha,
Yuri S. Berezovsky, Natalya N. Makaryants,
Larisa N. Chernousova and Elena E. Larionova

Additional information is available at the end of the chapter

<http://dx.doi.org/10.5772/66079>

Abstract

Currently, endobronchial ultrasound dramatically changed diagnostic approaches for mediastinal lesions, both benign and malignant. Still there is a lack of data regarding the optimal anaesthesia, route of intubation, needle type, and specific clinical situations concerning EBUS in real clinical practice. A short, but clinically oriented, description of EBUS-TBNA and EUS-b-FNA techniques for mediastinal lesions is provided.

Keywords: diagnostics, bronchoscopy, EBUS, EUS-b, sarcoidosis, tuberculosis, lung cancer, lymphoma

1. Introduction

From its first implementation [1] in clinical practice in 2003, convex endobronchial ultrasound-guided transbronchial needle aspiration (EBUS-TBNA) has rapidly evolved into one of the most hugely used diagnostic techniques in interventional pulmonology. Currently, all main companies in the field presented their systems for EBUS, with minor differences in modalities. Still there is a lack of data regarding the optimal anaesthesia, route of intubation, needle-type, and specific clinical situations, concerning EBUS in real clinical practice. Most recent CHEST panel recommendations, organized by AABIP/ACCP stated some unresolved issues with EBUS

features, including anaesthesia type, needle choice, and others [2]. Interestingly, many recommendations were even ungraded by expert panel due to the absence of any studies covering exact questions. Thereafter, authors will share their own experience with EBUS and try to answer some of the issues in this area.

2. Indications and contraindications

Indications for EBUS/EUS-b are:

- Mediastinal adenopathy of unknown cause
- PET-positive LNs in mediastinum in patients with previous or current malignancy, irrespective of their size
- Suspected mediastinal cyst (normally evaluation only)
- Central lung cancer with failed conventional biopsies (peribronchial growth)
- Suspected tumour invasion into main vessels/mediastinal structures
- Transoesophageal LAG biopsy using bronchoscope

Contraindications:

- Severe thrombocytopenia (<25,000/mcl)
- Confirmed mediastinal cyst (if no other abnormalities seen on radiology)
- Non-correctable severe hypoxia
- Lack of personnel experience

3. Endobronchial ultrasound: equipment

Currently, all main companies in the field supply dedicated systems for EBUS, with minor differences in modalities. Main features of the equipment presented in **Table 1**.

Principally, there is no fundamental difference between the systems. Olympus and Fujinon have chosen a path to establish a separate, dedicated endoscopic ultrasound units, which can be mounted in an endoscopic tray, thus making procedure more convenient for personnel. Pentax systems have no dedicated endoscopic ultrasound centres, using instead a separate machines of high-level and expert class (e.g., Hitachi Noblus system). Apart from general EUS area, where ultrasound quality plays an essential role, EBUS situations do not impose such high requirements for quality of ultrasound image. Mobility, compact fashion and laconic interface are main features, which much more important for interventional pulmonologist, performing a procedure. Still, Olympus echobronchoscopes have a possibility to be connected with stand-alone machines (e.g., Aloka $\alpha 7/\alpha 10$), which can be a possible option for large

endoscopic suites, where both EUS and EBUS are performed, giving a chance for a more optimal usage of these systems. Honestly, this variant is not currently popular.

There are several important things about echobronchoscopes. First of all, they all are very fragile and have to be used with great caution, and only for the purpose of EBUS, not for conventional procedures such as BAL, TBLB, etc. In frames of ease of use, Fuji scope is better to intubate and make an inspection of trachea and bronchial tree due to less oblique forward viewing (10° vs. 35° in Olympus and 45° in Pentax scopes) and high-definition image. One additional advantage of Fuji scope is that it allows to use conventional TBNA needles [3] during EBUS-TBNA procedure, when the other scopes have specific angulations of working channel, precluding insertion of conventional TBNA needle. The ultrasound field of view is a bit better in Fuji and especially Pentax comparing to Olympus, but in terms of biopsy procedure it does not make significant sense. From the other side, Olympus scope has a larger working channel diameter, which gives an opportunity to use 21G and even a 19G EBUS needles [4]. Pentax-based system (Hitachi Noblus) gives an access to latest generation of elastography and strain-ratio measurements, as also as additional features and options of ultrasound, given by a separate expert class machine, but the other side of the coin is less ease of use for such combination.

	Olympus	Pentax	Fujinon
Endoscope	BF-UC180F	EB-1970UK	EB-530US
Direction of view	35° forward oblique	45° forward oblique	10° forward oblique
Resolution	Standard, chip	Standard, chip	High Def, chip
Insertion tube o. d., (mm)	6.3	6.3	6.3
Channel diameter	2.2	2.0	2.0
Needle gauges	25-22-21-19	25-22	25-22
Main ultrasound systems	EU-ME1/ EU-ME2	Hitachi Noblus	Sonart SU-1
Scanning range, degrees	60	75	65
Colour and power Doppler	+/+	+	+
Tissue harmonic echo	-/+	+	-
Elastography	-/+	+	-
Contrast-enhanced US	-/+	-	-

Table 1. Main features of available EBUS systems.

In any case, all the scopes and systems provide the ability to perform intubation of trachea, inspection of bronchial tree, and needle biopsy of mediastinal and hilar structures for the vast majority of clinical situations.

4. Endosonography in mediastinal lesions: current status

For the last decade, EBUS implementation led to outstanding changes in management of respiratory patients, especially in lung cancer, sarcoidosis, tuberculosis and lymphoma.

Guidelines for diagnosis and treatment for lung cancer issued by ACCP [5] in May 2013 stated that in patients with suspected lung cancer with extensive mediastinal infiltration based on radiology and no evidence of metastatic disease, the diagnosis should be established including EBUS-TBNA or EUS-FNA, whatever technique is available and suitable for concrete patient. In the same guideline, in case of performing staging in patients with suspicion of N2-N3 disease, EBUS-TBNA, EUS-FNA or their combination are recommended over surgical staging as the best first step. Interestingly, that both these recommendations have a first-grade power, i.e., were confirmed by randomized clinical trials. In a more recent guideline, issued in June 2015 by ESGE/ERS/ESTS, dedicated to the role of EUS-EBUS in lung cancer diagnosis and staging [6], the main recommendation by experts was to use endosonography for staging in NSCLC patients over surgery as initial step (grade A), and if possible, to do that in combined fashion (EBUS-TBNA/EUS-FNA, or EBUS-TBNA/EUS-b-FNA) to achieve complete endoscopic staging (grade C).

Great number of publications were issued concerning the role of endosonography in sarcoidosis patients. Indeed, more than 80% of newly diagnosed sarcoidosis have mediastinal involvement by radiology. First paper, dedicated to EBUS-TBNA efficacy in sarcoidosis stage I, was published already in 2004 [7], showing the yield more than 90%. In frames of recent meta-analysis (more than 2000 cases of mediastinal adenopathy) published by Trisolini in 2015 [8], EBUS-TBNA was effective in 79% among sarcoidosis patients. Again, CHEST panel recommendations [2], issued in 2016, included suggestion to use EBUS-TBNA as first diagnostic modality for patients with suspicion of sarcoidosis. Surprisingly, international WASOG guidelines for diagnosis and treatment of sarcoidosis are extremely old and were issued in 1999, before new era of EBUS began, and still are not updated. Several countries in their national guidelines for sarcoidosis diagnostics and treatment already included EBUS-TBNA/EUS-FNA as a reliable technique in diagnostic workup in this cohort [8].

Tuberculosis, one of the most widespread infections on the global level, is also in the field of view for EBUS. Recent CHEST recommendations [2] have a suggestion to use EBUS-TBNA/EUS-FNA as suitable diagnostic modality for patients with suspicion of tuberculosis. Unfortunately, the data for endosonography in TB area are much weaker than in other diseases due high costs of this technique for low-income countries, which mostly suffer from high burden of tuberculosis.

Last, but not the least, lymphomas became a point of interest for endosonography in a last couple of years. Until recently, main option for such cohort of patients in primary diagnostics was surgical biopsy, due to need in a large amount of tissue with true biopsy specimen. When in 2014 EBUS tru-cut histology needles became available, situation began to change [9].

To improve the diagnostic yield, new imaging modalities enter now into EBUS area, arising from gastrointestinal endosonography. Among them—elastography—technique, which can

give as a non-invasive assessment of lesion stiffness and perform targeted biopsy; tissue harmonic echo, which diminishes artefacts from rapid motion and increases spatial resolution; and different contrast enhancement modes, allowing operator to assess vascularization patterns in mediastinal nodes or lesions to better characterize the origin of disease and perform precise interventions.

Besides that, a trend to change the focus from EBUS-guided biopsies to EBUS-guided interventions is clearly visible. In other words, now, we can diagnose the diseases of mediastinum effectively, and move on to the next step—to use this technique in treatment of patients. Some of these promising new goals—chemotherapy agent injections in locally advanced lung cancer, mediastinal cysts drainage, transvascular interventions—are discussed thereafter in this chapter.

5. Image modalities for EBUS/EUS-b

5.1. B-mode: grayscale

Grayscale mode, a basic mode for assessment of mediastinal structures, mainly lymphatic nodes (LN) during EBUS, can give a number of data for operator. LN size, echogenicity, shape, margins, central hilar structure, necrosis sign, invasion into main vessels of heart chambers can be estimated. Usually, main question for bronchologist, performing an EBUS investigation, is to distinguish benign and malignant adenopathy, because it has crucial impact on patient management. According to Fujiwara [10], who proposed a standard classification of EBUS image, features, typical for malignancy, are as follows: short axis size >10 mm, round shape, distinct margin, heterogeneous structure, hypoechoic, the absence of central hilar structure, and necrosis sign. If more than 4 of these criteria were met, calculated malignancy probability reached 96% (see **Figure 1**). Common features for benign lesions are—blurry margin, homogeneous structure, hyperechoic, the presence of central hilum, triangular or septate shape (see **Figure 2**).

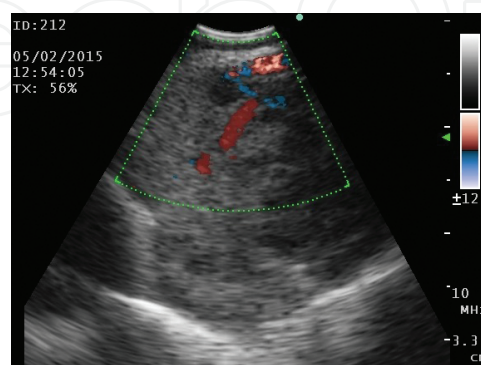


Figure 1. Malignant LN in mediastinal recurrence of renal cell carcinoma. Note hypoechoic character, heterogeneous structure, the presence of BA-flow (discussed afterwards). The presence of multiple necrosis signs in upper part of lesion is typical in patients after chemotherapy.

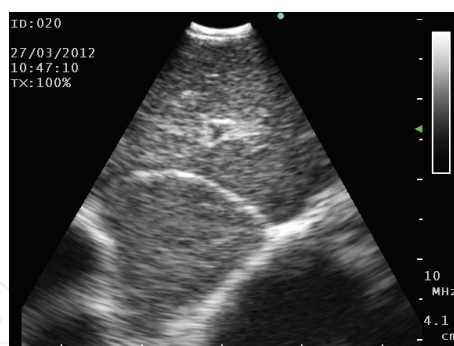


Figure 2. Benign LN in acute sarcoidosis. Note hyperechoic character, blurry margins, triangular shape, septated.

Of course, grayscale image cannot replace a biopsy, which is the gold standard for mediastinal lesions of any cause. Using B-mode, operator can choose, which of the lesions looks more suspicious for malignancy, or even choose an exact zone inside the node for biopsy.

5.2. Power and colour-flow Doppler

Doppler detects movement of fluid in the area of scanning. In theory, neovascularization in malignant LN can be traced by Doppler, and therefore, this technique can help to distinguish malignant lesion from benign. In 2012, Nakajima [11] proposed scoring system for blood flow in LN, from Grade 0 (no or small flow) through Grade 1 (few main vessels from hilum toward the centre), Grade 2 (few punctiforms or rod-shaped flow signals or a few small vessels found as a long strip of a curve) until Grade III (rich flow, more than four vessels found with different diameters or twist- or helical -low signal). The blood flow from the bronchial artery (BA) toward the LN was also recorded using Colour Doppler imaging as a sign for BA inflow. It was shown that Grades 0–1 were specific for benign lesion, whereas higher grades and especially BA sign—for malignancy with a total accuracy around 80%. It needs to be emphasized, that only biopsy can confirm or exclude malignant or benign disease, and this is perfectly illustrated (see **Figures 3, 4**).

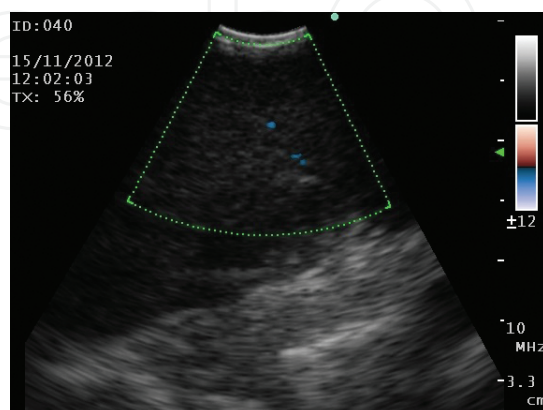


Figure 3. Large subcarinal LN in patient with metastatic adenocarcinoma. According to the Doppler flow (Grade 0–1 spot vessel), this LN can be falsely assessed as benign.

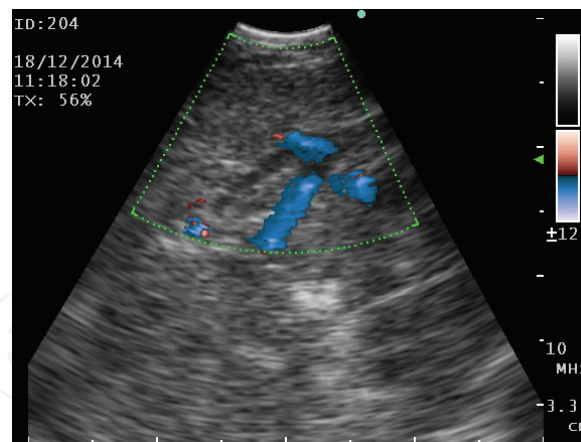


Figure 4. Large subcarinal LN, protruding to station 8 in patient with chronic sarcoidosis. According to the Doppler flow (Grade 3—number of large twisted vessels), this LN can be falsely assessed as malignant.

Use of Doppler during EBUS is irreplaceable when a biopsy is planned. This technique helps to plan a biopsy path, avoiding vessels inside LN, large vascular structures, heart chambers, thus providing a safe intervention. It should be noted that Colour Flow mode is less sensitive than power flow, so in difficult cases, when sludge is suspected, Power Doppler is more suitable option. Stand-alone ultrasound machines can reach even higher sensitivity, using special modes of vascular flow detection (e.g., Hitachi Noblus, see **Figure 5**).

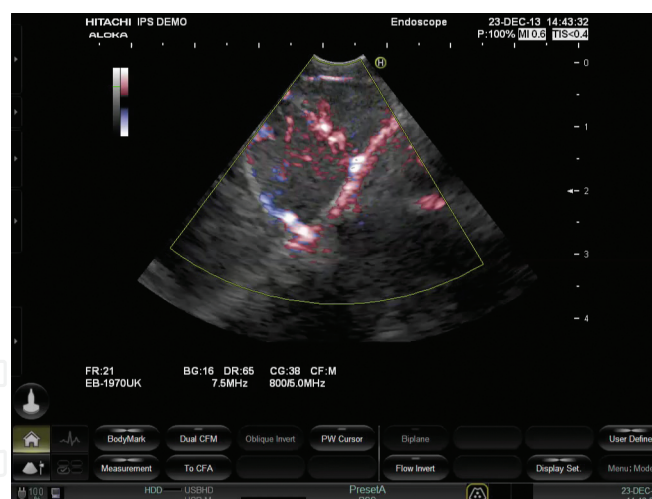


Figure 5. Subcarinal LN in patient with chronic sarcoidosis and concomitant pulmonary hypertension. eFlow regimen depicts vascular structures in septa between LN agglomeration, not detected in Colour Flow mode.

5.3. Elastography

One of the new modalities, which became available today for EBUS is elastography. This is an imaging procedure that can assess the biomechanical characteristics of different tissues and their deformation under compression [12]. Simplifying, elastography can measure stiffness of

scanning area, where malignant tissue has lower elasticity and higher stiffness than benign. Currently, both Olympus and Pentax provided such a mode for EBUS. Independently of producer, a colour histogram reflecting stiffness of scanning area is superimposed on a grayscale image, where more blue colour means less elastic areas, and more green colour depicts more elastic areas. In other words—“blue is bad, green is good”.

Two main logical applications for this technique are assessment of mediastinal LNs for probable malignancy during staging of NCLC, and performing a targeted EBUS-TBNA for a precise part of LN or group of them.

As elastography makes only first steps in respiratory world, the evidence of usefulness for this technique is still scarce. First publication for EBUS elastography was issued in 2013 [13] stated that this technique is feasible and can be performed in bronchial tree. In 2014, Izumo et al. [14] proposed classification of strain features of LNs based on the predominant colour at elastography investigation—predominantly blue, non-blue, or mixed, showing accuracy rate in malignancy detection more than 97%. The same year, in another study [15], feasibility of method in EBUS was confirmed, and impact of access (EBUS or EUS-b) on elastography results was depicted, showing probability to overestimate stiffness of the same lymphatic node using EBUS comparing to EUS-b approach. Rozman et al. [16] used a strain ratio—stiffness of targeted area divided by stiffness of reference area and came to conclusion that cut-off of ratio 8 and more predicts malignancy with positive predictive value of 81% and negative predictive value of 91%, which is the best efficacy than any other image modality for EBUS available nowadays.

Elastography can be used not only for mediastinal lesions assessment (see **Figure 6**). It can be utilized also for pulmonary masses, adjacent to bronchial tree or oesophagus (see **Figure 7**).

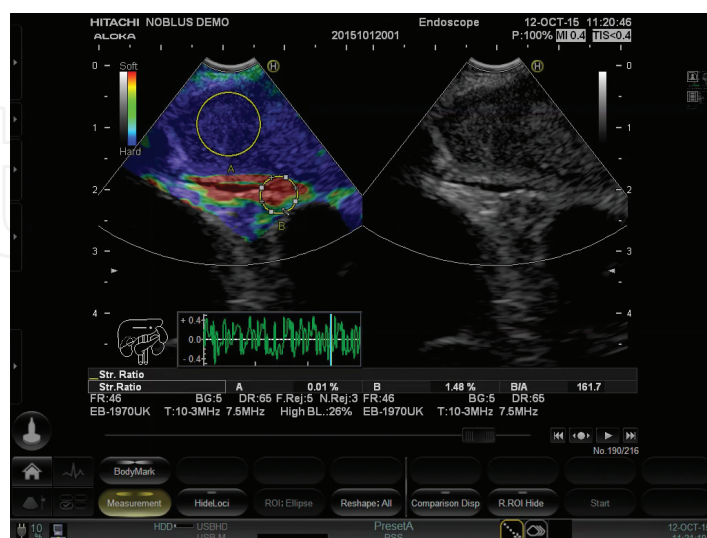


Figure 6. Huge subcarinal LN in patient with metastatic adenocarcinoma. Note the total blue colour on histogram, and two markers for strain ratio measurement, which far exceeded 120, suggesting malignant character of LN.

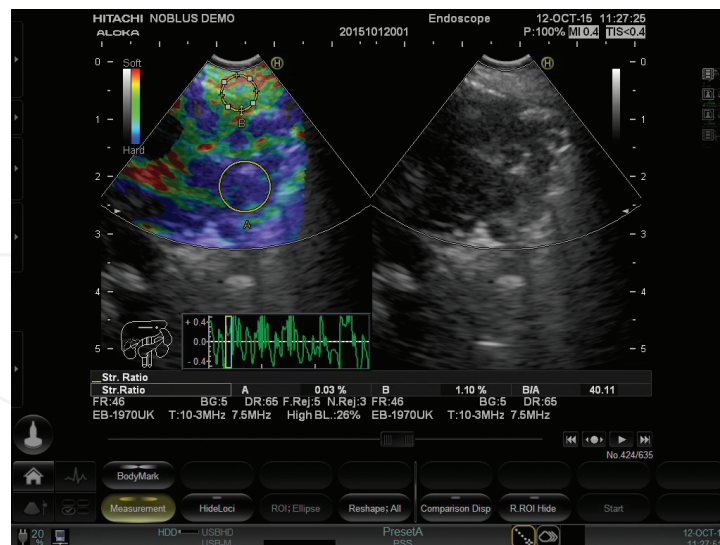


Figure 7. The same patient, lung mass is visible in right S6 adjacent to oesophagus, near the subcarinal LN. Note numerous echo artefacts on the mass border with aerated lung. Predominantly, blue-coloured area, SR exceeds 40. Metastatic adenocarcinoma.

5.4. Tissue harmonic echo (THE) and contrast-enhancement in EBUS

Several current systems for EBUS optionally can use both THE and contrast enhancement modes for endobronchial approach. Tissue harmonic echo is used for many years in digestive endosonography, namely for pancreatic lesions and hepatobiliary disorders [17]. Using a harmonic reflection instead of fundamental image can increase the signal ratio and thus give an opportunity to visualize structures more clear. Possible technique applications in mediastinum enclose better visualization of difficult-to-reach structures with low echogenicity, better assessment of tumour invasion in adjacent structures, etc.

The blood flow in small vessels and the parenchymal microvasculature of the target lesion can be observed non-invasively by contrast-enhanced EUS (CE-EUS). Through a hemodynamic analysis, CE-EUS permits the diagnosis of various gastrointestinal diseases and differential diagnoses between benign and malignant tumours [18]. It was shown that in mediastinal LNs CE-EUS can detect a filling defect, which is a typical sign of malignant lymphadenopathy, with a sensitivity of 100% and a specificity of 84% [19]. Thus, this indicates possibility for the application of this method in the differential diagnosis of mediastinal lymphadenopathy.

6. Endobronchial ultrasound-guided biopsies of mediastinum

6.1. Instruments

There is a long list of available biopsy needles for EBUS on the market. Basically, all the needles can be divided in two groups – cytology and dedicated histology needles. Comparison of some needle features is presented in **Table 2**.

	Length (mm)	Compatibility	Type
Olympus			
Vizishot 22G	40	Olympus	Cytology
Vizishot 21G	40	Olympus	Cytology
Vizishot 19G	40	Olympus	Histology
Cook Medical			
Echotip Ultra 22G	50	All	Cytology
Echotip ProCore 25G	50	All	Histology
Echotip ProCore 22G	50	All	Histology
Boston Scientific			
Expect Pulmonary 25G	60	Olympus	Cytology
Expect Pulmonary 22G	60	Olympus	Cytology
MediGlobe			
SonoTip EBUS Pro	40	All	Cytology
SonoTip EBUS Pro Flex	40	All	Cytology

Table 2. Main features of available EBUS needles.

There are little data available regarding comparative efficacy of different EBUS needles both in frames of cytology/histology quality or diagnostic yield. Regarding 21 and 22G needles, still there is only one randomized trial by Oki [20], where no difference was seen in terms of adequacy or diagnostic yield. The same results were achieved by several other studies [21–23]. In other study by Izumo [24], compared Olympus and MediGlobe EBUS 22G needles, the latter showed better efficacy in terms of histology and total yield (74 vs. 61%). Notably, this study was not randomized and used Olympus needle as a historical control group. In a recent pre-published study by Xing et al. [25], EBUS ProCore needle was compared to ordinary cytology EBUS-TBNA needle (exact gauge was not stated), with respective efficacy of 94 and 89%. Authors did not state, what kind of patients they studied, and the data are resembling those for patients with benign or typical malignancy diseases, whereas ProCore needle was mostly expected to be used in difficult situations like lymphoma. There was a small randomized comparative study of Olympus and Cook 22G cytology EBUS needles [26], where in terms of cytology both needles show equal efficacy, but total diagnostic yield and yield by histology favoured Cook needle.

Finally, taking into account, some of the studies mentioned above, CHEST panel of experts [2] recommended use any type of needle, either 21 or 22G as an acceptable option (Grade 1C). From personal experience, authors would recommend to use any needle in case of benign disease or NSCLC for typical LN stations, and histology EBUS needles (19G Olym-

pus or 22–25G ProCoreCook) in case of suspected lymphoma, or if definitive pathology diagnosis should be established. Smaller needle size (22–25G) can be an advantage in specific situations—like lesions in stations 2R/L, 4L, 11–12R/L, transvascular interventions.

6.2. Balloon: use or not?

All EBUS scopes have possibility to use a special balloon over their distal ultrasound tip, filled with saline for better contact of the probe with bronchial wall in challenging situations. Unfortunately, still there are no studies available to assess the real sense of this additional and disposable equipment. Balloons are widely accepted in routine practice in Northern America, and CHEST recommendations [2] on EBUS suggest their usage for paratracheal lesions and hilar stations. In Europe and Japan, balloon usage is much less popular, at least partially due to possibility to use transoesophageal approach for 7 and 4L stations via EUS-b procedures.

From personal experience, authors recommend balloon usage for the beginners in EBUS. With increased experience usage of balloon can be avoided in a vast majority of clinical situations.

6.3. Anaesthesia and intubation way

Endobronchial ultrasound can be performed in different anaesthesia settings—conscious sedation, general anaesthesia, or even local anaesthesia. Interestingly, that firstly EBUS-TBNA was performed mostly under local anaesthesia, and only in a couple of years after sedation was generally accepted [27]. Currently, moderate or deep sedation is recommended as the main anaesthesia way for EBUS by recent guidelines [2], but evidence level for that is not so good (Grade 2C). Studies dedicated to comparison of deep versus moderate sedation showed conflicting results, precluding clear algorithm of anaesthesia in EBUS procedure.

From personal experience, authors recommend to use all mentioned above ways of anaesthesia, but starting from exact situation. Thus, for example, local anaesthesia is still an option when a diagnostic procedure with single biopsy is planned, especially in case of EUS-b approach for enlarged LN in positions 7 and 4L. If an EBUS approach is planned, local anaesthesia still can be used, especially with transcricoid injection of 2% lidocaine. This type of anaesthesia provides adequate control over laryngeal and cough reflex, giving an opportunity to perform procedure with extremely high patient compliance for 15–20 min.

Sedation, deep or conscious, can be recommended in situations where procedure duration exceeds 15 min, LAG biopsy with EBUS scope is indicated, multiple biopsies planned (staging), or technical issues during puncture are foreseen.

General anaesthesia can be recommended in several situations—during EBUS implementation in clinic, when an operator is not very experienced, or if other anaesthesia types are not safe for patient, or in case of extremely long procedure (i.e., full staging of all assessable LN stations).

There are several ways of intubation with EBUS bronchoscope. It can be inserted alone via transoral or transnasal approach or can be inserted via artificial airways—laryngeal mask, intubation tube, or rigid scope. Again, data from studies referred for this question are ex-

tremely scarce and cannot give any definitive suggestion which variant of intubation is better. Based on personal experience, authors recommend further indications: use transoral approach during EBUS under local anaesthesia only. If it is sometimes needed to intubate through the nasal cavity, remember that this is slightly more difficult due to larger endoscope diameter, rigid distal part, and oblique optics. Choosing between laryngeal mask and intubation tube, we recommend fist option, because intubation tube limits as mobility of endoscope inside bronchial tree, as a visibility of some LN stations, like 2L/R, 4L/R, 3p. besides that, a cuff of a tube can damage the sheath of a scope, especially during staging procedures. Also, multiple scope passes in and out of intubation tube can lead to a more rapid degradation of this fragile equipment. The last option for EBUS intubation—through a rigid scope. This variant has only advantage over others—due to straight way of the barrel, EBUS scope have a less chance to be damaged during biopsy, and lower degradation rate due to less active bending. All the rest is not in favour of this method—so, scope can be damaged by retraction, angulation, and rotation during scanning and puncture, especially for 4L position. Besides that, upper paratracheal LN groups, as 3p group is not achievable using this approach.

Last, but not the least, it needs to be mentioned that echobronchoscope can be inserted not only in trachea, but also into oesophagus, thus obtaining an opportunity to reach 7 and especially 4L positions much more easy than through trachea, and widens assessable biopsy area to station 8, 9 and even LAG. This is called an EUS-b approach, and according to latest European guidelines [6], this method is encouraged to be used by respiratory care professionals for complete endoscopic staging in NSCLC. In North America, unfortunately, bronchologists are under severe pressure of regulations, and this limits spread of this very simple and convenient, both for doctor and patient, procedure.

6.4. Biopsy technique: movement, suction, stylet and more

Analyzing biopsy step by step, a huge decision tree for operator can be seen. Hereafter, each step of procedure will be discussed with relevant comments.

Stylet. Each needle has a stylet, which blocks an inner lumen to avoid contamination of specimen, and additionally, protects working channel from damage as needle passes through the scope. There are two options—to use stylet or not. Currently, there is no dedicated publications for this question regarding EBUS. But, taking into account recent meta-analysis of this issue for EUS-FNA [28] with more than 5000 cases included, it can be suggested that stylet possibly should not be used always during EBUS or EUS-b biopsies. From personal experience, authors recommend not to reinsert the stylet after first pass was performed, as it saves time of procedure, except needles where it is noted by manufacturer (MediGlobe) or needles with tru-cut design (ProCore), where stylet should be reinserted all the times to avoid working channel damage.

Suction. There are several options regarding suction: use, not use, apply “capillary” or “wet” approach. Capillary technique, or “slow-pull”, means slow withdraw of stylet from needle, thus creating a residual vacuum inside needle to aspirate specimen. “Wet” approach means filling of needle lumen with saline, thus increasing the power of conventional suction syringe. Again, both recent guidelines for EBUS [2, 29] stated equal possibility to use suction or not.

Personally, authors recommend during first pass apply half-syringe suction; if specimen is too bloody, proceed without suction or “capillary” technique, if specimen is poor, apply full suction with further option to use “wet” approach. Additionally, if a high vascular pattern is seen by ultrasound imaging, it is recommended to start biopsy without suction or use “capillary” way.

Biopsy movements. Needle motions can be different by speed, force, and number. There are no studies comparing these approaches in terms of biopsy quality and efficacy. Hereafter, authors’ opinion on their usage can be found.

- *RiSo—Rapid In, Slow Out.* Means rapid, forceful needle penetration into target, and slow return back. Fills up the needle-like a pipe. Recommended for LNs with low to intermediate vascular flow, and for ProCore needles.
- *SiSo—Slow In, Slow Out.* Means gentle, slow movement back and forth with low frequency. Suitable for highly vascularized lesions.
- *RiRo—Rapid In, Rapid Out.* Means rapid, forceful movements in both directions with high frequency. Option for rigid and stone-like lesions (e.g., lymphoma).
- *SiRo—Slow In, Rapid Out.* Means slow and gentle movement forward with more rapid way back. Rare option can be applied using 25G EUS ProCore needles through the bronchoscope, where cutting edge looks back; also can be used if a large vessel in LN cannot be avoided, providing careful entrance into the lesion.

Fanning. To cover larger amount of tissue inside the lesion, needle can change its path for each new movement, using control lever of the scope. This is called fanning, as it resembles the movements of a fan. Recommended for usage in most of situations as helps to sample more target areas.

Number of needle movements inside the LN. No data available. Authors recommend 15–20 needle agitations during single pass.

Number of passes. According to recent guidelines [2, 29], not <3 consecutive passes should be performed for each LN in case of NSCLC staging procedure. No data available regarding benign diseases. Authors recommend for benign diseases to perform at least 2 passes from each target LN, and in case of core retrieval avoid third pass.

6.5. Preparation of smears, cellblocks and culture

Smears should be prepared immediately after the material was expelled, or flushed from the needle. At first, specimen has to be macroscopically assessed (volume, colour, character, thickness, the presence of artificial fills). This can give an operator a chance to use the specimen more effectively. Any additional inclusions—looking like flocs, crumbs, firm strings, or nubbles of pus, should be evaluated. Any specimen, is it abundant or poor, bloody or not, can be used for cytology analysis (**Figure 8**).

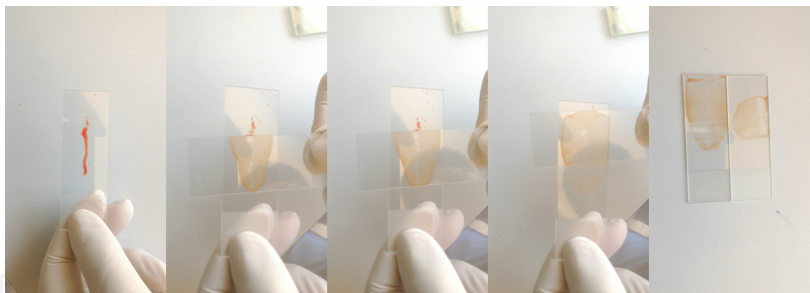


Figure 8. Steps of proper smear preparation from typical EBUS-TBNA specimen (from left to right).

In case of excessive blood contamination, smears should be prepared immediately to avoid clots formation, which will preclude the procedure. If specimen is liquid, it can be processed just like a blood smear (see **Figure 9**). If retrieved specimen is more solid, additionally smears can be achieved just rolling the solid component on the slide with a needle tip (see **Figure 10**). In other way, if retrieved specimen is too sticky, operator can put another slide from above and gently pressing, achieve the so-called touch smear (see **Figure 11**). All the movements and pressure should be applied to specimen with gentle force to avoid cells damage. In case of liquid, high-volume (>1 ml) specimen, it can be processed with centrifugation and consequent smears from precipitate. Notably, even low-volume specimens (<1 ml) can be processed using a cyto-spin.




Figure 9. Steps of smear preparation from bloody specimen. Note clearly seen circle-shaped artefact due to clot formation, emphasizing need in immediate processing of such specimen.




Figure 10. Steps of smear preparation from solid EBUS-TBNA specimen by rolling it by needle tip.




Figure 11. Steps of smear preparation from solid specimen by “touch smear” technique. Note that slides are moving after each touch, achieving sequential touch smears.

After air-dry, smears are stained for cytological examination. There are several staining methods available, and it depends on the local clinical practice of cytopathology or cytology laboratory.

If obtained specimen contains cores, it can be processed by two ways. Core tissue should be taken with care by tweezers or medical needle tip and placed directly to buffered 10% formalin solution; or core can be temporarily transferred to the filter paper to give blood to sink in paper, living core tissue free, and shortly after transfer the core into formalin. Most of this material is not a pure histology specimen, rather the so-called “cell block”, which is though suitable for processing in pathology laboratory with all possible staining.

In case of suspected tuberculosis or other infection, both PCR and culture tests should be performed. This can be carried out by performing additional EBUS-TBNA pass with consequent flushing or expelling the specimen into transport medium; also, after last pass processing, EBUS needle can be flushed with saline into transport medium. No formal recommendations exist for microbiological investigation. Authors recommend flush EBUS needle with 10–15 ml of saline to achieve enough material volume for both tests for TB.

7. EBUS-guided interventions

7.1. Mediastinal cysts drainage

For a long time, mediastinal cyst was a contraindication for EBUS-TBNA or EUS-FNA procedures, due to high risk of consequent infection and surgical interventions. Till now, the most common pathway for such a patient can be formulated as “no symptoms—no treatment, any symptoms—surgery”. Cystic lesions present some sort of a challenge for surgeon, that is why most of the cysts are not operated until they become symptomatic.

In 2007, Nakajima [30] published a first case of EBUS procedure performed to for diagnostic, but for curative intent in a patient with severe central airway stenosis due to mediastinal cyst, without any complication or cyst recurrence. Three years later, even infected mediastinal cyst was successfully treated by EBUS-TBNA [31]. Importantly, in this case, puncture allowed not only to evacuate debris, but also perform culture analysis and thus prescribe appropriate

antibiotics. This case also showed possibility for numerous punctures of the same lesion, providing stepwise approach to treatment. In 2015, Maturu et al. [32] performed first meta-analysis of mediastinal cysts drainage publications, found 16 cases of EBUS-TBNA for this indication. The overall complication rate after cyst drainage under EBUS-guidance was 18.7% (3 cases of complications, including cyst infection and pericarditis, cyst rupture and pneumonia, and mediastinitis), according to authors, this rate is comparable with surgical morbidity. Data regarding recurrence chances are scarce and non-reliable.

In conclusion, EBUS-TBNA for mediastinal cyst drainage is a possible option for at least some of cases. This can be a suitable alternative for surgery, or a salvation therapy for non-surgical candidates. Further studies needed to establish real value of such technique.

7.2. Chemotherapy agent injections in lung cancer

EBUS-TBNA became a standard of care in lung cancer patients. Possibility to precisely detect position of malignant LN and perform a biopsy in real-time fashion led to hypothesis of possible usage of endobronchial ultrasound for therapy agent injection in affected LN.

In 2013, first publication was performed regarding this issue by Brachmann group [33]. They used EBUS-TBNA with curative intent (named by authors TBND—transbronchial needle dosage) for regional metastatic LNs in six patients with stage IIIa-IV NSCLC, with six passes of cisplatin injections inside the lesion to cover the whole LN volume. Safety and possible efficacy of EBUS-TBND was shown. Two years later, in the end of 2015, Mehta et al. [34] reported first experience of lung cancer mediastinal and hilar recurrence EBUS-TBNI (I-injection) treatment with cisplatin in 36 patients. Response rate reached 69%, with significantly higher both overall and progression-free survival among responders.

In this way, EBUS-guided injection of chemotherapy is possible new paradigm for patient with locally advanced and recurrent NSCLC, not suitable for surgical resection.

8. Complications

From the beginning of EBUS implementation, it was stated that procedure is very safe, probably transferring experience available for conventional TBNA. Early sporadic case reports were interchanged with meta-analyses, when number of procedures has grown dramatically. According to the recent paper of Annema group [35], included more than 16,000 cases of EBUS/EUS performed for mediastinal lesions, severe adverse event rate was estimated as 0.05% for EBUS-TBNA, and minor adverse events rate was 0.22%, or around 1 in every 500 procedures. Authors came to conclusions that rate of minor adverse events is severely underestimated. Most of described in the literature EBUS-TBNA complications include infections of mediastinum (mediastinitis, abscess, pericarditis), pneumothorax, severe haemorrhage, and hypoxemia during and after procedure. It should be noted that most of infectious complications were caused by mediastinal cystic lesions, punctured by mistake without further drainage.

Among sarcoidosis patients, according to Agarwal et al. [36], minor adverse events were noted in 0.9% of cases. In elderly patients with lung cancer (>70-year old), complication rate was much higher and reached 5.8% [37]. Interestingly, in case of tuberculosis, rate of minor complications was calculated as 2.33% [38], and for severe as 0.12% [39] by two separate meta-analyses.

In conclusion, complications of EBUS-TBNA are rare, but not as rare as one might think. Each patient should be carefully observed after procedure to provide appropriate care for any consequent health problems.

9. Efficacy of EBUS-guided biopsies in specific diseases: clinical cases

9.1. Sarcoidosis and sarcoid-like reactions

Sarcoidosis stages I and II is one of the most common indications for EBUS-TBNA. According to the recent guidelines [2], EBUS-TBNA is recommended for diagnosis in patients with suspected sarcoidosis with mediastinal and/or hilar adenopathy. Efficacy of endosonography in diagnosing sarcoidosis varies—from 90% in highly selected population in 2004 [7], till 79% in routine practice in 2015 [40]. Mostly LN groups 7 and 4R are biopsied using EBUS approach, and station 7 and 4L—using EUS-b approach. In countries with high burden of TB, authors strongly recommend perform culture and PCR tests to avoid misinterpretation of granulomas in specimens.

Sarcoid-like reactions can accompany different malignancies, including NSCLC and lymphoma, sometimes mimic recurrence of main disease. They are seen in 4.4% of all solid tumours, and in almost 14% of patients with Hodgkin's lymphoma. In case of suspicion for such reaction, EBUS-TBNA can be performed to exclude or confirm malignancy.

Sometimes this reaction can coexist with tumour in the same lymphatic node (see **Figure 12**).

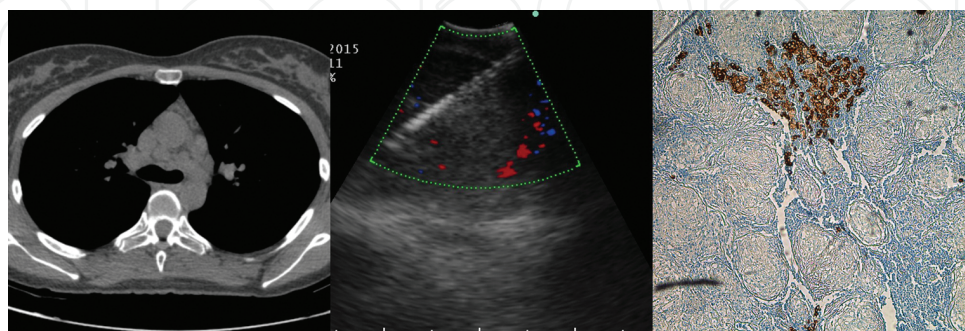


Figure 12. Patient with asymptomatic mediastinal adenopathy on chest CT (left), for suspected sarcoidosis EBUS-TBNA of LN 4R was performed using 21G Vizishot needle (middle, note the needle echo inside LN), pathology IHC with DAB staining for pancytokeratin revealing brown malignant cells, surrounded by multiple sarcoid granulomas (right). Metastatic adenocarcinoma coexisted with sarcoid-like reaction.

9.2. Primary and metastatic cancers

Both diagnosis and staging of lung cancer changed dramatically due to EBUS-TBNA implementation. Current guidelines for NSCLC diagnostics and staging [5, 6] recommend usage of endosonography for both mentioned indications as a first step, over a traditional surgical approach. The overall sensitivity and negative predictive value of EBUS-TBNA staging in NSCLC reaches 89 and 91%, respectively. New imaging modalities give a chance to further improve performance of lung cancer staging (see **Figure 13**).

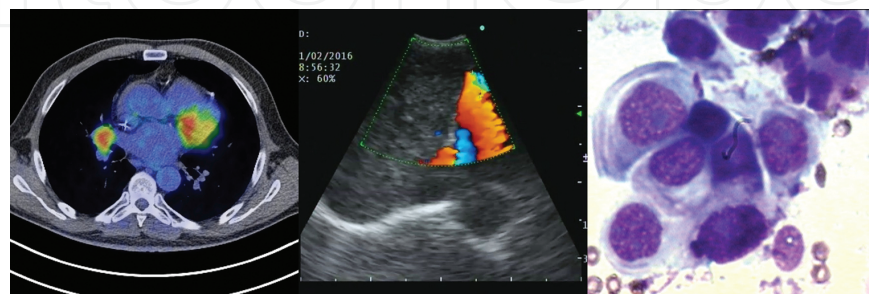


Figure 13. Patient with renal cell carcinoma in anamnesis with PET-positive R12 LN (left), for suspected cancer recurrence EBUS-TVNA (transvascular) was performed using 22G ProFlex needle (middle, note that branch of RPV flows closely to the lesion), cytology (Giemza staining) showed malignant cells (right). Metastatic RCC recurrence.

9.3. Tuberculosis

Tuberculosis is not a popular indication for EBUS because of two main reasons. In countries where EBUS is available, tuberculosis has low prevalence, and reversely—in countries with high TB burden EBUS is too costly procedure to be routinely used for this indication. Nevertheless, several recent meta-analyses [38, 39] showed its sensitivity in patients with TB of 80%. Based on personal experience, authors recommend perform culture, PCR test and Ziel-Nielsen staining in all cases of suspected TB infection, because each investigation modality has an additive effect for final diagnostic yield (see **Figure 14**).

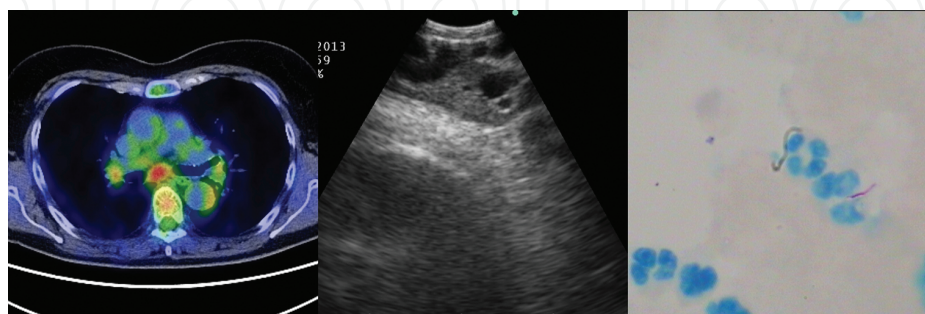


Figure 14. Patient with fever of unknown cause with Hodgkin's lymphoma anamnesis, with PET-positive 7 LN (left), for suspected lymphoma recurrence underwent EBUS-TBNA using 22G ProCore needle (middle, note multiple hypoechoic lesions—necrosis zones), cytology (Ziel-Nielsen staining) showed AFB, both PCR and Bactec tests were positive (right). Mediastinal LN tuberculosis.

9.4. Lymphoma

For decades, diagnosis of lymphoma was mostly surgical. Nowadays, situation began to change dramatically, and EBUS-TBNA becomes a suitable option for this indication [2]. Diagnosis of this disease is a real challenge both for clinician, bronchologist, and cytopathologist. According to the latest data [41], overall sensitivity of EBUS-TBNA in mediastinal lymphomas varies greatly from 38 to 91%, with further surgical confirmation needed in 13–43% of patients. Even in the worst scenario, EBUS-TBNA can possibly lower the need in surgical diagnosis of lymphoma more than by half. As new biopsy instruments and image modalities become available, efficacy of EBUS-TBNA for this indication will apparently increase (see **Figure 15**).

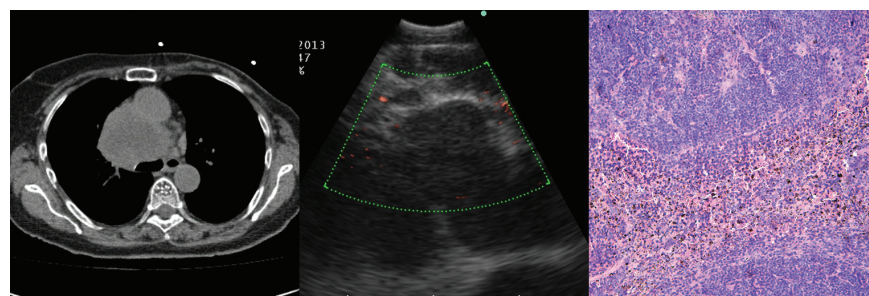


Figure 15. Patient with anterior mediastinal of unknown origin (left), for suspected lymphoma underwent EBUS-TBNA using 22G ProCore needle (middle, note huge hypoechoic mass without blood flow by power Doppler), pathology with HE staining showed widened mantle zone with prominent lymphoid tissue, consequent IHC confirmed Hodgkin's disease (right).

10. Conclusion

Endobronchial ultrasound is a powerful and effective instrument to diagnose mediastinal adenopathies. This technology already changed patient management strategies in sarcoidosis and lung cancer and starts to change situation in tuberculosis and lymphoma. Further developments in imaging modalities and biopsy equipment will give a chance to go beyond current indications of EBUS, provide a new step from diagnosis to treatment of both malignant and benign diseases.

Author details

Ilya V. Sivokozov*, Olga. V. Lovacheva, Irina. Y. Shabalina, Galina V. Evgushenko, Tatyana A. Statsuk, Larisa N. Lepekha, Yuri S. Berezovsky, Natalya N. Makaryants, Larisa N. Chernousova and Elena E. Larionova

*Address all correspondence to: grand63@yandex.ru

Central TB Research Institute, Moscow, Russia

References

- [1] Krasnik M, Vilmann P, Larsen SS, Jacobsen GK. Preliminary experience with a new method of endoscopic transbronchial real time ultrasound guided biopsy for diagnosis of mediastinal and hilar lesions. *Thorax*. 2003;58(12):1083–6.
- [2] Momen M, Wahidi, Felix Herth, Kazuhiro Yasufuku et al. Technical aspects of endobronchial ultrasound-guided transbronchial needle aspiration: CHEST guideline and expert panel report. *Chest*. 2016;149(3):816–835. doi:10.1378/chest.15-1216
- [3] Xiang Y, Zhang F, Akulian J, Yarmus L, Feller-Kopman D, Wang KP. EBUS-TBNA by a new Fuji EBUS scope (with video). *J Thorac Dis*. 2013;5(1):36–9. doi:10.3978/j.issn.2072-1439.2012.12.06
- [4] Felix J. Herth, Daniela Gompelmann, Pallav L. Shah, Ralf Eberhardt. Endobronchial ultrasound-guided TBNA (EBUS-TBNA) with a 19 gauge needle—first experience. *Am J Respir Crit Care Med* . 2015;191:A3726.
- [5] Detterbeck FC, Lewis S, Diekemper R, Addrizzo-Harris D, Alberts W. Diagnosis and management of lung cancer, 3rd ed: American College of Chest Physicians Evidence-Based Clinical Practice Guidelines. *Chest*. 2013;143(suppl 5):7S–37S. doi:10.1378/chest.12-2377.
- [6] Vilmann P, Clementsen PF, Colella S et al. Combined endobronchial and oesophageal endosonography for the diagnosis and staging of lung cancer. European Society of Gastrointestinal Endoscopy (ESGE) Guideline, in cooperation with the European Respiratory Society (ERS) and the European Society of Thoracic Surgeons (ESTS). *Eur Respir J*. 2015;46(1):40–60. doi:10.1183/09031936.00064515
- [7] Yasufuku K, Chiyo M, Sekine Y, Chhajed PN et al. Real-time endobronchial ultrasound-guided transbronchial needle aspiration of mediastinal and hilar lymph nodes. *Chest*. 2004;126:122–128.
- [8] Chuchalin AG, Vizel AA et al. Diagnosis and treatment of sarcoidosis: a summary of federal consensus clinical guidelines. Part 2: Diagnosis, treatment, prognosis. *Bull Contemp Clin*. 2014;7(5):73–81.
- [9] Sivokozov I. First experience with the 22 gauge EchoTip ProCore EBUS needle in cases with suspected lymphoma. *Channel*. 2014;2:12–14.
- [10] Fujiwara T, Yasufuku K, Nakajima T et al. The utility of sonographic features during endobronchial ultrasound-guided transbronchial needle aspiration for lymph node staging in patients with lung cancer: a standard endobronchial ultrasound image classification system. *Chest*. 2010;138(3):641–647. doi:10.1378/chest.09-2006
- [11] Nakajima T, Anayama T, Shingyoji M, Kimura H, Yoshino I, Yasufuku K. Vascular image patterns of lymph nodes for the prediction of metastatic disease during EBUS-TBNA

for mediastinal staging of lung cancer. *J Thorac Oncol.* 2012;7(6):1009–14. doi:10.1097/JTO.0b013e31824cbafa

- [12] Saftoiu A, Vilman P. Endoscopic ultrasound elastography—a new imaging technique for the visualization of tissue elasticity distribution. *Gastrointestin Liver Dis.* 2006;15:161–5.
- [13] Trosini-Desert V, Jeny F, Taillade L, Vignot S, Zribi H, Capron F, et al. Bronchial endoscopic ultrasound elastography: preliminary feasibility data. *Eur Respir J.* 2013;41:477–9.
- [14] Izumo T, Sasada S, Chavez C, Matsumoto Y, Tsuchida T. Endobronchial ultrasound elastography in the diagnosis of mediastinal and hilar lymph nodes. *Jpn J Clin Oncol.* 2014;44(10):956–62. doi:10.1093/jjco/hyu105
- [15] Sivokozov IV, Silina TL, Korolev VN et al. The first experience in using elastography in combination with endobronchial ultrasonography for mediastinal pathology: preliminary assessment of feasibility and comparison of characteristics via different approaches. *Vestn Rentgenol Radiol.* 2014;(4):13–19.
- [16] Rozman A, Malovrh MM, Adamic K et al. Endobronchial ultrasound elastography strain ratio for mediastinal lymph node diagnosis. *Radiol Oncol.* 2015;49(4):334–40. doi: 10.1515/raon-2015-0020
- [17] Ishikawa H, Hirooka Y et al. A comparison of image quality between tissue harmonic imaging and fundamental imaging with an electronic radial scanning echoendoscope in the diagnosis of pancreatic diseases. *Gastrointest Endosc.* 2003;57(7):931–6.
- [18] Sung Ill Jang, Dong Ki Lee. Contrast-enhanced endoscopic ultrasonography: advance and current status. *Ultrasonography.* 2014;33(3):161–169. doi:10.14366/usg.14017
- [19] Kanamori A, Hirooka Y, Itoh A et al. Usefulness of contrast-enhanced endoscopic ultrasonography in the differentiation between malignant and benign lymphadenopathy. *Am J Gastroenterol.* 2006;101(1):45–51.
- [20] Oki M, Saka H, Kitagawa C et al. Randomized study of 21-gauge versus 22-gauge endobronchial ultrasound-guided transbronchial needle aspiration needles for sampling histology specimens. *J Bronchol Interv Pulmonol.* 2011;18:306–310.
- [21] Nakajima T, Yasufuku K, Takahashi R et al. Comparison of 21-gauge and 22-gauge aspiration needle during endobronchial ultrasound-guided transbronchial needle aspiration. *Respirology.* 2011;16:90–94.
- [22] Yarmus L.B, Akulian J, Lechtzin N et al. Comparison of 21-gauge and 22-gauge aspiration needle in endobronchial ultrasound-guided transbronchial needle aspiration: results of the American College of Chest Physicians Quality Improvement Registry, Education, and Evaluation Registry. *Chest.* 2013;143:1036–43.

- [23] Jeyabalan A, Shelley-Fraser G, Medford AR. Impact of needle gauge on characterization of endobronchial ultrasound-guided transbronchial needle aspiration (EBUS-TBNA) histology samples. *Respirology*. 2014;19:735–739.
- [24] Izumo T, Sasada S, Watanabe J, Chavez C, Matsumoto Y, Tsuchida T. Comparison of two 22 G aspiration needles for histologic sampling during endobronchial ultrasound-guided transbronchial needle aspiration (EBUS-TBNA). *Jpn J Clin Oncol*. 2014;44(9): 841–5. doi:10.1093/jjco/hyu095
- [25] Xing J, Manos S, Monaco SE, Wilson DO, Pantanowitz L. Endobronchial ultrasound-guided transbronchial needle aspiration: a pilot study to evaluate the utility of the ProCore biopsy needle for lymph node sampling. *Acta Cytol*. 2016;60(3):254–9.
- [26] Sivokozov I, Lovacheva O et al. Comparative efficacy of endoscopic ultrasound-guided fine-needle aspiration for different 22G needle types using bronchoscope in mediastinal lymphadenopathies of uncertain origin. *Am J Respir Crit Care*. 2014;189:A4403.
- [27] Szlubowski A, Kuzdzał J et al. Ultrasound guided transbronchial needle aspiration as a diagnostic tool for lung cancer and sarcoidosis. *Pneumonol Alergol Pol*. 2008;76(4): 229–36.
- [28] Kim JH, Park SW et al. Meta-analysis for Cyto-Pathological outcomes in endoscopic ultrasonography-guided fine-needle aspiration with and without the stylet. *Dig Dis Sci*. 2016;61(8):2175–84.
- [29] van der Heijden EH, Casal R et al. Guideline for the acquisition and preparation of conventional and endobronchial ultrasound-guided transbronchial needle aspiration specimens for the diagnosis and molecular testing of patients with known or suspected lung cancer. *Respiration*. 2014;88:500–517. doi:10.1159/000368857
- [30] Nakajima T, Yasufuku K, Shibuya K, Fujisawa T. Endobronchial ultrasound-guided transbronchial needle aspiration for the treatment of central airway stenosis caused by a mediastinal cyst. *Eur J Cardiothorac Surg*. 2007;32(3):538–40.
- [31] Casal RF, Jimenez CA, Mehran RJ et al. Infected mediastinal bronchogenic cyst successfully treated by endobronchial ultrasound-guided fine-needle aspiration. *Ann Thorac Surg*. 2010;90(4):e52–3. doi:10.1016/j.athoracsur.2010.06.062.
- [32] Maturu VN, Dhooria S, Agarwal R. Efficacy and safety of transbronchial needle aspiration in diagnosis and treatment of mediastinal bronchogenic cysts: systematic review of case reports. *J Bronchol Interv Pulmonol*. 2015;22(3):195–203. doi:10.1097/LBR.0000000000000174
- [33] Hohenforst-Schmidt W, Zarogoulidis P, Brachmann J et al. Intratumoral chemotherapy for lung cancer: re-challenge current targeted therapies. *Drug Des Dev Ther*. 2013;18(7): 571–83. doi:10.2147/DDDT.S46393

- [34] Mehta HJ, Begnaud A, Penley AM et al. Treatment of isolated mediastinal and hilar recurrence of lung cancer with bronchoscopic endobronchial ultrasound guided intratumoral injection of chemotherapy with cisplatin. *Lung Cancer*. 2015;90(3):542–7. doi:10.1016/j.lungcan.2015.10.009
- [35] von Bartheld MB, van Breda A, Annema JT. Complication rate of endosonography (endobronchial and endoscopic ultrasound): a systematic review. *Respiration*. 2014;87:343–351.
- [36] Agarwal R, Srinivasan A, Aggarwal AN, Gupta D. Efficacy and safety of convex probe EBUS-TBNA in sarcoidosis: a systematic review and meta-analysis. *Respir Med*. 2012;106(6):883–92.
- [37] Evison M, Crosbie PA, Martin J, Bishop P, Doran H, Joseph L, Chaturvedi A, Barber PV, Booton R. EBUS-TBNA in elderly patients with lung cancer: safety and performance outcomes. *J Thorac Oncol*. 2014;9(3):370–6.
- [38] Li W, Zhang T, Chen Y, Liu C, Peng W2. Diagnostic value of convex probe endobronchial ultrasound-guided transbronchial needle aspiration in mediastinal tuberculous lymphadenitis: a systematic review and meta-analysis. *Med Sci Monit*. 2015;16(21):2064–72.
- [39] Ye W, Zhang R, Xu X, Liu Y, Ying K. Diagnostic efficacy and safety of endobronchial ultrasound-guided transbronchial needle aspiration in intrathoracic tuberculosis: a meta-analysis. *J Ultrasound Med*. 2015;34(9):1645–50.
- [40] Trisolini R, Lazzari Agli L, Tinelli C, De Silvestri A, Scotti V, Patelli M. Endobronchial ultrasound-guided transbronchial needle aspiration for diagnosis of sarcoidosis in clinically unselected study populations. *Respirology*. 2015;20(2):226–34. doi:10.1111/resp.12449
- [41] Kheir F, Itani A, Assasa O, Alraiyes AH. The utility of endobronchial ultrasound-transbronchial needle aspiration in lymphoma. *Endosc Ultrasound*. 2016;5(1):43–48. doi:10.4103/2303-9027.175884.

