

We are IntechOpen, the world's leading publisher of Open Access books Built by scientists, for scientists

6,900

Open access books available

185,000

International authors and editors

200M

Downloads

Our authors are among the

154

Countries delivered to

TOP 1%

most cited scientists

12.2%

Contributors from top 500 universities



WEB OF SCIENCE™

Selection of our books indexed in the Book Citation Index
in Web of Science™ Core Collection (BKCI)

Interested in publishing with us?
Contact book.department@intechopen.com

Numbers displayed above are based on latest data collected.
For more information visit www.intechopen.com



Overview of Common and Less Common Ocular Infections

Shimon Rumelt

Additional information is available at the end of the chapter

<http://dx.doi.org/10.5772/65957>

Abstract

Infection may occur in any tissue of the eye, orbit, and adnexa. Infection may spread directly through contact and indirectly through blood vessels (especially valviness veins) and nerves. A proper treatment for ocular infections is imperative because it dictates the prognosis. Ocular infections may share identical clinical finding and be caused by different etiologic agents. To obtain the best outcome, a systematic approach for ocular infections is essential. This chapter describes the characteristic clinical features and manifestations of some common ocular infections and the differentiation between them and inflammations and other diseases even without using new imaging modalities such as confocal electron microscopy, anterior segment optical coherence tomography, and laboratory tests including polymerase chain reaction.

Keywords: diagnosis, treatment, eyelid infections, conjunctiva, cornea, uvea, endophthalmitis, panophthalmitis, intraocular, retina, orbita

1. Introduction

A proper treatment for ocular infections is imperative because it dictates the prognosis. To obtain the best outcome, a systematic approach for ocular infections is essential. This chapter is aimed to describe the characteristic clinical features and manifestations of some common ocular infections and the differentiation between them and inflammations and other diseases even without using new imaging modalities such as confocal electron microscopy and anterior segment optical coherence tomography and laboratory tests including polymerase chain reaction.

Identifying and treating ocular infections can be challenging. Ocular infections may share identical clinical result and be caused by different etiologic agents. The infection is usually named according to the ocular structures involved with the suffix “itis” meaning infectious or noninfectious inflammation.

2. Eyelid infections

Infections of the eyelid include external and internal hordeolum [1]. The first one is abscess localized in the anterior lamella of the eyelid (orbicularis), whereas the internal is located in the posterior lamella (tarsus). Pain and swelling, redness, local tenderness and warmth of the eyelid characterize both. The swelling is well localized. When it is more diffuse, secondary preseptal cellulitis exists.

Preseptal cellulitis is diffuse swelling of one of the eyelids or both [2]. It includes the triad of tenderness (dolor), redness (color) and warmth (calor). The usual cause is eyelid abrasion by trauma. Preseptal cellulitis is distinguished from the more severe orbital cellulitis by the absence of proptosis, limitation of ocular movements and involvement of the optic disc (swelling) because the infection is confined anteriorly by the orbital septum.

Primary herpes simplex infection is characterized by small vesicle on the eyelid that may be accompanied by conjunctival hyperemia [3]. Necrotizing fasciitis is a rapidly progressive infection of the subcutaneous soft tissues that spreads through the fascia and may involve the eyelid and the orbit [4]. The first sign is skin erythema that spreads quickly and changes its color to purple. Later, the skin and subcutaneous tissues may separate from the deep tissues. The patient becomes toxic and suffers of severe local pain. It may be idiopathic or appear after trivial trauma or surgery. The most common causative agents are *A streptococci*, *clostridium* (with gas gangrene) and polymicrobial. Since the disease is fatal, early detection and treatment are essential.

Blepharitis is an bilateral inflammation of the eyelid margins that may be caused by infective agents (**Figure 1**) [5]. Seborrheic blepharitis causes scales over the eyelids and may accompany seborrhea. Staphylococcal blepharitis is clinically characterized by collarettes around the eyelash bases that move along the hair shaft as it grows. It is caused by staphylococcal species. Demodex blepharitis is characterized by sleeves along the base of the lash shaft and is caused by *Demodex folliculorum*. The eyelid margins may be erythematous. Patients may complain for ocular irritation, burning sensation, dryness or bouts of dryness and tearing. They may complain of stickiness or ocular tiredness/tense. Blepharitis may be accompanied by conjunctivitis (i.e. blepharoconjunctivitis) and in this case the eyelid margins show identical signs to blepharitis but the conjunctiva is also inflamed.

Phthiriasis palpebrarum is an infestation of the eyelid margins caused by *Phthirus pubis* [6]. Eggs and adults are found near the base of the eyelashes. Patients may complain from irritation. They are usually from nursery homes and the disease is sexually transmitted.

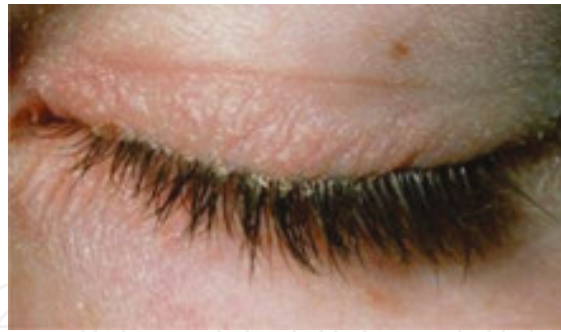

Figure 1. Blepharitis. Note the scales at the base of the eyelashes.

Treatment for localized infection such as hordeolum include warm dry compresses 3–4 times a day for 10 min each and antibiotic ointment until complete resolution is achieved or drainage, if possible. Preseptal cellulitis is treated by antibiotics such as amoxicillin trihydrate 875 mg with clavulanic acid 125 mg (Augmentin®) bid or ceftazidime 1 g/day PO or IV for a week.

Blepharitis can be prevented by eyelid hygiene. Blepharitis is treated by warm dry compresses followed by massage with tetracycline ointment for staphylococcal and seborrhea forms and fusidic acid (Fucithalmic®) for demodex. Topical azithromycin 1% is also very effective. In refractory cases, systemic antibiotics from the tetracycline family such as doxycycline 100 mg 1qd, tetracycline 250 mg qid or azithromycin 200 mg/day PO is added. Terpinen-4-ol, the main component of the essential oil of *Melaleuca alternifolia* (tea tree oil) has been demonstrated for Demodex. Blepharoconjunctivitis is treated similarly with an additional mild topical corticosteroid (such as fluorometholone (FML®) 0/1% qid or loteprednol (Lotemax®) 0.5% qid) for limited period or tear substitutes. Phthiriasis palpebrarum is treated by manual removal of all the mites and ova and treatment of the pubis with yellow mercuric oxide 1%. Necrotizing fasciitis is treated under hospitalization usually in intensive care unit. Treatment includes intravenous penicillin V 500 mg bid or intramuscular benzathine penicillin G 1.2 million units qid, aminoglycoside (e.g., gentamicin 1-1.5mg/kg/day IV tid) and clindamycin 600 mg IV tid in combination with surgical debridement and hyperbaric oxygen. patients that are allergic to penicillin receive either vancomycin 1 g bid and aztreonam 1 g tid with clindamycin instead of penicillin.

3. Conjunctival infections

Conjunctival infections manifested as conjunctival hyperemia [7, 8] (**Figure 2**). Lower eyelid follicles may accompany conjunctivitis. Discharge and preauricular lymphadenopathy may accompany be also present.

Acute conjunctivitis is less than 4 weeks, otherwise it is considered as chronic. Several entities should be mentioned. When conjunctivitis is accompanied by throat pain, fever and malaise, it is suggested as hay fever. When papillae and follicles in both upper and lower eyelids accompany conjunctivitis, adult inclusion conjunctivitis should be suspected. This is a sexually

transmitted disease and both mates should be treated. Gonorrhea conjunctivitis is characterized by copious purulent discharge while other agents cause mucopurulent, mucoid or serous discharge. A form of viral conjunctivitis is hemorrhagic conjunctivitis in which conjunctival hyperemia is accompanied by subconjunctival hemorrhages.

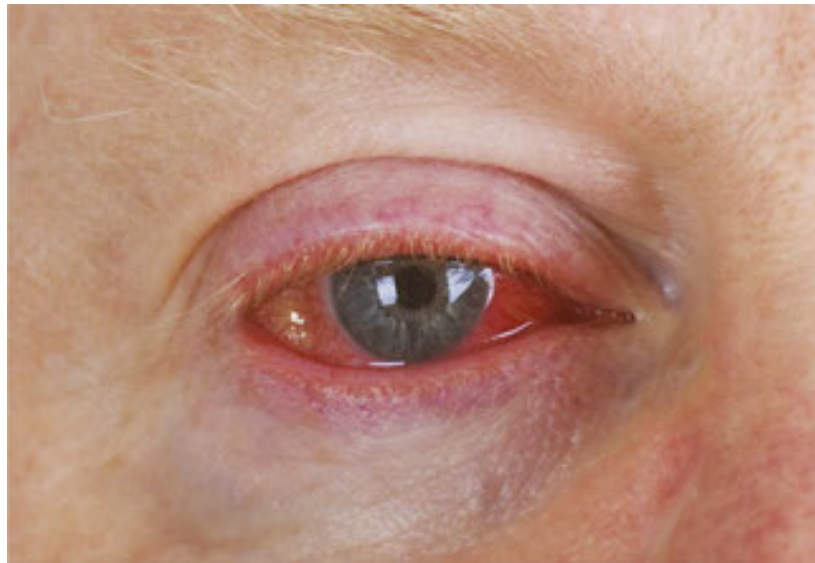


Figure 2. Viral conjunctivitis. Note the conjunctival congestion without corneal or intraocular involvement.

Conjunctival myiasis is conjunctival infestation by larvae of different types of flies depending on the habitat [9]. The larvae are tiny white and move quickly. They cause conjunctival hyperemia and the patient complains of unilateral ocular irritation. Rarely, the larva may migrate into the lacrimal drainage system and cause obstruction.

Infectious agents include bacteria, virus and chlamydia. Most microorganisms cannot invade intact epithelium. The only exceptions are *Neisseria gonorrhoeae*, *Corynebacterium diphtheria*, *Haemophilus aegyptius* and *Listeria*.

Infectious conjunctivitis should be differentiated from noninfectious agents such as allergic conjunctivitis and dry eyes. In neonates occurring in the first month of life, ophthalmia neonatorum is an entity that may be caused by various microorganisms such as chlamydia and less commonly by *Neisseria gonorrhoeae*. Tetracycline 1% or erythromycin 0.5% ointment qid for 3 weeks is effective for prevention and treatment.

Most of the acute viral conjunctivitis forms are self-limited and treatment is aimed to decrease discomfort and prevent secondary infection. Topical antibiotic such as sulfacetamide 10% (Sulfacid®) qid may be applied. In G6PD and sulfa-sensitive patients, other antibiotics such as Gatifloxacin (Zymar®) bid, a quinolon, may be prescribed. It is best to defer topical corticosteroid for a week to ascertain that the conjunctivitis is not herpetic or adenoviral. If no improvement is observed after a week, topical corticosteroid such as fluorometholone (FML®) 0.1% qid may be used for 1–2 weeks in tapered dosage. Patients should be instructed to prevent eye-finger-eye contact (and other contact means) especially with adenoconjunctivitis. The disease

is infective between 7 and 10 days. Hay fever is treated by mild topical corticosteroids such as fluorometholone (FML®) 0.1% qid or loteprednol (Lotemax®) 0.5% and nasal decongestant. Adult inclusion conjunctivitis is treated by topical and systemic tetracycline (e.g. doxycycline hyclate 100 mg once a day or tetracycline 250 mg qid). The mate should be treated as well. Myiasis is treated by removal of all the larvae from the conjunctival sac. Instillation of topical cocaine 4% may be added before removing the larvae to decrease their movement.

4. Corneal infections

The general name for corneal infection or inflammation is keratitis. The conjunctiva is usually secondarily involved as conjunctival hyperemia. The clinical manifestations vary and include corneal ulcer, abscess and/or infiltrate [10]. Corneal ulcer is distinguished from abscess and infiltrate by its staining with fluorescein. Abscess and infiltrate do not stain. The clinical findings may overlap between different etiologies.

The diagnosis of all corneal infections is based on scrapping for direct staining with hematoxylin and eosin or Giemsa, and cultures, which should be taken routinely before commencing with empiric broad-spectrum topical antibiotics. The only exceptions for obtaining corneal scraps and cultures are a marginal (near the limbus) smaller than 3 mm width flat ulcer(s) and certain typical findings such as dendrite suggesting herpetic keratitis or bilateral multiple epithelial minute defects (epitheliopathy) suggesting adenoviral (epidemic) keratoconjunctivitis.

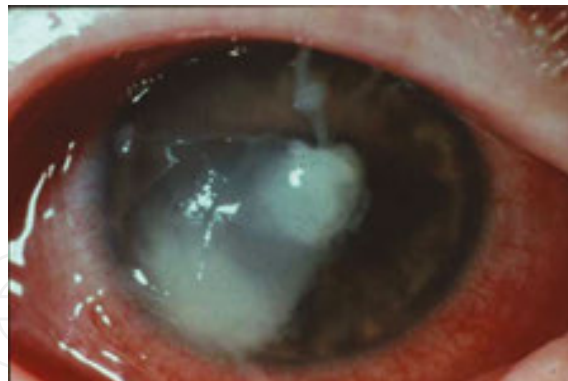


Figure 3. *Pseudomonas aeruginosa* corneal ulcer at the acute stage.

Bacterial keratitis or bacterial ulcer is usually a single solid ulcer with distinctive borders (**Figure 3**). Its size and depth may vary. It may be accompanied by an infiltrate in its base or by localized corneal edema. Infiltrate is white, more dense and distinct and is well localized in contrast to the grayish appearance and less distinctive borders of edema. A grayish, glistening appearance with secretions is a common manifestation of *Pseudomonas* ulcer. Flare and cells or hypopyon may accompany bacterial ulcer and they may be sterile or infected. If they appear under treatment, they indicate worsening of the infectious process. Any flare or

cells in the vitreous in phakic or pseudophakic eyes indicates the development of endophthalmitis. Predisposing factors for corneal ulcer include contact lens wear, ocular trauma, dry eyes and long use of topical antibiotics and/or corticosteroids.

Herpetic keratitis is characterized by dendrites in the secondary infection. In Herpes simplex, dendrites vary in number (usually 1–3). They are coarse with widening of their ends (terminal bulbs) (**Figure 4**). Thus, they differ from Herpes zoster dendrites, which are usually numerous, small, thin and without terminal bulbs (**Figures 5, 6**). Involvement of the tip of the nose (Hutchison's sign) indicates an involvement of the eye on the same side of herpes zoster (**Figure 7**). In repeated Herpes simplex infections, the epithelial defects may form a geographic pattern and may be accompanied by corneal vascularization. An important clinical test is corneal sensitivity, which is reduced in recurrent infections. Another finding is patchy sectorial atrophy of the iris that occurs mainly in the midperiphery after herpetic keratouveitis or uveitis.

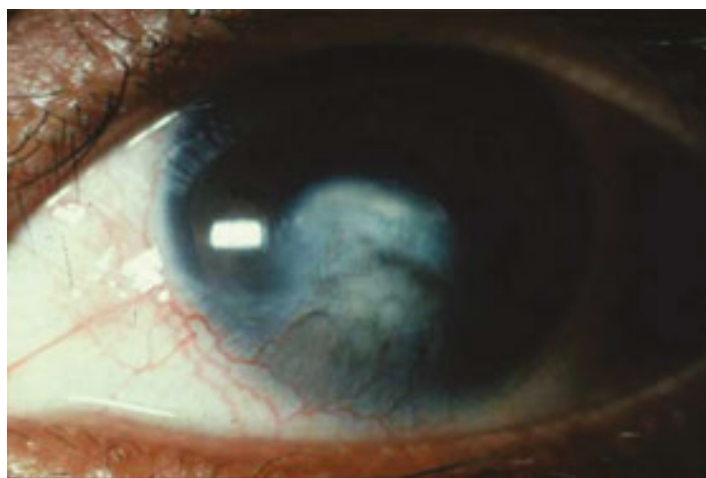


Figure 4. Corneal scar as a result of the ulcer seen in **Figure 3**.

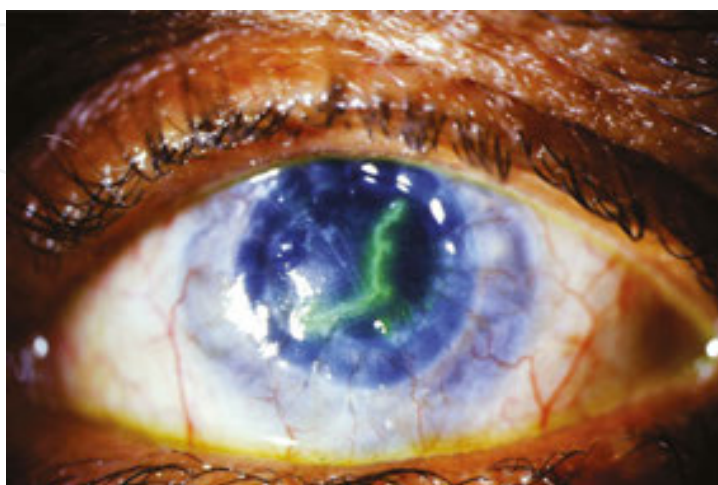


Figure 5. Recurrent herpetic keratitis with dendrite in corneal graft. The dendrite is large and has terminal bulbs.

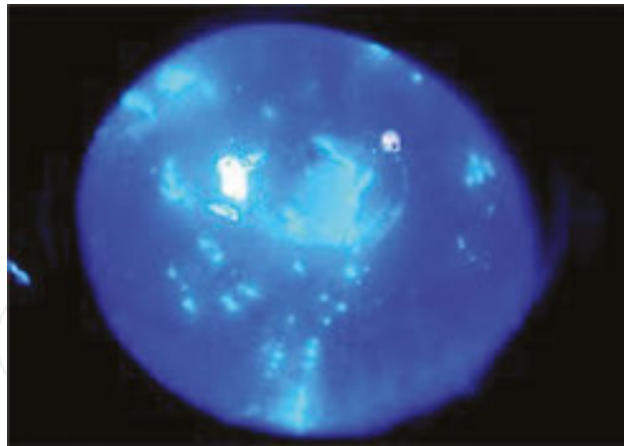


Figure 6. Corneal dendrites in herpes zoster. The dendrites are multiple and very fine. They represent immunologic reaction rather than true infection.

Fungal keratitis appears usually as multiple foci of feathery opacification of the cornea with satellites (**Figures 8 and 9**). Hyphae and yeast may be identified by confocal microscopy in the affected cornea.

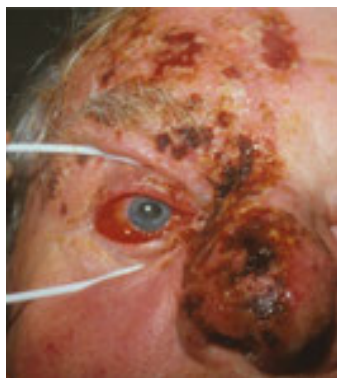

Figure 7. Herpes zoster ophthalmicus. The vesicular rash involves the dermatome innervated by the ophthalmic branch of the trigeminal nerve. Involvement of the tip of the nose indicates involvement of the eye (Hutchison's sign).

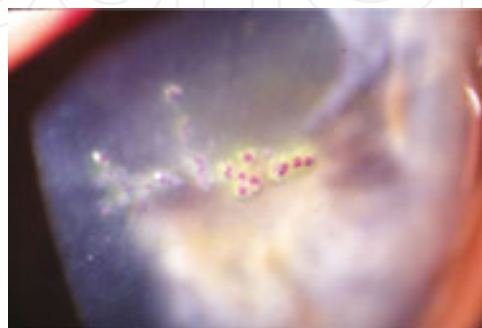


Figure 8. Fungal keratitis. Note the multiple foci.

Acanthamoeba infection may vary in presentation. The earliest clinical signs include multiple corneal epithelial cell swellings (as seen in adenoviral keratoconjunctivitis but here they are unilateral) and/or corneal edema. Late signs include perineural sheathing and stromal ring(s) (**Figure 10**). Acanthamoeba cysts may be identified by confocal microscopy. A history of contact lens wear and/or bathing in pools or sea is common and symptoms of pain are more striking than the clinical appearance. When diagnosis by cultures is impossible especially in recurrent disease, polymerase chain reaction of the involved tissue may establish the diagnosis.

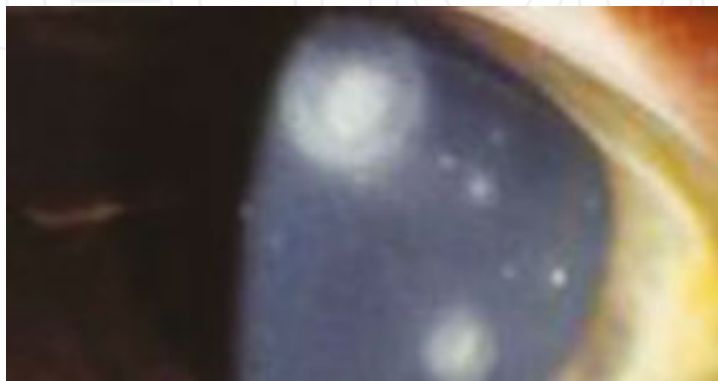

Figure 9. Fungal keratitis with multiple foci and indistinct borders.

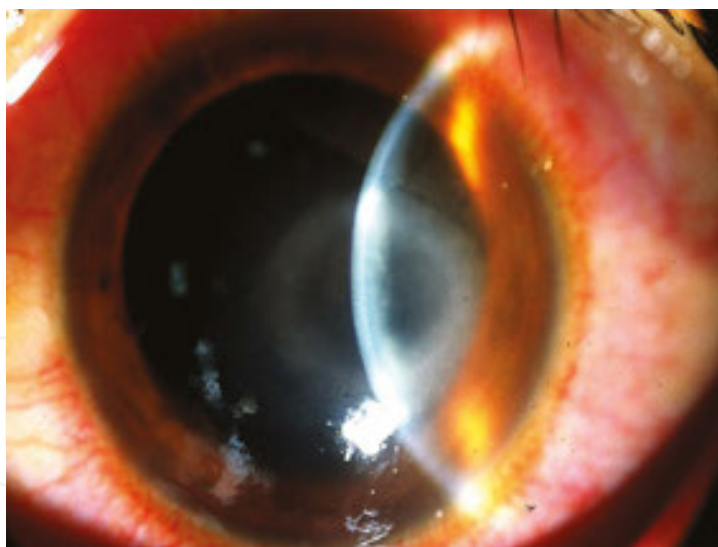


Figure 10. Immune ring in Acanthamoeba keratitis.

Corneal co-infections as other co-infections or mixed infections should be suspected when the course of the disease is atypical or when the condition deteriorates despite of treatment according to cultures and sensitivities. In such cases, repeated cultures should be obtained and broaden accordingly.

All corneal infections may result in either scarring (**Figure 10**) or melting and perforation.

The treatment approach differs between central and peripheral ulcers. Central ulcers are treated with topical antibiotics and are followed frequently to monitor their size and depth. Peripheral ulcers are treated with topical antibiotics and corticosteroids may be cautiously added. Treatment includes broad-spectrum topical antibiotics such as fortified cefazolin and gentamicin or moxifloxacin (Vigamox®) 0.5% every 30 min–1 h until sensitivity is obtained. Then antibiotic treatment is dictated by the sensitivity of the microorganism. In cases of pain and/or flare and cells in the anterior chamber, topical cycloplegic agent (e.g. cyclopentolate hydrochloride 1% tid) is added to decrease the pain originating from the ciliary body and/or prevention of posterior synechiae. Suspicion of infection other than bacteria should be made when no response is achieved or when the condition worsens under treatment. Additional treatment modalities include topical autologous serum, antipolymorphonuclear migration agents such as tetracycline 1% and/ or citrate 10%, which cause decrease of collagenase activity by chelating free calcium ions that are required for collagenase activity. Vitamin A (ascorbic acid) either topically 10% and/or PO (Vitamin A 500 mg bid). Liberal use of partial tarsorrhaphy is useful especially in recurrences of ulcers, exposure, dryness, corneal anesthesia or trophic ulcers and deep ones. All these means should be used in severe ulcer. Topical corticosteroids should be avoided at the acute phase of the keratitis and when the epithelium is not intact because they cause potentiation of collagenase that may lead to perforation and may also promote secondary infection. They may be used in later stage only after the epithelium healed (no corneal staining) to decrease stromal scarring. If descemetocoele occurs, several surgical options exist and include anterior corneal grafts such as deep anterior lamellar keratoplasty (DALK) or non-Descemet's membrane endothelial keratoplasty (DMEK). A relatively historic treatment is placement of hystoacryl for corneal perforation or descemetocoele. This promotes healing but also corneal vascularization, which impairs vision. Conjunctival flap (Gunderson operation) is indicated for perforation only for eyes with no potential for vision.

5. Endophthalmitis

The hallmarks of endophthalmitis are flare and white cells both in the vitreous and the anterior chamber [11]. Additional findings may include fibrin in the anterior chamber, hypopyon and retinal periphlebitis. The vision is decreased and ocular pain is noted.

Endophthalmitis is divided to two categories: exogenous (postoperative, bleb-associated and traumatic) and endogenous (source within another organ). Postoperative endophthalmitis may occur following any intraocular surgery including cataract, penetrating keratoplasty, glaucoma, vitrectomy and intraocular injections. Rarely, it may develop by spreading of keratitis or scleritis. In bleb-associated endophthalmitis, the bleb is pale and necrotic. Endophthalmitis should be suspected in any eye after penetrating keratoplasty if epithelial defect or ulcer is present near the corneal-graft interface even if there is corneal edema or signs suggesting corneal graft rejection (presence of flare and cells in the anterior chamber).

Prevention of endophthalmitis before any ocular surgery is by preparation with povidone iodide 5% that includes washing of the ocular periocular and surface. Prevention following

penetrating ocular trauma injury is by intravenous broad-spectrum antibiotics (e.g. ciprofloxacin 400 mg bid) for 3 days. The data about treatment of endophthalmitis are based mainly on postoperative (cataract extraction) endophthalmitis. When endophthalmitis is suspected, vitreous samples for smears, cultures and sensitivity should be obtained before commencing antibiotic treatment. Treatment includes intravenous broad-spectrum antibiotics such as vancomycin 1 gr bid and ceftazidime 1 gr tid or moxifloxacin 400 mg/day IV as well as periocular injections and topical. Topical and/or systemic corticosteroids may be added only after the regression of the endophthalmitis.

6. Intraocular infections

Intraocular infections may involve different intraocular structures. Primarily they affect the uveal tissues (choroid, ciliary body and iris), the retina and secondarily the vitreous [12, 13]. Therefore, they may be manifesting as uveitis and/or choroidal and/or retinal lesions and the differential diagnosis is from inflammation (sterile) disorders.

Uveitis may be divided either by location to anterior; intermediate (pars planitis) and posterior, by clinical features: granulomatous versus non-granulomatous and etiology: bacterial, viral, fungal, protozoan and helminthic.

Patients may complain of ocular pain, decreased vision and/or ocular redness. The clinical signs vary. In uveitis, the anterior uvea is affected and white cells and flare are encountered in the anterior and posterior chamber and in the anterior third of the vitreous (behind the lens). Keratic precipitates (inflammatory cells and debris) over the endothelium and hypopyon may exist. The precipitates may be fine as in nongranulomatous uveitis or large and coarse (mutton fat) in granulomatous uveitis. In intermediate uveitis, the pars plana may be covered by inflammatory white band and vitreous veils resembling snowballs may be found. In posterior uveitis, white cells and flare involve the posterior 2/3 of the vitreous. They may be accompanied by retinal, choroidal or chorioretinal lesions. These lesions are key element in clinical diagnosis, which may be made by the involved tissues (retina, choroid or both), location (posterior pole, peripapillary or periphery), size, color and number of lesions (**Table 1**). For definitive diagnosis, laboratory tests are usually required.

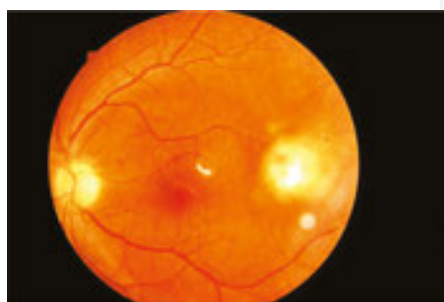

Figure 11. Toxocara retinochoroiditis. Note the active white lesion. It may appear adjacent to a chorioretinal scar.

Treatment should be first aimed at the offending microorganism. Topical and systemic antimicrobial are being used. Topical corticosteroids may be added in the absence of corneal ulcer. Systemic corticosteroids are being added if the offending microorganism is covered and the center of the macula is being threatened or involved by the infectious process.

Diagnosis	Tissue	No. of lesions	Color	Size	Location
Toxoplasmosis (Figure 11)	chorio-retina	1–3	White cream—new; usually near black—old scar, vitritis		Posterior pole, peripapillary
Toxocara (Figure 12)	Retina	One	White—elevated, TRD	1–2DD	Posterior pole
Tuberculosis	Choroid	1-multiple	Tuberculoma—white, round, elevated, indistinct margins, macular star	0.3–2DD	Posterior pole, midperiphery
Cytomegalovirus (CMV) (w or w/o HIV) (Figure 13)	Chorio-retina	Several	White areas with intraretinal hemorrhages, granular borders (Pizza pie)	Several DD	Everywhere
Acute retinal necrosis (herpetic) (Figure 14)	Retina	One	Confluent white-yellow, sharp irregular scalloped posterior margins, w or w/o intraretinal hemorrhages later replaced by atrophy and pigmentation	Several DD	Periphery
Syphilis	Sub-retina (chorio-retina)	Multiple, bilateral	Yellowish pale placoid lesions, optic nerve involvement	Variable	Anywhere, a mimicking disease
Cat scratch	Optic disc and retina		Optic disc edema with macular star	1–2 DD	Posterior pole
Candidiasis	Chorio-retina	Multiple	White faint with faint borders	0.5 DD	Posterior pole
Histoplasmosis	Choroid	Multiple	Small round lesions	0.2 DD	Anywhere

Table 1. TRD—traction retinal detachment; DD—disc diameter.

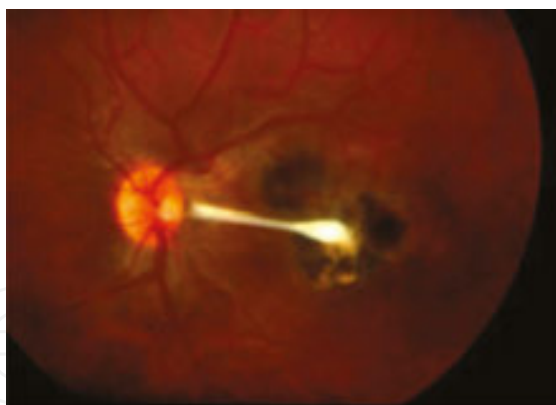


Figure 12. Toxocara chorioretinitis. Note the whitish lesion that may represent shrunk larva. Traction retinal detachment may occur.

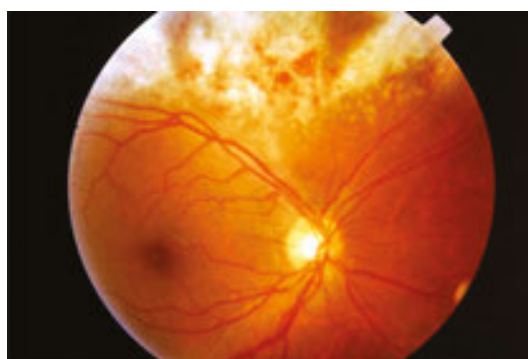

Figure 13. Cytomegalovirus (CMV) retinitis. Note the white lesions and intraretinal hemorrhages.

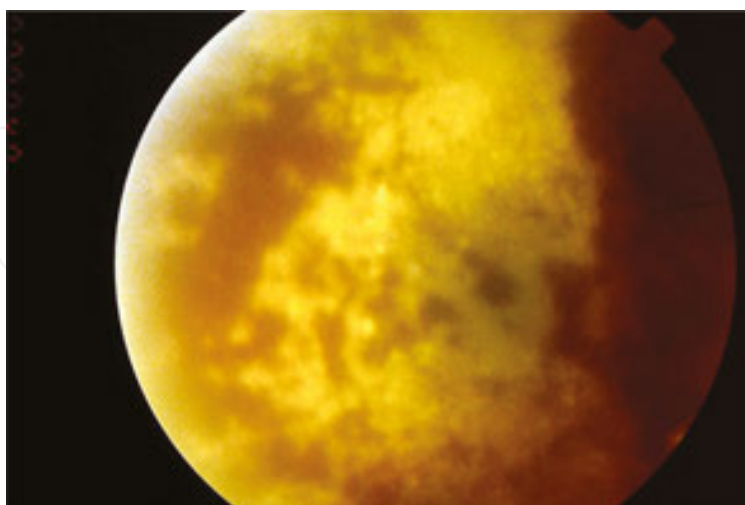

Figure 14. Acute retinal necrosis. Note the whitish lesion without retinal hemorrhages. The lesion is blurred by the inflammation in the vitreous.

7. Orbital infections

The hallmarks of orbital cellulitis include proptosis (exophthalmos) and limited ocular motility and/or involvement of the optic disc (decreased best-corrected visual acuity, positive afferent pupillary defect (Marcus Gunn) and/or swelling of the optic disc) [14, 15] (**Figure 15**). These findings differ from the signs of preseptal cellulitis in which swelling, erythema, heat and sensitivity of the eyelids occur. In both cases, the disease is usually unilateral. Orbital cellulitis in diabetic or immunocompromised patients should be considered as mucormycosis unless otherwise proven. Eschar of the oropharynx or the nose appears late and only in 10% of the patients with mucormycosis. Therefore, it should not be a sign to relay on. Bilateral orbital cellulitis may suggest of cavernous sinus thrombosis and diagnosis is made by computerized tomography. The clinical findings of cavernous sinus thrombosis are exophthalmos, unilateral or bilateral external and internal ophthalmoplegia that are usually accompanied by malaise and systemic fever (**Figure 16**). Nuchal rigidity as part of meningeal signs may also occur. Confirmation of the diagnosis is made by lumbar puncture. In orbital cellulitis and cavernous sinus thrombosis, blood cultures should be obtained when the body temperature increases to or over 39°C. In older patients, blood cultures are being obtained even if the temperature is normal. The source of the infection should be established by physical examination of the nose and mouth and imaging techniques (computed tomography and/or magnetic resonance imaging of the orbits and head. In contrast to preseptal cellulitis that is caused by infection from superficial skin wound, orbital cellulitis is most commonly caused by sinusitis (ethmoidal). Other sources may be upper jaw tooth abscess, otitis, mastoiditis, orbital osteomyelitis or extension from neglected preseptal cellulitis. Contamination may be by direct spreading through natural dehiscence sites and openings (foramina), veins, which are valveless or even nerves.

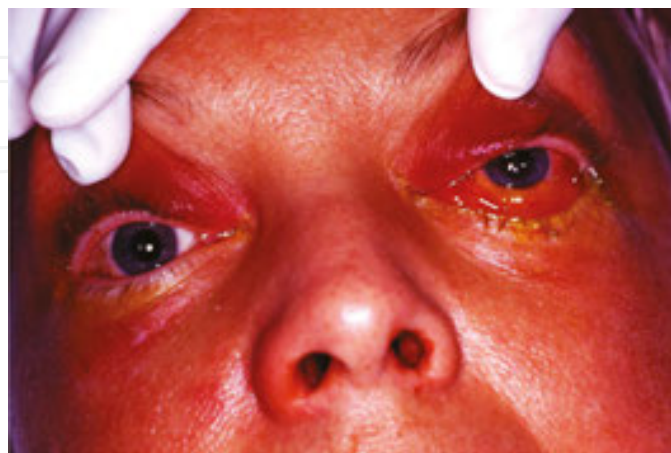

Figure 15. Cavernous sinus thrombosis in a diabetic patient. There was external ophthalmoplegia. The cause was mucormycosis.

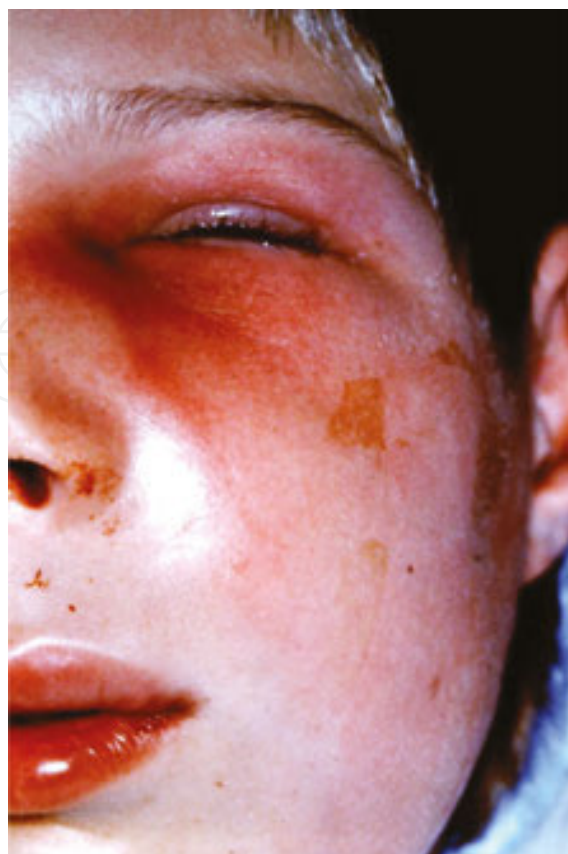

Figure 16. Orbital abscess as a result of tooth abscess. Note the erythema and swelling of both eyelids and cheek.

Orbital abscess is a complication of orbital cellulitis (**Figure 16**) [16, 17]. It should be suspected when orbital cellulitis aggravates despite treatment. When aggravation occurs, repeated orbital computerized tomography assists in confirming the diagnosis of orbital abscess. In such a case, drainage of the abscess and continuing systemic antibiotics is required. The source of the infection should also be treated by surgical drainage. In cases of sinusitis, functional endoscopic sinus surgery (FESS) or other procedures with removal of the sinus mucosa may be required to prevent recurrences.

Note: The antibiotic dosage is for adults. The author is not responsible for the dosage or for any use of antibiotics.

Author details

Shimon Rumelt

Address all correspondence to: shimon.rumelt@naharia.health.gov.il

1 Western Galilee, Nahariya Medical Center, Nahariya, Israel

2 Faculty of Medicine, Bar Ilan University, Zefat, Israel

References

- [1] Lederman C, Miller M. Hordeola and chalazia. *Pediatr Rev* 1999;20(8):283–284.
- [2] Babar TF, Zaman M, Khan MN, Khan MD. Risk factors of preseptal and orbital cellulitis. *J Coll Physicians Surg Pak* 2009;19:39–42.
- [3] Jackson WB. Blepharitis: current strategies for diagnosis and management. *Can J Ophthalmol* 2008;43:170–179.
- [4] Hakkarainen TW, Kopari NM, Pham TN, Evans HL. Necrotizing soft tissue infections: review and current concepts in treatment, systems of care, and outcomes. *Curr Probl Surg* 2014;51:344–362.
- [5] Raskin EM, Speaker MG, Laibson PR. Blepharitis. *Infect Dis Clin North Am* 1992;6:777–787.
- [6] The Wills eye manual, 6th ed. 2012.
- [7] Arfa RC, Grayson's diseases of the cornea, 3rd ed. St. Louis: Mosby. 1991.
- [8] Guideline: American Academy of Ophthalmology cornea/external disease panel. Preferred Practice Pattern Guidelines. Conjunctivitis. San Francisco, CA. 2008.
- [9] Panadero-Fontán R, Otranto D. Arthropods affecting the human eye. *Vet Parasitol* 2015; 208: 84–93.
- [10] Park J, Lee KM, Zhou H, Rabin M, Jwo K, Burton WB, et al. Community practice patterns for bacterial corneal ulcer evaluation and treatment. *Eye Contact Lens* 2015;41:12–18.
- [11] Rowsey JJ, Jensen H, Sexton DJ. Clinical diagnosis of endophthalmitis. *Int Ophthalmol Clin* 1987;27:82–88.
- [12] Sudharshan S, Ganesh SK, Biswas J. Current approach in the diagnosis and management of posterior uveitis. *Indian J Ophthalmol* 2010;58:29–43.
- [13] Khairallah M, Chee SP, Rathinam SR, Attia S, Nadella V. Novel infectious agents causing uveitis. *Int Ophthalmol* 2010;30:465–483.
- [14] Bergin DJ, Wright JE. Orbital cellulitis. *Br J Ophthalmol* 1986;70:174–178.
- [15] Rumelt S, Rubin PA. Potential sources of orbital cellulitis. *Int Ophthalmol Clin* 1996;36:207–221.
- [16] Harris GJ. Subperiosteal abscess of the orbit. *Arch Ophthalmol* 1983;101:751–757.
- [17] Liao JC, Harris GJ. Subperiosteal abscess of the orbit: evolving pathogens and the therapeutic protocol. *Ophthalmology* 2015;122:639–647.

