

# We are IntechOpen, the world's leading publisher of Open Access books Built by scientists, for scientists

6,900

Open access books available

185,000

International authors and editors

200M

Downloads

Our authors are among the

154

Countries delivered to

TOP 1%

most cited scientists

12.2%

Contributors from top 500 universities



WEB OF SCIENCE™

Selection of our books indexed in the Book Citation Index  
in Web of Science™ Core Collection (BKCI)

Interested in publishing with us?  
Contact [book.department@intechopen.com](mailto:book.department@intechopen.com)

Numbers displayed above are based on latest data collected.  
For more information visit [www.intechopen.com](http://www.intechopen.com)



---

## New Concepts on Safer Abdominoplasty

---

Guillermo Blugerman, Diego Schavelzon,  
Boris Martínez, Gabriel Wexler,  
Andrea Markowsky and Marcelo Lotoki

Additional information is available at the end of the chapter

<http://dx.doi.org/10.5772/65093>

---

### Abstract

Abdominoplasty was one of the first techniques described in literatura, and in some of his writings, Hippocrates mentioned the resection of skin and the apron-like abdominal flaps. The first standardization of this procedure was carried out by H.A. Kelly, who was a gynecologist, in 1890, but the procedure gained some popularity when Pitanguy published his report in 1967. With the advent of liposuction, they tried to replace abdominoplasty; however, in many cases, they yielded unreliable results. It was in the year 2000, with the advent of the pull down abdominal flap technique proposed by Avelar and then spread by Saldanha, surgeons significantly increased the indications for abdominoplasty. This was reflected in international statistics since abdominoplasty climbed from the 15th place in the 1990s to the 4th place in 2012. According to some publications, traditional abdominoplasty generally includes extensive dissection of upper abdominal flap all the way to the costal margin with a consequent decrease of blood flow of 50–70%. We present a technique with no flap undermining, including in-bloc resection of premarked área from the umbilicus scar to the suprapubic area, dissecting the tissue with an instrument called Iconoclast, thus preserving blood flow, after hydrodissection with tumescent solution, which varies if the patient is under general anesthesia or sedation. It has been shown that simultaneous liposuction of flap and flanks in the conventional abdominoplasty technique increases the risk of necrosis and seromas, so in many cases it is contraindicated. Therefore, our technique allows us to perform the liposuction of the upper abdominal flanks and waistline without running any risks. In this technique umbilicus scar its recreated with the use of skin graft. Unlike conventional abdominoplasty techniques, the presence of previous abdominal wall scars is not a limitation. In the case of smokers patients, risks are reduced by keeping the blood flow of the upper flap constant. We do not recommend this technique for very thin patients, with multiple pregnancies and regularly an important rectus muscles diastasis where we indicate the abdominal wall vertical plication.

**Keywords:** TULUA, conventional abdominoplasty, laser lipolysis, hydrodissection, neoumbilicus

---

## 1. Introduction

Abdominoplasty was one of the first techniques described in medical-surgical literature. In some of his writings, Hippocrates mentioned the resection of skin and the apron-like abdominal flaps. The first standardization of the procedure was carried out by H.A. Kelly, who was a gynecologist, in 1890 [1] but only gain some popularity when Pitanguy published his report in 1967 [2].

Although the abdomen is the part of the body that undergoes most changes during pregnancy due to changes in body weight, these techniques did not gain in popularity because of the high rate of complications that this surgery had regardless of the surgeon's experience.

With the advent of liposuction, in many cases it attempted to replace abdominoplasty, obtaining dissimilar and unreliable results.

It was in the year 2000, with the advent of the pull down abdominal flap technique proposed by Avelar [3] and then spread by Saldanha [4], when surgeons significantly increased the indications for abdominoplasty. This was reflected in international statistics since abdominoplasty climbed in popularity from the 15th place in the 1990s to the 4th place in 2012. This increase is linked to a higher number of bariatric surgeries, resulting in a greater number of patients interested in skin rehabilitation procedures, but it is also linked to the fact that surgeons felt more confident to obtain acceptable results with less risk to the patient and to the surgeon himself.

Since 1999 in our practice, we have been performing Juarez Avelar's technique—albeit modified by us—to work with tumescent anesthesia. Despite a significant reduction in the rate of serious complications, we continue to see a few cases of dehiscence of the flap, and infections by the presence of subcutaneous devitalized tissues likely to be colonized by skin flora bacteria. In February 2013 we attended the lecture delivered by Dr. Francisco Villegas about his personal technique called with the acronym TULUA (Transverse plication, no Undermining, full Liposuction, neoUmbilicoplasty, Abdominoplasty) in the ISAPS Congress in Santiago de Chile

We found very interesting concepts in this presentation, and that is why after our return we implemented a modified protocol in order to perform this technique with the assistance of tumescent anesthesia. For 18 months we performed 188 tucks with this new technique with a very low complication rate.

## 2. History

In 1890, Demars and Marx reported the first limited tummy tuck in France. H.A. Kelly, a surgeon gynecologist, was the first to report this procedure in the US, which took place at Johns Hopkins hospital in Baltimore in 1899. Kelly called this procedure “transverse abdominal lipectomy”. In Germany in 1909 S. Weinhold [5] reported the cloverleaf incision, a combination of vertical and oblique incisions.

In 1916, W. Babcock [6] was the first to report the vertical elliptical resection with wide undermining of the abdominal wall. In 1918, E. Schepelmann [7] modified the Babcock elliptical incision into transverse teardrop incision extending from the xiphoid appendix to the pubis. This resulted in a better contouring of the lower abdomen.

In 1924, M. Thorek [8] described the technique of placing the incision below the umbilicus in a transverse fashion and removing excess skin and fat down to the fascia in a wedge-shaped form. He called this technique plastic “adipectomy”. This researcher described the removal of the umbilicus if required in a crescent incision and transplanting it to the new place as a composite graft. In 1931, M. Flesh-Thebesius and K. Wheisheimer [9] modified Thorek’s incision and included the umbilicus. In 1949, I.F. Pick [10] reported his technique, followed by A.J. Barsky [11] in 1950, which was a modification of the Thorek transverse incision with the addition of the vertical incision at its ends.

In 1955, M. Galtier [12] reported the four quadrants resection technique. Vernon in 1957 reported his low transverse abdominal incision procedure with wide undermining and transposition of the umbilicus. This was followed by C. Dufourmentel [13] and R. Mouly [14] in 1959, which included Vernon’s technique [14] with the addition of a small vertical incision at the midline.

M. Gonzalez-Ulloa [15] in 1960 and Dubouset J.R. Vilain [16] in 1964 reported a similar technique to I.F. Pick and A.J. Barsky’s circular abdominoplasty. In 1965, Spadafora [17] described a similar technique to Vernon’s, but he lowered the incision to a less conspicuous site. His incision started at the center, curving around the mons pubis, and then at the inguinal crease the incision curved upward toward the anterior superior iliac spine.

When reviewing the literature up to 1967, researchers divided the tummy tuck procedure into three main categories:

- (1) Surgeons who favored transverse incision, (2) those who favored the vertical incision, and (3) those who described a combination of transverse and vertical incisions.

In 1967, Pitanguy published his technique, which was considered to produce successful results. From 1967 to 1975 he reported more than 500 cases of abdominoplasty and mammoplasty performed simultaneously.

In 1972, P. Regnault [18] reported “W” shaped incision technique which was later modified in 1975. In 1978, J. Planas [19] advocated the “vest over pants” technique. The belt lipectomy was replaced by suction-assisted lipectomy and abdominoplasty in 1980, which was popularized



by Y. Illouz. Between 2000 and 2004, Avelar together with Saldanha published the concept of Lipoabdominoplasty.

### 3. Anatomy

The anterolateral abdomen is divided into nine regions by four imaginary planes: two vertical (medioclavicular/midinguinal) and two horizontal (transpyloric/intertubercular) planes. The transpyloric plane corresponds to the midpoint between the umbilicus and the xiphoid appendix, crossing the pylorus at the lower border of the first lumbar vertebra. The subcostal plane that passes across the costal margins and the upper border of the third lumbar vertebra can be used instead of transpyloric plane. The lower horizontal plane, designated as the intertubercular line, crosses the anterior abdomen at the level of the fifth lumbar vertebra, and connects the anterior superior iliac spines on both sides. Thanks to these planes, these 9 regions are formed (epigastric region, hypochondriac region, flanks, mesogastric region, umbilicus and iliac fossa) [20].

The anterolateral abdominal wall consists, from the outside in, of the skin, superficial fascia, deep fascia, external and internal abdominal oblique, transverse abdominis, rectus abdominis and pyramidalis, as well as the transversalis fascia.

#### 3.1. Blood supply

The abdominal wall receives blood supply through branches of the femoral, external iliac, subclavian and intercostal arteries as well as from the abdominal aorta. These branches include the superficial epigastric, superficial circumflex iliac, superficial external pudendal, deep circumflex iliac, superior and inferior epigastric, posterior intercostal, subcostal, musculophrenic, and lumbar arteries.

#### 3.2. Venous drainage

It is drained via the superficial epigastric, thoracoepigastric, paraumbilical and the superficial circumflex iliac veins [21].

#### 3.3. Innervation

The skin of the anterior abdominal wall is innervated by the ventral rami of the lower five or six thoracic (thoracoabdominal) spinal nerves that continue from the intercostal spaces into the abdominal wall. The anterolateral abdominal also receives nerve fibers from the anterior roots of the twelfth thoracic pair (subcostal) and from the iliohypogastric, and ilioinguinal nerves. Each intercostal nerve is connected to a sympathetic ganglion by a connecting adjacent white branch that carries presynaptic sympathetic fibers, and a communicating branch gray transmitting postsynaptic sympathetic fibers [22].

## 4. Research methods

Scientific basis of traditional abdominoplasty.

According to some publications, traditional abdominoplasty generally includes extensive dissection of the upper abdominal flap all the way to the costal margin with a consequent decrease of blood flow of 50–70%. Furthermore, this technique involves the vertical plication of the fascia of the rectus abdominis muscles and certain techniques of the oblique muscles, demanding traumatic separation maneuvers of the flap which results in trauma on adipose tissue that is also exposed to surgical environment for a long time. It has been shown that simultaneous liposuction of flap and flanks in conventional abdominoplasty increases the risk of seroma and necrosis, so it is contraindicated in many cases.

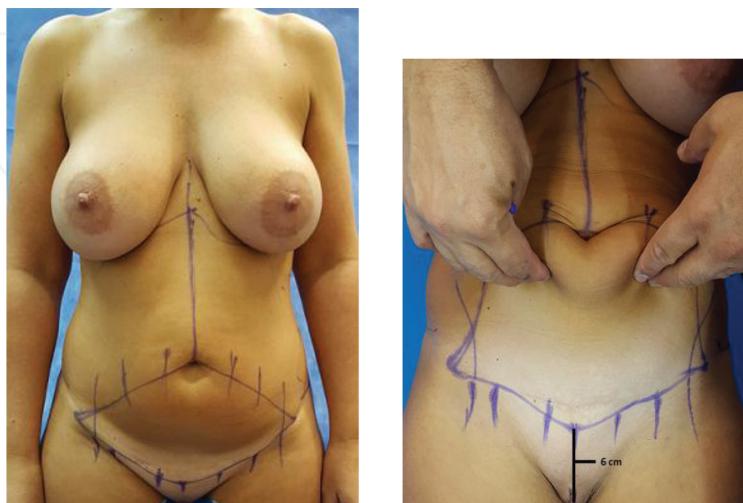
In most conventional techniques, reinsertion of the umbilicus is performed by exteriorization through an incision in the flap and suturing techniques of different designs [23].

### 4.1. Patient selection

Unlike other conventional abdominoplasty techniques, the presence of previous abdominal wall scars is not a limitation for this procedure. In the case of patients who smoke, risks are reduced by keeping the blood flow of the upper flap constant. We do not recommend this technique for very thin patients, with multiple pregnancies and regularly an important rectus muscles diastasis where we indicate the abdominal wall vertical plication in combination with the transverse one.

### 4.2. Surgical technique

Preoperative photographs are taken with the patient in a standing position. For marking surgeons can use laser levels as those used in architecture which allow us to draw lines and reference points in a symmetric fashion.

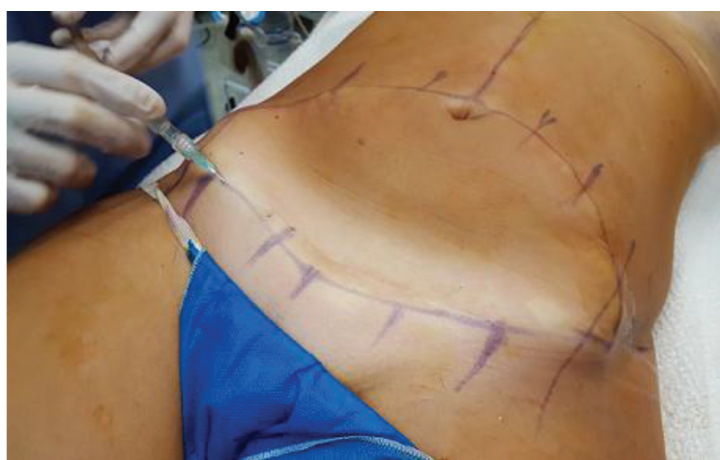

**Figure 1.** Surgical resection design on the anterior abdominal Wall.

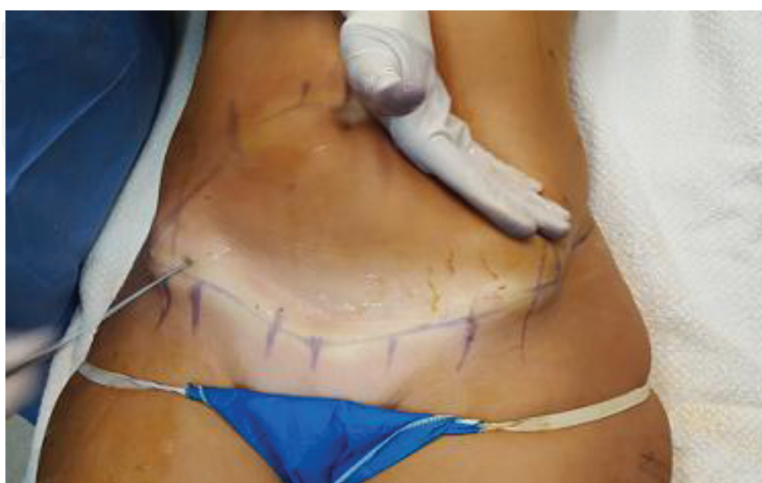It is very important to use a good quality, long lasting surgical skin marker so that the lines are not erased during liposuction with tumescent anesthesia and glove rubbing on the skin.

The first line to mark is the vertical line that goes from xiphoid to anterior vulvar commissure. This is very important because the umbilicus will be located on this line. The lower edge of the lozenge, indicating the place of the scar, is usually planned 6 cm above the superior vulvar commissure to ensure an anatomically regular pubis. The lozenge marked, must be mented by vertical lines that guide us when closing the wound (**Figure 1**).

This surgery can be performed under general, regional, or local tumescent anesthesia. In all cases we use local tumescent infiltration, but the concentration of lidocaine varies. If the patient is under general or regional anesthesia we use solutions that contain 300 mg of lidocaine per liter; however, when we don't work with benerl anesthesia we use 600 mg per liter of saline solution.



**Figure 2.** Superficial tumescent local anesthesia infiltration with a 50/8 needle and peristaltic pump.

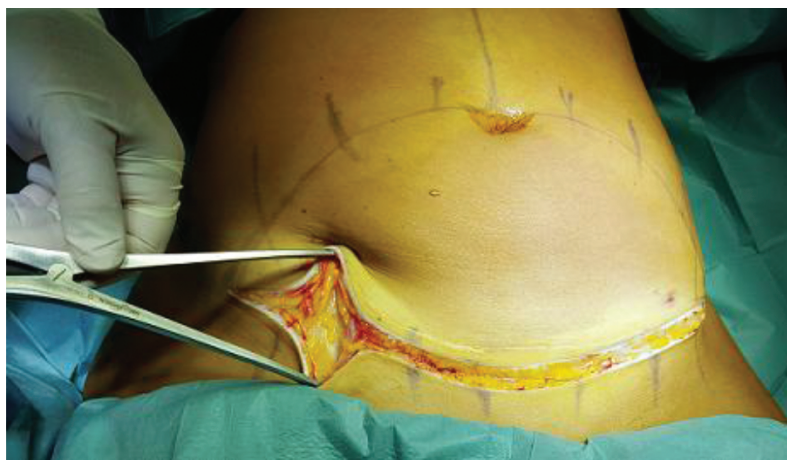

**Figure 3.** Suprafascial tumescent hidrodissection.

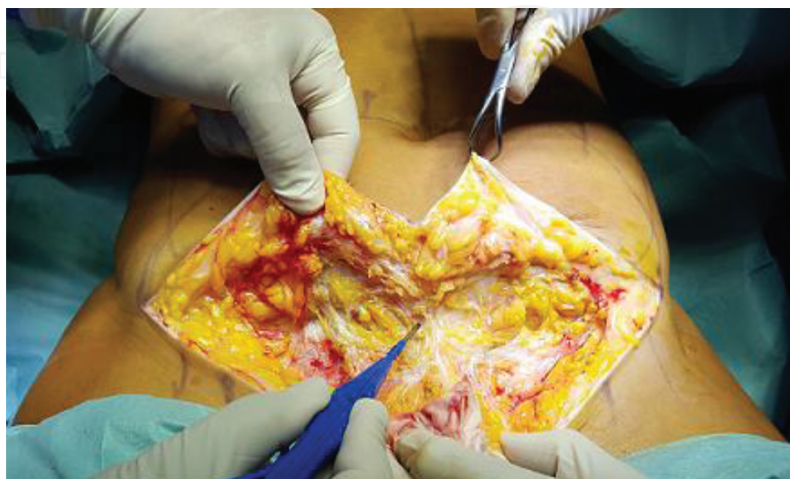Two different types of anesthetic infiltration are performed. In the areas where liposuction is performed, all planes of subcutaneous tissue are infiltrated, starting by the deepest layer until reaching more superficial subcutaneous layers. The area to be resected is hydrodissected with 500 cc of anesthetic solution just above the aponeurotic fascia using a 2.5-mm blunt tip cannula. In addition, it is infiltrated with a 50/8 needle below the lines on which the incision will be made, **Figures 2 and 3**.

After finishing the local anesthesia infiltration, laser assisted liposuction of previously marked and infiltrated areas is performed, making sure to preserve the fat in the area where the new umbilicus will be placed so that it has the correct depth.

Once liposuction, which usually covers the superior abdomen and flanks, is finished, we disinfect the surgical field by changing the surgical gloves of the surgical team to reduce the risk of contamination.



**Figure 4.** Dissection of adipose tissue with an instrument called Iconoclast.



**Figure 5.** Redundant block integument dissection between the fat and the anterior fascia.

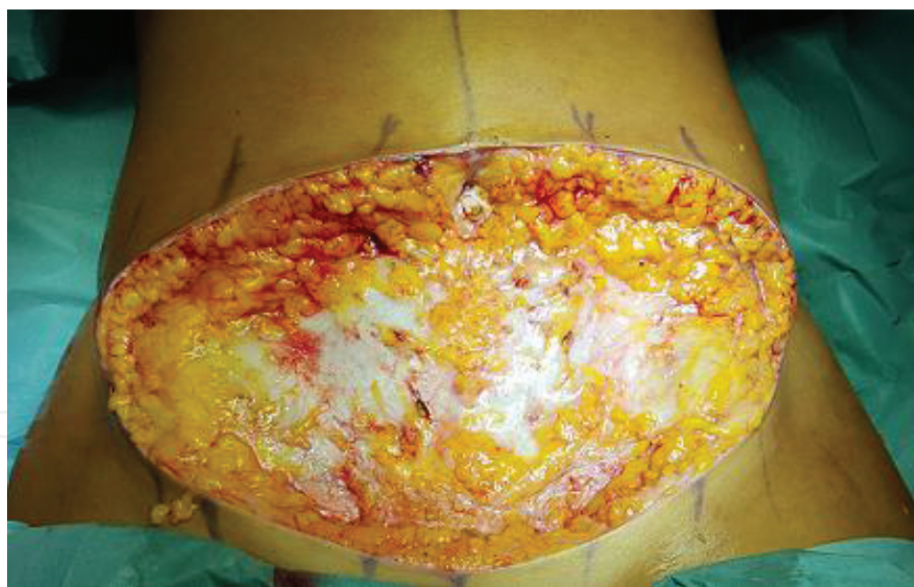

The skin is incised superficially to expose adipose tissue and dissection is performed with an instrument known as Iconoclast [4] that facilitates the identification of blood vessels running under the skin, which are cauterized by the assistant doctor as they become visible. The Iconoclast allows, if necessary, the preservation of scarpa fascia as shown in **Figures 4, 5 and 6**.

Once the lower border of the cutaneous adipose island/tissue is dissected, we advance over the aponeurosis, cauterizing perforating vessels in its emergence from the fascia.

All these dissection maneuvers can be performed with minimal bleeding thanks to the combination of hydrodissection and the use of the Iconoclast together with the simultaneous cauterization of vessel.

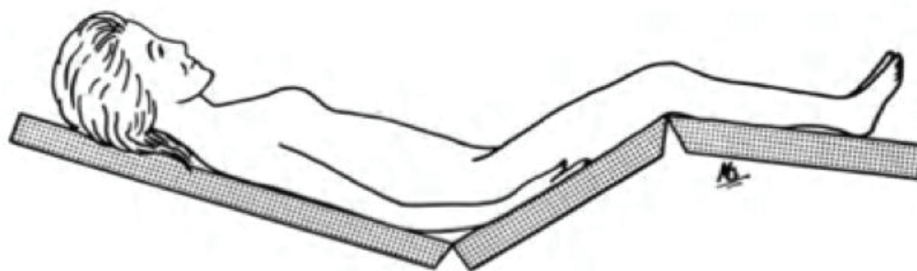
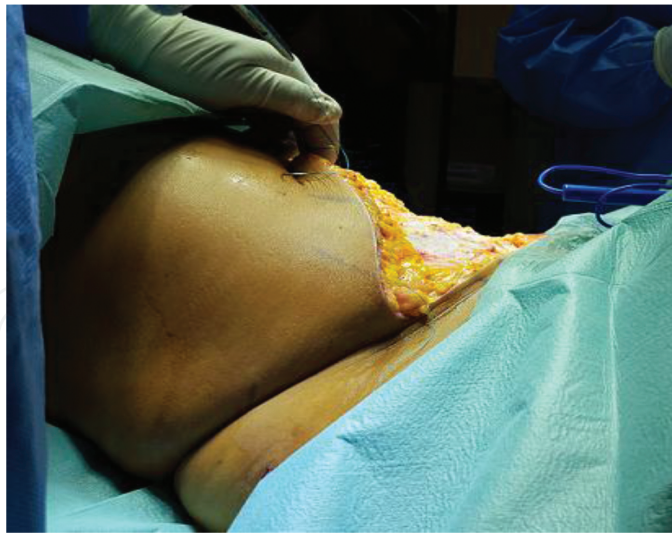After complete dissection of the premarked area, the following step is the deattachment of umbilical scar. We palpate the cylinder that connects the fascia with the skin to determine the presence or absence of hernias. If some degree of hernia is observed, it is mobilized to the abdominal cavity by squeezing movements. The bottom of the umbilical scar is exposed as a “bun” of hard, elastic consistency. This bun is then cut from beneath with a scalpel, making sure to remove all the skin to avoid future complications. The remaning deffect on the abdominal wall after aumbilicus deattachment is closed by means of a cross-shaped suture of braided, nonabsorbable material (nylon or polyester).



**Figure 6.** After In-Block redundant tissues resection including the umbilical scar.

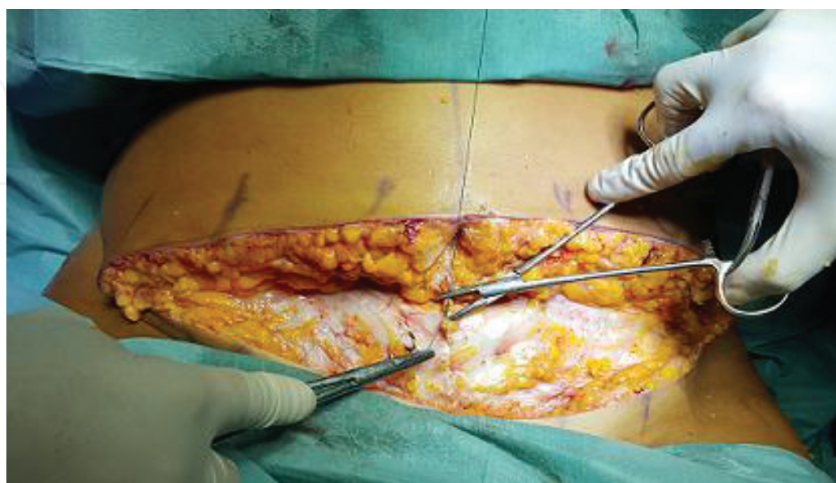At this point the patient should be placed in a semi-upright sitting position (45°) (bayonet position) **Figure 7**, to facilitate transverse plication of the aponeurotic fascia of the abdomen.

The first stitch we place is the central one that goes from the old umbilical scar to the nearest point of the suprapubic incision. Generally this distance is 5–10 cm depending on the degree of abdominal wall laxness, **Figure 8**.



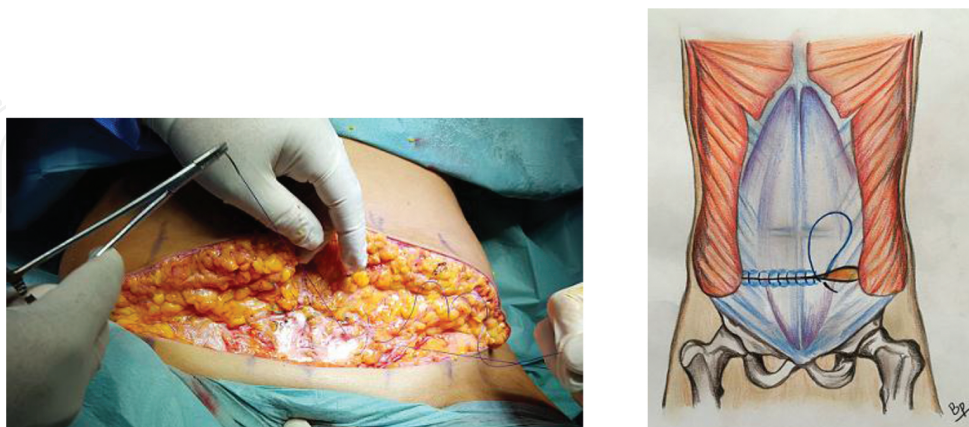Jackknife position of the operating table and bed.

**Figure 7.** Patient it's placed in a Jackknife position

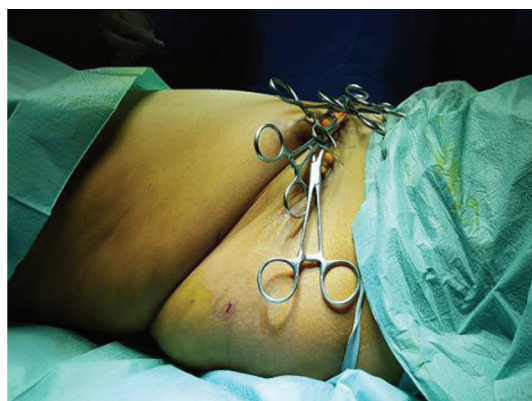


**Figure 8.** Closure of old umbilical defect and first stitch of thansverse plicature.

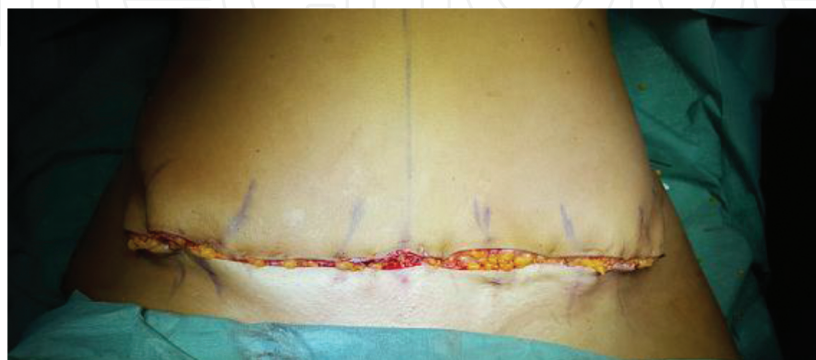Then with the same nonabsorbable material we perform a simple interrupted suture placing stitches on each side of the first one, every 3 cm, until we cover all the width of the anterior abdominal wall.



**Figure 9.** Transverse plicature final aspect.



**Figure 10.** Transitory wound closure with the help of towel clamps.

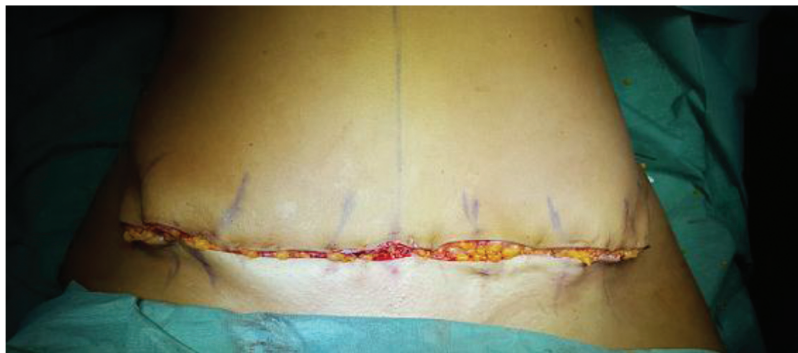

**Figure 11.** Closure of subcutaneous layer.

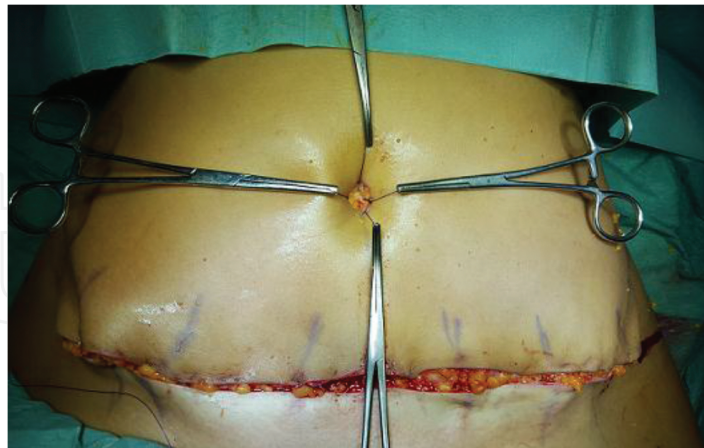

The suture takes an oblique direction so that the plication takes a vector from out to inside, thus improving the shape of the waist and avoiding a dog-ear formation. We perform a suture from scarpa fascia to mons pubis in order to stabilize the final scar position and then continuous running suture with nonabsorbable monofilament number 0. Before subcutaneous closure a careful control of hemostasis with electrocautery its done, **Figure 9**.

Bupivacaine 1% 10 cc solution its infiltrated at the subfascial plane on the inferior abdomen in order to control postoperative pain during the first 12 hours. The Scarpa fascia plane its closed using 2-0 vicryl sutures, for the subcutaneous cellular tissue, with 2-0 monocryl mattress suture and 3-0 monocryl for the dermis and skin using an intradermal continuous pattern, The surgical table return to the original position in order to stablish the position of the new umbilical scar **Figures 10 and 11**.



**Figure 12.** Skin and subcutaneous layer closure.

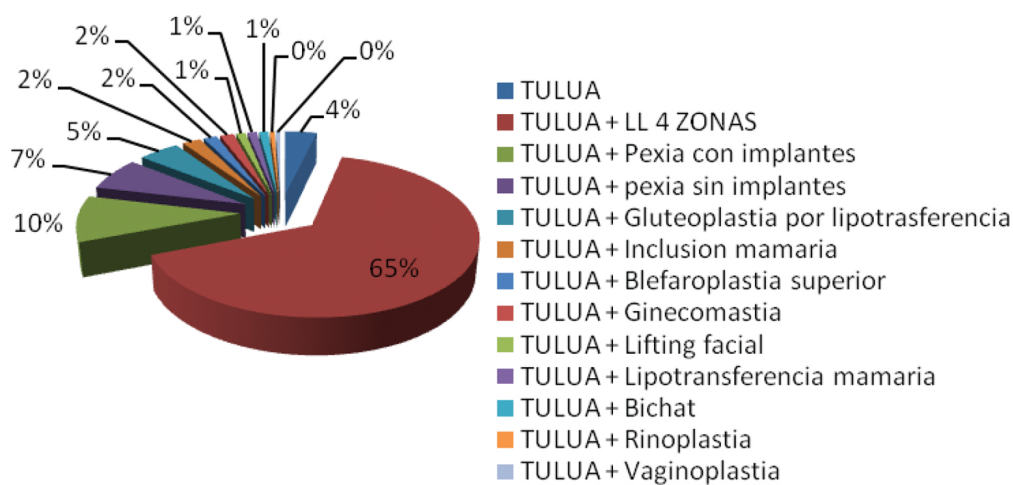


**Figure 13.** Umbilical reconstruction.

Through an oval-shaped incision in the midline, 3 cm cephalic direction from the iliac crests, the neoumbilicus is recreated by resecting skin, then the borders of the aponeurosis are folded with 3-0 monocryl and a full thickness skin graft is placed at the bottom fixed with 3-0 monocryl, careful control of hemostasis with electrocautery, **Figures 12 and 13**.

5. Results

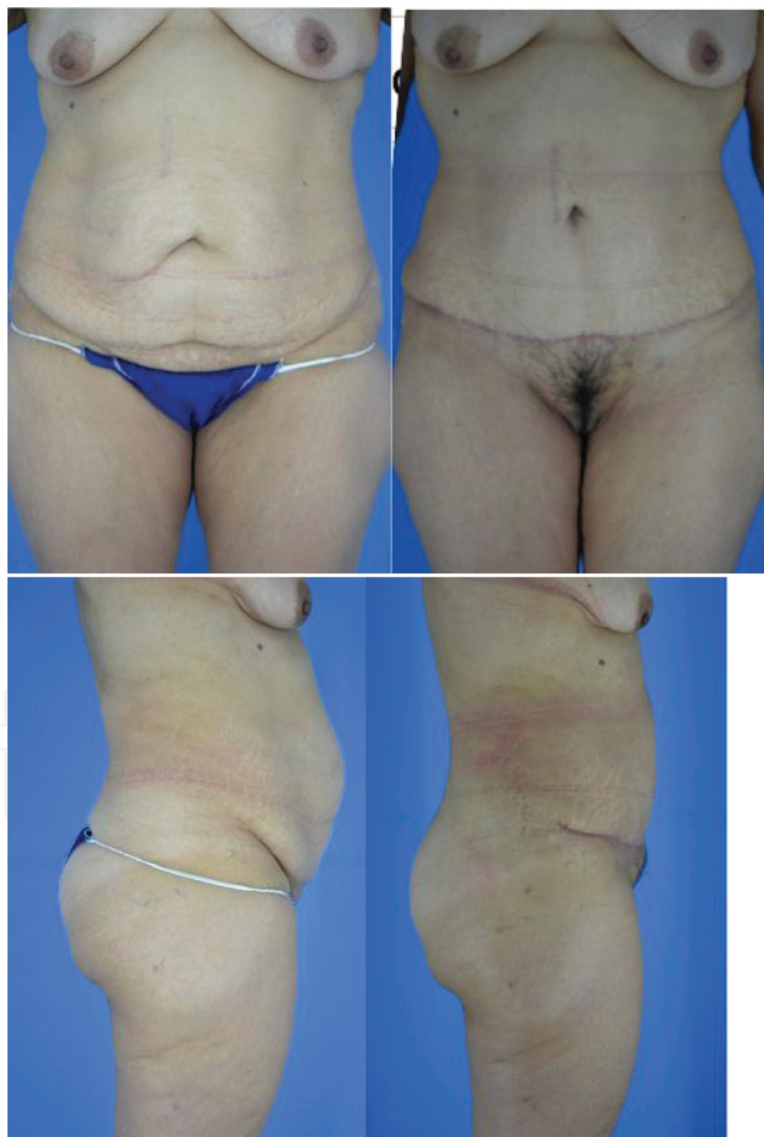
From 2013 to 2015, 188 patients were operated on, of which 178 were women and 10 were men; the age range was 24–74 years. Likewise, other combined surgeries were performed such as mastopexy, breast inclusion, face-lifting, rhinoplasty, and blepharoplasty, among others. The most common combined surgery was TULUA with laser lipolysis 4 regions 123 cases, then mastopexy with implants 18 cases, mastopexy without implants 13 cases, gluteoplasty increase by lipotransference 9 cases, TULUA 7 cases, breast inclusion 4, upper blepharoplasty 3, gynecomastia 3, facelift 2, breast lipotransference 2, bichat 2, rhinoplasty 1, and vaginoplasty 1 (see **Figure 14**).



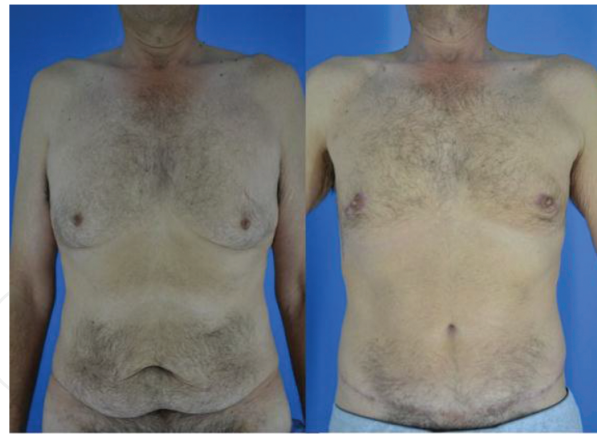**Figure 14.** The summary of all the results of the technique combined procedures and complications.

Combined surgeries and TULUA	
TULUA	7
TULUA + LL 4 regions	123
TULUA + mastopexy with implants	18
TULUA + mastopexy without implants	13
TULUA + gluteoplasty by fat graft	9
TULUA + breast inclusion	4
TULUA + superior blepharoplasty	3
TULUA + gynecomastia	3
TULUA + facelife	2
TULUA + breast lipotransference	2
TULUA + bichat	2
TULUA + rhinoplasty	1
TULUA + vaginoplastia	1

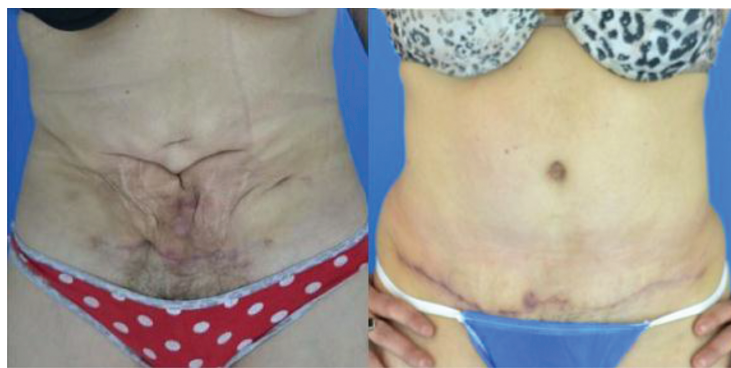Complications	
Seroma	17
Dehiscence	11
Umbilical flap loss	7
Hypertrophic scar	3
Dog-ear formation	2
Infected wound	1
Umbilical granuloma	1
Seroma + dehiscence	1



**Figure 15.** Before and after result in patient with a previous surgical scar.



**Figure 16.** Before and after result in a male patient after massive weight loss.



**Figure 17.** Before and after result in a patient that present fibrotic séuelas after liposuction.

The most common complications were seroma after liposuction, 17 cases; partial dehiscence —no more than 1 cm—, 11 cases; umbilical flap loss, seven cases; hypertrophic scar, three cases; dog-ear formation, two cases; infected wound, one case; umbilical granuloma, one case; seroma combined with dehiscence, one case.

Postoperative recovery—to resume activities—takes 15 days; the drain is not left, and manual lymphatic drain is prescribed 1 week after surgery for 1 month **Figures 15, 16 and 17.**

## 6. Conclusion

This paper attempts to show that the TULUA (transverse plication, no undermining, full liposuction, neoumbilicoplasty, and low transverse abdominal scar) technique offers abdominoplasty patients greater safety because no dissection of the upper flap is performed, preserving the major vessels of the integument in the anterior wall, they can be corrected hernias of the abdominal wall, low-rate infections, etc. Indicated for patients with multiple comorbidities; hypertension, diabetes, autoimmune diseases, along with tumescence. In our hands,

patients are discharged the same day, without relying on strong painkillers. This technique could be considered a modified lipoabdominoplasty focused in diminish the complications rate of this tyoe of procedures and the one observed in the classic abdominoplasty.

## Author details

Guillermo Blugerman, Diego Schavelzon, Boris Martínez\*, Gabriel Wexler, Andrea Markowsky and Marcelo Lotoki

\*Address all correspondence to: [drblugerman@gmail.com](mailto:drblugerman@gmail.com)

B & S Center of Excellence in Plastic Surgery, Buenos Aires, Argentina

## References

- [1] Kelly HA, Excision of the fat of the abdominal wall. *Surg Gynec Obstet* 1910; 10: 229.
- [2] Pitanguy I, Abdominal lipectomy: an approach to it through an analysis of 300 consecutive cases. *Plast Reconstr Surg* 1967; 40: 384.
- [3] Avelar J, Fat suction versus abdominoplasty. *Aesth Plastic Surg* 1985; 9: 265.
- [4] Saldanha OR. Lipoabdominoplasty without undermining. *Aesth Surg J* 2001; 21: 518.
- [5] Weinhold S, Bauchdeckenplastik. *Zentralbl F Gynak* 1909; 38: 1332.
- [6] Babcock W, The correction of the obese and relaxed abdominal wall with special reference to the use of buried silver chain. *Phila Obstet Soc* May 14, 1916.
- [7] Schepelmann E, Bauchdeckenplastik mit besonderer Berücksichtigung des Hangebauches. *Beitr Klm Chir* 1918; 3: 372.
- [8] Thorek M, Plastic surgery of the breast and abdominal wall, Charles C. Thomas, Springfield, II, 1924.
- [9] Flesh-Thebesius M, Wheisheimer K, Operation des hangebauches. *Chirug* 1931; 3: 841.
- [10] Pick IF, Surgery of repair: principles, problems, procedures. Abdomen (abdereplasty), vol 2. Lippmncott, Philadelphia, 1949, p. 435.
- [11] Barsky AJ, Principles and practice of plastic surgery, Williams & Wilkins, Baltimore, 1950.



- [12] Galtier M, Surgical therapy of obesity of the abdominal wall with ptosis. *Mcm Acad Chir* 1955; 81: 341.
- [13] Dufourmentel C, Mouly R, *Chirurgie plastique*. Flammarion, Paris, 1959, pp. 381–389.
- [14] Vernon S, Umbilical transplantation upward and abdominal contouring in lipectomie. *Am J Surg* 1957; 94: 490–492.
- [15] Gonzalez-Ulloa M, Belt lipectomy. *Br J Plast Surg* 1960; 13: 179.
- [16] Vilain R, Dubousset J, Technique et indications de la lipectomie circulaire. 1250 observations. *Ann Chir* 1964; 18: 289.
- [17] Spadafora A, Abdomen adiposa y péndulo-dermolipectomia iliaco-inguino-pubiana. *Prensa Universitaria (Buenos Aires)* 1965; 114: 1839.
- [18] Regnault P, Abdominoplasty by the W technique. *Plast Reconstr Surg* 1975; 55: 265.
- [19] Planas J, The vest over pants abdominoplasty. *Plast Reconstr Surg* 1978; 61: 694.
- [20] Shiffman MA, *Cosmetic surgery of the abdominal wall*, 2007, ISBN: 978-958-8328-10-2.
- [21] Hester TR Jr, Nahai F, Beegle PE, Bostwick J, Blood supply of the abdomen revisited, with emphasis on the superficial inferior epigastric artery. *Plast Reconstr Surg* 1984; 74: 657–670.
- [22] Linszka TG, Dellon AL, Manson PN. Iliohypogastric nerve entrapment following abdominoplasty. *Plast Reconstr Surg* 1994; 93: 181–184.
- [23] Neaman KC, Armstrong SD, Baca ME, et al., Outcomes of traditional cosmetic abdominoplasty in a community setting: a retrospective analysis of 1008 patients. *Plast Reconstr Surg* 2013; 131: 403e–410e.