

We are IntechOpen, the world's leading publisher of Open Access books Built by scientists, for scientists

6,900

Open access books available

186,000

International authors and editors

200M

Downloads

Our authors are among the

154

Countries delivered to

TOP 1%

most cited scientists

12.2%

Contributors from top 500 universities



WEB OF SCIENCE™

Selection of our books indexed in the Book Citation Index
in Web of Science™ Core Collection (BKCI)

Interested in publishing with us?
Contact book.department@intechopen.com

Numbers displayed above are based on latest data collected.
For more information visit www.intechopen.com



Fat Grafting in Body Contouring

Marco Romeo, Ayman Elmeligy and
Khalid Elsherbeny

Additional information is available at the end of the chapter

<http://dx.doi.org/10.5772/65486>

Abstract

Fat transfer had been used since the first decades of the twentieth century for body contouring and reconstruction. Since then, a lot of controversies and ongoing research regarding indications, harvesting and transplantation technique had been a concern for plastic surgeons. More recently, the use of fat as a source of stem cells had been the major point of research joining both the aesthetic and the regenerative advantages. Body reshaping using fat graft is nowadays a common non-invasive resource in the surgeon's armamentarium popularized as body sculpturing merging the benefits of liposuction and lipofilling to improve the aesthetic of virtually all the regions of human body. In this chapter, the role of fat grafting in aesthetic body contouring will be discussed. The association of stem cells is exposed to give the reader the possibility to better understand this option of treatment. Fat harvesting/grafting techniques are explained and the authors' preferred choice is exposed. Lipofilling details are discussed per area of the body with practical tips and pitfalls for the experienced or the newbie surgeon. A final summary on complications will remind all the possible incidences that may occur in the short- and long term after surgery.

Keywords: lipofilling, fat grafting, aesthetic, stem cells, body contouring

1. Introduction

1.1. The history of fat grafting

History of fat grafting is rather fascinating, yet quite controversial with all that it carries within its corners, from frustrations to adventurous experimentation.

The first attempt to use fat in human auto-transplantation was dated to 1889 by **Van der Meulen**. The procedure consisted of grafting an omentum and fat auto-graft between diaphragm and liver.

The first described free fat grafting attempt was recorded by Gustav Adolf Neuber, a German surgeon in 1893. Neuber used small fat grafts in order to fill facial defects in a 20-year-old man. According to Neuber, he had less success when he tried to use larger grafts, saying that 'grafts larger than an almond would not give good results'.

In 1895, Viktor Czerny (1842–1916) reported excising a lipoma and grafting it into a breast defect to establish symmetry following a unilateral partial mastectomy [1].

Gersuny in 1900 proposed paraffin injections. They became commonly used for post-syphilis saddle noses. Paraffin injections gave amazing results initially; however infections, paraffinomas, migration and pulmonary embolism were major complications of the procedure [2].

In 1912, Holländer proposed the technique of fat injection, but there was a high rate of reabsorption. He harvested adipose tissue from patients and mixed it with fat from rams. This mixture was injected as a fluid at body temperature. Patients had a painful rash afterwards for 2–3 days, but he reported a good outcome.

Lexer in 1919 also described fat grafting in his textbook, to correct sequelae of facial trauma, hemifacial microsomia, microgenia, breast asymmetry, and post-traumatic hand stiffness. He also described the use of fat to restore gliding tissue around tendons in Dupuytren disease [3].

Gillies in 1920, showed in his book, patients treated with fat grafting after facial injuries.

Peer in 1950, demonstrated that about 50% of fat cells died after transplantation and were replaced with fibrous tissue and stressed that survival of fat grafts was **dependent on early neovascular anastomoses** (new blood vessels), and stated that 50% of the adipose cells in free fat grafts survive.

Studies and research work in the past decades focused more on the pathology of obesity and the role of genetics on fat cells in obese people.

The general acceptance among researchers is that the number of adipocytes is fixed in adults.

Smith in 1971 described the fibroblast-like cells grown on tissue culture.

The adipocyte precursors studied in tissue culture was more profoundly investigated by Van in 1976, proved that fat tissue was more dynamic than historically thought it was.

It was Roncari who studied the morphology and maturation of cultured adipocytes in a culture system that he developed in 1978 [4].

Liposuction technique was invented by Fischer in 1974.

It was not until the era of liposuction in 1978 when the French physicians Illouz and Fournier further developed the procedure utilizing blunt cannulas for suction lipoplasty that made the process of fat extraction more reliably predicted.

By the early eighties, liposuction became quite popular in the United States. Klein, a dermatologist, invented the tumescent technique for liposuction that allowed patients to have liposuction performed totally under local anaesthesia with less bleeding and with much smaller cannulas.

Ellenbogen started using fat pearls in the reconstruction of facial defects [5] and in 1988, Chajchir described favourable results, emphasising cautious handling of adipocytes, rinsing of the lipoaspirate to eliminate dead cells and grafting into a well-vascularised bed [6].

In the nineties, Sydney Coleman from New York described standardized techniques for fat extraction, processing and injection of fat grafting [7, 8].

1.2. Fat potential and differentiation capacity

In 2001, a group of researchers from the University of Pittsburgh described the implications of adipose tissue in cell-based regenerative therapies.

This was quite a revelation for the scientific community, as up until that time adult mesenchymal stem cells (MSCs) were predominantly thought of as a bone marrow product.

As it turns out, adipose tissue is a much more prolific source of MSCs than bone marrow.

By volume, mesenchymal stem cells are actually 300–500 times more abundant in adipose tissue compared to bone marrow tissue.

Comparison of multi-lineage cells from human adipose tissue and bone marrow is given in Ref. [9].

Adipocytes derived from stem cells (SC) under the right stimulation could differentiate into different lineage like endothelial cells, fat cells, epithelial cells, neuronal cells, chondrocytes, myocytes and osteocytes.

Adipocytes also secrete more than 100 proteins (adipokines) and growth factors that regulate: angiogenesis, inflammation and apoptosis.

Growth factors include: vascular growth factor, liver growth factor, platelet and epidermic growth factors.

Fat grafting has truly opened new frontiers for plastic surgeons and other medical specialties.

Its power is only yet to be understood and it is clear that adipose tissue will be a pillar of regenerative medicine treating a huge spectrum of diseases like DM, Autism, Parkinson's disease, multiple sclerosis and others [10].

1.3. The fate of fat

The old, general concept of fat grafting was that the surgeon had to overfill the grafted area of about 40% of its volume since there will be resorption of 10–60%, some said up to 90%.

There was no proper understanding of the mechanism of survival and fate of grafted fat cells.

Today, research revealed the fate of grafted adipose tissue showing that three different zones will demarcate after 4 weeks of grafting, by name these zones are:

1. The outer surviving zone: the most superficial; several rows of fat cells that are clearly in direct contact with the vascularized recipient tissues of the host.

2. The intermediate regenerating zone: with a thickness from 600 to 1200 μm , which shows both surviving adipocytes along with dead.
3. The inner necrotic zone: with necrotic cells, inflammatory cells, fibrosis, oil drops and rare adipocytes.

At the outermost surviving zone, the cells are quite close to vascularity and the adipocytes tend to survive in a process quite similar to the physiology of skin grafts, called the diffusion/angiogenesis theory that suggests that donor adipocytes survive by oxygen diffusion at the recipient site during the initial days after grafting, with eventual micro-angiogenesis and formation of a viable blood supply.

At the regenerating zone, the fat cells do not succeed to survive; however the adipose-derived stem cells (pre-adipocytes) experience ongoing adipogenesis that increased rapidly after grafting and peaked at 4 weeks and full remodelling was completed by 12 weeks.

The necrotic zones will eventually be absorbed, filled with fibrous tissue, or become a problematic cyst.

Grafted fat tissue undergoes degeneration within 1 week, while regeneration reaches its peak at 4 weeks. Regeneration takes place by adipose tissue-resident progenitor cells. Phagocytosis and cicatrization occur in the regenerating and necrotic zones, predominantly by M1 and M2 macrophages respectively.

The stabilization process appears to persist for a long time after failed regeneration. The size of the necrotizing zone depends mainly on the size of the graft and the micro-environment into which it is placed. Eventually, necrotic zones will be absorbed, filled with fibrous tissue, or become a problematic cyst. Liposuction and reinjection procedures could be improved by preparing grafts with better viability and in an appropriate size, maximizing the contact surface of the grafts by ideal distribution, and placing the grafts in areas with high vascularity. Stabilization of the grafted fat may not occur until several months after complete regeneration at 3 months. This emphasizes the importance of long-term follow-up to thoroughly evaluate the clinical results of microfat grafting [11].

There are opposing theories about cell survival: The Hofer's theory versus the scaffold or matrix theory.

According to Hofer, all or most of the transplanted adult adipocytes are destined to die, acting as a non-viable scaffold, through which macrophages penetrate and through which stem cell-mediated angiogenesis and adipogenesis occur.

Cytokine induced cell-cell signalling between living and dying, and between the donor and recipient cells, is thought to play a role in this process [12, 13].

According to the scaffold matrix theory of Khouri and Rigotti, overcrowding of injected cells reaches a critical interstitial fluid pressure of 9 mmHg; therefore, in a tight recipient space fat droplets will merge into fat lakes, which is thought to interfere with capillary blood flow and hence oxygen diffusion leading to apoptosis and cell death.

In clinical setting, fat injections larger than 0.16 cm in radius will have a region of central necrosis.

2. Fat grafting technique

Fat grafting is promising, but clinical outcomes are not always predictable due to the variability of degree of fat resorption, which is highly dependent on surgeon's technique.

Fat-grafting procedure is divided mainly to three main steps:

1. Fat Harvesting
2. Fat Processing
3. Fat Grafting

Most surgeons believe that fat, as autologous tissue, can be considered the ideal soft-tissue filler because it is abundant, readily available, inexpensive, compatible, and can be harvested easily. If fat grafts are manipulated correctly, structural fat grafting represents a safe, long-lasting and natural-appearing method for soft-tissue augmentation in patients.

To obtain long-term survival of transplanted autologous fatty tissue, the harvested and processed fat grafts must remain viable before implantation. In 1994, Coleman first described his technique, which uses a syringe, cannula and centrifuge, for structural fat grafting [7].

He later refined and popularized his technique for fat-graft harvesting and processing with patented instruments and a centrifugation protocol, often referred to as the Coleman technique [14].

2.1. Harvesting

A number of techniques have been used for fat harvesting, these include conventional liposuction (syringe with vacuum suction), power-assisted liposuction (specialized cannula with mechanized movement), hand-held syringe liposuction (syringe with manual suction; Coleman technique) and internal ultrasound and LASER-assisted liposuction (specialized cannula that transmits ultrasound or LASER within the body syringe liposuction). A number of studies have compared conventional liposuction with suction- or power-assisted liposuction. Leong et al., upon comparing syringe liposuction to pump-assisted liposuction found no differences in cell viability, cell metabolic activity or adipogenic responses of cultured mesenchymal precursor cells processed from pump or syringe lipoaspirates [15, 16].

In contrast, Pu et al. demonstrated that syringe liposuction yields a greater number of viable adipocytes and sustains a more optimal level of cellular function within fat grafts than conventional liposuction. However, normal histologic structure was maintained in fat grafts obtained by both methods [17].

2.2. Infiltration

For fat aspiration, the donor site is infused with tumescent solution, consisting of a local anaesthetic (LA) (lidocaine, ropivacaine, prilocaine or bupivacaine) for pain relief and epinephrine for haemostasis in Lactated Ringer's solution or normal saline. The most currently used LA for liposuction and Autologous Fat Graft (AFG) is lidocaine and that is on this molecule that literature is the most abundant. Indeed, a survey from the American Society for Aesthetic Plastic Surgery concluded that: for adipose tissue harvest, 40% of surgeons use tumescent solution containing 50 mL of 1% xylocaine + 1 mL epinephrine 1:1000 in 1 L normal saline, which corresponds to 0.5 mg/mL of lidocaine, about 30% of them use a mixture of 0.5% xylocaine with epinephrine and 22% use 1% xylocaine epinephrine mixture. The remaining 8% of American physicians use epinephrine alone or other solution [18].

Several studies [19–21] have examined the effect of the local anaesthetic or epinephrine on fat viability. Oren in a study published in the journal of drugs in dermatology in 2005 stated that neither lidocaine nor adrenaline had long-term unfavourable results on the grafted fat cells.

According to authors' experience, the use of LA should be avoided under general anaesthesia (tumescent solution with diluted epinephrine only), preferably using regional or spinal anaesthesia to avoid injection of local anaesthetics.

2.3. Donor site preference

Whether there is an optimal donor site for fat grafting or not remains to be established.

In several studies, various authors showed that fat from the lower abdomen and medial thighs consist of a higher concentration of adipose-derived stem cells compared to the fat from the upper abdomen, trochanteric region, knee and flank [22].

However, other studies reported no influence of the donor site on fat viability [23, 24].

Among adrenergic receptor subtypes that regulate lipid mobilization, the alpha-2-adrenergic receptor is involved in the inhibition of fatty acid mobilization from adipose tissue and that can explain why some areas are more resistant to fat mobilization, the so called genetic fat areas, like abdomen for the men and trochanteric areas for women.

In our experience, the genetic fat theory had a clinical correspondency, with volumes of fat less susceptible to reduction with diet and exercise. The genetic fat expresses alpha-2 receptors that are more stable with metabolism and are anti-lipolytic. So it is usually useful to ask the patient about his resistant fat areas as a guide to the donor site, usually trochanters, lower abdomen and love handles in most people.

2.4. Optimal lobular size: choice of harvesting cannula

The size of cannula is debated among physicians. Some researchers stated that larger cannulas allow harvesting of bigger fat lobules with a higher survival rate [25].

Others stated that smaller cannula sizes theoretically create less donor site trauma and allow for removal of smaller sized lobules of fat, which may improve flow characteristics and reduce trauma during reinjection. An important consideration besides cannula size is cannula hole size and number of holes. A 12-gauge cannula with 6–8 side holes 2×1 mm in size can extract a significant amount of fat despite its small calibre.

The summation of the surface area of the individual openings on a 12-gauge, 12-hole cannula approaches or exceeds the surface area of the opening of a classic 10 mm one-hole cannula. This results in better tissue flow with less trauma in the donor area. In addition, each hole selects for lobules of a small, uniform size, which are more likely to flow easily through the injection cannula during the grafting phase of the procedure thus, there is no need for further processing or syringe transfers. The hole sizes on the aspiration cannula approach the size of the hole on the injection cannula. This ensures 'equalization' of hole sizes for more efficient fat flow [26].

In our experience midsize cannulas (3 and 4 mm) are a good compromise between too fine instruments (2 mm) and aggressive tools (5 or 6 mm).

Using wider-diameter cannulas (2.5 mm) may however be preferred as they have been shown to potentially improve fat-graft survival and reduce fat-graft resorption compared with small-diameter cannulas (1.6 or 2 mm).

The size of the needles does not appear to affect cell viability, at least when using 14-, 16-, and 20-gauge needles (Erdim et al) [27]. However, for any given needle size, it appears that fat viability is influenced by the shear stress, which is a function of the flow rate. Thus, fat injected at a slow rate (low shear stress) results in better fat-graft retention than fat injected at a fast rate (high shear stress) [25]

In the author's practice, nowadays with evolving of microfat and nanofat techniques, harvesting allows injection with ease using 0.7 and 0.9 mm diameter injection cannulas and needles as common practice without much worry about friction and sheer stress especially in areas of the face and hands where tiny injectors are needed.

2.5. Negative pressure

The literature regarding the isolated effects of negative pressure suggests that adipocytes can be suctioned below 700 mmHg without undue trauma according to Shiffman [28].

Claims of syringe suctioning as being safer than machine suctioning should be carefully considered. While a standard liposuction machine can generate up to one atmosphere (760 mmHg) of negative pressure, a 60-cc syringe connected to an in-line manometer can also generate nearly one atmosphere of negative pressure. It is likely that absolute pressure and not the source of this pressure is the key variable in adipocyte trauma and its effect of adipocyte viability [26].

The author's experience agrees with the aforementioned literature about keeping a low suction pressure at the level of 700 mmHg to maintain the viability of fat cells.

2.6. Processing

The harvested fat is processed in order to eliminate tumescent fluid, blood, cell fragments and oil (from disrupted adipocytes) [29].

Processing aims to retain viable adipocytes in a concentrated form which is believed to enhance the graft taken [16].

Filtration, centrifugation and sedimentation (decantation) are the most commonly used fat processing methods.

2.6.1. Filtration

The filtration technique uses a platform for concentrating fat cells and separating cells from fluids, oil and debris. Examples of platform used for filtering fat include filters or strainers with defined pore size, gauze, metal sieve, mesh and operating room cloth. During centrifugation process, the syringe containing the aspirate is placed in a centrifuge at a specified speed and time.

During the sedimentation process, the syringe containing the lipoaspirate is allowed to sit for decantation to occur under the effect of gravity.

A modification of this technique includes washing the lipoaspirate with 1–3 times the volume with normal saline or Lactated Ringer's solution and then left to decant under gravity. In all techniques, centrifugation, sedimentation and washing, the lipoaspirate is separated into three zones: an upper oil zone, a middle purified concentrated fat layer, and a lower aqueous zone consisting of blood and washing liquids. In the centrifugation technique, in addition, a pellet is seen at the bottom of the centrifuge.

2.6.2. Centrifugation

The Coleman technique is the most widely used centrifugation protocol in which the lipoaspirate is centrifuged at $\sim 1200 \times g$ (3,000 rpm) for 3 minutes.

In agreement with Coleman, Kurita et al. evaluated the effect of six centrifugation speeds (from 0 to $4200 \times g$ for 3 minutes) on fat aspirates and graft taken from nude mice and concluded that centrifugation at more than $3000 \times g$ significantly damaged adipose-derived stem cells and recommended $1200 \times g$ as an optimized centrifugal force for obtaining good short- and long-term results in adipose transplantation [30].

Some studies concluded that lower centrifugal forces than in Coleman's protocol may be more adipocyte-friendly.

Hoareau et al. subjected fat tissue to soft ($100 \times g/1$ min and $400 \times g/1$ min) and strong ($900 \times g/3$ min and $1800 \times g/10$ min) forces and examined the grafts viability. Strong centrifugation resulted in 3-fold more adipocyte death than soft centrifugation suggesting that soft centrifugation ($400 \times g/1$ min) seems to be the most appropriate protocol for the reinjection of adipose tissue.

Yet, others suggest that centrifugation has no effect on adipocyte viability as in Pulsfort et al. Pulsfort, using eight different centrifugal forces (up to 20,000 $\times g$) found no significant differences in the viability of centrifuged adipocytes. Furthermore, no apoptotic changes revealed during cultivation of isolated adipocyte after centrifugation. However, higher centrifugal accelerations were better in cleansing lipoaspirates from oil and cell debris, than lower centrifugal forces.

The authors do not advocate centrifugation forces above 5000 rpm for more than 5 minutes and more than 1200 G finding that it carries the risk of destruction to fat cells.

2.6.3. Sedimentation

Sedimentation is the oldest and the cheapest way to treat fat before injection. The most advanced purification techniques seem to have replaced decantation but some studies still support this simple filtration process also with higher amount of live pre-adipocytes [31].

Condé- Green showed that cell count, per high-power field, of intact nucleated adipocytes was significantly higher in decanted lipoaspirates while centrifuged samples showed a greater majority of altered adipocytes. On the other hand, the MSC concentration was significantly higher in washed lipoaspirates compared to decanted and centrifuged samples. However, the pellet collected at the bottom of the centrifuged samples had the highest concentration [32].

The authors wash adipose tissue grafts and recommend that if centrifugation is used, the pellet containing mesenchymal stem cells should be added to the concentrated adipose phase to augment graft take.

2.7. Fat placement

Although there is no standardized fat placement technique, the Coleman technique is the most widely used. Fat grafts, in this technique, are injected using a blunt Coleman infiltration cannula attached to a 1 mL syringe while withdrawing the cannula. Different syringe sizes (3 and 10 mL) as well as various cannula tip shapes, lengths, gauges and curves can be used depending on the volume of fat to be placed and the recipient site [33].

2.7.1. Types of fat grafting

Different sizes of fat graft obviously reflect the mean lobular size of each type.

Macrofat grafting: as the name implies, represents the largest lobular size and is the size obtained with a standard (3 mm and above) mostly Mercedes type liposuction cannula with large side holes (2 \times 7 mm). This kind was mostly the standard practice since the start of fat grafting, indifferently injected to all parts of the body including the face. Probably that was the reason why patients previously had complications like lumpiness and cyst formation due to the unsuitable grafted lobular size to the delicate areas of the face like tear trough.

Macrofat grafting is best indicated in areas that need large volume transfers like buttocks and breasts. Macrofat graft contains both viable adipocytes and adipocyte derived stem cells (ADSCs).

Blunt injection cannulas ranging from 0.7 to 0.9 mm are usually used, with very good results, for microfat grafting, usually performed in the facial area. The fat particles need to be sufficiently small in order to provide a smooth injection through these fine cannulas. If the fat particles are too large, passage through the fine injection cannula would be difficult. As a result, disrupted injection will follow, which may lead to an unequal lipofilling with irregular fat deposits.

Trepsat used a multi-perforated harvesting cannula of 2 mm with 1-mm side holes and 19-gauge injection cannulas, to provide fat grafts with smaller particles for microfat grafting procedures at the lower eyelid. To harvest fat for injection of other parts of the face, a multi-perforated liposuction cannula of 3 mm in diameter with 2-mm side holes was used [34, 35].

According to the authors' practice, the smaller lobular fat-graft size obtained with a (Tonnard) or (Sorensen) microfat harvester cannulas that are multi-port 2-3 mm cannulas (19-gauge) with sharp or bevelled 6–12 side holes of 1 mm in diameter. These are best mounted to a 10 mm luer lock tip syringe for a controlled low pressure microfat harvesting. Microfat-grafts were best used to fill the face, hands and delicate areas as tear trough. Microfat contains both viable adipocytes and adipocyte derived stem cells.

The radius of the fat particle is inversely proportional to its contact surface. This means that for the same volume of injected fat, reducing the diameter by half will double the contact surface. A larger contact surface means better contact with the capillaries in the recipient area and thus a better graft survival rate with less need for overcorrection. The authors do not advocate overfilling with microfat grafting. Microfat grafts due to their micro lobular size are easily injected with 0.7–0.9 mm micro-cannulas injected into different tissue layers in columns of fat pearls.

Aspirated fat has to be processed mechanically to provide a liquid fat emulsion, which is called nanofat. This is to ensure a smooth fat injection through 27-gauge sharp needles [34]. Using a nanofat processing procedure, a yield of 1 ml of nanofat per 10 ml of lipoaspirate can be expected.

For production of nanofat, the lipoaspirated fat is mechanically emulsified after rinsing by shifting the fat between two 10-cc syringes connected to each other by a female-to-female Luer-Lock connector. After 30 passes, the fat changes into an emulsion. At the end of the fragmentation process, the fat becomes liquid and has a whitish appearance. After emulsification process, the fatty liquid is again filtered over the sterile nylon cloth and the effluent is collected as nanofat. Nanofat does not add much volume as its filling capacity is pretty limited since it mostly lacks the viable adipocytes. However, nanofat grafts are rich in ADSCs that are capable of skin rejuvenation as in areas like perioral skin, glabellar skin, sun-damaged skin at the breast cleavage, dark eye hollows and scars. Nanofat is injected using a 23-gauge needle mounted to 1-cc syringe. The effect of nanofat usually appears with a delay of 4 weeks to 3 months.

Increased collagen, elastin synthesis and remodelling are the presumed mechanisms for this regenerative effect on improved elasticity. Stem cells rather than grafted adipocytes most likely trigger these effects. Presumably, the nanofat sample analysis revealed that adipocytes were destroyed during the emulsification process.

Another form of microfat graft, called SNIF (sharp needle intradermal fat injection), through which a 1 ml syringe is injected to the superficial dermal plane with a 23-gauge needle. SNIF is a cheaper and more effective filler for wrinkles in patients willing to have long-term results and would accept the process of fat harvesting and the post-operative swelling.

2.8. Tips and pitfalls

The authors carry on the microfat harvesting and injection technique for purpose of fat injection of the face, hands, scars and breasts. In case of buttocks augmentation, macrofat harvesting and injection techniques are utilized as described formerly in the literature.

Our main steps are:

Harvesting site choice. Selecting area for fat harvesting depending on genetic fat theory asking the patient about his areas of fat deposits that are least affected with metabolism during weight loss. In case of face treatment, the planned amount is usually around 50–100 cc; however in buttocks it could range up to 1 litre. Infiltration: Tumescence technique is carried in a 1:1 ratio of infiltration to aspirate ratio. For every 1000-cc of normal saline, 1ml adrenaline, and 10 cc of sodium bicarbonate. Usually, regional or spinal anaesthesia is utilized or other wise 20 cc of 1 % lidocaine is to be added to the 1 litre solution.

Harvesting. Usually waiting around 10 minutes from the start of infiltration to start suctioning the first infiltrated area. 2 mm microfat harvester cannulas with 6 –12 (1 mm) holes are used. More than one type of microfat cannula harvesters is used. We prefer in our practice the bevelled smooth edged side holes better than cannulas with sharp bevelled edged holes since the sharp edges were found to cut more readily into the connective tissues opening tissue planes together so instead of suctioning from tunnels, changes to spaces and that leads to losing suction pressure fast after a while, especially while using syringe suction which necessitates harvesting other areas to get the needed amount of fat.

Lipoaspiration with a low suction pressure (under 700 mmHg) either using 10-cc syringes for harvesting of microfat or suction assisted motors for larger volumes as for macrofat grafting of the buttocks for augmentation.

Processing. It is carried out with a process of decantation where the fat is collected in syringes standing upright in a metal rack for the fat to sediment into an oil layer (top), fatty layer (middle) and fluid (lower) layer with remains of tumescent fluid and blood.

Decantation. The process is carried with suction of the oil layer with 23-G needle until purification and eliminating the bottom fluid portion. Adding plasma-rich platelets to the purified aspirate in a ratio of 1:9 is an optional step.

Preparing for injection by transferring the filtered, activated microfat into individual 1-cc syringe with a 0.7 or 0.9 mm micro-injector cannulas in case of microfat placement and in 2mm injectors for macrofat placement as in larger volumes as the buttocks.

Placement of the fat should be carried out in many columns of fat pearls with multi-strokes or retrograde filling in different tissue layers, never in one bolus neither in an over correction.

3. Stem cells and fat grafting

Stem cells are present in many tissues of the human body.

The most common source of SC is the bone marrow, which is a relatively complicated location to perform a non-invasive harvesting procedure. Adipose tissue is a natural source of stem cells, which are at the edge of modern research for tissue regeneration, thanks to the easy, non-invasive harvesting and abundant availability of MSCs. Therefore, fat grafting has started to be considered not just a treatment to achieve morphologic improvement but a procedure of regenerative medicine. Beside the large availability of ADSCs, it has been demonstrated that ADSCs express CD3, CD14, CD19, CD34, CD44, CD45, CD73 and CD90 similar to cord tissue MSCs (CT-MSCs) [36], that confirms the same biological quality. ADSCs have been successfully extracted and used in many studies to seed specific tissues to obtain differentiation and local proliferation [37].

On the other hand, out of laboratory, most of the actual clinical applications do not use ADSCs alone but along with their adipose medium due to the easy, inexpensive harvesting and injection (liposuction/lipofilling) process.

Thus, concentration of MSCs is relevant to biological effect and various methods of concentration of cells inside adipose tissue have been invented. All commercially available system demonstrated to be effective but the concentration of MSCs can be quite heterogeneous [38].

Celution® (Cytosol Therapeutics, Inc., San Diego, Calif.) demonstrated to be the most effective in concentrating MSCs (2.41×10^5 cells/g) also bringing endothelial cells.

These devices are a promising advance in reconstructive surgery to treat difficult wounds or irradiated tissues. The biggest downside is the elevated cost of maintenance, which limits their use in aesthetic field.

In private practice, an efficient purifying system of adipose tissue (i.e. Puregraft® or centrifugation) has the right balance between cost and effectiveness.

In our experience, high concentration of stem cells has been used in perioral treatment of scleroderma to enhance tissue regeneration. It is authors' belief that stem cells may be of great help when active regeneration is needed but that aesthetic uses of MSCs may not justify the high processing price.

4. Applications and indications to fat grafting

Fat grafting has relevant roles both in reconstructive and aesthetic fields; for the purpose of this book, only the latter will be discussed.

Lipofilling has become more and more popular, plus the indications are growing broader each year. Therefore, it is hard for the surgeon to have clear guidelines to choose the right technique for the right patient.

In 2007, the American Society of Plastic Surgery (ASPS) [29] developed evidence-based indications to the use of fat grafting supported by strong literature data.

The first applied criterion is safety. Despite some heterogeneity of fat processing among physicians (infiltration, harvesting, processing and fat layering), the overall risk is low. Considering the mild anaesthesia needed, anaesthetic complications are barely reported, which allows including a wider group of potential patients according to general health conditions and comorbidities. Infections, seroma and hematoma are reported but mostly treated conservatively [39, 40].

Doubts related to cancer (mostly breast) due to the biological role of fat and stromal cells have been cleared by several studies [41, 42], although in specific cases, like breast injection, a mammography or ultrasound are recommended.

In aesthetic field the most popular indications include facial and hand rejuvenation, breast and buttocks augmentation, scar revision and less commonly penis and calf enlargement; the most important are discussed in this chapter.

Beside safety, there are some relative limits to aesthetic fat grafting, which include adipose tissue availability, associated risk factors to fat survival, for example smoking, patient permission to possible multiple sessions (therefore, higher costs) and expectations.

In conclusion, standardization of fat manipulation and careful choice of patients can contribute to satisfactory results from both parts.

5. Scar correction

Bad scarring represent either a functional and aesthetic trouble that often needs revision, although surgery (excision and z-plasty) alone may not solve the problem; for example, post-radiotherapy scarring often involves wide areas, which are not amenable of direct excision.

Scar depression and adherence to deep planes are common features of abnormal scarring that come along with pain and potential functional limitation.

For the reasons mentioned before about ADSCs, fat grafting plays a double role in scar revision: mechanical and biological.

In fact, fat layering corrects depressed scars, detach adhesences and can release trapped nerves and tendons.

On the other hand, ADSCs enhance local regeneration and improve vascularity, which can become particularly relevant in unstable scars.

Timing is important, if there is room for ordinary surgical revision (for example a z-plasty), fat grafting may anticipate surgery to improve tissues quality. Moreover, various sessions may be required and it must be discussed with the patient when planning surgery.

In any case, it is wise to wait at least 6 months of scar maturation before attempting any correction. Further sessions may come at an interval of 3–6 months.

5.1. Technique tips and pitfalls

Anaesthesia and amount of fat to be transferred cannot be standardized, as the clinical scenario is always different.

The first problem the surgeon will encounter is the stiffness of the scarred tissues, which makes difficult to create the funnels with a blunt cannula: remember that excessive strength pushing the cannula through will lead to poor control of trajectory and potential perforation of superficial and deep organs with high-risk consequences.

Therefore, a V-shaped cannula is the ideal tool to safely create the passages to infiltrate fat. It is possible to use either a simple dissector or a sharp cannula to dissect and infiltrate at once.

In our experience, the latter is better, so you can infiltrate in a retrograde fashion each new tunnel without creating false planes.

Superficial subcutaneous scarring may be treated with percutaneous release (rigotomy) with a thick 14–16 G needle.

It is important to try to create a three-dimensional network of tunnels in all directions to neutralize all the vectors of scarring and improve the result.

6. Facial rejuvenation

Facial aging is a complex phenomenon that includes all soft tissues and bones of the face.

A careful assessment must be made to address separately the loss of volume, the vertical displacement of soft tissues and worsening of skin texture [9, 10].

Volume loss mostly depends on soft tissues atrophy and secondarily on bone resorption.

As a matter of fact, when the bones profile becomes too visible it gives a skully aspect, which is instinctively recognized as aged.

Fat grafting is an excellent long lasting alternative to temporary hyaluronic acid (HA) filling.

Like HA, fat is used to correct nasolabial folds, marionette lines, and cheek prominence, tear trough, lip volume, jaw line and the temporal zone to restore a youthful oval face.

6.1. Technique tips and pitfalls

Fat grafting can be carried out as an outpatient procedure under sedation and local anaesthesia with or without nerve blocks.

Care must be taken to respect the principles of micrografting; a 1mm cannula is probably the best to retain more fat. On the other hand, the amount of resorption rate in the face is lower

than other parts of the body; therefore overfilling is equally a potential mistake. The most critical areas of the face are the tear trough (TT) and the lips.

TT assessment must clarify whether there is a problem of a deep anatomical groove or an excess of eye bags near the lower lid, in the second case a blepharoplasty is indicated against lipofilling.

Moreover, due to the thin skin of this area, one must avoid injecting too superficially to avoid permanent visible and palpable lumps; an inexperienced surgeon should not perform TT correction as his/her first procedure.

Lips enhancement is technically easier and equally rewarding for the surgeon and the patient but may suffer of delayed complications if the patient gains weight with deformities and distortion of the lip due to asymmetric adipose tissue expansion. This point must be discussed with the patient prior to surgery and possibly included in the consent form.

7. Hand rejuvenation

While face ageing has always been a concern for people, hand ageing awareness is a more recent discovery in our culture.

Hands more than anything else speak about us, our job, our hobbies and our lives.

With time subcutaneous tissues thin out making visible tendons, bones and veins, which give the typical 'skeleton hand' appearance perceived as aged.

Fat graft helps to restore the subcutaneous layers hiding the over mentioned structures [43].

7.1. Technique tips and pitfalls

The treatment can be performed as an outpatient procedure; thanks to the limited harvesting the procedure can be performed under mild sedation, local anaesthesia and nerve blocks at the wrist.

Once fat has been prepared with the preferred method, it can be injected through tiny access points in the second, third and fourth web space with a 1 and 2 mm cannula sliding dorsally in the superficial compartment immediately in the subcutaneous space. The correct plane of injection is above the dorsal veins, nevertheless it is advisable to aspirate before injecting in a retrograde fashion to avoid fat embolism.

The linear pattern in between the metacarpal bones can be enough for mild correction, cross-linear infiltration is indicated when major resurfacing is indicated, it is important to respect the micro-tunnelling principle, excessive lipofilling may lead to involuntary dissection of the plane with confluence of all the fat with fat necrosis/resorption.

The amount of fat depends on the correction we want to achieve, usually between 15 and 25-cc of fat per hand is enough.

Lipofilling can be safely combined with superficial peeling in the same session (30% trichloroacetic acid gave good results in the authors' experience) or laser to erase age marks and dyschromia.

A light bandage may be placed after surgery for a couple of days; no special care is needed afterwards.

8. Body contouring: gluteal augmentation using fat graft

The beauty of the buttock area is a difficult subject to address since racial and aesthetic preferences plays a major role in identifying the definition of an aesthetically pleasing buttock. There are some consensuses about the characteristics of a beautiful buttock area, which includes rounded shape, smooth projecting curves, short intergluteal crease and intragluteal crease that reach mid-thigh. The waist hip ratio (WHR) plays a crucial role in determining the upper extent of buttock and thus the back-to-buttock interface. Toledo [44] mentioned this ratio as 0.6 in South Americans and 0.7 in European females. In an attempt to understand the deformities in the buttock area, Murillo [45] had divided the buttock into A-direct areas (gluteus maximus, iliac, trochanteric and ischioirectal), B-indirect areas (sacral, femoral) and C-the border line area (gluteofemoral). We like to use a simple classification based in our mind, the WHR and the end shape we want to reach. This classification represents the buttock area and influencing areas around they are eight areas as shown in **Figure 1**. Based on these descriptions and deformities, there are four shapes of buttocks (triangular, trapezoidal, round and square) as given in **Figure 2**. Mendieta [46] describes point A, B and C. The foundation of this area is the pelvic skeletal system, which eventually share in forming the overall shape of buttocks, Caldwell-Moloy [47] described skeletal pelvis into gynecoid, anthropoid, platypeloid and android. We find this classification although explains different shapes of buttock area

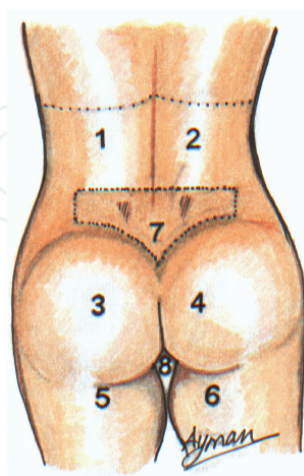


Figure 1. The buttock area and influencing areas around (1,2) bilateral symmetric waist area, (3,4) bilateral symmetric buttock area, (5,6) bilateral symmetric thighs, (7) sacral area, (8) diamond shaped area.

yet from practical point is irrelevant since there is no technique that involves bone remodelling for buttock reshaping.

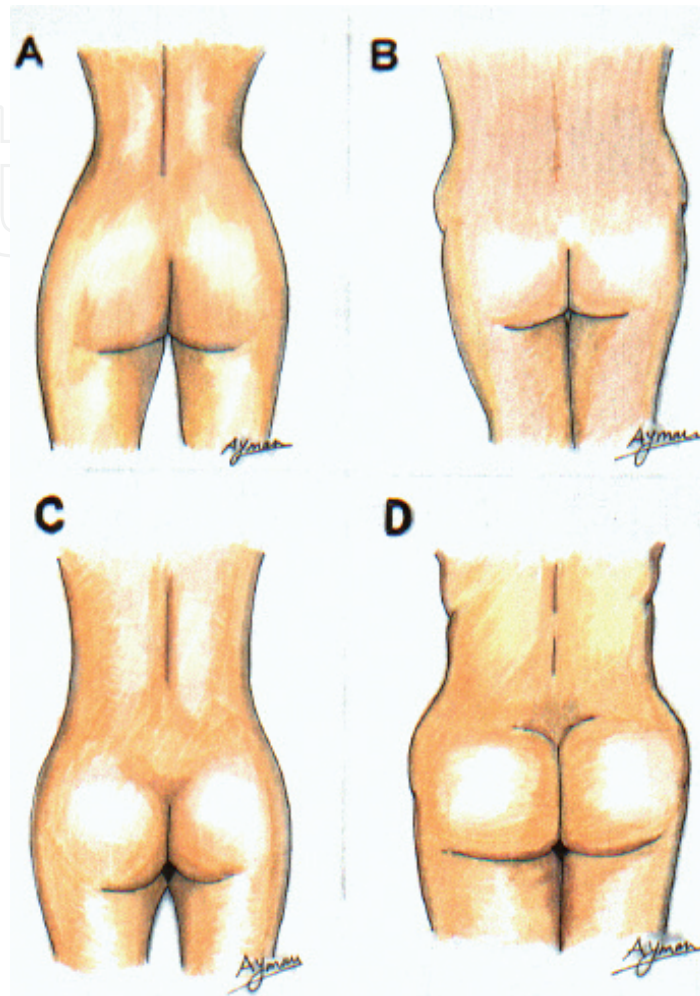


Figure 2. The four common shapes of buttocks A—triangular; B—trapezoidal; C—rounded; and D—square.

8.1. Technique tips and pitfalls

The key idea to reach the final shape of the buttock that is agreed upon with the patient is to remove and add fat in areas based on clinical analysis. The patient is instructed to shave related areas and take a shower the night before operation. Marking are done before operation while patient is standing in front of a mirror to double check the patient's will and opinion. Two colours are used in drawing areas to be injected and liposuctioned with estimate amount of fat to be added or removed on both sides. Although the choice of epidural anaesthesia is given, most patients pick up general anaesthesia. Scrubbing of patient is done after anaesthesia and towelling follows, the solution used is 500-cc Lactated Ringer's solution with adrenaline concentration (1/100000). Injection is done on a 1:1 ratio based on the amount of liposuction. The method used for liposuction is the conventional one using a 5-mm cannula and sy-

ringe. The amount depends on degree of deformity putting in mind to obtain an aesthetic WHR. The fat to be injected is decanted, usually we wait for 10 minutes and watery fluid is thrown and fat is taken to be injected. The buttock injection is done using same cannula in more than one plane avoiding intra-muscular injection. The average amount per side injected is 700cc, this is followed by gentle massage to settle injected fat and redistribute it evenly, suturing of incisions are done, the patient is encouraged to walk next day, have a shower and wear elastic garments for 4-6 weeks. A follow-up after 5 days and then every 10 days for one month to check on current condition and exclude any complications is carried out. Fat grafting in buttocks has two main issues that plastic surgeons do differ about; the first is resolution of the fat injected and longevity of the grafts injected. In our technique, we believe that intra-muscular injection can produce more complications than the postulated benefit of increase survival of fat grafts and, hence increase projection. Some authors reported the increased survival of fat when injected intra-muscular, moreover this may be lethal and carry a mortality rate as described by Czerny [48]. Lexer [6] had demonstrated using MRI scan, the survival of fat grafting in buttocks confirming role of fat grafting to increase buttock projection. The other point is the choice of buttock implant rather than fat injection, in the Ref. [7] high complications as regard to augmentation of buttocks as exposure and infection are reported. This may even necessitate removal of implant with corrective operation later on.

9. Body contouring: breast reshaping using fat graft

The word 'reshaping' is a more accurate description than 'augmentation' simply using fat grafts is one of techniques which result in ending up with an aesthetically pleasing breast and not only increasing the size of pre-existing breast. The history of breast augmentation dates back to more than a century. Many techniques were used; some worked, others did not. Substances that were used were paraffin, petroleum jelly and silicon [49]. The use of fat grafts had been used very early with a lot of changes to reach the final form we are using now. Berson [50] used dermofascial grafts with uncertain results. Complications like fat necrosis and major degree of resorption had been described by Watson [10] when injecting fat graft in the breast. Coleman [51] reported successful fat grafting in some of cases in 2007. In 2009, the ASPS fat graft task force stated that, 'Fat grafting may be considered for breast augmentation and correction of defects associated with medical conditions and previous breast surgeries; however, results are dependent on technique and surgeon expertise' [29].

9.1. Indications

In our experience, fat grafting has been used in various scenarios of breast surgery, from aesthetic to reconstruction.

For those patients, who do not want implants, primary breast augmentation in patients suffering from small sized breast and wish for modest increase about one cup. Sequential fat injections can increase the total amount injected reaching more than a one-cup size.

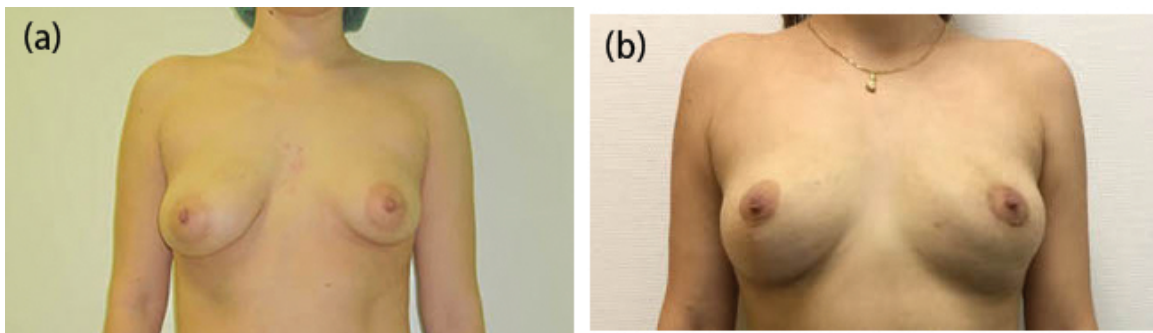


Figure 3. (a and b) Tuberous breast case treated with right mastopexy and left side lipofilling (two sessions) rigotomy and areola downsizing.

In association with silicone implants, fat injection could be used for masking apparent edges of breast implant or correction of associated wrinkles; it is an effective non-invasive procedure to correct visible rippling.

When implant explanation is required and the patient want to downsize the breast a combination of fat grafting and decreasing the pocket by sutures is usually a good choice for reaching the patient's goal.

Congenital breast deformity cases with tuberous breast where release of constricted base and fat injection would give a nice suitable breast size and shape when implant is not desired by patient or strictly necessary thanks to enough breast glandular volume (**Figure 3a and b**).

Breast reconstruction cases that had resultant defect after lumpectomy or skin sparing mastectomy or breast reduction asymmetry could benefit from localized fat injection to correct contour of breast or recreate the whole breast (**Figure 4a and b**).

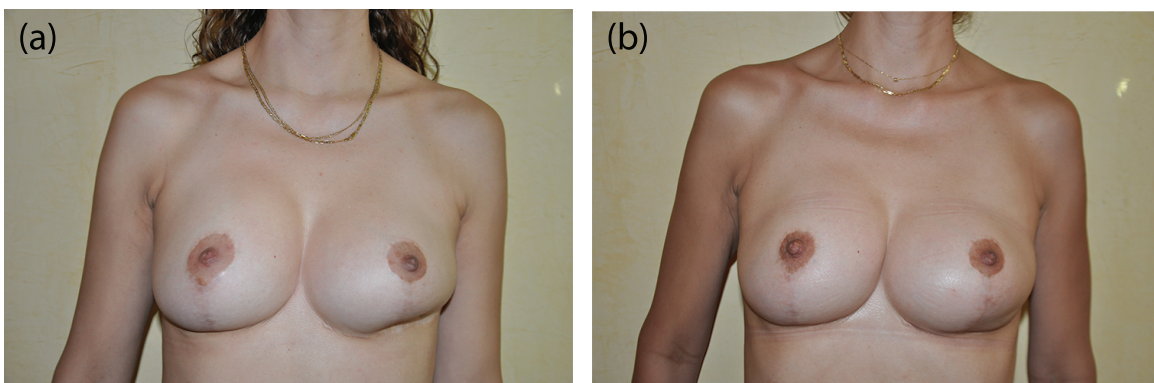


Figure 4. (a and b) Breast reshaping using fat graft after surgery complication. Two to three sessions may be needed.

Fat injection in breast had been used in combination with what is called the Brava system in cases of small breasts with very tight skin envelopes .The Brava system is an apparatus that induce external expansion to the skin to create a well-shaped cavity to be injected with fat thus forming a nice shaped breast. The apparatus is used for 3–4 weeks before surgery then breast-reshaping using fat injection is done.

9.2. Technique tips and pitfalls

Harvesting of fat is done in the same way we use in gluteal augmentation, as regard to injection, the fat is placed using blunt cannula 17 gauge, injection is done in all levels but not intramuscular putting in mind that superficial injection plays a major role in the final shape of breast. The amount injected is about 300–400-cc per breast. In cases of depressed scars, a v-shaped cannula is used to separate skin from underlying tissue. Incisions used are usually in inframammary crease or periareolar. All incisions are closed by 4/0 prolene, padding and a well-fitting bra are used while the patient is on table. In 1895, Czerny [48] had a 1 year stable result after lipoma transfer. In 1919, Lexer [3] had described positive results after fat grafting to all area including breast. In 1995 Coleman [52] had positive predictable results with their technique. In our experience fat injection in breast is a reliable technique with the potential to increase breast volume and reach an aesthetic shape even without using the Brava system (Brava, Inc., Miami, FL, USA), this can be done by multiple procedures specially in patients needing to increase the size more than one cup. We find the Brava technique helpful in cases with severe tight skin, we also used decanting only in fat preparation with no centrifuge with optimum results. It is obvious that although there are many indication for fat grafting in breast it is mainly for ‘breast reshaping’, rather than augmentation on the other hand breast prosthesis are still having a more popular and reproducible results but in breast augmentation. One point, which is still controversial, is the safety of fat injection especially in the breast.

The ASPS Task Force recommendations regarding fat grafts specified the high-risk patient who carries the BRCA-1, BRCA-2 gene and if they or their families have history of breast cancer. We agree on that and follow such recommendations, but the subject especially with the introduction of fat derived stem cells should be further studied.

10. Complications of fat grafting

Fat transfer is a widely used procedure now with a wide range of indications and the surgeon being acquainted with complications and dealing with it is of utmost importance. We should remember that this procedure includes complications of liposuction as well as fat transfer. A resume of complications that can happen shortly after procedure within a week and late complications will help the reader to recognize and manage them.

Infection. Although rare nowadays, still it can be seen in some cases. The primary goal is to prevent it from happening as dealing with infected fat grafts is troublesome and usually results in deformity. This can be done by the presence of sterile operating room and instrumentation, using of prophylaxis antibiotics, proper screening of patient for HIV and hepatitis B and C.

Embolism. It may be due compression on the venous system as in calf injection with resultant thrombus formation and produce a serious complication like pulmonary thromboembolism that either resolves or result in an increased pulmonary infarction and hypertension. Accidental injection of air in subcutaneous tissue with opening of big veins like the ones present in the neck could be lethal and mimic picture of massive pulmonary embolism

Blindness. It can take place in cases where fat injection is done around the orbit either by directly injecting fat into veins or by penetrating the eye capsule with formation of thrombus and resultant in central retinal vein occlusion. This can be avoided by using blunt cannula and marking of any veins apparent, also injection while withdrawing the cannula. Not only blindness had been described but also brain insults in the form of infarction had been recorded [53].

Skin necrosis. This can happen from severe infection or over-injection with resultant oedema and too much compression, there is no definite volumes that is fixed, each individual varies from the other yet average amount injected depends on laxity of skin and under-injection is always better than over-injection as there is the chance to inject more later but it is difficult to treat skin necrosis.

Haematoma and seromas. This can happen occasionally. As regard to haematoma, this can be avoided by proper pre-operative management and evaluation stopping smoking for 4 weeks and non-steroidal medications for 1 week would protect against unwanted bleeding. The uses of blunt cannula and avoid injury of seen veins. Compression is the main line of treatment and in the case of seroma, persistence aspiration and compression is done

Nerve injury. Depending on the site, facial nerve branches may be affected in injection of face or dorsal nerves in cases of hand injection. The injury could be permanent or transient with recovery depending on degree and type of injury [54].

Absorption (excessive). The rate of absorption depends a lot on atraumatic technique used in harvesting as well as areas where fat is harvested from, like upper abdomen and upper back. The rate of absorption varies from 0–50%. Some authors had prescribed over-correction by 30% [55]. This is suitable in areas like buttocks and breast but surely not the face in our opinion.

Asymmetry. Since fat injection is done on both sides of body, for example breasts gluteal area and hands, symmetrical injection should be done unless there is asymmetrical obvious difference, sometimes a combined liposuction and fat injection to reach symmetry is done. Minimal asymmetry can be accepted, as it is not obvious except for the patient only.

Cysts and mass formation. Cysts of various sizes can occur after fat injection it is mainly oily cyst, it can occur in any site but more common with increased fat injection. Various treatments had been described triamcinolone injection [56], aspiration and compression in big cysts. Hypertrophy of part of injected fat leads to formation of localized mass or sometimes generalized hypertrophy of the whole injected area. In order to avoid this, over-injection of fat is not recommended and the proper amount and plane of injection should be done. Fat also may migrate when over-injection is done and has been reported in the forehead where authors used botulinum toxin in association with fat injection [57].

Calcifications. Calcifications in breast are the most ones that invite worries yet for an experience radiologist both the size and form are quite different. Micro-calcifications from fat necrosis are Peri-parynchymal and do not exhibit multi-density, rod-like, punctate or branching spicule [58].

Acknowledgements

Thanks to Dr. Carlos Oaxaca for contributing with clinical images of his own cases.

Author details

Marco Romeo^{1*}, Ayman Elmeligy² and Khalid Elsherbeny²

*Address all correspondence to: doctor@drmarcoromeo.com

¹ University Autonoma of Madrid and Fundación Jimenez Diaz, Madrid, Spain

² Department of Plastic Surgery, Ain Shams University, Cairo, Egypt

References

- [1] C. S. Hultman and S. Daiza, "Skin-sparing mastectomy flap complications after breast reconstruction: review of incidence, management, and outcome," *Ann. Plast. Surg.*, vol. 50, no. 3, pp. 249–255; discussion 255, 2003.
- [2] R. Gersuny, "About subcutaneous prosthesis," *Ztschr Heilk*, vol. 21, p. 199, 1900.
- [3] E. Lexer, "*The free trasplants*". Enke, Stuttgart, Germany, 1919.
- [4] D. A. Roncari and R. L. Van, "Promotion of human adipocyte precursor replication by 17beta-estradiol in culture," *J. Clin. Invest.*, vol. 62, no. 3, pp. 503–508, 1978.
- [5] R. Ellenbogen, "Free autogenous pearl fat grafts in the face – a preliminary report of a rediscovered technique," *Ann. Plast. Surg.*, vol. 16, no. 3, pp. 179–194, 1986.
- [6] A. Chajchir, I. Benzaquen, and A. Arellano, "Comparative study on lipoinjection and other methods," *Med. Cutánea Ibero-Latino-Americana*, vol. 16, no. 6, pp. 489–496, 1988.
- [7] S. R. Coleman, "Facial recontouring with lipostructure," *Clin. Plast. Surg.*, vol. 24, no. 2, pp. 347–367, 1997.
- [8] S. Coleman, "The technique of periorbital lipo infiltration," *Oper Tech. Plast. Reconstr. Surg.*, vol. 1, no. 2, pp. 120–126, 1994.
- [9] D. A. De Ugarte, K. Morizono, A. Elbarbary, Z. Alfonso, P. A. Zuk, M. Zhu, J. L. Dragoo, P. Ashjian, B. Thomas, P. Benhaim, I. Chen, J. Fraser, and M. H.

- Hedrick, "Comparison of multi-lineage cells from human adipose tissue and bone marrow," *Cells. Tissues. Organs*, vol. 174, no. 3, pp. 101–109, 2003.
- [10] P. Gir, G. Oni, S. A. Brown, A. Mojallal, and R. J. Rohrich, "Human adipose stem cells: current clinical applications," *Plast. Reconstr. Surg.*, vol. 129, no. 6, pp. 1277–1290, 2012.
- [11] H. Kato, K. Mineda, H. Eto, K. Doi, S. Kuno, K. Kinoshita, K. Kanayama, and K. Yoshimura, "Degeneration, regeneration, and cicatrization after fat grafting: dynamic total tissue remodelling during the first 3 months," *Plast. Reconstr. Surg.*, vol. 133, no. 3, pp. 303e–313e, 2014.
- [12] D. Del Vecchio and R. J. Rohrich, "A classification of clinical fat grafting," *Plast. Reconstr. Surg.*, vol. 130, pp. 511–522, 2012.
- [13] S. O. P. Hofer, K. M. Knight, J. J. Cooper-White, A. J. O'Connor, J. M. Perera, R. Romeo-Meeuw, A. J. Penington, K. R. Knight, W. A. Morrison, and A. Messina, "Increasing the volume of vascularized tissue formation in engineered constructs: an experimental study in rats," *Plast. Reconstr. Surg.*, vol. 111, no. 3, pp. 1186–1192; discussion 1193–1194, 2003.
- [14] S. R. Coleman, "Hand rejuvenation with structural fat grafting," *Plast. Reconstr. Surg.*, vol. 110, no. 7, pp. 1731–1744; discussion 1745–1747, 2002.
- [15] D. T. W. Leong, D. W. Hutmacher, F. T. Chew, and T. C. Lim, "Viability and adipogenic potential of human adipose tissue processed cell population obtained from pump-assisted and syringe-assisted liposuction," *J. Dermatol. Sci.*, vol. 37, no. 3, pp. 169–176, 2005.
- [16] A. Gabriel, M. C. Champaneria, and G. P. Maxwell, "Fat grafting and breast reconstruction: tips for ensuring predictability," *Gland Surg.*, vol. 4, no. 3, pp. 232–243, 2015.
- [17] L. L. Q. Pu, S. R. Coleman, X. Cui, R. E. H. Ferguson, and H. C. Vasconez, "Cryopreservation of autologous fat grafts harvested with the coleman technique," *Ann. Plast. Surg.*, vol. 64, no. 3, pp. 333–337, 2010.
- [18] M. R. Kaufman, J. P. Bradley, et al. "Autologous fat transfer national consensus survey: trends in techniques for harvest, preparation, and application, and perception of short- and long-term results," *Plast. Reconstr. Surg.*, vol. 119, pp. 323–331, 2007.
- [19] O. Shoshani, J. Berger, L. Fodor, Y. Ramon, A. Shupak, I. Kehat, A. Gilhar, and Y. Ullmann, "The effect of lidocaine and adrenaline on the viability of injected adipose tissue – an experimental study in nude mice," *J. Drugs. Dermatol.*, vol. 4, no. 3, pp. 311–6, 2005.
- [20] M. Keck, M. Zeyda, K. Gollinger, S. Burjak, L.P. Kamolz, M. Frey, and T. M. Stulnig, "Local anesthetics have a major impact on viability of preadipocytes and their

- differentiation into adipocytes," *Plast. Reconstr. Surg.*, vol. 126, no. 5, pp. 1500–1505, 2010.
- [21] A.C. Girard, M. Atlan, K. Bencharif, M. K. Gunasekaran, P. Delarue, O. Hulard, C. Lefebvre-d'Hellencourt, R. Roche, L. Hoareau, and F. Festy, "New insights into lidocaine and adrenaline effects on human adipose stem cells," *Aesthetic Plast. Surg.*, vol. 37, no. 1, pp. 144–152, 2013.
- [22] M. Zhu, Z. Zhou, Y. Chen, R. Schreiber, J. T. Ransom, J. K. Fraser, M. H. Hedrick, K. Pinkernell, and H.C. Kuo, "Supplementation of fat grafts with adipose-derived regenerative cells improves long-term graft retention," *Ann. Plast. Surg.*, vol. 64, no. 2, pp. 222–228, 2010.
- [23] K. Li, J. Gao, Z. Zhang, J. Li, P. Cha, Y. Liao, G. Wang, and F. Lu, "Selection of donor site for fat grafting and cell isolation," *Aesthetic Plast. Surg.*, vol. 37, no. 1, pp. 153–158, 2013.
- [24] K. Small, M. Choi, O. Petruolo, C. Lee, and N. Karp, "Is there an ideal donor site of fat for secondary breast reconstruction?," *Aesthet. Surg. J.*, vol. 34, no. 4, pp. 545–550, 2014.
- [25] J. H. Lee, J. C. Kirkham, M. C. McCormack, A. M. Nicholls, M. A. Randolph, and W. G. Austen, "The effect of pressure and shear on autologous fat grafting," *Plast. Reconstr. Surg.*, vol. 131, no. 5, pp. 1125–1136, 2013.
- [26] Daniel Del Vecchio and Hetal Fichadia (2012). Autologous Fat Transplantation — A Paradigm Shift in Breast Reconstruction, *Breast Reconstruction — Current Techniques*, Prof. Marzia Salgarello (Ed.), ISBN: 978-953-307-982-0, InTech, Rijeka, Croatia
- [27] M. Erdim, L. E. Teze, A. Numanoglu, and A. Sav, "The effects of the size of liposuction cannula on adipocyte survival and the optimum temperature for fat graft storage: an experimental study," *J. Plast. Reconstr. Aesthet. Surg.*, vol. 62, no. 9, pp. 1210–1214, 2009.
- [28] M. A. Shiffman and S. Mirrafati, "Fat transfer techniques: the effect of harvest and transfer methods on adipocyte viability and review of the literature," *Dermatolog. Surg.*, vol. 27, no. 9, pp. 819–826, 2001.
- [29] K. A. Gutowski, "Current applications and safety of autologous fat grafts: a report of the ASPS fat graft task force," *Plast. Reconstr. Surg.*, vol. 124, no. 1, pp. 272–280, 2009.
- [30] M. Kurita, D. Matsumoto, T. Shigeura, K. Sato, K. Gonda, K. Harii, and K. Yoshimura, "Influences of centrifugation on cells and tissues in liposuction aspirates: optimized centrifugation for lipotransfer and cell isolation," *Plast. Reconstr. Surg.*, vol. 121, no. 3, pp. 1033–1041; discussion 1042–1043, 2008.
- [31] R. Khater, P. Atanassova, Y. Anastassov, P. Pellerin, and V. Martinot-Duquennoy, "Clinical and experimental study of autologous fat grafting after processing by centrifugation and serum lavage," *Aesthetic Plast. Surg.*, vol. 33, no. 1, pp. 37–43, 2009.
- [32] A. Condé-Green, N. F. Gontijo De Amorim, and I. Pitanguy, "Influence of decantation, washing and centrifugation on adipocyte and mesenchymal stem cell content of

- aspirated adipose tissue: a comparative study," *J. Plast. Reconstr. Aesthetic Surg.*, vol. 63, no. 8, pp. 1375–1381, 2010.
- [33] S. R. Coleman, "Structural fat grafts: the ideal filler?," *Clin. Plast. Surg.*, vol. 28, no. 1, pp. 111–119, 2001.
- [34] P. Tonnard, A. Verpaele, G. Peeters, M. Hamdi, M. Cornelissen, and H. Declercq, "Nanofat grafting: basic research and clinical applications," *Plast. Reconstr. Surg.*, vol. 132, no. 4, pp. 1017–1026, 2013.
- [35] P. S. A. Nguyen, C. Desouches, A. M. Gay, A. Hautier, and G. Magalon, "Development of micro-injection as an innovative autologous fat graft technique: the use of adipose tissue as dermal filler," *J. Plast. Reconstr. Aesthet. Surg.*, vol. 65, no. 12, pp. 1692–1699, 2012.
- [36] M. S. Choudhery, M. Badowski, A. Muise, and D. T. Harris, "Comparison of human mesenchymal stem cells derived from adipose and cord tissue," *Cytotherapy*, vol. 15, no. 3, pp. 330–343, 2013.
- [37] J. M. Gimble, A. J. Katz, and B. A. Bunnell, "Adipose-derived stem cells for regenerative medicine," *Circ. Res.*, vol. 100, no. 9, pp. 1249–1260, 2007.
- [38] J. A. Aronowitz and J. D. I. Ellenhorn, "Adipose stromal vascular fraction isolation: a head-to-head comparison of four commercial cell separation systems," *Plast. Reconstr. Surg.*, vol. 132, no. 6, p. 932e–939e, 2013.
- [39] J. Haik, R. Talisman, J. Tamir, J. Frand, E. Gazit, J. Schibi, A. Glicksman, and A. Orenstein, "Breast augmentation with fresh-frozen homologous fat grafts," *Aesthetic Plast. Surg.*, vol. 25, no. 4, pp. 292–294.
- [40] L. Hang-Fu, G. Marmolya, and D. H. Feiglin, "Liposuction fat-fillant implant for breast augmentation and reconstruction," *Aesthet. Plast. Surg.*, vol. 19, no. 5, pp. 427–437, 1995.
- [41] J. Y. Petit, V. Lohsiriwat, K. B. Clough, I. Sarfati, T. Ihrari, M. Rietjens, P. Veronesi, F. Rossetto, A. Scevola, and E. Delay, "The oncologic outcome and immediate surgical complications of lipofilling in breast cancer patients: a multicenter study – Milan-Paris-Lyon experience of 646 lipofilling procedures," *Plast. Reconstr. Surg.*, vol. 128, no. 2, pp. 341–346, 2011.
- [42] F. De Lorenzi, V. Lohsiriwat, and J. Y. Petit, "In response to: Rigotti G, Marchi A, Stringhini P et al. 'Determining the oncological risk of autologous lipoaspirate grafting for post-mastectomy breast reconstruction,' *Aesth Plast Surg* 2010; 34: 475," *Aesthetic Plast. Surg.*, vol. 35, no. 1, pp. 132–133, 2011.
- [43] N. Villanueva, S. M. Hill, K. H. Small, and R. J. Rohrich, "Technical refinements in autologous hand rejuvenation," *Plast. Reconstr. Surg.*, vol. 136, no. 6, pp. 1175–1179, 2015.

- [44] L. S. Toledo, "Gluteal augmentation with fat grafting the Brazilian buttock technique: 30 years' experience," *Clin. Plast. Surg.*, vol. 42, no. 2, pp. 253–261, 2015.
- [45] W. L. Murillo, "Buttock augmentation: case studies of fat injection monitored by magnetic resonance imaging," *Plast. Reconstr. Surg.*, vol. 114, no. 6, pp. 1606–1614; discussion 1615–1616, 2004.
- [46] C. G. Mendieta, "Classification system for gluteal evaluation," *Clin. Plast. Surg.*, vol. 33, no. 3, pp. 333–346, 2006.
- [47] H. A. Caldwell and W. Moloy, "Anatomical variations of female pelvis and their effect in labor with a suggested classification," *Am. J. Obs. Gynecol.*, vol. 26(4), no. 26, pp. 479–505, 1933.
- [48] V. Czerny, "Plastic replacement of the mammary gland by a lipoma" *Zentralbl Chir*, vol. 27, p. 72, 1895.
- [49] M. Thorek, "Plastic surgery of the breast and abdominal wall," *Plast. Surg. Breast Abdom. Wall*, vol. 120, no. 1, p. 85, 1942.
- [50] M. I. Berson, "Derma-fat-fascia transplants used in building up the breasts," *Surgery*, vol. 15, no. 3, pp. 451–456, 1914.
- [51] S. R. Coleman and A. P. Saboeiro, "Fat grafting to the breast revisited: safety and efficacy," *Plast. Reconstr. Surg.*, vol. 119, no. 3, pp. 775–785; discussion 786–787, 2007.
- [52] S. R. Coleman, "Long-term survival of fat transplants: controlled demonstrations," *Aesthetic Plast. Surg.*, vol. 19, no. 5, pp. 421–425, 1995.
- [53] O. Thaumat, F. Thaler, P. Loirat, J. P. Decroix, and A. Boulin, "Cerebral fat embolism induced by facial fat injection," *Plast. Reconstr. Surg.*, vol. 113, no. 7, pp. 2235–2236, 2004.
- [54] J. I. Park, "Preoperative percutaneous facial nerve mapping," *Plast. Reconstr. Surg.*, vol. 101, no. 2, pp. 269–77, 1998.
- [55] M. A. Shiffman, "History of Autologous Fat Transfer," in *Autologous Fat Transfer*, Berlin, Heidelberg: Springer, 2010, pp. 3–4.
- [56] G. Johnson, "Autologous fat graft by injection: ten year experience," *Am. J. Cosmet. Surg.*, vol. 9, pp. 61–65, 1992.
- [57] E. A. Coleman, S. J. Min, A. Chomiak, and A. M. Kramer, "Posthospital care transitions: patterns, complications, and risk identification," *Health Serv. Res.*, vol. 39, no. 5, pp. 1449–1465, 2004.
- [58] M. Bircoll, "Autologous fat transplantation: an evaluation of microcalcification and fat cell survivability following (AFT) cosmetic breast augmentation," *Am. J. Cosmet. Surg.*, vol. 5, pp. 283–288, 1988.