

We are IntechOpen, the world's leading publisher of Open Access books Built by scientists, for scientists

6,900

Open access books available

186,000

International authors and editors

200M

Downloads

Our authors are among the

154

Countries delivered to

TOP 1%

most cited scientists

12.2%

Contributors from top 500 universities



WEB OF SCIENCE™

Selection of our books indexed in the Book Citation Index
in Web of Science™ Core Collection (BKCI)

Interested in publishing with us?
Contact book.department@intechopen.com

Numbers displayed above are based on latest data collected.
For more information visit www.intechopen.com



Body Contour Surgery in Massive Weight Loss Patients

Redefining Body Lift Surgery and Other Contour Deformities

Marcelo A. Cuadrado, Gabriel Moina and
Daniel Moina

Additional information is available at the end of the chapter

<http://dx.doi.org/10.5772/64839>

Abstract

Background: Massive weight loss population presents different body deformities due to deflation and poor skin tone. Deformities in the lower trunk, upper torso, arms, and thighs are based on age, degree of skin laxity, and adipose tissue. Traditional plastic surgery techniques like abdominoplasty will not work in this kind of patients. Surgeon's major challenge is how to restore the skin and overlaying fat in patients that do not have the same deformities. Identifying the vectors of dropping tissue will lead to classifying this kind of deformities and planning the best surgical procedure.

Methods: Different operative techniques are described in this article to safely manage the main areas of the body. The use of combined liposuction to improve lipodystrophy areas is well indicated to avoid any complication of the main surgical treatment. A step-by-step description on postoperative indications and management is included.

Results: Plastic surgery office consultation has increased in massive weight loss patients, so it is very important to understand new body contouring techniques. It is critical that overall patient satisfaction is (mostly) achieved.

Conclusions: With a comprehensive diagnosis, patient classification, dynamic marking, and postoperative patient management, body contouring techniques have evolved from a traditional abdominoplasty, brachioplasty, thighplasty to a multiple vector correction. Results are consistent over time.

Keywords: body contouring, massive weight loss, body shaping, body lift, arm lifts, thigh reduction

1. Introduction

Today, massive weight loss patients are a big population in terms of plastic surgery office consultation. Since bariatric surgery evolution, many of the severe obese patients have become improved their health and life quality and the results of this change usually impacts their body. Skin tone and adipose tissue have their first impact revealing lax and lipodystrophy leading to hanging skin and fat all over the body.

One of the biggest problems is the correct diagnosis of patient's contour deformities.

It is our duty to exam all areas that we must treat as sections to have the contour as accurate as possible.

There are (**Figures 1 and 2**):

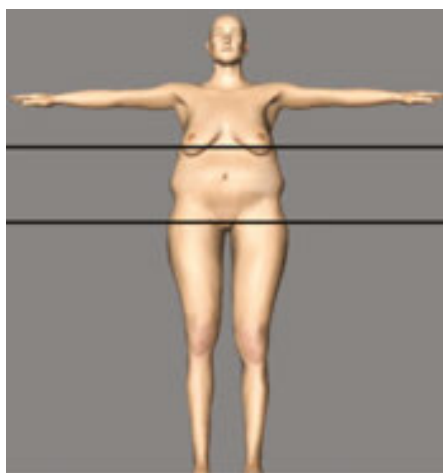


Figure 1. Front upper, middle, and lower section.

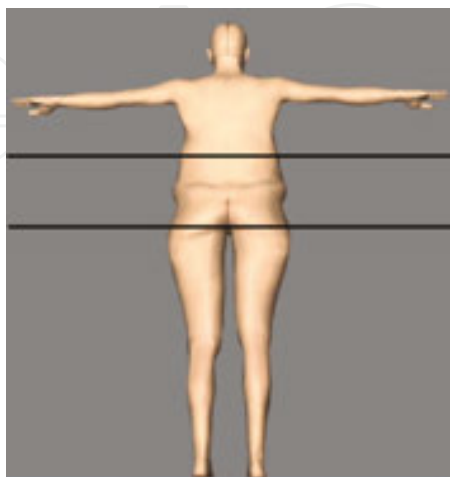


Figure 2. Back upper, middle, and lower section.

- Upper section (arms, thorax, and upper back).
- Middle section (central part of abdominal wall, lateral wall, buttocks, and back).
- Lower section (medial and lateral thighs and legs).

2. Body lift surgery

In the middle section, there are many surgical treatments and we must identify the best one for every patient.

So for a better classification, we must address patients' variability patterns (**Figures 3 and 4**):

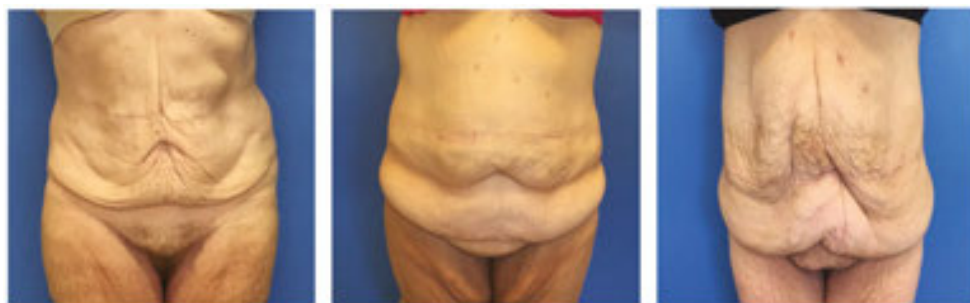

Figure 3. Variability patterns at front.

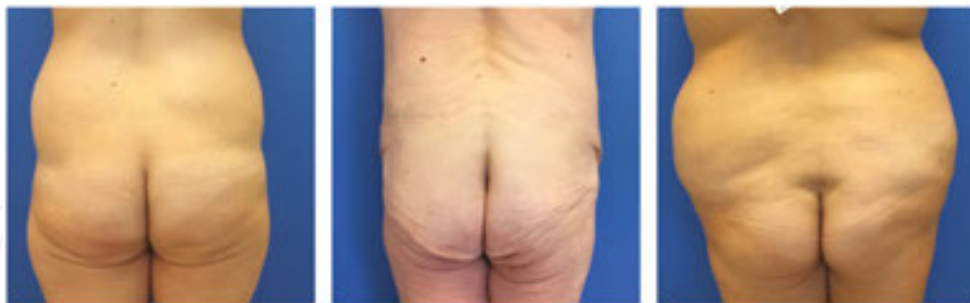

Figure 4. Variability patterns at back.

- In lax skin and rolls at the front and back in every patient.
- Previous scars (Special attention in anatomical blood supply).
- Structural body shape (android or gynecoid).
- Intra-abdominal excess.

Knowing the anatomical shape, we could see which one will have a better contour:

- Severe skin laxity, low adipose tissue, and medium size skeletal muscle will be the best body contouring patients, only need to re-drape skin to the continent underneath.
- Large and oblique scars are a big problem due to vascularization. If so, discuss with patient about necrosis and complications.
- Women mostly have a pear shape or gynecoid and are narrow from torso and wider at the hips, so stretching skin laxity contour improves. Men and some women have an android or pear shape so circumferential procedures are a standard treatment avoiding denting or heavy dog ears.

Why are body lifts the best procedures in the massive weight loss patients?

A common example is to watch the anterior abdominal wall and discard lateral and back or pretend to treat the anterior part and improve contour on lateral and back.

As shown in **Figure 5**, classic abdominoplasty has an ellipse pattern with a wider medial resection that have a 100% of skin tension, reaching the most lateral resection with no tension at the end of the closure is achieved and final dog ear or bulky tissue is revealed.

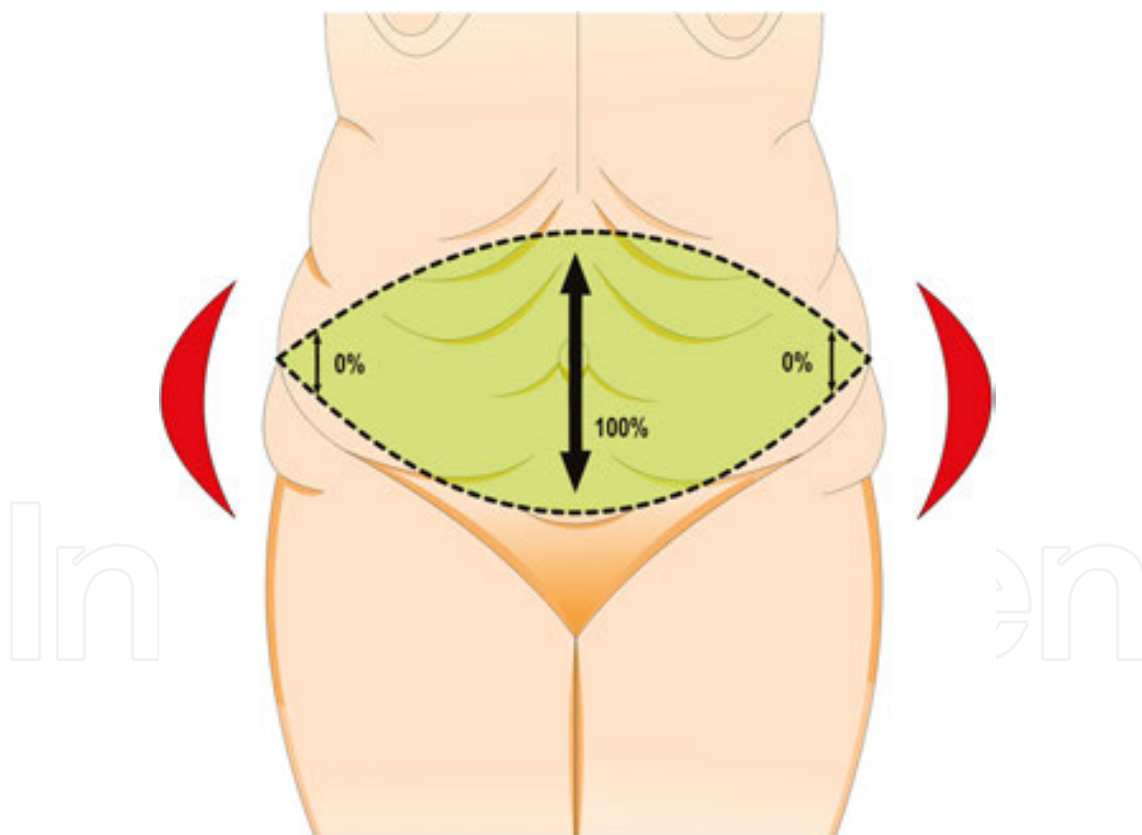


Figure 5. Classic abdominoplasty resection. The central part has the highest tension.

With a circumferential procedure, skin is resected over the front and back and a 100 percent of high tension applied to the skin ends with the best improvement in contour [1] (**Figures 6 and 7**).

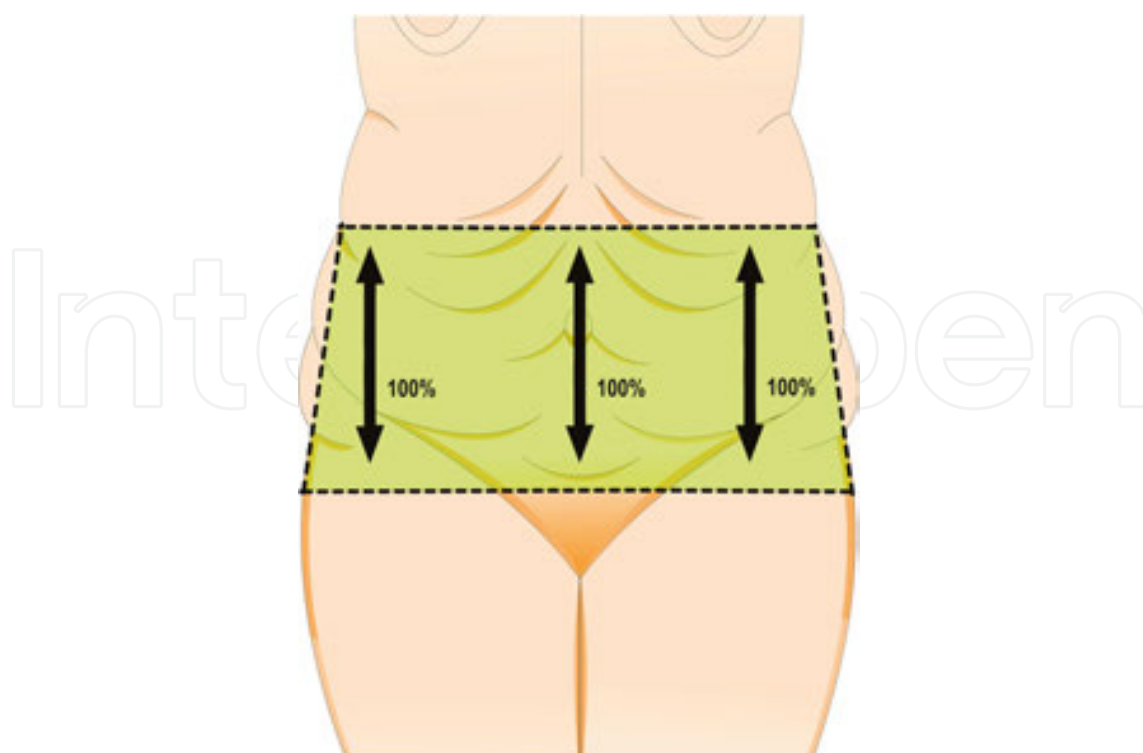


Figure 6. Highest tension in a circumferential procedure is applied at front and back.

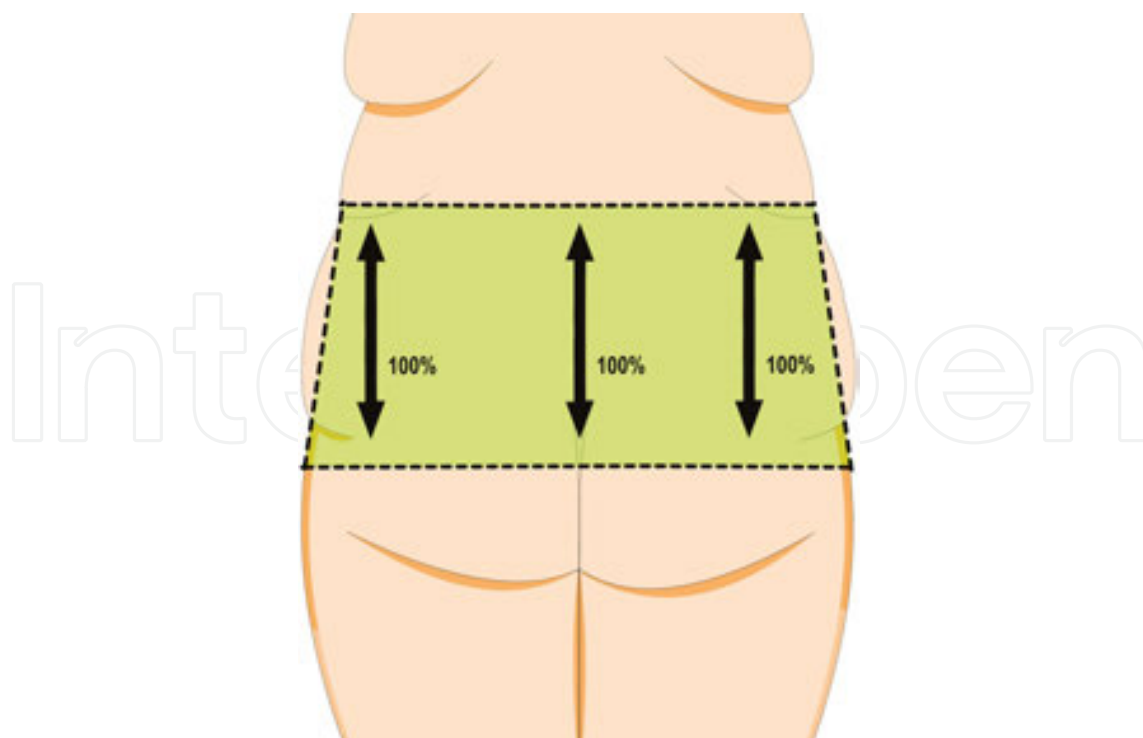


Figure 7. Higher tension at the back makes a better gluteal shape.

2.1. Markings

Start with the patient in a standing position (**Figures 8 and 9**).

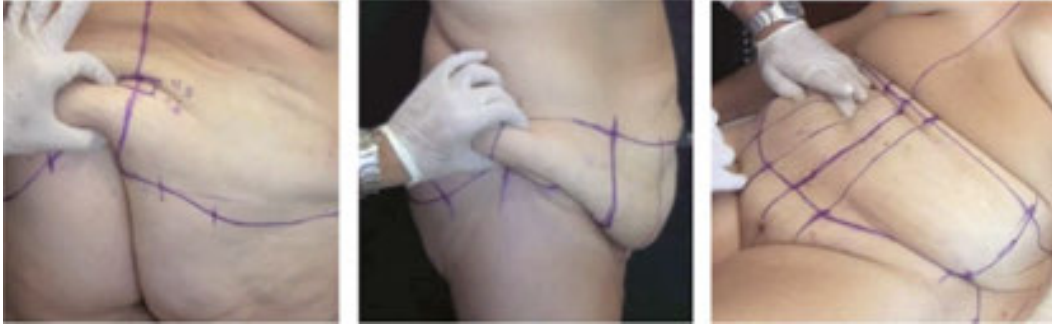

Figure 8. Dynamic pinch.

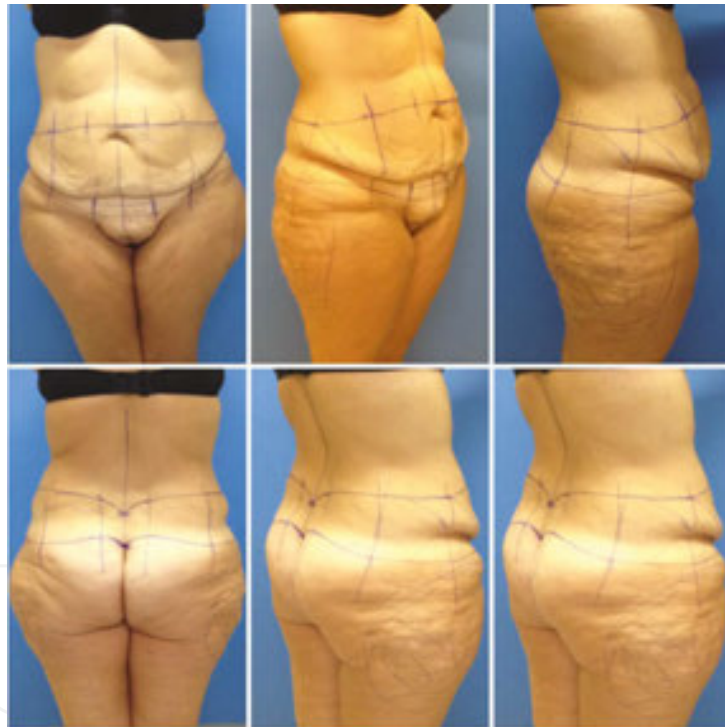

Figure 9. V-S pattern at the back and trapezoidal at front.

- Midline marking reaches xiphoid process to midline pubis.
- Midline marking of the back to gluteal crease.
- Dynamic pinch in the back lifting gluteal and lateral tissue in a V-S fashion
V (superior) and Italic S (inferior) improve buttocks shape.
- Dynamic pinch in the anterior part lifting pubis and inguinal area in a trapezoidal fashion.

- Always in the midline back decrease tension about 2 cm than pinch avoiding over resection.

Marking tips: Always use landmarks to keep anatomical references.

If not sure about resection, do not do it. It is better to decrease the amount of resection to keep surgery safe.

2.2. Operative technique

- The patient in prone position, incision, and dissection from upper marking down (**Figures 10 and 11**).
- Subfascial dissect avoiding lymphatic injury.
- Lift the flap and tailor tacking avoiding over resection.
- Fascial closure with absorbable sutures and subdermal [2].
- Drains placed under closure.
- Lateral ending with a dog ear to continue in the anterior part.
- In supine position, pubic marking incision as classic abdominoplasty.
- Subfascial dissection towards xiphoid, umbilical transposition.
- If needed, muscle plication will improve contour.
- Abdominal flap is descended and fascial and dermal closure is made.

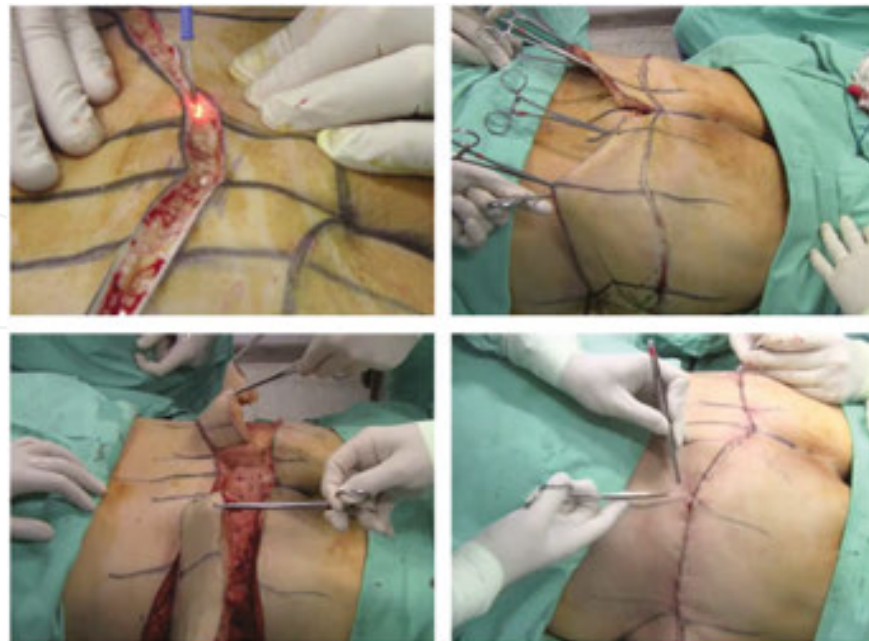


Figure 10. Body lift surgery pictures, starting in prone position. At the upper right, lifting the buttocks.

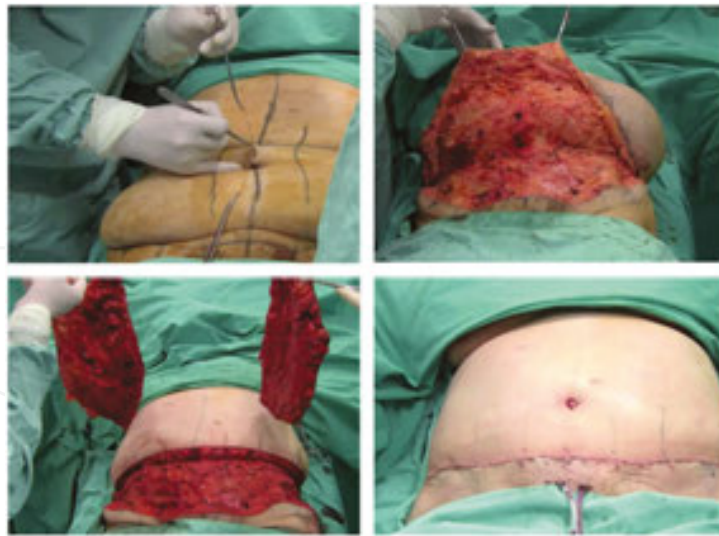


Figure 11. Body lift at the abdominal time, subfascial undermining.

Tips: Keep the subfascial tissue intact, decrease postoperative seromas.

Reaching the umbilicus area, look for any little hernia, and if so, repair it.

Safe liposuction area: Only at the lateral thighs with mild-to-severe lipodystrophy.

Patients who underwent a previous abdominoplasty have a different approach:

- The back is marking as usual.
- The lateral and anterior area is treated as an inverted ellipse fashion keeping most of the tension at lateral aspects than in the midline

Marking tips: Always look at the umbilicus position. A higher position improves in contour.

Try to lower the previous abdominoplasty scar. This is the most visible area.

Surgery tips: Umbilicus is the danger zone. Dissect the flap near the insertion and descend the new flap in a block.

If infra umbilical skin redundancy requires a higher resection, umbilical transposition is mandatory.

In lower position, umbilicus sometimes is better to repositioning a little bit higher and leaving a minimal vertical scar.

2.2.1. Postoperative care

- Do not fully extend for 1 week. It is a high-tension technique and dehiscence may occur.
- Drains will be kept until 20 ml serohematic/day.
- Compression garments for 1 month.

2.2.2. Pre- and post-op results

See **Figures 12** and **13**.

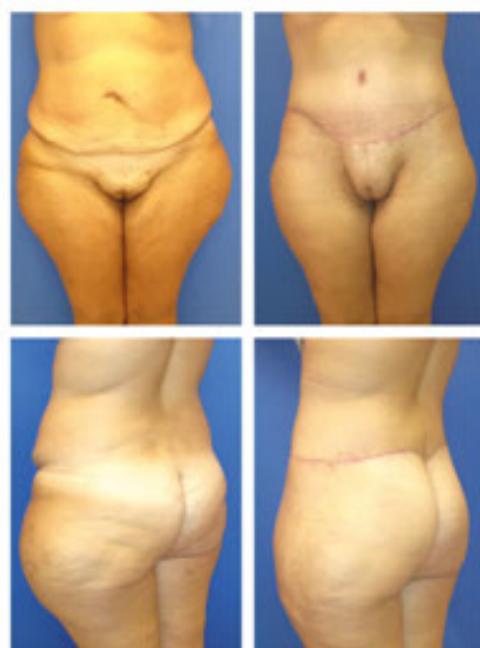

Figure 12. Left side, pre-op; right side, post-op. Improving contour and gluteal shape.

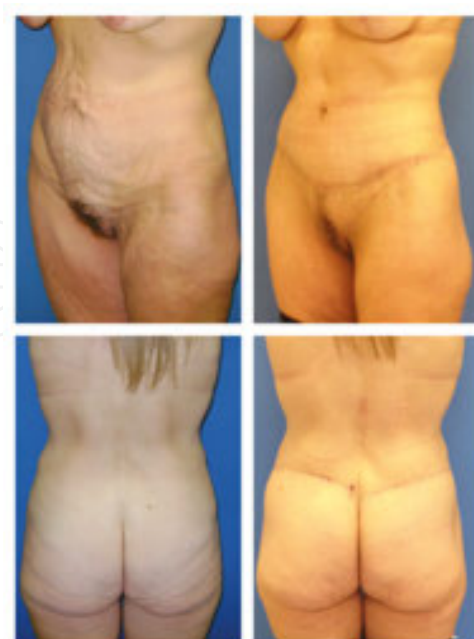

Figure 13. Left side pre-op, right side post-op, 2 years.

3. Arm lift and surrounding areas

After weight loss arms and axilla area often deflated and gravity vectors lead to a typical tent-like deformity from elbow to medial axillary line.

Patients feel uncomfortable about their upper extremities due to their visual movement of hanging tissue. This is usually patients' first consultation.

This hanging tissue reveals the drop vector due to gravity [1].

With the upper arm, horizontal extent (15°) and palms up the deformities show up.

Our goal is to reshape the arms to their natural looking.

Extension to medial axilla line is often needed due to tissue excess and not to falling in a dog ear final scar.

This is the natural extension line from the arm to the lateral chest area.

Arm deformities types and treatment classification (**Figure 14**)

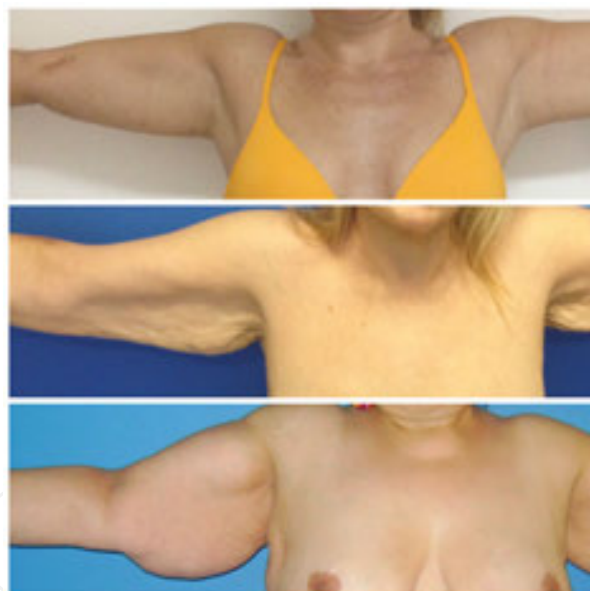

Figure 14. Different types of deformities.

Type 1: Mild adipose pinch—Good skin tension

Type 2: Severe adipose pinch—Severe skin laxity

Type 3: Low adipose pinch—Mild skin laxity

Type 1: Treatment: Liposuction (classic liposuction or ultrasound assisted)

Type 2: Treatment: Sequential ellipse skin resection

Type 3: Treatment: Skin resection with surrounding areas liposuction. Contour results may vary among patients

3.1. Scar placement

There is a controversial issue about placing the scar in a more medial fashion than a posterior place.

It is obvious that a scar placed in the bicipital crease will be in a more natural and anatomical area. But the truth is that after a long postoperative time, the scar will expand or migrate because of the gravity.

A scar placed at the lowest point of the posterior axillary fold is better because it extends to axilla defects and maintains the arm reduction over time without migration (**Figure 15**).

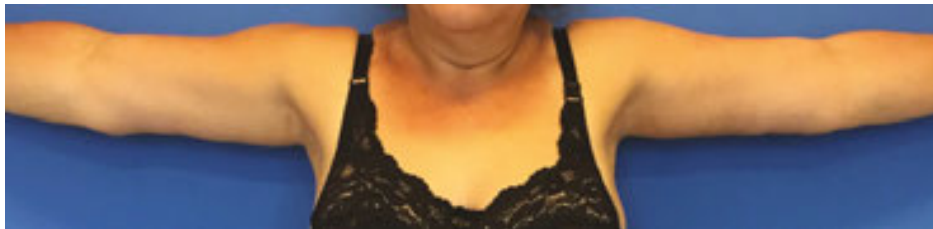


Figure 15. With arms open, scar is nonvisible.

At this time, you can combine arm lift with breast and upper back roll surgery and improve contour in the arms, lateral torso, back, and breast.

3.2. Markings

In standing position (**Figure 16**)

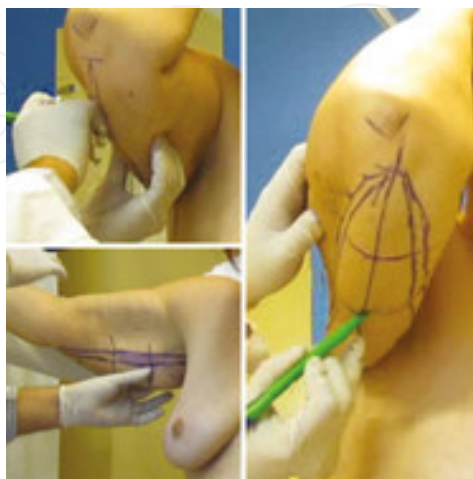

Figure 16. Pinch and hatch marks. Resection always is less than marked.

- Dynamic pinch at the posterior axillary fold towards axilla.
- This pinch will be about 1.5–2 cm less avoiding high tension in closure.
- Crossing axilla pinch will reclute lateral torso tissue.
- No marking Z-plasty is needed in the axilla.

3.3. Operative technique

- Patient positioned with arms open and movable to a position higher than the head (**Figure 16**).
- Partial Incision made from the elbow towards axilla maintaining superficial fascia.
- Sequential to the hatch marks to avoid over resection.
- Each hatch mark is accessed closure made from fascia and subdermal.
- Reaching axilla continue more subdermal to avoid lymph injury.
- Cross-axilla and resect until the last markings.
- Final closure made, skin glue.
- Drains under closure.

Tips: Arms are not collapsible, and compartmental syndrome could occur so less resection (**Figures 17–19**).

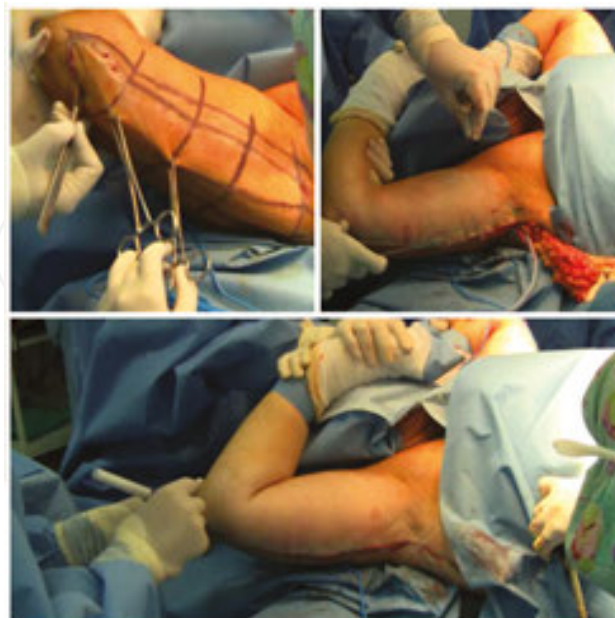


Figure 17. Upper left hatch marks are relevant in this surgery.

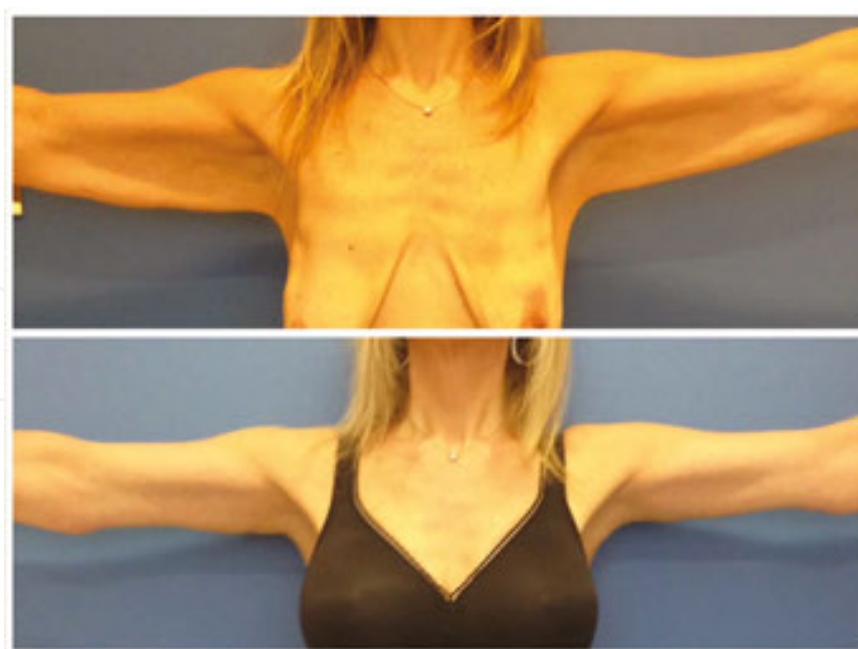

Figure 18. Deflated arm reaching axilla and lateral thorax. Pre- and post-op.

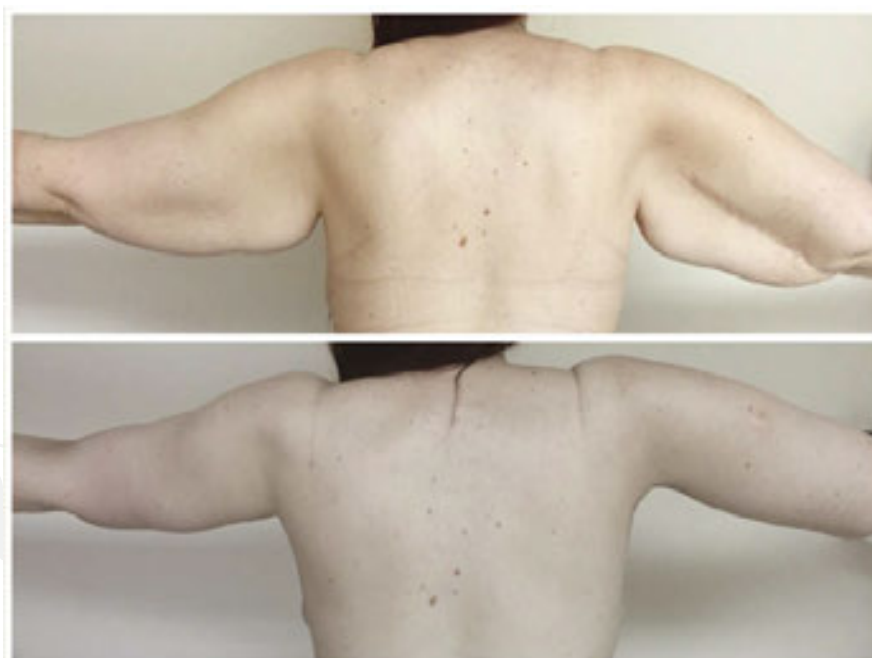

Figure 19. Aesthetic problem with adipose excess and scar due to trauma. Pre- and post-op.

Be gentle when moving, nerve compression or injury may happen.

Lateral torso resection shapes under the axilla and the lateral aspect of the breast and sometimes could lateralize the nipple, so if you are planning to combine surgery, be aware at this point.

3.4. Postoperative care

- Compression garments after surgery are mandatory from the hand to the axilla.
- The same day after surgery the surgeon must see patients hand for swelling and blood supply. Sometimes compression is too high and must free some pressure of the garment.
- Patient must elevate arms above the chest to avoid excessive swelling.
- Smooth movements and no lifting heavy objects.
- Drains kept a few days until 20 ml/day.
- Silicone sheets are applied 4–6 months.

Some male patients could benefit the chest wall with the lateral torso resection with marking extension and variation.

This selection is made in patients with (**Figure 20**).

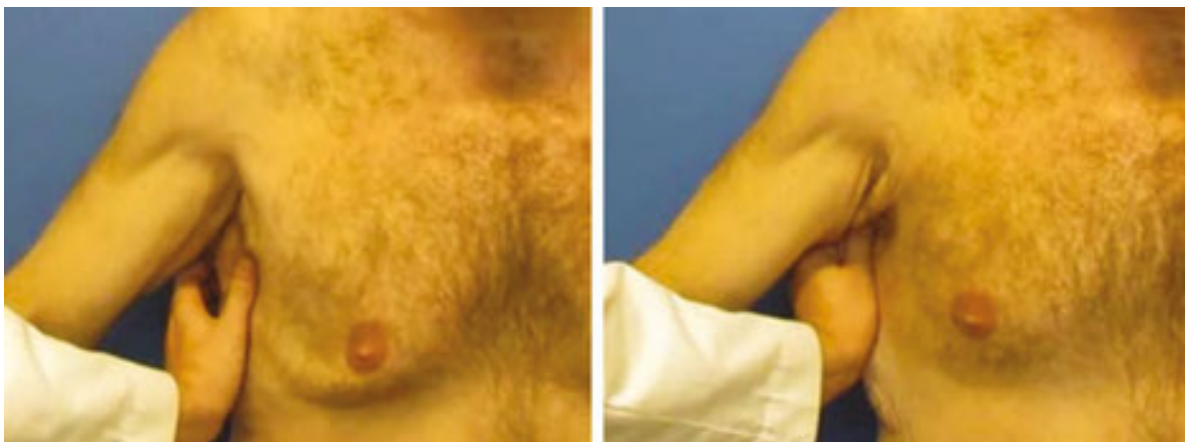


Figure 20. Notice the lateral traction improve NAC position.

- Deflation of the breast and position of NAC higher than inframammary fold.
- Lateral torso skin laxity.

Marking tips:

- Arm lift as described, crossing axilla and reaching lateral torso vertical dynamic high pinch is made.
- Evaluate NAC position as pinch.
- Sand clock shape is made with wider part at the NAC position.
- Extension will vary between patients (**Figure 21**).

With selected patients, we could perform upper body lift surgery resecting back rolls and leaving a final scar that cross from back to submammary fold.

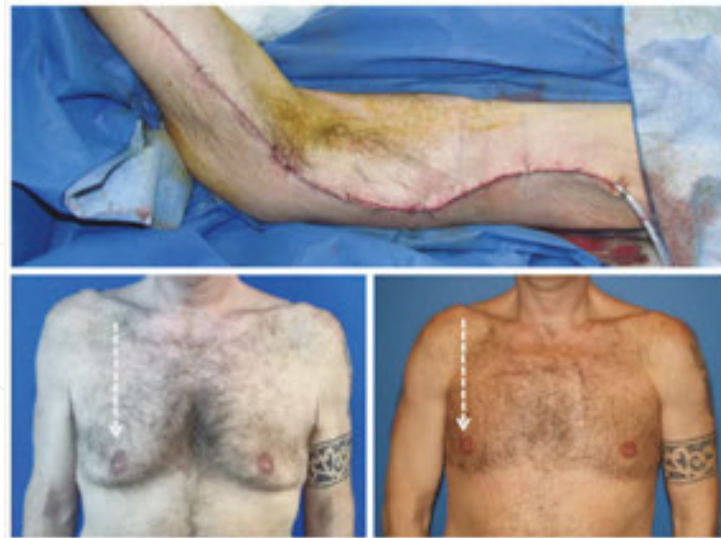

Figure 21. Long extension in lateral aspect. Pre- and post-op results.

This type of procedure requires changing position at the surgery table like the lower body lifts.

Markings:

- Standing position at the back elevate the excess in upward fashion.
- Dynamic pinch keeping the upper line just above the bra line.
- Continue to lateral hatch marks addressing submammary fold.

3.5. Operative technique

- Excise over the upper line and dissect downwards.
- Elevate the flap and tailor tack.
- Continue to the lateral aspect ending at the middle axillary line.
- Then rotate patient and continue in supine position.

Tips: Always keep the superficial fascia it will help you to anchor the flap in an upward position.

It is better to do lower body lift first as major skin tension body procedure it will tight some upper part excess leading to scar predictable positioning.

If breast or upper chest surgery will not be performed at this time, extend to the inframammary fold, dog ears at the lateral torso are too visible.

3.6. Results

See **Figures 22** and **23**.

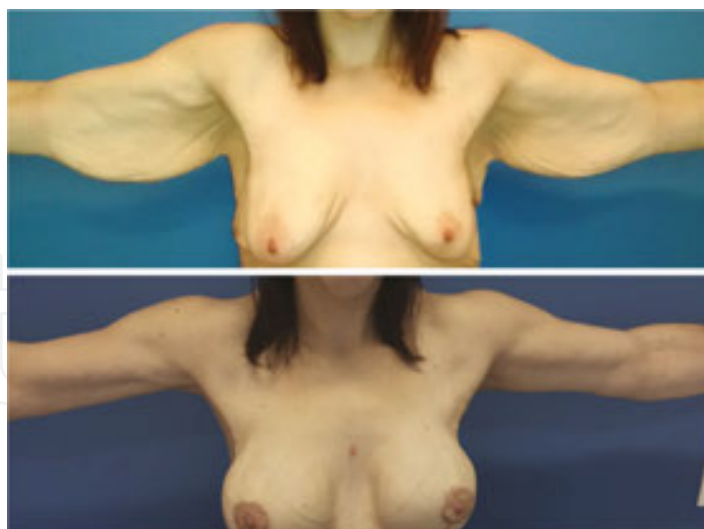


Figure 22. Brachioplasty, augmentation mastopexy, and back rolls surgery. Front view.

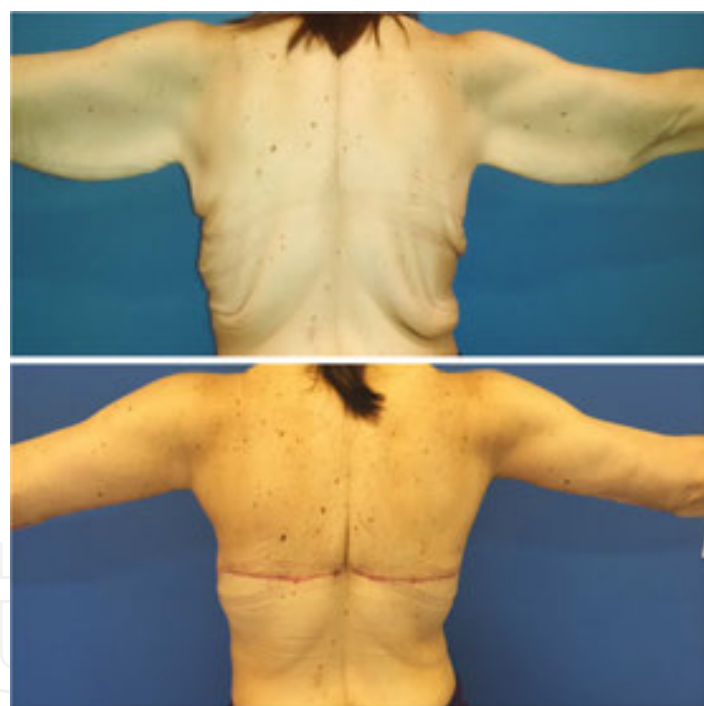

Figure 23. Back view.

4. Thigh lifting and reduction

The inner thighs are one of the areas that many plastic surgeons try to avoid mainly because the complication rate is higher than other surgical procedures [3].

Skin laxity and lipodystrophy vary according to patients so the thighs are divided into three zones (**Figure 24**):

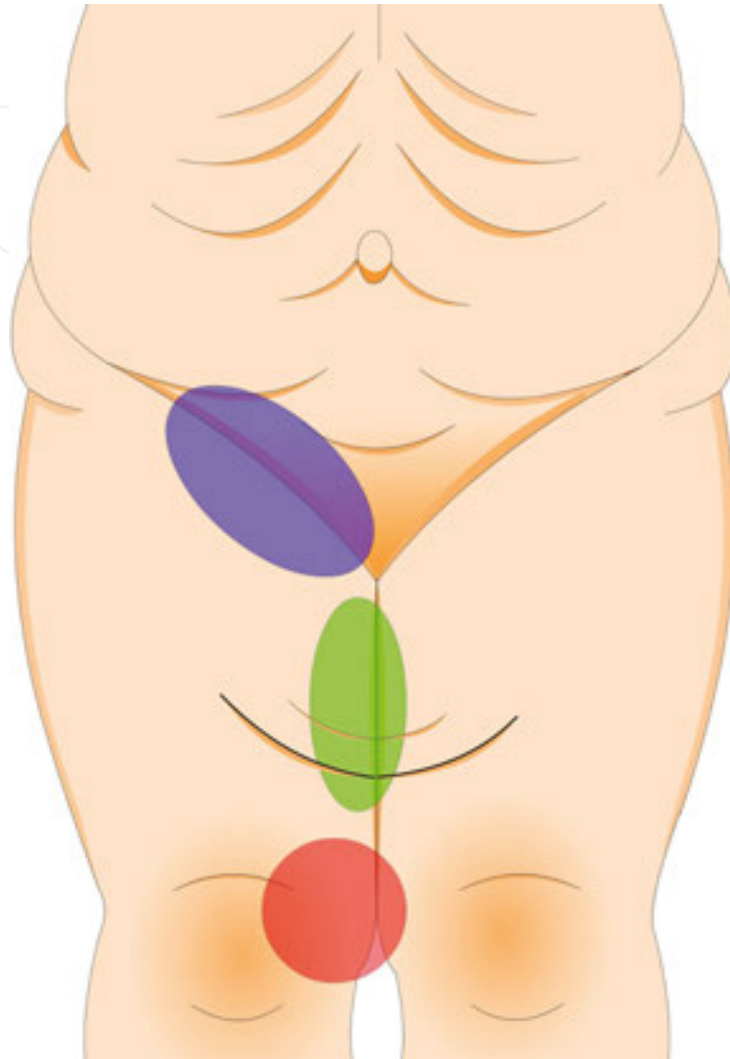


Figure 24. Thigh zones inguinal (purple), medial (green), upper knee (red).

- The inguinal zone.
- The medial inner thigh.
- The upper knee section.

The inner thigh as we describe it has two negative vectors due to gravity, skin laxity, and amount of fat in the area. The retaining skin ligaments in the inguinal and trochanter area are responsible for the vectors.

For reshaping the area, we propose to reinvert these critical vectors by anchoring the superficial fascia to the Colles ligament in the horizontal vector and resect the amount of skin and fat in the vertical one.

4.1. Planning inner thigh reduction

Which is the extension of the deformity?

- Pinch diagnosis in stand-up position.
- Elevation of the horizontal (subinguinal) vector.
- Careful examination of inner thigh and extension of vertical vector.
- Evaluate if deformity reaches or passes the knee.

4.2. Scar placement

- Inguinal scar should be placed in the inguinal crease.
- Vertical incision should not be too anterior or posterior.
- In stand-up position not visible scars.
- Evaluate patients with previous thigh incision.

4.3. Use of liposuction

- Only in areas that should not be excised (e.g., knee, lateral thigh).

4.4. Marking and tips

Pinch dynamic markings are used and marks are less than the original 1 or 1.5 cm to avoid over resection (**Figure 25**).

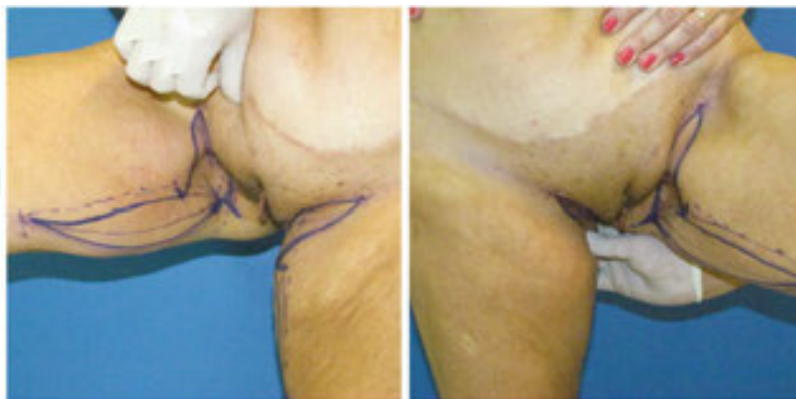

Figure 25. Marking and pinching the defect, the definitive marks are less than original pinch.

The amount of skin and fat excised in the horizontal excess often is less than what we can elevate.

Horizontal excess must be anchored in the Colles fascia just above 2 cm the inguinal crease so the mark in the inguinal region should be 2 cm less than the pinch.

This type of anchoring is strong and the horizontal flap could be suspended by the superficial fascia (**Figure 26**).

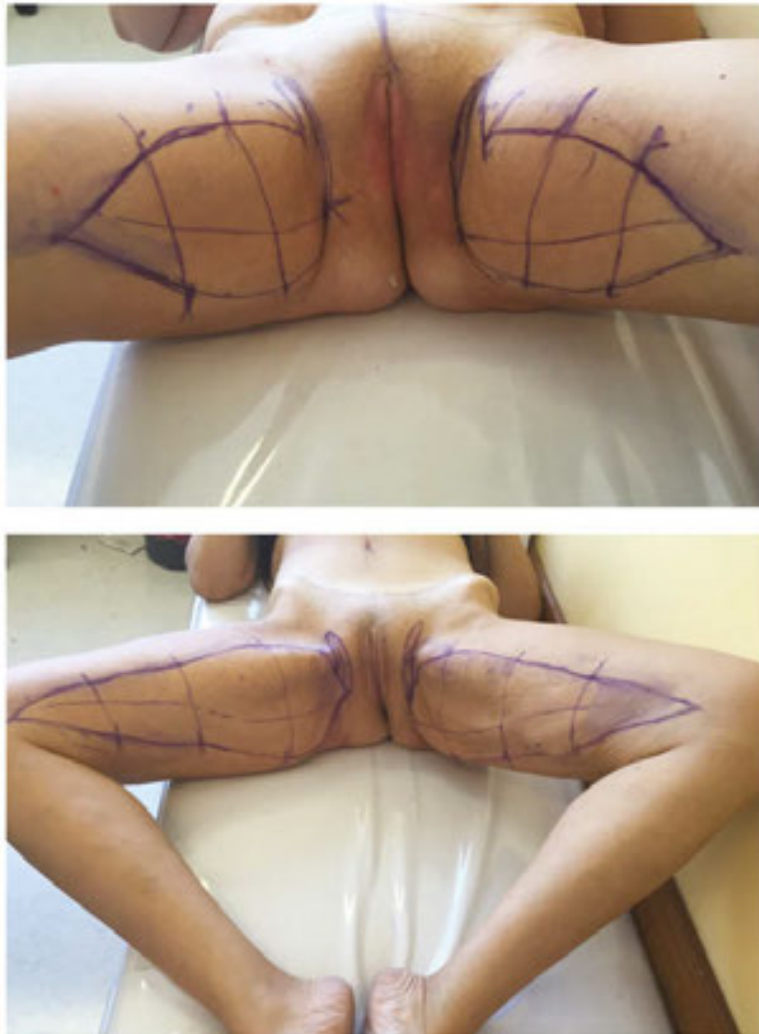


Figure 26. Different patients, different markings, and both improve contour.

4.4.1. Operative technique

- Patient positioned in frog-like position (**Figure 27**).
- Incision made from the distal marking towards inguinal maintaining superficial fascia.
- Sequential to the hatch marks to avoid over resection [4].
- Each hatch mark is accessed closure made from fascia and subdermal.
- Continue at the inguinal incision. Subfascial dissection.
- Do not over resect, suspension of the thigh has to be 2 cm or 3 above the crease to reach the Colles ligament, so marks should be 2 cm less than marked.

- Use polypropylene 0 for anchoring, in a “x” fashion to relax tension in superficial fascia.
- Final closure made, skin glue.
- Drains under closure.

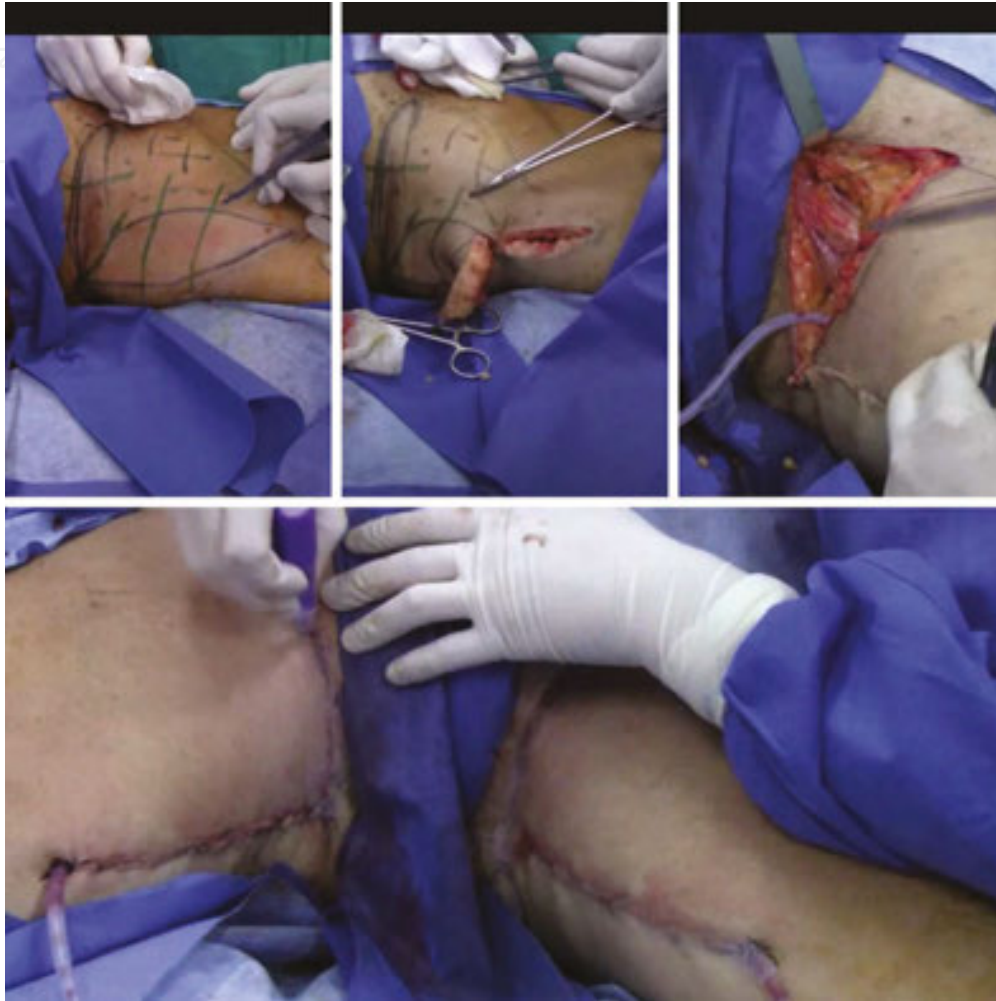

Figure 27. Thigh surgery. Upper right anchoring subfascial tissue to Colles ligament.

4.4.2. Post-op treatment

- Use of compression garments.
- Early deambulation.
- Leave silicone drains until 25 cc/day.

4.4.3. Pre-/post-op Photographs

See **Figures 28 and 29.**

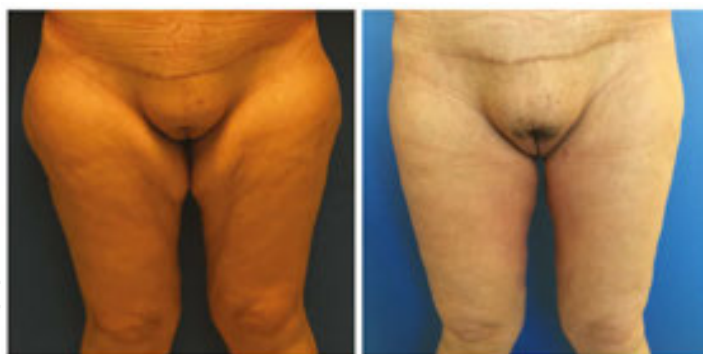

Figure 28. Deformity at inguinal and medial zone. Pre- and post-op.

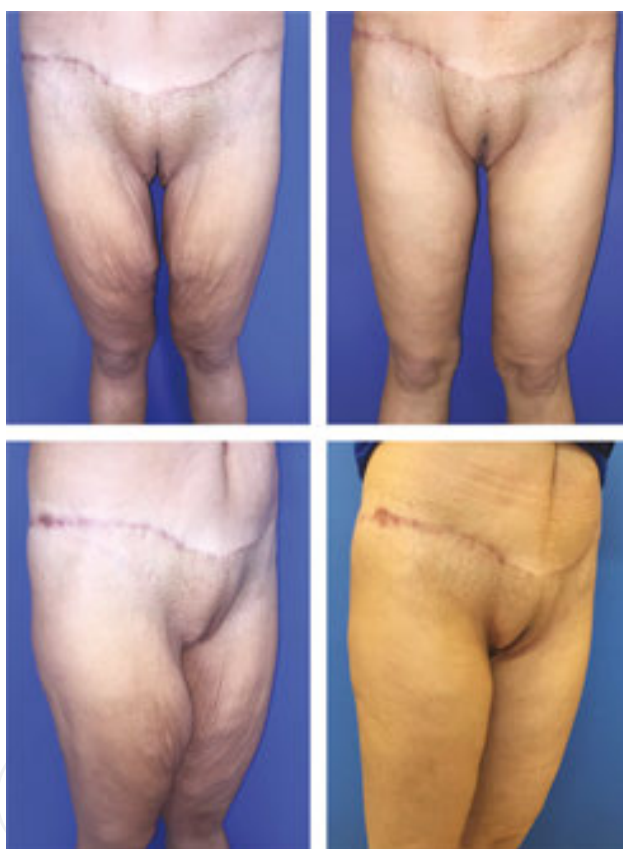


Figure 29. Some patients reach the upper knee so extension of the vertical extension is applied. Pre- and post-op.

5. Discussion

Many techniques have been described through the past century to achieve good contour and aesthetic results. But some of this new postbariatric population with weight loss have contour deformities that never have been shown in past century consultation.

New surgical approach as body lifts, extensive brachioplasty, and thighplasty should be consider as a gold standard for this kind of patients

6. Conclusions

With a comprehensive diagnosis, patient classification, dynamic marking, and postoperative patient management, body contouring has evolved from traditional plastic surgery techniques to a multiple vector correction.

It provides a good contour; skin tension and results are consistent over time, but should consider to:

- Be conservative and do not over resect.
- Plan and mark since these are critical for the surgery.
- Take care of patients' postoperative management, watch out for complications.

Author details

Marcelo A. Cuadrado*, Gabriel Moina and Daniel Moina

*Address all correspondence to: drcuadrado@gmail.com

Hospital Británico de Buenos Aires, Centro de Rinología y Cirugía plástica Dr. Moina, Buenos Aires, Argentina

References

- [1] Aly A, Cram A. editors. Body Contouring After Massive Weight Loss. Missouri: QMP Publishing; 2006. 386 p. doi:9781576262115
- [2] Ted Lockwood. Superficial fascial system (SFS) of the trunk and extremities: A new concept. *Plast Reconstr Surg.* 1991;87(6):1009–1018.
- [3] Grazer FM. Body contouring. Introduction. *Clin Plast Surg.* 1996;23(4):511–528.
- [4] Cram A, Aly A. Thigh reduction in the massive weight loss patient. *Clin Plast Surg.* 2008;35(1):165–172.