

We are IntechOpen, the world's leading publisher of Open Access books Built by scientists, for scientists

6,900

Open access books available

186,000

International authors and editors

200M

Downloads

Our authors are among the

154

Countries delivered to

TOP 1%

most cited scientists

12.2%

Contributors from top 500 universities



WEB OF SCIENCE™

Selection of our books indexed in the Book Citation Index
in Web of Science™ Core Collection (BKCI)

Interested in publishing with us?
Contact book.department@intechopen.com

Numbers displayed above are based on latest data collected.
For more information visit www.intechopen.com



Cardiomyopathies in Animals

Kazumasu Sasaki, Tatsushi Mutoh, Kinji Shirota and
Ryuta Kawashima

Additional information is available at the end of the chapter

<http://dx.doi.org/10.5772/65060>

Abstract

A wide variety of animal models in cardiomyopathy have been established for the discovery of pathophysiological mechanisms, diagnosis, and treatment of human myocardial disease. Experimentally, several species including rodents, rabbit, canine, pig, and sheep have been involved in the fundamental research in medical field. However, knowledge about naturally occurring myocardial disease in animals is limited in the veterinary medicine. Among small and large animals that develop myocardial disease, to the best of authors' knowledge, naturally occurring cardiomyopathy in canine and feline is commonly encountered in veterinary clinical setting. Their pathophysiology is not fully described; specific pathophysiology is documented in both species, which resembles those of humans. These conditions are hypertrophic cardiomyopathy (HCM) in feline and dilated cardiomyopathy (DCM) in canine. Each has distinct etiology and pathophysiology. In order to translate new findings from naturally occurring cardiomyopathies in small and large animals into medical applications, knowledge gained through animals with cardiomyopathies becomes a necessary approach. The purpose of this chapter is to introduce the overview of findings on small and large animals with naturally occurring cardiomyopathies already investigated.

Keywords: animal model, canine dilated cardiomyopathy, feline hypertrophic cardiomyopathy, naturally occurring cardiomyopathies

1. Introduction

Several animal models in cardiomyopathy have been established for the discovery of pathophysiological mechanisms, diagnosis, and treatment of human myocardial disease. Experimentally, rodents, rabbit, canine, pig, sheep, and other species have been involved in the

fundamental research in medical field [1–7]. Although anatomic and biochemical differences between species are critical, each experimentally induced animal model plays an important role for translation to clinical practice in human. In addition to experimentally induced animal models, naturally occurring cardiomyopathies in small and large animals offer an excellent opportunity to evaluate novel therapies for those of human. However, knowledge about naturally occurring myocardial disease in animals is limited in the veterinary medicine. Among animals that develop myocardial disease, to the best of authors' knowledge, cardiomyopathy in canine and feline is commonly encountered in veterinary clinical setting [8–12]. Their pathophysiology is not always clearly described yet; however, specific features are documented in both canine and feline. Briefly, naturally occurring myocardial disease is one of the most common heart diseases in canine and feline. A number of remarkable similarities have been reported between these animals and humans [13, 14]. Several causes concerning genetic, metabolic, inflammatory, nutritional, infectious, and drug-induced myocardial disease have been reported as canine and feline idiopathic or secondary myocardial disease [15, 16]. Generally speaking, treatment strategy of these naturally occurring diseases in veterinary clinical setting is based on those of humans. Therefore, this chapter provides pathophysiological aspects of these diseases.

Dilated cardiomyopathy (DCM) was first reported in 1970, as congestive heart failure (CHF). It is characterized by chamber dilation and myocardial systolic and diastolic dysfunction. DCM appears to be common in canine, which has been suspected to be inherited defects and mainly affects the certain large- to giant-sized pure-bred such as English Cocker Spaniels, Doberman Pinschers, Irish Wolfhounds, Newfoundlands, Boxers, German Short-haired Pointers, Portuguese Water Dog, Airedale Terriers, St. Bernards, Standard Poodles, Scottish Deerhounds, Afghan Hounds, and other breeds [8, 15–17]. Myocardial dysfunction results from ischemia, tachycardia, and trauma in canine myocardial disease. An underlying disease associated with neoplasia, renal disease, immune-mediated hemolytic anemia, acute pancreatitis, disseminated intravascular coagulopathy (DIC), myocardial infarction, mitral insufficiency, and other disease results in ischemic myocardial disease. Atrioventricular nodal-reciprocating tachycardias can lead to the tachycardia-induced cardiomyopathy in several breeds. However, hypertrophic cardiomyopathy (HCM) occurs less often in canine [15–17].

On the other hand, HCM is being the most commonly diagnosed cardiomyopathy in feline [10, 18, 19]. It is prevalent in certain populations. The disease is known to be inherited in some breeds, most notably The Domestic Shorthair, Turkish Van, Maine Coon, Persian, Ragdoll, Sphynx, Scottish Fold Cats, Chartreux, British Shorthair, Norwegian Forest Cat, Persian, and other breeds [14–16, 18]. The pathogenic mechanisms responsible for the development of HCM remain unclear; however, causal genetic mutations in genes encoding the sarcomere protein myosin-binding protein C (MYBPC3) have been identified in specific breeds such as Maine Coons and Ragdolls [14, 19–21].

Limited information exists on naturally occurring cardiomyopathies in large animals such as swine, cattle, and other species. Generally, these large animals are classified as farm animals and treated under group control. Compared with small animal veterinary practice,

which mainly treats canine and feline, large animals are not potentially therapeutic objectives. From this circumstance, few opportunities exist for veterinarian to treat the disease. Even though numerous anatomic and biochemical differences exist, naturally occurring disease in large animal species can provide significant advantages for understanding those human conditions.

2. Canine DCM

2.1. Etiology and pathogenesis

The canine DCM can be divided into two categories: idiopathic and secondary (**Table 1**). The exact underlying molecular and biochemical mechanisms for canine DCM are generally not established in all cases. However, the etiology concerning genetic, nutritional, infectious, metabolic, inflammatory, drug- or toxin-induced myocardial hypokinesis have been proposed in canine DCM [17]. In idiopathic cases, genetic basis is thought to exist especially in certain breeds with high prevalence or familial occurrence of disease [15–17]. Large and giant breeds such as Great Danes, Scottish Deerhounds, Boxers, St. Bernards, Newfoundlands, Dalmatians, Doberman Pinschers, Irish Wolfhounds, and other breeds have been documented [8, 15, 16]. Newfoundlands, Irish Wolfhounds, Boxers, and Doberman Pinschers appear to have an autosomal dominant mode of transmission pattern of inheritance [8, 22, 23]. An autosomal recessive transmission has been documented in the inherited form of DCM in juvenile Portuguese Water Dogs [24, 25]. The disease is rapidly progressive and fatal in puppies. In some German Short-haired Pointer littermates, DCM appears to be an X-linked disorder caused by mutations in the Duchenne muscular dystrophy (DMD) gene [8, 26]. This gene codes for dystrophin, which is thought to strengthen muscle fiber membranes.

Myocardial function can impair result from a variety of causes including infections, inflammation, nutritional deficiencies, metabolic abnormalities, certain drugs, and other factors. These factors can lead to canine secondary myocardial disease. The antineoplastic drug doxorubicin and ethyl alcohol can cause severe myocardial damage and death. Plant toxins (e.g., *Taxus*, foxglove, black locust, buttercup, gossypol), cocaine, cobalt, catecholamines, and anesthetic drug can also affect the myocardial function [8, 15–17]. Carnitine and taurine deficiencies have been described in canine DCM [8]. L-Carnitine deficiency is not a primary cause of canine DCM; however, in Boxers, Doberman Pinschers, American Cocker Spaniels, Irish Wolfhounds, Newfoundlands, and Great Danes, low myocardial L-carnitine concentration has been reported [15]. L-Carnitine is an essential component of the long-chain fatty acids, which is an important energy-producing substrate of the myocardium. Taurine is known to regulate calcium influx across membranes in heart muscle. However, most cases with canine DCM are not taurine deficient; a reversible canine DCM associated with low plasma taurine concentration was reported in Cocker Spaniels [27]. Low plasma taurine level has also been described in Golden Retrievers, Labrador Retrievers, St. Bernards, Dalmatians, and other breeds with DCM.

Etiology/pathogenesis	Breed	References
Idiopathic DCM		
<i>Genetic disorder</i>		
Dystrophin	German Short-haired Pointers	Schatzberg et al. [47]
Desmin	Doberman Pinschers	Stabej et al. [48]
Titin-cup	Irish Wolfhounds	Philipp et al. [49]
α -actinin	Doberman Pinschers	O'Sullivan et al. [50]
Striatin	Boxers	Cattanach et al. [51]
Secondary DCM		
<i>Nutritional disorder</i>		
L-Carnitine	Doberman Pinschers, Boxers	Keene et al. [52]
	American Cocker Spaniels	Kittleson et al. [53]
<i>Metabolic disorder</i>		
Thyroid hormone	Great Dane	Phillips and Harkin [54]
	Alaskan Malamute	Flood and Hoover [55]
	Doberman Pinschers	Beier et al. [56]
<i>Immunological disorder</i>		
Anti-mitochondrial antibodies	English Cocker Spaniel	Day [57]
Canine adenovirus type 1	Crossed breed	Maxson et al. [58]

Table 1. Possible factors of naturally occurring canine DCM.

2.2. Pathophysiology

Dilation of all cardiac chambers is typical in canine DCM [8, 15, 16, 28]. Decreased ventricular contractility is the major functional defect. Compensatory mechanisms become activated as progressive cardiac chamber dilation and remodeling develop as cardiac output worsens. Development of higher end-diastolic pressure, venous congestion, and congestive heart failure occurs in response to increased diastolic stiffness. Valve insufficiency also occurs because of cardiac enlargement and papillary muscle dysfunction. Arterial fibrillation (AF) is typical in canine DCM [15].

2.3. Histologic description

Gross anatomically, canine idiopathic DCM reveals marked dilation of all four cardiac chambers and/or predominantly dilation of the left chambers [8, 29–31]. Generally, myocardial hypertrophy is evident in the lesion. Distinct two histological forms of canine DCM have been reported: the fatty infiltration-degenerative type observed in specific breeds such as Boxers and Doberman Pinschers, and the attenuated wavy fiber type reported in medium-, large-, and giant-sized breed (**Table 2**). Histological forms such as vacuolar degeneration of myofib-

ers, atrophic myofibers, lipid deposits, and fatty infiltration replacing myofibers are evident for the fatty infiltration-degenerative type. On the other hand, the attenuated wavy fiber type seems to be a major histological form of canine DCM. The myofibers are stretched and thinner than normal with wavy appearance. The morphological alterations including myofiber atrophy, impairing wavy appearance to the fibers, and diffuse infiltration of subendocardial fibrosis were reported [8]. These lesions were most abundant in the lateral wall of the left ventricle (LV) [32, 33].

References	Breed
Fatty infiltration-degenerative type	
Calvert et al. [59]	Doberman Pinschers
Harpster et al. [34]	Boxers
Hazlet et al. [60]	Doberman Pinschers
Tidholm and Jönsson [61]	Newfoundland
Calvert et al. [62]	Doberman Pinschers
Dambach et al. [25]	Portuguese Water Dogs
Everett et al. [63]	Doberman Pinschers
Vollmar et al. [64]	Doberman Pinschers
Lobo et al. [65]	Estrela Mountain Dogs
Attenuated wavy fiber type	
Tilley and Liu [66]	Great Dane, Doberman Pinschers, Irish Wolfhound
Sandusky et al. [67]	Afghan Hound, Doberman Pinschers, Great Dane
Tidholm et al. [33]	Large- and medium-size breeds
Dambach et al. [25]	Portuguese Water Dogs
Tidholm et al. [32]	Newfoundlands
Alroy et al. [68]	Portuguese Water Dogs
Vollmar et al. [69]	Doberman Pinschers
Sleeper et al. [24]	Portuguese Water Dogs

Table 2. Two distinct histological forms of canine idiopathic DCM.

2.4. Survival and prognosis

Prognosis in canine DCM varies from weeks to several years. Sudden death may occur before the development of disease. Survival rate of Doberman Pinschers with fatty infiltration-degenerative type of DCM is shorter than attenuated wavy fiber type of those with DCM [8].

3. Cardiomyopathy in Boxers

Inherited cardiomyopathy in Boxers has similar features to arrhythmogenic right ventricular cardiomyopathy (ARVC) [15, 23]. Three forms were originally described by Harpster in 1983

including the cases with asymptomatic arrhythmias, ventricular tachyarrhythmias, cardiac arrhythmias, and congestive heart failure [34]. The disease appears to have an autosomal dominant inherited pattern. The Boxers with cardiac arrhythmias and congestive heart failure is considered to be a form of canine DCM, which is characterized by left and right ventricular myocardial systolic dysfunction [15, 23]. Histologic form of the disease includes myofibers atrophy, fibrosis, and fatty infiltration in the right ventricular wall. Deletion in the desmosomal striatin gene is associated with the disease developed in Boxer with ARVC [23]. The prognosis is varied in the forms of disease but survival is less than 6 months in case of CHF. Sudden death is common in asymptomatic cases.

4. Feline HCM

4.1. Etiology and pathogenesis

Recent report suggested that feline cardiomyopathy may be classified as HCM, hypertrophic obstructive cardiomyopathy (HOCM), restrictive cardiomyopathy (RCM), dilated cardiomyopathy, arrhythmogenic right ventricular cardiomyopathy, and unclassified cardiomyopathy (UCM) based on echocardiography and other factors [12]. However, diagnosis is quite challenging because of complexity of the disease. Feline idiopathic HCM is the most commonly diagnosed heterogeneous disease, which is transmitted in autosomal dominant trait in some specific breeds [15]. The disease is more frequent in male than in female. Genetic mutations in gene encoding in sarcomere protein myosin-binding protein C (MYBPC3) is associated with the development of disease in Manine Coon Cats (A31P mutation) and Ragdoll Cats (R820W mutation) [18]. Other breeds including Domestic Short Hair, Norwegian Forest Cats, Sphinx, Bengals, Chartreux, British Shorthairs, European, Scottish Folds, Cornish Rex, and Persian breeds are also high in disease prevalence but causative mutations associated with disease have yet to be documented [11, 15, 16]. In addition to specific gene mutation, feline myocardial hypertrophy results from possible causes such as an excessive production of catecholamines, myocardial ischemia, fibrosis, primary collagen abnormality, and abnormalities in myocardial calcium-handling process [15].

4.2. Pathophysiology

The disease is characterized by papillary muscle and LV hypertrophy, systolic anterior motion (SAM) of the mitral valve, diastolic dysfunction, end-systolic cavity obliteration, and enlargement of the left atrium [14, 35]. Abnormal sarcomere function results from myocyte hypertrophy and increased collagen synthesis. Asymmetric or symmetric LV free-wall concentric hypertrophy with interventricular septum is the characteristic form of the disease [36]. Some have limited abnormality in the basal septum and/or papillary muscles. These different patterns of hypertrophy may be caused by different phenotypic expression between different breeds.

Myocardial hypertrophy and reduced ventricular distensibility result in increased diastolic pressure and LV filling accompanying increased left arterial (LA) and pulmonary venous

pressure. Secondary right-sided congenital heart failure (CHF) may occur in response to prolonged pulmonary vasoconstriction and increased pulmonary arterial pressure. LV outflow obstruction accompanying ejection murmur results from LV papillary muscle hypertrophy. Several factors contribute to myocardial ischemia, which leads to fibrosis, arrhythmias, and other complications. CHF, arterial thromboembolism (ATE), and sudden cardiac death are common clinical manifestation in end-stage feline HCM [15].

4.3. Histologic description

Gross anatomy is characterized by moderate to severe papillary muscle and LV concentric hypertrophy (**Figure 1**). Histologic findings based on hematoxylin and eosin (HE) staining and other specific markers revealed several abnormalities including multifocal myocardial interstitial fibrosis, myofiber disarray, diffuse myocyte hypertrophy with or without scattered individual cell necrosis, and arteriosclerosis in papillary muscles in the LV wall, interventricular septum, and intramural coronary artery [10, 37]. Recent evidence showed remodeling of the myofibrils and interfibrillar mitochondria, sarcolemmal remodeling with depletion of the subsarcolemmal mitochondria, changes of Z-disc morphology, myofibrillar degeneration, and endomysial fibrosis based on electron microscopic examination [10].

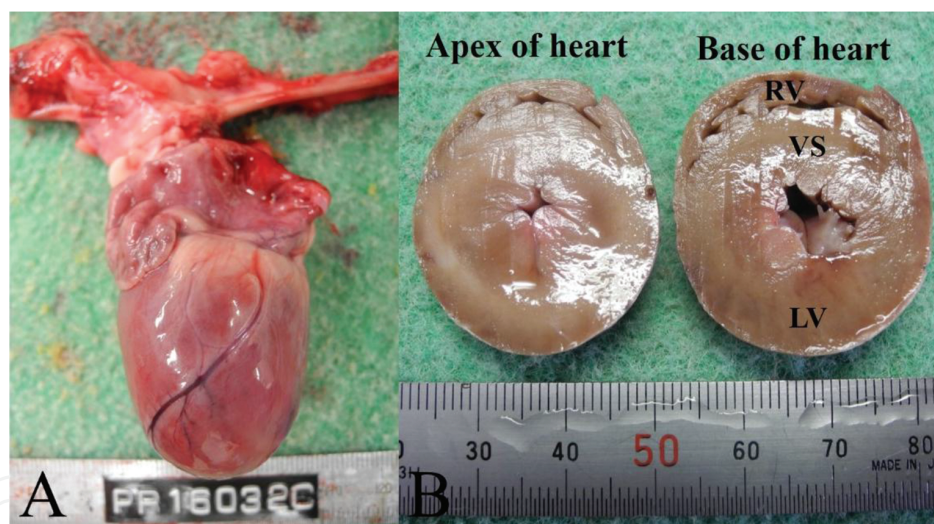


Figure 1. Gross morphologic features of heart from feline with HCM. (A) Overview of the heart from feline HCM. (B) Hypertrophy of ventricular septum (VS) in relation to left ventricular (LV) free wall. RV = right ventricle. Images courtesy of Prof. Kinji Shirota.

4.4. Survival and prognosis

Some prognostic factors such as heart rate and LA size are associated with survival time [12]. The prognosis is worse in case with ATE and/or CHF. Restrictive cardiomyopathy may be a consequence of the end stage of myocardial failure and infarction caused by HCM. Several factors cause a secondary RCM including tumor and infectious disease that were documented [15]. The prognosis is poor for feline with RCM accompanied by heart failure.

5. Other species

5.1. Swine

Experimentally induced porcine model of cardiomyopathy is widely used for medical applications [2, 38]. On the other hand, we have limited knowledge about naturally occurring swine cardiomyopathies. To date, naturally occurring porcine HCM and DCM have been described [39–41]. In addition to experimentally induced animal models, characteristics of naturally occurring affected pigs would be useful for translational research.

Several findings from swine HCM resemble those of humans with HCM. Higher incidence of specific breeds such as Landrace, Yorkshire, and Duroc were reported [39]. Pathological findings including increased number of mitochondria contained in the LV, increased amount of collagen matrix and abnormality in intramural coronary arteries, alternation of endogenous antioxidant enzymes, and decreased Ca^{2+} -ATPase activity in the LV are identical to those found in humans [39]. Histological abnormalities in swine HCM including abnormal intramural coronary arteries, subendocardial fibrosis in the ventricular septum, myocardial fibrosis, abnormalities in matrix connective tissue in myocardium, increased perimysial coil, and weave fibers of matrix connective tissue space between myocytes were documented [41, 42].

Recently, the case of spontaneous DCM was recognized in Yorkshire-Landrace crossbred [40]. The postmortem investigation after sudden death of this case revealed marked dilated ventricles and thinned ventricular walls and interventricular septum. Characteristics of gross anatomy and histological findings including multifocal myofiber attenuation and loss of myofiber cross striations supported the diagnosis of swine DCM. Cardiac lesions observed in the reported case were consistent with DCM as recognized in other species.

5.2. Cattle

Few reports on cardiomyopathies in cattle were described [43, 44]. Hereditary cardiomyopathy in cattle has been described in some breeds including Japanese Black Calves, Holstein-Friesian-Cattle, Simmental/Red and White Holstein crossbreds, and Polled Hereford Calves [44, 45]. Recently, evidence suggested that specific breeds appear to have an autosomal dominant mode of transmission pattern of inheritance [45]. However, limited information exists about pathophysiological features compared with those of canine and feline. Affected cattle had multifocal myocardial degeneration and necrosis under histological investigation [46].

6. Conclusion

Naturally occurring inherited canine DCM and feline HCM are well-recognized myocardial disease in veterinary clinical setting. Although anatomic and biochemical differences between species are critical, reported findings resemble those of human disease condition. Little is known about naturally occurring cardiomyopathies in large animals but evidence suggested that they also develop spontaneous myocardial disease, which resembles those of other species

including human. Given the similarities of cardiomyopathies in both human and other species, the knowledge of naturally occurring myocardial disease in small and large animals may help expand the understanding of disease pathophysiology.

Acknowledgements

The authors gratefully acknowledge the financial support: Sendai Animal Care and Research Center Foundation of Japan.

Author details

Kazumasu Sasaki^{1,2*}, Tatsushi Mutoh^{3,4}, Kinji Shiota⁵ and Ryuta Kawashima⁶

*Address all correspondence to: kazumasu.sasaki.d8@tohoku.ac.jp

1 Department of Functional Brain Imaging and Preclinical Evaluation, Institute of Development, Aging and Cancer, Tohoku University, Sendai, Japan

2 Sendai Animal Care and Research Center, Sendai, Japan

3 Department of Nuclear Medicine and Radiology, Institute of Development, Aging and Cancer, Tohoku University, Sendai, Japan

4 Department of Surgical Neurology, Research Institute for Brain and Blood Vessels-AKITA, Akita, Japan

5 Department of Veterinary Pathology, School of Veterinary Medicine, Azabu University, Kanagawa, Japan

6 Department of Functional Brain Imaging, Institute of Development, Aging and Cancer, Tohoku University, Sendai, Japan

References

- [1] Sirasaka T, Miyagawa S, Fukushima S, et al. Skeletal myoblast cell sheet implantation ameliorates both systolic and diastolic cardiac performance in canine dilated cardiomyopathy model. *Transplantation*. 2016;100:295–302.

- [2] Lacroix D, Gluais P, Marquié C, et al. Repolarization abnormalities and their arrhythmogenic consequences in porcine tachycardia-induced cardiomyopathy. *Cardiovasc Res.* 2002;54:42–50.
- [3] Mittal A, Sharma R, Prasad R, et al. Role of cardiac TBX20 in dilated cardiomyopathy. *Mol Cell Biochem.* 2016;414:129–36.
- [4] Wilder T, Ryba DM, Wieczorek DF, et al. N-acetylcysteine *reverses* diastolic dysfunction and hypertrophy in familial hypertrophic cardiomyopathy. *Am J Physiol Heart Circ Physiol.* 2015;309:1720–1730.
- [5] Frey N, Franz WM, Gloeckner K, et al. Transgenic rat hearts expressing a human cardiac troponin T deletion reveal diastolic dysfunction and ventricular arrhythmias. *Cardiovascular Res.* 2000;47:254–264.
- [6] Sanbe A, James J, Tuzcu V, et al. Transgenic rabbit model for human troponin I-based hypertrophic cardiomyopathy. *Circulation.* 2005;111:2330–2338.
- [7] Geens JH, Trenson S, Rega FR, et al. Ovine models for chronic heart failure. *Int J Artif Organs.* 2009;32:496–506.
- [8] Tidholm A, Jönsson L. Histologic characterization of canine dilated cardiomyopathy *Vet Pathol.* 2005;42:1–8.
- [9] Martin MW, Stafford Johnson MJ, Strehlau G, et al. Canine *dilated* cardiomyopathy: a retrospective study of prognostic findings in 367 clinical cases. *J Small Anim Pract.* 2010;51:428–436.
- [10] Christiansen LB, Prats C, Hyttel P, Koch J. Ultrastructural myocardial changes in seven cats with spontaneous hypertrophic cardiomyopathy. *J Vet Cardiol.* 2015;17: 220–232.
- [11] Maron BJ, Fox PR. Hypertrophic cardiomyopathy in man and cats. *J Vet Cardiol.* 2015;17:6–9.
- [12] Ferasin L. Feline myocardial disease 2: *diagnosis*, prognosis and clinical management. *J Feline Med Surg.* 2009;11:183–194.
- [13] Simpson S, Edwards J, Ferguson-Mignan TF, et al. Genetics of human and canine dilated cardiomyopathy. *Int J Genomics.* 2015;2015:204823.
- [14] Kittleson MD, Meurs KM, Harris SP. The genetic basis of hypertrophic cardiomyopathy in cats and humans. *J Vet Cardiol.* 2015;17:53–73.
- [15] Nelson RW, Couto CG., editors. Small animal internal medicine. St. Louis, MO: Elsevier Mosby; 2014.
- [16] Tilley LP, Smith, Jr FWK, Oyama MA, Sleeper MM. Manual of canine and feline cardiology. St. Louis, MO: Saunders Elsevier; 2008.

- [17] Tidholm A, Häggström J, Borgarelli M, et al. Canine idiopathic dilated cardiomyopathy. Part I: aetiology, clinical characteristics, epidemiology and pathology. *Vet J*. 2001;162:92–107.
- [18] Longeri M, Ferrari P, Knafelz P, et al. Myosin-binding protein C DNA variants in domestic cats (A31P, A74T, R820W) and their association with hypertrophic cardiomyopathy. *J Vet Intern Med*. 2013;27:275–285.
- [19] Häggström J, Luis Fuentes V, Wess G. Screening for hypertrophic cardiomyopathy in cats. *J Vet Cardiol*. 2015;17:134–149.
- [20] Meurs KM, Norgard MM, Ederer MM, et al. A substitution mutation in the myosin binding protein C gene in ragdoll hypertrophic cardiomyopathy. *Genomics*. 2007;90:261–264.
- [21] Meurs KM, Sanchez X, David RM, et al. A cardiac myosin binding protein C mutation in the Maine Coon cat with familial hypertrophic cardiomyopathy. *Hum Mol Genet*. 2005;14:3587–3593.
- [22] Meurs KM, Fox PR, Norgard M, et al. A prospective genetic evaluation of familial dilated cardiomyopathy in the Doberman Pinscher. *J Vet Intern Med*. 2007;21:1016–1020.
- [23] Meurs KM, Stern JA, Sisson DD, et al. Association of dilated cardiomyopathy with the striatin mutation genotype in boxer dogs. *J Vet Intern Med*. 2013;27:1437–1440.
- [24] Sleeper MM, Henthorn PS, Vijayasathy C, et al. Dilated cardiomyopathy in juvenile Portuguese Water Dogs. *J Vet Intern Med*. 2002;16:52–62.
- [25] Dambach DM, Lannon A, Sleeper MM, et al. Familial dilated cardiomyopathy of young Portuguese water dogs. *J Vet Intern Med*. 1999;13:65–71.
- [26] Towbin JA, Hejtmancik JF, Brink P, et al. X-linked dilated cardiomyopathy. Molecular genetic evidence of linkage to the Duchenne muscular dystrophy (dystrophin) gene at the Xp21 locus. *Circulation*. 1993;87:1854–1865.
- [27] Gavaghan BJ, Kittleson MD. Dilated cardiomyopathy in an American cocker spaniel with taurine deficiency. *Aust Vet J*. 1997;75:862–868.
- [28] Borgarelli M, Tarducci A, Tidholm A, et al. Canine idiopathic dilated cardiomyopathy. Part II: pathophysiology and therapy. *Vet J*. 2001;162:182–195.
- [29] Liu SK, Roberts WC, Maron BJ. Comparison of *morphologic* findings in spontaneously occurring hypertrophic cardiomyopathy in humans, cats and dogs. *Am J Cardiol*. 1993;72:944–951.
- [30] Legge CH, López A, Hanna P, et al. Histological characterization of dilated cardiomyopathy in the juvenile toy Manchester terrier. *Vet Pathol*. 2013;50:1043–1052.

- [31] Janus I, Noszczyk-Nowak A, Nowak M, et al. A comparison of the histopathologic pattern of the left atrium in canine dilated cardiomyopathy and chronic mitral valve disease. *BMC Vet Res.* 2016;12:3.
- [32] Tidholm A, Häggström J, Jönsson L. Detection of attenuated wavy fibers in the myocardium of Newfoundlands without clinical or echocardiographic evidence of heart disease. *Am J Vet Res.* 2000;61:238–241.
- [33] Tidholm A, Häggström J, Jönsson L. Prevalence of attenuated wavy fibers in myocardium of dogs with dilated cardiomyopathy. *J Am Vet Med Assoc.* 1998;212:1732–1734.
- [34] Harpster N. Boxer cardiomyopathy. *Vet Clin North Am Small Anim Pract.* 1991;21:989–1004.
- [35] Granström S, Godiksen MT, Christiansen M, et al. Prevalence of hypertrophic cardiomyopathy in a cohort of British Shorthair cats in Denmark. *J Vet Intern Med.* 2011;25:866–871.
- [36] Gundler S, Tidholm A, Häggström J. Prevalence of myocardial hypertrophy in a population of asymptomatic Swedish Maine coon cats. *Acta Vet Scand.* 2008;50:22.
- [37] Cesta MF, Baty CJ, Keene BW, et al. Pathology of end-stage remodeling in a family of cats with hypertrophic cardiomyopathy. *Vet Pathol.* 2005;42:458–467.
- [38] Saito Y, Suzuki Y, Kondo N, et al. Direct epicardial assist device using artificial rubber muscle in a swine model of pediatric dilated cardiomyopathy. *Int J Artif Organs.* 2015;38:588–594.
- [39] Lin JH, Huang SY, Lee WC, et al. Echocardiographic features of pigs with spontaneous hypertrophic cardiomyopathy. *Comp Med.* 2002;52:238–242.
- [40] Collins DE, Eaton KA, Hoenerhoff MJ. Spontaneous dilated cardiomyopathy and right-sided heart failure as a differential diagnosis for hepatosis dietetica in a production pig. *Comp Med.* 2015;65:327–332.
- [41] Shyu JJ, Cheng CH, Erlandson RA, et al. Ultrastructure of intramural coronary arteries in pigs with hypertrophic cardiomyopathy. *Cardiovasc Pathol.* 2000;11:104–111.
- [42] Liu SK, Chiu YT, Shyu JJ, et al. Hypertrophic cardiomyopathy in pigs: quantitative pathologic features in 55 cases. *Cardiovasc Pathol.* 1994;3:261–268.
- [43] Horiuchi N, Kumagai D, Matsumoto K, et al. Detection of the nonsense mutation of OPA3 gene in Holstein Friesian cattle with dilated cardiomyopathy in Japan. *J Vet Med Sci.* 2015;77:1281–1283.
- [44] Van Vleet JF, Ferrans VJ. Myocardial diseases of animals. *Am J Pathol.* 1986;124:98–178.
- [45] Owczarek-Lipska M, Plattet P, Zipperle L, et al. A nonsense mutation in the optic atrophy 3 gene (OPA3) causes dilated cardiomyopathy in Red Holstein cattle. *Genomics.* 2011;97:51–57.

- [46] Furuoka H, Yagi S, Murakami A, et al. Hereditary dilated cardiomyopathy in Holstein-Friesian cattle in Japan: association with hereditary myopathy of the diaphragmatic muscles. *J Comp Pathol*. 2001;125:159–165.
- [47] Schatzberg SJ, Olby NJ, Breen M, et al. Molecular analysis of a spontaneous dystrophin ‘knockout’ dog. *Neuromuscul Disord*. 1999;9:289–295.
- [48] Stabej P, Imholz S, Versteeg SA, et al. Characterization of the canine desmin (DES) gene and evaluation as a candidate gene for dilated cardiomyopathy in the Doberman. *Gene*. 2004;340:241–249.
- [49] Philipp U, Vollmar A, Distl O. Evaluation of the titin-cap gene (TCAP) as candidate for dilated cardiomyopathy in Irish wolfhounds. *Anim Biotechnol*. 2008;19:231–236.
- [50] O’Sullivan ML, O’Grady MR, Pyle WG, Dawson JF. Evaluation of 10 genes encoding cardiac proteins in Doberman Pinschers with dilated cardiomyopathy. *Am J Vet Res*. 2011;72:932–939.
- [51] Cattanach BM, Dukes-McEwan J, Wotton PR, et al. A pedigree-based genetic appraisal of Boxer ARVC and the role of the Striatin mutation. *Vet Rec*. 2015;176:492.
- [52] Keene BW, Panciera DP, Atkins CE, et al. Myocardial L-carnitine deficiency in a family of dogs with dilated cardiomyopathy. *J Am Vet Med Assoc*. 1991;198:647–650.
- [53] Kittleson MD, Keene B, Pion PD, et al. Results of the multicenter spaniel trial (MUST): taurine- and carnitine-responsive dilated cardiomyopathy in American cocker spaniels with decreased plasma taurine concentration. *J Vet Intern Med*. 1997;11:204–211.
- [54] Phillips DE, Harkin KR. Hypothyroidism and myocardial failure in two Great Danes. *J Am Anim Hosp Assoc*. 2003;39:133–137.
- [55] Flood JA, Hoover JP. Improvement in myocardial dysfunction in a hypothyroid dog. *Can Vet J*. 2009;50:828–34.
- [56] Beier P, Reese S, Holler PJ, et al. The role of the hypothyroidism in the etiology and progression of dilated cardiomyopathy in Doberman Pinschers. *J Vet Intern Med*. 2015;29:141–149.
- [57] Day MJ. Inheritance of serum autoantibody, reduced serum IgA and autoimmune disease in a canine breeding colony. *Vet Immunol Immunopathol*. 1996;53:207–219.
- [58] Maxson TR, Meurs KM, Lehmkuhl LB, et al. Polymerase chain reaction analysis for viruses in paraffin-embedded myocardium from dogs with dilated cardiomyopathy or myocarditis. *Am J Vet Res*. 2001;62:130–135.
- [59] Calvert CA, Chapman WL, Toal RL. Congestive cardiomyopathy in Doberman Pinscher dogs. *J Am Vet Med Assoc*. 1982;181:598–602.
- [60] Hazlett MJ, Maxie MG, Allen DG, et al. A retrospective study of heart disease in Doberman Pinscher dogs. *Can Vet J*. 1983;24:205–210.

- [61] Tidholm A, Jönsson L. Dilated cardiomyopathy in the Newfoundland: a study of 37 cases (1983–1994). *J Am Anim Hosp Assoc*. 1996;32:465–470.
- [62] Calvert CA, Pickus CW, Jacobs GJ, et al. Signalment, survival and prognostic factors in Doberman Pinschers with end-stage cardiomyopathy. *J Vet Intern Med*. 1997;11:323–326.
- [63] Everett RM, McGann J, Wimberly HC, et al. Dilated cardiomyopathy of Doberman Pinschers: retrospective histomorphologic evaluation of heart from 32 cases. *Vet Pathol*. 1999;36:221–227.
- [64] Vollmar AC, Fox PR, Meurs KM, et al. Dilated cardiomyopathy in juvenile Doberman Pinscher dogs. *J Vet Cardiol*. 2005;5:23–27.
- [65] Lobo L, Carnevalheira J, Canada N, et al. Histologic characterization of dilated cardiomyopathy in Estrela mountain dogs. *Vet Pathol*. 2010;47:637–642.
- [66] Tilley LP, Liu S-K. Cardiomyopathy in the dog. *Recent Adv Stud Cardiac Struct Metab*. 1975;10:641–653.
- [67] Sandusky GE, Capen CC, Kerr KM. Histological and ultrastructural evaluation of cardiac lesions in idiopathic cardiomyopathy in dogs. *Can J Comp Med*. 1984;48:81–86.
- [68] Alroy J, Rush JE, Freeman L, et al. Inherited infantile dilated cardiomyopathy in dogs: genetic, clinical, biochemical, and morphologic findings. *Am J of Med Genet*. 2000;95:57–66.
- [69] Vollmar AC, Fox PR, Meurs KM, et al. Dilated cardiomyopathy in juvenile Doberman Pinscher dogs. *J Vet Cardiol*. 2005;5:23–27.