

We are IntechOpen, the world's leading publisher of Open Access books Built by scientists, for scientists

6,900

Open access books available

186,000

International authors and editors

200M

Downloads

Our authors are among the

154

Countries delivered to

TOP 1%

most cited scientists

12.2%

Contributors from top 500 universities



WEB OF SCIENCE™

Selection of our books indexed in the Book Citation Index
in Web of Science™ Core Collection (BKCI)

Interested in publishing with us?
Contact book.department@intechopen.com

Numbers displayed above are based on latest data collected.
For more information visit www.intechopen.com



Microscopic Evaluation of Necrotic Cell Death in the Cartilage Destined for Experimental Tracheal Allografts: Lyophilization vs Cryopreservation

Avelina Sotres-Vega, Jaime Villalba-Caloca,
Miguel O. Gaxiola-Gaxiola,
Miriam Mendoza-Santiago,
Juan A. Morales-Tiburcio,
Claudia Hernández-Jiménez and
Francisco Figueroa-Cavero

Additional information is available at the end of the chapter

<http://dx.doi.org/10.5772/65014>

Abstract

Tracheal replacement remains an important unmet need for patients with extensive lesions. Tracheal allografts treated by cryopreservation and lyophilization have been used as experimental methods for replacing long segments of the trachea. We compare the effect of lyophilization and cryopreservation on the canine tracheal cartilage by microscopic evaluation of necrotic cell death. Canine tracheal segments were rinsed and randomly divided into a control group (G1) and two biopreservation groups: lyophilization (G2) [-70 – $-55^{\circ}\text{C}/10$ mmBar] and cryopreservation (G3) [RPMI-1640 + 10%DMSO + 10%SBF, $-70^{\circ}\text{C}/-196^{\circ}\text{C}$]. After tracheal segments were rehydrated (G2) or thawed (G3), the central ring was obtained from each tracheal segment and processed for histological evaluation with hematoxylin and eosin and for caspase-3 expression by immunohistochemistry. Compared with the control group, chondrocytes without apparent abnormalities, nucleus with karyorrhexis, and caspase-3 expression decreased significantly with the effect of lyophilization and cryopreservation ($p < 0.001$, ANOVA + Tukey, chi-square, Kruskal-Wallis), while a significant decrease in pyknotic nuclei was observed only with the effect of the lyophilization as well as an increase in the nucleus with karyolysis and empty lacunae ($p < 0.001$, ANOVA + Tukey). The mean percentages of normal chondrocytes and empty lacunae were significantly affected by lyophilization compared with cryopreservation ($p < 0.01$, ANOVA + Tukey). Our results strongly suggest that lyophilization has a deleterious impact on the tracheal cartilage.

Keywords: Trachea, Tracheal allograft, Cryopreservation, Lyophilization, Cell death

1. Introduction

End-to-end anastomosis after an extensive tracheal resection is the method of choice for tracheal pathologies such as benign stenosis secondary to post-intubation injury, trauma, congenital, iatrogenic, or neoplasm causes. It is successfully performed in defects affecting up to 50% of the trachea in adults and 33% in infants. More extensive lesions are not amenable to conventional surgical intervention. Tracheal reconstruction after extensive resection is unresolved and remains one of the most important challenges in tracheal surgery [1]. In the search for alternative methods of replacing long tracheal segments, segmental trachea substitution using tracheal segments biopreserved by cryopreservation and lyophilization has been attempted; however, the clinical application of the procedure has been limited due to the fact that contradictory results have been reported [1–3]. A series of interconnected cartilage rings maintain the tubular shape of the trachea, allowing the passage of air. Chondrocytes are the resident cells of the tracheal cartilage. They reside in cavities in the matrix called cartilage lacunae. Chondrocyte connections to each other are crucial for adequate matrix balance and function, determining the tracheal cartilage stiffness of the biopreserved tracheal allograft. The biopreservation of the cartilage must therefore be investigated in basic research models of chondrocyte injuries. Necrosis, or irreversible cell death, is characterized by nuclear swelling, pyknosis, karyorrhexis, karyolysis, and cytoplasmic eosinophilic staining. Dehydration, rehydration, freezing, and thawing result in increased cell death by both necrosis and apoptosis.

Caspase-3 is the primary inducer of cell death by apoptosis. It is implicated in tissue damage due to mechanical ventilation [4], ischemia-reperfusion [5, 6], orotracheal cannulation due to the tidal volume effect [7], and freezing and thawing processes inherent in the cryopreservation of different tissues and cells [1].

The aim of this study was to compare the effect of two preservation methods (lyophilization and cryopreservation) on the canine tracheal cartilage by microscopic evaluation of necrotic cell death.

2. Experimental design

2.1. Material and methods

The protocol was reviewed and approved by the ethics committee of the Instituto Nacional de Enfermedades Respiratorias (INER) (“Ismael Cosío Villegas”) and carried out under the Technical Specification for the Care and Use of Laboratory Animals of the Mexican Official

Norm [8] and the Guide for the Care and Use of Laboratory Animals prepared by the US National Institutes of Health [9].

We harvested nine tracheas from dogs weighing 15–30 kg, regardless of sex and age, which were at the end of non-related tracheal research studies. Initial anesthesia was induced by intravenous administration of 0.1 mg/kg xylazine hydrochloride (Bayer, Leverkusen, Germany) and 6 mg/kg propofol (Pisa, Jalisco, Mexico). Anesthetized animals were placed in the supine position, intubated with an endotracheal tube, and placed on mechanical ventilation (Harvard Apparatus and a Vaporizer Isotec 3 Ohmeda). Anesthesia was maintained with 2% isoflurane, FiO₂ 100%, tidal volume 15 ml/kg, and respiratory rate 20/min. The neck and the thorax of each animal were shaved and prepared with povidone-iodine solution (EQM, Mexico, DF). A midline cervical to thoracic incision was made. After separating the strap muscles, the trachea was exposed from the cricoid cartilage to the carina and thoroughly dissected. Before harvesting the entire trachea, euthanasia was carried out using an intravenous administration of pentobarbital overdose and 1 mg KCl (Pisa, Jalisco, Mexico). The surrounding tissue was dissected on a cold Mayo table. The trachea was trimmed into seven ring segments and rinsed with a 50% glucose solution (Pisa, Jalisco, Mexico) with 5000 IU heparin/L (Pisa, Jalisco, Mexico) and 0.1 ml/L of antibiotic-antimycotic solution (Sigma, St. Louis, MO, USA). Immediately after washing in glucose solution, the tracheal segments were randomly divided into a control group without preservation (Group 1: nonpreservation tracheal segments) and two biopreservation groups (lyophilization and cryopreservation).

2.2. Lyophilization

Each tracheal segment was mounted on a 13 × 100 mm polypropylene tube (Datalab, Barcelona, Spain), transferred into a Kitasato flask (Pyrex, Corning, USA), and sealed with a polypropylene plug and parafilm (Bemis, Wisconsin, USA). The glass container was placed inside a polystyrene foam box and stored for 24 h at –70°C using a Revco freezer (Thermo Fisher Scientific, Georgia, USA). The Kitasato flask was then introduced into the lyophilizing device (Labconco, Kansas City, MO, USA) at –55°C and 10 mmBar vacuum pressure for 24 h. The tracheal segment was then sealed in airtight double-layered polyethylene bags, sterilized with ethylene oxide (Steri-Vac, Sterilizer/Aerator 5XL, 3 M, USA) at 736 mg ethylene oxide/L air, and stored at room temperature for 30 days. For rehydration, the lyophilized tracheal segment was placed inside a cold glass beaker with saline solution at 4°C for 30 min (Pisa, Jalisco, Mexico). After rehydration, it was removed from the polypropylene tube which was used as a support.

2.3. Cryopreservation

The solutions used for cryopreservation of the tracheal segments were RPMI-1640 media (R8758, Sigma, USA) with 10% dimethyl sulfoxide (D2650, Sigma, USA), 20% fetal bovine serum (16000-044, Gibco, USA), and 0.1 ml antibiotic-antimycotic solution (A5955, Sigma, USA) added per liter of solution. Each tracheal segment was transferred into a cryogenic vial (Nalgene, New York, USA), and the cryopreservation solution was added. Cryogenic vials were placed in a high-density polyethylene vial holder (Thermo Fisher Scientific, Nalgene 5200

Cryo $-1^{\circ}\text{C}/\text{min}$ Mr. Frosty Freezing Container, New York, USA) and stored for 24 h at -70°C in a Revco freezer (Thermo Fisher Scientific, Georgia, USA). The cryogenic vials were then stored in liquid nitrogen (-196°C) for 60 days. At the end of cryopreservation, the cryogenic vials were placed in a double boiler at 37°C for 30 min and immediately rinsed for 3 min in saline solution maintained at 4°C (Pisa, Jalisco, Mexico) with three changes of solution.

2.4. Histological and caspase-3 evaluations

Control group (G1): After harvesting, the tracheal segments were rinsed with a 50% glucose solution (Pisa, Jalisco, Mexico) and fixed with 10% buffered formalin for 24 h. Biopreserved groups (G2 and G3): After lyophilization and cryopreservation, tracheal segments were rehydrated (G2) or thawed (G3) and fixed with 10% buffered formalin for 24 h. After tracheal segments were fixed, the central ring was obtained from each tracheal segment, embedded and blocked in paraffin wax (McCormick Scientific, St. Louis, MO, USA), cut into $2\text{ }\mu\text{m}$ and $4\text{ }\mu\text{m}$ thick sections, and mounted on glass slides (Kling-On HIER Slides, Biocare Medical, USA) with a rotary microtome (Reichert, New York, USA). The rings were then processed for histological evaluation with hematoxylin and eosin (Merck, Darmstadt, Germany) and for caspase-3 expression. Histological assessment included the measurement of the percentage (average of four counts) of nucleated chondrocytes, empty lacunae, and cells with pyknosis, karyorrhexis, and karyolysis along the entire tracheal ring (**Figure 1**).

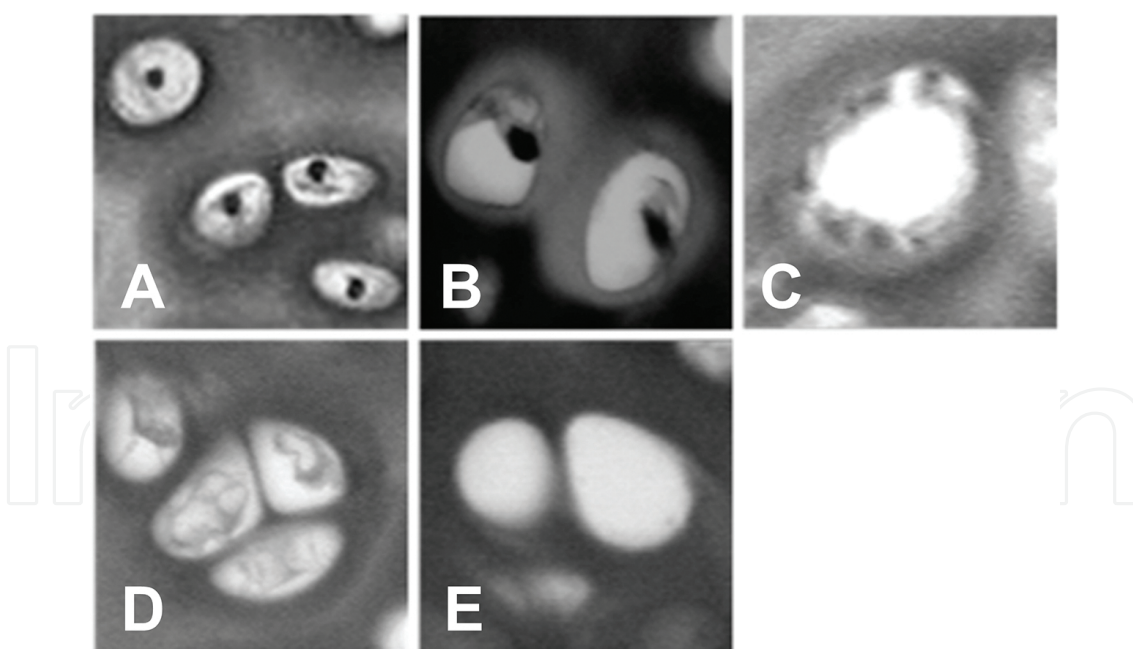


Figure 1. Histological assessment included the measurement of the percentage of nucleated chondrocytes (A), cells with pyknosis (B), karyorrhexis (C), karyolysis (D), and empty lacunae (E) along the entire tracheal ring. Hematoxylin and eosin (40 \times).

Caspase-3 expression in the cartilage was determined by immunohistochemistry using a polyclonal antibody [Caspase 3 (CPP32) Ab-4, rabbit polyclonal antibody, NeoMarkers, Lab

Vision, RB-1197-P, USA], biotin-avidin-peroxidase system (Vector, California, USA), staining with aminoethylcarbazole (BioGenex, California, USA), and double staining with hematoxylin (Vector, California, USA). Negative and positive controls for caspase-3 expression were counted using an optical microscope (Carl Zeiss, Jena, Germany) and a manual counter (Thermo Fisher Scientific, Waltham, MA, USA). Caspase-3 assessment included measurement of the percentage (average of three counts) of chondrocytes positive for caspase-3 immunoreactivity along the tracheal ring.

Statistical analysis was performed using SPSS 6.1 (Statistical Product and Service Solutions Inc., Chicago, IL, USA). The ANOVA + Tukey test was used to compare. The mean percentages of unaltered chondrocytes, degenerated cells (pyknosis, karyorrhexis, karyolysis), and empty lacunae chi-square and Kruskal-Wallis tests were used to compare caspase-3 expression in the cartilage. A value of $p < 0.05$ was considered statistically significant.

2.5. Results

The mean percentages of unaltered chondrocytes, degenerated cells (pyknosis, karyorrhexis, karyolysis), and empty lacunae obtained over the entire cartilage tracheal ring in all study groups are reported in **Table 1** and illustrated in **Figure 2**.

| Nuclei | Normal | Pyknosis | Karyorrhexis | Karyolysis | Empty lacunae |
|-----------------------|--------------|--------------|--------------|--------------|---------------|
| Control | 14.73 ± 0.69 | 26.36 ± 0.88 | 0.94 ± 0.16 | 24.02 ± 1.47 | 33.92 ± 1.34 |
| Post-lyophilization | 4.73 ± 0.49 | 15.78 ± 0.75 | 0.17 ± 0.05 | 35.45 ± 2.11 | 43.86 ± 1.41 |
| Post-cryopreservation | 9.15 ± 0.77 | 24.96 ± 1.41 | 0.25 ± 0.06 | 31.29 ± 2.57 | 34.26 ± 1.70 |

Table 1. Mean percentage ± standard error of chondrocytes without apparent alterations and degenerated cells.

The lyophilized tracheal segments showed a decreased percentage of unaltered chondrocytes [14.73–4.73 (67.89%)], nuclei with pyknosis [26.36–15.78 (40.14%)], and chondrocytes with karyorrhexis [0.94–0.17 (81.92%)] compared to tracheal segments without lyophilization. The percentage of chondrocytes with karyolysis [24.02–35.45 (47.58%)] and empty lacunae [33.92–43.86 (33.23%)] increased after lyophilization. All changes were statistically significant (control vs post-lyophilization: $p < 0.001$, ANOVA + Tukey).

Cryopreserved tracheal segments showed a decreased percentage of chondrocytes without apparent abnormalities [14.73–9.15 (35.01%)], nuclei with pyknosis [26.36–24.96 (5.32%)], and karyorrhexis [0.94–0.25 (73.41%)], as well as an increase in the percentage of cells with karyolysis [24.02–31.29 (30.26%)] and empty lacunae [33.92–34.26 (1.0%)]. The changes in the percentages of normal chondrocytes and cells with karyorrhexis were significantly different from the control group [control vs post-cryopreservation: chondrocytes unaltered and karyorrhexis ($p < 0.001$), ANOVA + Tukey]. Percentages of nuclei with pyknosis, karyolysis, and empty lacunae were not significantly different when compared to the control group [control vs post-cryopreservation: pyknosis ($p = 0.798$), karyolysis ($p = 0.060$), and empty lacunae ($p = 0.998$, ANOVA + Tukey).

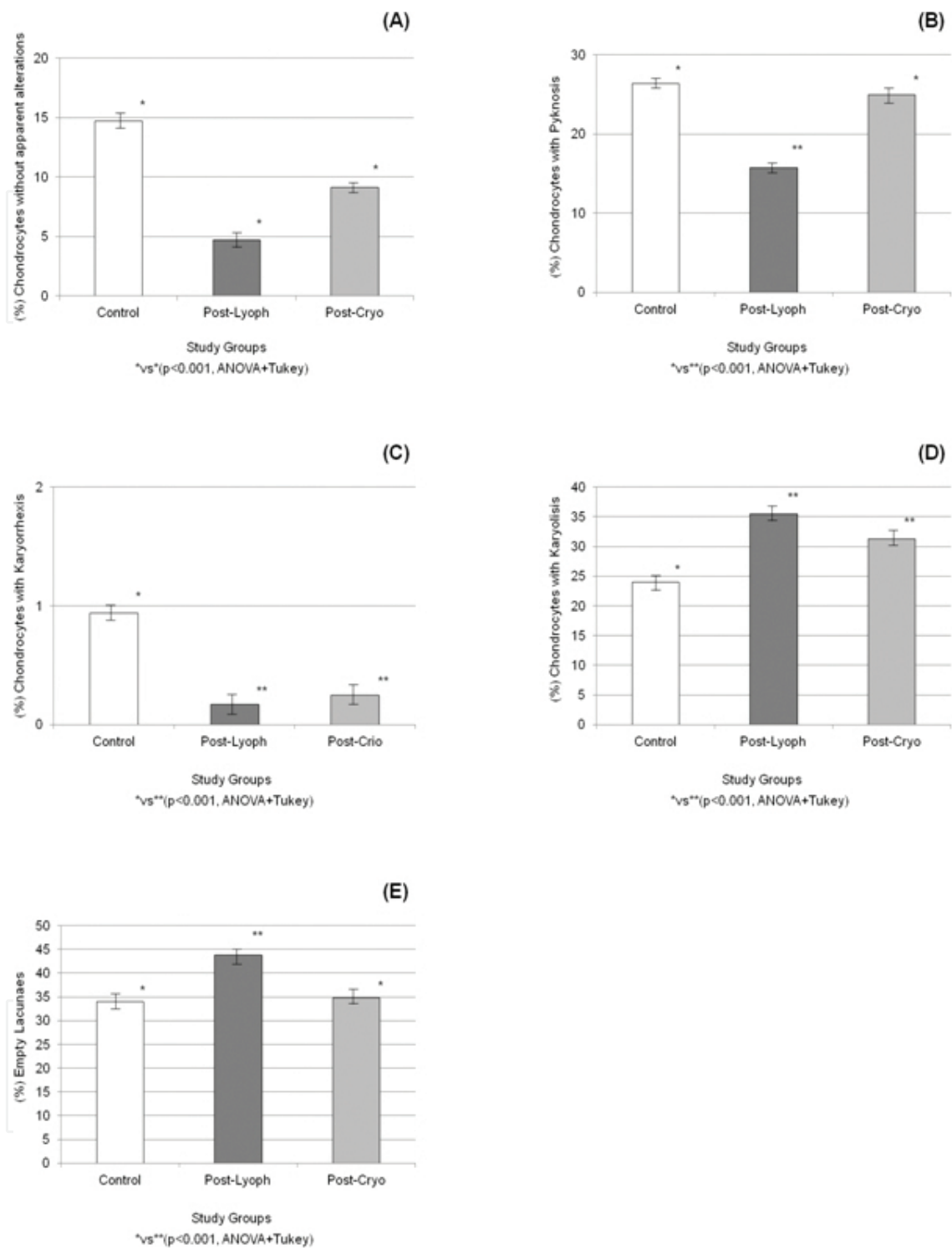


Figure 2. Percentage of chondrocytes without apparent alterations (A), nuclei with pyknosis (B), karyorrhexis (C), and karyolysis (D) before and after biopreservation of the tracheal segments.

The mean percentages of normal chondrocytes, pyknotic nuclei, and empty lacunae were significantly affected by lyophilization compared with cryopreservation [normal chondrocytes, pyknotic cells, and empty lacunae ($p < 0.01$), ANOVA + Tukey].

Only four tracheal segments from the control group were positive for caspase-3 expression in the chondrocytes. This expression was significantly diminished after biopreservation of tracheal segments [control vs post-lyophilization and control vs post-cryopreservation: ($p < 0.01$), chi-square, Kruskal-Wallis] (**Figure 3**).

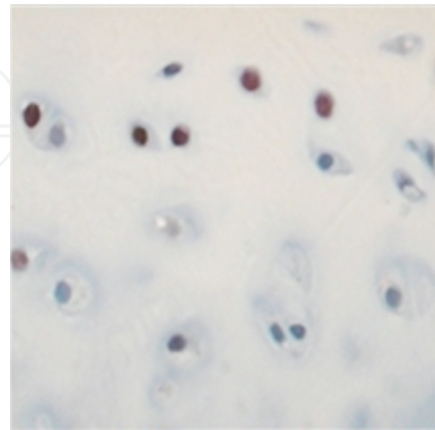


Figure 3. Caspase-3 immunoreactivity (chondrocytes with brown coloration) in one tracheal segment from the control group. Aminoethylcarbazole-hematoxylin staining under $\times 25$ magnification.

3. Discussion

Despite numerous attempts made with synthetic prostheses and tracheal transplants of autologous tissues, none of these alternatives has permitted functional reconstruction due to complications such as devascularization, stenosis, necrosis, dehiscence, infection, immune reactions, and formation of granulation tissue. Reconstruction of long-segment tracheal defects is an important, unresolved clinical problem. Several attempts at replacing the trachea have been made using lyophilized and cryopreserved tracheal segments. We compared the effect of two preservation methods (lyophilization and cryopreservation) on the canine tracheal cartilage by microscopic evaluation of necrotic cell death.

Cell death by means of histological changes and expression of caspase-3 in lyophilized and cryopreserved tracheal cartilage was evaluated. Histology was evaluated by light microscopy. Our results showed that the tracheal cartilage treated with lyophilization or cryopreservation induced significant changes in the chondrocyte integrity. These changes were more severe with lyophilization.

The nucleated chondrocytes decreased significantly with preservation (lyophilization or cryopreservation) compared to the tracheal segments from the control group. However, unaltered chondrocytes were significantly affected by lyophilization compared with cryopreservation. Major cell death could lead to a failure in cartilage matrix turnover because chondrocytes are the only source of matrix component synthesis in the cartilage. If chondrocytes are crucial for adequate matrix balance and function, chondrocyte death could be related to tracheal death.

Chondrocytes reside in cavities in the matrix called cartilage lacunae. In the bone, the standard technique for determining osteonecrosis in clinical pathology remains the identification of empty lacunae [10, 11]. Most osteocyte number studies used the number of lacunae as a reference [11]. Empty osteocyte lacunae rarely occur within the first seven days of bone death, and it may take over 16 weeks for a complete loss of osteocytes from the lacunae [10].

We found that the percentage of empty lacunae increased significantly with lyophilization. This increase was 33% higher than in cryopreserved tracheal segments. This increased percentage of empty lacunae might indicate that lyophilized chondrocytes are prone to die sooner than cryopreserved chondrocytes.

A series of characteristic morphological changes occurs when chondrocytes lose their viability. Necrosis, or irreversible cell death, is characterized by nuclear swelling, pyknosis, karyorrhexis, karyolysis, and cytoplasmic eosinophilic staining [10]. Several studies over the past decade have shown convincing evidence that osteocytes die by apoptosis. During the last stages of programmed cell death, osteocytes break up into apoptotic bodies that may be less than 2–3 μm in diameter. Such bodies are likely to remain undetectable to light microscopy and may well be interpreted as empty lacunae [12]. On the other hand, apoptotic bodies are phagocytosed by neighboring cells or macrophages, thereby preventing the retention of cellular debris in the extracellular space. In the bone, some osteocytes die in situ by apoptosis. This process is brief, and the remnants of apoptotic death are recognizable by conventional light microscopy. Apoptotic bodies can remain as pyknotic nuclei for many months. Eventually, the products of cell death are removed and become undetectable, leaving apparently empty lacunae. Much later, the empty lacunae become filled with mineralized debris and may no longer be visible by light microscopy [13]. Our results indicate that the percentage of chondrocytes with nuclear pyknosis decreased after both lyophilization and cryopreservation. This decrease was statistically significant only in the lyophilized group of tracheal segments, and pyknosis does not necessarily mean necrosis. Coupled with the decrease in the percentage of pyknotic nuclei after preservation, we also found that caspase-3 expression was significantly diminished due to lyophilization or cryopreservation of the tracheal segments. If caspase-3 expression is implicated in tissue damage due to ischemia [5, 6], orotracheal cannulation due to the tidal volume effect [7], and the freezing process inherent in the preservation, it is possible that in lyophilized or cryopreserved tracheal segments, cell death by apoptosis or expression of caspase-3 occurs before biopreservation. The main cell death pathway after rehydrating or thawing tracheal segments would then be necrosis. According to Hedgecock [12], if large numbers of osteocytes undergo apoptosis at the time of tissue harvest, many other osteocytes likely underwent apoptosis previously, becoming shrunken and fragmented and disappearing from their lacunae. Empty lacunae may represent osteocytes that previously died by apoptosis. We also found that lyophilized or cryopreserved tracheal segments showed a significantly decreased percentage of nuclei with karyorrhexis and an increased percentage of nuclei with karyolysis. However, this increase was significant only after lyophilization. Karyolysis is usually preceded by karyorrhexis and occurs primarily as a result of necrosis. In apoptosis, karyorrhexis usually follows after the core is dissolved in apoptotic bodies. The mean percentage of normal or unaltered chondrocytes, pyknotic nuclei, and empty lacunae was

significantly affected by lyophilization compared with cryopreservation. Our results therefore strongly suggest that lyophilization has a deleterious impact on the tracheal cartilage and corroborate the findings reported by Lenot et al. [2] and Villalba-Caloca [14].

4. Conclusions

By microscopic evaluation of necrotic cell death, lyophilization has a deleterious impact on the tracheal cartilage.

Author details

Avelina Sotres-Vega^{1*}, Jaime Villalba-Caloca¹, Miguel O. Gaxiola-Gaxiola²,
Miriam Mendoza-Santiago¹, Juan A. Morales-Tiburcio¹, Claudia Hernández-Jiménez³ and
Francisco Figueroa-Cavero¹

*Address all correspondence to: avelinasotres@gmail.com

1 Experimental Lung Transplant Unit, National Institute of Respiratory Diseases, "Ismael Cosío Villegas", Mexico City, Mexico

2 Morphology Department, National Institute of Respiratory Diseases, "Ismael Cosío Villegas", Mexico City, Mexico

3 Experimental Surgery Department, National Institute of Respiratory Diseases, "Ismael Cosío Villegas", Mexico City, Mexico

References

- [1] Sotres-Vega A, Villalba-Caloca J, Jasso-Victoria R, Olmos-Zíñiga JR, Gaxiola-Gaxiola M, Baltazares-Lipp M, Santibañez-Salgado A. Cryopreserved tracheal grafts: A review of the literature. *J Invest Surg* 2006;19:125–35.
- [2] Lenot B, Macchiarini P, Dulmet E, Weiss M, Darteville P. Tracheal allograft replacement. An unsuccessful method. *Eur J Cardiothorac Surg* 1993;7:648–52.
- [3] Haykal S, Salna M, Waddell T, Hofer S. Advances in tracheal reconstruction. *Plast Reconstr Sur Glob Open* 2014;2:e178; doi: 10.1097/GOX000000000000097).
- [4] Bradley N, Smuder A, Hudson M, Talbert E, Powers S. Cross-talk between the calpain and caspase-3 proteolytic systems in the diaphragm during prolonged mechanical ventilation. *Crit Care Med* 2012 40: 1857–1863. doi:10.1097/CCM.0b013e318246bb5d.

- [5] Petrache I, Fijalkowska I, Medler T, Skirball J, Cruz P, Zhen L, Petrache H, Flotte T, Tudor R. α -1 Antitrypsin inhibits caspase-3 activity, preventing lung endothelial cell apoptosis. *Am J Pathol* 2006; 169: 1155–1166. doi: 10.2353/ajpath.2006.060058
- [6] Hunaid A, Galiñales M. Effect of degree of ischemic injury and reoxygenation time on the myocardial cell death in man: Role of caspases. *BMC Physiol* 2005;5:1–12.
- [7] Hu G, Cai S, Chen Y, Gao F. Effect of different tidal volume ventilation on rat bronchial and alveolar epithelial cell apoptosis. *Di Yi Jun Da Xue Xue Bao* 2005;25:508–512.
- [8] Official Journal of the Federation. Technical specifications for the production care and use of laboratory animals of the Official Mexican Standard NOM-062-ZOO-1999. Mexico: United States of Mexico (December 6); 1999.
- [9] National Institutes of Health U.S.A. Guide for Care and Use of Laboratory Animals. U.S. Eighth Edition. The Guide NRS, <http://www.nap.edu/catalog/12910.html>; 2011.
- [10] Kieser D, Poole T, Jennings M, Parker K, Kieser S, Kieser J, Theis J. The validity of CMFDA and Ethd-1 in the determination of osteocyte viability in the diaphysis of long bones in a sheep model. *J Clin Exp Pathol* 2014; 4: 201. doi:10.4172/2161-0681.1000201
- [11] Parfitt M. Life history of osteocytes: relationship to bone age, bone remodeling, and bone fragility. *J Musculoskel Neuron Interact* 2002; 2:499–500
- [12] Hedgecock N, Hadi T, Chen A, Curtiss S, Martin R, Hazelwood S. Quantitative regional associations between remodeling, modeling, and osteocyte apoptosis and density in rabbit tibial midshafts. *Bone* 2006;40:627-637, 2007. DOI: <http://dx.doi.org/10.1016/j.bone.10.006>
- [13] Shijing Q, Sudhaker R, Palnitkar S, Parfitt A. Differences in osteocyte and lacunar density between black and white American women. *Bone* 2006; 38:130–135.
- [14] Villalba-Caloca J. Tisular response of lyophilized and cryopreserved tracheal allograft treated with immunosuppressive therapy and topical application of vascular endothelial growth factor. [Doctoral Thesis]. Mexico: National Polytechnic Institute; 2007.