

We are IntechOpen, the world's leading publisher of Open Access books Built by scientists, for scientists

6,900

Open access books available

186,000

International authors and editors

200M

Downloads

Our authors are among the

154

Countries delivered to

TOP 1%

most cited scientists

12.2%

Contributors from top 500 universities



WEB OF SCIENCE™

Selection of our books indexed in the Book Citation Index
in Web of Science™ Core Collection (BKCI)

Interested in publishing with us?
Contact book.department@intechopen.com

Numbers displayed above are based on latest data collected.
For more information visit www.intechopen.com



Deep Neuromuscular Blockade Improves Surgical Conditions During Gynecological Laparoscopy

Christophe Dransart, Laurie Putz,
Maria-Laura Marotta and Philippe E. Dubois

Additional information is available at the end of the chapter

<http://dx.doi.org/10.5772/64934>

Abstract

Obtaining an appropriate laparoscopic workspace depends on several factors related to the patient (i.e., weight and abdominal compliance) and the procedure (i.e., body's position, depth of anesthesia and intra-abdominal (IA) pressure). Among them, a deep neuromuscular blockade (NMB) contributes to provide the surgeon with better operating conditions. This chapter discusses the interests and challenges of muscle relaxation during gynecological laparoscopy. The introduction of sugammadex into clinical practice provides the opportunity to modify the management of neuromuscular blockade to improve the surgical conditions during laparoscopy as well as the safety of the patients. The maintenance of a rocuronium-induced deep neuromuscular block from the trocar insertion until the end of laparoscopy is no longer incompatible with rapid recovery and awakening in optimal conditions. Neuromuscular transmission (NMT) monitoring is the key to adequate management and should be used in all cases. Objective measurements allow for excellent intubation and surgical conditions, the definition of thresholds and doses for the administration of reversal agents, and the exclusion of residual blockade prior to the patient extubation.

Keywords: neuromuscular blockade, laparoscopic surgical conditions, rocuronium, neostigmine, sugammadex

1. Introduction

Since the first laparoscopy was performed on a human by Jacobaeus in Sweden in 1910 [1], laparoscopic techniques have steadily developed. It was not until 1943 that the first diagnostic gynecological laparoscopy was performed with uterine mobilization, thanks to Raoul Palmer's

ingenuity [2]. In the 1950s, with the advent of a safer laparoscopic lighting system, laparoscopy had taken a step forward but remained mostly a diagnostic tool [3]. In 1982, the addition of a video camera to laparoscopes allowed surgeons to be helped by assistants and to perform more and more surgical techniques by laparoscopy (e.g., adhesiolysis, appendectomy, cholecystectomy, and hysterectomy) [2, 3].

Diagnostic laparoscopy became part of fertility work-ups, with the growing development of assisted reproductive technology (intrauterine inseminations and *in vitro* fertilization). When cost-effectiveness debates began, routine diagnostic laparoscopy was increasingly supplanted by these treatments. Nevertheless, surgical laparoscopy to treat advanced-stage endometriosis, tubal pathology, and ovarian cysts or to perform myomectomy remains beneficial [4–7].

Relative limitations of performing surgical laparoscopy are surgeon expertise (in fertility surgery), general anesthesia, patient obesity, cardiovascular disease (less frequent in young patients receiving fertility treatments), and previous abdominal surgery [3–5].

In the last few years, new techniques emerged providing the surgeon with high precision and less invasive tools (robotically assisted laparoscopy, single-port laparoscopy) [3, 8–11]. However, all laparoscopic procedures need to create a space inside the abdomen: the pneumoperitoneum.

2. The laparoscopic workspace

When insufflating the intra-abdominal (IA) cavity with gas, numerous elements contribute to provide the surgeon with an adequate space to work. Some depend on the patient and others on the procedure (**Figure 1**).

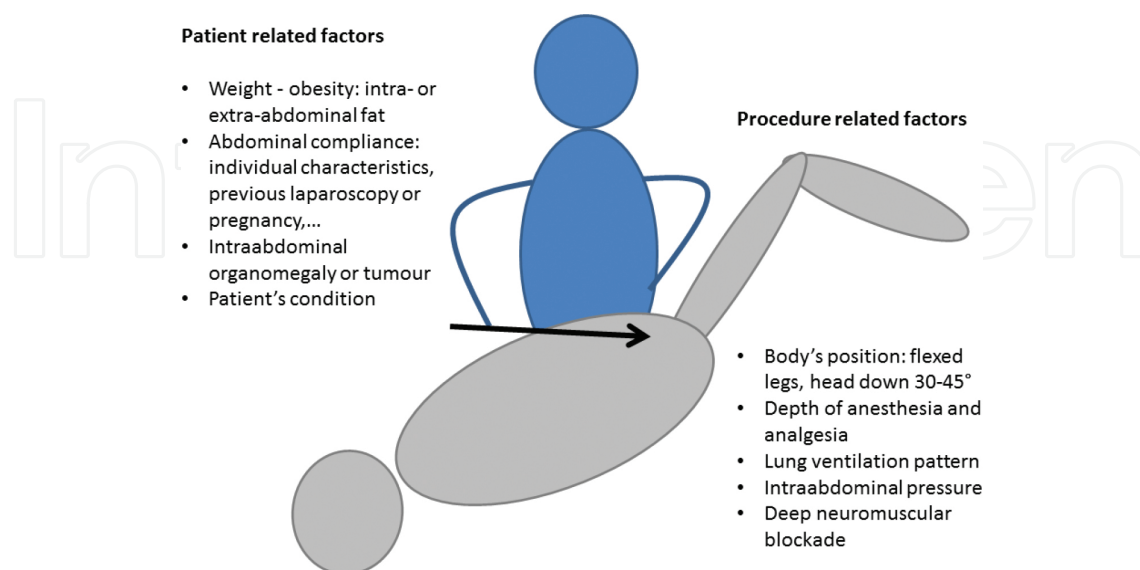


Figure 1. Contributing factors to the establishment of the laparoscopic workspace.

2.1. Weight

When creating the laparoscopic workspace in overweight or obese patients, difficulties are encountered due to the placement of laparoscopic trocars, with a higher risk of bleeding from abdominal wall vessels due to a restricted operative field limited by the thick abdominal wall or IA fat, and also due to limitations in placing obese patients in the Trendelenburg position [3]. To decrease the risk of bowel injury during under-umbilical laparoscopic entry, different techniques can be used: open under-umbilical laparoscopy or left/right upper-quadrant trocar insertion [3, 12].

2.2. Previous abdominal surgery

Fibrosis and adhesions can be barriers to the creation of a large IA workspace.

2.3. Previous pregnancy or laparoscopy

On the contrary, a previous muscular stretching of the abdominal wall could have modified the abdominal compliance in favor of larger IA volume [13].

2.4. Patient's anatomy

Any IA tumor or organomegaly can constitute a threat for laparoscopic entry and adequate workspace. In the case of huge or multiple fibroids (>10 cm in size), laparoscopic myomectomy cannot be performed, and laparotomy is then indicated [12].

2.5. Depth of anesthesia and analgesia

Anesthesiologists are obligated to provide the patient with safe care during surgery. This includes an adequate level of anesthesia and analgesia, considering the procedure requirements and the patient's health status. The anesthesiologist must, in collaboration with the surgeon, find the balance between benefits and harm of applying deep anesthesia during laparoscopy to improve the quality of surgical conditions. Their common goal is to perform safe and fast surgery under the best obtainable conditions.

2.6. The patient's body position

The body position significantly influences the abdominal inflation volume and, thus, could improve or worsen the surgical workspace. The mean inflated volume can be increased up to 900 mL in the Trendelenburg position and/or when the legs are slightly flexed at the hips [13, 14].

2.7. Intra-abdominal pressure (IAP)

Insufflating gas in the abdominal cavity during laparoscopy allows the creation of a workspace between the abdominal wall and the IA organs, the pneumoperitoneum.

The measurement of abdominal compliance makes it possible to estimate the required pressure needed to achieve a certain IA volume and explain why certain patients have a limited abdominal workspace compared with others during laparoscopy. The abdominal pressure-inflated volume relationship behaves in a linear fashion between 0 and 12 mmHg. Every abdomen can be described by two parameters: elastance and the pressure at zero volume [15].

In clinical practice, IAP is routinely monitored at 12–15 mmHg [16]. Low IAP is defined as 6–10 mmHg [17]. Low IAP has potential benefits when compared with standard pressure:

- Fewer adverse effects on pulmonary function [18]. However, blood gas analyses and pulmonary function tests are not significantly different. Healthy individuals, with the aid of artificial ventilator adjustments, are able to compensate for pulmonary function reduction during pneumoperitoneum [17]. Further studies are necessary for ASA three to four patients.
- Fewer hemodynamic side effects are encountered, including reduced preload and decreased cardiac output [19], but this does not seem to have significant advantages when compared with standard IAP in healthy patients [17].
- No significant or persistent liver (transient elevation of liver enzymes such as AST and ALT) or renal impairment (reduced renal perfusion, decreased urine output, but no changes in postoperative creatinine) was observed or had clinical consequences in healthy patients [17].
- Postoperative peritoneal adhesions and anastomotic leakage are important complications following gynecological and abdominal surgery. The mechanism is unclear but could include local hypoxemia caused by mechanical compression of the capillary bed reducing blood flow. Local hypercapnia induces acidosis and an impaired microcirculation [17]. One human study suggests that low IAP minimizes the adverse effects on surgical peritoneal environment [20].
- As with the head-down position, elevated IAP increases intrathoracic pressure, reduces cerebral venous drainage, and increases cerebrospinal fluid and subsequently intracranial and intraocular pressure [17].
- Low IAP is associated with significantly lower postoperative inflammatory response of IL2, IL6, and CRP [17, 21]. This has to be confirmed by further studies.
- Low IAP was associated with less postoperative pain during the early postoperative phase [22–24], including less shoulder referred pain [25–27]. This was also demonstrated after laparoscopic gynecologic procedures [28, 29]. Extended wash out of IA gas (5 min with open valve umbilical trocar after lap hysterectomy) was found to be an effective and safe method of reducing postoperative abdominal and shoulder pain levels [30].

A clinically significant reduction in pain score is likely to result in shorter hospital stays and earlier return to normal activity and work [31]. However, the difference in pain intensity between low and standard IAP was not always immediately significant, only after 2–3 days [17]. In addition, the reduction in postoperative analgesic requirement was not always relevant [22, 32]. Factors implicated in pain after laparoscopic surgery include diaphragm and

phrenic nerve irritation or stretching, intraperitoneal acidosis, residual IA gas, volume and lack of humidity of the insufflated gas, wound size and the presence of drains, and also sociocultural and individual factors [31, 33, 34].

On the other hand, low IAP was often associated with a substantial reduction in visibility and available working space [35]. Then, decreasing IA pressure might prolong operation time and subsequently increase the costs of the procedure; this was not found to be significant [36]. Low pressure apparently resulted in a less than optimal surgical field, which could result in an increased incidence of surgical complications. However, low IAP had a comparable incidence of serious adverse events and conversions to open procedures when compared with standard pressure [28, 37, 38].

Finally, recommendations to use low IAP are weak, and more studies are required to establish the safety of low-pressure pneumoperitoneum and to explore its value for physicians and patients [17]. A practical and reasonable approach is to start with the lowest possible IAP that is required to obtain adequate exposure of the operative field [39] and to increase the pressure to routine level when the exposure is inadequate [40].

2.8. Is there a place for deep neuromuscular blockade (NMB) to improve the laparoscopic workspace and surgical conditions?

Neuromuscular blocking agents (NMBAs) were introduced into clinical practice in 1942 and were rapidly adopted as an important part of modern balanced anesthesia [41]. At a time when anesthesia was tricky in most patients, inducing a NMB significantly improved surgical conditions in more and more situations [42]. However, almost as soon as its use began, NMBA administration was associated with side effects and related mortality [43].

To secure the airway, orotracheal intubation is traditionally performed after injecting a NMBA. Compared with other techniques, excellent intubating conditions are more easily obtained with NMB and are less frequently associated with postoperative hoarseness and vocal cord injuries [44].

Classically, administering NMBA continuously during some surgical procedures may enhance patient safety and decrease morbidity (e.g., open eye surgery under general anesthesia and intracranial surgery) [31], but new indications emerged with the development of surgery, including laparoscopy [45]. The major determinant of the amount of pressure that is required for adequate surgical conditions is the compliance of the abdominal wall, which could be increased significantly by the administration of NMBA [17]. Madsen and colleagues also suggest that the possible negative effects of low-pressure pneumoperitoneum on perioperative conditions might be overcome by the adequate use of NMBA [46].

The goal of this chapter is to provide the reader with the factors that help to determine the benefits and challenges of maintaining a deep NMB during pelvic laparoscopy to improve the surgical workspace and the operating conditions.

3. Neuromuscular transmission: physiology and monitoring

The neuromuscular junction is the chemical step that transduces the electrical activity of a motor nerve ending to the postjunctional muscle membrane to ultimately generate muscle contraction (**Figure 2a**). The presynaptic nerve ending is responsible for acetylcholine (ACh) synthesis, packaging into vesicles, and release when the nerve membrane depolarizes. The synaptic cleft allows for rapid diffusion of the neurotransmitter. The postsynaptic membrane is a specialized region of folded muscle membrane filled with nicotinic acetylcholine receptors. Two acetylcholine molecules have to fix on the nicotinic receptor to open its ionic channel and, when numerous enough, induce the muscle membrane depolarization and the propagation of the electric signal, which generate the muscle contraction. ACh is rapidly inactivated and divided into acetate and choline by acetylcholinesterases present in the postsynaptic membrane folds. A presynaptic mechanism allows for sustained transmitter release over time to maintain the muscle contraction. When stimulated by ACh, slightly different nicotinic receptors present on the presynaptic nerve terminal mobilize storage vesicles to reach the nerve membrane and release a higher quantity of ACh in the synaptic cleft. This positive feedback mechanism allows for high intensity and long-duration muscle contraction [47].

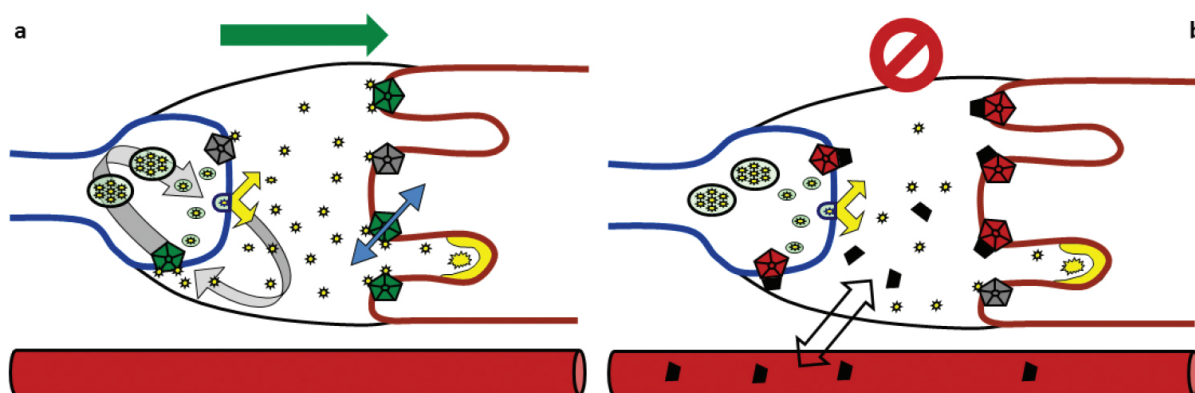


Figure 2. Neuromuscular transmission (a) and blockade (b). (a) The motor nerve (on the left) synthesizes, stores, and liberates vesicles of acetylcholine in the synaptic cleft when it depolarizes. Acetylcholines (yellow stars) bind to postsynaptic nicotinic receptors to open the ionic channel and depolarize the muscle membrane (on the right), inducing the muscle contraction. Cholinesterases inactivate rapidly acetylcholine in the folds of the motor end plate. Presynaptic nicotinic receptors allow for a positive feedback on the nerve in order to liberate more acetylcholine to induce intense contraction. (b) Neuromuscular blocking agents (black trapezes) distribute from the plasma into the synaptic cleft to bind and inactivate the nicotinic receptors on pre- and postsynaptic membranes, competitively with acetylcholine.

Non-depolarizing neuromuscular blocking agents (NMBA) fix competitively with ACh on nicotinic receptors. On presynaptic receptors, for which they have the highest affinity, they prevent the mobilization and release of storages of ACh, inducing fade to repetitive nerve stimulation because of a lack of available ACh. On the postsynaptic receptors, they prevent the membrane from depolarizing and, therefore, initiating the muscle contraction. The NMB is a combination of these two actions (**Figure 2b**).

According to the pharmacokinetics of each drug, NMBA is metabolized and/or progressively eliminated from the plasma. The concentration decreases in the synaptic cleft and, as ACh can reach more and more receptors, the neuromuscular transmission (NMT) recovers gradually.

During anesthesia, the level of NMB can be monitored with the use of a nerve stimulator (**Figure 3**). As the standard, the ulnar nerve is stimulated at the wrist and the degree of relaxation is measured at the adductor pollicis muscle [48]. The motor nerve is stimulated by standardized electric patterns:

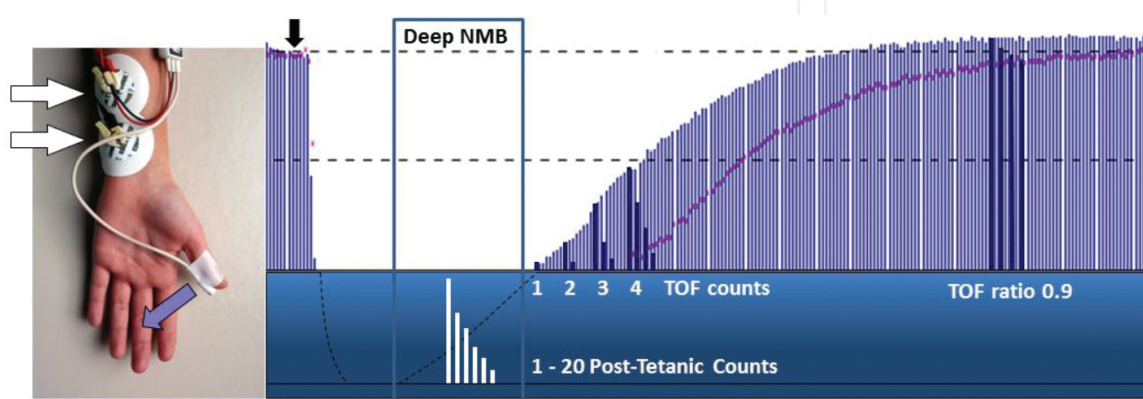


Figure 3. Neuromuscular transmission monitoring. The ulnar nerve is electrically stimulated at the wrist by train of four (TOF) or post-tetanic count (PTC) sequences. The thumb movements are recorded and displayed during the onset (after neuromuscular blocking agent administration: black arrow) and spontaneous recovery of a neuromuscular blockade: vertical lines represent the first twitch height (T1), purple dots are the TOF ratio (T4/T1), PTC and TOF count are additionally represented. Deep neuromuscular blockade is defined as TOF count 0 and PTC ≥ 1 .

- The train-of-four (TOF) [49] is an automatic repetition of four square electric twitches (200 μ s) at 2 Hz for every 15 s. The current intensity can be set according to every patient characteristic (50–60 mA as the default level). During NMB recovery and related to presynaptic fade, TOF recovers progressively 1, 2, 3, and then 4 counts before a TOF ratio (relative height of T4/T1) can quantify the residual fade until reaching 1.
- When there is no response to TOF, the post-tetanic count (PTC) [50] is another automatic sequence dedicated to monitoring deeper levels of blockade, including a tetanic stimulation (twitches at 50–100 Hz during 5 s) to mobilize presynaptic storages of ACh before 20 single twitches (1 Hz) are delivered.

The corresponding muscle responses are evaluated by the operator (visual or tactile subjective evaluation) or, much better, are objectively quantified by a dedicated monitor. Then, the complete course of any NMB can be accurately described by PTC, TOF count, and TOF ratio. Unfortunately, many clinicians still do not use objective monitors in their clinical practice [51]. This is undoubtedly a prerequisite to proper intraoperative management of NMB.

According to PTC, TOF count, and TOF ratio, different levels of NMB are determined as follows: [31, 48]

- Intense block: no response to PTC.
- Deep NMB: a PTC one or more but no response to TOF.
- Moderate block: TOF count 1–3.
- Shallow block: a TOF count of 4 with fade, quantified as TOF ratio.
- Threshold for safe tracheal extubation: TOF ratio >0.9.

It is important to know that different muscle groups have different sensitivities to NMBAs [52, 53]. Particularly, the adductor pollicis muscle is more sensitive to NMBAs compared with the abdominal wall muscles and the diaphragm, which have a more rapid recovery [54–56]. Consequently, the depth of blockade at the thumb does not reflect the exact level of blockade at the other muscle groups. Even when no TOF count is recorded at the thumb, laparoscopic surgeons may experience insufficient relaxation of the abdominal wall muscles that could induce unexpected movements of the IA instruments and could impair the surgical conditions. On the other hand, using PTC allows for properly monitoring deep NMB at the thumb and is sufficiently sensitive to ensure enough diaphragm paralysis for most clinical purposes [57, 58].

4. Neuromuscular blockade: the impact on laparoscopic workspace

Modern anesthesia provides every patient undergoing laparoscopic surgery with a combination of drugs and techniques as closely adapted to his physical status as possible, including hypnotic agents, multimodal analgesia, lung ventilation in head-down position, hemodynamic and fluid management, and postoperative nausea prevention. Among them, NMB is indicated for intubation and during the surgical procedure. But, as do most drugs, NMBAs have some risks related to their administration, including:

- Anaphylaxis (1/13,000, depending on the drug). Anesthesiologists are trained to manage this acute complication (protocol, algorithm, and simulation).
- Awareness during the procedure. Monitoring of the depth of anesthesia continues to improve, including using the bispectral index, which helps to prevent awareness during anesthesia [59].
- Residual paralysis at the time of tracheal extubation (see Section 5).

As a consequence, some anesthesiologists might be reluctant to induce deep NMB, especially during the entire procedure. Satisfactory surgical conditions are the end product of multiple factors that may range from the level of general anesthesia administered to the skill of the surgeon and the collaboration between the surgeon and the anesthesiologist [60]. In clinical practice, when a surgeon experiences surgical conditions that are less than satisfactory, the anesthesiologist can take some of the following actions [61]:

- Changing the body position.

- Increasing the depth of anesthesia (high dose of hypnotics, vapors, and/or opioids).
- Changing the ventilator patterns.
- Increasing the insufflation pressure.

These alternatives often cause cardiovascular depression and increased peak airway pressure and cannot reliably abolish all movements [62, 63]. Without appropriate NMB, sudden muscle contractions are experienced in $\pm 30\%$ of laparoscopic procedures [64, 65]. The initial (blind) insertion of the trocars is a high-risk part of the laparoscopic procedure that could cause the most serious complications related to laparoscopy, such as perforations of a bowel or a large vessel [66]. The establishment of a deep NMB in this initial part of the procedure seems to be essential to reduce the possible occurrence of these complications. However, no study actually demonstrates that maintaining a deep NMB reduces the surgical complication rate [60], and NMB should not be used as a substitute for adequate depth of anesthesia [31].

Ultimately, what level of NMB is associated with optimal conditions for laparoscopic surgery, and does a deep NMB provide superior operating conditions for laparoscopy than does a moderate block?

4.1. Studies to determine the interest of deep NMB during pelvic laparoscopy

The requirement for muscle relaxation has evolved with the development of surgery. Few studies addressed this question in the specific field of gynecologic laparoscopy. Different methods were used, making comparison difficult and inducing a risk of bias in the interpretation of the results. The most frequent outcome was the subjective surgeon's assessment of the surgical conditions during the procedure [61]. Different surgical rating scales (SRSs) (three to five points) were used to quantify the quality of the surgical field and the operating conditions, ranging from excellent to poor or unacceptable. However, these scales have not yet been validated for assessment of surgical conditions.

To enable the reader to come to his own conclusion, the different studies available in pelvic/gynecological laparoscopic surgery are summarized in **Table 1** given below [65, 67–73].

Authors, year, reference	NMB design	Relevant results concerning surgical
Type of surgery, n	Method of evaluation	conditions
Bertrand et al. (1983) [67]	Succinylcholine 1 mg kg ⁻¹ + infusion or	Better muscle relaxation, less supplemental
Various gynecological lap,	vecuronium 0.05–0.06–0.07 mg kg ⁻¹	vecuronium and less IAP with
n = 40	SRS 4 grades	succinylcholine or 0.07 mg kg ⁻¹
		vecuronium.
Swann et al. (1993) [68]	Atracurium 0.3 mg kg ⁻¹ (TT) versus no	Two poor conditions in the no NMB group
Various gynecological lap,	NMB (LMA).	(vs 0 in Atracurium group), but concluded
n = 60	SRS 3 grades	as not clinically different.

Authors, year, reference	NMB design	Relevant results concerning surgical conditions
Type of surgery, n	Method of evaluation	
Chassard et al. (1996) [69]	Atracurium 0.25 mg kg ⁻¹ + boluses to maintain T1 < 10% versus no NMB.	The operating conditions were not influenced by NMB.
Various gynecological lap, n = 50	SRS 4 grades	
Williams et al. (2003) [70]	Atracurium 0.5 mg/kg (TT) supplemented as required, versus no NMB (LMA).	Better adequacy of pneumoperitoneum with NMB; 28% inadequate trocar insertion in the no NMB group
Day case gynecological lap, n = 40	SRS 4 grades	
Paek et al. (2009) [71]	Rocuronium 0.6 mg kg ⁻¹ + 0.15 mg kg ⁻¹ boluses to maintain TOF count ≤ 2 versus no additional bolus.	No coughing, bucking or movement during procedures.
Pelvic laparoscopy, n = 56	Events, IAP	No supplemental NMBA required during propofol remifentanyl anesthesia.
Chen et al. (2013) [72]	Rocuronium 0.6 mg kg ⁻¹ versus no NMB. LMA in all cases.	Comparable surgical conditions. No benefit of NMB during anesthesia with LMA.
Gynecological lap, n = 120	Surgeon's questionnaire	
Dubois et al. (2014) [65]	Rocuronium 0.6 mg kg ⁻¹ + 5 mg boluses to maintain TOF count ≤ 2 versus shallower NMB.	Deep NMB provided better (excellent) surgical conditions when TOF count = 0 and prevented unacceptable conditions (28% in shallow NMB).
Lap hysterectomy, n = 100	SRS 4 grades	
Madsen et al. (2015) [73]	Rocuronium 1 mg kg ⁻¹ deep NMB versus no NMB.	Slightly improved workspace and better conditions during suturing of the fascia with deep NMB.
Gynecologic lap, n = 14	SRS 4 grades	
	Distance from sacral promontory to the trocar	

Table 1. Studies investigating the interest of neuromuscular blockade during gynecological laparoscopic surgery.

Overall, there is good evidence that NMB optimizes surgical conditions in gynecological laparoscopy. This was also true during laparoscopic prostatectomy and nephrectomy. Deep NMB seems superior to moderate NMB [61, 74, 75].

In addition, when compared to moderate NMB (or no NMB) during upper abdominal laparoscopy, deep NMB marginally optimizes surgical conditions and allows the IAB pressure to be reduced by 3–5 mmHg without compromising surgical conditions [61, 76].

It seems useful to establish a deep NMB from the beginning of the procedure instead of waiting for the surgeon to request it [46]. The main problem is the residual block at the end of surgery and the time needed to recover before being able to extubate the patient. This issue is addressed in the following section.

5. The residual neuromuscular blockade after surgery

Any administration of a NMBA during general anesthesia carries the risk of residual effects after surgery. This becomes inevitable when maintaining the NMB deep until the end of the surgical procedure. Based on numerous studies, postoperative residual NMB is defined as a TOF ratio <0.9 [77, 78]. Its incidence when arriving in the post-anesthesia care unit (PACU) is estimated to be approximately 40% of the patients who received NMBA in clinical practice. Residual NMB has clinical consequences and complications that can prolong hospitalization. Before reaching the safety threshold of TOF ratio >0.9 , the most frequent adverse events include patient anxiety, upper airway collapse because of the high sensitivity of pharyngeal muscles to NMBA [79], hypoxia because of the decreased sensitivity of chemoreceptors [80], and dysphagia and reduced protection against aspiration increasing the risk of postoperative pneumonia [81]. For these reasons, guidelines should be observed to rule out any level of residual NMB before awakening and extubating the patient. Current recommendations are to use short- or intermediate-acting NMBAs, to routinely reverse all NMB, and to monitor neuromuscular transmission whenever relaxants are used, especially before and after NMB reversal [82–84]. By decreasing the incidence of the residual NMB in the PACU, patient safety is improved, as is demonstrated by the reduction in postoperative respiratory complications [85].

5.1. Quantitative neuromuscular transmission monitoring in daily practice

The use of neuromuscular transmission (NMT) monitoring is mandatory to manage deep NMB and to determine the threshold for the administration of the appropriate doses of reversal agents and, finally, to confirm their effect until attaining a TOF ratio >0.9 . Unfortunately, visual or manual evaluation of the contraction intensity induced by the nerve stimulation does not allow for the effective quantification of the relative force of the successive muscular responses and, consequently, lacks accuracy and cannot exclude significant levels of residual NMB [86]. The recommendation is to use objective measures to confirm NMB recovery at a minimum of a TOF ratio of 0.9 before extubating the patient [83]. Measurements obtained by recording techniques (i.e., the application of custom sensors) using the principles of acceleromyography, kinemyography, or electromyography have proved their effectiveness, with some specific precautions [82, 87–89]. Implementing these quantitative monitors to manage every NMBA administration in daily practice demonstrated a reduction in the residual NMB incidence to a very low level [90].

5.2. Pharmacological reversal of the residual NMB

- Neostigmine antagonizes a non-depolarizing NMB by increasing the availability of acetylcholine (ACh) in the synaptic cleft, tipping the competitive balance in favor of the neurotransmitter primarily by inactivating the acetylcholinesterases at the muscle endplate (**Figure 4a**).

Administered routinely at the end of anesthesia, neostigmine has demonstrated a positive effect on postoperative mortality [91]. Beyond this favorable overall trend, the effectiveness of NMB reversal with neostigmine is limited by several specific problems.

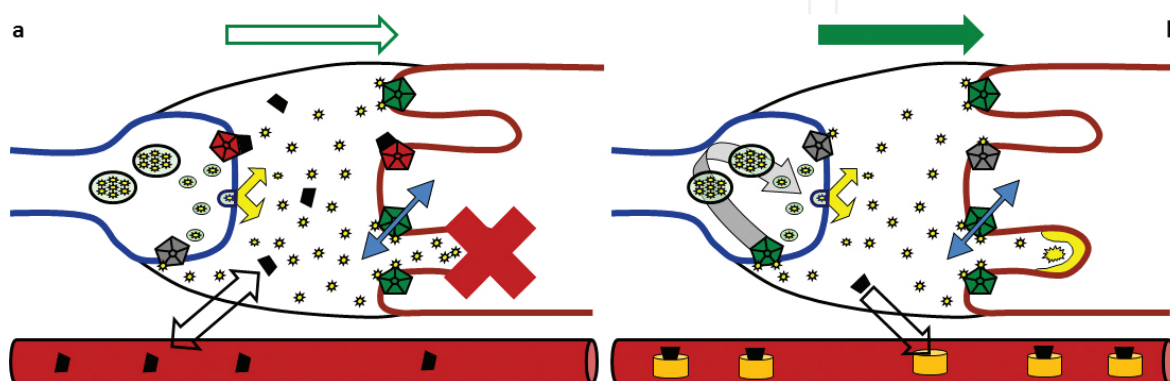


Figure 4. Reversal agents. (a) Neostigmine inhibits cholinesterase making more acetylcholine available in the synaptic cleft. The competitive block evolves in favor of the acetylcholine and neuromuscular transmission increases gradually. Neuromuscular blocking agents still present are progressively eliminated according to their pharmacokinetic properties. (b) Sugammadex encapsulates rocuronium in the plasma, washing the synaptic cleft of all neuromuscular blocking agents for good. Normal neuromuscular transmission recovers rapidly.

Even the maximal recommended dose of 70 $\mu\text{g/kg}$ (or 5 mg) has limited effects and cannot effectively reverse deep levels of NMB [92]. Neostigmine can only be administered from a moderate block with a minimum TOF of 3 to increase efficacy and safety [93, 94]. Moreover, the delay needed for reversal with neostigmine (10–15 min on average) has a large interindividual variability. Patients might need more than 60 min to reach a TOF ratio of 0.9 [95]. The problem is that most anesthesiologists will not wait long enough before extubating their patients. Consequently, even when routinely administered, neostigmine is frequently insufficient to completely reverse the residual NMB at the time of tracheal extubation [96]. The risk of residual blockade without quantitative NMT monitors is significant. Even when using a peripheral nerve stimulator with subjective (visual or tactile) evaluation, more than 50% of the patients could experience residual NMB after the administration of neostigmine [97]. Then, only the proper use of neostigmine guided by NMT monitors can help eliminate postoperative respiratory complications associated with the use of NMBA [82, 83, 98].

Because neostigmine is an acetylcholinesterase inhibitor, it induces ACh stimulation on muscarinic receptors in smooth muscles, the heart and various glands and nicotinic receptors in the autonomic ganglia, which induce adverse side effects including postoperative nausea and/or vomiting, bradycardia, prolonged QT interval, unpredictable bronchoconstriction, ptialism, and increased intraluminal pressure and propulsive activity in the bowels [99]. To

prevent some of these side effects, parasympatholytic drugs (atropine or glycopyrrolate) are administered simultaneously. These compounds are also accompanied by potential secondary effects (i.e., tachycardia, urinary retention, accommodation disorders, and dry mouth).

Because of the limited ability of anticholinesterases to antagonize deep NMB, most clinicians wisely attempt to avoid deep block as the end of surgery approaches, exposing the surgeon and the patient to impaired surgical conditions. But recently with the availability of sugammadex as an alternative to neostigmine, there has been renewed interest in other potential indications for the intraoperative maintenance of deep NMB, especially for laparoscopic surgery [31].

- Sugammadex is a selective relaxant-binding agent [100]. The modified gamma-cyclodextrin encapsulates the steroidal NMBA rocuronium or vecuronium present in the plasma and the neuromuscular synaptic cleft. The concentration of the free steroidal NMBA is rapidly reduced. The nicotinic receptors again become available to ACh, and the NMB fades rapidly (**Figure 4b**). The steroidal NMBA-sugammadex complexes remain bound until they are excreted by the kidneys. Because of the molecular selectivity for steroidal NMBA, sugammadex has no effect on the benzylisoquinolines (atracurium, cisatracurium, and mivacurium).

Different doses of sugammadex have been determined to guarantee effective reversal according to the depth of the NMB (according to the plasma concentration of the steroidal NMBA) [101]. A dose of 4 mg/kg is indicated to reverse deep NMB within a few minutes (**Figure 5**). It is not only much faster and more predictable than neostigmine, but it is also able to reverse all depths of blockades [95, 101]. In addition, sugammadex has an excellent clinical tolerance, few side effects, and it is beneficial for numerous categories of patients who are at a particular risk for developing complications from residual NMB or for undesirable effects from neostigmine [45, 101].

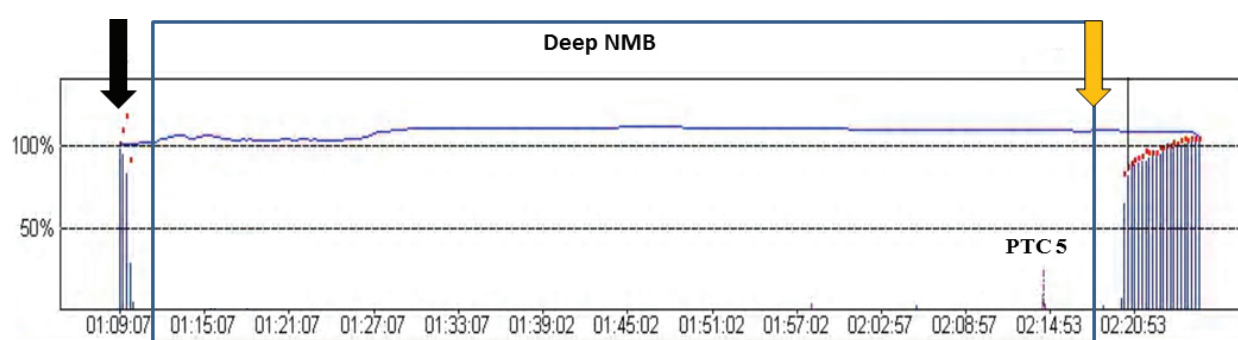


Figure 5. Deep NMB during the entire laparoscopic procedure. Following rocuronium administration (*black arrow*), a deep neuromuscular blockade is maintained until the end of surgery. Then, sugammadex (*orange arrow*) allowed for a fast and complete reversal.

As an innovative drug, sugammadex is expensive when compared with most drugs used in anesthesia. Intraoperative maintenance of deep NMB and sugammadex reversal have important economic repercussions that could call into question the routine use of deep NMB for

laparoscopic surgery [60]. On the other hand, every minute of open operating theater time has a high financial value [102]. A few minutes spared with a faster and more predictable reversal strategy allowing for a shorter operating room discharge can balance the cost of the new drug and contribute to optimization of operating theater turnover and overall financial return [103].

6. Conclusion

The introduction of sugammadex into clinical practice provides the opportunity to modify the management of NMB to improve the surgical conditions during laparoscopy as well as the safety of the patients. The maintenance of a deep rocuronium induced NMB from the trocar insertion until the end of laparoscopy is no longer incompatible with rapid recovery and awakening in optimal conditions. In all cases, NMT monitoring is the key to adequate NMB management. Objective measurements allow for excellent intubation and surgical conditions, the definition of thresholds and doses for the administration of reversal agents, and the exclusion of residual NMB prior to the patient extubation.

Author details

Christophe Dransart, Laurie Putz, Maria-Laura Marotta and Philippe E. Dubois*

*Address all correspondence to: phil.dubois@uclouvain.be

CHU UCL Namur, Yvoir, Belgium

References

- [1] Hatzinger M et al. Hans Christian Jacobaeus: inventor of human laparoscopy and thoracoscopy. *J Endourol* 2006; 20: 848–850.
- [2] Litynski GS. Raoul Palmer, World War II, and transabdominal coelioscopy. *Laparoscopy extends into gynecology. JSLS* 1997; 1: 289–92.
- [3] Hurd W et al. “Gynecologic Laparoscopy”; Medscape: <http://emedicine.medscape.com/article/265201>; updated in 28 December 2015.
- [4] Bosteels J et al. The effectiveness of reproductive surgery in the treatment of female infertility: facts, views and vision. *Facts Views Vis Obgyn* 2010; 2: 232–52.
- [5] Bosteels J et al. The position of diagnostic laparoscopy in current fertility practice. *Hum Reprod Update* 2007; 13: 477–85.

- [6] Practice Committee of the American Society for Reproductive Medicine. Diagnostic evaluation of the infertile female: a committee opinion. *Fertil Steril* 2015; 103: 44–50.
- [7] Practice Committee of the American Society for Reproductive Medicine. Role of tubal surgery in the era of assisted reproductive technology: a committee opinion. *Fertil Steril* 2015; 103: 37–43.
- [8] Gala RB, Society of Gynecologic Surgeons Systematic Review Group. Systematic review of robotic surgery in gynecology: robotic techniques compared with laparoscopy and laparotomy. *J Minim Invasive Gynecol* 2014; 21: 353–61.
- [9] Kim SM et al. Abdominal, multi-port and single-port total laparoscopic hysterectomy: eleven-year trends comparison of surgical outcomes complications of 936 cases. *Arch Gynecol Obstet* 2015; 291: 1313–9.
- [10] Zhao M et al. Single-incision multiport laparoscopy versus multichannel-tipped single port laparoscopy in gynecologic surgery: outcomes and benefits. *Int J Clin Exp Med* 2015; 8: 14992–8.
- [11] Park JY et al. Laparoendoscopic single-site compared with conventional laparoscopic ovarian cystectomy for ovarian endometrioma. *J Minim Invasive Gynecol* 2015; 22: 813–9.
- [12] Donnez J, Dolmans MM. Uterine fibroid management: from the present to the future. *Hum Reprod Update*. 2016 Jul 27. [Epub ahead of print]
- [13] Malbrain M, De Laet I, De Waele J et al. The role of abdominal compliance, the neglected parameter in critically ill patients—a consensus review of 16. Part 2: measurement techniques and management recommendations. *Anaesthesiol Intensive Ther* 2014; 46: 406–32.
- [14] Mulier J, Dillemans B, Van Cauwenberge S. Impact of the patient's body position on the intraabdominal workspace during laparoscopic surgery. *Surg Endosc*. 2010; 24: 1398–1402.
- [15] Mulier J, Dillemans B, Crombach M et al. On the abdominal pressure volume relationship. *Internet J Anesthesiol* 2008; 21 :1–7.
- [16] Hypolito OH et al. Creation of pneumoperitoneum: noninvasive monitoring of clinical effects of elevated intraperitoneal pressure for the insertion of the first trocar. *Surg Endosc* 2010; 24: 1663–1669.
- [17] Özdemir-van Brunschot D et al. What is the evidence for the use of low-pressure pneumoperitoneum? A systematic review. *Surg Endosc* 2016; 30: 2049–2065.
- [18] Strang CM, Freden F, Maripuu E et al. Improved ventilation-perfusion matching with increasing abdominal pressure during CO₂-pneumoperitoneum in pigs. *Acta Anaesthesiol Scand* 2011; 55: 887–96.

- [19] Dexter SP, Vucevic M, Gibson J, McMahon MJ. Hemodynamic consequences of high- and low-pressure capnoperitoneum during laparoscopic cholecystectomy. *Surg Endosc* 1999; 13: 376–81.
- [20] Matsuzaki S et al. Impact of intraperitoneal pressure of a CO₂ pneumoperitoneum on the surgical peritoneal environment. *Hum Reprod* 2012; 27: 1613–1623.
- [21] Schietroma M et al. Changes in the blood coagulation, fibrinolysis, and cytokine profile during laparoscopic and open cholecystectomy. *Surg Endosc* 2004; 18: 1090–1096.
- [22] Gurusamy KS, Samraj K, Davidson BR. Low pressure versus standard pressure pneumoperitoneum in laparoscopic cholecystectomy. *Cochrane Database Syst Rev* 2009; 2: CD006930.
- [23] Barczyński M, Herman RM. A prospective randomized trial on comparison of low-pressure (LP) and standard-pressure (SP) pneumoperitoneum for laparoscopic cholecystectomy. *Surg Endosc* 2003; 17: 533–8.
- [24] Joshipura VP, Haribhakti SP, Patel N et al. A prospective randomized, controlled study comparing low pressure versus high pressure pneumoperitoneum during laparoscopic cholecystectomy. *Surg Laparosc Endosc Percutan Tech* 2009; 19: 234–40.
- [25] Sarli L, Costi R, Sansebastiano G, Trivelli M, Roncoroni L. Prospective randomized trial of low-pressure pneumoperitoneum for reduction of shoulder-tip pain following laparoscopy. *Br J Surg* 2000; 87: 1161–5.
- [26] Kandil TS, El Hefnawy E. Shoulder pain following laparoscopic cholecystectomy: factors affecting the incidence and severity. *J Laparoendosc Adv Surg Tech* 2010; 20: 677–82.
- [27] Yasir M, Mehta KS, Banday VH et al. Evaluation of postoperative shoulder tip pain in low pressure versus standard pressure pneumoperitoneum during laparoscopic cholecystectomy. *Surgeon* 2012; 10: 71–4.
- [28] Bogani G et al. Low vs standard pneumoperitoneum pressure during laparoscopic hysterectomy: prospective randomized trial. *J Minim Invasive Gynecol* 2014; 21: 466–471.
- [29] Topcu HO et al. A prospective randomized trial of postoperative pain following different insufflation pressures during gynecologic laparoscopy. *Eur J Obstet Gynecol Reprod Biol* 2014; 182: 81–85.
- [30] Radosa JC, Radosa MP, Mavrova R et al. Five minutes of extended assisted ventilation with an open umbilical trocar valve significantly reduces postoperative abdominal and shoulder pain in patients undergoing laparoscopic hysterectomy. *Eur J Obstet Gynecol Reprod Biol* 2013; 171: 122–7.
- [31] Kopman A, Naguib M. Laparoscopic surgery and muscle relaxants: is deep block helpful? *Anesth Analg*. 2015; 120: 51–58.

- [32] Hua J, Gong J, Yao L, Zhou B, Song Z. Low-pressure versus standard-pressure pneumoperitoneum for laparoscopic cholecystectomy: a systematic review and meta-analysis. *Am J Surg* 2014; 208: 143–50.
- [33] Mouton WG, Bessell JR, Otten KT, Maddern GJ. Pain after laparoscopy. *Surg Endosc* 1999; 13: 445–8.
- [34] Donatsky AM, Bjerrum F, Gogenur I. Surgical techniques to minimize shoulder pain after laparoscopic cholecystectomy. A systematic review. *Surg Endosc* 2013; 27: 2275–2282.
- [35] Vijayaraghavan N, Sistla SC, Kundra P et al. Comparison of standard-pressure and low-pressure pneumoperitoneum in laparoscopic cholecystectomy: a double blinded randomized controlled study. *Surg Laparosc Endosc Percutan Tech* 2014; 24: 127–33.
- [36] Gurusamy KS, Vaughan J, Davidson BR. Low pressure versus standard pressure pneumoperitoneum in laparoscopic cholecystectomy. *Cochrane Database Syst Rev* 2014; (3): CD006930.
- [37] Warlé MC, Berkens AW, Langenhuijsen JF et al. Low-pressure pneumoperitoneum during laparoscopic donor nephrectomy to optimize live donors' comfort. *Clin Transplant* 2013; 27: E478–83.
- [38] Cravello L et al. Laparoscopic surgery in gynecology: randomized prospective study comparing pneumoperitoneum and abdominal wall suspension. *Eur J Obstet Gynecol Reprod Biol* 1999; 83: 9–14.
- [39] Neudecker J et al. The European Association for Endoscopic Surgery clinical practice guideline on the pneumoperitoneum for laparoscopic surgery. *Surg Endosc* 2002; 16: 1121–1143.
- [40] Staehr-Rye A, Rasmussen L, Rosenberg J et al. Surgical space conditions during low-pressure laparoscopic cholecystectomy with deep versus moderate neuromuscular blockade: a randomized clinical study. *Anesthesia Analgesia* 2014; 119: 1084–92.
- [41] Griffith HR, Johnson GE. The use of curare in general anesthesia. *Anesthesiology* 1942; 3: 418–420.
- [42] Gray TC, Halton J. Technique for the use of d-tubocurarine chloride with balanced anaesthesia. *BMJ* 1946; 2: 293–295.
- [43] Beecher HK, Todd DP. A study of the deaths associated with anesthesia and surgery. *Ann Surg* 1954; 140: 2–34.
- [44] Mencke T, Echternach M, Kleinschmidt S et al. Laryngeal morbidity and quality of tracheal intubation: a randomized controlled trial. *Anesthesiology* 2003; 98: 1049–56.
- [45] Dubois PE, Mulier JP. A review of the interest of sugammadex for deep neuromuscular blockade management in Belgium. *Acta Anaesthesiol Belg* 2013; 64: 49–60.

- [46] Madsen M, Staehr-Rye A, Claudius C, Gatke M. Is deep neuromuscular blockade beneficial in laparoscopic surgery? Yes, probably. *Acta Anaesthesiol Scand* 2016; 60: 710–6.
- [47] Fagerlund MJ, Eriksson LI. Current concept in neuromuscular transmission. *Br J Anaesth* 2009; 103: 108–14.
- [48] Fuchs-Buder T, Claudius C, Skovgaard LT et al. Good clinical research practice in pharmacodynamic studies of neuromuscular blocking agents II: the Stockholm revision. *Acta Anaesthesiol Scand* 2007; 51:789–808.
- [49] Ali HH, Utting JE, Gray C. Stimulus frequency in the detection of neuromuscular block in humans. *Br J Anaesth* 1970; 42: 967–78.
- [50] Viby-Mogensen J et al. Posttetanic count (PTC): a new method of evaluating an intense nondepolarizing neuromuscular blockade. *Anesthesiology* 1981; 55: 458–61.
- [51] Naguib M, Kopman AF, Lien CA et al. A survey of current management of neuromuscular block in the United States and Europe. *Anesth Analg* 2010; 111: 11–9.
- [52] Meistelman C, Plaud B, Donati F. Rocuronium neuromuscular blockade at the adductor muscles of the larynx and adductor pollicis in humans. *Can J Anaesth* 1992; 39: 665–9.
- [53] Hemmerling TM, Donati F. Neuromuscular blockade at the larynx, the diaphragm and the corrugator supercilii muscle: a review. *Can J Anaesth* 2003; 50: 779–94.
- [54] Cantineau JP, Porte F, d'Honneur G, Duvaldestin P. Neuromuscular effects of rocuronium on the diaphragm and adductor pollicis muscles in anesthetized patients. *Anesthesiology* 1994; 81: 585–90.
- [55] Kirov K, Motamed C, Dhonneur G. Differential sensitivity of abdominal muscles and the diaphragm to mivacurium: an electromyographic study. *Anesthesiology* 2001; 95: 1323–8.
- [56] Moerer O, Baller C, Hinz J et al. Neuromuscular effects of rapacuronium on the diaphragm and skeletal muscles in anaesthetized patients using cervical magnetic stimulation for stimulating the phrenic nerves. *Eur J Anaesthesiol* 2002; 19: 883–7.
- [57] Fernando PU, Viby-Mogensen J, Bonsu AK et al. Relationship between posttetanic count and response to carinal stimulation during vecuronium-induced neuromuscular blockade. *Acta Anaesthesiol Scand* 1987; 31: 593–6.
- [58] Dhonneur G, Kirov K, Motamed C et al. Post-tetanic count at adductor pollicis is a better indicator of early diaphragmatic recovery than train-of-four count at corrugator supercilii. *Br J Anaesth* 2007; 99: 376–379.
- [59] Myles PS, Leslie K, McNeil J et al. Bispectral index monitoring to prevent awareness during anaesthesia: the B-Aware randomised controlled trial. *Lancet* 2004; 363: 1757–63.

- [60] Kopman AF, Naguib M. Is deep neuromuscular block beneficial in laparoscopic surgery? No, probably not. *Acta Anaesthesiol Scand* 2016; 60: 717–22.
- [61] Madsen M, Staehr-Rye AK, Gätke MR, Claudius C. Neuromuscular blockade for optimising surgical conditions during abdominal and gynaecological surgery: a systematic review. *Acta Anaesthesiol Scand* 2015; 59: 1–16.
- [62] Mourtua MA, Deogaonkar A, Bakri MH et al. Dosing of remifentanyl to prevent movement during craniotomy in the absence of neuromuscular blockade. *J Neurosurg Anesthesiol* 2008; 20: 221–5.
- [63] Green RS, Edwards J, Sabri E, Fergusson D. Evaluation of the incidence, risk factors, and impact on patient outcomes of postintubation hemodynamic instability. *CJEM* 2012; 14: 74–82.
- [64] Blobner M, Frick CG, Stäuble RB et al. Neuromuscular blockade improves surgical conditions. *Surg Endosc* 2015; 29: 627–36.
- [65] Dubois PE, Putz L, Jamart J et al. Deep neuromuscular block improves surgical conditions during laparoscopic hysterectomy: a randomised controlled trial. *Eur J Anaesthesiol* 2014; 31: 1–7.
- [66] Ahmad G, O'Flynn H, Duffy JM, Phillips K, Watson A. Laparoscopic entry techniques. *Cochrane Database Syst Rev* 2012; 2: CD006583.
- [67] Bertrand M, Lienhart A, Daloz M et al. Clinical use of vecuronium during celioscopy. *Ann Fr Anesth Reanim* 1983; 2: 27–31.
- [68] Swann DG, Spens H, Edwards SA, Chestnut RJ. Anaesthesia for gynaecological laparoscopy -a comparison between the laryngeal mask airway and tracheal intubation. *Anaesthesia* 1993; 48: 431–434.
- [69] Chassard D, Bryssine B, Golfier F et al. Gynecologic laparoscopy with or without curare. *Ann Fr Anesth Reanim* 1996; 15: 1013–1017.
- [70] Williams MT, Rice I, Ewen SP, Elliott SM. A comparison of the effect of two anaesthetic techniques on surgical conditions during gynaecological laparoscopy. *Anaesthesia* 2003; 58: 574–578.
- [71] Paek CM, Yi JW, Lee BJ, Kang JM. No supplemental muscle relaxants are required during propofol and remifentanyl total intravenous anesthesia for laparoscopic pelvic surgery. *J Laparoendosc Adv Surg Tech A* 2009; 19: 33–7.
- [72] Chen BZ, Tan L, Zhang L, Shang YC. Is muscle relaxant necessary in patients undergoing laparoscopic gynecological surgery with a ProSeal LMA? *J Clin Anesth* 2013; 25: 32–35.
- [73] Madsen MV, Gätke MR, Springborg HH et al. Optimising abdominal space with deep neuromuscular blockade in gynaecologic laparoscopy– a randomised blinded cross-over study. *Acta Anaesthesiol Scand* 2015; 59: 441–7.

- [74] Martini CH, Boon M, Bevers RF et al. Evaluation of surgical conditions during laparoscopic surgery in patients with moderate vs deep neuromuscular block. *Br J Anaesth* 2014; 112: 498–505.
- [75] Dubois PE. TOF count 0 ensured optimal surgical conditions during laparoscopic hysterectomy. *Eur J Anaesthesiol*. 2015; 32: 65–6.
- [76] Van Wijk RM, Watts RW, Ledowski T, Trochsler M, Moran JL, Arenas GWN. Deep neuromuscular block reduces intra-abdominal pressure requirements during laparoscopic cholecystectomy: a prospective observational study. *Acta Anaesthesiol Scand* 2015; 59: 434–40.
- [77] Plaud B et al. Residual paralysis after emergence from anaesthesia. *Anesthesiology* 2010; 112: 1013–2.
- [78] Murphy GS, Brull SJ. Residual neuromuscular block: lessons unlearned. Part I: definitions, incidence, and adverse physiologic effects of residual neuromuscular block. *Anesth Analg* 2010; 111: 120–8.
- [79] Eriksson LI et al. Functionnal assessment of the pharynx at rest and during swallowing in partially paralysed humans. *Anesthesiology* 1997; 87: 1035–43.
- [80] Eriksson LI et al. Attenuated ventilatory response to hypoxemia at vecuronium-induced partial neuromuscular block. *Acta Anaesthesiol Scand* 1992; 36: 710–5.
- [81] Berg H, Viby-Mogensen J et al. Residual neuromuscular block is a risk factor for postoperative pulmonary complications. *Acta Anaesthesiol Scand* 1997; 41: 1095–1103.
- [82] Murphy GS, Brull SJ. Residual neuromuscular block: lessons unlearned. Part II: methods to reduce the risk of residual weakness. *Anesth Analg* 2010; 111: 129–40.
- [83] Viby-Mogensen J, Claudius C. Evidence-based management of neuromuscular Block. *Anesth Analg* 2010; 111: 1–2.
- [84] Miller RD, Ward TA. Monitoring and pharmacologic reversal of a nondepolarizing neuromuscular blockade should be routine. *Anesth Analg* 2010; 111: 3–5.
- [85] Murphy GS, Szokol JW, Avram MJ et al. Intraoperative acceleromyography monitoring reduces symptoms of muscle weakness and improves quality of recovery in the early postoperative period. *Anesthesiology* 2011; 115: 946–54.
- [86] Cammu G, De Witte J, De Veylder J et al. Postoperative residual paralysis in outpatients versus inpatients. *Anesth Analg* 2006; 102: 426–9.
- [87] Claudius C, Viby-Mogensen J. Acceleromyography for use in scientific and clinical practice. A systematic review of the evidence. *Anesthesiology* 2008; 108: 1117–40.
- [88] Murphy GS, Szokol JW, Marymont JH et al. Intraoperative acceleromyographic monitoring reduces the risk of residual neuromuscular blockade and adverse respiratory events in the postanesthesia care unit. *Anesthesiology* 2008; 109: 389–99.

- [89] Dubois PE, De Bel M, Jamart J et al. Performance of acceleromyography with a short and light TOF-tube compared with mechanomyography. A clinical comparison. *Eur J Anaesthesiol.* 2014; 31: 404–10.
- [90] Baillard et al. Postoperative residual neuromuscular block: a survey of management. *Br J Anaesth* 2005; 95: 622–6.
- [91] Arbous MS, Meursing AE, van Kleef JW et al. Impact of anesthesia management characteristics on severe morbidity and mortality. *Anesthesiology* 2005; 102: 257–68.
- [92] Bartkowsky RR. Incomplete reversal of pancuronium neuromuscular blockade by neostigmine, pyridostigmine and edrophonium. *Anesth Analg* 1987; 66: 594–598.
- [93] Kirkegaard H, Heier T, Caldwell JE. Efficacy of tactile-guided reversal from cisatracurium-induced neuromuscular block. *Anesthesiology* 2002; 96: 45–50.
- [94] Srivastava A, Hunter JM. Reversal of neuromuscular block. *Br J Anaesth* 2009; 103: 115–29.
- [95] Blobner M, Eriksson LI, Scholz J et al. Reversal of rocuronium-induced neuromuscular blockade with sugammadex compared with neostigmine during sevoflurane anaesthesia: results of a randomised, controlled trial. *Eur J Anaesthesiol* 2010; 27: 874–881.
- [96] Murphy GS, Szokol JW, Marymont JH et al. Residual paralysis at the time of tracheal extubation. *Anesth Analg* 2005; 100: 1840–5.
- [97] Fortier LP, McKeen D, Turner K et al. The RECITE study: a Canadian prospective, multicenter study of the incidence and severity of residual neuromuscular blockade. *Anesth Analg* 2015; 121: 366–72.
- [98] McLean DJ, Diaz-Gil D, Farhan HN et al. Dose-dependent association between intermediate-acting neuromuscular-blocking agents and postoperative respiratory complications. *Anesthesiology* 2015; 122: 1201–13.
- [99] Savarese JJ, Miller RD, Lien CA, Caldwell JE. Pharmacology of muscle relaxants and their antagonists. *Anesthesia*, Churchill Livingstone, New York, 4th edition; p 417–488, 1994.
- [100] Booij LH. Cyclodextrins and the emergence of sugammadex. *Anaesthesia* 2009; 64: 31–37.
- [101] Mirakhur RK. Sugammadex in clinical practice. *Anaesthesia* 2009; 64: 45–54.
- [102] Macario A. What does one minute of operating room time cost? *J Clin Anesth.* 2010; 22: 233–6.
- [103] Putz L, Dransart C, Jamart J et al. Operating room discharge after deep neuromuscular block reversed with sugammadex compared to shallow block reversed with neostigmine: A randomized controlled trial. Accepted in *J Clin Anesth* 2016.

