

# We are IntechOpen, the world's leading publisher of Open Access books Built by scientists, for scientists

6,900

Open access books available

185,000

International authors and editors

200M

Downloads

Our authors are among the

154

Countries delivered to

TOP 1%

most cited scientists

12.2%

Contributors from top 500 universities



WEB OF SCIENCE™

Selection of our books indexed in the Book Citation Index  
in Web of Science™ Core Collection (BKCI)

Interested in publishing with us?  
Contact [book.department@intechopen.com](mailto:book.department@intechopen.com)

Numbers displayed above are based on latest data collected.  
For more information visit [www.intechopen.com](http://www.intechopen.com)



---

# Diagnosis and Management of Rectosigmoid Perforations

---

Alper Yavuz, Çiğdem Hacifazlıoğlu, Gökhan Akkurt,  
Altan Aydın and Hakan Ataş

Additional information is available at the end of the chapter

<http://dx.doi.org/10.5772/64383>

---

## Abstract

Rectosigmoid colon, starting from the descending colon to the anus, having the peritoneal and retroperitoneal parts, is provided through the superior mesenteric artery and the inferior mesenteric artery. Many etiological reasons may be responsible for the perforation of the rectosigmoid colon, which may be usually perforated due to causes of iatrogenic and traumatic origins. The rectosigmoid perforations, which can be diagnosed preoperatively through examination, laboratory, and radiological examinations, may not be detected even in the intraoperative period sometimes. In its treatment, applications, such as conservative approaches, endoclip, laparoscopy, and open surgery, can be performed.

**Keywords:** rectum, sigmoid colon, perforation

---

## 1. Introduction

Rectosigmoid colon perforations are emergency surgery cases that general surgeons may encounter. Some intraperitoneal and retroperitoneal rectosigmoid colon cases develop out of sight away from the pelvis. It may be because of this that serious problems may be experienced in the diagnosis and treatment of the disease. These difficulties cause delayed diagnosis or no diagnosis at all. For this reason, discussing the diagnosis and treatment of rectosigmoid perforation under a separate heading can be important.

---

## 2. Sigmoid colon and rectum anatomy

The colon is a part of the gastrointestinal tract ranging between the ileocecal valve and the rectosigmoid junction. It consists of the cecum, ascending colon, transverse colon, descending colon, and the sigmoid colon in that order. The descending colon continues as sigmoid colon at crista iliac level. The sigmoid colon is divided into two sections as 'iliac part', located and constant in the left iliac region, and 'pelvic part', which is mobile. This structure has been named as such because it looks like letter 'S'. Although it varies from person to person, it ends at the third sacral vertebra level. While the iliac part does not have a mesentery, the pelvic part has a mesentery that looks like the Greek letter lambda ( $\Lambda$ ). The pelvic colon terminates in the rectosigmoid region, and superior rectal veins are located in the sigmoid colon mesentery. While the rectosigmoid compound serves as a functional sphincter, allowing transition of faeces to the rectum by opening up with sigmoid contractions, it prevents stool reflux by closing up during rectal contractions.

The sigmoid colon is the continuation of the descending colon and while its length is variable, it is usually 40 cm. The sigmoid colon, which follows an intraperitoneal course, is in close neighbourhood to the iliac artery and vein, ureter, bladder, uterus, sacral plexus, and the piriformis muscle. The rectum is part of the gastrointestinal system extending between the rectosigmoid junction and the anus and is about 13–15 cm long. The nourishment of the loops of the colon is supplied generally by two main vessels: the superior mesenteric artery (SMA) and the inferior mesenteric artery (IMA) originating from the abdominal aorta. The SMA, which provides nourishment to the small intestine, the cecum, the ascending colon, and the transverse colon, departs from the abdominal aorta right from underneath the celiac trunk, following its course downwards from the rear part of the pancreas and gives out the right colic, middle colic, and ileocolic branches into the colon mesentery. The inferior mesenteric artery (IMA) originating from the infrarenal aorta provides nourishment to the descending colon, the sigmoid colon, and the upper rectum. Major vascular anastomoses are involved in the circulation of the intestines. The vasa recta of the colon are formed by the anastomoses made peripherally between the ileocolic, right, middle, and left colic arteries and the marginal artery of Drummond. The arc of Riolo is described as the anastomosis between the left colic branch of the IMA and the middle colic branches of the SMA. The venous drainage of the colon and rectum is maintained in parallel with the arteries with the exception of the inferior mesenteric vein (IMV). The IMV progresses retroperitoneal behind the pancreas and flows into the splenic vein, allows the venous drainage of the descending colon, the sigmoid colon, and the upper rectum. Autonomic innervation is provided through pre-ganglionic and post-ganglionic sympathetic fibres and lumbar branches of sympathetic chain. The pre-ganglionic parasympathetic fibres are provided through pelvic splanchnic fibre, extending from the S2, S3, and S4 primer ventral ramus. It prevents stool reflux by closing up during contractions [1–3].

Rectum is a part of gastrointestinal system located between rectosigmoid compound and anus and approximately 13–15 cm long. Although there are disagreements between anatomists and surgeons on the identification of the rectosigmoid region, the region where

the sigmoid colon turns downwards at the level of promontorium, towards the sacrum concavity, is named as the rectosigmoid corner. Rectum descends down the sacrum concavity 13–15 cm, reaching 2–3 cm below the coccyx. At this level, passing through the levator muscles, it constitutes the anal canal of 3–4 cm long and terminates at the anus. There are also two different identifications of the anal canal: anatomical and surgical. While the anatomical anal canal is the region between the anal verge and the lineadentata, the surgical anal canal is the section of about 3–4 cm between the anal verge and the anorectal ring. Rectum is typically divided into three sections as the upper  $\frac{1}{3}$ , the medium  $\frac{1}{3}$ , and the lower  $\frac{1}{3}$  of the rectum. In practice, each section is calculated as about 5 cm. The anterior and lateral of the upper  $\frac{1}{3}$  of the rectum is covered with peritoneum. While the medium  $\frac{1}{3}$  of the rectum is covered with peritoneum on the anterior, the lower  $\frac{1}{3}$  of the rectum is below the peritoneal reflection. While the proximal and distal section of the rectum is convex to the right, its middle part is convex to the left. These folds extend towards the lumen as Houston valves, and usually, the middle valve of the Houston is on a line with anterior peritoneal reflection [4, 5]. The rectum descends down forward towards the sacrum concavity from the rectosigmoid junction onward, turns backwards in the direction of the rectum canal from about 2–3 cm below the coccyx, and going through the levator muscles and form the anal canal, ends at the anus. The blood flow to the rectum is maintained by three arteries. While the superior rectal artery that supplies blood flow to the upper and middle section of the rectum is rooted in the IMA, the middle rectal arteries branch out from the internal iliac arteries and the inferior rectal arteries branch out from the internal pudendal arteries. The middle sacral artery originating from the aortal bifurcation is responsible even if only for a little blood supply to the rectum. The venous drainage of the rectum follows the arteries like in the colon but differently from this, they flow into both the portal and the caval system. While the venous drainage of the upper and middle rectum flow into the portal system, that of the lower rectum and the anal canal flow into the caval system [2, 3]. The lymphatic vessels of the upper and middle rectum pour into inferior mesenteric nodes. The lymph flow coming from the lower rectum may also be lateral towards inferior and middle rectal arteries, posterior middle sacral artery, or anterior rectovesical or the canals in rectovaginal septum. While the anal canal lymphatics on the lineadentata pour into the superior rectal lymphatics and the inferior mesenteric lymph nodes, those below the lineadentata pour primarily into inguinal, superior, and inferior rectal lymph nodes. The rectum innervation consists of sympathetic and parasympathetic nerves. The sympathetic nerves taken from the thoracic columnar segment unite under the inferior mesenteric artery and form the inferior mesenteric plexus. The lower rectum, bladder and genital organs take their sympathetic innervation from the hypogastric nerves. The sacral third, fourth, and fifth parasympathetic nerves merge and are named as nerv-ierigentes. Combining with the hypogastric nerves at anterior and lateral of the rectum, they form the pelvic plexus. The internal anal sphincter is innervated by both sympathetic and parasympathetic nerves and the both are inhibitors. The external anal sphincter and the levator muscles are innervated by the inferior rectal branch of the internal pudendal nerve (S2, S3, and S4) and the perineal branch of the fourth sacral nerve [4, 5].

### 3. Epidemiology

There is not enough data in the literature on the incidence and prevalence of rectum or colon perforations. Studies have been traced especially on perforations occurring as a result of colonoscopic procedures and perforations developing after diverticulitis. While the incidence rate of perforations due to diverticular disease was observed to be around four in 100,000, it is 0.019–0.8% during diagnostic procedures following colonoscopy and 0.10–3% in therapeutic procedures [6, 7].

### 4. Aetiology and pathogenesis

Because several factors of a varying range are responsible in the aetiology of colon perforations, it is quite difficult to classify. However, colon perforations can be classified as follows according to their aetiologies:

1. Iatrogenic perforations
2. Traumatic perforations
3. Perforations due to malignant or diverticular disease
4. Stercoral perforation
5. Idiopathic perforations
6. Perforations that develop owing to other reasons

While in the past, barium enemas used to play an important role among the iatrogenic causes of colon perforations, today endoscopic and surgical interventions are more commonly observed in the aetiology. While perforation rates were high in diagnostic endoscopic procedures when endoscopic procedures were first put into application, these rates have decreased considerably today, thanks to technological developments and experience. However, with the development and frequent application of therapeutic (stent, excision, and clips) endoscopic procedures, a rise is being observed in perforation rates. When colon perforations following colonoscopy are evaluated according to their locations, they are most frequently observed at the rectosigmoid junction and the sigmoid colon with a rate of 52% followed by the cecum with 17%, ascending colon with 14% descending colon with 8%, transverse colon with 7%, and the rectum with around 1%. Colon injuries during endoscopic procedures usually occur on account of two main reasons. The first of these is mechanical-related injuries and the other is electrocautery-related injuries. Another reason for iatrogenic rectosigmoid injuries is surgical interventions [7–9]. While iatrogenic rectosigmoid perforations are commonly observed following the surgeries of branches such as General Surgery, Gynaecology, and Urology that deal frequently with the abdominal and pelvic regions, iatrogenic colon injuries are rarely observed in the surgeries of branches such as brain surgery and orthopaedics that deal with vertebrae and pelvic bone structures.

Traumatic rectosigmoid injuries develop as a result of direct or indirect traumas depending on how they occur. In indirect traumas, usually the injuring of the rectum by indirect means as a result of blunt or sharp abdominal traumas is observed. In direct traumas, injury occurs through the application of a foreign object or pressure to the rectum and sigmoid colon anally as is particularly seen in homosexuals. Direct traumas can also be observed in the form of the injuring of the colon and rectum by direct means such as receiving a blow to the anal region from a sharp object or firearms or falling on top of sharp objects.

Perforation cases of the rectum and sigmoid colon after malignant diseases or diverticular diseases are frequently observed in the literature. While in malignant diseases, they can be spontaneously perforated as a result of the progression of the tumour and they can also be iatrogenically perforated as a result of endoscopic procedures. Sigmoid colon perforation is observed quite frequently in diverticular diseases. As similar to malignant diseases, perforations in diverticular diseases can also occur spontaneously or iatrogenically as a result of endoscopic procedures [6].

Stercoral perforation, which was first described by Berry in the year 1894, is described as the development of necrosis and perforation on the intestinal wall due to the pressure effect of faecal mass [10]. In stercoral perforations, the area that is ulcerated due to the effect of pressure and the perforated area within this area should be pathologically confirmed. Despite the rare incidence of stercoral perforations, the fact that its distinction from other aetiological causes is not made adequately may lead to wrong diagnoses being made [11].

In the aetiology of rectosigmoid perforations, reasons other than the causes mentioned above, such as systemic lupus erythematosus and Behçet's disease, connective tissue diseases such as rheumatoid arthritis, and infectious conditions like cytomegalovirus do rarely lead to perforations. Among drugs, non-steroid inflammatory drugs and steroids are the drugs that most commonly lead to perforations. Despite such a wide range of aetiological agents being involved in the aetiology of rectosigmoid perforations, sometimes idiopathic perforation cases, the cause of which cannot be determined, are also observed [12–14].

## 5. Clinical picture

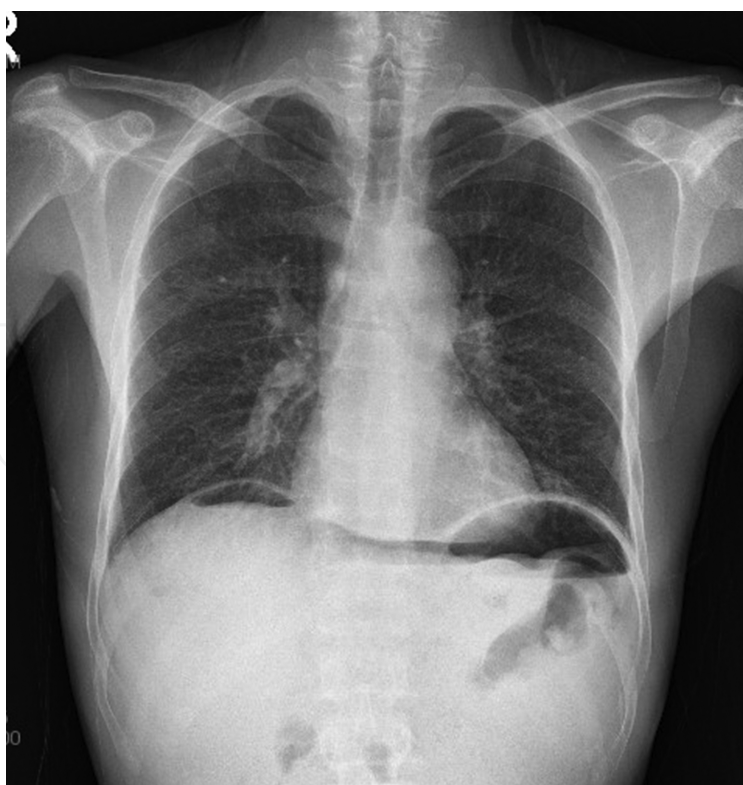
The clinical symptoms of rectosigmoid perforations may involve a wide spectrum. While no clinical symptom is observed in a small perforation with an extra peritoneal localisation, a large perforation with an intraperitoneal localisation can present very severe clinical symptoms. It is quite difficult to make a diagnosis so long as clinical symptoms, such as acute abdomen, rectal bleeding, and tenesmus, which are the clinical triad of colon perforations, are absent. Especially, complaints of pain in the epigastric region and duodenal or gastric ulcer in some cases can make diagnosis even more difficult or can lead to a misdiagnosis [14, 15]. The questioning of aetiological factors is very important in diagnosis. The taking of history, such as a recent colonoscopy, diagnosed diverticular, or malignant colorectal disease or anorectal trauma, can help make a diagnosis. Clinical examination can help in the diagnosis of rectosigmoid perforations. A careful abdominal and rectal examination is very important as a



clinical examination. Examination findings such as sensitivity, muscular rigidity, and rebound suggesting acute abdomen in the abdominal examination and rectal blood in the rectal examination or irregular intestinal wall structure suggestive of perforation in the palpation can help in making a diagnosis. Acute abdomen, pneumoperitoneum, or several disease groups that cause rectal complaints should be considered in the differential diagnosis of rectosigmoid perforations and patients should be scrutinised carefully and be examined.

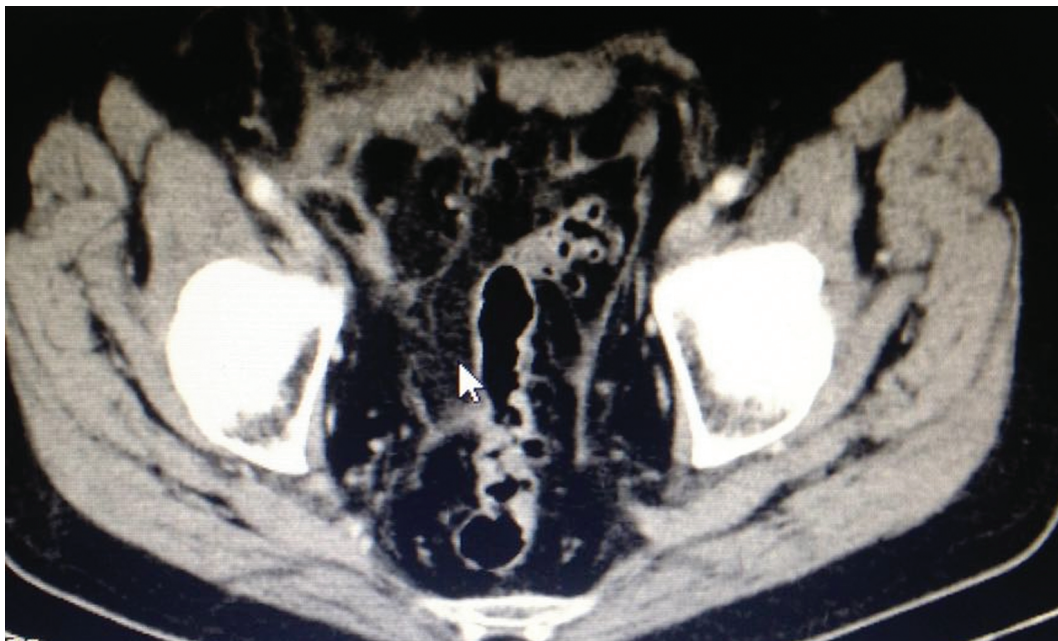## 6. Diagnosis

Because rectosigmoid perforations are life-threatening, they require early diagnosis and prompt surgical intervention. Diagnosis can usually be made with clinical findings. However, it may be difficult to clinically detect the location and cause of the perforation due to the symptoms not being specific. Clinical diagnosis can vary depending on conditions such as the size of the perforation, the colonic segment where perforation has taken place, the formation mechanism of the perforation, peritoneal contamination, and the underlying colonic pathology. Just as it can be asymptomatic, symptoms and findings can present at the moment of perforation or late. Generally speaking, perforation findings include general or localised abdominal pain, nausea/vomiting, fever, shortness of breath, and chest pain [16, 17].



**Figure 1.** Chest X-Ray showing collection of air in the right subdiaphragmatic space.

The basic question in imaging is revealing the location and the cause of perforation. The first choice in modality of imaging in patients with suspected perforation is direct radiography. In conventional radiography, observing free air inside the peritoneum indicates perforation, but the location and the cause of the perforation cannot be determined (**Figure 1**). Also, small amounts of air may not be detected in radiographies. For the findings of direct radiography to be normal does not exclude the possibility of perforation [16–19]. In the case of suspected perforation, an abdominal graphy and lung graphy are done standing or in the left lateral decubitus position. In the case of perforation, the free air outside the colon can move into the retroperitoneal region and cause subcutaneous emphysema in the scrotum, chest, axilla, and neck. In direct graphies, air beneath the diaphragm, retroperitoneal air, pneumomediastinum, pneumothorax, and subcutaneous air is investigated. Lateral graphies are more sensitive in detecting free air than PA graphies. In left lateral decubitus graphy, air between the liver and the abdominal wall can easily be discerned. In lateral chest graphy, air beneath the diaphragm can be clearly observed. In direct graphies, air inside the subhepatic and perihepatic spaces in the upper quadrant, in the Morrison pouch can be detected. The double wall appearance known as the Rigler sign, air under the central part of the diaphragm known as the Cupola sign and a large amount of air inside the peritoneal cavity known as the Football sign can be detected in direct radiographies [17, 18].



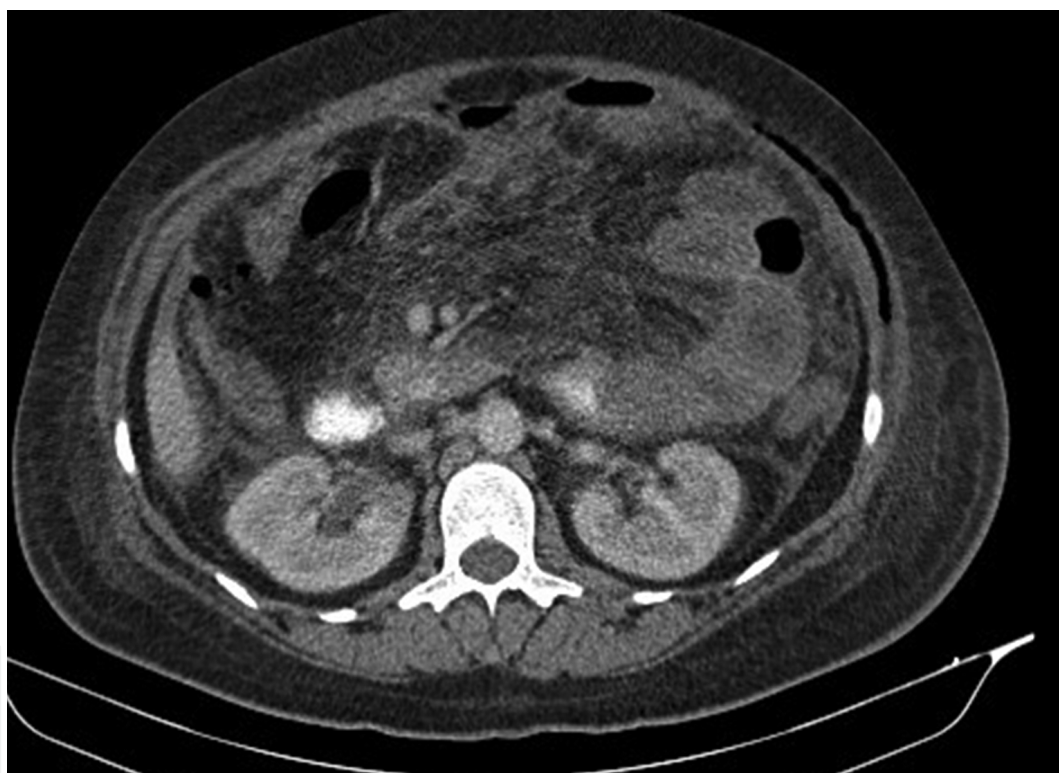**Figure 2.** Abdominal CT showing sigmoid diverticular disease and indirect signs of perforation (mesenteric contamination and heterogeneity).

The other method used in the diagnosis of perforation is ultrasonography. It provides fast and easy scanning. It does not include radiation and, therefore, can be preferred in children and in pregnant women. It can detect intraabdominal free or loculated fluid. Also, ultrasonography provides additional diagnostic information. There are studies which state that pneumoperitoneum can be detected with ultrasonography. However, there are also studies stating that it



is inadequate due to abdominal gas. For this reason, it has a low diagnostic value when compared with CT [19, 20].

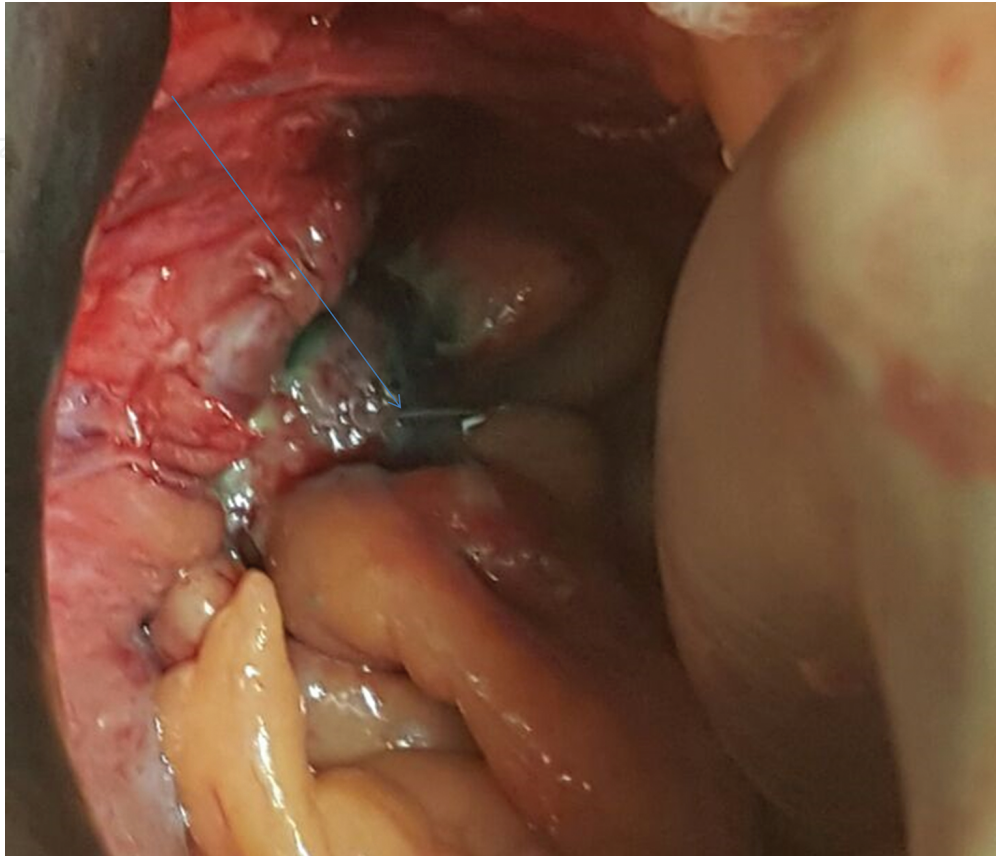
Directographies and ultrasonography, when compared with CT, are suboptimal in the evaluation of perforation. CT has been accepted as the best imaging method in revealing the presence, location, cause, and complications (such as phlegmon, abscesses, and peritonitis) of a perforation. Oral and IV contrast agents can be used. The entire abdomen from the pelvis to the upper section of the diaphragm can be scanned with thin slice thickness. The three-dimensional (3D) images can be obtained through multiplanar reconstructions. In the diagnosis of perforation, there are direct and indirect findings of CT (**Figures 2 and 3**). Extraluminal air and contrast agent and intestinal wall discontinuation are direct findings, whereas a phlegmon, abscess, or inflammatory mass related or unrelated to the intestinal wall are indirect findings [20, 21]



**Figure 3.** Abdominal CT showing the air in abdominal muscle because of close perforation of sigmoid colon.

The diagnosis of rectosigmoid perforations sometimes can be very difficult in the pre-operative period. In fact, sometimes perforations cannot be observed even intraoperatively. In case of presence of findings suggesting intestinal perforation (gas in the stomach and intestinal content) if perforation focuses cannot be observed, rectosigmoid perforations should be definitely investigated. In the first place, any perforation should be tried to be detected visually, and if no perforation is detected, the pelvic region should be filled with saline and gas bubbles that may come out through manipulation of rectosigmoid should be examined. If no perforation focuses are observed, it is not an indication of absence of perforation. For hidden and small

perforation focus, the rectum should be filled with methylene blue (about 250 cc) and possible leakage area should be investigated again by manipulating the rectosigmoid (**Figure 4**).



**Figure 4.** Microperforation only be demonstrated by the way given transanal methylene blue.

## 7. Treatment

A wide range of treatment options is available from a conservative treatment option to a wide intestinal resection and stoma in the treatment of rectosigmoid perforations. However, the real debate is what treatment will be applied to whom. The way the perforation occurred, its location, diameter, the condition of the intestines, the amount of time that passed after the perforation, the underlying disease, the level of intraabdominal contamination, and the clinical laboratory and radiological findings of the patient gives the physician insight on which treatment option will be applied.

The conservative treatment option is included among colon perforation treatment options due to it shortening the length of hospital stay and decreasing mortality rates. However, for conservative treatment, there must first be an appropriate patient selection and an intensive care unit that can provide adequate support in the unit where it will be applied and a radio-

logical unit must be present. Because these patients must be able to be monitored and given radiological examinations at any hour of the day when necessary [9, 22].

The form of treatment that is usually recommended for rectosigmoid perforations is immediate surgical intervention. The findings detected during the surgery provide guidance on the type of surgery. The form of surgery applied is usually the repairment of the perforation and resection of the perforated area. It is decided according to the level of contamination and the condition of the tissues whether a stoma will be done or not. In the case of more than 24 h having passed after the perforation and a perforation size of more than 2 cm, usually faecal diversion surgeries are recommended [23].

Just as with technological development is used in the treatment of several diseases, laparoscopy is also widely used in the treatment of rectosigmoid perforations. Several surgical techniques such as primary repair resection and faecal diversion which are performed in open surgeries can also be performed laparoscopically. Early return to work and reduced infection and pain are important advantages provided to patients by laparoscopy.

Another minimally invasive technique used in the treatment of rectosigmoid perforations is the repair of perforations with endoscopic approaches. The most commonly used method in this form of treatment is repair of the perforation with an endoscopic clip. In this form of treatment, the size of the perforation, and the experience of the endoscopist performing it are very important [24].

## 8. Conclusion

Rectosigmoid perforations are seen rarely. The most frequent causes in the aetiology are malignant or diverticular diseases and iatrogenic and traumatic perforations. Clinical examination is very important, but sometimes, diagnosis can be very difficult in spite of advanced assays. Non-invasive or minimal invasive procedures should be the first choice for the treatment, but the selection of a suitable case, of course, is very important.

## Author details

Alper Yavuz<sup>1\*</sup>, Çiğdem Hacifazlıoğlu<sup>2</sup>, Gökhan Akkurt<sup>1</sup>, Altan Aydın<sup>1</sup> and Hakan Ataş<sup>1</sup>

\*Address all correspondence to: alperyavuz@hotmail.com

1 General Surgery Department, Kecioren Research and Training Hospital, Ankara, Turkey

2 Radiology Department, Kecioren Research and Training Hospital, Ankara, Turkey

## References

- [1] Shafik A. Sigmoido-rectal junction reflex. Role in the defecation mechanism. *Clin Anat* 9:391–394, 1996.
- [2] Dunn KMB, Rothenberger DA. Chapter 29. Colon, Rectum, Anus. In: Brunicaardi F, Andersen DK, Billiar TR, Dunn DL, Hunter JG, Matthews JB, Pollock RE. eds. *Schwartz's Principles of Surgery*, 10e. New York, NY: McGraw-Hill; 2015.
- [3] Corman ML, Allison SI, Kuehne PJ. Chapter 1. Anatomy and Embryology of the Anus, Rectum and Colon. *Colon & Rectal Surgery*, Fourth Edition. (Ö. Alabaz, Aygen E, trans). Adana: Nobel Tıp Kitapevi; 2004.
- [4] Kodner IJ, Robert D. Colon, Rectum and Anus, *Principles of Surgery*, Schwartz. 1284 90, 1999.
- [5] Romolo J.L. Embryology and anatomy of the colon. *Shackelford's Surgery of the Alimentary Tract*, 4: 3–16, Philadelphia, 1996.
- [6] Morris CR, Harvey IM, Stebbings WS, Speakman CT, Kennedy HJ, Hart AR. Epidemiology of perforated colonic diverticular disease. *Postgrad Med J*. 2002;78:654–658.
- [7] Lohsiriwat V. Colonoscopic perforation: incidence, risk factors, management and outcome. *World J Gastroenterol*. 2010; 28:16:425–430.
- [8] Tam MS, Abbas MA. Perforation following colorectal endoscopy: what happens beyond the endoscopy suite?. *Perm J* 2013;17:17–21.
- [9] Cai SL, Chen T, Yao LQ, Zhong YS. Management of iatrogenic colorectal perforation: From surgery to endoscopy. *World J Gastrointest Endosc*. 2015;7:819–823.
- [10] Berry J. Dilatation and rupture of the sigmoid flexure. *Br Med J*. 1894;1:301.
- [11] Maurer CA, Renzulli P, Mazzucchelli L, Egger B, Seiler CA, Buchler MW. Use of accurate diagnostic criteria may increase incidence of stercoral perforation of the colon. *Dis Colon Rectum* 2000;43:991– 998.
- [12] Yaman İ, Kara C, Karabuğa T, Sözütek A, Tansuğ T, Bozdağ AD, Nazlı O. Nontravmatikkolonperforasyonlu hastaların klinik değerlendirilmesi ve tedavisi sonuçları. *Kolon Rektum Hast Derg* 2010; 20:11–18.
- [13] Tachikawa Y, Nozawa H, Tanaka J, Nishikawa T, Tanaka T, Kiyomatsu T, Hata K, Kawai K, Kazama S, Yamaguchi H, Ishihara S, Sunami E, Kitayama J, Fujisawa M, Takahashi K, Sakaguchi Y, Ushiku T, Fukayama M, Watanabe T. Colonic perforation in a patient with systemic lupus erythematosus accompanied by cytomegalovirus infection: A case report. *Int J Surg Case Rep*. 2016;23:70–73.
- [14] Yavuz A, Şeker D, Buluş H, Aydın A. Recto-sigmoid perforation mimicking peptic ulcer perforation: a case report. *Turkish J Surg*. 2011; 27:243–245.

- [15] Olnick HM, Harris CM. Spontaneous perforation of the colon. *South Med J.* 1980;73(3): 326–328.
- [16] Cho KC, Baker SR. Extraluminal air. Diagnosis and significance. *Radiol Clin North Am* 1994;32:829–844.
- [17] Rice RP, Thompson WM, Gedgaudas RK. The diagnosis and significance of extraluminal gas in the abdomen. *Radiol Clin North Am* 1982;20:819–837.
- [18] Ghahremani GG. Radiologic evaluation of suspected gastrointestinal perforations. *Radiol Clin North Am* 1993;31:1219–1234
- [19] Stapakis JC, Thickman D (1992) Diagnosis of pneumoperitoneum: abdominal CT vs. upright chest film. *J Comput Assist Tomogr* 16:713–716
- [20] Maniatis V, Chryssikopoulos H, Roussakis A, et al. (2000) Perforation of the alimentary tract: evaluation with computed tomography. *Abdom Imaging* 25:373–379.
- [21] Miki T, Ogata S, Uto M, et al. (2004) Multidetector-row CT findings of colonic perforation: direct visualization of ruptured colonic wall. *Abdom Imaging* 29:659–662.
- [22] Iqbal CW, Chun YS, Farley DR. Colonoscopic perforations: a retrospective review. *J Gastrointest Surg* 2005; 9: 1229–1235.
- [23] Rotholtz NA, Laporte M, Lencinas S, Bun M, Canelas A, Mezzadri N. Laparoscopic approach to colonic perforation due to colonoscopy. *World J Surg.* 2010;34:1949–1953.
- [24] Kim JS, Kim BW, Kim JI, Kim JH, Kim SW, Ji JS, Lee BI, Choi H. Endoscopic clip closure versus surgery for the treatment of iatrogenic colon perforations developed during diagnostic colonoscopy: a review of 115,285 patients. *Surg Endosc.* 2013;27:501–504.