

We are IntechOpen, the world's leading publisher of Open Access books Built by scientists, for scientists

6,900

Open access books available

186,000

International authors and editors

200M

Downloads

Our authors are among the

154

Countries delivered to

TOP 1%

most cited scientists

12.2%

Contributors from top 500 universities



WEB OF SCIENCE™

Selection of our books indexed in the Book Citation Index
in Web of Science™ Core Collection (BKCI)

Interested in publishing with us?
Contact book.department@intechopen.com

Numbers displayed above are based on latest data collected.
For more information visit www.intechopen.com



Acanthamoeba Keratitis: The Emerging Vision-Threatening Corneal Disease

Lidia Chomicz, Jacek P. Szaflik, Marcin Padzik and Justyna Izdebska

Additional information is available at the end of the chapter

<http://dx.doi.org/10.5772/64848>

Abstract

Some *Acanthamoeba* species are distributed in natural and man-made environments, in a wide range of soil and aquatic habitats, also in clinical settings. The amphizoic organisms can exist as facultative parasites - causative agents of serious human disease, *Acanthamoeba* keratitis. The vision-threatening eye disease occurring particularly in contact lens wearers is reported with increasing prevalence in different regions of the world. The amoebic keratitis is difficult to diagnose as clinical symptoms are similar to those observed in other eye diseases. Moreover, bacterial, viral, fungal, and amoebic co-infections frequently occur; also amoebae act as carriers for ~ 20 species pathogenic for humans, e.g. from *Pseudomonas*, *Legionella*, *Mycobacterium* and *Escherichia* genera; thus the corneal disease is frequently misdiagnosed. Complex etiology, late proper recognition of amoebic infections, and the exceptional resistance of *Acanthamoeba* cysts to chemicals are important factors influencing diagnostic and therapeutic difficulties. Surgical interventions are needed as an alternative treatment in refractory *Acanthamoeba* keratitis. It should be taken into consideration that the knowledge and awareness of increasing threat generated by the amphizoic amoebae are still insufficient. This compilation presents selected aspects of eye disease that is becoming the increasingly significant for human health worldwide.

Keywords: *Acanthamoeba* keratitis, risk factors, symptoms, pathogenesis, diagnostics, therapy

1. Introduction

Acanthamoeba keratitis (AK), the vision-threatening corneal disease that was first time recognized in 1973 in the United States in a Texas rancher [1], is reported with increasing prevalence in different regions and countries year after year [1- 7]. This corneal, usually acute and progressive infection is becoming increasingly significant for human health worldwide.

Eye diseases affecting the cornea are a major cause of blindness worldwide. Among different infectious agents, bacteria, fungi, viruses and protozoans may be causes of keratitis in contact lens users. At present, the epidemiology of microbial keratitis is complicated, diverse, and even controversial; the use of contact lenses is considered as the most important risk factor of corneal infections in humans [4,8]. It was emphasized in several reviews [8- 10] that the incidence rates of particular organisms causing keratitis associated with contact lens wear differ between parts of the world, from country to country and even from one population to another. Economic factors, various frequencies of contact lens wear in particular geographical locations, different availabilities and standards of eye care, and different methods of etiological agent isolation and culture in particular surveys were mentioned as factors influencing the differences and criteria taken into consideration in the studies.

The frequency of microbial keratitis cases caused by Gram-negative bacteria from genus *Pseudomonas* (as percent of total isolates from given location) varied in Europe: from 6.6% in Turkey to 72.2% in Italy and from 12% to 28.5% in various surveys from the United Kingdom [8]. Climate also influenced the incidence of bacterial keratitis: e.g. in Australia, the frequency of *P. aeruginosa* contact lens keratitis was increased in tropical zones than temperate zones.

The highest proportion of fungal corneal infections (*Aspergillus* sp., *Candida* sp.), 67% was found in India [9]; in Europe, the highest frequency of 22.2% was found in Turkey.

Correlations between the contact lens wear and percentages of bacterial and fungal keratitis were statistically significant.

The viruses from *Herpes* spp. are other agents of keratitis. There are relatively few studies on the epidemiology of *Herpes* keratitis in humans. According to review by Farooq and Shukla [11], in developed countries, *Herpes* keratitis is believed to be an important cause of infectious blindness mainly resulting from stromal opacification, e.g. it was reported from France that the incidence was 25.8 (21.2–30.4) per 100,000 person-years; 95% of the cases occurred in contact lens users. These authors found that the incidence of this keratitis is about 1.5 million, including 40,000 new cases of severe visual impairment each year, however, it is difficult to ascertain the frequency of the viral keratitis because of a lack of surveillance-based epidemiologic studies [11].

Protozoan eye disease, *Acanthamoeba* keratitis (AK), is rare in the general population (estimated incidence: 1.4 per million person- year) but much frequent in contact lens wearers. [4,12,13]. In the United States, an estimated 85% of cases occur in contact lens users. The incidence of the disease in developed countries is approximately 1-33 cases per million contact lens wearers, e.g. in England 17-21 cases per million. Currently, it is emphasized that an awareness and knowledge about AK -the serious, vision-threatening eye disease are still insufficient [12,18].

Previous and recent studies continued in many centers with a participation of practicing researchers and other scientists are crucial for a better understanding of *Acanthamoeba* keratitis [4,14-18]. Advances in the field are expected by both laboratory and clinical practitioners; particularly, an improvement in duration from first symptoms until suitable diagnosis as well as in efficacy of the therapeutic management and prophylaxis is the urgent need. Here, we

present selected aspects of this multi-factorial human disease, including the results of our studies and own experiences in the topic.

1.1. Possible environmental sources of *Acanthamoeba* spp.

Free-living amoebae belonging to *Acanthamoeba* genus are ubiquitous and widely distributed in natural and man-made environments of many parts of the world [4,19-25]. The amoebae have been isolated from a wide range of soil and aquatic habitats; they occur in sea, fresh-chlorinated- and tap- water, drinking water systems, bottled mineral water, thermal recreational waters, swimming pools, air, air-conditioning systems including humidifiers, soil and dust, and sewage. The amoeboid protists have been found in fruits, vegetables, and also healthy, diseased or dead animals [12,18]. The amoebae have been isolated also from clinical settings and the hospital environment: on surfaces of different equipment and accessories, in water and air-conditioning systems, on surgical instruments, in dental irrigation units, in contact lenses and their cases, and in dialyzers [7,26,27].

1.2. The developmental forms and classification of *Acanthamoeba* spp.

The amoeboid, mitochondria-bearing protist is known as free-living organism that exists in two morphologic forms: trophozoite and cyst [4,12,18]. The life cycle of *Acanthamoeba* is asexual; the reproduction of trophozoite is by binary fission. This active vegetative stage contains one nucleus with large, central nucleolus (endosome), ectoplasm and granular endoplasm, with a large contractile vacuole as well as numerous mitochondria and digestive vacuoles. The trophozoite is changing in shape, 15–45µm in size and moving by cytoplasmic-transparent pseudopodia that create characteristic protrusions: spine-like acanthopodia. The dormant stage, cyst is smaller, 8-24µm in size, rounded or polygonal in shape, and double-walled, with wrinkled or rippled outer layer; the form indicates minimal metabolic activity. The outer wall of the cyst, the so-called ectocyst, contains lipids and proteins; the inner cyst wall, endocyst contains cellulose that is not present in trophozoite stage. The two cyst walls are separated by a space, except of points in that both walls meet; in these points - pores, i.e. ostioles occur that are covered by plugs, so-called opercula. The plugs are removed when trophozoites emerge from cysts during excystation [4,12]. Trophozoites transform into cyst stages after the growth developmental phase of amoeba population, in which high cell density occurs as well as under harmful environmental conditions (e.g. extremes in temperature and pH, increased or decreased osmolarity, lack of nutrients). The therapeutic experience and many *in vitro* studies showed that the cysts are highly resistant to antimicrobial drugs and a variety of chemical and physical agents [reviewed in 4,12]; they can remain viable under prolonged desiccation, starvation, heat and cold. Also, they can survive *in vitro* in distilled water as long as 25 years [28] and maintain their viability and virulence.

Following the recognition of the amoebae and increasing number of isolates belonging to the genus *Acanthamoeba*, for years they were classified using morphological criteria. In this classification, a size of cysts and the number of characteristic arm-like structures visible within a single cyst in light microscope were mainly taken into consideration [4,12,18,29,30]. At the time, 18 species have been determined and placed in three morphological groups I, II and III.

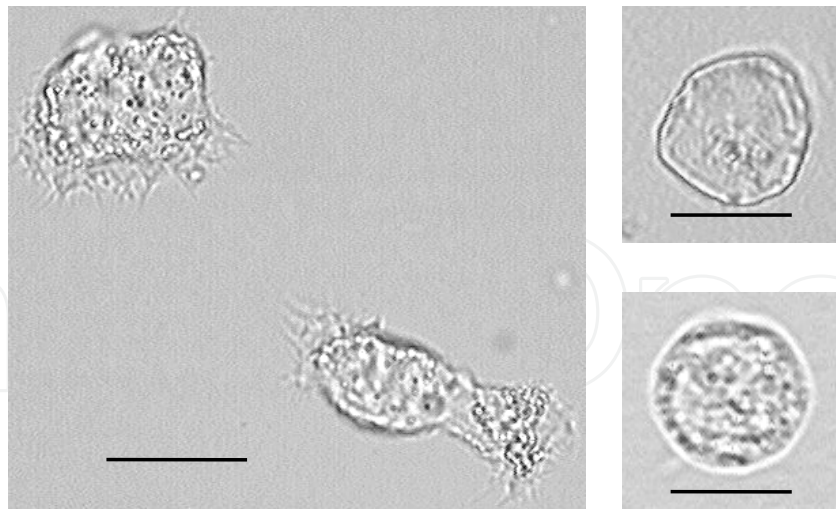


Figure 1. *Acanthamoeba* sp. - wet-mount slides from corneal scrapings; note characteristic spine-like acanthopodia in trophozoites and the double-walled cysts; light micrographs; scale bar = 10μm

The classification of *Acanthamoeba* species /isolates changed with the advances in molecular methods. Recently, it is based on genotype associations - the 18S rRNA gene sequence [5,20,31-33]. The modern approach differs from morphology solely: the species identification is based on combination of the morphological and molecular characterization [3,5,15,20]. At present, 18 or 19 genotypes are distinguished for diagnostics and for the characterization of clinical and environmental *Acanthamoeba* isolates [12,15,18,31-33].

2. *Acanthamoeba* spp. as potential agents of human diseases

The protozoans belonging to *Acanthamoeba* spp. complete their life cycles in different outer environments as free-living organisms. Trophozoite forms are able to feed on various micro-organisms dwelling in soil and water (on bacteria, algae, and yeasts as well as on other protozoans) and on small organic particles. In natural, and even in man-made environments, the amoebae develop without entering human or animal organisms. However, in predisposing circumstances, the amoebae may enter the human body. According to literature [34,35], there are evidences from various regions that humans are exposed frequently to the amoebae: it has been confirmed by 50–100% of the healthy populations having specific anti- *Acanthamoeba* antibodies. The protists may permeate into the human body without pathogenic consequences. Investigations in which serological, biochemical and molecular methods were applied showed that people may be exposed both, to pathogenic as well as non-pathogenic *Acanthamoeba* strains [reviewed in 12,13,18]. In immunocompetent individuals, infections with these amoebae may be asymptomatic and/or self-limited.

Nevertheless, several amoebic strains belonging to this genus are able to enter, and colonize human organs and multiply within them, indicating pathogenic effects [4,12,26,27,36].

For this reason, these amoebae are called amphizoic amoebae, because they are able to exist in two different modes: as free-living-exozoic organisms and as endozoic parasitic organisms, within host tissues; thus, the free-living protozoans are also believed as facultative parasites.

Trophozoites and cysts of *Acanthamoeba* were detected during infections of various human cavities and tissues: in paranasal sinuses in rhino-sinusitis, in skin inflammation and skin ulceration, and in pneumonia [7,37,38]. We also found trophozoites and numerous cysts of *Acanthamoeba* among the oral cavity microbiota in 4% somatically and mentally disordered patients. The amoebae accompanied infections with other amoebae, *Entamoeba gingivalis*, the oral amoebae associated with a prolonged deterioration of the periodontium and gingiva [39].

Developmental stages of the amphizoic species may be causative agents of an systemic opportunistic disease developing in immunocompromised individuals. This is rare but almost always fatal granulomatous *Acanthamoeba* encephalitis (GAE) [6,12,18,40]. Other infection caused by the amphizoic amoebae may result in a sight-threatening *Acanthamoeba* keratitis (AK), a non-opportunistic disease occurring mainly in immunocompetent persons, mostly in contact lens wearers [1-3,7,14].

3. Pathogenesis in AK

In the early phase of AK, there are nonspecific symptoms variable in their intensity starting with redness, photophobia, and excessive tearing. Most commonly, only one eye is involved. Active epithelial inflammations usually progress from the outermost layer of the cornea deeper, to the stroma. Symptoms of the devastating eye disease include loss of the visual acuity. In many cases of AK, excruciating eye pain occurs, in which the intensity is often incommensurate with relatively small degree of corneal deterioration. There are clinical and histopathological evidences that the severe pain is associated with *Acanthamoeba* trophozoite activeness that result in the inflammation of the corneal nerves -radial keratoneuritis [4,27]. It is also emphasized that a characteristic ring-like corneal infiltration may occur in some patients. This amoebic eye infection may develop from a few days to several months, as a severe, prolonged disease, which, without suitable treatment may lead to blindness.

A pathogenesis of *Acanthamoeba* keratitis is a multi-factorial process connected with some factors contributing directly and indirectly in production of diseases in humans [12].

Among the direct contributing factors, the following are listed: adhesion of *Acanthamoeba* trophozoites to host cells, phagocytosis to take up food particles, neuraminidase activity, and secretion of toxins. The neuraminidase enzyme, which is active at 25-30 °C, is believed to be important in a damaging of corneal epithelial cells [12,41]. Recently, the first toxin, acanthaporin, with pore-forming activity, cytotoxic for human neuronal cells was isolated from *Acanthamoeba*, which activation mechanism remains under investigations [12,42].

Among the indirectly contributing factors, there are amoebic and host determinants. Morphophysiological features: the amoeboid motion and spine-like acanthopodia allow protozoans to modulate binding to biological and inert surfaces. Also, changes in the overall numbers of

the amoebae as well as in the proportion of trophozoites and cysts dependent on the environmental conditions are also listed as the amoebic pathogenesis determinants. The temperature tolerance, osmotolerance and growth at different pH allow the amphizoic *Acanthamoeba* to exist in different environments and simultaneously easy adapt to different human organ and tissues, including the human cornea. Moreover, it has been shown that both, clinical and environmental *Acanthamoeba* strains/isolates vary in their among the oral cavity microbiota pathogenicity. The thermal tolerance and ability to grow at high temperature are considered to be indirect markers of the pathogenicity of *Acanthamoeba* strains [12,17,18,43-45].

4. Predisposing/ risk factors sufficient to contract AK

In several studies it is underlined that the initiating of AK is a multi-factorial process, in which both host and environmental determinants are likely involved, apart connected with *Acanthamoeba* pathogenic strains [4,12].

It is considered that *Acanthamoeba* keratitis is mainly related to contact lens wear, although, *Acanthamoeba* corneal infections are also detected in persons not using contact lenses [7,12-14, 46]. After the first case of AK associated with contact lenses in Central Europe was reported from Germany, more than 85% of all incidences of the disease have been recognized in different countries in wearers of contact lenses [12,17,18,47-50].

The estimation of AK findings in several countries showed various, generally relatively low, but constantly increasing number of the corneal disease incidents during the last few decades i.e. 1.36 cases per million contact lens wears in the United States, 17 to 21 cases per million in England, 1 per 30,000 contact lens wears in France, 0.05 per 10,000 in Holland [4,12,13]. However, "it is noteworthy", as Khan [4] concluded "that variations in the incidence rate of *Acanthamoeba* keratitis do not reflect the geographical distribution of *Acanthamoeba*, and are most likely due to variations in the extended wear of soft contact lenses, varied awareness of the potential risk associated with the contact lens wear, enhanced detection, and/or local conditions that promote growth of pathogenic *Acanthamoeba* only e.g.. water hardness or salinity, or conditions that suppress growth of non-pathogenic *Acanthamoeba*." Interestingly, in Austria, women and men were affected almost equally; the highest AK incidences occurred in the 21-30-years-old patients; simultaneously, poor contact lens hygiene is indicated as the most important risk factor of AK in this country [46].

Some micro-traumas occurring earlier or appearing in connection with the use of the lenses predispose to contract AK; a human organism's susceptibility, tissue specificity, tear factors, and secretory immunoglobulin A (sIgA), important in the specific immune defense mechanism, are among other host factors influencing development of this corneal disease. Environmental conditions such as temperature, osmolarity, and pH may be important in initiating AK.

Simultaneously, the amoebae were found in contact lens and in storage cases that may be potential sources and reservoirs of the facultative parasites [12,18,47-53]. In spite of this, the incidence rate of AK in wearers of contact lenses is remarkably low in comparison with the contact lens storage cases contaminated with *Acanthamoeba*.

Additionally, it has been confirmed for various *Acanthamoeba* strains that a swimming in recreational pools while contact lenses wearing promotes the infection; it is because of some human corneal micro-defects caused by lenses and extremely high resistance of the amoebae to chlorine disinfectants [12,17, 49-53].

In persons not using contact lenses, other circumstances influence as important for contract AK [4,47]. The different *Acanthamoeba* strains are ubiquitous in natural and man-made environments thus, an exposure of the eye especially to dust, water or moist soil, as well as to any foreign particle, on which trophozoites and cyst of the amoebae can occur, is considered as an AK predisposing factor. Also, if corneal epithelial injuries appear, and also during eye surgery, circumstances promoting the infection may occur.

There have been no reports of *Acanthamoeba* keratitis being spread from one person to another.

5. When the clinician should suspect *Acanthamoeba* keratitis?

It is known, that the emerging vision-threatening AK is difficult to diagnose because clinical manifestations are similar to those observed in the course of other infectious eye diseases.

In anamnesis, in the early stage of this eye disease - patients are complaining of photophobia, excessive tearing, and reduced visual acuity; the clinical manifestations of this keratitis may also include redness and eyelid edema [13,17,50,54].

Particularly, if a presence of any foreign particles will be excluded, appearing of excruciating eye pain with intensity incommensurate with degree of corneal deterioration may suggest that *Acanthamoeba* infection develops; however, the pain not always occurs. As a rule, AK should be suspected if, in anamnesis, the contact lens wear, a history of swimming in a lake, and in recreational pools while contact lenses wearing, exposure to soil, any case of corneal trauma, surgical procedures are reported to clinician [12,18]. However, according to different reports and own experience, the amoebic etiology of the keratitis cannot be excluded in patients with above mentioned symptoms and history, previously unsuccessfully treated in ophthalmic units with antiviral, antibacterial and/or antifungal medications that delayed proper diagnosis and the suitable therapeutic management [17,50,55].

6. Differential diagnosis of AK

6.1. A tentative diagnosis of AK

The non-invasive methods are useful for the tentative diagnosis of AK, in which the slit-lamp that provides magnification from 10 to 25 times and *in vivo* confocal microscopy (Figures 2 and 3) are applied [4,12,44,50,56].

The use of a slit lamp is indicated in any acute situation that requires magnification to inspect the anterior segment of the eye. Active epithelial inflammations and hyper reflective tissues

in the affected eye may be visualized by the slit lamp; a corneal ulcer and characteristic, ring-like corneal infiltration may occur in some patients. However it should be underlined that the characteristic ring infiltrate is seen in approximately 50% of AK cases.

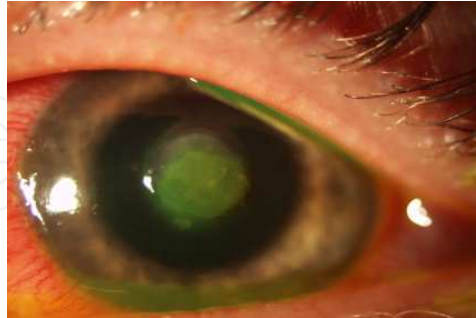

Figure 2. Slit-lamp photograph of corneal ulceration of severe *Acanthamoeba* keratitis case.

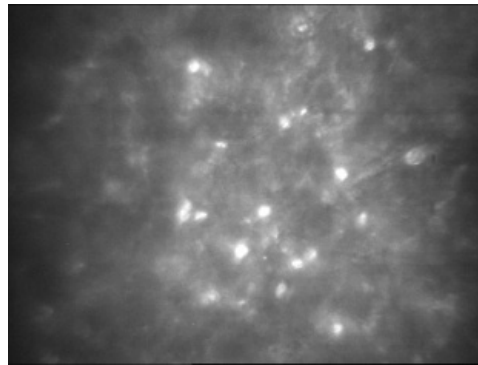


Figure 3. Hyper reflective objects - *Acanthamoeba* cysts in the affected eye with the late diagnosed severe keratitis; *in vivo* confocal microscopy; scale bar = 50 μ m

Different clinical presentations may occur in various causes of keratitis. However, in clinical AK practice there are nonspecific signs variable in their intensity starting with photophobia, redness, and excessive tearing that present with similar symptoms as viral, bacterial and fungal keratitis [4,7, 9-12].

In the slit lamp, corneal epithelial disease caused by *Herpes simplex* virus may be seen as dendritic keratitis or the geographic ulcer. The edges of these lesions with swollen epithelial cell stain with rose bengal while the central part stains with fluorescein [11,12,18].

Bacterial corneal infection appears typically as a one gray-white stromal infiltrate with well-demarcated borders. Critical signs for fungal keratitis, e.g. *Fusarium* keratitis, are stromal gray-white or yellow-white infiltrate with a feathery border, satellite lesions surrounding the primary lesion; co-infections with fungi and bacteria can complicate the fungal keratitis [9,10,12].

In the early epithelial stage of *Acanthamoeba* keratitis, this infection can be misdiagnosed as a *Herpes simplex* keratitis because of irregular grayish lesions and pseudodendrites that are

frequently observed in the epithelium. In advanced stage, AK can be mistaken as a fungal keratitis [9,11,12].

Active epithelial inflammations usually progresses from the outermost layer of the cornea -a superficial keratitis -to deeper stroma -the stromal or interstitial keratitis.

In the initial epithelial phase, typical signs of AK include epithelial or sub-epithelial infiltrates, pseudodendrites resembling these observed in *Herpes* keratitis, radial keratoneuritis (infiltrates along corneal nerves) and recurrent punctate staining of the corneal epithelium. Perineural infiltrates -a radial keratoneuritis are described as pathognomonic for the diagnosis of *Acanthamoeba* keratitis [12,18]; they are evoked by tropism of the amoebic organism for corneal nerves. Radial keratoneuritis is the reason for the extreme pain and is usually seen during the first one to four weeks of disease. Anterior stromal infiltrates are another common sign of AK. They gradually enlarge and coalesce to form a ring abscess, commonly located in the center of the cornea. Less specific signs of AK are satellite stromal infiltrates, diffuse stromal infiltrates and endothelial plaques observed in many of the patients.

Later signs of AK develop in 3-8 weeks and include a deep inflammation of the cornea consisting of a central stromal thinning and melting, anterior chamber cells and flare, hypopyon and extension of inflammation into sclera. The latter is generally reactive reaction rather than extension of infection; later in the disease course, the slowly progressive stromal opacifications and neovascularization may occur.

Etiological agents of infectious keratitis can be differing using *in vivo* confocal microscopy that is confirmed as useful tool for rapid diagnosis with high sensitivity [4,12,18,56,57].

Common findings in viral keratitis are: highly reflective, desquamating epithelial cells in superficial epithelial layer, multiple dendritic cells in basal epithelial layer, the absence of subepithelial nerve plexus, and hyperreflective keratocytes in the anterior stroma.

In bacterial keratitis, confocal micrographs typically reveal leucocytes infiltrating the corneal stroma and adherent to vessel walls. In some cases, the dendritic cells are present intrastromally; the bacteria themselves cannot be detected with the confocal microscopy.

Filamentous fungi and bacteria (e.g. *Nocardia*) can form filamentous structures that are large enough to be distinguished by confocal microscopy [57]. Another characteristics sing of filamentous fungal infection is hyphae branching, in a case of *Aspergillus* at 45° and in a case of *Fusarium* at 90°.

The examination of affected eyes by *in vivo* confocal microscopy make possible to distinguish AK from the aforementioned infectious keratitis. Lately, confocal scan features of cysts and trophozoites as well as associated corneal epithelial and stromal findings were described as criteria to specify AK in clinical diagnosis [57]. Presumable *Acanthamoeba* cysts can be visible as numerous hyper reflective, double-walled ovoid or spherical objects, 10-25µm in diameter, localized typically in deeper parts of epithelium and in anterior layers of the corneal stroma [4,18,57]. These findings should be distinguished from the well-delineated individual epithelial cell nuclei or leucocytes; the latter are larger and more regular than *Acanthamoeba* cysts. The outer wall of the cyst is more reflective than internal wall; with time, some cysts are not

seen and the others become calcified. Trophozoites are also described as visible in confocal scan images, however, false results can occur because the forms are difficult to distinguish from nuclei of leukocytes and keratocytes [4,12,18]. Although confocal microscopy, if available, is non-invasive, high-sensitive tool for rapid *in vivo* diagnosis, examiners have to be familiar with morphology of *Acanthamoeba* forms. Also, differences in strain pathogenicity and viability can be taken into consideration.

It was evident also in our studies on monitoring of *in vitro* dynamics of *Acanthamoeba* strains isolated from infected eyes [17,50]; the presence of hyper reflective objects/cysts was revealed by this non-invasive *in vivo* confocal microscopy mainly for severe, late diagnosed infections with strains of which strong viability was indicated by intensive multiplying of trophozoites *in vitro* and their long survival time (42 months) in culture medium. Contrary to this, no cysts were detected by the confocal technique in material from corneal scraping if infections with weak viability strains occurred; a low amoeba number in the exponential growth phase and short (10 days) survival time of such amoeba strains were manifested *in vitro* in the culture medium. Also, no cyst was found in confocal microscopy images when mixed infections occurred, although finally the infection with *Acanthamoeba* was confirmed by laboratory methods.

Negative results of the *in vivo* confocal microscopy were reported if patients have already been pre-treated, thus the amoeba density was very low [12,50].

6.2. Why clinical manifestations are not sufficient to indicate a causative agent of keratitis

Knowledge and awareness of threat are necessary as the most important step in proper AK diagnosis as it is underlined by J. Lorenzo-Morales et al. [12].

The careful anamnesis is very important and helpful. Most of the clinical symptoms of *Acanthamoeba* keratitis are nonspecific and frequently a variability in their intensity is observed and reported from different world regions. AK is often misdiagnosed as viral infection with *Herpes simplex*, bacterial with *Pseudomonas aeruginosa* or keratitis caused by fungi of genera *Fusarium* or *Candida*; moreover, bacterial, viral, and fungal co-infections with *Acanthamoeba* may occur [2,4,46]. This is why the clinical symptoms alone, as non-pathognomonic, are not sufficient to indicate an etiological agent of human keratitis.

Undoubtedly, the non-invasive *in vivo* confocal microscopy is a valuable technique, however usefulness of it is limited if bacterial or viral keratitis occurs, thus it should be applied for the tentative diagnosis.

Also, in our several studies we analyzed serious keratitis cases regarding patients who were under suspicion of *Acanthamoeba* etiology of the infections. Although, in our hospital, finally AK was determined, there were mistakes in results of earlier diagnostics. The mixed amoebic, bacterial (*P. aeruginosa*, *E. faecalis*), and fungal (*Candida* sp.) infections have been revealed by us in more than 50% cases regarding persons previously unsuccessfully treated only with antibacterial and antifungal medications in other ophthalmic units [17,50].

It has been reported that *Acanthamoeba* protozoans may carry more than 20 species pathogenic for humans, among others bacteria belonging to genera *Legionella*, *Pseudomonas*, *Mycobacterium*,

Listeria and *Escherichia*, protozoa *Cryptosporidium* sp., and fungi *Cryptococcus neoformans*. The microorganisms are able not only to survive within cells but even proliferate inside the amoebae; thus, secondary infections can occur and influence diagnostic difficulties [4,12, 18].

6.3. Laboratory evaluation

Literature data as well as results of our studies indicated that microscopic visualization of amoebae in unstained or stained slides prepared directly from corneal scraping is usefulness for AK diagnostics. Also, laboratory examinations of specimens from *in vitro* cultivated corneal isolates allow to identify directly the facultative pathogens and to verify previous misdiagnoses [4,12,46,50].

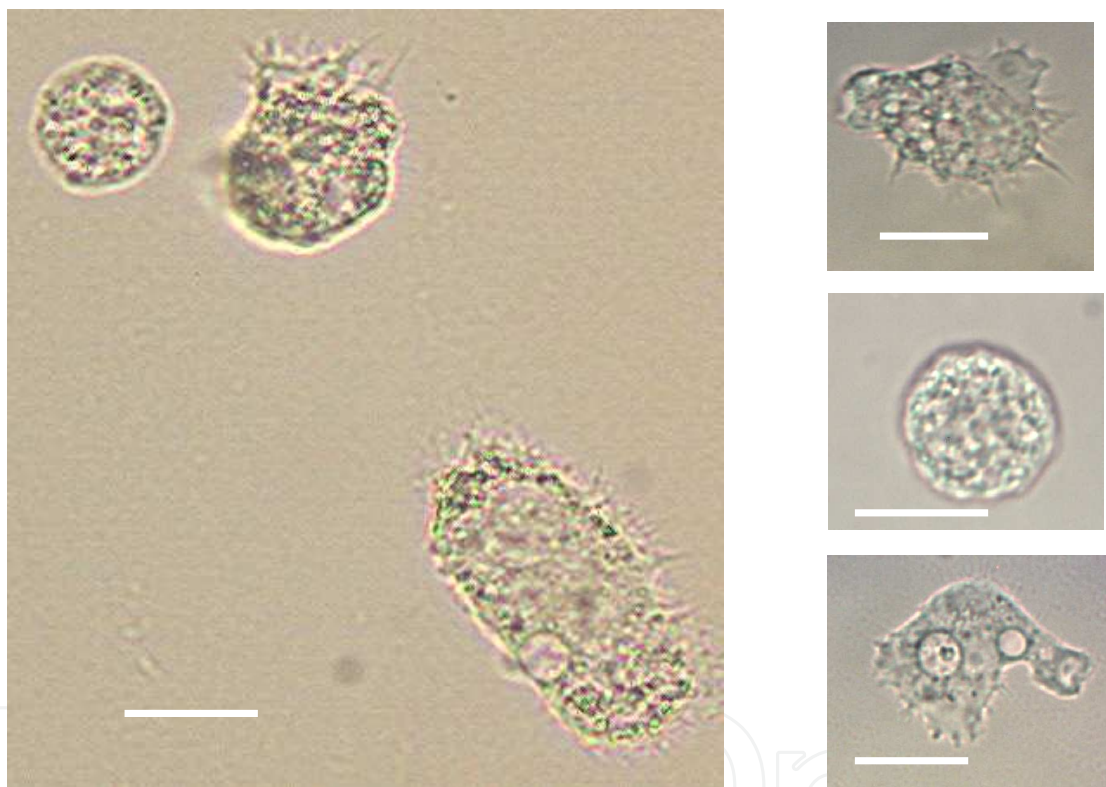


Figure 4. Live *Acanthamoeba* trophozoites and cysts in unstained preparations from corneal isolates cultured *in vitro*; light micrographs. Scale bars = 10 μ m

Moreover, culture methods are considered as the gold standard of diagnosis, which needs, however, collaboration between clinicians and laboratory staff and, also, the familiarization with a morphological characteristic of *Acanthamoeba* stages [12,14,18,55,58-60]. Non-nutrient (NN) agar plates seeded with Gram- negative, non-mucous bacteria: *Escherichia coli* or *Enterobacter aerogenes* are applied for isolation/growth of *Acanthamoeba* trophozoites both from environmental and clinical samples (corneal scrapings, biopsies, swabs). The incubation of the plates at 30°C promotes a transformation of amoeba trophozoites into cysts within approximately 1 week. Also, the cultivation of amoebae in bacteria-free (axenic) conditions in a

modified enriched culture medium containing antibiotics (penicillin, streptomycin) is useful for classification cysts to the morphological level.

Simultaneously, molecular methods of classification of *Acanthamoeba* isolates, with the use of sensitive PCR techniques, basing on genotype associations are distinguishing for diagnostics and for the characterization of clinical and environmental *Acanthamoeba* isolate [12,18,27,32,33,59]. In this modern approach, the species identification is based on the combination of morphological and molecular characteristics of amoebae. Additionally, our experiences gave convincing evidences of an importance of a clinical examination of the affected eyes and laboratory differentiations/identification of amoebic forms in material deriving from infected corneas.

7. Treatment options in AK

7.1. Factors complicating effective pharmacotherapy in AK

AK treatment is difficult and often unsuccessful despite of advances in pharmacotherapy. There are several factors that are listed as influencing difficulties and still not fully effective of applied therapy [12,18].

AK is often incorrect diagnosed due to nonspecific clinical symptoms; similar clinical pictures to this observed in the amoebic keratitis may give a wide range of agents e.g. viral *Herpes simplex*, bacterial -mostly *Pseudomonas aeruginosa* or fungi of *Fusarium* spp.

Additionally, mixed amoebic, fungal viral and bacterial keratitis may occur that complicate therapeutic management.

Acanthamoeba strains vary in their pathogenicity: they may be virulent, weakly virulent or non-virulent; they show different susceptibilities to chemicals and answer to pharmacotherapy.

It is also underlined that extremely high resistance of *Acanthamoeba* cysts to different chemicals, disinfectants as well as anti-microbial and anti-parasitic drugs result in disappointing therapeutic management [12,18,54,59-64].

Among the abovementioned facts, diagnostic mistakes that cause delayed in a beginning of an efficient treatment may result in a prolonged, severe course of AK and vision deterioration.

It is also emphasized that some chemicals can induce amoebic encystment that subsequently, by excystment, may lead to repeated development of trophozoites, thus an activation of the dormant cysts can lead to recurrence of the disease. It is why not only amoebicidal effects but also the cysticidal efficacy of applied therapeutics is very important [43-46].

In some research works, also in our experimental studies it has been reported that higher concentrations of drugs and some new-synthesized imidazole derivatives may be *in vitro* efficacious against *Acanthamoeba* strains and result not only in amoebostatic but also in amoebicidal effects. However, many of these chemicals cannot be applied *in vivo* in such concentrations due to their toxicity for human tissues [44-50].

7.2. Treatment recommended in management in AK

Currently, there are not known single-treatment methods effective against both trophozoites and cysts of *Acanthamoeba*; generally, AK is difficult to treat. *Acanthamoeba* stages differ in their susceptibility to various drugs. Trophozoite form is highly responsive to the treatment, while cysts are highly resistant as the cystic form protects the amoebic organism from unfavorable environmental factors, including drugs. The therapeutic approach recommended in AK consists of antimicrobial agent's combination [4,12,18,36].

The mainstay agents that are used as a first-line treatment for *Acanthamoeba* keratitis are diamidines (propamidine, hexamidine) and biguanides (polyhexamethylene biguanide (–PHMB), chlorhexidine), which were found to be cysticidal anti-amoebics *in vitro*. PHMB is the most preferred agent in monotherapy or in combinations with other drugs. Chlorhexidine can also be used in monotherapy, but it is much more effective in combined treatment. Propamidine is used in combination with one of biguanides, as the latter are more effective against cysts of *Acanthamoeba* [65]. Although neomycin was used widely, it is ineffective against cysts *in vitro*; thus, it is no longer used by most ophthalmologists.

However, particularly after earlier improper treatment in other centers, the combination drug therapy with the antimicrobial agents is used more or less successfully. Additionally, such factors as human organism status, a virulence of amoeba strains, phase of infection, and kind and concentration of the chemicals applied may determine variability in effects of drugs on trophozoites and cysts of several *Acanthamoeba* strains [12,16,22,45,50,64-67].

The most frequently used agents that achieve sufficient high concentrations at the site of infection and are effective against trophozoites and cysts of *Acanthamoeba* are cationic disinfectants: chlorhexidine 0.02–0.2% (200–2000 g/ml), polyhexamethylene biguanide (PHMB) 0.02–0.06% (200–600g/ml), and propamidine isethionate (Brolene 0.1%). These topical antimicrobials should be administered immediately to the infected eye one to two drops on the surface of the cornea at the first several days, every hour, minimum nine times/day, and, next, every 3h. The therapy duration is depending on clinical response. The amoebae may persist in the encysted stage for months and reactivate after therapy discontinuation. It was indicated in many earlier and current studies that a therapy continuation is very important to avoid an activation of the dormant cysts that may lead to repeated trophozoite development and thus to recurrence of the disease [4,12,13]. Some authors advise the treatment for 3- 4 months in order to preclude recurrence; however, the treatment for 6–12 months is also recommended. Nevertheless, it is reported that *Acanthamoeba* strains/cysts resistance to drug may occur, which is the main difficulty in AK treating [12,18,43,63,66]; particularly, resistance to propamidine and, also toxicity effect are observed in the course of AK. Corneal epithelial toxicity has been minimal for both chlorhexidine 0.02% and PHMB 0.02%. The greatest frequency of ocular toxicity has been reported with propamidine; the most common side effect is the superficial punctate keratopathy [65]. Pain can be relieved by topical cycloplegics (e.g. atropine 0.5-1.0%, scopolamine 0.25% t.i.d.), agents and oral non-steroidal anti-inflammatory medications (e.g. naproxen 250-500mg p.o. b.i.d.).

It should be also taken into consideration that co-infections with other microorganisms may complicate the course and treatment of the severe amoebic disease [18,49-51].

Although the low doses of topical steroids can be useful to diminish inflammation in cases of controlled infection but the use of topical corticosteroids is controversial.

Systemic corticosteroids are preferred over topical ones in cases of severe inflammation. This route of administration provides better ocular safety profile (less concentration in the cornea) but less body safety profile. However there are some suggestions that steroid use may result in increased pathogenicity of the amoebae [68].

If the topical pharmacotherapy fails, surgical interventions are needed [12,44,64,67]. Cross-linking and cryopreserved amniotic membrane graft (AMG) have been reported to be effective in AK.

The corneal transplantation can be performed for therapeutic or optical indications. Therapeutic, usually penetrating, keratoplasty is applied when the infectious process spreads to the corneal stroma, causing corneal melting and thinning despite of aggressive prolonged anti-amoebic therapy [4,12,18]. In a case of threatening or completed perforation of the cornea, the surgery must be performed urgently. Some authors recommend systemic steroids prior to surgery if concomitant limbitis or scleritis is present [69].

Sacher et al.[70] show that pretreatment of *Acanthamoeba* keratitis with intravenous pentamidine before therapeutic keratoplasty may assist with the achievement of microbiological cure, clear graft, and good visual outcome in a majority of eyes with AK.

The size of corneal graft should be minimum to excise an inflamed and necrotic tissue. Although remaining clinically healthy cornea is frequently also infected, this tissue should be saved because of the higher risk of rejection with large/decentrated grafts and because the possibility of repeat grafting should be kept in mind in the event of recurrence; a further graft represents a new food source for the organism and can be used to attract residual amoebae [69].

In a case of therapeutic keratoplasty for AK, the topical steroids in combination with anti-amoebic drugs are applied for 6-12 months following keratoplasty, to relieve pain, lessen the inflammation, and prevent graft rejection and recurrence of infection. Corneal grafts performed in the eyes with active inflammation are the high-risk transplants and they required systemic immunosuppression similar to this given in organ transplants (cyclosporine and/or mycophenolate mofetil). Apart from a poor graft survival, the postoperative glaucoma is a frequent complication.

In optical keratoplasty performed after resolution of active keratitis there is an excellent prognosis for both graft survival and visual outcome [71].

Promising clinical results were reported from amoebicidal effect of combined riboflavin and UV-A (ultraviolet light A, 365nm wavelength) exposure -corneal cross-linking (CXL) that was used for stabilization of corneal melting which can delay surgical treatment [12,72,73]. CXL has also an antimicrobial effect that is due to the effect of UV light interacting with riboflavin as the chromophore. It damages both the DNA and RNA of pathogens. Photoactivated chromophore for infectious keratitis (PACK)-CXL is an alternative to standard antibiotic therapy in treating infectious corneal disorders, and may help reduce the microbial resistance to antibiotics and avoid therapeutic keratoplasty in some cases [74].

Many chemicals and antimicrobials were examined and are still tested *in vitro* for their potential activity against different species, strains and isolates of *Acanthamoeba* [45,54,61-63,67]. Due to the toxicity of high concentrations of agents tested and a drug resistance, an optimal strategy for anti-acanthamoebic treatment is not yet defined. Further studies in this field are needed, particularly, in terms of cysticidal effects of the chemicals tested.

8. Prevention and prognosis of AK

The *Acanthamoeba* species are ubiquitous and widely distributed in natural and man-made environments. In various regions, humans were exposed frequently to the amoebae, that has been confirmed when in healthy populations specific anti- *Acanthamoeba* antibodies have been detected. For this reason, knowledge and awareness of threat are important to avoid the infection [6,12,18].

The contact lens wearers must be well educated as for the proper use and care of their lenses; do not use saline solution for lens storage, and do not to swim wearing contact lenses or use the swimming goggles. It is also very important to educate the ophthalmologist to be aware of signs and symptoms of AK and be able to early diagnose and initiate suitable treatment.

The prognosis for visual recovery with only mild residual stromal involvement is very good; in other cases, the visual prognosis is poor. Generally, a prediction depends on inflammation status at the time of diagnosis and the prompt initiation of proper treatment.

A retrospective review indicates that early diagnosis (less than 18 days) results in better final visual acuity and less likely needs keratoplasty [75]. In the early stage of infection, trophozoite forms are predominated, and the infection is confined to the superficial corneal layers. With time as the process progresses, the microorganisms enter to the deeper corneal stroma and encyst. Cysts are much more resistant to anti-protozoan drugs compared to trophozoites. Severe inflammation, scleral involvement, late diagnosis, and retardation of the therapy initialization are associated with poor clinical outcomes. In 10% of cases, there is associated scleritis. *Acanthamoeba* sclerokeratitis is associated with poor clinical outcomes [12,13,75].

9. Conclusions

Complex infective etiology and late recognition of amoebic infections were the important factors influencing diagnostic and therapeutic difficulties in AK. Laboratory examinations including *in vitro* cultivation of the isolates, acquired from corneal scrapings, allow directly to identify the facultative pathogens -the causative agents of the keratitis and to verify previous misdiagnoses. Early proper diagnosis in *Acanthamoeba* keratitis, confirmed by detection of live trophozoites in corneal scraping cultures are decisive for the treatment efficacy, particularly in contact lens wearers. The pharmacotherapy of the infectious eye disease is often unsuccessful; among others, it is if chemicals induce amoebic encystment; subsequently, an activation of the cysts can lead to repeated development of trophozoites and recurrence of the disease.

In some severe cases, keratoplasty and prolonged application of a mixture of drugs may be an appropriate option for visual rehabilitation.

Moreover, as our studies and experience show, *in vitro* monitoring of dynamics of *Acanthamoeba* strains isolated from affected eyes may be useful tool for proper diagnosis, therapeutic management and treatment prognosis.

Human infections with facultative parasitic *Acanthamoeba* strains are serious medical problem that should be taken into consideration as emerging threats of the public health worldwide.

Therefore, further educational efforts directed first of all to contact lens users are desirable for the prevention of this vision-threatening corneal disease.

Author details

Lidia Chomicz^{1*}, Jacek P. Szaflik², Marcin Padzik¹ and Justyna Izdebska²

*Address all correspondence to: lidia.chomicz@wum.edu.pl

1 Department of Medical Biology, Medical University of Warsaw, Warsaw, Poland

2 Department of Ophthalmology, Medical University of Warsaw, SPKSO Ophthalmic University Hospital, Warsaw, Poland

References

- [1] Nagington J, Watson PG, Playfair TJ, McGill J, Jones BR, Steele ADM: Amoebic infection of the eye. *Lancet*. 1974;304:1537–540.
- [2] Ibrahim YW, Boase DL, Cree IA: Factors affecting the epidemiology of *Acanthamoeba* keratitis. *Ophthalmic Epidemiology*. 2007;14:53–60.
- [3] Lorenzo-Morales J, Martín-Navarro CM, López-Arencibia A, Arnalich-Montiel F, Piñero JE, Valladares B: *Acanthamoeba* keratitis: an emerging disease gathering importance worldwide? *Trends in Parasitology*. 2013;29(4):181–187.
- [4] Khan NA: *Acanthamoeba: Biology and Pathogenesis*. Caister Academic Press, Norfolk, UK. 2009;290.
- [5] Schroeder M, Booton GC, Hay J: Use of subgenic 18S ribosomal DNA PCR and sequencing for genus and genotype identification of *Acanthamoebae* from humans with keratitis and from sewage sludge, *Journal of Clinical Microbiology*. 2001;39:1903–1911.

- [6] Schuster FL, Visvesvara GS: Amebic encephalitides and amebic keratitis caused by pathogenic and opportunistic free-living amebas. *Current Treatment Options in Infectious Diseases*. 2003;5:273–282.
- [7] Marciano-Cabral F, Cabral G: *Acanthamoeba* spp. as agents of disease in humans. *Clinical Microbiology Reviews*. 2003;16(2):273–307.
- [8] Giese MJ, Weissman BA: Contact lens associated corneal infections. Where do we go from here? *Clinical & Experimental Optometry*. 2002;85(3):141–148.
- [9] Shah A, Sachdev A, Coggon D, Hossain P: Geographic variations in microbial keratitis: an analysis of the peer-reviewed literature. *British Journal of Ophthalmology*. 2011;95:762–767. doi:10.1136/bjo.2009.169607.
- [10] Willcox M DP: Management and treatment of contact lens-related *Pseudomonas* keratitis. *Clinical Ophthalmology*. 2012; 6:919– 924. <http://dx.doi.org/10.2147/OPTH.S25168>.
- [11] Farooq AV, Shukla D: *Herpes simplex* epithelial and stromal keratitis: an epidemiologic update. *Survey of Ophthalmology*. 2012;57(5):448–462. doi:10.1016/j.survophthal.2012.01.005.
- [12] Lorenzo-Morales J, Khan NA, Walochnik J: An update on *Acanthamoeba* keratitis: diagnosis, pathogenesis and treatment. *Parasite*. 2015;22:1–20.
- [13] Trabelsi H, Dendana F, Sellami A, Sellami H, Cheikhrouhou F, Neji S, Makni F, Ayadi A: Pathogenic free-living amoebae: Epidemiology and clinical review. *Pathologie Biologie*. 2012;60:399–405.
- [14] Khan NA: *Acanthamoeba*: biology and increasing importance in human health. *FEMS Microbiology Reviews*. 2006;30:564–595.
- [15] Booton GC, Joslin CE, Shoff M: Genotypic identification of *Acanthamoeba* sp. isolates associated with an outbreak of *Acanthamoeba* keratitis. *Cornea*. 2009;28(6):673–676.
- [16] Alizadeh H, Apte S, El-Agha MS: Tear IgA and serum IgG antibodies against *Acanthamoeba* in patient with *Acanthamoeba* keratitis. *Cornea*. 2001;20:622–627.
- [17] Chomicz L, Conn DB, Padzik M, Szaflik JP, Walochnik J, Zawadzki PJ, Pawłowski W, Dybicz M: Emerging threats for human health in Poland: pathogenic isolates from drug resistant *Acanthamoeba* keratitis monitored in terms of their *in vitro* dynamics and temperature adaptability. *BioMed Research International*. 2015:Article ID 231285, 8pages, doi:10.1155/2015/231285.
- [18] Khan NA: *Acanthamoeba*: Biology and Pathogenesis 2nd ed, Caister Academic Press. Norfolk, UK. 2015;295.
- [19] Rodriguez-Zaragoza S, Magana-Becerra A: Prevalence of pathogenic *Acanthamoeba* (Protozoa: Amoeboidea) in the atmosphere of the city of San Luis Potosi, Mexico. *Toxicology & Industrial Health*. 1997;13:519–526.

- [20] Kilic A, Tanyuksel M, Sissons J, Jayasekera S, Khan NA: Isolation of *Acanthamoeba* isolates belonging to T2, T3, T4 and T7 genotypes from environmental samples in Ankara, Turkey. *Acta Parasitologica*. 2004;49(246):252.
- [21] Martinez AJ, Visvesvara GS: Free-living, amphizoic and opportunistic amebas. *Brain Pathology*. 1997;7:583–598.
- [22] Łanocha N, Kosik-Bogacka D, Maciejewska A, Sawczuk M, Wilk A, Kuźna-Grygiel W: The occurrence *Acanthamoeba* (free living amoeba) in environmental and respiratory samples in Poland. *Acta Protozoologica*. 2009;48(3):271–279.
- [23] Nagyová V, Nagy A, Janeček Š, Timko J: Morphological, physiological, molecular and phylogenetic characterization of new environmental isolates of *Acanthamoeba* spp. from the region of Bratislava, Slovakia. *Biologia*. 2010;65(1):81–91.
- [24] Mahmoudi MR, Taghipour N, Eftekhari M, Haghighi A, Karanis P: Isolation of *Acanthamoeba* species in surface waters of Gilan province-north of Iran. *Parasitology Research*. 2012;110(1):473–477.
- [25] Visvesvara GS, Moura H, Shuster FL: Pathogenic and opportunistic free-living amoebae: *Acanthamoeba* spp., *Balamuthia mandrillaris*, *Naegleria fowleri* and *Sappinia diploidea*. *FEMS Immunology and Medical Microbiology*. 2007;50:1–26.
- [26] Schuster FL, Visvesvara GS: Free-living amoebae as opportunistic and non-opportunistic pathogens of humans and animals. *International Journal for Parasitology*. 2004a;34:1001–1027.
- [27] Trabelsi H, Sellami A, Dendena F, Sellami H, Cheikh-rouhou F, Makni F, S. Ben Dhiaa Ayadi A: Free-living amoebae (FLA): morphological and molecular identification of *Acanthamoeba* in dental unit water. *Amibes libres : identification morphologique et moléculaire d'Acanthamoeba dans l'eau des unités dentaires*. *Parasite*. 2010;17:67–70.
- [28] Mazur T, Hadas E, Iwanicka I: The duration of the cyst stage and the viability and virulence of *Acanthamoeba* isolates. *Tropical Medicine and Parasitology*. 1995;46:106–108.
- [29] Poussard M, Pons R: Morphologies de la paroi kystique et taxonomie du genre *Acanthamoeba* (Protozoa, Amoebida). *Protistologica*. 1997;13:557–610.
- [30] Page FC: A New Key to Fresh Water and Soil Gymnamoebae, Freshwater Biological Association Scientific Publications, Ambleside. 1988;122.
- [31] Khan NA, Jarroll EL, Paget TA: Molecular and physiological differentiation between pathogenic and nonpathogenic *Acanthamoeba*, *Current Microbiology*. 2002;45:197–202.
- [32] Rivière D, Szczepara FM, Berjeaud JM, Frère J, Héchard Y: Development of a real-time PCR assay for quantification of *Acanthamoeba* trophozoites and cysts. *Journal of Microbiological Methods*. 2006; 64(1):78–83.

- [33] Risler A, Coupat-Goutaland B, Pelandakis M: Genotyping and phylogenetic analysis of *Acanthamoeba* isolates associated with keratitis. *Parasitology Research*. 2013;112(11):3807-3816.
- [34] Chappell CL, Wright JA, Coletta M, Newsome AL: Standardized method of measuring *Acanthamoeba* antibodies in sera from healthy human subjects. *Clinical and Diagnostic Laboratory Immunology*. 2001;8:724-730.
- [35] Brindley N, Matin A, Khan NA: *Acanthamoeba castellanii*: high antibody prevalence in racially and ethnically diverse populations. *Experimental Parasitology*. 2009;121:254-256.
- [36] Schuster FL, Visvesvara GS: Opportunistic amoebae: challenges in prophylaxis and treatment. *Drug Resistance Updates*. 2004b;7:41-51.
- [37] Teknos TN, Poulin MD, Laruentano AM, Li KK: *Acanthamoeba* rhinosinusitis: characterization, diagnosis and treatment. *American Journal of Rhinology*. 2000;14:387-391.
- [38] van Hamme C, Dumont M, Delos M, Lachapelle JM: Cutaneous acanthamoebiasis in a lung transplant patient. *Annales de Dermatologie et de Vénérologie*. 2001;128:1237-1240.
- [39] Chomicz L, Piekarczyk J, Starościak B, Fiedor P, Piekarczyk B, Szubińska D, Zawadzki PJ, Walski M: Comparative studies on the occurrence of protozoans, bacteria and fungi in the oral cavity of patients with systemic disorders. *Acta Parasitologica*. 2002;47:147-153.
- [40] Jones B, Visvesvara GS and Robinson NM: *Acanthamoeba polyphaga* keratitis and *Acanthamoeba* uveitis associated with fatal meningoencephalitis, *Transactions of the Ophthalmological Societies of the United Kingdom*. 1975;95:221-232.
- [41] Pellegrin JL, Ortega-Barria E, Barza M, Baum J, Pereira ME: Neuraminidase activity in *Acanthamoeba* species trophozoites and cysts. *Investigative Ophthalmology and Visual Science*. 1991;32:3061-3066.
- [42] Michalek M, Sönnichsen FD, Wechselberger R, Dingley AJ, Hung CW, Kopp A, Wienk H, Simanski M, Herbst R, Lorenzen I, Marciano-Cabral F, Gelhaus C, Gutschmann T, Tholey A, Grötzinger J, Leippe M: Structure and function of a unique pore-forming protein from a pathogenic *Acanthamoeba*. *Nature Chemical Biology*. 2013;9:37-42.
- [43] Aksozek A, McClellan K, Howard K: Resistance of *Acanthamoeba castellanii* cysts to physical, chemical and radiological conditions. *Journal of Parasitology*. 2002;88:621-623.
- [44] Szaflik JP, Padzik M, Chomicz L, Oledzka G, Izdebska J: Usefulness of *in vitro* diagnostics in difficult incidences of *Acanthamoeba* keratitis requiring pharmacotherapy and surgical management. *Okulistyka*. 2012;3:28-32.

- [45] Chomicz L, Padzik M, Graczyk Z, Starociak B, Graczyk T., Naprawska A, Olędzka G, Szostakowska B: *Acanthamoeba castellanii*: *in vitro* effects of selected biological, physical and chemical factors. *Experimental Parasitology*. 2010;126:103–105.
- [46] Walochnik J, Scheikl U, Haller-Schober EM: Twenty years of *Acanthamoeba* diagnostics in Austria. *Journal of Eukaryotic Microbiology*. 2015;62(1),3–11.
- [47] Padzik M, Chomicz L, Szaflik JP, Chruscikowska A, Perkowski K, Szaflik J: *In vitro* effects of selected contact lens care solutions on *Acanthamoeba castellanii* strains in Poland. *Experimental Parasitology*. 2014;145:98–101.
- [48] Witschel H, Sundmacher R, Seitz HM: Amebic keratitis: clinico-histopathologic case report. *Klinische Monatsblätter für Augenheilkunde*: 1984;185:46–49.
- [49] Moore MB, McCulley JB, Luckenbach M: *Acanthamoeba* keratitis associated with soft contact lenses. *American Journal of Ophthalmology*. 1985;100:396–403.
- [50] Chomicz L, Padzik M, Szaflik JP, Nahorski WL, Kryczka T, Szaflik J: Monitoring of *in vitro* dynamics of *Acanthamoeba* strains isolated from infected eyes as a useful tool in keratitis management. *Experimental Parasitology*. 2014;145:73–77.
- [51] Larkin DFP, Kilvington S, Easty L: Contamination of contact lens storage cases by *Acanthamoeba* and bacteria. *British Journal of Ophthalmology*. 1990;74:133–135.
- [52] Hiti K, Walochnik J, Haller-Schober EM, Faschinger C, Aspöck H: Viability of *Acanthamoeba* after exposure to a multipurpose disinfecting contact lens solution and two hydrogen peroxide systems. *British Journal of Ophthalmology*. 2002;86:144–146.
- [53] Hiti K, Walochnik J, Faschinger C, Haller-Schober EM, Aspöck H: One- and two-step hydrogen peroxide contact lens disinfection solutions against *Acanthamoeba*: how effective are they? *Eye*. 2005;19:1301–1305.
- [54] Chomicz L, Zebrowska J, Piekarczyk J, Starosciak B, Myjak P, Walski M, Kazimierzuk Z: *In vitro* studies on susceptibility of *Acanthamoeba castellanii* to selected chemical agents. *Acta Parasitologica*. 2005;50:25–31.
- [55] da Rocha-Azevedo B, Tanowitz HB, Marciano-Cabral F: Diagnosis of infections caused by pathogenic free-living amoebae. Hindawi Publishing Corporation. *Interdisciplinary Perspectives on Infectious Diseases*. 2009:1–14. ID 251406.
- [56] Winchester K, Mathers WD, Sutphin JE, Daley TE: Diagnosis of *Acanthamoeba* keratitis *in vivo* with confocal microscopy. *Cornea*. 1995;14(1):10–17.
- [57] Rezaei Kanavi M, Naghshgar N, Javadi MA, Sadat Hashemi M: Various confocal scan features of cysts and trophozoites in cases with *Acanthamoeba* keratitis. *European Journal of Ophthalmology*. 2012; 22:46–50.
- [58] Schuster FL: Cultivation of pathogenic and opportunistic free-living amebas. *Clinical Microbiology Reviews*. 2002;15(3):342–354.

- [59] Lass A, Szostakowska B, Idzińska A, Chomicz L: The first genotype determination of *Acanthamoeba* potential threat to human health, isolated from natural water reservoirs in Poland. *Parasitology Research*. 2014;113(7):2693-2699.
- [60] Walochnik J, Obwaller A, Aspöck H: Correlations between morphological, molecular biological, and physiological characteristics in clinical and nonclinical isolates of *Acanthamoeba* spp. *Applied and Environmental Microbiology*. 2000;66:4408-4413.
- [61] Lloyd D, Turner NA, Khunkitti W, Hann AC, Furr JR, Russell AD: Encystation in *Acanthamoeba castellanii*: development of biocide resistance. *Journal of Eukaryotic Microbiology*. 2001;48:11-16.
- [62] Kopanska K, Najda A, Zebrowska J, Chomicz L, Piekarczyk J, Myjak P, Bretner M: Synthesis and activity of 1H-benzimidazole and 1H-benzotriazole derivatives as inhibitors of *Acanthamoeba castellanii*. *Bioorganic & Medicinal Chemistry*. 2004;12:2617-2624.
- [63] Turner NA, Russell AD, Furr JR, Lloyd D: Emergence of resistance to biocides during differentiation of *A. castellanii*. *Journal of Antimicrobial Chemotherapy*. 2000;46:27-34.
- [64] Chomicz L, Szaflik JP, Padzik M, Oledzka G, Iwanczyk B, Szaflik J: Anti-amoebic chemotherapeutics and surgical procedures in *Acanthamoeba* keratitis difficult to diagnose. In: *Proceedings of 47th Congress of the European Society for Surgical Research*, 6-9 June, 2012, Lille, France. Medimond International Proceedings. 2012;55-57.
- [65] Yolton DP, Haesaert SP: Anti-infective drugs. Bartlett JD, Jaanus SD. *Clinical Ocular Pharmacology*. 5th ed. Elsevier. Butterworth Heinemann. 2008
- [66] Ficker L, Seal D, Warhurst D, Wright P: *Acanthamoeba* keratitis- resistance to medical therapy. *Eye*. 1990;4:835-838.
- [67] Chomicz L, Padzik M, Izdebska J, Baltaza W, Wroczynski P, Szaflik JP: *In vitro* activity of toyocamycin and novel thioinozine derivative as potential drugs against amoebic -the causative agents of *Acanthamoeba* keratitis. *The International Symposium on Ocular Pharmacology and Therapeutics*. 12th ISOPT Clinical, Berlin, Germany, July 9-12. Session: Inflammation and Infection, Abstracts. 2015;732.
- [68] Robaei D, Carnt N, Minassian DC, Dart JK: The impact of topical corticosteroid use before diagnosis on the outcome of *Acanthamoeba* keratitis. *Ophthalmology*. 2014;121(7):1383-1388.
- [69] Graffi S, Peretz A, Jabaly H, Naftali M: *Acanthamoeba* Keratitis. *Israel Medical Association Journal*. 2013; 15:182-185.
- [70] Sacher BA, Wagoner MD, Goins KM, Sutphin JE, Greiner MA, Kitzmann AS: Treatment of *Acanthamoeba* keratitis with intravenous pentamidine before therapeutic keratoplasty. *Cornea*. 2015;34(1):49-53.

- [71] Kitzmann AS, Goins KM, Sutphin JE, Wagoner MD: Keratoplasty for treatment of *Acanthamoeba* keratitis. *Ophthalmology*. 2009;116(5):864-869. doi:10.1016/j.opthta.2008.12.029.
- [72] Garduño-Vieyra L, González-Sánchez CR, Hernández-Da Mota SE: Ultraviolet-A light and riboflavin therapy for *Acanthamoeba* keratitis: a case report. *Case Reports in Ophthalmology*. 2011;2(2):291–295.
- [73] Khan YA, Kashiwabuchi RT, Martins SA, Castro-Combs JM, Kalyani S, Stanley P, Flikier D, Behrens A: Riboflavin and ultraviolet light a therapy as an adjuvant treatment for medically refractive *Acanthamoeba* keratitis: report of 3 cases. *Ophthalmology*. 2011;118(2),324–331.
- [74] Tabibian D, Richoz O, Hafezi F: PACK-CXL: Corneal cross-linking for treatment of infectious keratitis. *Journal Ophthalmic and Vision Research*. 2015;10(1):77-80.
- [75] Claerhout I, Goegebuer A, Van Den Broecke C., Kestelyn P: Delay in diagnosis and outcome of *Acanthamoeba* keratitis. *Graefes Archive for Clinical and Experimental Ophthalmology*. 2004;242(8):648-653.