

We are IntechOpen, the world's leading publisher of Open Access books Built by scientists, for scientists

6,900

Open access books available

185,000

International authors and editors

200M

Downloads

Our authors are among the

154

Countries delivered to

TOP 1%

most cited scientists

12.2%

Contributors from top 500 universities



WEB OF SCIENCE™

Selection of our books indexed in the Book Citation Index
in Web of Science™ Core Collection (BKCI)

Interested in publishing with us?
Contact book.department@intechopen.com

Numbers displayed above are based on latest data collected.
For more information visit www.intechopen.com



Laparoscopy in the Management of Colon Cancer

Valentin Ignatov, Anton Tonev, Nikola Kolev,
Aleksandar Zlatarov, Shteryu Shterev, Dilyan Petrov,
Tanya Kirilova and Krasimir Ivanov

Additional information is available at the end of the chapter

<http://dx.doi.org/10.5772/64507>

Abstract

The minimally invasive techniques in surgical practice have been well introduced and widely accepted for certain procedures, including surgery for colon cancer. The advantages of the laparoscopic approach in terms of early and late postoperative results and the oncological safety have been established by numerous reports, including randomized controlled trials. The application of laparoscopic colon surgery for cancer has been adopted in various institutions. This chapter reviews the available literature data regarding the use of minimally invasive surgery for colon cancer, including early and late surgical and oncological results and new trends. Retrospective and prospective trials published in the last 20 years are reviewed to address the issues. Technological advantages such as intracorporeal anastomosis, single incision, and natural orifice surgery are commented in the chapter.

Keywords: minimally invasive surgery, laparoscopy, colon cancer, hemicolectomy, colectomy, sigma resection

1. Introduction

The mainstay of treatment of colon cancer is the multidisciplinary approach. The advances of medical technology in various areas have led to improvement of cancer staging, surgical technique, medical oncology, and cancer biology. The logical consequence led to better treatment options. It was well stated in the article by Dinu et al. that a multidisciplinary team consisting of oncologists, surgeons, radiologists, physicists, and pathologists should provide the patient with a specific elaborate protocol of treatment, given the generally accepted treatment guidelines that are based on the efficacy of the multimodal treatment [1].

Reference	Procedure	Conversion to open surgery, % (number of total)		Operating time, min		Length of hospital stay, days		Postoperative morbidity, % (number of total)	
		HALS	LAC	HALS	LAC	HALS	LAC	HALS	LAC
HALS Study Group [♦] [3]	All	14% (3/22)	22% (4/18)	152 ± 66	141 ± 54	7 (2–12)	6 (2–10)	5% (1/22)	22% (4/18)
Hassan [♦] [6]	All	15% (16/109)	11% (17/149)	277 ± 96*	211 ± 108*	6 ± 3*	5 ± 3*	20% (18/109)	17% (11/149)
Segmental colectomy									
Targarona [10]	Left and right colectomy	7% (2/27)	7% (2/27)	140 ± 56 (70–300)	152 ± 34 (109–240)	6.5 ± 3.7	7.2 ± 3.9	26% (7/27)	22% (6/27)
Chang [14]	Sigmoidectomy/ left colectomy	0% (0/66)*	13% (11/85)*	189 ± 40 (120–290)	205 ± 60 (90–380)	5.2 ± 3.0 (3–22)	5.0 ± 2.4 (2–17)	21% (11/66)	16% (14/85)
Yano [16]	Low anterior resection	0% (0/5)	12.5% (1/8)	211 ± 48*	311 ± 78*	–	–	–	–
Lee [18]	Sigmoidectomy diverticulitis	4.8% (1/21)	14% (3/21)	171 ± 34*	197 ± 42*	6.7 ± 2.1	7.5 ± 8.2	24% (5/21)	19% (4/21)
Anderson [24]	Sigmoidectomy diverticulitis	6.1% (6/98)	23.5% (4/17)	142 ± 46.5	153 ± 40.4	5.0 ± 3.0	5.1 ± 3.3	14.6% (14/98)*	29.4% (5/17)*
Ringley [♦] [26]	Left and right colectomy	–	–	120 (78–181)*	156 (74–300)*	4 (2–11)	4 (2–14)	–	–
Tjandra [♦] [28]	Ultralow anterior resection	0% (0/32)	0% (0/31)	170 ± 20*	188 ± 16*	5.9 ± 0.8	5.8 ± 1.2	22% (7/32)	26% (8/31)
Total (procto)colectomy									
Nakajima [29]	Total (procto-)colectomy	0% (0/12)	9.1% (1/11)	217 ± 63*	281 ± 62*	7.6 ± 2.7	8.1 ± 2.4	33% (4/12)	45% (5/11)
Rivadeneira [30]	Proctocolectomy	10% (1/10)	0% (0/13)	265 ± 57 (210–390)*	311 ± 40 (240–400)*	6.1 ± 3.3 (3–13)	7.2 ± 3.9 (4–17)	40% (4/10)	31% (4/13)
Boushey [♦] [31]	Total (procto-)colectomy	2% (1/45)*	7% (6/85)*	TAC: 240 ± 49 TPC: 297 ± 52	271 ± 60 315 ± 70	TAC: 6 (3–34) TPC: 5 (4–14)	5 (4–25) 5 (3–24)	TAC: 24% (4/17) TPC: 32% (9/28)	35% (18/52) 24% (8/33)
Polle [32]	Total restorative proctocolectomy	0% (0/30)	0% (0/35)	231 ± 60 (149–400)	297 ± 38.5 (235–375)	11.8 ± 5.7 (5–31)			

Table 1. Characteristics of HALS and LAC in several studies included in the metaanalysis on hand-assisted and laparoscopic assisted approach in colorectal surgery by Aalbers et al. [33].

Laparoscopic approach is used with increased frequency for many surgical procedures. The laparoscopic colectomy follows the principles of open oncological surgery – low ligation of the blood vessels at their origin and no-touch isolation [2]. Usually the anastomosis for right-colon tumors is performed extracorporally, and thus minimal laparotomy is required. The laparoscopic technique decreases length of hospital stay and pain and allows sooner restoration of food intake. Laparoscopy can be safely used if the following criteria are absent: severe adhesions, advanced tumor (e.g., T4), and/or complicated colon cancer. The similarity between oncological results and the defined short-term clinical advantages of laparoscopic and open surgery for colon cancer have been proven in various multicenter studies. [14]. The patients with previous abdominal surgery (PAS) are at risk due to severe adhesions. The laparoscopic adhesiolysis is more technically challenging and time consuming. The study of Zanghi et al. reviews that matter and concludes that laparoscopic adhesiolysis increases the risk of bowel injury [7]. PAS is not universally accepted as contraindication for laparoscopic surgery, although it complicates the procedure as a whole. Law et al. reported patients with PAS who did not develop short-term postoperative complications such as ileus, prolonged hospital stay, or conversion rate after colorectal surgery [4]. In contrast, Yamamoto et al. described relatively higher rates of intraoperative intestinal injury and postoperative complications, including ileus and delayed time to diet in patients with a history of abdominal surgery [5] (**Table 1**).

2. Laparoscopy for colon cancer

2.1. Patients

In results from a single-center study from Tajima et al., patients were compared according to their age, gender, and tumor location between the hand-assisted laparoscopy (HALS) and CL groups [8] (**Table 2**). Less bleeding during surgery, faster postoperative recovery, and shorter stay are some of numerous advantages of laparoscopic resection of colon. After all, there are doubts of the radical curative effect of complete tumor resection, lymph node dissection, and puncture implantation metastasis by laparoscopic surgery. However, the most important indicator for the radical curative effect of laparoscopic surgery is the number of dissected lymph nodes. CRM is significant for the assessing of the prognosis of colorectal cancer surgery. The long-term survival rate of colorectal cancer patients undergoing laparoscopic surgery compared to open surgery procedures is also analyzed. No statistical difference in 3- or 5-year OS and 3-or 5-year DFS between the two procedures was reported ($P>0.05$) [8].

Surgical time of colorectal cancer laparoscopic surgery is longer compared to open surgery, and laparoscopic surgery requires a more skilful surgeon. The surgeons undergo rigorous training and development for a period of time, which improves the surgical procedure [9]. Also the nonneoplasm technique is important, which is the same as the open surgery is. The previously used method for the quality assessment with digital score may cause deviation.

Surgical methods	HALS, % (n)	CL, % (n)	P-value
Right hemicolectomy	26.5 (26)	24.6 (28)	0.743
Transverse colectomy	2.0 (2)	7.0 (8)	0.088
Left hemicolectomy	8.2 (8)	7.0 (8)	0.753
Anterior resection	27.6 (27)	33.3 (38)	0.363

Table 2. Comparison of stage I/II/III patients (n = 145) who underwent HALS (n = 63) or CL (n = 82).

2.2. Hand-Assisted Laparoscopic Surgery

Over the last years, minimally invasive laparoscopic surgery is being used more and more. Additional bowel resection for stage I rectal cancer, radical resection of stage II or III rectal cancer, and palliative surgery in patients with stage IV rectal cancer are among the indications of laparoscopic surgery. Traditional laparotomy for rectal cancer makes it difficult to visualize certain areas, including the pelvic floor, the ventral part of the bladder, and the posterior to apical regions of the prostate.

The traditional laparoscopic approach has been well established. In some cases a hybrid approach is required, e.g., rectal cancer surgery. The traditional laparotomy may reveal certain anatomical areas. On the other hand, the laparoscope provides magnified view of the structures and allows for safer approach. Laparoscopy-assisted colorectal surgery (LACS) is used in Japan and several drawbacks are reported – is more time consuming and requires specific experience and technical equipment, which makes it more challenging. In Europe and the United States, the so-called hybrid-hand assisted laparoscopic surgery (HALS) is more widespread, which allows for direct vision. The advantages of HALS include direct safe palpation and grasping with the hand, shorter operative time, and shorter learning-curve.

2.3. Outcomes

2.3.1. Short-term benefits of laparoscopic surgery

Laparoscopic procedures have several short-term benefits that are well described in all reports on the topic of minimally invasive procedures. Those include earlier restoration of bowel function, oral food intake, smaller incision, and less operative trauma (therefore less need for analgesia) and were proven in various randomized control trials. In the case of cancer surgery, the laparoscopic approach allows for faster recovery, which may influence the oncological results by sooner initiation of systemic therapy. The hospital stay is shorter in comparison to open surgery. In elderly and comorbid patients, the laparoscopic surgery may lead to cardiovascular and pulmonary complications, although the mortality and morbidity rates are lower than in open surgery.

2.3.2. Long-term outcomes

Oncological outcomes of LS and OS for colorectal cancer patients were similar in most randomized studies. The random trial conducted by Lacy et al. [11] showed excellent long-

term oncologic outcomes following LS, when compared with OS in patients with curable colon cancer. This study had a median follow-up of 95 months, but there was only one difference between the two techniques including the higher survival rate of patients with stage III colon cancer.

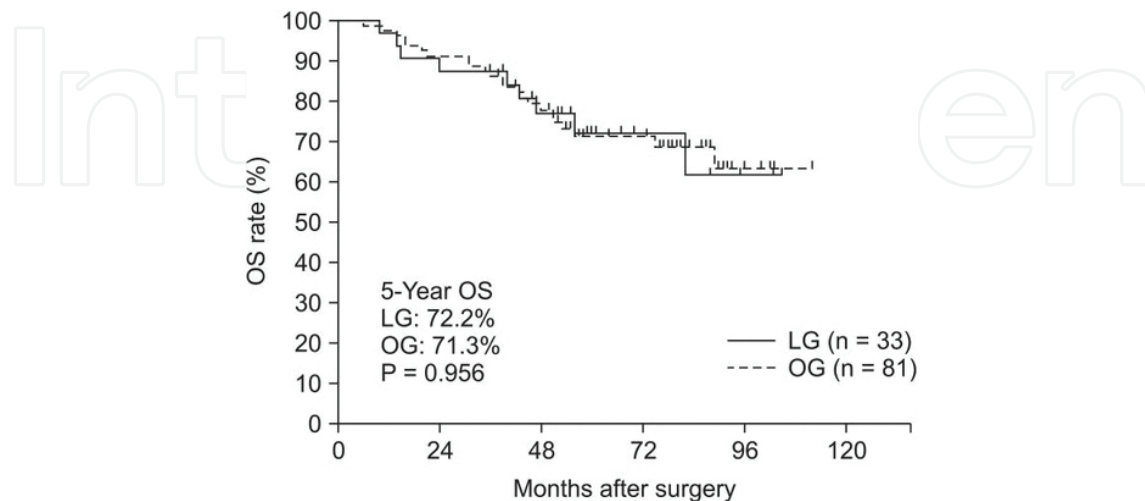


Figure 1. Overall survival (OS) of stage III colon cancer patients. LG, laparoscopic surgery group; OG, open surgery group [11].

The oncologic outcomes after performing LS instead of OS are still being analyzed when treating colorectal cancer patients. Recurrences and disease-free and overall survivals following LS compared to OS for stage III colorectal cancer patients are shown on **Figure 1** [11].

The long-term results are similar for laparoscopy and open surgery. On the contrary, a study made by Lacy et al. [11] has noted some oncological benefits for stage III colon cancer, including better local recurrence rates and higher rates of long-term and overall survival. For stage I and II, there were no significant oncological differences. Those results could be explained by patient's immunity response, dissemination of cancer cells, and earlier start of systemic treatment. The rates of local and distant metastases are found to be lower after laparoscopic surgery [12]. Despite that peritoneal carcinomatosis rates remain the same. The local recurrence rate of right colon cancer is relatively higher in compared to the left localization, although this is not confirmed by randomized studies [13].

3. New trends

3.1. SILS

The increasing patients' interest in cosmetic results has led to the more frequent use of single-incision surgery, even for colon cancer. The ultimate goal of "scarless surgery" could be achieved only when oncological results are proven to be equivalent to standard laparoscopic surgery. SILS ports are placed at the umbilicus or in case of rectal cancer at the planned site of

a stoma. SILS reduces the abdominal incision trauma, provides better cosmesis, and reportedly, shorter hospital stay. SILS approach is successfully applied in laparoscopic colorectal procedures. For last few years, there are more data about this approach, which confirmed benefits of and interests in this technique. The SILS technique is administered to patients and the achieved results are promising. The development of SILS went from simple surgical procedures to the first colorectal resections in 2008. The first sigmoidectomy for benign disease was performed by Bucher et al. [17]. This approach was also used for anterior rectal resection, proctocolectomy, and total proctocolectomy. Lu C-C et al. as well as some other authors suggested that SILS could be applied both for benign and malignant cases [17, 20, 22, 23].

The operative time compared to conventional laparoscopic surgery is varying, and according to some retrospective studies the difference is not statistically significant. The operative time yet is longer, regardless of the procedure according to a study by Kwag et al [20]. The difference of operative times could be explained also by the fact that this techniques is not that widely used and the learning curve is steeper. Other criteria such as pain are reported to be more severe after SILS [20], although other authors report decrease of pain [22, 23].

4. NOTES

The first human colorectal natural orifice endoscopic surgery (NOTES) procedure was initiated with the reports of Bernhardt et al. [19] and Palanivelu et al. [25], who performed appendectomy in 2008. Performance of more complex procedures was limited by the instrumentation. In addition the colorectal procedures require restoration of continuity, which is a major limitation for NOTES. The hybrid NOTES procedures such as trans- anal total mesocolic excision (TEM) broaden the possibilities for this technique (**Figure 2**).

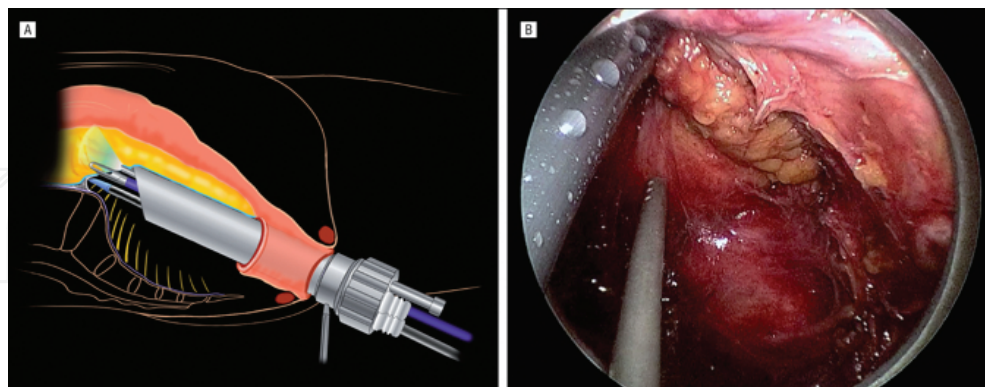


Figure 2. Schematic of retroperitoneal dissection with the transluminal transanal endoscopic operation device (A) and intraoperative view of the retroperitoneal approach at the sacral promontory (B) [24].

SILS evolved starting with cadavers and swines [25]. Sylla et al. [15] reported successful total mesorectum excision (TME) with laparoscopic assistance in a human. Two cases of laparoscopically assisted transanal TME were reported by Dumont et al. [21]. The clinical and oncological advantages are yet to be analyzed [2, 27–29].

Alternative technique is the mini-laparoscopy-assisted natural orifice surgery (MA-NOS), which includes additional laparoscopic ports less than 5mm and main port inserted in the natural orifice. The largest port is placed in the natural orifice. Lacy et al. [27] has pioneered this technique and presented a case of total colectomy. The authors suggest that the lack of dedicated NOTES instruments requires laparoscopic assistance.

5. Summary

Laparoscopic colon resection for cancer can be performed safely and accurately with many short-term benefits to the patients while resulting in at least equivalent long-term results as open surgery procedures. Other potential benefits may include better preservation of cell-mediated immune function and reduced tumor cell proliferation. The scientific confirmation of the efficacy of laparoscopic surgery is needed to implement it further in the practice and accept it as a worldwide standard. The available level 1 data support safety, patient-related benefits, and oncological similarity. Innovative approaches are being tested, including less abdominal wall trauma. Mastering the laparoscopic approach still has a steep learning curve, although the even more available laparoscopic courses will diminish that issue.

Author details

Valentin Ignatov, Anton Tonev*, Nikola Kolev, Aleksandar Zlatarov, Shteryu Shterev, Dilyan Petrov, Tanya Kirilova and Krasimir Ivanov

*Address all correspondence to: teraton@abv.bg

Department of General and Operative Surgery, Medical University of Varna, Varna, Bulgaria

References

- [1] Therapeutic strategies in colonic cancer. *Chir Buchar Rom* 1990. 2014 Dec;109(6):741–6.
- [2] García- Valdecasas JC, Delgado S, Castells A, Taurá P, Piqué JM,. Laparoscopy-assisted colectomy versus open colectomy for treatment of non-metastatic colon cancer: a randomised trial. *The Lancet*. 2002 Jun 29;359(9325):2224–9.
- [3] HALS Study Group (2000) Hand-assisted laparoscopic surgery vs. standard laparoscopic surgery for colorectal disease: a prospective randomized trial. *Surg Endosc* 14:896–901 CrossRef

- [4] Law WL, Lee YM, Chu KW. Previous abdominal operations do not affect the outcomes of laparoscopic colorectal surgery. *Surg Endosc Interv Tech*. 2005;19(3):326–30.
- [5] Yamamoto M, Okuda J, Tanaka K, Kondo K, Asai K, Kayano H, . Effect of Previous Abdominal Surgery on Outcomes Following Laparoscopic Colorectal Surgery: Dis Colon Rectum. 2013 Mar;56(3):336–42.
- [6] Hassan I, Nancy You Y, Cima RR, Larson DW, Dozois EJ, Barnes SA, Pemberton JH (2007) Hand-assisted versus laparoscopic-assisted colorectal surgery: practice patterns and clinical outcomes in a minimally-invasive colorectal practice. *Surg Endosc* Aug [Epub ahead of print]
- [7] Zanghi A, Cavallaro A, Piccolo G, Fisichella R, Di Vita M, Spartà D, . Dissemination metastasis after laparoscopic colorectal surgery versus conventional open surgery for colorectal cancer: a metaanalysis. *Eur Rev Med Pharmacol Sci*. 2013 May;17(9):1174–84.
- [8] Tajima T, Mukai M, Noguchi W, Higami S, Uda S, Yamamoto S, . Comparison of hand-assisted laparoscopic surgery and conventional laparotomy for rectal cancer: Interim results from a single center. *Mol Clin Oncol* [Internet]. 2015 Feb 9 [cited 2016 Feb 5]; Available from: <http://www.spandidos-publications.com/10.3892/mco.2015.508>
- [9] Lee S. Laparoscopic Procedures for Colon and Rectal Cancer Surgery. *Clin Colon Rectal Surg*. 2009 Nov;22(04):218–24.
- [10] Targarona EM, Gracia E, Garriga J, Martinez-Bru C, Cortes M, Boluda R, Lerma L, Trias M (2002) Prospective randomized trial comparing conventional laparoscopic colectomy with hand-assisted laparoscopic colectomy: applicability, immediate clinical outcome, inflammatory response, and cost. *Surg Endosc* 16:234–239 PubMed Cross Ref.
- [11] Lacy AM, Delgado S, Castells A, Prins HA, Arroyo V, Ibarzabal A, . The long-term results of a randomized clinical trial of laparoscopy-assisted versus open surgery for colon cancer. *Ann Surg*. 2008 Jul;248(1):1–7.
- [12] Baek J-H, Lee G-J, Lee W-S. Comparison of long-term oncologic outcomes of stage III colorectal cancer following laparoscopic versus open surgery. *Ann Surg Treat Res*. 2015;88(1):8.
- [13] Guerrieri M, Campagnacci R, De Sanctis A, Lezoche G, Massucco P, Summa M, . Laparoscopic versus open colectomy for TNM stage III colon cancer: results of a prospective multicenter study in Italy. *Surg Today*. 2012 Nov;42(11):1071–7.
- [14] Chang YJ, Marcello PW, Rusin LC, Roberts PL, Schoetz DJ (2005) Hand-assisted laparoscopic sigmoid colectomy: helping hand or hindrance? *Surg Endosc* 19:656–661 PubMed CrossRef.
- [15] Sylla P, Bordeianou LG, Berger D, Han KS, Lauwers GY, Sahani DV, . A pilot study of natural orifice transanal endoscopic total mesorectal excision with laparoscopic assistance for rectal cancer. *Surg Endosc*. 2013 Sep;27(9):3396–405.

- [16] Yano H, Ohnishi T, Kanoh T, Monden T (2005) Hand-assisted laparoscopic low anterior resection for rectal carcinoma. *J Laparoendosc Adv Surg Tech A* 15:611–614 PubMed CrossRef.
- [17] Bucher P, Pugin F, Morel P. Single port access laparoscopic right hemicolectomy. *Int J Colorectal Dis.* 2008 Oct;23(10):1013–6.
- [18] Lee SW, Yoo J, Dujovny N, Sonoda T, Milsom JW (2006) Laparoscopic vs. hand-assisted laparoscopic sigmoidectomy for diverticulitis. *Dis Colon Rectum* 49:464–469 PubMed CrossRef.
- [19] Bernhardt J, Gerber B, Schober H-C, Kähler G, Ludwig K. NOTES--case report of a unidirectional flexible appendectomy. *Int J Colorectal Dis.* 2008 May;23(5):547–50.
- [20] Kwag S-J, Kim J-G, Oh S-T, Kang W-K. Single incision vs conventional laparoscopic anterior resection for sigmoid colon cancer: a case-matched study. *Am J Surg.* 2013 Sep; 206(3):320–5.
- [21] Dumont F, Goéré D, Honoré C, Elias D. Transanal endoscopic total mesorectal excision combined with single-port laparoscopy. *Dis Colon Rectum.* 2012 Sep;55(9):996–1001.
- [22] Kim S-J, Ryu G-O, Choi B-J, Kim J-G, Lee K-J, Lee SC, . The short-term outcomes of conventional and single-port laparoscopic surgery for colorectal cancer. *Ann Surg.* 2011 Dec;254(6):933–40.
- [23] Lu C-C, Lin S-E, Chung K-C, Rau K-M. Comparison of clinical outcome of single-incision laparoscopic surgery using a simplified access system with conventional laparoscopic surgery for malignant colorectal disease: Single-incision laparoscopic colectomy. *Colorectal Dis.* 2012 Apr;14(4):e171–6.
- [24] Anderson J, Luchtefeld M, Dujovny N, Hoedema R, Kim D, Butcher J (2007) A comparison of laparoscopic, hand-assist and open sigmoid resection in the treatment of diverticular disease. *Am J Surg* 193:400–403 PubMed CrossRef.
- [25] Palanivelu C, Rajan PS, Rangarajan M, Parthasarathi R, Senthilnathan P, Prasad M. Transvaginal endoscopic appendectomy in humans: a unique approach to NOTES--world's first report. *Surg Endosc.* 2008 May;22(5):1343–7.
- [26] Ringley C, Lee YK, Iqbal A, Bocharov V, Sasson A, McBride CL, Thompson JS, Vitamvas ML, Oleynikov D (2007) Comparison of conventional laparoscopic and hand-assisted oncologic segmental colonic resection. *Surg Endosc* 24: Epub ahead of print.
- [27] Lacy AM, Adelsdorfer C, Delgado S, Sylla P, Rattner DW. Minilaparoscopy-assisted transrectal low anterior resection (LAR): a preliminary study. *Surg Endosc.* 2013 Jan; 27(1):339–46.
- [28] Tjandra JJ, Chan MKY, Yeh CH (2007) Laparoscopic-vs. hand-assisted ultralow anterior resection: a prospective study. *Dis Colon Rectum* Dec [Epub ahead of print]

- [29] Nakajima K, Lee SW, Cocilovo C, Foglia C, Sonoda T, Milsom JW (2004) Laparoscopic total colectomy: hand-assisted vs. standard technique. *Surg Endosc* 18:582–586 PubMed CrossRef
- [30] Rivadeneira DE, Marcello PW, Roberts PL, Rusin LC, Murray JJ, Collier JA, Schoetz DJ Jr (2004) Benefits of hand-assisted laparoscopic restorative proctocolectomy: a comparative study. *Dis Colon Rectum* 47:1371–1376 PubMed CrossRef
- [31] Boushey RP, Marcello PW, Martel G, Rusin LC, Roberts PL, Schoetz DJ Jr (2007) Laparoscopic total colectomy: an evolutionary experience. *Dis Colon Rectum* 50: 1512–1519 PubMed CrossRef
- [32] Polle SW, van Berge Henegouwen MI, Slors FM, Cuesta MA, Gouma DJ, Bemelman WA (2008) Total laparoscopic restorative proctocolectomy: are there any advantages compared with the open and hand-assisted approach? *Dis Colon Rectum* [Epub ahead of print]
- [33] Aalbers AGJ, Biere SSAY, van Berge Henegouwen MI, Bemelman WA. Hand-assisted or laparoscopic-assisted approach in colorectal surgery: a systematic review and meta-analysis. *Surg Endosc.* 2008;22(8):1769–80.