

We are IntechOpen, the world's leading publisher of Open Access books Built by scientists, for scientists

6,900

Open access books available

186,000

International authors and editors

200M

Downloads

Our authors are among the

154

Countries delivered to

TOP 1%

most cited scientists

12.2%

Contributors from top 500 universities



WEB OF SCIENCE™

Selection of our books indexed in the Book Citation Index
in Web of Science™ Core Collection (BKCI)

Interested in publishing with us?
Contact book.department@intechopen.com

Numbers displayed above are based on latest data collected.
For more information visit www.intechopen.com



What Clinical Strategies are Applied for Botulinum Toxin Injection in the Oromandibular Region?

Merete Bakke, Torben Dalager and Eigild Møller

Additional information is available at the end of the chapter

<http://dx.doi.org/10.5772/64271>

Abstract

Botulinum neurotoxin (BoNT) inhibits the release of acetylcholine from cholinergic nerve terminals in muscles or salivary glands. With reduced activation, the muscle activity or secretion decreases. Indications for medical, non-cosmetic use of BoNT in the orofacial area include among others oromandibular dystonia, painful masseter hypertrophy, Frey's syndrome, and severe drooling. The chapter covers anamnestic characteristics of these conditions as well as clinical, electromyographic (EMG) and laboratory findings, treatment methods with guided injections, and outcome from systematic treatment controls and follow-up examinations.

Keywords: dystonia, drooling, Frey's syndrome, masticatory muscles, salivary glands

1. Introduction

There are a limited number of publications concerning botulinum neurotoxin (BoNT) treatment in the oromandibular region, probably due to an overlap between the working areas for dentists and medical specialists. This chapter presents various neurological and neuromuscular conditions that may benefit from treatment with BoNT, and strategies developed for such treatment based on the collaboration between dental, neurological, and neurophysiological specialists in hospitals and university clinics.

In addition to its action at cholinergic motor endings, acetylcholine is also an important neurotransmitter in the autonomic nervous system. Thus, BoNT can be injected into muscles and salivary glands to achieve therapeutic benefit in a large range of clinical conditions in the oromandibular region such as dystonia, spasticity, and drooling. With reduced or blocked

release of acetylcholine, the signals from the nervous system to the muscles or glands are decreased. This results in a temporary functional denervation of the muscle fibers with inhibition of the contractions and paralysis, and a temporary functional denervation of the salivary glands with reduced secretion. In the oromandibular region with small muscle groups, vital functions, and delicate anatomical structures, precise injection of the BoNT is crucial. Diffusion at injection site and spread to unintended areas may lead to significant although temporary discomfort. Such problems are most often swallowing difficulties due to effect on adjacent muscle groups or dry mouth from displacement into salivary glands. Therefore, it is strongly advocated to use guidance of the injections by EMG and/or ultrasonography to avoid off-target side effects and to secure effective placing of BoNT.

The latency for the full effect on the muscles after injection of BoNT is about a week, and the effect is optimal within the first 1.5–2 months. Since neuromuscular transmission regenerates slowly, muscle function is restored and the effect ceased after 3–6 months. Therefore, BoNT treatments are typically repeated up to three to four times per year. Inhibition of the release of acetylcholine from the postganglionic parasympathetic nerve ending to the salivary glands and the effect on the salivary secretions has a similar course [1, 2, 21]. BoNT/A, onabotulinumtoxinA (A/Ona), abobotulinumtoxinA (A/Abo), incobotulinumtoxinA (A/Inco), and BoNT/B, rimabotulinumtoxinB (B/Rima) are used for the treatment of muscles and salivary glands. There may be a small risk of developing antibodies and immunity by repeated treatments with the same type of BoNT. Therefore, it is generally recommended to have an interval of at least 3 months between treatments. If the patient seems to develop resistance to one type of BoNT, so that treatment is ineffective, the other is attempted [1].

Unlike other drugs, there is no direct correlation between the dosage units for the various compositions of BoNT. Depending on the preparation, there may be up to 50-fold difference in the number of units for the same treatment. Thus, the recommended dose is specific to the individual preparations. Storage and dilution differ also for the different compositions. Therefore, instructions for each preparation must be reviewed carefully to avoid mistakes, and the substance for injection must be diluted with saline corresponding to the needed units and the target for the treatment.

2. Oromandibular muscles

BoNT/A is the preferred choice for the muscles in the oromandibular region [3]. In most cases, the indication for such treatment is based on electromyographic (EMG) examination with bipolar surface electrodes and/or concentric needle electrodes. The indication for treating a muscle is abnormally increased spontaneous activity. This is defined partly as a mean level significantly above the reference for postural activity and partly as an activity pattern with more than 100 turns per second [4]. The dose depends on the activity and volume of the muscles (**Figure 1**) [1, 5–7]. When treating a muscle in a patient for the first time, the dose is usually low. In the following treatments, it is adjusted individually corresponding to the effect. This strategy not only reduces the possibility of side effects but also minimizes the cost.

Oromandibular muscles	Maximal voluntary contraction	Units of A/Ona or A/Inco
Temporalis	Jaw closing	10-45
Masseter		
Medial pterygoid		
Anterior digastric	Jaw opening	5-10
Lateral pterygoid	Jaw opening, side movement and protrusion	10-45
Orbicularis oris	Lip pursing	5-10

Figure 1. Oromandibular muscles, their maximal activation, and recommended doses of BoNT/A. Units are shown for one muscle in one side and for the orbicularis oris muscle for each side of the upper and lower part of the lip. It is advisable to start treatment with a low dose when treating a muscle in a patient for the first time. The patient should be informed that injections into the digastric muscle may give temporary swallowing difficulties. A/Ona: onabotulinumtoxinA and A/Inco: incobotulinumtoxinA. For A/Abo (abobotulinumtoxinA) is the dose probably 2.5 times higher [7].

The BoNT is injected as a bolus with cannulated electrodes and EMG guidance. One injection site is normally sufficient in the oromandibular muscles. If unfamiliar with the possible injection site in the oromandibular muscles, the procedures become easier after checking the locations and anatomic details of the targeted muscles, and if possible, to palpate them during maximal voluntary contraction (see **Figure 1**).

The site for the percutaneous injection into the masseter is the lower half of the superficial part, for the anterior voluminous part of the temporalis muscle, for the medial pterygoid muscle on the medial side of the ramus above its fusion with the masseter to form a common tendinous sling, and for the anterior belly of the digastric muscle. With respect to the orbicularis oris muscles, the injections are placed in the protruding parts but just above (upper lip) or below (lower lip) the carmine margin of the lip. The lateral (external) pterygoid is best approached intraorally to have direct access for palpation and injection. The direction of the needle insertion is posteriorly and slightly laterally in parallel with the buccal surfaces of the maxillary molars. Sometimes a more problematic percutaneous approach for the lateral pterygoid muscle is used with injection in front of the tragus and the mandibular condyle. However, with the intraoral approach, there is less vasculature encountered, and the risk of injecting several branches of the trigeminal and facial nerves is reduced, as well as injecting the parotid gland (that may lead to mouth dryness) [8]. In addition, the intraoral approach allows recording during chewing as well as opening and lateral movements of the mandible [9]; (**Figure 1**). When the cannulated electrode is inserted, the position is verified by the presence of well-defined sharp spikes with high EMG amplitude during posture. Subsequently, the level of maximal activity is recorded to ascertain a normal interference pattern during maximal effort of the muscle, that is, strong biting, jaw opening, lateral jaw movement, or pursing of the lips.

2.1. Temporomandibular disorders (TMD)

As TMDs are the most common disorders in the oromandibular region, they should be mentioned shortly. The prevalence in the adult population is 8–15% [10]. TMD are recognized as a group of musculoskeletal and neuromuscular conditions that involve the temporomandibular joints, the masticatory muscles, and associated tissues [11]. The signs and symptoms of TMD are orofacial pain and impaired jaw function, and they may be confused with other conditions in the orofacial region. However, in contrast to the other conditions mentioned in this chapter, BoNT treatment does not seem to have a significant role in the treatment of TMD and episodic tension headaches, and evidence on the effect of BoNT on most orofacial pain conditions is lacking [12, 13].

2.2. Painful bilateral masseter hypertrophy

Benign masseter hypertrophy is characterized by a soft swelling near the angle of the mandible. It is relatively uncommon and may occur unilaterally or bilaterally [14]. The swelling can be so prominent that it is considered cosmetically disfiguring. Occasionally, there are also pain symptoms. The condition may be associated with clenching and bruxism but often it is idiopathic. Diagnosis of masseter hypertrophy should not be based on the clinical findings alone as differential diagnoses are conditions such as tumors in the muscle and parotid gland. The diagnosis should be supported by imaging with ultrasonic or magnetic resonance scanning. Various treatment options have been reported including surgical reduction, while injection of BoNT/A into the masseter muscle represents a less invasive modality [15, 16].

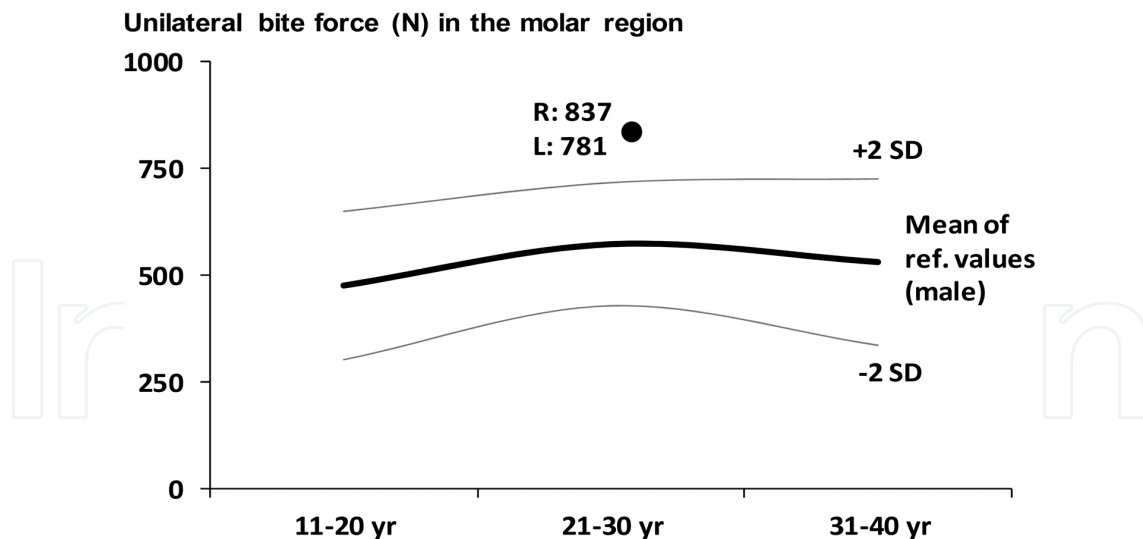


Figure 2. Increased bite force in a young man with painful masseter hypertrophy. Recording of maximum unilateral clenching force during 1–2 s biting on a strain-gauge transducer in the right and left molar region before treatment with indications of reference values (M and SD; average of stored peak values) [17].

To illustrate the treatment strategy with BoNT for this condition, a case with a 24-year-old male student is presented. He developed increasing masseter hypertrophy through some years with high mental stress. The condition was painful and associated with a feeling of jaw tension. In

addition, he reported sleep bruxism. The hypertrophy was documented by ultrasonic scanning of the muscle structure. Examinations of the muscle function with bite-force measurements and EMG of the masseter muscles showed increased values (**Figure 2**). The increased muscle volume was ascribed to his sleep bruxism, based on reports from his companions, and as the dental attrition was greater than might be expected from his age. Treatment was performed with BoNT/A injections into the masseter muscles. At the first treatment, the dose was low, 20 units A/Ona in each masseter. The intramuscular injections were repeated twice with 3–4 months intervals with 30 units A/Ona in each masseter to a total of three treatment series. No further BoNT treatment was necessary as the pain and the thickness of the muscles were reduced (**Figure 3A** and **B**). After the BoNT treatments, a bite splint was provided to reduce further dental attrition as he still had episodes with grinding of his teeth during sleep.

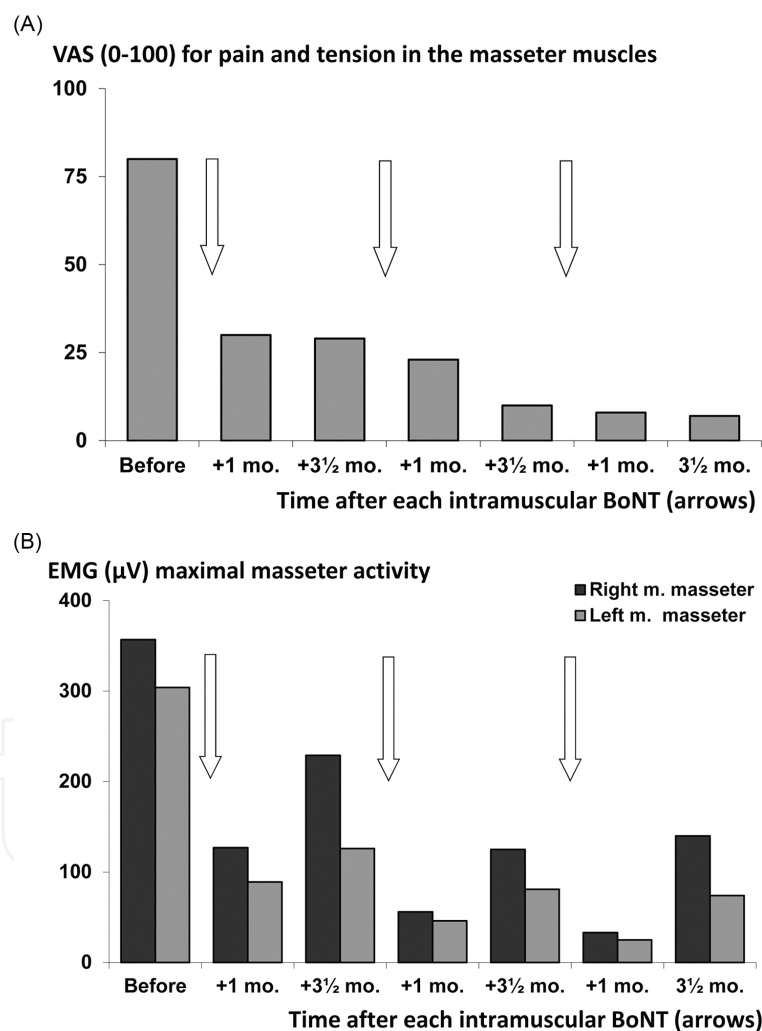


Figure 3. Jaw pain and muscle activity in a young man with painful masseter hypertrophy treated with intramuscular BoNT injection. (A) Jaw pain and feelings of jaw tension recorded on horizontal visual analog scales (VAS) before treatment and at controls during the treatment period. (B) Recordings with surface electromyography from right and left masseter muscles during maximum biting in the intercuspal position measured before treatment and at controls during the treatment period. Reference value is M: 250 μV, SD: 180 μV (bipolar electrodes, mean voltage; custom-designed 8-channel EMG system; Electromyographic Laboratory, Dept. of Odontology, University of Copenhagen) [18].

2.3. Oromandibular dystonia (OMD)

OMD is a rare focal neurological disorder affecting the lower part of the face and jaws. It is characterized by sustained or repetitive involuntary jaw and tongue movements and facial grimacing, caused by involuntary activity of the masticatory, facial, pharyngeal, lingual, and lip muscles [19]. The dystonic activity may look similar to idiopathic sleep bruxism but it usually ceases during sleep. Dystonia is thought to be derived from dysfunction of the basal ganglia, and the excess movements to be due to loss of inhibitory motor control. Neurophysiologic and neuroimaging studies have shown abnormalities at cortical and subcortical levels, probably reflecting a dysfunction in the basal ganglia-thalamo-cortical circuits. However, peripheral mechanisms and abnormal sensorimotor integration or somatosensory dysfunction may occur in dystonia and aggravate the disorder [20].

OMD is typically classified as jaw opening, jaw closing, jaw deviating, or lingual dystonia (tongue protrusion or curling) or combinations of these [8]. The combination of OMD, blepharospasms (sustained, forced, involuntary closing of the eyelids), and dystonic movements of the upper face is known as Meige's syndrome [6]. OMD often interferes with normal orofacial function, such as chewing and control of food bolus, swallowing, and verbal and nonverbal communication. EMG recordings have shown high spontaneous and deviating masticatory muscle activity with co-contractions of antagonists and loss of rhythmicity during chewing [5, 19]. Depending on the subtype, OMD may lead to trauma and damage of the structures of the oral cavity, dental restorations, and dentures. Thus, jaw-closing dystonia may result in excessive dental wear, dental fractures, and trauma of the lips, gums, and tongue, whereas jaw-opening dystonia may be associated with temporomandibular joint overload and dislocations. Consequently, there is need for both dental and neurological efforts as well as collaboration between the two professions, although the diagnosis is neurological.

To illustrate the diversity of oromandibular dystonia and the need for careful control of BoNT treatment, two patients are presented in the following section. First patient is a woman with focal oromandibular dystonia and blepharospasms. She was referred for examination 15 years earlier when she was 60 years. Her condition started 5 years previously in the eye region. Later chewing and swallowing problems arose. In addition, constant and strong biting and grinding movements developed, causing fractures of dental restorations and severe attrition of the teeth. She used a bite splint but her dentition was also challenged by her drug-induced hyposalivation that contributed to increased caries activity and dental erosions. Besides clonazepam for the dystonia, she was also medicated with psychoactive drugs and BoNT for the blepharospasms. She felt her dystonia as a severe handicap and therefore quit her job as secretary. Her dystonia changed over the 15 years (**Figure 4**). It grew worse also including the lips.

The BoNT/A injections were adjusted accordingly and were able to reduce the high spontaneous activity (**Figure 5**). In spite of the regular treatments, 3.3 BoNT series per year, the dentition deteriorated and was reduced from consisting of a full complement of 29 with only 3 wisdom tooth missing, to 5 remaining natural tooth and prosthetic restorations (**Figure 6**).

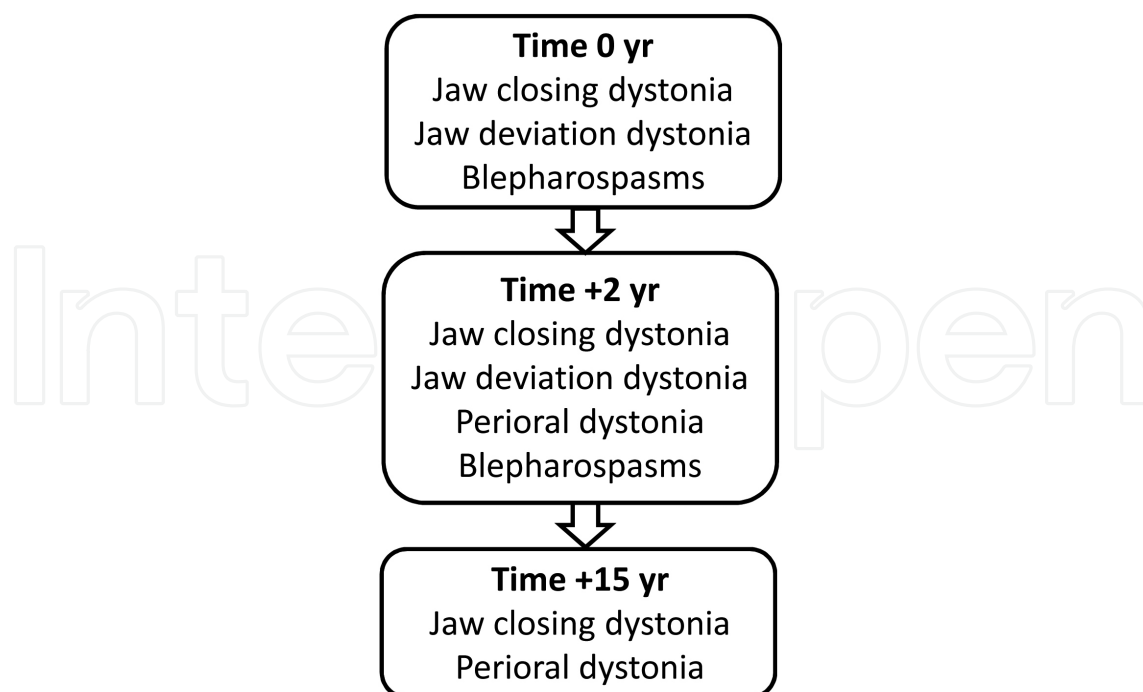


Figure 4. Shifts of dystonia types during a 15-year period in an elderly woman.

<u>Time +10 yr</u>					
Spontaneous activity (EMG μ V)		Before A/Ona	Units A/Ona	2 months after A/Ona	Reference Values M \pm SD
Muscles					
Temporalis	R	24	20	8	3.5 \pm 1.9
	L	20	20	12	
Masseter	R	17	25	7	2.4 \pm 1.0
	L	9	25	5	
Medial pterygoid	R	20	15	6	11.5 \pm 4.5
	L	9	15	4	
Anterior digastric	R	44	0	22	4.0 \pm 2.5
	L	32	0	19	
Lateral pterygoid	R	12	25	8	11.0 \pm 4.5
	L	33	25	9	
Orbicularis oris superior	R	14	5	6	4.0 \pm 2.0
	L	15	5	5	
Orbicularis oris inferior	R	45	10	9	5.3 \pm 2.5
	L	34	10	5	

Figure 5. Electromyographic recordings of spontaneous muscle activity in an elderly woman with oromandibular dystonia immediately before and after a BoNT treatment series. The activity is clearly reduced from the treatment, even in the nontreated digastric muscles (bipolar surface electrodes, mean voltage; custom-designed eight-channel EMG system; Electromyographic Laboratory, Dept. of Odontology, University of Copenhagen).

Fifteen years after the diagnosis, the dystonia was reduced compared to previous years. There were fewer outbursts of dystonic activity and the involuntary jaw closing and lip dystonia was less powerful. In spite of her tooth loss, the patient was satisfied with her dentures and her chewing function had improved.

The second patient is a woman referred 17 years earlier when she was 59 years. She had gradually developed an anterior mandibular overjet through some months and could only with difficulty bite the teeth together with normal incisor relationships. There was no pain associated with the condition, but increasing chewing and speech problems. She was diagnosed with jaw deviation associated with dystonia of the lateral pterygoid muscle on both sides.

Time 0 yr	Molars			Pre-molars		Canines	Incisors				Canines	Pre-molars		Molars		
		7	6	5	4	3	2	1	1	2	3	4	5	6	7	
		7	6	5	4	3	2	1	1	2	3	4	5	6	7	8
Time +2 yr	Molars			Pre-molars		Canines	Incisors				Canines	Pre-molars		Molars		
			6		4	3	2	1	1	2	3	4		6	7	
			6	5	4	3	2		1	2	3	4	5			8
Time +15 yr	Molars			Pre-molars		Canines	Incisors				Canines	Pre-molars		Molars		
	Partial denture						2	1	1	2	3	Partial denture				
	Full denture															

Figure 6. Reduction in the number of teeth in an elderly woman during 15 years with oromandibular dystonia. The deterioration of the dentition was associated with fractures of dental restorations and severe attrition of the teeth from the dystonic jaw movements combined with increased caries activity and dental erosions from hyposalivation.

Her habitual occlusion was displaced 4–5 mm anteriorly to the normal sagittal relationship, a so-called mandibular overjet. However, analysis of the dental attrition on plaster models revealed that the original occlusion in the front was a 2-mm maxillary overjet, that is, a normal sagittal relationship between the maxillary and mandibular anterior teeth. In contrast to the patient with focal dystonia, the jaw deviation dystonia did not change over time. No other muscles were involved. At first, treatment the lateral pterygoid muscles were injected with 20 units A/Ona each, and later on with 40 units each (**Figure 7**). The type of dystonia was unchanged during 17 years in contrast to the female patient mentioned earlier. An excellent treatment effect was obtained with complete reversal of the jaw protrusion and normalization of chewing and speech, and it was repeated again and again with A/Ona injections on an average 1.7 times per year (**Figure 8**).

Time +3 yr					
Spontaneous activity (EMG μV)		Before A/Ona	Units A/Ona	2 months after A/Ona	Reference Values M\pmSD
Muscles					
Temporalis	R	4	0	3	3.5 \pm 1.9
	L	3	0	3	
Masseter	R	5	0	14	2.4 \pm 1.0
	L	4	0	9	
Anterior digastric	R	5	0	4	4.0 \pm 2.5
	L	6	0	5	
Lateral pterygoid	R	50	40	15	11.0 \pm 4.5
	L	38	40	5	

Figure 7. Electromyographic recordings of spontaneous muscle activity in an elderly woman with jaw deviation dystonia immediately before and after a BoNT treatment series. The injections in the lateral pterygoid muscles reduced the activity in the treated muscles and normalized the dental occlusion (bipolar electrodes, mean voltage; custom-designed 8-channel EMG system; Electromyographic Laboratory, Dept. of Odontology, University of Copenhagen).

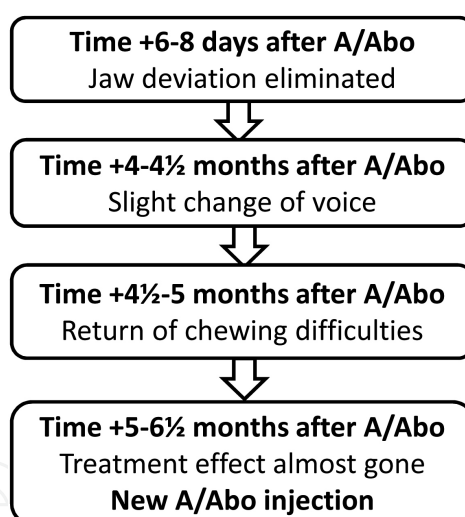


Figure 8. Unchanged jaw deviation dystonia persisting during a 17-year period in an elderly woman.

2.4. Special conditions

Besides the already mentioned conditions, BoNT may be helpful in special situations as a palliative intervention. Bite wounds in the tongue, lips, and cheeks may occur after accidental or involuntary jaw closures in patients with cerebral palsy, parkinsonian syndromes, dementia, or in retarded persons. Intramuscular injections with BoNT may attenuate bite force and thus reduce the possibility of severe lesions. Frequent dislocations of the temporomandibular joints represent a serious problem. They imply frequent contacts with the health care system and the

emergency wards. Such habitual dislocations may result from neurological disorders, articular hypermobility, or sequelae after jaw trauma. BoNT injections into the lateral pterygoid muscle, in one or both sides, may reduce the problem if the situation is very frustrating and painful [21].

3. Drooling and secretory disorders of the salivary glands

Saliva secretion amounts to about 1 L per day with higher secretion rates during chewing and taste stimulation than at rest [22]. Under normal physiological conditions, the resting secretion rate of whole saliva is 0.2–0.5 ml per min during wakefulness and practically negligible during sleep. The most important salivary glands are the parotid and the submandibular glands. They have different functional patterns. Unstimulated the submandibular gland secretes the majority of the saliva. In the stimulated state, the saliva production from the parotid and the submandibular glands is approximately the same.

3.1. Drooling

Usually the saliva is swallowed unconsciously throughout the day. Unintentional loss of saliva from the mouth, referred to as sialorrhoea or drooling, is most often due to decreased swallowing function rather than regular hypersalivation [23]. Drooling is unusual after the age of 5 years. In adults it is often related to gastroesophageal reflux, pregnancy, or develops as a side effect of pharmacological treatment. Even patients with a low salivary flow rate may suffer from sialorrhoea, when impaired swallowing function leads to accumulation of saliva in mouth, and when insufficient lip closure or reduced oral sensitivity causes overflow and loss of saliva from the mouth. If the saliva passes over the lower lip, it may run down the chin and drip on the clothing, or it may be aspirated and cause coughing and lung inflammation. Thus, drooling both results in reduced quality of life and poses a significant health risk.

Severe and psychosocially embarrassing drooling occurs especially in congenital or acquired neurological disorders, such as parkinsonian syndromes, amyotrophic lateral sclerosis, and cerebral palsy. Therefore, the general diagnosis and treatment of this type of drooling are primarily within the working area for neurologists and takes place in a hospital setting. However, dentists must be able to identify the problem in order to refer for treatment. The treatment consists essentially in reducing the saliva secretion (**Figure 9**).

Such treatment may induce severe side effects in terms of dry mouth depending on its type, which range from irreversible surgical interventions and radiation to reversible treatments with intraglandular BoNT injections. As a consequence, the treatment may also cause accelerated caries progression and other oral disorders. To minimize or prevent such development, the patient should be followed closely by a dentist. However, as BoNT is one of the least invasive treatments for drooling, it should always be considered as a relevant option. Based on clinical evidence, treatment of severe drooling with percutaneous BoNT injections bilaterally into the parotid and submandibular glands is considered useful [25].

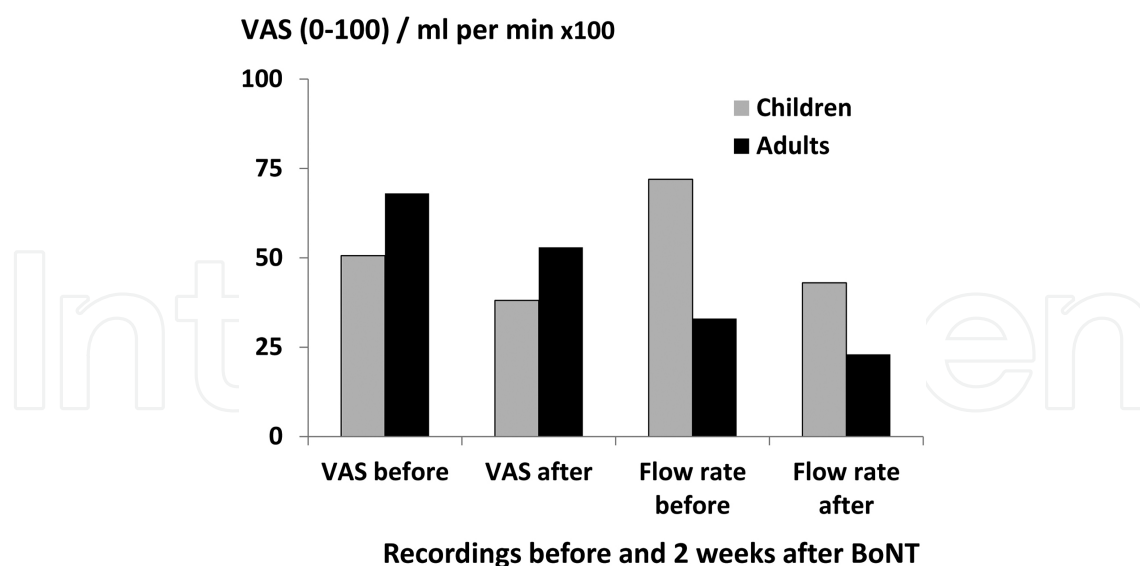


Figure 9. The effect of intraglandular injections into each parotid and submandibular gland with 15–40 units onabotulinumtoxinA (A/Ona) or incobotulinumtoxinA (A/Inco) evaluated by visual analog scales (VAS) for drooling discomfort and unstimulated whole saliva flow rate (ml/min × 100). Mean values before and 2 weeks after the treatment in 14 children with cerebral palsy and in 9 adults with amyotrophic lateral sclerosis and Parkinson's disease [2, 24].

Before the treatment start, it is important to record the frequency and extent of the drooling as well as the impact of the drooling problem. The unstimulated salivary secretion rate should be measured to clarify the cause and to determine the BoNT dose. Depending on the cooperation from the patient, saliva can be collected either in a cup by the draining method or by a modified swab method with dental cotton rolls. Intraglandular injections with BoNT should be given with ultrasonographic guidance to place the bolus centrally in the glands to ensure maximum efficiency and minimize the side effects (**Figure 10**) [2, 24].

Light anesthesia or sedation may be necessary, especially in children, because the injections are associated with local discomfort or pain and therefore provoke avert reaction and movements. Most clinical reports include treatments with commercially available preparations of type BoNT/A, such as A/Ona and A/Inco, with 15–40 units in each parotid gland and in each submandibular gland. Compositions of BoNT/B such as B/Rima in doses of 750–2500 units have also been used for drooling, for example, Møller et al. [1]. The treatment effect of BoNT is local. It has few side effects, which is usually short lasting and results from the injection trauma. In few cases, there may be difficulty in swallowing due to impaired muscle activity usually lasting some weeks. In all circumstances, the effect is temporary, and largely gone after 3 months. Repetition of the treatment and possible dose modifications should depend on the effect of treatment, the current secretions rate, the drooling level, and the extent of any adverse effects.

In children and young subjects, spontaneous cessation of drooling may occur as a result of the physiological development [2]. Therefore, the drooling treatment should not be performed automatically. It must be ensured that the drooling problems have returned after the expected duration of the treatment effect before performing a new treatment. As a consequence, it is advisable that treatment of drooling in these age groups is reversible, such as intraglandular

injections with BoNT, as more invasive types of treatment with long-term or permanent effect [2].

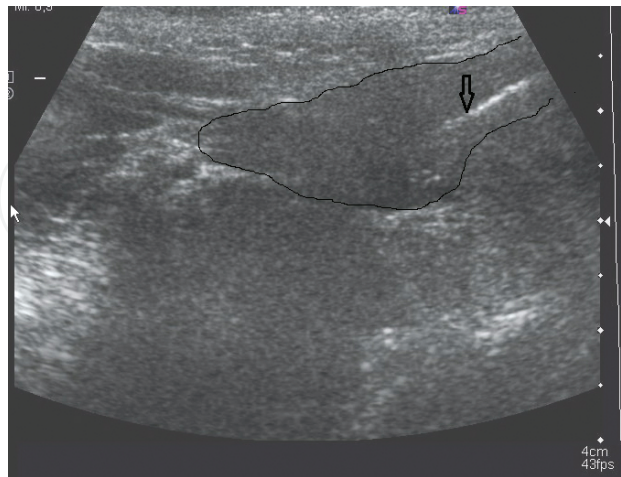


Figure 10. Ultrasonographic guidance during intraglandular injection of BoNT into the submandibular gland. The tip of the injection needle is indicated by an arrow. (GE Logiq 9, “thyroid” settings; 12 MHz linear transducer).

3.2. Frey's syndrome

Frey's syndrome or gustatory sweating in the preauricular area is an unpleasant phenomenon typically appearing during meals. It may also be socially disabling when flushing and intense sweating with subsequent wetting of clothes prevents the patient from eating in company. The syndrome occurs after surgical procedures or traumas on the parotid gland. Frey's syndrome is most likely caused by misdirected regeneration of cut or damaged parasympathetic fibers, producing new “salivary” reflex arches activating sweat glands and small subcutaneous blood vessels instead of salivary gland tissue. Thus, sweating and vasodilatation appear in the reinnervated area when salivation is induced upon cholinergic stimulation from gustatory and masticatory stimuli [26]. Intradermal injections of BoNT/A may be considered for gustatory sweating and seems clinically effective [27]. It has also been suggested that Frey's syndrome should be viewed as a dynamic process in which the stimulus for aberrant reinnervation of parasympathetic nerve fibers can be reduced in some patients, with BoNT injections to the treated areas [28]. Thus, the gustatory sweating may fade over time and does not necessarily have to be retreated over and over again.

To localize the extent of involved skin area, Minor's iodine-starch test is used before treatment. An iodine solution (castor oil mixed with 2% iodine alcohol solution 1:9) is applied on the skin of the involved cheek and dried for 0.5 min, and potato flour is spread out evenly and thinly through a sieve over the area. During chewing of slices of apple, or sucking sour or strong-flavored candies for 5 min, a chemical reaction takes place between iodine and starch. This leaves the zones of perspiration dark brown. Then the surplus of flour is gently removed by compressed air and suction (**Figure 11**).

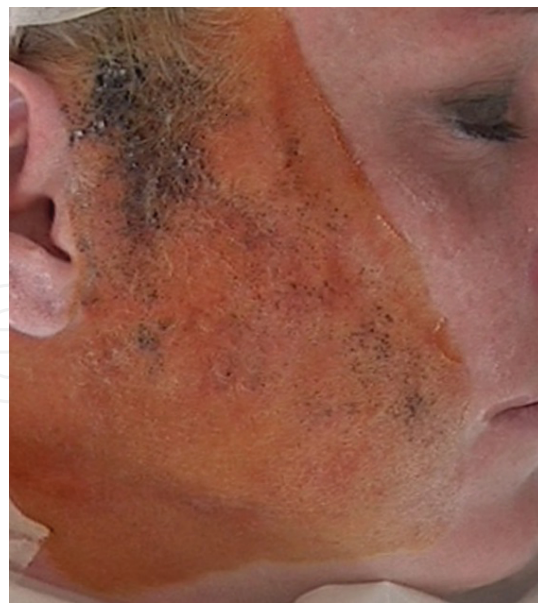

Figure 11. Frey's syndrome or gustatory sweating after stabbing of the face in a 37-year-old woman. Dark brown spotted areas with perspiration obtained by the Minor's iodine-starch test after eating apple.

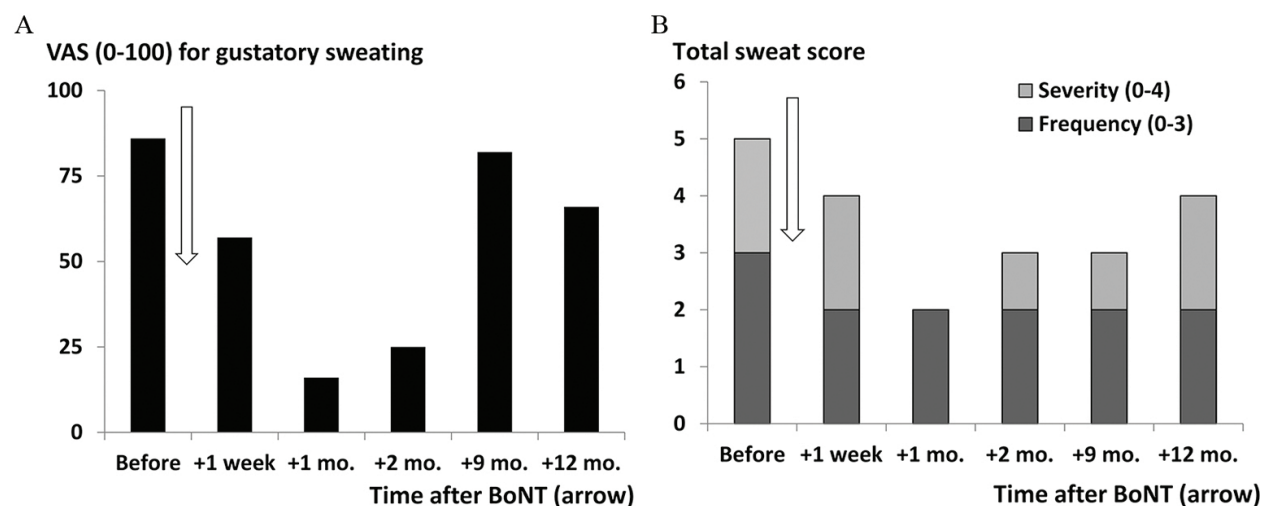


Figure 12. Frey's syndrome or gustatory sweating after stabbing of the face in a 37-year-old woman. A: Self-reported impact of discomfort and problems with perspiration of the cheek in daily life on horizontal visual analog scales (VAS) before treatment and at follow-ups during 1 year after treatment. B: Self-reported total score for severity and frequency of gustatory sweating (0–7) before treatment and at follow-ups during 1 year after treatment (modified after Thomas-Stonell and Greenberg [29]).

The distribution of the zones can be documented using a digital camera and by evaluating the skin areas morphometrically [28]. The distribution of the dark brown spotted areas may also be transferred to an acetate template with anatomical landmarks corresponding to ear, eye, and mouth for reference during the injections [26]. Local anesthetic cream is applied to the involved skin areas before BoNT treatment as the repeated intradermal injections may be rather painful. The injections are made at 1-cm distances, that is, one single injection per

1 cm², and for each injection, 0.5 units A/Ona or A/Inco is used [26]. After about 1 week, the perspiration is reduced (**Figure 12A and B**), especially the severity. After treatment, not only the sweating is reduced. The treated areas may also remain pale when the cheeks otherwise blush during physical exercise or fitness. The effect may last for 0.5–1 year.

4. Conclusion

Several conditions in the oromandibular region may benefit from treatment with BoNT injections. The treatment is local, and there are few side effects if the injections are guided by electromyography and/or ultrasonography. However, animal studies indicate that changes in muscle fibers and bone loss may be a risk factor for the use of BoNT in jaw muscles [30, 31]. In any circumstances, the treatment should be planned by thorough examination of possible injection targets, and the effect of the treatments must be controlled. The dose and targets should not be repeated routinely but must be adjusted in repeated injection series based on analysis of the effect. To get the best results and minimize or prevent side effects, collaboration between doctors with several different professional backgrounds is important.

Author details

Merete Bakke^{1*}, Torben Dalager² and Eigild Møller²

*Address all correspondence to: mbak@sund.ku.dk

1 Department of Odontology, Faculty of Health and Medical Sciences, University of Copenhagen, Copenhagen, Denmark

2 Department of Neurology, Bispebjerg University Hospital, University of Copenhagen, Copenhagen, Denmark

References

- [1] Møller E, Daugaard D, Holm O, Winge K, Bardow A, Lykkeaa J, Belhage B, Bakke M. Repeated treatments of drooling with botulinum toxin B in neurology. *Acta Neurol Scand.* 2015;131: 51–57.
- [2] Møller E, Pedersen SA, Vinicoff PG, Bardow A, Svendsen P, Bakke M. Onabotulinum A treatment of drooling in children with cerebral palsy: a prospective, longitudinal open-label study. *Toxins (Basel).* 2015;7: 2481–2493.

- [3] Møller E, Bakke M, Dalager T, Werdelin LM. Oromandibular dystonia involving the lateral pterygoid muscles: four cases with different complexity. *Mov Disord.* 2007;22:785–790.
- [4] Fuglsang-Frederiksen A, Ostergaard L, Sjö O, Werdelin L, Winkel H. Quantitative electromyographical changes in cervical dystonia after treatment with botulinum toxin. *Electromyogr Clin Neurophysiol.* 1998;38:75–79.
- [5] Bakke M, Werdelin LM, Dalager T, Fuglsang-Frederiksen A, Prytz S, Møller E. Reduced jaw opening from paradoxical activity of mandibular elevator muscles treated with botulinum toxin. *Eur J Neurol.* 2003;10:695–699.
- [6] Møller E, Werdelin LM, Bakke M, Dalager T, Prytz S, Regeur L. Treatment of perioral dystonia with botulinum toxin in 4 cases of Meige's syndrome. *Oral Surg Oral Med Oral Pathol Oral Radiol Endod.* 2003;96:544–549.
- [7] Yun JY, Kim JW, Kim HT, Chung SJ, Kim JM, Cho JW, Lee JY, Lee HN, You S, Oh E, Jeong H, Kim YE, Kim HJ, Lee WY, Jeon BS. Dysport and Botox at a ratio of 2.5:1 units in cervical dystonia: a double-blind, randomized study. *Mov Disord.* 2015;30:206–213.
- [8] Rosales RL, Ng AR, Santos MM, Fernandez HH. The broadening application of chemodenervation in X-linked dystonia-parkinsonism (Part II): an open-label experience with botulinum toxin-A (Dysport®) injections for oromandibular, lingual, and truncal-axial dystonias. *Int J Neurosci.* 2011;121 Suppl 1:44–56.
- [9] Møller E. The chewing apparatus. An electromyographic study of the action of the muscles of mastication and its correlation to facial morphology., *Acta Physiol Scand Suppl.* 1966;280:1–229.
- [10] Prevalence of TMJD and its signs and symptoms [Internet]. Available from: <http://www.nidrcr.nih.gov/DataStatistics/FindDataByTopic/FacialPain/PrevalenceTMJD.htm> [Accessed: 2016-4-1].
- [11] Greene CS, American Association for Dental Research. Diagnosis and treatment of temporomandibular disorders: emergence of a new care guidelines statement. *Oral Surg Oral Med Oral Pathol Oral Radiol Endod.* 2010;110:137–139.
- [12] Ernberg M, Hedenberg-Magnusson B, List T et al. Efficacy of botulinum toxin type A for treatment of persistent myofascial TMD pain: a randomized, controlled, double-blind multicenter study. *Pain.* 2011;152:1988–1996.
- [13] Linde M, Hagen K, Stovner LJ. Botulinum toxin treatment of secondary headaches and cranial neuralgias: a review of evidence. *Acta Neurol Scand. Suppl.* 2011;191:50–55.
- [14] Smyth AG. Botulinum toxin treatment of bilateral masseteric hypertrophy. *Br J Oral Maxillofac Surg.* 1994;32:29–33.
- [15] Moore AP, Wood GD. The medical management of masseteric hypertrophy with botulinum toxin type A. *Br J Oral Maxillofac Surg.* 1994;32:26–28.

- [16] Fedorowics Z, van Zuuren EJ, Schoones J. Botulinum toxin for masseter hypertrophy. *Cochrane Database Syst Rev.* 2013;9:CD007510.
- [17] Bakke M, Holm B, Jensen BL, Michler L, Møller E. Unilateral, isometric bite force in 8-68-year-old women and men related to occlusal factors. *Scand J Dent Res.* 1990;98:149–158.
- [18] Bakke M, Møller E, Thomsen CE, Dalager T, Werdelin LM. Chewing in patients with severe neurological impairment. *Arch Oral Biol.* 2007;52:399–403.
- [19] Bakke M, Larsen BM, Dalager T, Møller E. Oromandibular dystonia—functional and clinical characteristics: a report on 21 cases. *Oral Surg Oral Med Oral Pathol Oral Radiol.* 2013;115:e21–26.
- [20] Møller E, Bakke M, Dalager T, Werdelin LM, Lonsdale MN, Højgaard L, Friberg L. Somatosensory input and oromandibular dystonia. *Clin Neurol Neurosurg.* 2013;115:1141–1143.
- [21] Fu KY, Chen HM, Sun ZP, Zhang ZK, Ma XC. Long-term efficacy of botulinum toxin type A for the treatment of habitual dislocation of the temporomandibular joint. *Br J Oral Maxillofac Surg.* 2010;48:281–284.
- [22] Sreebny LM. Saliva in health and disease: an appraisal and update. *Int Dent J.* 2000;50:140–161.
- [23] Bakke M, Bardow A, Møller E. Severe drooling and treatment with botulinum toxin. *ASHA SIG 13 Perspectives on Swallowing and Swallowing Disorders (Dysphagia).* 2012;21:15–21.
- [24] Møller E, Karlsborg M, Bardow A, Lykkeaa J, Nissen FH, Bakke M. Treatment of severe drooling with botulinum toxin in amyotrophic lateral sclerosis and Parkinson's disease: efficacy and possible mechanisms. *Acta Odontol Scand* 2011;69:151–157.
- [25] Naumann M, So Y, Argoff CE, Childers MK, Dykstra DD, Gronseth GS, Jabbari B, Kaufmann HC, Schurch B, Silberstein SD, Simpson DM; Therapeutics and Technology Assessment Subcommittee of the American Academy of Neurology. Assessment: botulinum neurotoxin in the treatment of autonomic disorders and pain (an evidence-based review): report of the Therapeutics and Technology Assessment Subcommittee of the American Academy of Neurology. *Neurology* 2008;70:1707–1714.
- [26] Bakke M, Max Thorsen N, Bardow A, Dalager T, Eckhart Thomsen C, Regeur L. Treatment of gustatory sweating with low-dose botulinum toxin A: a case report. *Acta Odontol Scand.* 2006;64:129–133.
- [27] Steffen A, Rotter N, König IR, Wollenberg B. Botulinum toxin for Frey's syndrome: a closer look at different treatment responses. *J Laryngol Otol.* 2012;126:185–189.
- [28] Eckardt A, Kuettner C. Treatment of gustatory sweating (Frey's syndrome) with botulinum toxin A. *Head Neck.* 2003;25:624–628.

- [29] Thomas-Stonell N, Greenberg J. Three treatment approaches and clinical factors in the reduction of drooling. *Dysphagia*. 1988;3:73–78.
- [30] Korfage JAM, Wang J, Langenbach GEJ. Influence of botulinum toxin on rabbit jaw muscle activity and anatomy. *Muscle Nerve*. 2012;45:684–691.
- [31] Matthys T, Dang HAH, Rafferty KL, Herring SW. Bone and cartilage changes in rabbit mandibular condyles after 1 injection of botulinum toxin. *Am J Orthod Dentofacial Orthop*. 2015;148:999–1009.

