

We are IntechOpen, the world's leading publisher of Open Access books Built by scientists, for scientists

6,900

Open access books available

186,000

International authors and editors

200M

Downloads

Our authors are among the

154

Countries delivered to

TOP 1%

most cited scientists

12.2%

Contributors from top 500 universities



WEB OF SCIENCE™

Selection of our books indexed in the Book Citation Index
in Web of Science™ Core Collection (BKCI)

Interested in publishing with us?
Contact book.department@intechopen.com

Numbers displayed above are based on latest data collected.
For more information visit www.intechopen.com



Complications of Orthognathic Surgery

Reza Tabrizi and Hassan Mir Mohammad Sadeghi

Additional information is available at the end of the chapter

<http://dx.doi.org/10.5772/64035>

Abstract

Orthognathic surgery is a common approach for treatment of maxillofacial deformities. Sagittal split ramus osteotomy (SSRO) is one of the most common techniques used to treat various mandibular deformities. A LeFort I osteotomy is suggested in deformities of the maxilla and can be used along with SSRO or intra-oral vertical ramus osteotomy (IVRO). The aim of orthognathic surgery is to improve function and facial appearance; this benefits the patient psychologically and socially. Common complications which may occur in orthognathic surgery include vascular disease, temporomandibular joints (TMJ) problems, nerve damage, infection, bone necrosis, periodontal disease, vision impairment, hearing problems, hair loss, and neuropsychiatric problems. Rarely complications could be fatal. Because of the wide range of complications the surgeon should keep prevention protocols in mind and be prepared to treat them should they occur. In this chapter, common complications of various osteotomies in the mandible and maxilla are discussed.

Keywords: osteotomies, complications

1. Introduction

1.1. LeFort osteotomies

Midface osteotomies have been used to correct maxillary-zygomatic deformities, and historically have been classified anatomically based on the Guerin-LeFort fracture classification [1]. The first total LeFort I osteotomy was performed by Wassmund in 1927 for correction of the skeletal open bite [2]. In spite of all the advancements made in the field of orthognathic surgery, a variety of complications are documented [3]. These include maxillary sinusitis, loss of tooth vitality, sensory nerve morbidity, aseptic necrosis, vascular complications (i.e., arteriovenous fistulae or hemorrhage) nasal septum deviation, unfavorable fractures of the skull base and

pterygoid plates, ophthalmic complications (including blindness) malpositioning, nonunion, maxilla instability, and relapse [4].

1.2. Hemorrhage

Excessive bleeding has been reported as a common complication of LeFort osteotomies. The incidence of life-threatening hemorrhage in maxillary osteotomies is reported in approximately 1% [5]. The descending palatine artery is the most common source for mild to moderate bleeding during LeFort I osteotomy and delayed bleeding afterward. The descending palatine artery damage may occur during the medial wall osteotomy. Injury to the descending palatine artery during LeFort I osteotomy can be minimized by limiting the osteotomy to 30 mm posterior to the piriform rim in females and to 35 mm in males [6]. In maxillary superior repositioning, bone removal around the descending palatine artery is a common cause of vascular injury. If the surgeon encounters the descending palatine artery, it should be cauterized. The internal maxillary artery is the most frequently cited source of massive hemorrhage [7]. Meticulous placement of the curved osteotome in the pterygomaxillary junction is important to avoid injury to the internal maxillary artery and its branches. Turvey and Fonseca reported that the main trunk of the maxillary artery was most vulnerable to the damage within the pterygopalatine fossa in the lateral position and they recommended angling the posterior lateral maxillary osteotomy downward to avoid damaging the artery [8]. Packing is suggested as the first attempt to tamponade the hemorrhage. In delayed bleeding after LeFort I osteotomy, the surgeon should reopen surgical site and move the maxilla downward to find the bleeding source (**Figure 1**). In many cases, direct visualization of the bleeding source and cauterization of injured vessels stops the hemorrhage (**Figure 2**). Several techniques have been suggested to control bleeding from the internal maxillary artery such as ligation of the external carotid artery and angiographic embolization. Emergency access to vascular embolization is crucial. If a patient has severe bleeding, the surgeon should not waste time and intervene immediately. The collateral arteries and the anastomoses between circulations lead to the limited success of surgical ligation of the external carotid artery [9]. A recent study recommended use of tranexamic acid irrigation in obviating perioperative blood loss during orthognathic surgery [10].

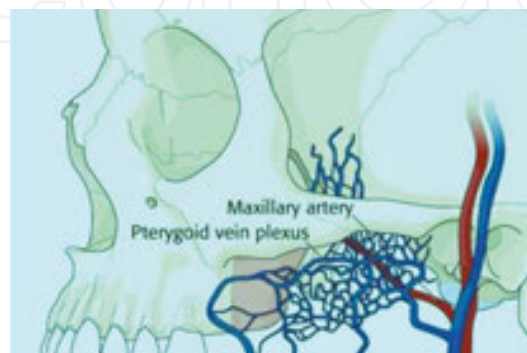


Figure 1. Possible bleeding sources during LeFort I osteotomy.

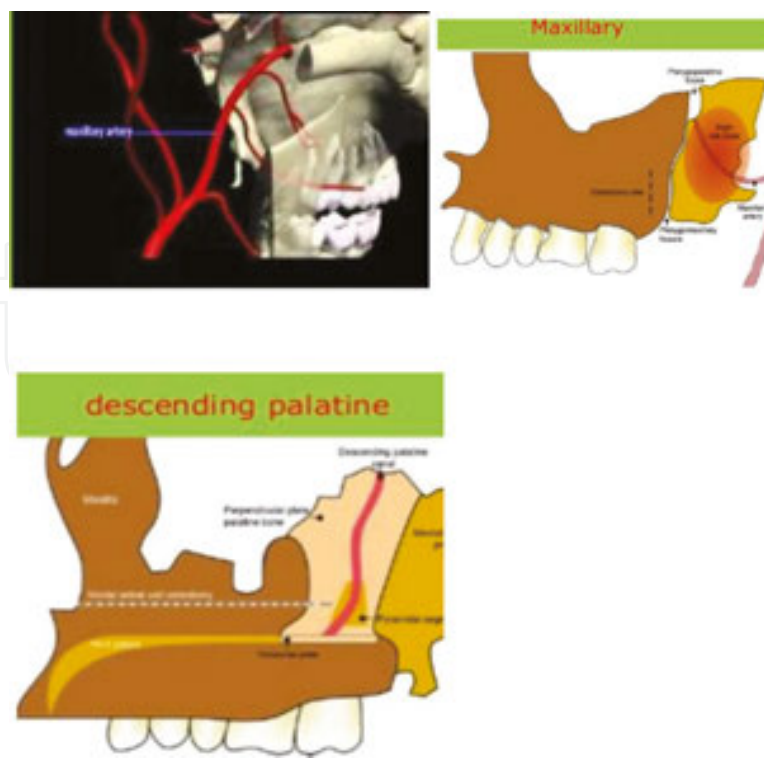


Figure 2. Relationship of osteotomy sites and major hemorrhage sources during LeFort I osteotomy.

1.3. Neurosensory deficit

The infraorbital nerve may be compressed, retracted or transected inadvertently during subperiosteal dissection.

Infraorbital nerve injury may have resulted from incorrect separation during disimpaction.

As are the cases with bilateral sagittal ramus osteotomy, nerve sensitivity may return within 6–12 months [11].

The absence of post-operative sensitivity after a LeFort I procedure was documented in a study that applied both objective and subjective tests. The results showed a greater incidence of insensitivity in the region above the upper lip, followed by the lower lip and the chin, as was observed in bimaxillary procedures [12]. Neurosensory alterations are normally immediately perceived in the post-operative period. They are the result of traction of the infraorbital nerve and direct trauma to the anterior, medial, and posterior superior alveolar nerves, as well as to the nasopalatine nerve and the descending palatal nerve [13]. A study performed at the University of North Carolina on patients undergoing bilateral Sagittal split ramus osteotomy (SSRO) reported that 98% of the patients presented altered sensitivity of the chin 1 month after the operation; with 81% of these patients still presenting with this alteration 6 months after the operation [14]. It is recommended that the patient be advised of possible neurosensory alterations in pre-operative visits, thus reducing the patient's post-operative anxiety [15]. Many studies confirm the return of neurosensory function up to 1 year after surgery [11].

1.4. Tooth sensitivity

An osteotomy closer than 5 mm of the apices of the teeth has risk of root injuries[16]. In superior repositioning of the maxilla by more than 6 mm, saving of 5 mm margin is not always possible because of the infraorbital foramen position [4]. After orthognathic surgery, loss of vascularity of the dentition is rare, but initial loss of response to pulpal stimulation is common. Long-term suppressed response to stimulation can occur, but does not necessarily mean a tooth requires endodontic therapy. Although some teeth may eventually become necrotic and require endodontic treatment, many teeth recover without treatment and return to normal coloration and respond to pulp testing [17]. De Jongh et al. studied electric and thermal pulp testing of 10 patients after LeFort I osteotomy in compared to 10 control patients without osteotomy. Their study showed that 71% of 128 teeth were responsive to electric and thermal pulp stimulation and 93% of 136 teeth in the controls [18].

1.5. Maxillary sinusitis

Sinusitis after LeFort I osteotomy is uncommon, with a reported incidence of septic complications of 0.5–4.8% [19]. Possible explanations for postoperative maxillary sinusitis following LeFort I osteotomy were pre-existing sinus disease or non-viable bone fragments left in the maxillary sinus (**Figure 3**) [20]. A recent study by Valestar et al. showed LeFort I procedure did not influence already existing physical or mental complaints, and nasal ventilation was not negatively affected. However, evaluation of sino-nasal pathology should be emphasized in the preoperative work-up [19]. A recent study by Nocini et al. suggested that LeFort I osteotomies can affect the maxillary sinus. The postoperative radiologic views of the maxillary sinus showed inflammation and rhinosinusitis symptoms after LeFort osteotomies. Larger long-term studies are warranted to clarify the postoperative outcomes and complications (**Figure 4**) [21].

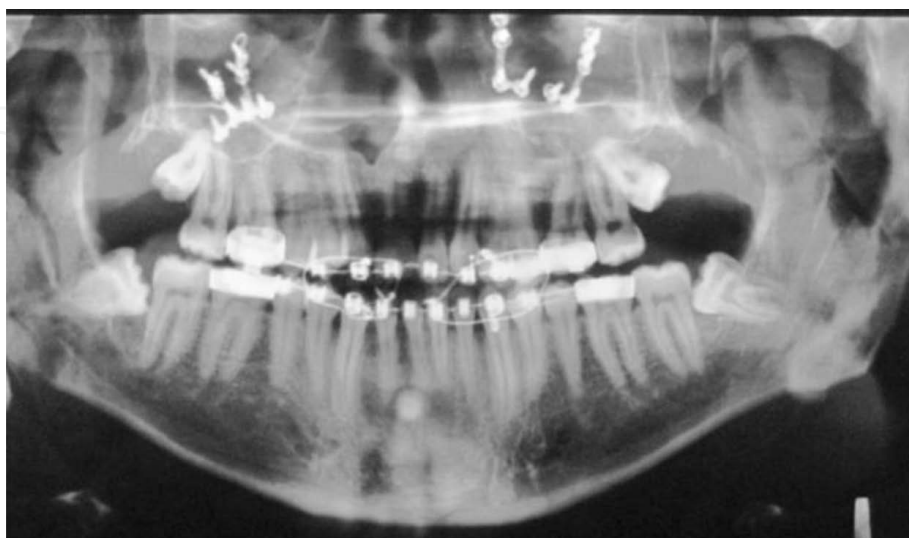


Figure 3. Maxillary sinusitis after LeFort I osteotomy.

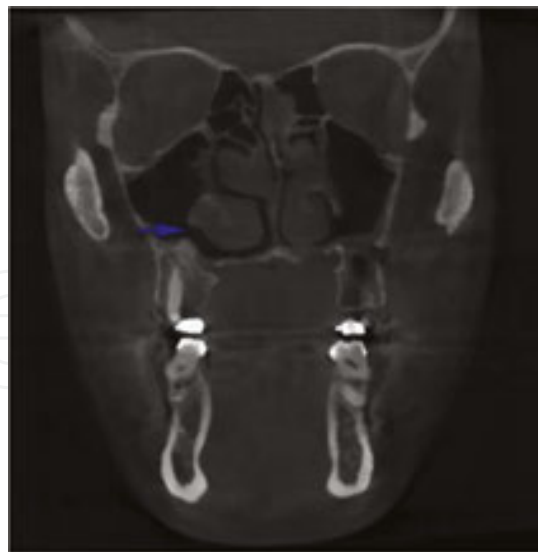

Figure 4. Radiologic findings: postoperative computed tomography scan displaying interruption of the medial walls [21].

1.6. Nose deformity

Septal malposition may occur during LeFort osteotomy and cause nasal deviation. A possible reason for a cartilagenous septum deviation after a maxillary osteotomy is dislocation by a partially deflated cuff during extubation. Manual inspection of the nares after extubation is important, yet often forgotten [22]. Nasal ventilation generally improves after orthognathic surgery [19]. The most common reason for postoperative nasal-septal deviation is compression or displacement from inadequate bone removal of the nasal crest of the maxilla or inadequate trimming of the cartilagenous septum (**Figure 5**) [9].

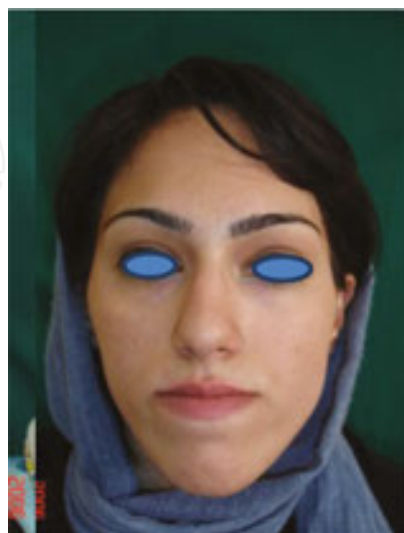


Figure 5. Severe nasal deviation after LeFort I osteotomy.

1.7. Aseptic necrosis

Avascular necrosis of the maxilla after LeFort I osteotomy has been reported [23]. Usually, these complications relate to the degree of vascular compromise and occur in less than 1% of cases. Rupture of the descending palatine artery during surgery, postoperative vascular thrombosis, perforation of palatal mucosa when splitting the maxilla into segments, or partial stripping of palatal soft tissues to increase maxillary expansion may impair blood supply to the maxillary segments. Sequelae of compromised vasculature include loss of tooth vitality, development of periodontal defects, tooth loss, or loss of major segments of alveolar bone or the entire maxilla (**Figure 6**) [24]. The risk is increased in patients with anatomical irregularities, such as craniofacial dysplasia's, orofacial clefts, or vascular anomalies [5]. The treatment of avascular necrosis of the maxilla is not easily manageable [25]. Regarding no treatment protocol has been established, aseptic necrosis of the maxilla should be treated by maintenance of optimal hygiene, antibiotic therapy to prevent secondary infection, heparinization, and hyperbaric oxygenation [24]. In such cases, it is evident that there is a serious problem with the tissue perfusion immediately postoperatively and the patient must be taken back to the theatre immediately to reposition the segment; delay only makes it worse [26].

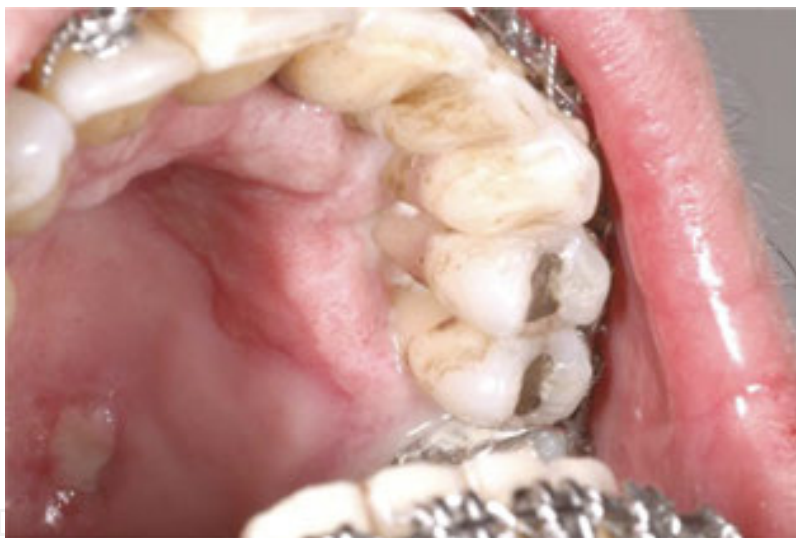

Figure 6. Initial aspect of the aseptic maxillary necrosis on the seventh postoperative day [24].

1.8. Unfavorable fractures

Unfavorable fractures may consist of pterygoid plate, sphenoid bone, and middle cranial fossa fractures. Lanigan and Guest demonstrated pterygomaxillary dysjunction using a curved osteotome and described high-level fractures of the pterygoid plates with disruption of the pterygopalatine fossa which could extend to the skull base [27]. Unfavorable pterygoid plate fracture is well studied and documented (**Figure 7**) [28]. Postoperative CT scans indicated that the prevalence of unfavorable fractures of the pterygomaxillary region may be more than previous expectations. Many of these unfavorable fractures are unobserved as there was no

CSF leak because of a local soft tissue seal [29]. Renicke et al. reported the incidence of pterygoid plate fracture was 58% following LeFort I osteotomy using postoperative CT scans [30].

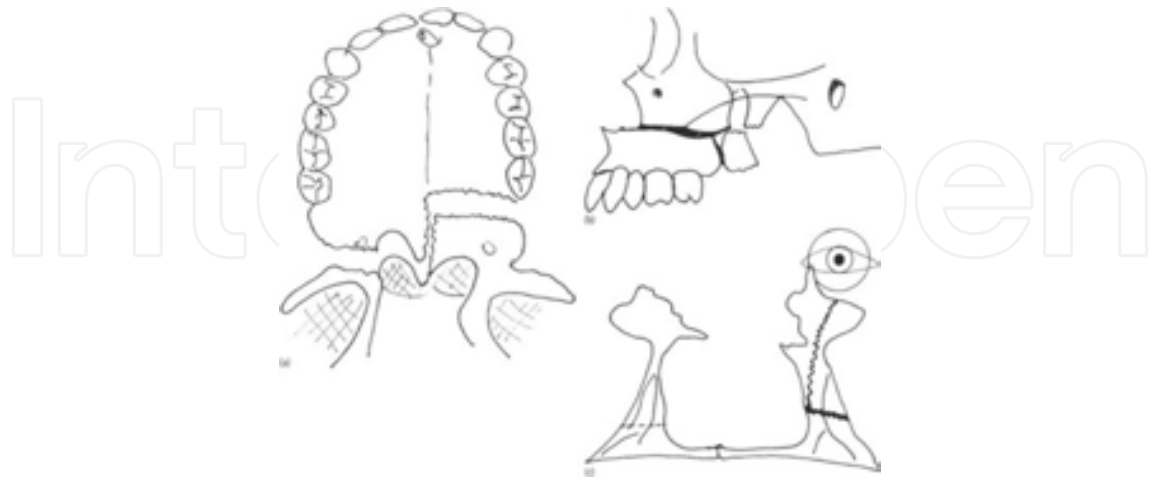


Figure 7. Possible lines of bad split during LeFort I osteotomy.

1.9. Improper maxillary repositioning

Several factors are responsible for improper maxillary repositioning such as missing a centric relation-centric occlusion discrepancy preoperatively; failure to achieve the desired maxillary position during isolated maxillary surgery, failure to seat the condyle because of inadequate removal of posterior bony interference and inaccurate vertical positioning [9]. Improper maxillary positioning may occur in correction of vertical maxillary excess. In a study by the first author, the incidence of under-correction (25%) was more than over-correction (7.5%)

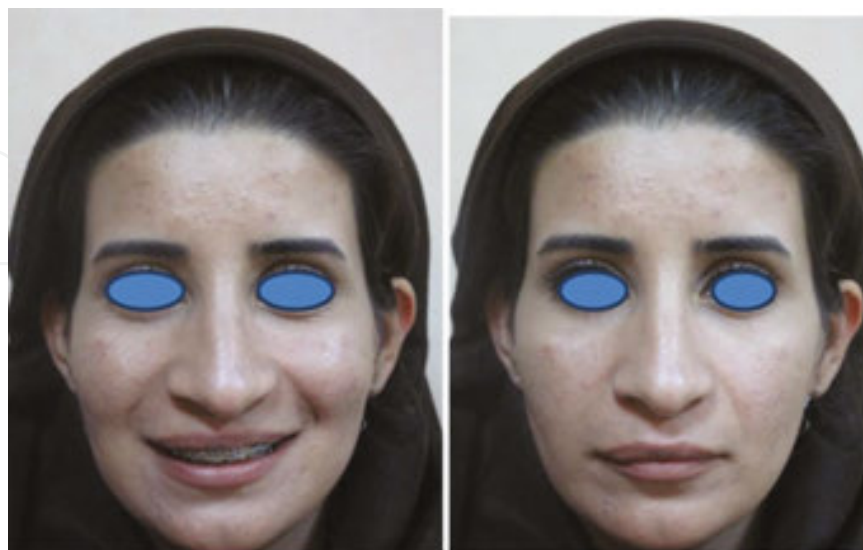

Figure 8. Over-correction after maxillary superior repositioning.

(Figure 8). Five millimeter was considered as a cutoff point for tooth shows at rest and 15 mm at the maximum smile. When tooth show at rest was more than 5 mm presurgically, 50.5% of clinical predictions did not follow the clinical results, and 75% of clinical predictions revealed the same results when the tooth show was less than 5 mm. When the amount of tooth shown in the maximum smile was more than 15 mm presurgically, 75% of clinical predictions did not follow clinical results, and 25% of the predictions met the same results in the maximum smile was less than. Clinical predictions based on the tooth show at rest and at the maximum smile did not have a reliable correlation with clinical results in maxillary superior repositioning. The risk of errors in predictions raised when the amount of superior repositioning of the maxilla increased. Generally, surgeons had a tendency to under-correct rather than over-correct. Also clinical prediction is used as a guideline by many surgeons, and it may be associated with variable clinical results [31].

1.10. Trigemino-cardiac reflex

Trigemino-cardiac reflex (TCR) is characterized by cardiac arrhythmia, ectopic beats, atrio-ventricular block, bradycardia, syncope, vomiting, and asystole. This life-threatening condition has been documented during simple zygomatic arch elevations, repositioning of blowout and maxillary fractures, orthognathic surgery, and nasoethmoidal fractures [32]. Besides evaluation of at-risk patients (e.g., children and patients with a medical history of cardiac disease) and high-risk surgeries (e.g., strabismus), some authors suggested using ketamine for anesthetic induction to decrease the oculocardiac reflex in children undergoing strabismus surgery [32]. Predisposing factors besides cardiac disease are hypoxia and hypercarbia, and use of opioids and β -blockers. TCR has been identified with a sudden onset of parasympathetic hypotension, apnea, or gastric hypermotility during stimulation of any of the sensory branches of the trigeminal nerve. In some cases, stopping the surgery has resulted in recovery of a normal rhythm; in other cases, anticholinergic drugs and cardiac massage have been mentioned. It is recommended that the anesthesiology team be informed that they may be prepared for mobilization in case of adverse effects. In every high-risk case presented in the classification, prophylactic administration of, for example, 0.5 mg atropine IV, right before any surgical manipulation known to be risky for TCR is mandatory [32].

1.11. Ophthalmic complications

Potential ophthalmic complications following LeFort I osteotomy includes decrease in visual acuity, extraocular muscle dysfunction, neuroparalytic keratitis, and lacrimal apparatus problems including epiphora [33]. Visual impairment after LeFort I osteotomy may be due to inappropriate separation of the pterygomaxillary junction and resulting fractures extending to the pterygoid plates, sphenoid bone, orbital floor, optic canal, or the skull base. It may damage the optic nerve or its vascular supply. Hemorrhage from the descending palatine artery or sphenopalatine artery in LeFort I osteotomy may be considered as a reason for systemic hypotension. Hemorrhage from the pterygopalatine fossa may leak the orbital cavity through the inferior orbital fissure and increase intraocular pressure (IOP). Hypotensive anesthesia is useful during a maxillofacial operation for blood loss control and enhancing the

visibility in the surgical field. The blood flow to the globes may be changed by elevated IOP or dropped systemic blood pressure. Hypotensive anesthesia may potentially reduce the blood supply to the retina and choroid and may cause embolism of the vessels or infarction of the optic nerve. The effect of hypotensive anesthesia on visual impairment has not been clarified yet [34].

1.12. Nasolacrimal duct obstruction

Nasolacrimal duct obstruction (NLDO) after maxillary orthognathic surgery is rare. The absence of an NLDO after LeFort I osteotomy is reasonable because the distance from the nasal opening of the NLD to the levels of osteotomy should be at least 5 mm. The normal distance between the NLD nasal opening and the nasal floor is 11–17 mm. LeFort I osteotomy should be performed 5 mm above the nasal floor. The distal to the proximal part of the NLD is vulnerable to be obstructed after maxillary osteotomy. Secondary inflammatory changes associated with an indirect injury of the NLD lead to obstruction. So surgeons should be aware of the risk of NLDO after orthognathic surgery (**Figures 9–11**); this can be managed by dacryocystorhinostomy with high success rate [35].

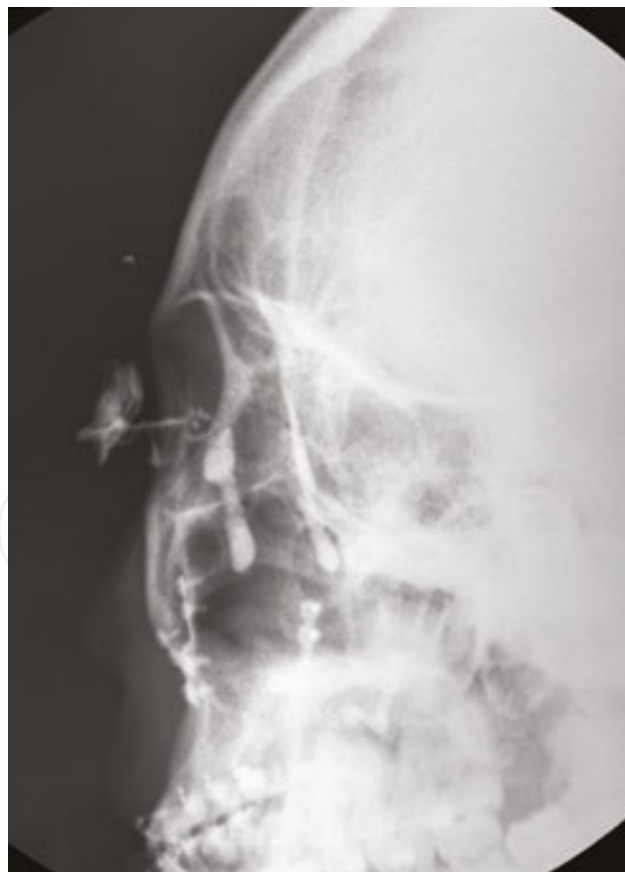

Figure 9. Representative dacryocystograms showing obstruction of the nasolacrimal duct in a patient who underwent orthognathic surgery and complained of permanent epiphora [35].

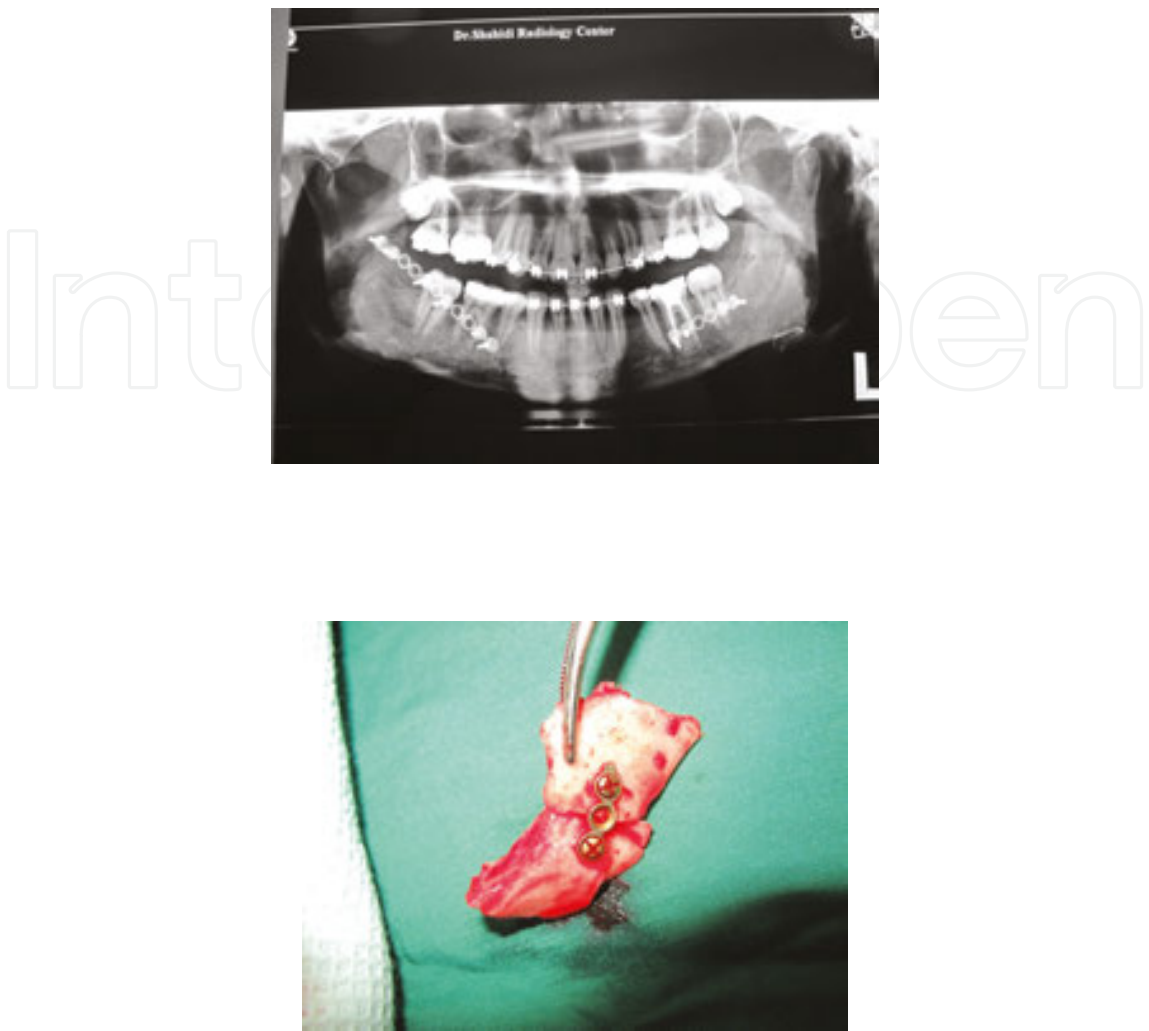


Figure 10. (A) Bad split occurred on the right side. (B) Fixation of bone fragment was done and replaced.

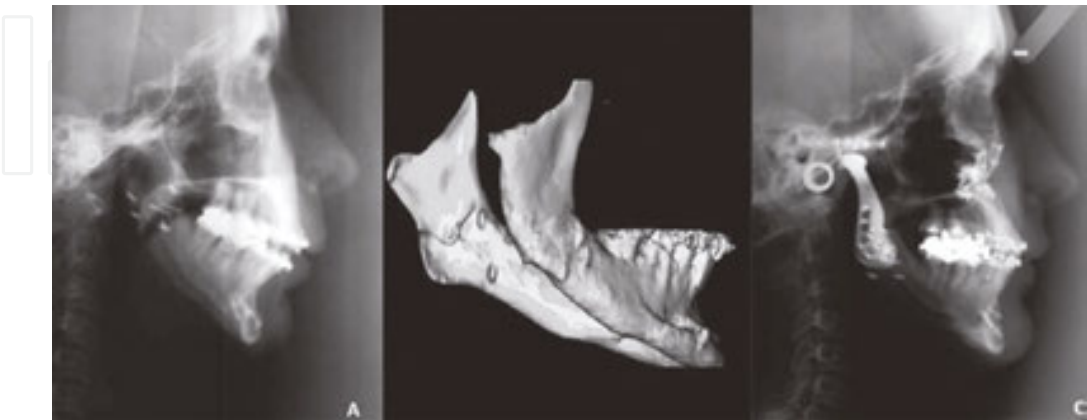


Figure 11. Complete destruction of condyle in a patient, who had undergone orthognathic surgery, was re-treated with the aid of temporomandibular joint prostheses. Before surgery (A), 3D image of the mandible showing bilateral absence of condyles (B), and after surgery (C) [53].

1.13. Nonunion of segments

Nonunion of segments in conventional LeFort I osteotomy is rare. In segmental osteotomy the risk of nonunion is higher. A good vascular pedicle and bone grafts are crucial. Additional stability of the maxillary segments after fixation with miniplates was suggested by the use of palatal dressing plates. Use of split with intermaxillary fixation may be useful. Three-dimensional fixation or immobilization can therefore be gained by using miniplates superiorly on the bony aspect, a dressing plate on the palatal aspect, and a wired-in final surgical wafer on the occlusal aspect of the dentoalveolar segments [36]. If nonunion occurs the surgical site should be reopened, fibrous tissue removed and proper rigid fixation be used for predictable union of segments.

1.14. Tooth damage

Tooth damage in segmental osteotomy is not uncommon. In LeFort I, the risk of damage to the teeth roots increases when the horizontal osteotomy line is 5 mm or less. Close proximity to interdental osteotomy cuts or to screws may cause tooth damage, and pulp necrosis [36]. The pulpal blood flow of teeth adjacent to vertical osteotomies of LeFort I segmental maxillary osteotomies has been reported to be decreased significantly at 4 days after surgeries for lateral incisors, canines, and premolars. However, recovery was seen 56 days after operations. The central incisors and teeth that are distant from the vertical osteotomy have blood flow without significant change [37]. It is advocated that presurgical orthodontic separation of the roots by at least 2 mm at the cemento-enamel junction and 4 mm at the apical third be maintained to avoid vascular compromise or damage to the roots adjacent to interdental osteotomies [36].

2. Sagittal split osteotomy

Sagittal split osteotomy (SSO) is a conventional technique to correct mandibular excess or retrognathia. Since its introduction by Trauner and Obwegeser, SSO has undergone numerous modifications and improvements [38].

2.1. Neurosensory disturbance

In SSO, the inferior alveolar nerve (IAN) may be injured and cause neurosensory disturbance (NSD) in the lower lip. The NSD caused by damage to the IAN is reportedly 9–84.6% [39, 40]. Even with careful surgery, injury to the IAN appears unpredictable. Multiple factors are considered responsible for the development of NSD after SSO, including fixation methods, patient age and surgical procedures, improper splinting, magnitude of mandibular movement, experience of the surgeon, and timing of the postoperative neurosensory evaluation [40]. Injury to the IAN may happen with direct and indirect intraoperative trauma and results in change of sensibility or altered sensation of the lower lip and/or mental region. It may lead the negative effect on patients' normal functions such as eating, drinking, speech, and social interaction. NSD may affect patients' everyday lives and can have social or psychological problems [41].

The position of the canal is important in NSD following SSO because the canal position is impacted by osteotomy design and fixation techniques. Nowadays, technologies and software help to evaluate the canal by using CBCT data. An increased distance between the canal and cortical bone presurgically decreased the incidence of postoperative NSD, and high bone density increased the risk of postoperative NSD. A short post-operation assessment comparing monocortical and bicortical fixation in a monkey model, showed that IAN function was better with plate fixation than screw fixation [42].

2.2. Unfavorable split

An unfavorable fracture, called a “bad split” although infrequent in the hands of an experienced operator, occasionally develop and can lead to intraoperative difficulties as well as postoperative relapse [43]. Frequently cited reasons for bad split include incomplete osteotomies, using osteotomes that are too large, attempting to split the segments too rapidly presence of impacted third molars, misdirecting the medial osteotomy upward toward the condyle and placement of the medial osteotomy too far superior to the lingula [44].

Synonyms used for bad split include “buccal cortical plate fracture” (proximal segment) and “lingual cortical plate fracture” (distal segment) [45]. A bad split can occur during SSO of the mandible regarding precautions. The incidence of bad split is low (0.7% of all SSOs) and patients sometimes have uneventful healing. A significant decrease in incidence did not report during the 20-year period, and neither technical progress nor the surgeon's experience further decreased the frequency of bad splits [45]. It was reported that older patients experienced more bad splits than younger patients [46]. The length of the medial osteotomy line—short or long—did not alter the prevalence of a bad split. The bone thickness of the ramus may affect the type of fracture pattern on the medial side of the ramus [47]. It is clear that certain mandibular anatomic differences can increase the risk of a bad split during SSO [44]. Use of splitters and separators instead of chisels does not increase the risk of a bad split and is therefore safe with predictable results [48].

2.3. Infection

Postoperative infection was reported in studies of patients undergoing bilateral sagittal ramus osteotomy in a period ranging from 5 days to up to a year after surgery. Infections required antibiotic therapy, and in some cases, the patients underwent surgical drainage. osteomyelitis in bilateral sagittal ramus osteotomy was reported [11]. The rate of infection after SSO is up to 11.3%. Infection after SSO is within normal range for a clean-contaminated procedure. Rigid fixation of the osteotomy may decrease the need for hardware removal [49].

2.4. Excessive bleeding

In the literature, there were no uniform criteria defining bleeding complications. Incidence varied between 0.39 and 38% ranging from slight to a life-threatening hemorrhage.

Minor bleeding in SSOs can usually be easily managed by using local anesthetics containing 1:100,000 adrenalin injected before the operation, electrocautery or compression. Excessive

blood loss may due to surgical injury of larger vessels. It was reported that excessive blood loss happen mainly to maxillary surgery and the need for blood transfusion in mandibular operations is rarely necessary [50].

2.5. Condylar resorption

Condylar resorption (CR) or condylolysis can be defined as progressive change of condylar shape with a reduction in mass. Most patients have a decrease in posterior face height, retrognathism, and progressive anterior open bite with clockwise rotation of the mandible. CR may be defined as osteoarthritis and can be categorized as primary (idiopathic) and secondary. Current evidence on CR is not clear but seen more in female with mandibular deficiency and high mandibular plane angle after bimaxillary surgery; a change in occlusal plane (counterclockwise rotation) may be associated with condylar resorption after orthognathic surgery [51]. It was hypothesized that condylar remodeling is due to an imbalance between mechanical stress applied to the temporomandibular joints (TMJ) and patient' adaptive capacities. It mainly occurs in 14 to 50-years-old women with pre-existing TMJ dysfunction, estrogen deficiency, and class II malocclusion with a high mandibular plane angle, a diminished posterior facial height and posteriorly inclined condylar neck. Mandibular advancement superior to 10 mm, counterclockwise rotation of the mandible, and posterior condylar repositioning were associated with an increased risk of CROS. Treatment consists of reoperation in case of degradation after an inactivity period of at least 6 months [52].

2.6. Temporomandibular dysfunction

The effect of orthognathic surgeries on temporomandibular dysfunction(TMD) is controversial. Some studies support degrees of improvement of TMD [5, 54]. Patients with preexisting TMJ dysfunction undergoing orthognathic surgery, particularly mandibular advancement, are likely to have significant worsening of the TMJ dysfunction postsurgery. TMJ dysfunction must be closely evaluated, treated if necessary and monitored in the orthognathic surgery patients [55]. Use of lag screws, improper control of the proximal segments, and advancement more than 10 mm increases the risk of post-orthognathic TMD. Orthognathic surgery should not be used solely for management of TMD; patients having orthognathic treatment for correction of their dentofacial deformities with TMD problem had more improvement in their signs and symptoms than deterioration [56].

2.7. Postoperative airway problem

It is clear that mandibular set back can affect upper airway patency [57]. The amount of narrowing of the pharyngeal airway is smaller in patients undergoing bimaxillary surgery than in patients undergoing mandibular setback surgery [58]. Bimaxillary orthognathic surgery for correction of Class III malocclusion caused an increase of the total airway volume and improvement of polysomnography parameters [59]. Bimaxillary surgery rather than mandibular setback surgery should be used to correct a class III deformity and reduce the risk of obstructive sleep apnea; in fact, bimaxillary surgery may have less effect on the pharyngeal airway patency than mandibular setback surgery alone [60]. A recent study suggested that

BSSO presents less change in the pharyngeal airway space after mandibular setback surgery compared to intraoral vertical ramus osteotomy. Furthermore, bimaxillary surgery is superior to mandibular setback surgery alone for the correction of the prognathic mandible, particularly in patients with factors predisposing them to the development of breathing problems [61].

3. Intraoral vertical ramus osteotomy

Intraoral vertical ramus osteotomy (IVRO) is another approach for the correction of mandibular prognathism. It is very simple and rapid. The inherent anatomic architecture of the mandible poses little interference on the cut surface of the IVRO osteotomy site during mandibular setback, even in cases of severe asymmetry. In addition, because the segments are not fixed, no stress occurs while the distal segment is positioned with the condylar head during and after the osteotomy procedure. Moreover, IVRO has less chance of nerve damage during the osteotomy procedure than SSRO. In addition to advantages provided during the operation, this procedure has various postoperative advantages. It seems to have curable effects on most patients with preoperative TMD [9].

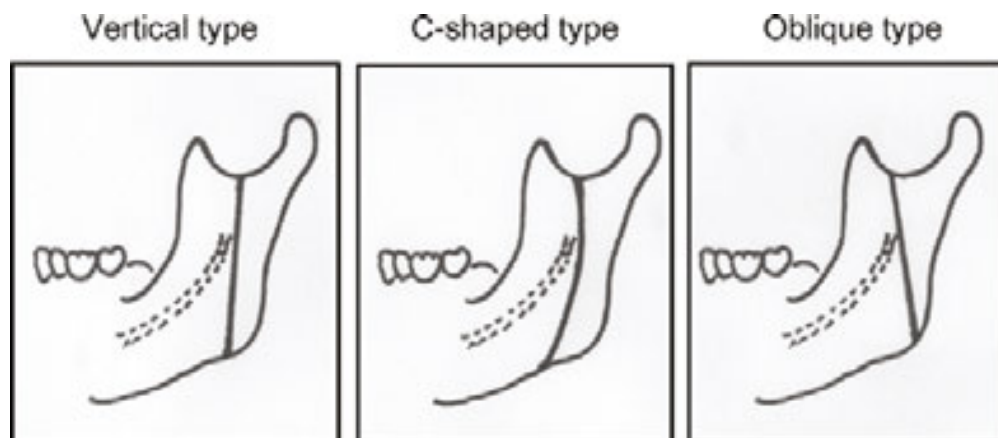


Figure 12. Classification of the shape of the osteotomy line [62].

During IVRO, inferior alveolar nerve (IAN) damage may occur due to the proximity of the vertical osteotomy to the IAN. Preoperatively, the surgeon should evaluate the lingula on radiographic views. The antilingual eminence on the lateral surface of the ramus should be detected. This small protuberance is located at the posterior one third from the posterior border of the ramus and about 10 mm above the occlusal plane of the lower molars in the vertical aspect, which corresponds to the opposite side of the mandibular foramen. The cut should begin 6–7 mm from the posterior border of the ramus. Kawase-Koga et al. classified the osteotomy line into three types, namely vertical, C-shaped, and oblique. The most complications occurred in the vertical type cases, and no complications were found in oblique type cases. Condylar luxation was found mainly in unilateral IVRO cases, and bony interference was found in bilateral IVRO cases. These results suggest that the oblique type of osteotomy line has the advantage of avoiding complications (**Figure 12**) [62].

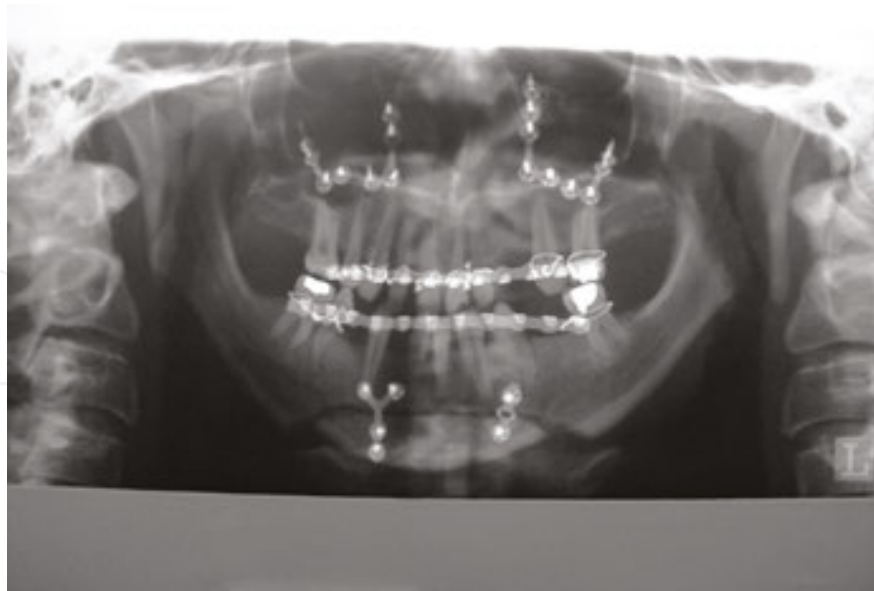

Figure 13. Condylar sagging at the (left side) after IVRO.

Condylar luxation and bony interference are major complications of IVRO [62]. The most troublesome sequelae are skeletal instability and antero-inferior condylar displacement (sag), with resultant unpredictability of postoperative mandibular position [63]. Condylar luxation is considered to be related to condylar sag, which occurs with the antero-inferior postoperative displacement of the proximal segment [62]. When the attachments of the masseter and medial pterygoid muscles to the proximal segment are removed extensively, large condylar sag occurs as a complication of IVRO. Condylar luxation is also related to forward force on the condyle from the lateral pterygoid muscle. Normally, the condyle is located in the anterior and inferior position within the glenoid fossa immediately after IVRO. It is gradually resealed into the original position after surgery with the application of intermaxillary elastics [64]. Several techniques have been reported to avoid condylar luxation and interference of the proximal segment. Suturing the periosteum of the segments around the incision with 3–0 Vicryl to prevent sagging against the mandibular fossa has been suggested [64]. Rigid fixation is not recommended in IVRO and increases risk of post-operation open bite. Elastic therapy after osteotomy effectively decreases open bite due to the muscle tension (**Figure 13**).

Author details

Reza Tabrizi* and Hassan Mir Mohammad Sadeghi

*Address all correspondence to: tabmed@gmail.com

Department of Oral and Maxillofacial Surgery, Shahid Beheshti University of Medical Sciences, Tehran, Iran

References

- [1] Kim, S.-G., and S.-S. Park, *Incidence of complications and problems related to orthognathic surgery*. Journal of Oral and Maxillofacial Surgery, 2007. 65(12): p. 2438–2444.
- [2] Tabrizi, R., H. Pakshir, and B. Nasehi, *Does the type of maxillomandibular deformity influence complication rate in orthognathic surgery?* Journal of Craniofacial Surgery, 2015. 26(7): p. e643–e647.
- [3] Wassmund, M., Leipzig: H. Meußner *Lehrbuch der praktischen Chirurgie des Mundes und der Kiefer*. Vol. 1. 1935: H. Meusser.
- [4] Garg, S., and S. Kaur, *Evaluation of post-operative complication rate of Le Fort I osteotomy: a retrospective and prospective study*. Journal of Maxillofacial and Oral Surgery, 2014. 13(2): p. 120–127.
- [5] Kramer, F.J., et al., *Intra- and perioperative complications of the LeFort I osteotomy: a prospective evaluation of 1000 patients*. Journal of Craniofacial Surgery, 2004. 15(6): p. 971–977; discussion 978–979.
- [6] Li, K.K., J.G. Meara, and A. Alexander, Jr., *Location of the descending palatine artery in relation to the Le Fort I osteotomy*. Journal of Oral and Maxillofacial Surgery, 1996. 54(7): p. 822–825; discussion 826–827.
- [7] Khanna, S., and A.B. Dagum, *A critical review of the literature and an evidence-based approach for life-threatening hemorrhage in maxillofacial surgery*. Annals of Plastic Surgery, 2012. 69(4): p. 474–478.
- [8] Turvey, T., and R. Fonseca, *The anatomy of the internal maxillary artery in the pterygopalatine fossa: its relationship to maxillary surgery*. Journal of Oral Surgery (American Dental Association: 1965), 1980. 38(2): p. 92.
- [9] Felice O'Ryan, A.S., *Complications with Orthognathic Surgery*, in *Oral and maxillofacial surgery*, M. Fonseca, Turvey, Editor. 2009, Saunders Elsevier. p. 419–489.
- [10] Eftekharian, H., et al., *Effect of tranexamic acid irrigation on perioperative blood loss during orthognathic surgery: a double-blind, randomized controlled clinical trial*. Journal of Oral Maxillofacial Surgery, 2015. 73(1): p. 129–133.
- [11] Sousa, C.S., and R.N.T. Turrini, *Complications in orthognathic surgery: a comprehensive review*. Journal of Oral and Maxillofacial Surgery, Medicine, and Pathology, 2012. 24(2): p. 67–74.
- [12] Essick, G., et al., *Short-term sensory impairment after orthognathic surgery*. Oral and Maxillofacial Surgery Clinics of North America, 2001. 13(2): p. 295–314.
- [13] Hummes, B., et al., *Complicações no tratamento cirúrgico da deficiência transversa do osso maxilar*. Stomatos, 2008. 14(27):p. 63–73.

- [14] Essick, G.K., et al., *Facial altered sensation and sensory impairment after orthognathic surgery*. International Journal of Oral and Maxillofacial Surgery, 2007. 36(7): p. 577–582.
- [15] Panula, K., K. Finne, and K. Oikarinen, *Incidence of complications and problems related to orthognathic surgery: a review of 655 patients*. Journal of Oral and Maxillofacial Surgery, 2001. 59(10): p. 1128–1136.
- [16] Kahnberg, K., and H. Engström, *Recovery of maxillary sinus and tooth sensibility after Le Fort I osteotomy*. British Journal of Oral and Maxillofacial Surgery, 1987. 25(1): p. 68–73.
- [17] Robl, M.T., B.B. Farrell, and M.R. Tucker, *Complications in orthognathic surgery: a report of 1000 cases*. Oral and Maxillofacial Surgery Clinics of North America, 2014. 26(4): p. 599–609.
- [18] de Jongh, M., D. Barnard, and D. Birnie, *Sensory nerve morbidity following Le Fort I osteotomy*. Journal of Maxillofacial Surgery, 1986. 14: p. 10–13.
- [19] Valstar, M.H., et al., *Maxillary sinus recovery and nasal ventilation after Le Fort I osteotomy: a prospective clinical, endoscopic, functional and radiographic evaluation*. International Journal of Oral Maxillofacial Surgery, 2013. 42(11): p. 1431–1436.
- [20] Bell, C.S., W.J. Thrash, and M.K. Zysset, *Incidence of maxillary sinusitis following Le Fort I maxillary osteotomy*. Journal of Oral and Maxillofacial Surgery, 1986. 44(2): p. 100–103.
- [21] Nocini, P.F., et al., *Is Le Fort I osteotomy associated with maxillary sinusitis?* Journal of Oral and Maxillofacial Surgery, 2016. 74(2): p. 400. e1–400. e12.
- [22] Acebal-Bianco, F., et al., *Perioperative complications in corrective facial orthopedic surgery: a 5-year retrospective study*. Journal of Oral and Maxillofacial Surgery, 2000. 58(7): p. 754–760.
- [23] Lanigan, D.T., J.H. Hey, and R.A. West, *Aseptic necrosis following maxillary osteotomies: report of 36 cases*. Journal of Oral and Maxillofacial Surgery, 1990. 48(2): p. 142–156.
- [24] Pereira, F.L., et al., *Maxillary aseptic necrosis after Le Fort I osteotomy: a case report and literature review*. Journal of Oral and Maxillofacial Surgery, 2010. 68(6): p. 1402–1407.
- [25] Kahnberg, K.E., and C. Hagberg, *The approach to dentofacial skeletal deformities using a multisegmentation technique*. Clinics in Plastic Surgery, 2007. 34(3): p. 477–484.
- [26] Singh, J., et al., *Reconstruction of post-orthognathic aseptic necrosis of the maxilla*. British Journal of Oral Maxillofacial Surgery, 2008. 46(5): p. 408–410.
- [27] Lanigan, D.T., and P. Guest, *Alternative approaches to pterygomaxillary separation*. International Journal of Oral Maxillofacial Surgery, 1993. 22(3): p. 131–138.
- [28] Precious, D.S., et al., *Pterygoid plate fracture in Le Fort I osteotomy with and without pterygoid chisel: a computed tomography scan evaluation of 58 patients*. Journal of Oral Maxillofacial Surgery, 1993. 51(2): p. 151–153.

- [29] Bhaskaran, A., et al., *A complication of Le Fort I osteotomy*. International Journal of Oral and Maxillofacial Surgery, 2010. 39(3): p. 292–294.
- [30] Renick, B.M., and J.M. Symington, *Postoperative computed tomography study of pterygo-maxillary separation during the Le Fort I osteotomy*. Journal of Oral Maxillofacial Surgery, 1991. 49(10): p. 1061–1065; discussion 1065–1066.
- [31] Tabrizi, R., B. Zamiri, and H. Kazemi, *Correlation of clinical predictions and surgical results in maxillary superior repositioning*. Journal of Craniofacial Surgery, 2014. 25(3): p. e220–e223.
- [32] Lübbers, H.-T., et al., *Classification of potential risk factors for trigeminocardiac reflex in craniomaxillofacial surgery*. Journal of Oral and Maxillofacial Surgery, 2010. 68(6): p. 1317–1321.
- [33] Lanigan, D.T., K. Romanchuk, and C.K. Olson, *Ophthalmic complications associated with orthognathic surgery*. Journal of Oral and Maxillofacial Surgery, 1993. 51(5): p. 480–494.
- [34] Cheng, H.C., et al., *Blindness and basal ganglia hypoxia as a complication of Le Fort I osteotomy attributable to hypoplasia of the internal carotid artery: a case report*. Oral Surgery, Oral Medicine, Oral Pathology, Oral Radiology and Endodontology, 2007. 104(1): p. e27–e33.
- [35] Jang, S.Y., et al., *Nasolacrimal duct obstruction after maxillary orthognathic surgery*. Journal of Oral and Maxillofacial Surgery, 2013. 71(6): p. 1085–1098.
- [36] Ho, M., et al., *Surgical complications of segmental Le Fort I osteotomy*. British Journal of Oral and Maxillofacial Surgery, 2011. 49(7): p. 562–566.
- [37] Emshoff, R., et al., *Effect of segmental Le Fort I osteotomy on maxillary tooth type-related pulpal blood-flow characteristics*. Oral Surgery, Oral Medicine, Oral Pathology, Oral Radiology and Endodontology, 2000. 89(6): p. 749–752.
- [38] Trauner, R., and H. Obwegeser, *The surgical correction of mandibular prognathism and retrognathia with consideration of genioplasty. I. Surgical procedures to correct mandibular prognathism and reshaping of the chin*. Oral Surgery, Oral Medicine, Oral Pathology, 1957. 10(7): p. 677–689; contd.
- [39] Al-Bishri, A., et al., *Neurosensory disturbance after sagittal split and intraoral vertical ramus osteotomy: as reported in questionnaires and patients' records*. International Journal of Oral and Maxillofacial Surgery, 2005. 34(3): p. 247–251.
- [40] Kuroyanagi, N., et al., *Prediction of neurosensory alterations after sagittal split ramus osteotomy*. International Journal of Oral and Maxillofacial Surgery, 2013. 42(7): p. 814–822.
- [41] Bruckmoser, E., et al., *Factors influencing neurosensory disturbance after bilateral sagittal split osteotomy: retrospective analysis after 6 and 12 months*. Oral Surgery, Oral Medicine, Oral Pathology and Oral Radiology, 2013. 115(4): p. 473–482.

- [42] Rich, J., B.A. Golden, and C. Phillips, *Systematic review of preoperative mandibular canal position as it relates to postoperative neurosensory disturbance following the sagittal split ramus osteotomy*. International Journal of Oral and Maxillofacial Surgery, 2014. 43(9): p. 1076–1081.
- [43] Smith, B.R., et al., *Mandibular ramus anatomy as it relates to the medial osteotomy of the sagittal split ramus osteotomy*. Journal of Oral and Maxillofacial Surgery, 1991. 49(2): p. 112–116.
- [44] Aarabi, M., et al., *Relationship between mandibular anatomy and the occurrence of a bad split upon sagittal split osteotomy*. Journal of Oral and Maxillofacial Surgery, 2014. 72(12): p. 2508–2513.
- [45] Falter, B., et al., *Occurrence of bad splits during sagittal split osteotomy*. Oral Surgery, Oral Medicine, Oral Pathology, Oral Radiology, and Endodontology, 2010. 110(4): p. 430–435.
- [46] Kriwalsky, M.S., et al., *Risk factors for a bad split during sagittal split osteotomy*. British Journal of Oral and Maxillofacial Surgery, 2008. 46(3): p. 177–179.
- [47] Zamiri, B., et al., *Medial cortex fracture patterns after sagittal split osteotomy using short versus long medial cuts: can we obviate bad splits?* International Journal of Oral and Maxillofacial Surgery, 2015.44(7): p. 809–15
- [48] Mensink, G., et al., *Bad split during bilateral sagittal split osteotomy of the mandible with separators: a retrospective study of 427 patients*. British Journal of Oral and Maxillofacial Surgery, 2013. 51(6): p. 525–529.
- [49] Bouchard, C. and M. Lalancette, *Infections after sagittal split osteotomy: a retrospective analysis of 336 patients*. Journal of Oral and Maxillofacial Surgery, 2015. 73(1): p. 158–161.
- [50] Teltzrow, T., et al., *Perioperative complications following sagittal split osteotomy of the mandible*. Journal of Craniomaxillofacial Surgery, 2005. 33(5): p. 307–313.
- [51] de Cirugía Ortognática, R.C.D. and U.R. Sistemática, *Condylar resorption after orthognathic surgery: a systematic review*. International Journal of Morphology, 2012. 30(3): p. 1023–1028.
- [52] Catherine, Z., P. Breton, and P. Bouletreau, *Condylar resorption after orthognathic surgery: a systematic review*. Revue de stomatologie, de chirurgie maxillo-faciale et de chirurgie orale, 2015.
- [53] Valladares-Neto, J., et al., *TMJ response to mandibular advancement surgery: an overview of risk factors*. Journal of Applied Oral Science, 2014. 22(1): p. 2–14.
- [54] Panula, K., et al., *Effects of orthognathic surgery on temporomandibular joint dysfunction*. International Journal of Oral & Maxillofacial Surgery, 2000. 29(3): p. 183–187.

- [55] Wolford, L.M., O. Reiche-Fischel, and P. Mehra, *Changes in temporomandibular joint dysfunction after orthognathic surgery*. Journal of Oral and Maxillofacial Surgery, 2003. 61(6): p. 655–660; discussion 661.
- [56] Al-Riyami, S., S.J. Cunningham, and D.R. Moles, *Orthognathic treatment and temporomandibular disorders: a systematic review. Part 2. Signs and symptoms and meta-analyses*. American Journal of Orthodontics and Dentofacial Orthopedics, 2009. 136(5): p. 626.e1–16, discussion 626–627.
- [57] Fernandez-Ferrer, L., et al., *Effects of mandibular setback surgery on upper airway dimensions and their influence on obstructive sleep apnoea—a systematic review*. Journal of Craniomaxillofacial Surgery, 2015. 43(2): p. 248–253.
- [58] Hong, J.S., et al., *Three-dimensional changes in pharyngeal airway in skeletal class III patients undergoing orthognathic surgery*. Journal of Craniomaxillofacial Surgery, 2011. 69(11): p. e401–e408.
- [59] Gokce, S.M., et al., *Evaluation of pharyngeal airway space changes after bimaxillary orthognathic surgery with a 3-dimensional simulation and modeling program*. American Journal of Orthodontics and Dentofacial Orthopedics, 2014. 146(4): p. 477–492.
- [60] Santagata, M., et al., *Effect of orthognathic surgery on the posterior airway space in patients affected by skeletal class III malocclusion*. Journal of Craniomaxillofacial Surgery, 2015. 14(3): p. 682–686.
- [61] Al-Moraissi, E.A., et al., *Impact on the pharyngeal airway space of different orthognathic procedures for the prognathic mandible*. International Journal of Oral and Maxillofacial Surgery, 2015. 44(9): p. 1110–1118.
- [62] Kawase-Koga, Y., et al., *Complications after intraoral vertical ramus osteotomy: relationship to the shape of the osteotomy line*. International Journal of Oral and Maxillofacial Surgery, 2016. 45(2): p. 200–204.
- [63] Ueki, K., et al., *The effects of changing position and angle of the proximal segment after intraoral vertical ramus osteotomy*. International Journal of Oral and Maxillofacial Surgery, 2009. 38(10): p. 1041–1047.
- [64] Yamauchi, K., T. Takenobu, and T. Takahashi, *Condylar luxation following bilateral intraoral vertical ramus osteotomy*. Oral Surgery, Oral Medicine, Oral Pathology, Oral Radiology, and Endodontology, 2007. 104(6): p. 747–751.