

We are IntechOpen, the world's leading publisher of Open Access books Built by scientists, for scientists

6,900

Open access books available

186,000

International authors and editors

200M

Downloads

Our authors are among the

154

Countries delivered to

TOP 1%

most cited scientists

12.2%

Contributors from top 500 universities



WEB OF SCIENCE™

Selection of our books indexed in the Book Citation Index
in Web of Science™ Core Collection (BKCI)

Interested in publishing with us?
Contact book.department@intechopen.com

Numbers displayed above are based on latest data collected.
For more information visit www.intechopen.com



Peritoneal Dialysis Catheters

O. Obinwa, J. McLoughlin, D. Kavanagh and C. Wall

Additional information is available at the end of the chapter

<http://dx.doi.org/10.5772/64024>

Abstract

In peritoneal dialysis, a well-functioning catheter is of great importance because a dysfunctional catheter may be associated with exit-site infection, peritonitis, reduced efficiency of dialysis, and overall quality of treatment, representing one of the main barriers to optimal use of peritoneal dialysis. This chapter reviews the literature on indications and contraindications for peritoneal dialysis, peritoneal dialysis catheter design and materials, the techniques of insertion, complications, and method of removal of dialysis catheters.

Keywords: peritoneal dialysis, Tenckhoff catheter design, indications, insertion technique, removal, complications

1. Introduction

Peritoneal dialysis (PD) is a suitable modality of renal replacement therapy in the setting of end-stage kidney disease. It was first used for the management of end-stage renal disease in 1959 [1]. The use of this modality became widespread, following the introduction of continuous ambulatory peritoneal dialysis. However, like in every aspect of medical care, the use of PD can at times result in harm to the patient [2]. A dysfunctional catheter may be associated with complications such as exit-site infection and peritonitis as well as technique failure. Evidence-based criteria for selection of suitable patients, catheter insertion techniques, and management should be employed, so as to reduce the potential for adverse events and subsequent requirement for transfer to hemodialysis (HD).

2. Peritoneal dialysis catheter design and materials

Various shapes, lengths, and sizes of peritoneal dialysis catheters have been described in the literature. Each catheter typically has an intraperitoneal component and an extraperitoneal component (**Figure 1**).

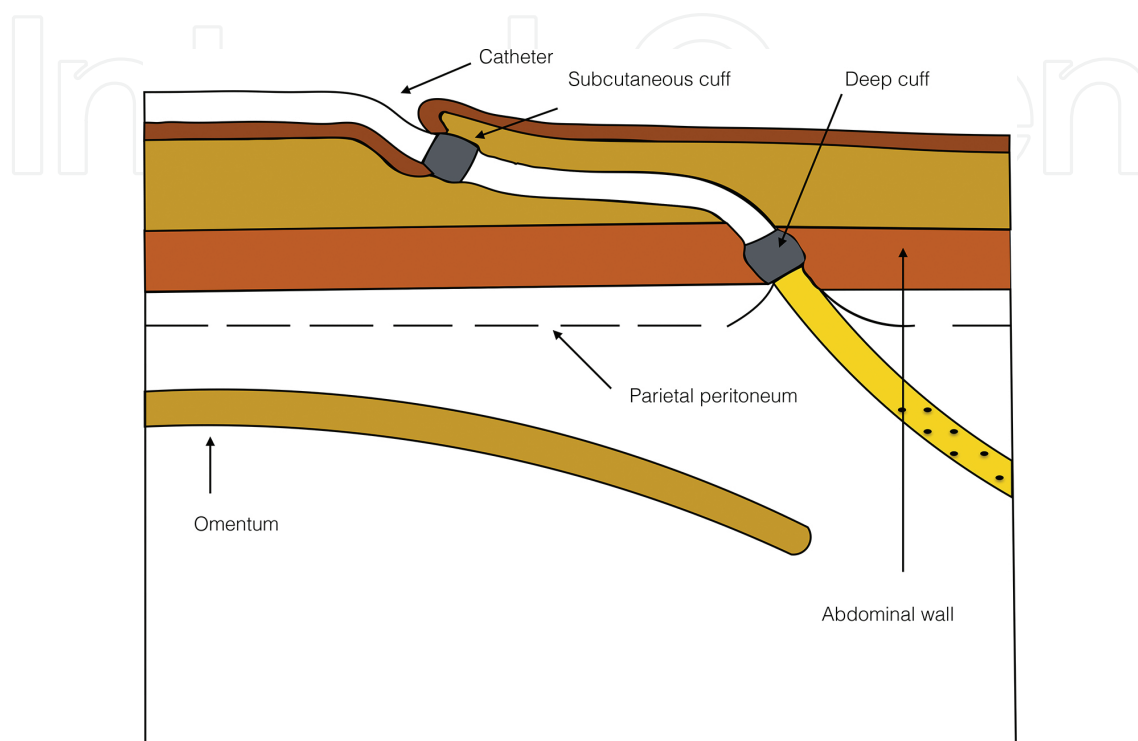


Figure 1. Schematic presentation of an indwelling catheter showing the intraperitoneal and extraperitoneal components.

The intraperitoneal component is often a flexible silicone tube with an open-end port and several side holes, which provide optimal drainage of the dialysate. The extraperitoneal component of the catheter has either one or two Dacron cuffs, which permit optimal ingrowth and fixation. A double-cuff catheter is typically used in adults: the proximal cuff is positioned in the preperitoneal space, while the distal cuff is placed in the subcutaneous tissue. The proximal cuff holds the catheter in place, while the distal cuff acts as a barrier to infection. Longer dialysis catheters have also been developed to allow placement of the exit sites in remote places such as the presternal area [3]. Such extended catheters may be useful in obese patients and those with an abdominal stoma.

The choice of catheter used for peritoneal dialysis is clinician-dependent and may be affected by available research evidence. The shape of the intraperitoneal segment may be an important factor when considering complication rates and catheter survival. Typical shapes of catheter tips include straight, pigtail-curved, and swan-neck forms. Although a coiled intraperitoneal segment may minimize infusion and pressure pain, straight catheters have demonstrated significant survival benefits when compared to coiled-tip catheters [4]. Further, surgically placed double-cuffed straight catheters display better survival rates than surgically placed

double-cuffed coiled catheters; however, the reason remains unknown [5]. Due to the reasons above, the double-cuffed straight Tenckhoff catheter remains the most widely used catheter in practice. Also, most Tenckhoff catheters have a barium-impregnated radio-opaque stripe, which aids radiological visualization of the catheter.

Further, there has been recent research on the use of antimicrobial modified silicone peritoneal catheters. In vitro challenge tests of these catheters impregnated with rifampicin, trimethoprim, and triclosan showed a long-standing ability for these catheters to kill more than 99% of pathogens commonly associated with PD infections, without the development of significant mutational resistance. These trial results have demonstrated promising results in reducing PD catheter infections. However, human clinical trials have not yet been performed [6].

3. Indications and contraindications

There are several advantages of using PD over hemodialysis. The simplicity of use and lower mortality in the first years after starting treatment are the most important.

3.1. Indications

Strong indications for PD include obligate situations such as vascular access failure and intolerance to hemodialysis (HD) generally due to cardiovascular instability. Certain medical conditions such as congestive heart failure, prosthetic valvular disease, peripheral vascular disease, and children aged 0–5 years infer a preference to PD over HD.

There are social situations to consider, such as patient preference and living far from an in-center dialysis unit [7]. PD is also beneficial in suitable patients as it facilitates home therapy, increases patient autonomy, and improves the quality of life when compared with in-center hemodialysis [8].

PD has been shown to better prolong residual renal function when compared with HD in patients awaiting renal transplant [9]. Other situations where PD is preferred include bleeding diathesis, multiple myeloma, labile diabetes, chronic infections, age between 6 and 16 years, needle anxiety, and active lifestyle [7].

Peritoneal dialysis has infrequently been utilized for nonrenal indications with variable benefits in conditions such as refractory congestive heart failure [10, 11], hepatic failure [12], hypothermia [13], hyponatremia, dialysis-associated ascites, drug poisonings, pancreatitis [14], and inherited enzyme deficiencies.

3.2. Contraindications

One absolute contraindication is the inability of a patient or caregiver to safely and efficiently use the PD catheter and equipment to carry out peritoneal dialysis. Other absolute contraindications include patients with documented Type II ultrafiltration failure (UF), severe inflammatory bowel disease, active acute diverticulitis, abdominal abscess, active ischemic bowel disease [15], severe active psychotic disorder, marked intellectual disability, and in women, starting dialysis in the third trimester of pregnancy [7].

Relative contraindications for PD include patients with severe malnutrition, multiple abdominal adhesions, ostomies [16], proteinuria with protein losses of more than 10 g/day, advanced COPD, ascites, presence of a LeVeen or ventriculoperitoneal shunt, upper limb amputation with no help at home, poor hygiene, dementia, and those who are homeless [7]. Situations where PD is not preferred but possible with some special considerations include obesity, severe backache, multiple abdominal surgeries, impaired manual dexterity, blindness, less-than-ideal home situation, and depression [7].

4. Insertion technique

In 1968, Henry Tenckhoff developed the indwelling peritoneal catheter, which was placed through an open surgical technique [17]. Since then, additional approaches including laparoscopic, percutaneous Seldinger, peritoneoscopic, and fluoroscopic placement techniques have been described. Both open and laparoscopic approaches to PD insertion are routinely performed under general anesthetic. Although traditionally reserved for patients not fit for general anesthesia, the percutaneous Seldinger technique of PD catheter insertion avoids general anesthesia and is being favored over recent years for use in PD naïve patients without a history of prior abdominal surgery [18]. In one single-center study, equivalent outcomes were reported with no difference regarding catheter survival at 3 months and 1 year, overall peritonitis rate, exit-site leaks, and primary and secondary drainage failure for open versus percutaneous PD catheter insertion techniques in patients without any history of prior abdominal surgery [19]. The implication is that the percutaneous Seldinger technique may also be the frontline approach to younger and healthier patients requiring dialysis in experienced hands and centers. The surgical and laparoscopic techniques still, however, retain their utility, particularly for insertions considered high-risk because of suspected abdominal adhesions or complex underlying anatomy.

Given that the key to successful dialysis is a well-functioning catheter, there are several clinical points, which must be considered before catheter insertion [20]. Careful patient selection, catheter choice, insertion technique, prophylactic antibiotics, and asepsis during the procedure are all important general concepts. Procedures should be performed by an operator with training and expertise in creating peritoneal access [21]. Antibiotic prophylaxis should be based on local guidelines [22]. Specific considerations for PD catheter insertion include the following:

1. The abdominal cavity must be able to store up to 2L of fluid at any one time before PD should be considered [16]. Therefore, attention must be paid to those with significant abdominal adhesions or entering the third trimester of pregnancy as they usually do not have sufficient capacity for dialysate fluid.
2. Patients with hernia, omphalocele, and gastroschisis, with several mechanical defects of the abdominal wall should have these defects corrected before contemplating peritoneal dialysis. The lack of integrity of their abdominal wall may prevent PD and may cause a fluid leak into the pleural space [16].

3. The use of PD catheters in patients with intra-abdominal vascular grafts and peritoneal shunts may increase the risk of contamination and graft infection [23]. Therefore, a 4-month waiting period between graft insertion and PD catheter insertion has been recommended by the National Kidney Foundation Kidney Disease Outcomes Quality Initiative Guidelines [15].

4.1. Open surgical technique [24]

This is the earliest described technique for peritoneal catheter insertion. Here, a 3–5 cm infraumbilical midline incision is made. Then, the subcutaneous layer is dissected down to the sheath of the rectus abdominal muscle. The anterior rectus sheath is opened, and the muscle fibers are separated by blunt dissection. The abdominal cavity is entered following incision of the posterior rectus sheath and peritoneum. The abdomen is inspected for adhesions, and if any adhesion is present close to the abdominal wall, they are dissected. Next, the patient is placed in the Trendelenburg position; the catheter is advanced into the peritoneal cavity over a stylet. The cuff is finally positioned in the preperitoneal space on removing the stylet. The peritoneum and posterior and anterior rectus sheaths are closed with absorbable sutures, taking care to prevent catheter obstruction and leakage of dialysate. A tunnel is then created to the preferred exit site, which is usually lateral and caudal to the entrance site below the belt line (**Figure 2**).

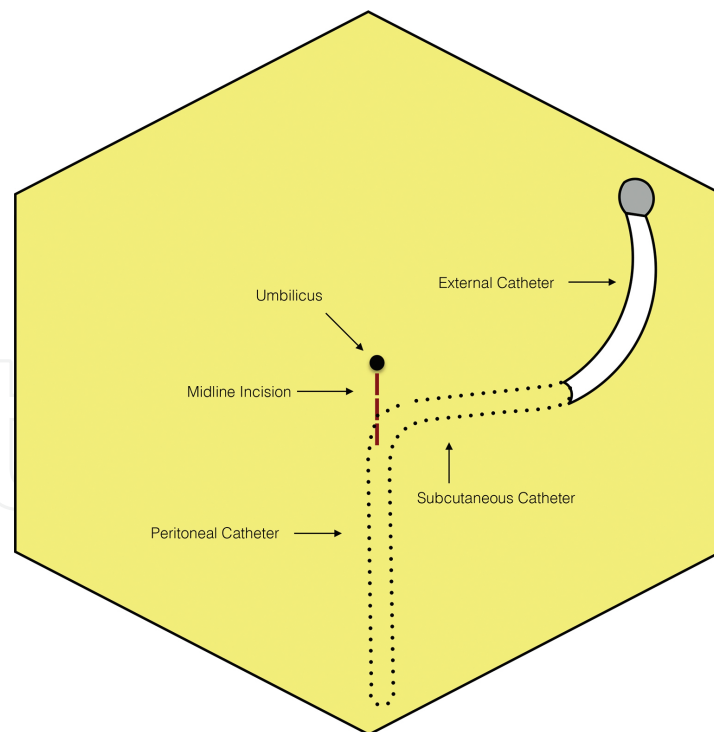


Figure 2. Open surgical placement of a peritoneal dialysis catheter. The distal cuff is placed subcutaneously, 2 cm from the exit site. The incision is closed, and the catheter is tested by filling the abdomen with 100 ml of sterile saline. It is important to check for leakage at the entrance site. The drained saline is also inspected to ensure no intraperitoneal bleeding or fecal contamination.

4.2. The laparoscopic technique

The laparoscopic approach to peritoneal dialysis is becoming more popular because of its advantage in facilitating a partial omentectomy or adhesiolysis during the initial catheter placement. Approximately 80% of patients who have had previous abdominal operations have adhesions between the omentum and abdominal wall, with 20% having involvement of the small intestine [25]. The laparoscopic PD catheter insertion technique has also been found to be superior to the conventional open technique. This superiority was measured in a higher rate of catheter survival at 1 year and a lower rate of catheter migration (1.3–5.4% following laparoscopic insertion compared to between 7.6 and 17.1% with open techniques) [20]. There was no difference noted in the rates of peritonitis or exit-site/tunnel infections between the laparoscopic and open techniques [20].

A safe technique of insertion is described here. First, a pneumoperitoneum is typically established via an open Hasson technique with a 10 mm access port in a subumbilical midline position. Diagnostic laparoscopy is performed with a 0° lens of 10 mm. A 5 mm right iliac fossa (RIF) port is inserted under vision (**Figure 3a**).

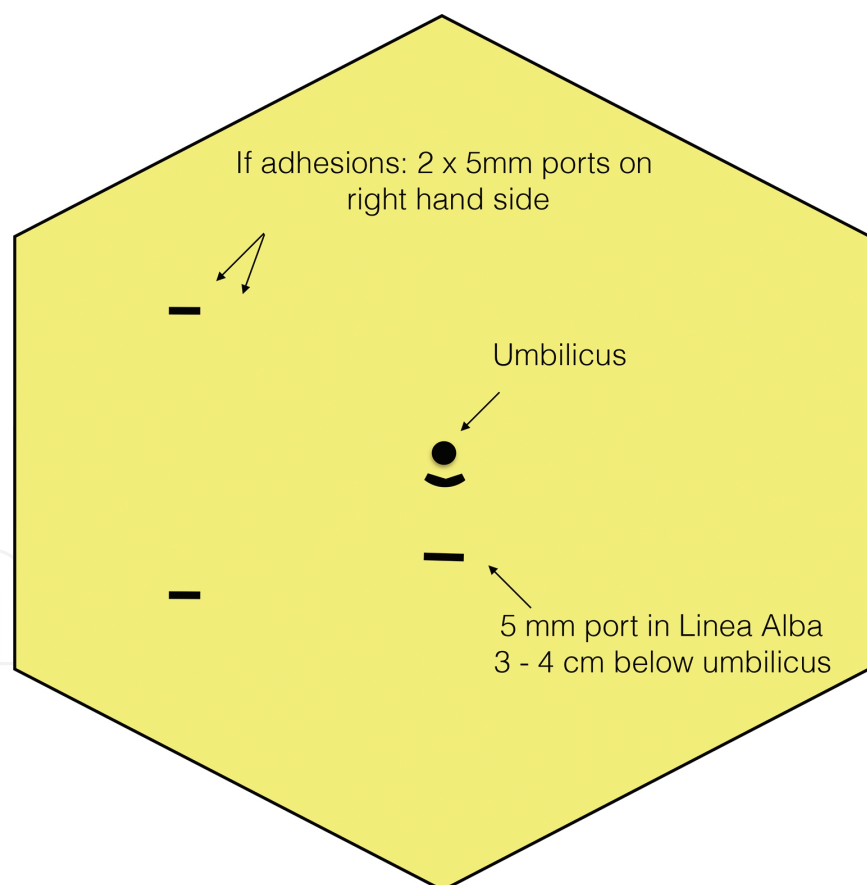


Figure 3a. Laparoscopic port placement for PD catheter insertion. If adhesions are present, then an additional 5 mm right upper quadrant trocar is placed into the abdominal cavity, and the adhesions are lysed using instruments via the two right-hand ports. A 5 mm trocar is then placed under direct vision, 3–4 cm below the umbilicus, and the PD catheter is advanced through this port in the linea alba.

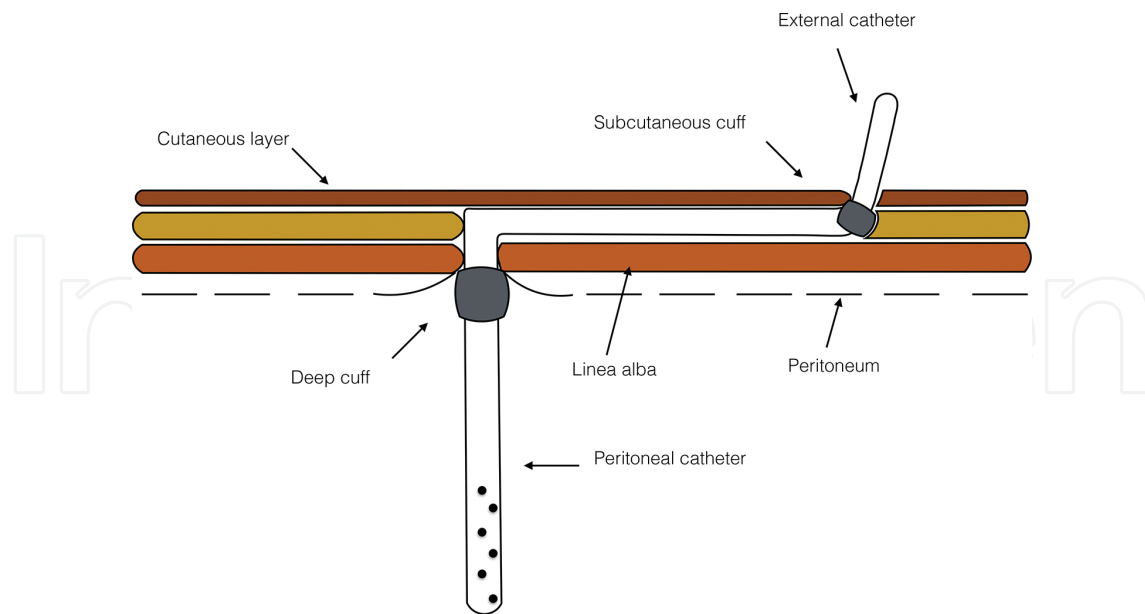


Figure 3b. PD catheter insertion through the linea alba. The catheter tip is manipulated into position (Pouch of Douglas in females or behind the urinary bladder in males) using the RIF port instrument. The paraumbilical trocar is removed, and the catheter is then directed to its premarked exit-site location. The catheter is tested before abdominal desufflation. The trocars are removed under vision, and the rectus sheaths and skin are closed.

4.3. Percutaneous technique

The percutaneous approach provides a less invasive approach but conversely has an increased risk of catheter malplacement or bowel injury [24]. These complications largely occur because the procedure employs a blind approach. Errors may be limited by the careful selection of patients or by additional use of image guidance for insertion. A blind technique is considered less safe in very obese patients [18]. Other contraindications to percutaneous catheter insertion include previous open abdominal surgery other than appendectomy or cesarean section, a bleeding tendency, and preexisting hernia requiring simultaneous repair [18]. In a recent review, it was shown that catheter survival was unaffected by placement modality (i.e., percutaneous vs. open) [26]. However, early mechanical complications, including technical failures, are more likely to occur with the percutaneous Seldinger technique [26].

Percutaneous insertion of a PD catheter is carried out as a side-room procedure. The catheter is inserted under local anesthesia, and conscious sedation is managed according to local clinical governance procedures. Premedications may include DF118 (dihydrocodeine) 60 mg, intravenous prophylactic antibiotics, and oral diazepam 10 mg [18]. A small infraumbilical incision is made at the entrance site, usually in the midline. The subcutaneous tissues are divided; the anterior rectus sheath is incised; and the abdominal rectus muscles are separated by blunt dissection. An appropriate-sized needle (18 gauge) is placed into the peritoneal cavity. Proper positioning of the needle is confirmed by filling the peritoneal cavity with air or 500 ml of saline. The absence of pain or resistance with filling suggests proper needle positioning. The catheter is placed in the peritoneal space using the Seldinger technique, with the aid of a 0.035-inch guide wire, a dilator, and a peel-away sheath. Of note, the proximal cuff should be in the

preperitoneal position at the end of a successful placement. Tunneling and catheter checks are similar to that described for the open technique. The entrance site only is closed.

An alternative placement technique is to bury the external segment of the catheter in the subcutaneous tissues until such a time that PD is required. The rationale is to prevent colonization of the catheter by skin bacteria and to promote attachment of the cuff to the tissue before exteriorization. Results with this technique have, however, been conflicting. The developers noted a reduction in the rate of peritonitis and colonization of bacterial biofilms in the catheter segments between the two cuffs [27]; however, a randomized controlled trial would be required to confirm these results [28].

Units should have clear and well-documented protocols for perioperative catheter care. It may be feasible to commence PD immediately after placement, but this approach should be limited to those who have an immediate clinical need to commence renal replacement therapy [29]. Ideally, PD should be started between 2 and 3 weeks after placement of the catheter. This approach allows sufficient time for wound healing and securing of the catheter cuff. Following insertion, the catheter is flushed with low-volume dialysate until the effluent is clear. Then the catheter is capped and covered with nonocclusive dressings. It is left undisturbed for 10–14 days with infrequent changes of dressing (such as once or twice a week).

5. Complications and management

Peritoneal dialysis-related complications remain a significant cause of morbidity and mortality. It is recommended that all healthcare providers who insert PD catheters in each institution should meet at least once every 12 months to review their PD catheter data [22]. Data collected should include details and management of postoperative complications, infections, dialysate fluid leak, and catheter dysfunction. Audit standards for catheter-related complications include bowel perforation rate of less than 1%, significant hemorrhage of less than 1%, and exit-site infection within 2 weeks of catheter insertion of less than 5% [22]. Other standards include peritonitis within 2 weeks of catheter insertion of less than 5% and limiting the incidence of functional catheter problem requiring interventions to less than 20% of cases [22]. A greater than 80% patency rate of catheters at 1 year (censoring for death and elective modality change) is also recommended [21].

Complications can be classified into early (occurring within 30 days from insertion) and late (occurring after 30 days from insertion) [24].

5.1. Early complications

5.1.1. Bowel perforation

Bowel perforation is a rare complication with an approximate incidence of 1% [24]. It usually occurs during entry into the abdominal cavity. Delayed perforation of the bowel by a PD catheter can also occur, but it is more uncommon [30]. The clinical finding of watery diarrhea

on commencement of dialysis raises clinical suspicion. Other findings might include sudden onset of abdominal pain and rigidity on examination. Contrast fluoroscopy, colonoscopy, and CT are recommended for diagnosis. Patients should be treated after confirmation of diagnosis. The treatment of choice in bowel perforation is definitive surgical exploration, repair, and removal of the catheter [24]. In the presence of significant peritoneal contamination, a diversion of stoma may be required [31]. However, there are anecdotal reports of successful management, with the removal of the catheter, antibiotics, parenteral nutrition, and hemodialysis [32]. In one case report, the catheter was successfully removed laparoscopically, and the perforation was closed with endoscopic clips [30].

5.1.2. Bleeding

The rate of serious bleeding complications related to catheter insertions is low and was associated with anticoagulation in one series [33]. Holding anticoagulation therapy for a minimum of 24 h during the postoperative period should eliminate much of the risk [33]. Coagulation parameters should be obtained and corrected preoperatively. When such bleeding occurs, it is usually at the exit site [24]. Manual pressure or addition of suturing can stop the persistent bleeding [24]. Additionally, the initial effluent drained may be bloody, due to the trauma of insertion, but this would normally clear within a few days [24].

5.1.3. Exit-site infection

The most common causative organisms include *Staphylococcus epidermidis* and *Staphylococcus aureus* [34]. Other organisms include *Pseudomonas aeruginosa*, gram-negative bacteria, and some nondiphtheria *Corynebacteria* [34]. The presence of nondiphtheria *Corynebacteria* species infection favors consideration for antiseptics to be applied as part of the exit-site management [34]. Once established, exit-site infection may respond to appropriate antibiotic treatment when it is superficial. Deep infection may require drainage, catheter removal, and replacement [35]. An exit-site infection that does not respond to treatment may lead to tunnel infection including abscess formation and to persistent peritonitis, which may require catheter removal and occasionally discontinuation of the peritoneal dialysis.

5.1.4. Outflow failure

There are multiple distinct causes of outflow failure. These include clots or fibrin deposits within the catheter, catheter malplacements, kinking of the catheter within the subcutaneous tunnel, and development of omental wrap or adhesions in the abdomen [24]. Attempts can be made to clear an obstructed catheter: either forceful irrigation using saline or urokinase can be performed; alternatively, advancement of a stiff guide wire under direct fluoroscopic control can be utilized in an attempt to clear [24]. If there is a kink in the subcutaneous tunnel, then an incision is made directly over the kink, and the catheter is repositioned [24]. Outflow obstruction may also occur from malpositioning of the catheter into the upper abdomen. The position of the catheter may be identified on plain film or under fluoroscopy, with the injection of contrast into the catheter [24]. The catheter may then be repositioned with a stiff guide wire, forceps, or laparoscopically [36].

5.1.5. *Leakage of the dialysate*

Dialysate leakage represents a major noninfectious complication of PD and includes any dialysate loss from the peritoneal cavity other than via the lumen of the catheter [37]. This may be identified by the presence of drainage at the exit site or the appearance of a bulge underneath the entrance site. Early leaks, occurring within 30 days of catheter insertion, most often manifest as pericatheter leakage [37]. Late leaks tend to develop more than 30 days after catheter insertion and may present with poor dialysate outflow, subcutaneous edema, weight gain, peripheral or genital edema, hernia, and apparent ultrafiltration failure [37].

Leaks may also occur due to a hernia at the entrance site, trauma, or due to the positioning of the proximal cuff on the rectus muscle. Withholding peritoneal dialysis for several weeks may solve the problem [24]. Management options for dialysate leaks include surgical repair, use of lower dialysate volumes, temporary transfer to hemodialysis, and changing from the continuous ambulatory PD modality to automated PD with a dry day. Delaying PD for 14 days after catheter insertion may prevent early dialysate leaks [37], and initiating PD with low dialysate volumes is recommended as a good practice measure [38].

5.1.6. *Peritonitis*

This may occur early and manifests as abdominal pain associated with the cloudy peritoneal fluid [39]. In one prospective randomized study, the use of preoperative single-dose IV vancomycin prophylaxis for permanent PD catheter placement reduces the risk of postoperative peritonitis [40]. Further, single-dose vancomycin was superior to single-dose cefazolin in minimising the risk of postoperative peritonitis [40]. Absence of prophylaxis is associated with a high risk of developing postoperative peritonitis [40].

5.2. Late complications

5.2.1. *Cuff extrusion or infection*

This complication may occur when the exit-site catheter is placed directly beneath the belt line or when the superficial cuffs are placed too close to the skin. In any such situations, the catheter should be exchanged and a new exit site selected. The use of modified Tenckhoff catheters such as a swan-neck catheter, Ash catheter, and the T-fluted catheter may reduce this risk of extrusion.

5.2.2. *Outflow failure*

Outflow failure that occurs after 30 days is most commonly due to constipation and is best managed with appropriate laxative therapy [24].

5.2.3. *Peritonitis*

Peritonitis is a leading cause of switch from PD to HD, in particular, within the first 2 years [41], and it is often the result of contamination with skin bacteria. A study by Davenport et al. [42]

reported the highest incidence organism as coagulase-negative staphylococcus in 77.2% of cases. Other organisms in decreasing order of frequency included gram-negative organisms, *Staphylococcus aureus*, *Pseudomonas*, and methicillin-resistant *S. aureus*. In that study, the cure rates were higher for those centers that used a combination of intraperitoneal gentamicin and cephalosporins than those centers that used oral-based regimens [42].

The cure rates for PD-associated peritonitis are largely dependent on the infecting organism. Systemic or intraperitoneal antibiotics are administered. Usually, a peritoneal dialysis catheter-related peritonitis resolves with proper antibiotic therapy. If the infection persists, catheter removal and transfer to hemodialysis for 4–6 weeks are sufficient for the resolution of peritonitis [43]. There is a strong association between exit-site infections and subsequent peritonitis, with an increased risk up to 60 days after initial diagnosis [44].

5.2.4. Ultrafiltration failure

Loss of ultrafiltration (UF) and ability to maintain volume homeostasis is another cause of failure of PD. Prevalence rates of ultrafiltration failure resulting in a switch to HD occur in approximately 1.7–13.7% of cases and increase with time on peritoneal dialysis as well, following recurrent peritonitis episodes [45]. UF failure presents clinically with circulatory volume overload. It is important to first rule out other possible causes of volume overload [46].

5.2.5. Catheter migration

Catheter migration is a significant complication of PD with the potential to cause PD failure, removal of the catheter, and requirement for transfer to HD therapy. Manipulation under fluoroscopy by a guide wire or Fogarty catheter and catheter exchange may be attempted first. Surgical intervention may, however, be necessary in some cases to restore function. Various catheter designs and insertion techniques have been described to overcome this problem [47]. The dialysate can still be infused when migration occurs, but drainage of the fluid from the peritoneal cavity may be difficult. In some cases, the catheter tip is fixated to prevent migration [48].

6. Catheter removal

Refractory peritonitis which is defined as failure of the effluent to clear after 5 days of appropriate antibiotics is best managed by removal of the PD catheter [49]. This follows the ethos of “save the patient not the catheter” [50]. Catheter removal prevents morbidity and mortality associated with refractory peritonitis and importantly protects the peritoneum for future PD. Attempts to manage prolonged peritonitis without catheter removal have been associated with an extended hospital stay, peritoneal membrane damage, and increased risk of fungal peritonitis [39]. The British Renal Association has recommended that following the removal of a catheter in patients with nonconcomitant peritonitis, a new catheter can be inserted into the opposite side of the abdomen, either during the same operation as the removal or at a subsequent date. They also recommend that for patients with simultaneous peritonitis that has

failed to clear, a new catheter should not be inserted until for at least 2 weeks following removal [51]. Besides the indication for removal based on infectious complications, noncatheter-related reasons for discontinuation of PD include death, transplantation, recovery of renal function, and transfer to hemodialysis because of ultrafiltration failure, poor clearance, or patient choice [18].

Two techniques of catheter removal are described in the literature: PD pull technique and surgical removal. Each technique has advantages. The main advantages of the pull technique over the surgical technique include the following: a general anesthetic or operation is not required; the procedure takes only a few minutes with quicker patient recovery, allowing little to no interruption to work or home schedule.

6.1. PD pull technique

Here, the patient lies on a couch or bed, and the dressing is removed. The exit site is inspected for the presence of an infection. In the absence of an exit-site infection, the PD catheter is extracted by applying firm abdominal pressure around the PD catheter site, while maintaining a firm and steady pull on the catheter with the other hand. The superficial cuff may slide off the skin, but usually both cuffs are left in situ. The cuff may become infected at a later stage, and this serves a limitation to this approach.

6.2. Surgical removal

This method of removal is recommended for infected PD exit sites. The procedure is usually performed as a day case and follows standard day surgery protocols including preoperative assessment and consent. A general anesthesia is required, and the procedure takes about 20 min. A small incision is made just below the umbilicus. The catheter and cuff are then removed from the abdominal cavity. The incision is closed using absorbable sutures. A dressing is applied and replaced weekly until the wound is healed.

7. Summary

A well-functioning peritoneal dialysis catheter is essential for ongoing effective peritoneal dialysis. In order to optimize its function and patient safety, careful patient selection plays an important role. Catheter insertion is performed using several approaches, including laparoscopic, percutaneous, and open surgical, each with its unique advantages. However, there may be complications following insertion, which may necessitate catheter removal and switch to hemodialysis. A regular audit of outcomes of catheter insertions is recommended.

Key points

- The success of peritoneal dialysis requires a functional peritoneal dialysis catheter in an appropriately selected and trained patient.

- Peritoneal catheterization should be avoided until the need for regular peritoneal dialysis arises.
- There are several catheter designs available, but the choice is often clinician-dependent.
- Numerous techniques for insertion have been described, including open, laparoscopic, and percutaneous techniques.
- Laparoscopic catheter insertion is becoming more popular. This insertion technique has been reported to have a higher rate of catheter survival and a lower rate of catheter migration when compared to open surgical insertion.
- A percutaneous insertion is an option in patients with end-stage kidney disease and multiple comorbidities as it can be performed under local anesthesia. The trade-off may be a higher incidence of early mechanical complications. Recent studies also show this technique to be a viable frontline approach in patients without any prior abdominal surgery with equivalent outcomes when compared to use of the open approach.
- Reasons for removal of PD catheter include nonresolving peritonitis, fungal peritonitis, ultrafiltration failure, and transplantation. Regular audit of outcomes of catheter insertions is recommended.

Author details

O. Obinwa^{1*}, J. McLoughlin^{1,2}, D. Kavanagh¹ and C. Wall²

*Address all correspondence to: obinnaobinwa@rcsi.ie

1 Department of Surgery, The Adelaide and Meath Hospital, Tallaght, Dublin, Ireland

2 Department of Nephrology, The Adelaide and Meath Hospital, Tallaght, Dublin, Ireland

References

- [1] Blagg CR. The early history of dialysis for chronic renal failure in the United States: a view from Seattle. *American Journal of Kidney Diseases: The Official Journal of the National Kidney Foundation*. 2007;49(3):482–96. DOI:10.1053/j.ajkd.2007.01.017
- [2] Bender FH. Avoiding harm in peritoneal dialysis patients. *Advances in Chronic Kidney Disease*. 2012;19(3):171–8. DOI:10.1053/j.ackd.2012.04.002
- [3] Crabtree JH. Extended peritoneal dialysis catheters for upper abdominal wall exit sites. *Peritoneal Dialysis International: Journal of the International Society for Peritoneal Dialysis*. 2004;24(3):292–4.

- [4] Hagen SM, Lafranca JA, IJzermans JN, et al. A systematic review and meta-analysis of the influence of peritoneal dialysis catheter type on complication rate and catheter survival. *Kidney International*. 2014;85(4):920–32. DOI:10.1038/ki.2013.365
- [5] Stylianou KG and Daphnis EK. Selecting the optimal peritoneal dialysis catheter. *Kidney International*. 2014;85(4):741–3. DOI:10.1038/ki.2013.424
- [6] Bayston R, Fisher LE and Weber K. An antimicrobial modified silicone peritoneal catheter with activity against both Gram-positive and Gram-negative bacteria. *Biomaterials*. 2009;30(18):3167–73. DOI:10.1016/j.biomaterials.2009.02.028
- [7] Shetty A and Oreopoulos D. Peritoneal dialysis: its indications and contraindications. *Dialysis & Transplantation*. 2000;29(2):71–7.
- [8] Juergensen E, Wuerth D, Finkelstein SH, et al. Hemodialysis and peritoneal dialysis: patients' assessment of their satisfaction with therapy and the impact of the therapy on their lives. *Clinical Journal of the American Society of Nephrology: CJASN*. 2006;1(6):1191–6. DOI:10.2215/CJN.01220406
- [9] Tokgoz B. Clinical advantages of peritoneal dialysis. *Peritoneal Dialysis International: Journal of the International Society for Peritoneal Dialysis*. 2009;29(Suppl. 2):S59–61.
- [10] Rubin J and Ball R. Continuous ambulatory peritoneal dialysis as treatment of severe congestive heart failure in the face of chronic renal failure. Report of eight cases. *Archives of Internal Medicine*. 1986;146(8):1533–5.
- [11] Konig PS, Lhotta K, Kronenberg F, et al. CAPD: a successful treatment in patients suffering from therapy-resistant congestive heart failure. *Advances in Peritoneal Dialysis. Conference on Peritoneal Dialysis*. 1991;7:97–101.
- [12] Mactier RA, Dobbie JW and Khanna R. Peritoneal dialysis in fulminant hepatic failure. *Peritoneal Dialysis International*. 1986;6(4):199–202.
- [13] Reuler JB and Parker RA. Peritoneal dialysis in the management of hypothermia. *JAMA*. 1978;240(21):2289–90.
- [14] Mayer AD, McMahon MJ, Corfield AP, et al. Controlled clinical trial of peritoneal lavage for the treatment of severe acute pancreatitis. *The New England Journal of Medicine*. 1985;312(7):399–404. DOI:10.1056/NEJM198502143120703
- [15] DOQI N. Clinical Practice Guidelines for Peritoneal Dialysis Adequacy: update 2000. *American Journal of Kidney Diseases: The Official Journal of the National Kidney Foundation*. 2001;37(1 Suppl. 1):S65–136.
- [16] Haggerty S, Roth S, Walsh D, et al. Guidelines for laparoscopic peritoneal dialysis access surgery. *Surgical Endoscopy*. 2014;28(11):3016–45. DOI:10.1007/s00464-014-3851-9
- [17] Tenckhoff H and Curtis FK. Experience with maintenance peritoneal dialysis in the home. *Transactions – American Society for Artificial Internal Organs*. 1970;16:90–5.

- [18] Medani S, Shantier M, Hussein W, et al. A comparative analysis of percutaneous and open surgical techniques for peritoneal catheter placement. *Peritoneal Dialysis International: Journal of the International Society for Peritoneal Dialysis*. 2012;32(6): 628–35. DOI:10.3747/pdi.2011.00187
- [19] Medani S, Hussein W, Shantier M, et al. Comparison of percutaneous and open surgical techniques for first-time peritoneal dialysis catheter placement in the unbreached peritoneum. *Peritoneal Dialysis International: Journal of the International Society for Peritoneal Dialysis*. 2015;35(5):576–85. DOI:10.3747/pdi.2013.00003
- [20] Hagen SM, Lafranca JA, Steyerberg EW, et al. Laparoscopic versus open peritoneal dialysis catheter insertion: a meta-analysis. *PloS One*. 2013;8(2):e56351. DOI:10.1371/journal.pone.0056351
- [21] Flanigan M and Gokal R. Peritoneal catheters and exit-site practices toward optimum peritoneal access: a review of current developments. *Peritoneal Dialysis International: Journal of the International Society for Peritoneal Dialysis*. 2005;25(2):132–9.
- [22] Figueiredo A, Goh BL, Jenkins S, et al. Clinical practice guidelines for peritoneal access. *Peritoneal Dialysis International: Journal of the International Society for Peritoneal Dialysis*. 2010;30(4):424–9. DOI:10.3747/pdi.2010.00087
- [23] Gulanikar AC, Jindal KK and Hirsch DJ. Is chronic peritoneal dialysis safe in patients with intra-abdominal prosthetic vascular grafts? *Nephrology, Dialysis, Transplantation: Official Publication of the European Dialysis and Transplant Association – European Renal Association*. 1991;6(3):215–7.
- [24] Peppelenbosch A, van Kuijk WH, Bouvy ND, et al. Peritoneal dialysis catheter placement technique and complications. *NDT Plus*. 2008;1(Suppl. 4):iv23–8. DOI:10.1093/ndtplus/sfn120
- [25] Menzies D and Ellis H. Intestinal obstruction from adhesions – how big is the problem? *Annals of the Royal College of Surgeons of England*. 1990;72(1):60–3.
- [26] Park YS, Min SI, Kim DK, et al. The outcomes of percutaneous versus open placement of peritoneal dialysis catheters. *World Journal of Surgery*. 2014;38(5):1058–64. DOI: 10.1007/s00268-013-2346-5
- [27] Moncrief JW, Popovich RP, Dasgupta M, et al. Reduction in peritonitis incidence in continuous ambulatory peritoneal dialysis with a new catheter and implantation technique. *Peritoneal Dialysis International: Journal of the International Society for Peritoneal Dialysis*. 1993;13(Suppl. 2):S329–31.
- [28] Danielsson A, Blohme L, Tranaeus A, et al. A prospective randomized study of the effect of a subcutaneously “buried” peritoneal dialysis catheter technique versus standard technique on the incidence of peritonitis and exit-site infection. *Peritoneal Dialysis International: Journal of the International Society for Peritoneal Dialysis*. 2002;22(2):211–9.

- [29] Ghaffari A. Urgent-start peritoneal dialysis: a quality improvement report. *American Journal of Kidney Diseases: The Official Journal of the National Kidney Foundation*. 2012;59(3):400–8. DOI:10.1053/j.ajkd.2011.08.034
- [30] Baek SK, Bae OS and Jang BK. Endoscopic management of delayed perforation of the rectum caused by a peritoneal dialysis catheter. *Surgical Laparoscopy, Endoscopy & Percutaneous Techniques*. 2011;21(1):e44–7. DOI:10.1097/SLE.0b013e3182093fb4
- [31] Finkle SN. Peritoneal dialysis catheter erosion into bowel: amyloidosis may be a risk factor. *Peritoneal Dialysis International: Journal of the International Society for Peritoneal Dialysis*. 2005;25(3):296–7.
- [32] Grzegorzewska A and Deja A. Conservative treatment of perforation of the transverse colon caused by a catheter for continuous peritoneal dialysis. A case report. *Polskie Archiwum Medycyny Wewnętrznej*. 1989;81(6):368–72.
- [33] Mital S, Fried LF and Piraino B. Bleeding complications associated with peritoneal dialysis catheter insertion. *Peritoneal Dialysis International: Journal of the International Society for Peritoneal Dialysis*. 2004;24(5):478–80.
- [34] Teixido J, Arias N, Tarrats L, et al. The microbial pattern of the catheter exit-site infection in peritoneal dialysis: a non-diphtheria *Corynebacteria* emergence? *Nefrologia: Publicacion Oficial de la Sociedad Espanola Nefrologia*. 2007;27(3):350–8.
- [35] Thodis E, Passadakis P, Ossareh S, et al. Peritoneal catheter exit-site infections: predisposing factors, prevention and treatment. *The International Journal of Artificial Organs*. 2003;26(8):698–714.
- [36] Savader SJ, Lund G, Scheel PJ, et al. Guide wire directed manipulation of malfunctioning peritoneal dialysis catheters: a critical analysis. *Journal of Vascular and Interventional Radiology*. 1997;8(6):957–63.
- [37] Leblanc M, Ouimet D and Pichette V. Dialysate leaks in peritoneal dialysis. *Seminars in Dialysis*. 2001;14(1):50–4.
- [38] Hassan K, Rubinchik I, Hassan F, et al. Unusual cause of late peritoneal dialysate leakage. *Peritoneal Dialysis International: Journal of the International Society for Peritoneal Dialysis*. 2012;32(3):360–1. DOI:10.3747/pdi.2011.00044
- [39] Li PK, Szeto CC, Piraino B, et al. Peritoneal dialysis-related infections recommendations: 2010 update. *Peritoneal Dialysis International: Journal of the International Society for Peritoneal Dialysis*. 2010;30(4):393–423. DOI:10.3747/pdi.2010.00049
- [40] Gadallah MF, Ramdeen G, Mignone J, et al. Role of preoperative antibiotic prophylaxis in preventing postoperative peritonitis in newly placed peritoneal dialysis catheters. *American Journal of Kidney Diseases: The Official Journal of the National Kidney Foundation*. 2000;36(5):1014–9. DOI:10.1053/ajkd.2000.19104

- [41] Jaar BG, Plantinga LC, Crews DC, et al. Timing, causes, predictors and prognosis of switching from peritoneal dialysis to hemodialysis: a prospective study. *BMC Nephrology*. 2009;10:3. DOI:10.1186/1471-2369-10-3
- [42] Davenport A. Peritonitis remains the major clinical complication of peritoneal dialysis: The London, UK, peritonitis audit 2002–2003. *Peritoneal Dialysis International: Journal of the International Society for Peritoneal Dialysis*. 2009;29(3):297–302.
- [43] Piraino B, Bailie GR, Bernardini J, et al. Peritoneal dialysis-related infections recommendations: 2005 update. *Peritoneal Dialysis International: Journal of the International Society for Peritoneal Dialysis*. 2005;25(2):107–31.
- [44] van Diepen AT, Tomlinson GA and Jassal SV. The association between exit site infection and subsequent peritonitis among peritoneal dialysis patients. *Clinical Journal of the American Society of Nephrology*. 2012;7(8):1266–71. DOI:10.2215/CJN.00980112
- [45] Margetts PJ and Churchill DN. Acquired ultrafiltration dysfunction in peritoneal dialysis patients. *Journal of the American Society of Nephrology*. 2002;13(11):2787–94.
- [46] Teitelbaum I. Ultrafiltration failure in peritoneal dialysis: a pathophysiologic approach. *Blood Purification*. 2015;39(1–3):70–3. DOI:10.1159/000368972
- [47] Scott PD, Bakran A, Pearson R, et al. Peritoneal dialysis access. Prospective randomized trial of 3 different peritoneal catheters—preliminary report. *Peritoneal Dialysis International: Journal of the International Society for Peritoneal Dialysis*. 1994;14(3):289–90.
- [48] Bay WH, Cerilli GJ, Perrine V, et al. Analysis of a new technique to stabilize the chronic peritoneal dialysis catheter. *American Journal of Kidney Diseases: The Official Journal of the National Kidney Foundation*. 1983;3(2):133–5.
- [49] Choi P, Nemati E, Banerjee A, et al. Peritoneal dialysis catheter removal for acute peritonitis: a retrospective analysis of factors associated with catheter removal and prolonged postoperative hospitalization. *American Journal of Kidney Diseases: The Official Journal of the National Kidney Foundation*. 2004;43(1):103–11.
- [50] Piraino B. Peritoneal dialysis catheter replacement: “save the patient and not the catheter”. *Seminars in Dialysis*. 2003;16(1):72–5.
- [51] Gokal R, Ash SR, Helfrich GB, et al. Peritoneal catheters and exit-site practices: toward optimum peritoneal access. *Peritoneal Dialysis International: Journal of the International Society for Peritoneal Dialysis*. 1993;13(1):29–39.

