

# We are IntechOpen, the world's leading publisher of Open Access books Built by scientists, for scientists

6,900

Open access books available

186,000

International authors and editors

200M

Downloads

Our authors are among the

154

Countries delivered to

TOP 1%

most cited scientists

12.2%

Contributors from top 500 universities



WEB OF SCIENCE™

Selection of our books indexed in the Book Citation Index  
in Web of Science™ Core Collection (BKCI)

Interested in publishing with us?  
Contact [book.department@intechopen.com](mailto:book.department@intechopen.com)

Numbers displayed above are based on latest data collected.  
For more information visit [www.intechopen.com](http://www.intechopen.com)



---

# **Regenerative Approaches in Wound Healing: New Alternatives for Older Tools**

---

Michele R Colonna, Lupo Flavia, Delia Gabriele and  
Stagno d'Alcontres Francesco

Additional information is available at the end of the chapter

<http://dx.doi.org/10.5772/64133>

---

## **Abstract**

Critical wounds are well known to develop in elderly people and in other conditions where inflammation, vascular, and nervous disease lead to chronic inefficiency in running up healing processes. Recent researches have been focusing on microenvironment, and specific technologies have contributed to design and produce new materials (the era of biomaterials and devices in wound healing).

At present, regenerative medicine and surgery have introduced a new approach, based on cells' transplantation producing specific cytokines and stimulating healing. This is the role played by fat transplantation combining both stromal and vascular cellular progenitor lines, monocyte products, platelet-rich plasma, and glues.

New tools, such as templates and materials (comprising micro- and nanoparticles), as well as technologies, such as cell seeding and gene therapy, revealed promising in this direction. The authors report their experimental evidences and clinical experiences with lipografting and peripheral blood mononuclear cells in critical wounds, focusing on how to treat monocyte/macrophage cell depletion as well as insufficient vascular supply.

**Keywords:** adipose-derived stem cells, angiogenesis, difficult wounds, lipografting, monocytes, vascular supply

---

## **1. Introduction**

Wound healing is a highly structured physiological process involving cells and signal molecules; it is known to run throughout inflammation, cell proliferation, angiogenesis,

collagen deposition, and re-epithelization [1]. In the very first steps, natural immunity [2] plays an important role through aggregation of inflammasomes. The next step goes through inflammatory cell types, and messages from the first to this step together with monocyte responsivity are able to determine whether inflammation will prolong to a sort of a steady, chronically established state, which freezes the whole process transforming it into a chronic inflammation [2–6].

Monocyte/macrophage sequestration together with their lack of switch to type 2 [3, 4, 6] impairs angiogenesis and cell activities resulting in a delayed re-epithelialization, reduced call for fibroblasts and diminishing collagen deposition, as well as a decreased cell proliferation.

The aim of this chapter is to report our experience on how to modify impaired wound healing, starting from our experimental studies and concluding with our recent clinical experiences.

## 2. Pathophysiology

Following our studies [2] and those by Mirza et al. [4, 5], we started to focus on the role of accumulation and insufficiency of macrophages in wound healing. Macrophage dysfunction has been shown to produce prolonged inflammatory responses in critical wounds, in diabetes through local secretion of proinflammatory cytokines, such as IL-1 $\beta$ , TNF- $\alpha$ , MMP-9, and IL-6, in particular, lack of switch to a second macrophage phenotype secreting proregenerative factors, such as IL-10, IGF-1, and TGF- $\beta$  [6].

The result is an important interruption of healing with persistence of inflammation, whether hyperglycemia through cascade of ROS is its cause or not.

This produces critical wounds. Obviously, single biological steps can be analyzed in experimental studies, whereas in clinical practice this single factor must often be added to other associated diseases, such as reduction of blood supply due to vascular obstruction. In the latter case, translation from experimental to clinical work must also take into account adding proangiogenetic factors even to provide a complete care.

Our clinical experience deals with persistence of inflammation through both monocyte and vascular insufficiency.

### 2.1. Our experimental studies on wound healing

In this section, we report our experimental evidences leading to the results about the above-mentioned inflammasome inhibition [2]. Plastic surgeons together with pharmacologists of the University of Messina have been working on wound healing for more than 15 years developing some models on rodents.

#### 2.1.1. *Animals*

For these experiments adult male mice have been chosen, caged alone, and maintained under a controlled environment (12-hour light cycles day/night and 23°C room temperature, food,

and water ad libitum) following Helsinki's declaration and European and Italian laws and Guidelines for Animal Laboratory Experiments.

Animals aging 8 weeks and weighing 20–25 g were used.

## **2.2. Model of incisional wound healing**

The animals (mice) underwent general anesthesia with sodium thiopental (80 mg/kg intraperitoneal injection) were scrubbed with iodine povidone on their back – their back skin shaved and rinsed with physiological serum. Two longitudinal parallel 4 cm incisions were performed and sutured with alternate stitches placed 1 cm from one another.

Sacrifices were conducted on Days 7 and 14, respectively, and wounds were divided into three segments of 80 mm large and 120 mm long. Caudal and cranial strips were used for molecular studies, whereas the central one was used for histology and immunohistochemistry.

## **2.3. Model of dorsal skin flap**

“Double H” flaps were described following Quirinia et al.'s classification: this model was modified and adopted [7, 8].

The animals (mice) underwent general anesthesia with sodium thiopental (80 mg/kg intraperitoneal injection) were scrubbed with iodine povidone on their back – their back skin shaved and rinsed with physiological serum. Double H flap consists of two opposite flaps: the former pedicled from the cranial side and the latter from the caudal one, both to be incised and elevated on the dorsal skin. The central horizontal wound together with the two distal parts of the flaps acts as critical ischemia-risk area. The flaps were sutured back with separate stitches in Nylon 4/0. The animals were divided into three groups and sacrifices were performed on Days 3, 6, and 12, respectively. As for incisional wounds, three flap segments were taken and processed the cranial and distal one for molecular essays, the central one for histology and immunocytochemistry

## **2.4. Model of burn injury**

Under the same anesthesia and dorsum preparation described above, the dorsum of mice was immersed in an 80°C bath for 10 seconds to produce a scald burn. Fluid resuscitation was achieved through a subcutaneous 1 mL saline injection, treated with different agents (last used EPO Z in comparison with EPO alpha), divided into three groups, and sacrificed on Days 3, 6, and 12, respectively. Burned skin has been divided into two flaps that have been, respectively, used for molecular essays and histology.

Molecular essays are consisted in cytoplasmic protein dosage (Bio-Rad Protein Assay (Bio-Rad Lab, Richmond, CA, USA), spectrophotometry, using albumin as a standard); Western blot for GFs and cell cycle molecules; histology measured the presence of inflammatory infiltrates, necrosis, and repair in standard hematoxylin (eosin, trichromic, and immunohistochemistry were used to visualize and quantify alpha-smooth positive cells such as a response to VEGF in both neoangiogenesis and neovasculogenesis).

Statistical analysis was conducted with parametric essays for repeated measures (ANOVA) and bonferroni test was used to evaluate intergroup positivity, with a  $p \leq 0.05$  considered as statistically significant.

Our experimental studies have pointed out some important features of antioxidant molecules in impaired wound healing (diabetic mice), as well as the role of some cytokine-related molecules and endogenous products belonging to natural immunity cascade [2] in normal and impaired wound healing [9–13].

### **2.5. Another important contribution to the study of neoangiogenesis and biomaterials prefabrication**

Our group also developed a collaboration with the group from Padriciano, International Center for Genetic Engineering and Biology, United Nations, to study a model of prefabricated flap in the groin of adult rats creating an artero-venous loop that was included into a dermal regenerative template; this new regeneration chamber was then injected with different viral vectors (AAV 156) encoding for the production of VEGF. Results were remarkable, demonstrating enhancement of neoangiogenesis and neovasculogenesis and the utility of this novel model of regeneration chamber that could act as a bioreactor and stimulate healing and even repair poor vascularized tissues [14, 15].

## **3. Clinical experiences**

Chronic wounds are produced either by an interruption in healing processes, as an effect of lack of positive (vascular supply and neurotrophism) or of an excess of inhibitory factors (metallo proteinases in ECM, some cytokines), or by a lack of switch in inflammatory cell phenotypes, such as in diabetes.

As a final effect, wound bed does not progress beyond detersion, typically presenting itself as necrosis or debris. They are especially present in lower limbs, often as a result of complex mix of the above-mentioned factors.

Vascular and diabetic ulcers are the most common chronic wounds affecting nearly 2–5% of the general population and have received an important impact in terms of morbidity, absence from work, and social costs.

Traditional wound dressings do not restore vascular supply, which is a *sine qua non* for restarting healing.

An important role is played by vascular surgery and endovascular techniques, which act restoring the lost vascular supply or producing bypasses to revascularize the area.

At present, some novel suggestions come from regenerative surgery.

### 3.1. Lipograft in chronic wounds

The target is endothelial insufficiency, as documented in diabetes and vascular obstructive diseases.

It consists of poor endothelial progenitor cell mobilization and homing, with altered levels of the chemokine stromal-derived factor-1 (SDF-1) at the wound site [2, 6, 16].

The use of tissue engineering techniques such as stem-cell therapy and gene therapy to improve wound healing has proved a promising strategy [14, 15].

A well-established clinical experience with lipografting has been obtained in the early years of this century, especially in scar treatment after important fibrotic status, such as in postburn scars and in postradiation mastectomy scars [17, 18].

Since 2001, Zuk et al. documented that lipoaspirate from adipose tissue represents a source of adipose tissue-derived stem cells, which are adult mesenchymal stem cells [19].

Starting from the first regenerative approach with lipografting on fibrotic tissues, its role has been expanded to chronic wounds, applying as a rationale, and has the potential to induce angiogenesis and regeneration. The potential of ADSCs to differentiate into adipocytes, osteoblasts, chondrocytes, cardiomyocytes, and endothelial cells, in vitro and in vivo, was shown by several authors. In particular, ADSCs are able to express endothelial markers when cultured in the presence of VEGF.

The stimulatory effect of ADSC on cutaneous wound healing may be partially mediated by paracrine effects of ADSCs on other skin cells [20–27].

Application of ADSCs or ADSC-derived molecules could be an innovative therapeutic approach in the treatment of chronic wounds and other conditions; it has been proposed in association with platelet-rich plasma [28] or under particular conditions [29].

#### 3.1.1. Procedure

The surgical procedure was performed under local anesthesia together with midazolam medication (see below). The periumbilical area and the hip were the preferred donor site because of the good quantity and quality of dermal fat graft.

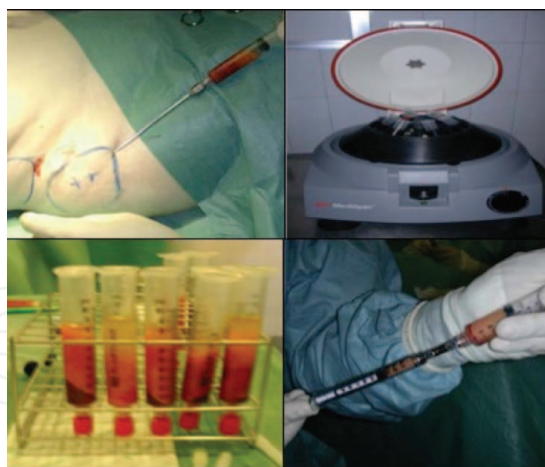
With the patient in supine position, the donor area was infiltrated with 250 cc of saline solution (NaCl 0.9%), 0.5 cc adrenalin 1/1000, 10 cc of lidocain 2%, and 10 cc ropivacain 7.5%; the incision to introduce the cannula was made with a no. 11 scalpel (**Figure 1**).

Adipose tissue was harvested through the same incision by a blunt 2 mm cannula connected to a Luer-Lock syringe of 10 cc, a small amount of aspirate (about 10 cc) was sufficient.

The full syringe was placed into a sterile cup and washed with NaCl 0.9% to remove the anesthetic solution.

The authors used Coleman's technique and centrifuged the fat (3000 rpm for 3 minutes) to separate cellular blood components with infiltration solution, adipocytes with vascular stromal tissue and oil derived from the breakdown of fat cells.





**Figure 1.** Lipoaspirate procedure: ADSC and VASF harvesting, centrifuge and its products on the aspirate, and harvesting of the lipograft to be implanted.

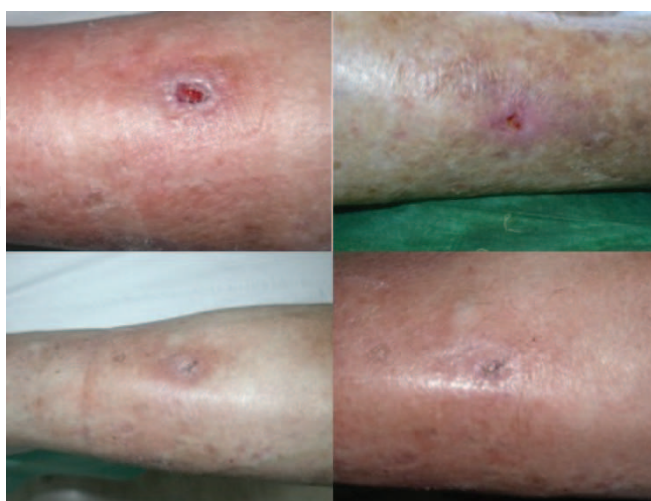
The adipose-stromal fraction was transferred from a 10 cc syringe to a 1 mL Luer-Lock syringe to allow a precise control of the amount of injected fat (**Figure 1**).

The adipose tissue fraction was then implanted with gentle care; small “pearls” of adipose tissue were placed at the dermal-hypodermal junction in the ulcer’s edges and into the wound bed. Many radiating passages were made through the same incision, to place fat in different directions.

The access incisions in the donor areas were sutured with Nylon 5/0.

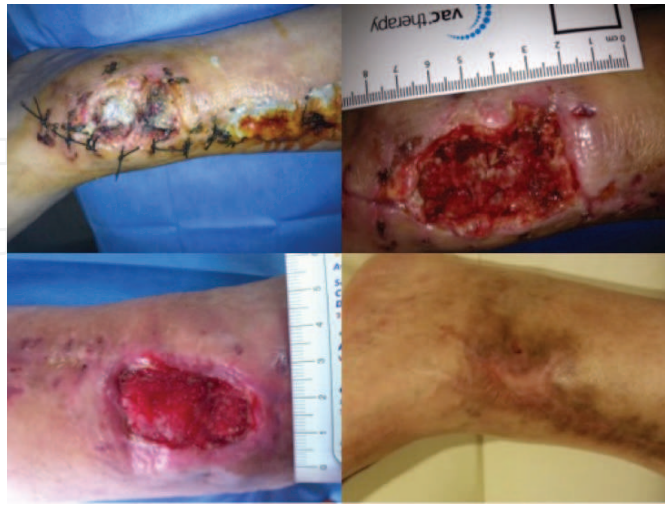The treated area after surgical procedure was covered with non-adherent gauze, whereas an elastic adhesive bandage was applied to the fat donor site to prevent hematomas and seromas.

A second grafting session was performed, if needed, 3 months later.



**Figure 2.** Chronic ulcers: before and after treatment with ADSCs.

Four patients were treated, wound closure occurred in approximately 17 days (**Figures 2 and 3**).



**Figure 3.** Lipografting in chronic posttraumatic wound in a diabetic patient. Two sessions were needed to obtain a complete closure.

### 3.2. Mononuclear cells in chronic wounds

Cell therapy is an innovative and promising approach for regeneration of damaged tissues. In particular, new scientific evidence shows that the total mononuclears from peripheral blood are cells with high angiogenic and vasculogenic capacity and, in general, in tissue regeneration processes.

Patients with CLI, who suffer from rest pain, nonhealing ischemic ulcers, or necrosis (Fontaine 3–4), rarely respond to standard therapy as drug therapy (e.g., prostaglandin and anticoagulant, etc.) and surgical revascularization.

The autologous transplantation of peripheral blood mononuclear cells (PBMNCs) can produce tissue regeneration and improve physiological healing process through their paracrine action, consisting in production of cytokines, especially VEGF and bFGF.

The monocells have three principal roles:

- progenitors of multipotent cells,
- angiogenesis and vasculogenesis, and
- anti-inflammatory.

The PBMNCs isolated from peripheral blood have the same differentiating and regenerating capacities as the bone marrow mononuclear cells (BMMNCs), but their isolation is simpler and minimally invasive.



Monocytes and macrophages are capable of producing a large variety of growth factors, metalloproteinases, chemokines, and vasoactive substances such as nitric oxide; all can facilitate angiogenesis and arteriogenesis [30–34].

Angiogenesis is characterized by capillary sprouting, endothelial cell migration, proliferation, and luminogenesis to generate new capillaries [14, 32–34].

Arteriogenesis is a positive remodeling of preexisting collateral channels in the limb, as the product of endothelial factors, as well as of infiltrating macrophages [15, 32–34].

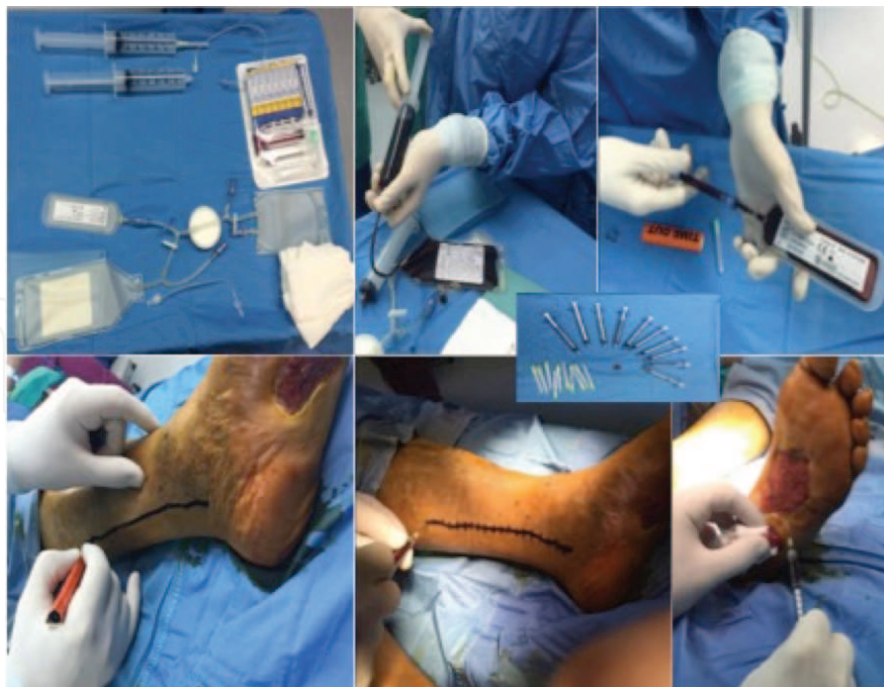During chronic inflammation, macrophages/monocells are polarized in the antimicrobial form (M1), or in the regenerative form (M2). The implantation of concentrated PBMNCs in this condition can address M1 to M2 promoting the regenerative form.

The autologous transplantation of PBMNCs can be considered a valid and safe treatment option for patients with critical wounds [30–34].

### 3.2.1. Procedure

In the theater, under sedation and local anesthesia of the patient, 120 mL of peripheral venous blood was drawn and added to 12 mL of ACD-A (anticoagulant by apheresis). This was then processed by the WB Pall Celeris system to obtain 12 mL of concentrated PBMNCs (**Figure 4**).

The concentrated PBMNCs were transferred to a 1 mL Luer-Lock syringe to allow a precise control during injection (**Figure 4**).

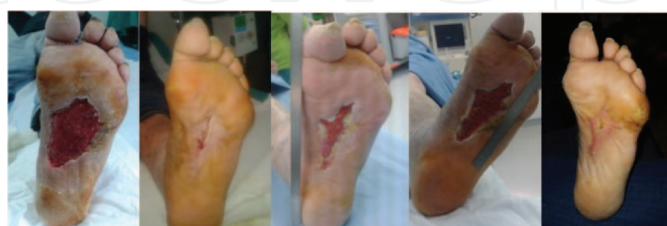

**Figure 4.** Mononuclear cells preparation procedure: 120 mL of peripheral venous are processed by the WB Pall Celeris system to obtain 12 mL of concentrated PBMNCs, and the posterior tibial axis is traced and the injection performed.

After an appropriate surgical cleansing of the wound bed, the concentrate was implanted into the perilesional area in a single-stage procedure with multiple local subcutaneous perilesional and intralesional injections and intramuscular injections.

The suspension was placed along the relevant damaged vascular axis too, at intervals of 1–2 cm and at a mean depth of 1.5–2 cm, using a 21G needle (**Figure 4**).

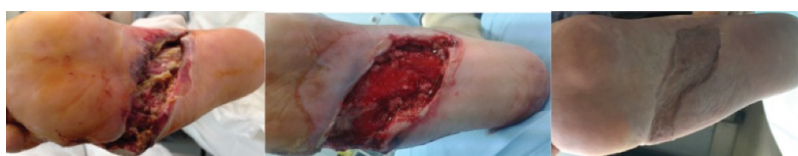After the A-PBMNCs implant, the wound was always covered with hyaluronic acid monolayer. This treatment was repeated three times, once a month for three months (**Figure 5**).



**Figure 5.** PBMNC injections were repeated three times, once a month for three months, and a complete healing was registered.

One month after the first treatment, the size of the ulcers of all patients were significantly reduced. At the end of the third session, ulcers seemed totally healed, the skin overlying the wound appeared perfectly normal, and the skin complexion was ruddy (**Figure 5**).

Because of their early capability to stimulate vascular ingrowth, monocell implant can be used in one step only to prepare wound bed to receive an autologous skin graft (**Figure 6**).



**Figure 6.** Monocell implants can be used in one step only to prepare wound bed to receive an autologous skin graft. In this case, a severe necrosis of the midplantar skin was excised and PBMNCs injected. A well-vascularized granulation tissue was appreciated in 12 days, allowing repair with a split thickness skin graft in this nonweight bearing area.

## Author details

Michele R Colonna\*, Lupo Flavia, Delia Gabriele and Stagno d'Alcontres Francesco

\*Address all correspondence to: [mrcolonna1@gmail.com](mailto:mrcolonna1@gmail.com)

Department of Human Pathology and the Child's and Adolescent's Diseases, University of Messina, Messina, Italy

## References

- [1] Falanga V. Wound healing and its impairment in the diabetic foot. *Lancet*. 2005;366(9498):1736–43.
- [2] Bitto A, Altavilla D, Pizzino G, Irrera N, Pallio G, Colonna MR, Squadrito F. Inhibition of inflammasome activation improves the impaired pattern of healing in genetically diabetic mice. *Br J Pharmacol*. 2014;171(9):2300–7. doi: 10.1111/bph.12557.
- [3] Salazar JJ, Ennis WJ, Koh TJ. Diabetes medications: impact on inflammation and wound healing. *J Diabetes Complications*. 2015. pii:S1056-8727(15)00506-1. doi: 10.1016/j.jdiacomp.2015.12.017.
- [4] Mirza RE, Fang MM, Weinheimer-Haus EM, Ennis WJ, Koh TJ. Sustained inflammasome activity in macrophages impairs wound healing in type 2 diabetic humans and mice. *Diabetes*. 2014;63(3):1103–14. doi: 10.2337/db13-0927.
- [5] Weinheimer-Haus EM, Mirza RE, Koh TJ. Nod-like receptor protein-3 inflammasome plays an important role during early stages of wound healing. *PLoS One*. 2015;10(3):e0119106. doi: 0.1371/journal.pone.0119106.
- [6] Koh TJ, Novak ML, Mirza RE. Assessing macrophage phenotype during tissue repair. *Methods Mol Biol*. 2013;1037:507–18. doi: 10.1007/978-1-62703-505-7\_30.
- [7] Quirinia A, Jensen FT, Viidik A. Ischemia in wound healing. I: Design of a flap model – changes in blood flow. *Scand J Plast Reconstr Surg Hand Surg*. 1992;26:21–8.
- [8] Quirinia A, Viidik A. Ischemia in wound healing. II: Design of a flap model – biochemical properties. *Scand J Plast Reconstr Surg Hand Surg*. 1992;26:133–9.
- [9] Irrera N, Bitto A, Pizzino G, Vaccaro M, Squadrito F, Galeano M, Stagno d'Alcontres F, Stagno d'Alcontres F, Buemi M, Minutoli L, Colonna MR, Altavilla D. Epoetin alpha and epoetin zeta: a comparative study on stimulation of angiogenesis and wound repair in an experimental model of burn injury. *Biomed Res Int*. 2015;2015:968927. doi: 10.1155/2015/968927.
- [10] Altavilla D, Galeano M, Bitto A, Minutoli L, Squadrito G, Seminara P, Venuti FS, Torre V, Calò M, Colonna M, Lo Cascio P, Giugliano G, Scuderi N, Mioni C, Leone S, Squadrito F. Lipid peroxidation inhibition by raxofelast improves angiogenesis and wound healing in experimental burn wounds. *Shock*. 2005;24(1):85–91.
- [11] Galeano M, Deodato B, Altavilla D, Squadrito G, Seminara P, Marini H, Stagno d'Alcontres F, Colonna M, Calò M, Lo Cascio P, Torre V, Giacca M, Venuti FS, Squadrito F. Effect of recombinant adeno-associated virus vector-mediated vascular endothelial growth factor gene transfer on wound healing after burn injury. *Crit Care Med*. 2003;31(4):1017–25.
- [12] Galeano M, Torre V, Deodato B, Campo GM, Colonna M, Sturiale A, Squadrito F, Cavallari V, Cucinotta D, Buemi M, Altavilla D. Raxofelast, a hydrophilic vitamin E-

like antioxidant, stimulates wound healing in genetically diabetic mice. *Surgery*. 2001;129(4):467–77.

- [13] Altavilla D, Saitta A, Cucinotta D, Galeano M, Deodato B, Colonna M, Torre V, Russo G, Sardella A, Urna G, Campo GM, Cavallari V, Squadrito G, Squadrito F. Inhibition of lipid peroxidation restores impaired vascular endothelial growth factor expression and stimulates wound healing and angiogenesis in the genetically diabetic mouse. *Diabetes*. 2001;50(3):667–74.
- [14] Manasseri B, Cuccia G, Moimas S, D'Alcontres FS, Polito F, Bitto A, Altavilla D, Squadrito F, Geuna S, Pattarini L, Zentilin L, Collesi C, Puligadda U, Giacca M, Colonna MR. Microsurgical arterovenous loops and biological templates: a novel in vivo chamber for tissue engineering. *Microsurgery*. 2007;27(7):623–9.
- [15] Moimas S, Manasseri B, Cuccia G, Stagno d'Alcontres F, Geuna S, Pattarini L, Zentilin L, Giacca M, Colonna MR. AAV vector encoding human VEGF165-transduced pectineus muscular flaps increase the formation of new tissue through induction of angiogenesis in an in vivo chamber for tissue engineering: a technique to enhance tissue and vessels in micro surgically engineered tissue. *J Tissue Eng*. 2015;6. doi: 10.1177/2041731415611717. eCollection 2015 Jan–Dec.
- [16] Di Rocco G, Gentile A, Antonini A, Ceradini F, Wu JC, Capogrossi MC, Toietta G. Enhanced healing of diabetic wounds by topical administration of adipose tissue-derived stromal cells overexpressing stromal-derived factor-1: biodistribution and engraftment analysis by bioluminescent imaging. *Stem Cells Int*. 2010;2011:304562.
- [17] Caviggioli F, Klinger FM, Vinci V, Cornegliani G, Klinger M. Treatment of Chronic Posttraumatic Leg Injury Using Autologous Fat Graft, *Case Reports in Medicine*, Volume 2012, Hindawi Publishing Corporation, Article ID 648683, 4 pp.
- [18] Klinger M, Caviggioli F, Vinci V, Salval A, Villani F. Treatment of chronic posttraumatic ulcers using autologous fat graft. *Plast Reconstr Surg*. 2010;126(3):154e–5e.
- [19] Zuk PA, Zhu M, Mizuno H, Huang J, Futrell JW, Katz AJ, Benhaim P, Lorenz HP, Hedrick MH. Multilineage cells from human adipose tissue: implications for cell-based therapies. *Tissue Eng*. 2001;7(2):211–28.
- [20] Miranville A, Heeschen C, Sengenès C, Curat CA, Busse R, Bouloumié A. Improvement of postnatal neovascularization by human adipose tissue-derived stem cells. *Circulation*. 2004;110(3):349–55.
- [21] Coleman SR, Mazzola R. Fat injection from filling to regeneration. *QMP Missouri*. 2009.
- [22] Coleman SR. Structural fat graft: more than permanent filler. *Plastic Reconstr Surg*. 2006;118(3 Suppl):108S–20S.
- [23] Seung HL, Sang YJ, Jin SS, Kyle KS, Kwang HC. Paracrine effects of adipose-derived stem cells on keratinocytes and dermal fibroblasts. *Ann Dermatol*. 2012;24(2):136–43.

- [24] Akita S, Yoshimoto H, Ohtsuru A, Hirano A, Yamashita S. Autologous adipose-derived regenerative cells are effective for chronic intractable radiation injuries. *Radiat Prot Dosimetry*. 2012;151(4):656–60.
- [25] Akita S, Yoshimoto H, Akino K, Ohtsuru A, Hayashida K, Hirano A, Suzuki K, Yamashita S. Early experiences with stem cells in treating chronic wounds. *Clin Plast Surg*. 2012;39(3):281–92.
- [26] Lee SH, Jin SY, Song JS, Seo KK, Cho KH. Paracrine effects of adipose-derived stem cells on keratinocytes and dermal fibroblasts. *Ann Dermatol*. 2012;24(2):136–43.
- [27] Tabit CJ, Slack GC, Fan K, Wan DC, Bradley JP. Fat grafting versus adipose-derived stem cell therapy: distinguishing indications, techniques, and outcomes. *Aesthetic Plast Surg*. 2012;36(3):704–13.
- [28] Cervelli V, Gentile P, Grimaldi M. Regenerative surgery: use of fat grafting combined with platelet-rich plasma for chronic lower-extremity ulcers. *Aesthetic Plast Surg*. 2009 May;33(3):340–5.
- [29] Waniczek D, Mikusek W, Kamiński T, Wesecki M, Lorenc Z, Cieślik-Bielecka A. The “biological chamber” method—use of autologous platelet-rich plasma (PRP) in the treatment of poorly healing lower-leg ulcers of venous origin. *Pol Przegl Chir*. 2015;87(6):283–9. doi: 10.1515/pjs-2015-0055.
- [30] Nuschke A. Activity of mesenchymal stem cells in therapies for chronic skin wound healing. *Organogenesis*. 2014;10(1):29–37. Published online 2013 December.
- [31] Michael BD, Amil AJ, Ambalangodage CJ. Current wound healing procedures and potential care. *Mater Sci Eng C Mater Biol Appl*. 2015;48:651–62.
- [32] Strong AL, Bowles AC, MacCrimmon CP, Frazier TP, Lee SJ, Xiyang Wu, Katz AJ, Gawronska-Kozak B, Bunnell BA, Gimble JM. *Stem Cells Transl Med*. 2015;4(6):632–42.
- [33] Spalto G, Straino S, Gambini G, Bassetti B, Persico L, Zoli S, Zanobini M, Capogrossi MC, Spirito R, Quarti C, Pompilio G. Characterization of the pall celeris system as a point-of-care device for therapeutic angiogenesis. *Cytotherapy*. 2015;17:1302–13.
- [34] De Angelis B, Gentile P, Orlandi F, Bocchini I, Di Pasquali C, Agovino A, Gizzi C, Patrizi F, Scioli MG, Orlandi A, Cervelli V. Limb rescue: a new autologous-peripheral blood mononuclear cells technology in critical limb ischemia and chronic ulcers. *Tissue Engineering: Part C*. 2015;21.