

We are IntechOpen, the world's leading publisher of Open Access books Built by scientists, for scientists

6,900

Open access books available

186,000

International authors and editors

200M

Downloads

Our authors are among the

154

Countries delivered to

TOP 1%

most cited scientists

12.2%

Contributors from top 500 universities



WEB OF SCIENCE™

Selection of our books indexed in the Book Citation Index
in Web of Science™ Core Collection (BKCI)

Interested in publishing with us?
Contact book.department@intechopen.com

Numbers displayed above are based on latest data collected.
For more information visit www.intechopen.com



Pediatric Multiple Sclerosis

Ozgul Ekmekci

Additional information is available at the end of the chapter

<http://dx.doi.org/10.5772/63919>

Abstract

Multiple sclerosis (MS) is an autoimmune inflammatory demyelinating disorder of the central nervous system. Although pediatric and adult-onset MS have similar neurologic symptoms, there are some differences from adults in radiologic findings, cognitive features, clinical course, and diagnostic criteria of pediatric MS. Diagnostic criteria and radiologic features of pediatric MS have been defined in recent years. There are no large, randomized, controlled therapeutic trials in pediatric MS. In this chapter, clinical characteristics, diagnostic criteria, laboratory findings, differential diagnosis, and treatment of pediatric MS are summarized.

Keywords: multiple sclerosis, pediatric multiple sclerosis, childhood multiple sclerosis, demyelinating disorders, demyelination

1. Introduction

Multiple sclerosis (MS) is an autoimmune chronic inflammatory disease of the central nervous system; it is characterized by demyelination and axonal loss. MS primarily affects young adults. Recently, it has been increasingly recognized in children and adolescents. Approximately 2–5% of all MS patients have onset before age 18 [1,2]. Onset before 10 years of age occurs in less than 1% of all patients. There are some differences, including clinical presentation, magnetic resonance imaging (MRI) findings, and neuroimmunologic features, between pediatric and adult MS patients. The first attack can be acute disseminated encephalomyelitis, particularly in young children. Relapses are more frequent in pediatric MS patients than in adults, though improvement is better. Cognitive impairment including linguistic dysfunction and reduction in IQ scores also differs from adults. T2 lesion burden is higher in pediatric patients

in MRI as compared to adult MS patients. These differences are more marked in prepuberal children [3]. The still developing central nervous and immune systems may be responsible for these differences. However, studies on pathogenesis and pathology of pediatric MS are limited.

2. Epidemiology

The incidence of pediatric MS is unknown, but its estimated prevalence has been reported to be 1.35–2.5 per 100,000 children [4]. The gender ratio varies with the age of onset: in patients older than 10 years, the female-to-male ratio is similar to adults; there is female dominance. In children younger than 10 years old, the female-to-male ratio decreases. This difference may be due to hormonal influence or gender-specific genetic influence on immunological reactivity [5].

3. Etiology and risk factors

Pediatric MS has a complex etiology related to both genetic and environmental factors. Vitamin D deficiency has been implicated as a risk factor for MS in children, as it is in adults. Mowry et al. have demonstrated an association between relapse rate and vitamin D level in pediatric MS patients [6]. Smoking has been considered as a risk factor in adults, whereas passive smoke exposure has been recognized as a risk factor in children [7]. One of the most studied environmental risk factors is viral exposure and studies have found that viral exposure in childhood may predispose some individuals to the development of MS. Epstein-Barr seropositivity and serum anti-EBV antibody titers tend to be higher in MS patients than they are in normal individuals. The relationship between the Epstein-Barr virus and MS has also been shown in pediatric MS [8]. Another risk factor is obesity. Childhood and adolescent obesity has been suggested as a risk factor for the development of MS in both adults and children [9]. Genetic susceptibility is also a risk factor for MS. HLA-DRB1 locus has been associated with multiple sclerosis in children. Twin studies have demonstrated a concordance rate of 27% in monozygotic twins. The incidence for first-degree relatives of patients with MS is 2–5%, whereas the incidence for the general population is under 0.1% [10].

4. Pathogenesis

Multiple sclerosis is a neuroimmunologic disorder characterized pathologically by inflammation, demyelination, and axonal loss. Neuropathological findings and animal models such as experimental allergic encephalomyelitis support the immunopathogenesis in multiple sclerosis. HLA Class II genes which are associated with MS risk are also related to the immune system.

The first step in the immunopathogenesis of MS is peripheral activation of CD4⁺ T lymphocytes in response to an antigen. This antigen is unknown. It has been suggested that

molecular mimicry between this antigen and central nervous system antigens causes cross reactivity. Subsequently, activated T lymphocytes migrate through the blood-brain barrier into the central nervous system [10, 11]. Lymphocyte migration represents an important step in MS pathogenesis. This multistep process includes adhesion, chemoattraction, and active infiltration into the central nervous system. Adhesion molecules, chemokines, and cytokines play an important role in these steps [10]. $\alpha 4 \beta 1$ integrin (VLA-4, very late activating antigen) is an adhesion molecule which is expressed on the lymphocyte surface and binds to the vascular cell adhesion molecule-1 (VCAM-1) located on the endothelium. As a result of this interaction, lymphocytes adhere to the endothelium and transmigrate across the endothelial cell layer into the central nervous system [12]. Chemokines regulate migration of immune cells into the brain; they also manipulate the lymphocyte transendothelial migration and locomotion within the tissue along chemoattractant gradients. Reactivation of infiltrating immune cells within the central nervous system leads to perivascular inflammation and injury. This injury results in the release of additional central nervous system antigens such as myelin proteins and leads to immune responses to these self-antigens (antigen spreading/epitope spreading). T cells reactive to myelin proteins including myelin basic protein (MBP), myelin oligodendrocyte glycoprotein (MOG), and myelin proteolipid protein (PLP) are involved in the central nervous system inflammatory response of MS patients [10]. Myelin-reactive T cells have differences in MS patients as compared with healthy controls. In MS patients myelin-reactive T cells differ by having memory phenotype. Memory T cells play an important role in MS pathogenesis. Other immune cells including proinflammatory and anti-inflammatory/regulatory CD4⁺ T cells (helper T lymphocytes), CD8⁺ T cells (cytotoxic T lymphocytes), myeloid cell subsets, B cells, and natural killer cells contribute to the pathogenesis of MS in adults. After activation by antigen-presenting cells such as dendritic cells, naïve T cells differentiate into one of the several subsets with different effector functions. Th1 lymphocytes secrete proinflammatory cytokines such as interferon gamma, while Th2 lymphocytes produce anti-inflammatory cytokines such as interleukin 4, interleukin 10. The imbalance between proinflammatory and anti-inflammatory cytokines has been invoked in MS pathogenesis. Proinflammatory cytokines play crucial roles in MS pathogenesis including peripheral immune activation, enhancement of trafficking of activated immune cells into the CNS, and direct damage to oligodendrocytes, myelin, and axons [10, 12]. Th17 lymphocytes are also a subgroup of CD4⁺ T cells that produce the proinflammatory cytokines interleukin 17A and interleukin 17F. Th17 lymphocytes are developmentally distinct from Th1 and Th2 lineages. Interleukin 23 produced by macrophages and dendritic cells contributes to development of Th17. High Th17 to Th1 ratios are associated with T cell infiltration and inflammation in the brain parenchyma [13]. The presence of interleukin 17 in MS lesions and increased interleukin 17 expression in both blood and CSF of MS patients have been demonstrated [14, 15]. Other subgroups of T cells also have been implicated in the immunopathogenesis of MS. Regulatory T (Treg) cells control potentially pathogenic autoreactive T cells. Studies demonstrated that regulatory T cell functions are altered in MS. In a study, similar T cell responses to myelin basic protein and myelin oligodendrocyte glycoprotein epitopes have been found in both adult and pediatric MS patients [16]. Vargas Lowy demonstrated increased CD4⁺ T

cell proliferation to myelin peptides in children with MS and also found an increased proportion of dividing CD4⁺ T cell to myelin peptides with a memory phenotype which produced interleukin 17 [10].

Humoral immunity has also been implicated in MS pathogenesis. B lymphocytes, plasma cells, immunoglobulins, and complement deposition have been shown in MS lesions. Anti-myelin oligodendrocyte glycoprotein antibodies (anti-MOG) have been reported in pediatric cases with inflammatory demyelinating diseases, predominantly in children with ADEM-like first episodes and in pediatric MS patients younger than 10 years of age at disease onset. Anti-MOG antibodies have also been observed in pediatric patients with recurrent optic neuritis and seronegative NMO [10, 17]. The presence of anti-MOG antibodies has been reported in a subgroup of adults with seronegative NMO but only rarely in adults with MS [18]. Moreover, antibody-independent functions of B lymphocytes such as cytokine production play a role in MS immunopathogenesis.

Neurodegeneration and axonal damage are other processes in the pathogenesis of MS. Mechanisms of axonal damage in multiple sclerosis include a specific immunologic attack on axons; the presence of soluble mediators such as proteases, cytokines, and free radicals released during the inflammatory process and lack of neurotrophic factors provided to the axon by oligodendrocytes as a result of chronic demyelination [10, 19].

5. Pathology

The cellular content of MS lesions includes primarily T lymphocytes (CD4⁺ and CD8⁺) and macrophages. Lucchinetti et al. have described four distinct pathological patterns of demyelination in autopsy and biopsy samples from adult MS patients. Patterns I and II showed T cell/macrophage inflammation and there was also T cell plus antibody-mediated autoimmune damage in pattern II. Patterns III and IV were suggestive of a primary oligodendrocyte dystrophy. Oligodendrocyte apoptosis or death and lesser macrophage-T cell inflammation were observed in patterns III and IV [20]. In another study, Trapp et al. demonstrated axonal damage in normal appearing white matter [21]. Additionally, subpial cortical, intracortical, and leukocortical lesions were found in adult-onset multiple sclerosis patients' biopsy specimens. Immune cells were also identified within the pia-arachnoid in adult-onset multiple sclerosis and ectopic B-cell follicles with germinal centers were detected in the meninges of patients with secondary progressive multiple sclerosis. All these pathological findings were identified in adult patients [10, 22, 23]. Neuropathological studies are limited in pediatric multiple sclerosis [10]. Tumefactive demyelinating lesions have been investigated in pediatric patients with MS [24]. The pathological characteristics of tumefactive demyelinating lesions include relative axonal preservation, perivascular and parenchymal lymphocyte and macrophage inflammation [25].

6. Diagnostic criteria

In 2007, the International Pediatric Multiple Sclerosis Study Group (IPMSSG) proposed a consensus on definitions for pediatric acquired demyelinating disorders of the central nervous system and pediatric MS. Pediatric MS referred to “children” (under the age of 10) and “adolescents” (aged 10 and above but younger than 18) in this definition. In 2012, the study group revised the criteria in consideration of studies that had applied 2007 pediatric MS criteria and the 2010 revised McDonald’s criteria for adults [26–28].

According to the 2012 revised criteria, pediatric MS can be satisfied by any of the following:

- Two or more non-encephalopathic (e.g. not ADEM-like) clinical central nervous system (CNS) events with a presumed inflammatory cause, separated by more than 30 days and involving more than one area of the CNS.
- One non-encephalopathic episode typical of MS which is associated with MRI findings consistent with the 2010 revised McDonald criteria for DIS (dissemination in space) and in which a follow-up MRI shows at least one new enhancing or non-enhancing lesion consistent with DIT (dissemination in time) MS criteria.
- One ADEM attack followed by a non-encephalopathic clinical event, three or more months after the onset of symptoms, which is associated with new MRI lesions that fulfill the 2010 revised McDonald DIS criteria.
- A first single, acute event that does not meet ADEM criteria and whose MRI findings are consistent with the 2010 revised McDonald criteria for DIS and DIT (applies only to children ≥ 12 years old).

7. Clinical features

Most of the patients with pediatric MS have a relapsing remitting course. A primary progressive course is extremely rare in pediatric MS. The definition of an attack (relapse/exacerbation) in pediatric MS is similar to that in adults. An attack is defined as “the appearance of new symptoms and neurologic signs, or worsening of old symptoms and signs due to an acute inflammatory demyelinating event in the CNS, with duration of at least 24 hours in the absence of fever or infection,” and the onset of the attack should be separated from the onset of a previous attack by at least 30 days [27].

Visual, sensory, motor, brainstem, cerebellar symptoms, sphincter, and cognitive dysfunctions may also occur in pediatric MS, as they do in adults. Polysymptomatic and ADEM-like onset are more common in prepubertal patients, particularly in very young children. Visual and sensory symptoms may go unnoticed in very young children. In adolescents, the presentation of monosymptomatic and sensorimotor symptoms is frequent, and optic neuritis is the most common initial presentation. The interval between the initial demyelinating event and the second attack varies, and this interval may be longer in very young children. Relapses are more

frequent and may be more severe in pediatric patients but recovery is often better than it is in adults. The accumulation of disability takes a long time in pediatric MS; however, over the long term, patients can become disabled at a younger age. The transition to secondary progressive MS occurs at a younger age in pediatric-onset MS than in adult-onset MS. The risk of transition to secondary progressive MS in pediatric patients is associated with a higher frequency of relapses and shorter intervals between attacks in the first few years of the disease [2, 29–31].

Cognitive disturbance is an important feature in pediatric MS. Cognitive impairment can occur even in the first few years of the disease and does not correlate with physical disability, number of relapses, and disease duration. The onset of multiple sclerosis in very young children increases the risk of cognitive impairment [3]. In adult MS patients, the most commonly affected cognitive functions include processing speed, visual-spatial function, memory, and executive functions. The most commonly affected cognitive areas in pediatric MS are attention span, processing speed, and visual-motor skills as adults. Receptive language, verbal fluency, and intelligence also are affected in pediatric MS, and they are affected differently than they are in adult MS. Linguistic involvement (verbal fluency, naming, and comprehension) is an important neuropsychological difference between pediatric and adult-onset MS [32, 33]. Pediatric MS patients are also at risk for a lower IQ [3]. Differences in cognitive dysfunctions between pediatric MS and adult MS may be due to the effect of inflammatory demyelination on the developing central nervous system and neuronal networks. All patients with pediatric MS should be checked for cognitive dysfunction because it occurs in the early stages of the disease and is unrelated to physical disability [29, 30, 33].

Psychiatric disorders such as depression or anxiety are common in pediatric MS, as they are in adults. Fatigue is also reported in patients with pediatric MS. Cognitive impairment, depression, and fatigue disrupt the child's academic performance and quality of life [3].

8. Diagnostic evaluation

8.1. Magnetic resonance imaging features

MRI is the most important paraclinical tool for the diagnosis of MS, and it also provides information for differential diagnosis.

Demyelinating plaques are demonstrated as an increased signal on T2 and FLAIR sequences and are typically located in deep white matter, corpus callosum, periventricular zone, juxtacortical, and posterior fossa. Hypointense lesions occur on T1 sequences. These hypointense lesions are named “black holes.” Black holes are a result of tissue loss due to previous inflammatory events. Acute MS plaques may appear to be T1 hypointense as a result of transient edema, but these are not true T1-black holes. T1 hypointensity may remain for months after an acute event with such lesions evolving to isointensity (loss of edema or repair) or persisting as chronic, permanent hypointensity [34]. Active demyelinating plaques may show gadolinium enhancement due to a blood-brain barrier breakdown and enhancement is often incomplete around the periphery (open ring sign) (**Figures 1 and 2**).

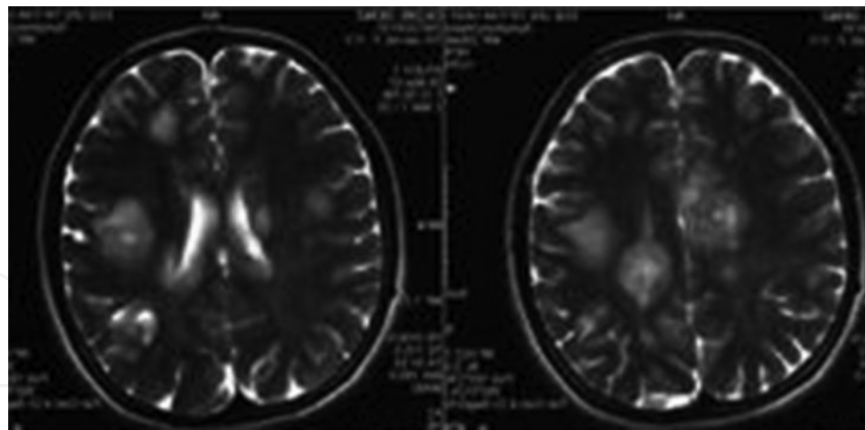


Figure 1. Large, hyperintense lesions on T2-weighted sequences.

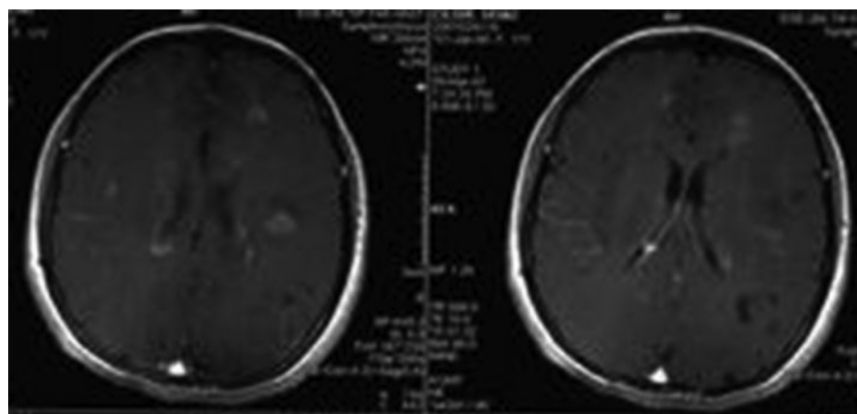


Figure 2. Gadolinium enhanced demyelinating plaques and black holes on T1-weighted sequences.

MRI findings in McDonald's diagnostic criteria are important and provide a diagnosis of MS at the first demyelinating event. According to McDonald's diagnostic criteria, dissemination in space (DIS) can be demonstrated by one or more T2 lesions in at least two of four areas of the CNS (periventricular, juxtacortical, infratentorial, spinal cord) and dissemination in time (DIT) can be demonstrated by a new T2 and/or gadolinium-enhancing lesion(s) on a follow-up MRI, with reference to a baseline scan, irrespective of the timing of the baseline MRI or the simultaneous presence of asymptomatic gadolinium-enhancing and non-enhancing lesions at any time [10]. These criteria have been found to be highly sensitive (100%) and highly specific (86%) for children older than 12 years with non-ADEM presentation, but they may not be appropriate for young children [35].

There are some differences in MRI findings between children and adults, particularly in prepubertal cases: T2-hyperintense lesion volume and lesion load in the infratentorial area are higher in children than they are in adults; first presentation may be as ADEM; there is an increased incidence of larger, tumefactive lesions in young children; spinal cord lesions may be longer than three vertebral segments in children with MS as in neuromyelitis optica [29, 36].

8.2. Cerebrospinal fluid (CSF) features

Analysis of CSF provides information about both the inflammatory process and differential diagnosis such as infection and malignancy. Cell count, presence of oligoclonal bands, and IgG index are examined in CSF analysis. A mild lymphocytic pleocytosis may be seen in children, but it has been shown that children younger than 11 years have more neutrophils in the CSF than older children. Oligoclonal band positivity has been found in 92% of patients with pediatric MS [37, 38]. An increased IgG index is more common in adolescents than in young children.

8.3. Evoked potentials

Evoked potentials help to demonstrate subclinical demyelination and to evaluate prior demyelination [39]. Visual evoked potentials are more informative than brainstem auditory and somatosensory evoked potentials.

9. Differential diagnosis

Other immune-mediated central nervous system demyelinating disorders (clinically isolated syndrome, acute disseminated encephalomyelitis, neuromyelitis optica) must be excluded in pediatric patients presenting a first demyelinating attack.

Clinically isolated syndrome (CIS) is a monofocal (optic neuritis, brainstem syndrome, transverse myelitis, cerebellar syndrome, or hemispheric syndrome) or polyfocal clinical CNS event with a presumed inflammatory demyelinating cause without a prior clinical history of a CNS demyelinating disease and encephalopathy. MRI features do not meet McDonald's criteria. Therefore, a follow-up check for the possibility of developing MS is necessary; however, the likelihood of developing MS is low in patients with a normal brain MRI [28].

Acute disseminated encephalomyelitis (ADEM) is an inflammatory demyelinating disease which is characterized by acute encephalopathy and polyfocal neurologic deficits. Encephalopathy is an important feature and diagnostic criterion. Encephalopathy is defined as an alteration in consciousness or behavioral change unexplained by fever, systemic illness, or postictal symptoms in IPMSSG criteria 2012. Encephalopathy is an unexpected finding in MS. MRI features are also defined for pediatric ADEM in the 2012 IPMSSG criteria [28]. Diffuse, large (>1–2 cm), poorly demarcated hyperintense lesions are detected in cerebral white matter on T2-weighted and fluid-attenuated inversion recovery (FLAIR) sequences; T1 hypointense lesions are rare and deep gray matter lesions can be present in the thalamus or basal ganglia. White matter lesions are multiple, bilateral, and asymmetrical in the cerebral hemispheres, cerebellum, brainstem, and spinal cord. Deep gray matter lesions are usually symmetrical and more characteristic of ADEM than of MS. The presence of T1 hypointense lesions in white matter leads to a diagnosis of MS. Periventricular lesions are less common. Cerebrospinal fluid (CSF) oligoclonal bands are rarely observed and usually transient in ADEM. Anti-MOG antibodies may be transiently present in the serum. ADEM is usually a monophasic disorder.

Clinical and radiologic findings may fluctuate in the first 3 months after the onset of disease. A second attack of ADEM may occur rarely, and it is named “multiphasic ADEM” [28]. This second ADEM event can involve either new neurologic symptoms and MRI findings or the re-emergence of prior neurologic symptoms and MRI findings. In the 2012 IPMSSG criteria, multiphasic ADEM is defined as two episodes consistent with ADEM separated by 3 months but not followed by any further events [28]. Sometimes pediatric ADEM may be the first manifestation of pediatric MS. Mikaeloff et al. showed that 18% of patients with pediatric ADEM had a second attack suggesting MS [40]. The second attack usually occurs within 2 years of the initial event.

Neuromyelitis optica (NMO) is an inflammatory disorder characterized by severe acute transverse myelitis and optic neuritis. Pediatric NMO can be monophasic or relapsing. Optic neuritis and myelitis are more severe in NMO and the prognosis is worse than it is for MS. Atypical presentations such as encephalopathy, persistent hiccups, nausea, and vomiting may occur. A brain MRI does not meet the criteria for MS and can show lesions in the supratentorial area, periaqueductal gray matter, hypothalamus, medial thalamus, dorsal pons, and medulla. The presence of longitudinally extensive spinal cord lesions (more than three vertebral segments) in a spinal MRI is an important finding and a supportive criterion. Anti-aquaporin-4 IgG seropositivity is another supportive criterion and it is 99% specific and 60–70% sensitive in children [41]. CSF oligoclonal bands are generally absent.

Other causes such as vasculitis, vascular, infectious, or neoplastic diseases must be excluded in pediatric patients with acute neurologic deficits. The presence of encephalopathy, persistent headaches, fever, polyneuropathy, and hearing loss, the involvement of other organs such as arthritis, skin rashes, oral/genital ulcers, lymphadenopathy, nephropathy, or hepatopathy with a progressive course should be suggestive of other causes. A progressive course and the involvement of the peripheral nervous system usually occur in mitochondrial diseases or neurometabolic disorders such as leukodystrophies. The diseases that should be kept in mind in the differential diagnosis are shown in **Table 1**. Markedly elevated pleocytosis, low glucose, and increased protein in CSF analysis should rouse suspicions. Persistent gadolinium enhancement and continued enlargement of lesions, leptomeningeal enhancement, T2 hyperintensities in the basal ganglia, thalamus, and hypothalamus, and calcifications in an MRI should also eliminate the diagnosis of MS.

Other demyelinating disorders

- Clinically isolated syndrome
- ADEM
- Neuromyelitis optica

Vasculitis/inflammatory diseases

- Primary CNS angiitis
- Systemic lupus erythematosus
- Sjögren syndrome
- Behcet disease

Neurosarcoidosis
Cerebrovascular disorders
Infection
Neurborreliosis
Tuberculosis
Viral encephalitis
HIV
Progressive multifocal leukoencephalopathy (PML)
Neurometabolic/genetic disorders
Mitochondrial diseases
Leukodystrophies
Neoplasm
CNS lymphoma
Other CNS tumors

Table 1. Differential diagnosis of pediatric MS.

10. Treatment

10.1. Treatment of the acute demyelinating attack

A mildly acute demyelinating attack that does not impair the patient's functions may not require treatment. The first option in the treatment of an acute demyelinating attack is a high-dose intravenous corticosteroid. Corticosteroids increase the speed of recovery and reduce the number of gadolinium-enhancing lesions on an MRI. The presumed mechanisms of action are modification of cytokine responses, reduction in T cell activation, and reduction in blood-brain barrier permeability. Intravenous corticosteroid is administered as 20–30 mg/kg (up to 1 g/day) methyl prednisolone over 3–5 days in children. There is no consensus on tapering oral corticosteroid. Oral prednisone may be administered to patients with incomplete recovery after intravenous treatment. Plasma exchange can be considered for patients with severe, life-threatening attacks or patients who were unresponsive to intravenous steroid treatment. The typical course is 5–7 exchanges over the course of 10–14 days. Plasma exchange therapy is an invasive treatment; its side effects include infection, blood clotting issues, and electrolyte disturbances. Another option is intravenous immunoglobulin (IVIG) if the steroids are contraindicated or the response is inadequate. There have been no controlled studies for the efficiency of this treatment in pediatric MS. IVIG influences cytokine production, T cell proliferation, and autoantibodies against myelin. It is given at a dose of 2 g/kg over 2–5 days. Side effects include fever, headache, aseptic meningitis, thromboembolism, and allergic reactions. Severe allergic reactions may develop in people with IgA deficiency; therefore, serum IgA levels should be examined before treatment [42, 43].

10.2. Disease-modifying therapy

The aims of treatment are to reduce disease activity, prevent disability, and preserve cognitive functions. Therefore, it is recommended to start treatment at an early stage.

First-line disease-modifying therapy includes interferon beta and glatiramer acetate. These drugs are used in adults for 15–20 years. Their efficacy, side effects, and safety are well known in adults. Both interferon beta and glatiramer acetate reduce relapse rates by approximately 30% and the accrual of new lesions on the MRI. There have been no randomized controlled trials in pediatric patients.

Glatiramer acetate is a synthetic amino acid polymer that resembles myelin basic protein. Its mechanism is not clear. It modulates T cells, shifts the population of T cells from proinflammatory Th1 cells to regulatory Th2 cells, and reduces antigen presentation. Standard dosage is 20 mg daily by subcutaneous injection. Its side effects include injection reactions, lipoatrophy at injection sites, chest pain, and a post-injection reaction (anxiety, flushing, palpitations, dyspnea, and chest pain) [42–44].

Interferon beta inhibits autoreactive T cells, increases production of anti-inflammatory cytokines, reduces proinflammatory cytokines, and decreases the migration of inflammatory cells into CNS. There are two subgroups: interferon beta 1a and 1b. Interferon beta 1a is given three times a week at a dose 22 or 44 µg via subcutaneous injection or intramuscularly at a dose of 30 µg a week. A pegylated form of interferon beta 1a is used in adults, but the safety and efficacy of this form in children and adolescents have not been established. The standard dose of interferon beta-1b is 0.25 mg (8 MIU), injected subcutaneously every other day. Dose titration is recommended at the start of treatment for interferons. Most pediatric patients tolerate the adult dose. The most frequent side effects are flu-like symptoms, injection site reaction, transient transaminase elevation, bone marrow suppression, thyroid dysfunction, and depression. Paracetamol and ibuprofen are effective in managing the flu-like symptoms. Liver transaminases, blood counts, and a thyroid function test should be carried out following the treatment.

The aim of disease-modifying therapy is to reduce clinical and radiological disease activity. Disease activity is defined as clinical relapses, new or enlarging lesions on an MRI, or gadolinium-enhancing lesions on an MRI. When the first-line disease-modifying therapy remains insufficient to reduce disease activity, second-line therapies can be used. The second-line therapies that have been used in pediatric MS include natalizumab, rituximab, and cyclophosphamide [42–44].

Natalizumab is a humanized monoclonal antibody. Natalizumab selectively binds to the 4-integrin component of adhesion molecules found in lymphocytes, monocytes, eosinophils and inhibits the α 4-mediated adhesion of leukocytes to their counter-receptors. It decreases clinical relapse rate by about 70% and reduces the accumulation of new or enlarging T2 hyperintense lesions. Natalizumab is given at a dose of 300 mg intravenously every 4 weeks. Its side effects include hypersensitivity and headaches. The most serious risk is progressive multifocal leukoencephalopathy (PML) in adults. This fatal risk is higher in patients who have been exposed to the JC virus and have been treated with immunosuppressive drugs previously.

There is also a relationship between the duration of natalizumab therapy and an increased risk. There have been no controlled, randomized trials in pediatric MS to date.

Rituximab is a monoclonal antibody. It selectively depletes CD20+ B lymphocytes. There have been no controlled, randomized trials. Salzer et al. suggested that rituximab treatment is safe, effective, and well tolerated in their case series with pediatric MS [45].

Trials on the safety and efficacy of new oral therapies including fingolimod, dimethyl fumarate, and teriflunamide in pediatric MS patients have not been finalized.

10.3. Symptomatic treatment

Spasticity, fatigue, tremor, neuropathic pain, paroxysmal symptoms, epileptic seizures, bladder dysfunctions, and depression can be persistent symptoms in MS and affect patient's quality of life. Medical drugs can be effective in the treatment of these symptoms as in adult patients.

Baclofen, tizanidine, and benzodiazepines are effective for spasticity. Amantadine, modafinil, methylphenidate can be used for fatigue. Antiepileptic drugs such as carbamazepine, gabapentine are effective for both paroxysmal symptoms and neuropathic pain [42]. Anticholinergic agents (oxybutynin, tolterodine) can be used for detrusor hyperreflexia, and desmopressin may be beneficial for nocturia.

10.4. Rehabilitation

The aim of MS rehabilitation is to reduce symptoms including spasticity, gait disturbances, imbalance, bladder-bowel dysfunction, speech and swallowing disorders, fatigue, pain and improve quality of life. Rehabilitation interventions for MS symptoms include methods such as exercise (stretching/strengthening), gait training, endurance training, aerobic training, hydrotherapy, physiotherapy, exercise-pelvic floor training, occupational therapy, psychological training [46]. Rehabilitation interventions should be selected according to patient's characteristics such as age and functional deficits.

Cognitive rehabilitation is an important part of MS rehabilitation, but there is no specific cognitive rehabilitation intervention for pediatric MS. Rehabilitative strategies include rehabilitation of attention and language based on other disease such as trauma, stroke, and tumor [47].

11. Conclusion

Two to 5% of all MS patients have their first attack during childhood or adolescence. Pediatric MS has different clinical features from adult-onset MS, particularly in very young children. ADEM can occur as first attack in children, especially those under 10 years of age. The relapse rate in pediatric MS is higher than in adult MS, but recovery from relapse is better than in adults. However, the onset of secondary progression occurs at a younger age as compared

with adult-onset MS. The primary progressive form of MS is extremely rare in pediatric patients. Primary progressive course should suggest other diagnoses in children. Cognitive impairment is one of the most important causes of disability and has different characteristics from adults. Linguistic dysfunction and decrease in IQ scores can occur during the first year of disease. Despite all these differences from adult MS, the therapeutic approach is based on information in adult MS. There are no randomized controlled trials on efficacy and safety of immunomodulatory and immunosuppressive drugs. Studies on pathogenesis are also limited in pediatric MS. One of the most important differences in the pathogenesis of pediatric-onset and adult-onset MS is the presence of anti-MOG antibodies in children. More studies on pathogenesis will provide insight into clinical differences and the development of more safe and effective treatment.

Author details

Ozgul Ekmekci

Address all correspondence to: ozgul.ekmekci@ege.edu.tr

Ege University, Faculty of Medicine, Department of Neurology, Izmir, Turkey

References

- [1] Duquette P, Murray TJ, Pleines J, et al.: Multiple sclerosis in childhood: clinical profile in 125 patients. *J Pediatr.* 1987;111:359–363. DOI: 10.1016/S0022-3476(87)80454-7.
- [2] Ghezzi A, Deplano V, Faroni J, et al.: Multiple sclerosis in childhood: clinical features of 149 cases. *Mult Scler.* 1997;3:43–46. DOI: 10.1177/135245859700300105.
- [3] Bigi S, Banwell B: Pediatric multiple sclerosis. *J Child Neurol.* 2012;27(11):1378–1383. DOI: 10.1177/0883073812452784
- [4] Gadoth N: Multiple sclerosis in children. *Brain Dev.* 2003;25:229. DOI: 10.1016/S0387-7604(03)00035-4.
- [5] Banwell B, Ghezzi A, Bar-Or A, Mikaeloff Y, Tardieu M: Multiple sclerosis in children: clinical diagnosis, therapeutic strategies, and future directions. *Lancet Neurol.* 2007;6:887–902. DOI: 10.1016/S1474-4422(07)70242-9.
- [6] Mowry EM, Krupp LB, Milazzo M, et al.: Vitamin D status is associated with relapse rate in pediatric onset multiple sclerosis. *Ann Neurol.* 2010;67(5):618–624. DOI: 10.1002/ana.21972.

- [7] Mikaeloff Y, Cardidade C, Tardieu M, Suissa S: Parental smoking at home and risk of childhood onset multiple sclerosis in children. *Brain*. 2007;130:2589–2595. DOI: 10.1093/brain/awm198.
- [8] Ascherio A, Munger KI: Environmental risk factors for multiple sclerosis: part 1: the role of infection. *Ann Neurol*. 2007;61(4):288–289. DOI: 10.1002/ana.21117.
- [9] Langer-Loud A, Brara SM, Beaber BE, et al.: Childhood obesity and risk of pediatric multiple sclerosis and clinically isolated syndrome. *Neurology*. 2013;80(6):548–552. DOI: 10.1212/WNL.0b013e31828154f3.
- [10] Vargas-Lowy D, Chitnis T: Pathogenesis of pediatric multiple sclerosis. *J Child Neurol*. 2012;27(11):1394–1407. DOI: 10.1177/0883073812456084.
- [11] Chitnis T: The role of CD4 T cells in the pathogenesis of multiple sclerosis. *Int Rev Neurobiol*. 2007;79:43–72. DOI: 10.1016/S0074-7742(07)79003-7.
- [12] Ciccarelli O, Barkhof F, Bodini B, et al.: Pathogenesis of multiple sclerosis: insights from molecular and metabolic imaging. *Lancet Neurol*. 2014;13:807–822. DOI: 10.1016/S1474-4422(14)70101-2.
- [13] Stromnes IM, Cerretti LM, Liggitt D, et al.: Differential regulation of central nervous system autoimmunity by TH1 and TH17 cells. *Nat Med*. 2008;14:337–342. DOI: 10.1038/nm1715.
- [14] Lock C, Hermans G, Pedotti R, et al.: Gene-microarray analysis of multiple sclerosis lesions yields new targets validated in autoimmune encephalomyelitis. *Nat Med*. 2002;8:500–508. DOI: 10.1038/nm0502-500.
- [15] Graber JJ, Allie SR, Mullen KM, et al.: Interleukin-17 in transverse myelitis and multiple sclerosis. *J Neuroimmunol*. 2008;196:124–132. DOI: 10.1016/j.jneuroim.2008.02.008.
- [16] Correale J, Tenembaum SN: Myelin basic protein and myelin oligodendrocyte glycoprotein T-cell repertoire in childhood and juvenile multiple sclerosis. *Mult Scler*. 2006;12:412–420. DOI: 10.1191/135248506ms1282oa.
- [17] Fernandez-Carbonell C, Vargas-Lowy D, Musallam A, et al.: Clinical and MRI phenotype of children with MOG antibodies. *Mult Scler J*. 2016;22(2):174–184. DOI: 10.1177/1352458515587751.
- [18] Kitley J, Woodhall M, Waters P, et al.: Myelinoligodendrocyte glycoprotein antibodies in adults with a neuromyelitis optica phenotype. *Neurology*. 2012;79:1273–1277. DOI: 10.1212/WNL.0b013e31826aac4e.
- [19] Chitnis T, Imitola J, Khoury SJ.: Therapeutic strategies to prevent neurodegeneration and promote regeneration in multiple sclerosis. *Curr Drug Targets Immune Endocr Metabol Disord*. 2005;5:11–26.

- [20] Lucchinetti C, Bruck W, Parisi J, et al.: Heterogeneity of multiple sclerosis lesions: implications for the pathogenesis of demyelination. *Ann Neurol*. 2000;47:707–717.
- [21] Trapp BD, Peterson J, Ransohoff RM, et al.: Axonal transection in the lesions of multiple sclerosis. *N Engl J Med*. 1998;338:278–285. DOI: 10.1056/NEJM199801293380502.
- [22] Kutzelnigg A, Lucchinetti CF, Stadelmann C, et al.: Cortical demyelination and diffuse white matter injury in multiple sclerosis. *Brain*. 2005;128(pt 11):2705–2712. DOI: 10.1093/brain/awh641.
- [23] Kutzelnigg A, Faber-Rod JC, Bauer J, et al.: Widespread demyelination in the cerebellar cortex in multiple sclerosis. *Brain Pathol*. 2007;17:38–44. DOI: 10.1111/j.1750-3639.2006.00041.x.
- [24] McAdam LC, Blaser SI, Banwell BL.: Pediatric tumefactive demyelination: case series and review of the literature. *Pediatr Neurol*. 2002;26:18–25. DOI: 10.1016/S0887-8994(01)00322-8.
- [25] Lucchinetti CF, Gavrilova RH, Metz I.: Clinical and radiographic spectrum of pathologically confirmed tumefactive multiple sclerosis. *Brain*. 2008;131(7):1759–1775. DOI: 10.1093/brain/awn098.
- [26] Krupp LB, Banwell B, Tenenbaum S: Consensus definitions proposed for pediatric multiple sclerosis and related disorders. *Neurology*. 2007;68:S7–S12. DOI: 10.1212/01.wnl.0000259422.44235.a8.
- [27] Polman CH, Reingold SC, Banwell B, et al.: Diagnostic criteria for multiple sclerosis: 2010 revisions to the McDonald criteria. *Ann Neurol*. 2011;69:292–302. DOI: 10.1002/ana.22366.
- [28] Krupp LB, Tardieu M, Amato MP et al.: International Pediatric Multiple Sclerosis Study Group criteria for pediatric multiple sclerosis and immune-mediated central nervous system demyelinating disorders: revisions to the 2007 definitions. *Mult Scler*. 2013;19(10):1261–1267. DOI: 10.1177/1352458513484547.
- [29] Narula S: New perspectives in pediatric neurology-multiple sclerosis. *Curr Probl Pediatr Adolesc Health Care*. 2016;46(2):62–69. DOI: 10.1016/j.cppeds.2015.11.002.
- [30] Pena JA, Lotze TE: Pediatric multiple sclerosis: current concepts and consensus definitions. *Autoimmune Dis*. 2013;2013, Article ID 673947:12 p. DOI: 10.1155/2013/673947.
- [31] Huppke B, Ellenberger D, Rosewich H, Friede T, Gartner J, Huppke P: Clinical presentation of pediatric multiple sclerosis before puberty. *Eur J Neurol*. 2014;21(3):441–446. DOI: 10.1111/ene.12327.

- [32] Cardoso M, Olmo NR, Fragoso YD: Systematic review of cognitive dysfunction in pediatric and juvenile multiple sclerosis. *Pediatr Neurol.* 2015;53:287–292. DOI: 10.1016/j.pediatrneurol.2015.06.007.
- [33] Suppiej A, Cainelli E: Cognitive dysfunction in pediatric multiple sclerosis. *Neuropsychiatr Dis Treat.* 2014;10:1385–1392. DOI: 10.2147/NDT.S48495.
- [34] Simon JH, Li D, Traboulsee A, et al.: Standardized MR imaging protocol for multiple sclerosis: consortium of MS centers consensus guidelines. *Am J Neuroradiol.* 2006;27:455–461.
- [35] Sadaka Y, Verhey LH, Shroff MM, et al.: 2010 McDonald criteria for diagnosing pediatric multiple sclerosis. *Ann Neurol.* 2012;72(2):211–223. DOI: 10.1002/ana.23575.
- [36] Waubant E, Chabas D, Okuda T, et al.: Difference in disease burden and activity in pediatric patients on brain magnetic resonance imaging at time of multiple sclerosis onset vs adults. *Arch Neurol.* 2009;66(8):967–971. DOI: 10.1001/archneurol.2009.135.
- [37] Ghezzi A, Pozzilli C, Liguori M, et al.: Prospective study of multiple sclerosis with early onset. *Mult Scler.* 2002;8(2):115–118. DOI: 10.1191/1352458502ms786oa.
- [38] Pohl D, Rostasy K, Reiber H, Hanefeld F: CSF characteristics in early-onset multiple sclerosis. *Neurology.* 2004;63(10):1966–1967. DOI: 10.1212/01.WNL.0000144352.67102.BC.
- [39] Pohl D, Rostasy K, Treiber H et al.: Pediatric multiple sclerosis: detection of clinically silent lesions by multimodal evoked potentials. *J Pediatr.* 2006;149:125–127. DOI: 10.1016/j.jpeds.2006.01.003.
- [40] Mikaeloff Y, Suissa S, Vallée L, Lubetzki C, et al.: First episode of acute CNS inflammatory demyelination in childhood: prognostic factors for multiple sclerosis and disability. *J Pediatr.* 2004;144(2):246–252. DOI:10.1016/j.jpeds.2003.10.056.
- [41] Banwell B, Tenenbaum S, Lennon VA, et al.: Neuromyelitis optica-IgG in childhood inflammatory demyelinating CNS disorders. *Neurology.* 2008;70(5):344–352. DOI: 10.1212/01.wnl.0000284600.80782.d5.
- [42] Narula S, Hopkins SE, Banwell B: Treatment of pediatric multiple sclerosis. *Curr Treat Options Neurol.* 2015;17:10. DOI: 10.1007/s11940-014-0336-z.
- [43] Bernton JN, Banwell BL. Therapeutic approach to the management of pediatric demyelinating disease: multiple sclerosis and acute disseminated encephalomyelitis. *Neurotherapeutics.* 2016;13:84–95. DOI: 10.1007/s13311-015-0396-0.
- [44] Kornek B. Treatment of pediatric multiple sclerosis. *Neuropediatrics.* 2013;44(06):309–313. DOI: 10.1055/s-0033-1359308.
- [45] Salzer J, Lycke J, Wickstrom R, Naver H: Rituximab in paediatric onset multiple sclerosis: a case series. *J Neurol.* 2016;263(2):322–326. DOI: 10.1007/s00415-015-7979-x.

- [46] Beer S, Khan F, Kesselring J. Rehabilitation interventions in multiple sclerosis: an overview. *J Neurol*. 2012;259(9):1994–2008. DOI: 10.1007/s00415-012-6577-4.
- [47] Portaccio E, Goretti B, Zipoli V, et al. Cognitive rehabilitation in children and adolescents with multiple sclerosis. *Neurol Sci*. 2010;31(Suppl 2):S275–S278. DOI: 10.1007/s10072-010-0377-3.

IntechOpen

IntechOpen

