

We are IntechOpen, the world's leading publisher of Open Access books Built by scientists, for scientists

6,900

Open access books available

185,000

International authors and editors

200M

Downloads

Our authors are among the

154

Countries delivered to

TOP 1%

most cited scientists

12.2%

Contributors from top 500 universities



WEB OF SCIENCE™

Selection of our books indexed in the Book Citation Index
in Web of Science™ Core Collection (BKCI)

Interested in publishing with us?
Contact book.department@intechopen.com

Numbers displayed above are based on latest data collected.
For more information visit www.intechopen.com



Intraoperative Neurophysiological Monitoring in Neuro-oncology

Lorena Vega-Zelaya, Rafael G. Sola and Jesús Pastor

Additional information is available at the end of the chapter

<http://dx.doi.org/10.5772/63241>

Abstract

Neurosurgery can be considered a radical method to treat some illnesses and can seriously damage the nervous system. To avoid deleterious effects, such injuries must be detected during their initial development by means of intraoperative neurophysiological techniques (including intraoperative neurophysiological monitoring (IONM) and functional mapping).

In this chapter, we review the most relevant and frequently performed IONM/mapping techniques. Some insight about the electrophysiological basis of stimulation and recording of the nervous system are provided. Intraoperative neurophysiological techniques can be divided into free running or evoked elicited. Among the first we discuss EMG, EEG and ECoG. Evoked potentials discussed include somato-sensory (SSEPs), auditory (BAEPs), visual (VEPs), motor (MEPs) and stimulated EMG. We are especially interested in the clear and concise exposition of the methodological peculiarities, the fields of application and the flaws associated with the different techniques discussed, with a focus on practical applications. Therefore, we show examples of real operations performed at our institution.

We conclude that IONM and mapping are some of the techniques with more relevance during recent decades for oncological neurosurgery. The widespread use and improvement of these techniques have allowed a safer removal of a radical tumour, reducing the risk of permanent postoperative deficits and better functional postsurgical outcomes during neuro-oncological surgery.

Keywords: anaesthetized craniotomy, awake craniotomy, intraoperative neurophysiology, motor evoked potentials, multimodal evoked potentials

1. Introduction

Neuro-oncology is a great challenge for neurosurgeons from two perspectives: first, in some types of tumours, gross total resection (GTR) is the best predictor of outcome in terms of life

expectancy [1,2]; second, a main goal of every surgery is to avoid introducing new iatrogenic lesions. The relative weight of every one of these principles can be changed based on individual considerations of the type of tumour, the structures affected, the life expectancy and even the social considerations of each patient. These features are particularly relevant to patients suffering from high-grade gliomas, for whom survival is directly related to the degree of tumour removal. Therefore, to maintain an adequate quality of life, the primary goal of surgery is to achieve GTR without compromising neurological function.

Central nervous system tumours are relatively common in adults; they are the second most common form of cancer and the most common type of solid tumour in children. Although more than half of these tumours are benign, they can cause substantial morbidity. The most common tumours in adolescents and adults aged 15–34 years are gliomas and meningiomas [3]. Glioblastoma multiforme (GBM) is the most common type of glioma. Meningiomas derive from meningotheelial cells and comprise approximately 20 percent of primary brain tumours. GBM are more commonly located in the supratentorial region, with the frontal lobe being the most common site [3].

Advances in surgical techniques, such as intraoperative neurophysiological monitoring (IONM), intraoperative magnetic resonance imaging (MRI), diffusion tensor imaging (DTI), stereotactic guidance and fluorescent-guided resection (FGR), have facilitated the delineation of tumour borders and can aid in optimizing safe surgical resection [4–6].

Neurosurgery can be considered a radical method to treat some illnesses and can seriously damage the nervous system (NS). These injuries may not be apparent by visual inspection by the surgeon in the operating room but subsequently evolve into a definite lesion [7]. To avoid deleterious effects, such injuries can be detected during their initial development by IONM. Therefore, IONM is a powerful set of techniques that provide increased functional knowledge during a surgical operation, resulting in the safer removal of a radical tumour [8,9].

The operating room is an aggressive environment to perform recordings due to the presence of several sources of noise. Therefore, it is very important to identify the source of electromagnetic noise and to determine how to manage it. Unfortunately, this subject is beyond the scope of this chapter, but we refer the reader to Pastor J, 2014, [10] for a detailed discussion of these topics.

In this chapter, we review the most relevant and frequently performed IONM techniques. We are especially interested in the clear and concise exposition of the methodological peculiarities, the fields of application and the flaws associated with the different techniques discussed, with a focus on practical applications. Therefore, we show examples of real operations performed at our institution.

2. Neurophysiological techniques

The possibility of using neurophysiological techniques to study the physiology of the NS is based on the way of function of the NS. Therefore, before introducing the techniques, we must

understand, at least in a general manner, the function of this system for recording signals because all of the information that can be obtained and used clinically ultimately depends on both features.

2.1. Some insight regarding the function and recordings of the nervous system

The basic functional unit of the NS is the action potential (AP), which is the stereotypical change in the transmembrane voltage of a neuron [11–13]. In general, the AP originates in the neural soma or axon hillock and is transmitted by the axon to the synapse. All potentials originate from closed circuits of current [14], and the extracellular component can be recorded using the appropriate electrodes. In general, small metal electrodes are used to detect these currents.

Bioelectrical signals coming from the brain originate from synaptic currents in the cortex [13,14], or in deep nuclei of the thalamus or brainstem. These currents (clearly together with their intracellular components) form closed circuits that spread via volume conduction. The relationship between the current density (mA/cm^2) and the electric field (\vec{E} , in V/cm) is given by the generalized Ohm's law:

$$\vec{J} = \sigma \vec{E} \quad (1)$$

where σ is the tensor of conductivity (mS/cm). Considering that conductivity is the inverse of resistivity, ϱ ($\text{k}\Omega \text{ cm}$). In the electrostatic approach, the electric field can be expressed in terms of the electrostatic potential (\varnothing , in V) by the following expression:

$$\vec{E} = -\nabla \varnothing \quad (2)$$

where ∇ is the symbol for the gradient operator.¹ Substituting this expression into the first equation, we obtain the following:

$$\vec{J} = -\sigma \nabla \varnothing \quad (3)$$

which provides the current in terms of the potential. We want to highlight the presence of symbol σ . In the real head, conductivity depends on position (inhomogeneity) and direction (anisotropy). Therefore, it is not possible avoid the vectorial approach in Eq. (3) that can be written in the three spatial dimensions (x, y, z) as follows:

¹ The gradient operator is the partial derivative for the space and is given by $\nabla = \frac{\partial}{\partial x} \vec{i} + \frac{\partial}{\partial y} \vec{j} + \frac{\partial}{\partial z} \vec{k}$

$$\begin{pmatrix} J_x \\ J_y \\ J_z \end{pmatrix} = - \begin{bmatrix} \sigma_{xx} & \sigma_{xy} & \sigma_{xz} \\ \sigma_{yx} & \sigma_{yy} & \sigma_{yz} \\ \sigma_{zx} & \sigma_{zy} & \sigma_{zz} \end{bmatrix} \begin{pmatrix} \frac{\partial \phi}{\partial x} \\ \frac{\partial \phi}{\partial y} \\ \frac{\partial \phi}{\partial z} \end{pmatrix} \quad (4)$$

This tensorial equation can be represented for every spatial dimension x, y, z as follows:

$$\vec{J}_i = -\sigma_{ix} \frac{\partial \phi}{\partial x} \vec{i} - \sigma_{iy} \frac{\partial \phi}{\partial y} \vec{j} - \sigma_{iz} \frac{\partial \phi}{\partial z} \vec{k}; i = x, y, z \quad (5)$$

Hence, for the same voltage source, the current obtained depends on the conductivity of the different structures. Consequently, structures with higher resistivity, such as the skull and the skin, will only allow a lower current [14]. Similarly, if we recall that higher frequency oscillations of the cortex imply smaller synchronized regions, we can understand why frequencies above the beta band (13–30 Hz) are extremely difficult to record from the scalp. The necessity to record very small currents is the main reason why a low impedance is needed at the patient–electrode interface.

In general, two types of recordings can be distinguished in neurophysiology [15]: near-field and far-field potentials. These concepts are completely different from the same words used in electromagnetic theory. The generators of near-field potentials are located in the cerebral cortex with limited spreading on the scalp. That is, we assume that the neurons responsible for the potential are in the immediate proximity of the region in which this potential is observed. However, far-field potentials originate from the deepest structures (white matter, basal ganglia or brainstem nuclei), and their distribution throughout the scalp is more extensive.

We can divide the neural response recorded by electrodes into three types according to the type of stimuli that induces the response in the neural tissue [13]: (i) electrically induced responses. We apply a controlled stimulation to activate different structures. Among these, we have all the types of evoked potentials or the response of a muscle after electrical stimulation of its innervating nerve (stimulated electromyography or sEMG); (ii) neural response by involuntary stimulation. Those responses appearing in the neural tissue after surgical aggression, e.g., mechanical compression or torsion, ischemia or heating induced by electrocoagulation, must be included in this group. A typical example of this is the neurotonic discharge of a muscle (free electromyography or fEMG) induced by stretching or overheating of a cranial nerve (CN); (iii) physiological response of the NS. These are spontaneously induced responses that are intrinsically generated by the neural activity, either as a physiological or pathological expression of the activity, and can include electrocorticography (ECoG) or electrocardiography (EKG).

Neurophysiological techniques can be classified according to the manner by which the signals can be obtained, by means of a previous stimulation (a) or without that stimulus (b and c).

2.2. Free-running techniques

The recordings obtained using these techniques can be acquired continuously and do not require a command from the neurophysiologist to be released.

2.2.1. *Electromyography (EMG)*

Free EMG (or fEMG) is the recording of the bioelectrical activity from muscles. Usually, fEMG is recorded by a pair of intramuscular stainless steel electrodes that are inserted into the muscle separated by a distance of 2 cm.

Although we may be interested in the state of the muscle, the most common use of the fEMG signal is to identify changes in the CN or peripheral nerves. In fact, we used nerve-induced electrical activity of the muscle as a measure of the state of that nerve. In this way, we could be aware of irritative activity originating in the nerve as a consequence of traction, torsion, compression, or heat injury, among others. In addition, the patient should not be curarized during most of the surgery. It is important to distinguish between mechanical activity induced by surgical activity, which is usually transient, and neurotonic discharges, which are continuous and persist after the surgeon leaves the surgical field.

Settings that are used to record fEMG depend on the muscle being recorded, the size of the electrodes and the objective. However, it is quite common to use a 10–3000 Hz bandwidth, with either the notch on or off (in this case, the high pass filter should be increased up to 50 Hz), a gain always greater than 30 $\mu\text{V}/\text{div}$ (the most common is 50 $\mu\text{V}/\text{div}$), and a time base between 100 ms/div (for small periods) and 750 ms/div (for longer periods). In the last case, we are aware that the shape of the muscle activity can be distorted (depending on the screen resolution) and could be misinterpreted as an artefact.

2.2.2. *Electroencephalography (EEG) and electrocorticography (ECoG)*

The difference between EEG and ECoG resides in the location of the recording electrodes. However, this difference is sufficient great to warrant separate discussion of the methods. As a result of the analysis of volume conduction, among other dissimilarities that are not discussed herein, EEG and ECoG will be differentiated based on the magnitude of the current and the frequency composition.

2.2.2.1. *EEG*

Recording electrodes are placed onto the skin of the scalp. The most common types are subdermal stainless steel needles that are placed inside the skin or cork-screw electrodes, which are more easily fixed to the patient but are clearly also more aggressive. Subdermal electrodes allow low impedance (less than 5 k Ω is fine), which is important for acquiring a

good recording. We can use the International System 10–20 [16] to position the electrodes, but it is more common to use a reduced version of this system.

EEG can be used to monitor the state of the cerebral cortex, and the main indications in IONM are blood flow alterations and epileptic activity. Bioelectrical activity directly depends on blood flow, and a reduction of this variable will be observed as a slowing of the brain activity denoted by the appearance of theta/delta activity [17]. Epileptic activity can appear after a perfusion alteration or as a consequence of an insult to the cortex (mechanical, chemical or electrical). Considering that high-voltage electrical stimulation is common during IONM, EEG should be used in all patients with an increased risk of epileptic seizure. Similarly, we must be aware that general anaesthetics can increase the likelihood of seizures [18]. Customarily, some degree of quantification should be useful.

The bandwidth filter should be at least 0.5–30 Hz, with the notch on. For this type of recording, higher frequencies are uncommon in the presence of anaesthesia. The gain must be set between 7 and 15 $\mu\text{V}/\text{div}$ and the time base at approximately 15–30 mm/s.

2.2.2.2. ECoG

ECoG is used to record the bioelectrical activity directly from the cortical surface. Several types of tumours that are located in the cortex can induce epilepsy or irritative activity, which are defined by the presence of a spike or sharp waves and its combinations. Hence, it is very relevant to assess the presence of these activities. In this sense, ECoG can discriminate between different functional regions in the cortex, namely [9,19] (i) the spiking area, where the irritative activity can be observed; (ii) the lesional area, where abnormal slowing or loss of activity is observed; and (iii) the non-pathological area, which is defined by the absence of the above-mentioned activities. The identification of these regions helps the surgeon to select the cortical region through which to approach the tumour [6,20].

As we have stated previously, it is very important to monitor the presence of epileptic activity during electrical stimulation of the cerebral cortex.

The settings for ECoG should consist of a bandwidth filter of 0.5–100 Hz, with the notch on, a gain of 750–1500 $\mu\text{V}/\text{div}$ and a time base of 15–30 mm/s. As stated previously, some type of mathematical analysis can be helpful for the assessment of ECoG [5,6].

2.3. Evoked potentials

The signals recorded using these techniques have the common feature that a previous stimulation must be elicited. Some of these, due to a very small amplitude, must be averaged. Before each technique is discussed in detail, we shall briefly explain why an average is needed [21,22]. Averaging is an extraordinarily powerful tool to separate the signal from its noisy environment.

A neurophysiological measurement (m) consists of the signal to be acquired (s) and the noise (n) [23]. Consider $m(t)=s(t)+n(t)$. In many cases, the noise amplitude is greater than the signal ($n>s$). Therefore, to reduce the noise and enhance the signal we perform several rounds of stimulation (say M), such that, for each k th stimulus, the expression of the measure will be as follows:

$$m_k(t) = s_k(t) + n_k(t); k = 1, 2, \dots, M \quad (6)$$

We can see that the average of M leads to $m(t)$, $s(t)$ and $n(t)$, denoted by, \bar{m} , \bar{s} , \bar{n} , and can be written as follows:

$$\bar{m} = \frac{1}{M} \sum_{i=1}^M m_i(t) = \frac{1}{M} \sum_{i=1}^M s_i(t) + \frac{1}{M} \sum_{i=1}^M n_i(t) = \bar{s} + \bar{n} \quad (7)$$

This expression embodies the justification of the method. However, to be truly useful, it is necessary that two conditions are met: (i) there is no causal relationship between the signal and the noise and (ii) the noise varies randomly from one stimulus to the next. The mean for any variable that varies randomly is $\bar{n}=0$; therefore, the greater the stimulus number, then the greater will be the similarity between \bar{m} and \bar{s} . Furthermore, it is easy to prove (see Van Drongelen), but omitted here, the signal estimated from the measurement, improves by a factor of $1/\sqrt{M}$.

2.3.1. Somato-sensory evoked potentials (SSEPs)

These are potentials that are generated at several points of the somato-sensory pathway.

Electrical stimulation is performed along the path of a peripheral nerve. In the upper limb, the median nerve or ulnar nerve (at wrist or elbow) is commonly used. In the lower limb, the posterior tibial nerve is commonly used. In general terms, nerve stimulation is achieved in the region closest to the cathode (i.e., negative electrode), where it produces a cationic output current [24] that depolarizes the membrane. To avoid anodic block, it is very important to place the anode distally and the cathode proximally.

Stimulation can be performed through the use of auto-adherence electrodes or subdermal needles [23].

It is customary to name the recorded waves (potentials) according to two criteria: polarity; the downward deflection of the wave is considered to be positive (P) and upward deflection negative (N) and latency; the time (measured in milliseconds) during which the potential appears with greater frequency.

Different points will be used throughout the path that reflect the activity of various nerve structures [15]. Recording is performed by placing and properly fixing subdermal electrodes (other types, such as cork-screws or discs, can clearly also be used) according to the 10–20 IS.

2.3.1.1. Upper limb SSEP

- Erb's point. The active electrode is located on the midclavicular line, 2 cm above the clavicle. The reference electrode can be placed several centimetres away. A wave called N9 is recorded. It represents the near-field generated by the afferent arrival of CNAP in the brachial plexus.
- Cervical. The active electrode is located on the second spinose apophysis (C2) or fifth (C5) cervical vertebra, with the reference electrode in the Fz. At this location, we can identify several potentials as follows: (a) N11. This potential is likely a presynaptic travelling wave arising near the root entry zone of C6 and C7 and action potentials ascending in the dorsal columns. It is also known as the dorsal column volley. (b) N13. This potential is generated by the synapse of neurons spanning from dorsal columns onto the nucleus cuneatus. (c) P/N14. This is a distant potential generated by the caudal part of the medial lemniscus at the location of the brainstem. Latency and morphology can vary between individuals (i.e., they can be positive or negative) and may have one or more phases.
- Scalp. The active electrode is placed 5 cm in the lateral direction and 2 cm caudally in relation to the vertex (C4'/C3' for right/left). The reference electrode is located on Fz. Typically, several potentials are registered as follows: (a) N18. Reflecting the postsynaptic potential activity of the ventrocaudal nucleus of the thalamus. (b) N20. This is a near-field potential that is generated by postsynaptic potentials at the hand cortical region. (c) P25 may be an average of the independent posterior frontal and parietal generators. (d) The N35 peak is attributed to the sense of pain and temperature (conveyed by small myelinated fibres).

2.3.1.2. Lower limb SSEP

- Popliteal fossa. Labelled N8.
- Lumbar point. The reference electrode is located in the spinous process of L1 with the reference electrode on the iliac crest. It is called LP (lumbar point) or N22.
- Cervical. It is known as N30.
- Scalp. The active electrode is located in the midline, 2 cm caudal to the vertex (Cz'), with the reference electrode located at Fz. The waves are called P37 and originate from the cortical area of the foot. A potential can also be registered in the fronto-central region with a latency of 38 ms (N38). Because the orientation of the dipole inside the longitudinal fissure is variable, P38 is sometimes maximal over the ipsilateral scalp (paradoxical localization).

The most common parameters employed for stimulation are trains between 4.18 and 7.1 Hz, with a 200–300 μ s pulse width and an amplitude that is double the threshold of the motor

response. In general, the amplitudes are approximately 15–30 mA, and 200–300 pulses/train is recommended. The recording will have a bandwidth of 10–1500 Hz, with the notch off, a gain of 0.1–2 $\mu\text{V}/\text{div}$ and a base time of 5–10 ms/div for the upper and the lower limbs, respectively. It is very important to recall that impedances must be below 5 k Ω .

Warning criteria include increase the latency greater than 10% and/or a decrease in amplitude to less than 50% with respect to baseline.

2.3.1.3. *Cortical SSEP*

During surgery of the cortex, it is very common to use phase reversal of SSEP to identify the transition between motor and somato-sensory areas, which usually occurs at the central sulcus (CS).

Thalamo-cortical projections from the ventrocaudal nucleus synapse in layer IV of the primary somato-sensory area. However, the rostral part of area 3 is located in the anterior wall of the central sulcus, and thus the current sources generated by these afferents can be modelled by a dipole oriented parieto-frontally rather than in a normal position relative to the surface.

We always use cortical SSEP when we need to identify the primary somato-sensory region and/or the motor area (Brodmann area 4). It is very important to keep in mind that in the case of tumours, a significant distortion of the anatomy can be observed [25,26].

The somato-sensory region corresponding to the forearm can be easily identified by the greater amplitude of the complex N1/P1/N2 waves [25].

The recording will have a bandwidth of 10–1500 Hz, with the notch off, a gain of 10–30 $\mu\text{V}/\text{div}$ and a base time of 5–10 ms/div for the upper and the lower limbs, respectively. A 20-electrode grid placed at the lateral region of the fronto-parietal transition can be very helpful. By contrast, for the lower limb SSEP, a 4-8-electrode strip is placed at the medial region. The reference electrode should be placed as far as possible, i.e., at the contralateral earlobe, whereas the ground electrode should be as close as possible, e.g., at the ipsilateral earlobe [13,20].

2.3.2. *Auditory evoked potentials (AEPs)*

Brainstem AEPs (BAEP) are generated by different relay nuclei along the auditory pathway. They are far-field potentials that originate from very deep structures.

2.3.2.1. *Brainstem auditory evoked potentials (BAEPs)*

BAEPs are the set of waveforms that are recorded at the scalp after auditory stimulation of the middle ear. They are formed by the following potentials [26]: (a) wave I. Originates at the distal action potential of cranial nerve (CN) VIII, typically has a latency of 1.5 ms; (b) wave II. This potential is generated at the entry of CN VIII into the brainstem; (c) wave III. Synapse at the ipsilateral superior olivary nucleus. Latency of 3.5 ms; (d) wave IV is produced by activation of the nucleus or axons of the lateral lemniscus; (e) wave V appears to result from activation of the inferior colliculus; (f) waves VI and VII are presumed to be generated by the medial geniculate body and the thalamo-cortical pathways, respectively.

BAEPs are indicated when tumours affect the auditory system (mainly schwannomas of CN VIII) and tumours affecting the brainstem.

A high intensity (greater than 80 dB) is usually used during IONM. The frequency is 21.14 Hz, and a bandwidth of 10/30–1500 Hz is optimal (a broader bandwidth can allow too much noise), with the notch on. A minimum of 1000 stimuli/train are needed to obtain reproducible and stable waveforms.

2.3.2.2. *Cortical auditory evoked potentials (cAEPs)*

These potentials were initially thought to be generated in the primary auditory cortex (PAC), located deeply in the white matter of the lateral fissure of the transverse gyrus of Heschl. However, other different areas, including the second auditory cortex (SAC) and the insula are capable of eliciting cAEPs. There is considerable inter-subject and inter-hemispheric variability [27], and the whole structure remains to be elucidated.

cAEPs are characterized by a series of waves, which can be systematized as follows: (a) short latency waves: N13/P17/N30. These waves are typically recorded from the PAC. This complex is absent in the SAC and (b) intermediate latency waves: peak between 60 and 100 ms. These waves, which are always present in the SAC, can also be present in the PAC.

A stimulation frequency of 2.18 would be adequate. The bandwidth filter is 0.5–1500 Hz, with the notch filter off, and a minimum intensity of 70 dB (sensation level) is applied to the contralateral ear.

2.3.3. *Visual evoked potentials (VEPs)*

These waves exhibit the characteristics of near-field potentials generated from the primary visual cortex. In the surgery room, the most widely (and probably the only) technique used for stimulation is the application of flashes of light. A normal VEP in response to a pattern-reversal checkerboard is a positive midoccipital peak that occurs at a mean latency of 100 ms with three separate phases: an initial negative deflection (N1 or N75), a prominent positive deflection (P1 or P100) and a later negative deflection (N2 or N145).

Although we think that VEP has undeniable utility, there have been some questions about its efficacy. However, more recent results have demonstrated stable recordings and a strong correlation with the postoperative visual function [28,29]. Therefore, intraoperative VEP monitoring will be mandatory for surgeries harbouring a risk of visual impairment [30].

Stimulation is performed by flashing light-emitting diodes at 2.18 Hz, with 10 μ s pulse width, and a bandwidth of 10–1000 Hz. We considered an increase in latency of 10% or a reduction in amplitude greater than 50% amplitude compared with baseline as alarm criteria [6].

In some cases, VEP can be directly recorded from the cortical surface. In these cases, potentials are much more stable, require fewer stimuli (in fact, a very small number of stimuli can induce the response) and are 2–3 orders of magnitude higher than the scalp recording [31].

2.3.4. Motor evoked potentials (MEPs)

Motor evoked potentials are the recordings that are obtained from muscles in response to stimulation of the motor system at different levels (cortex, inner capsule, corticospinal/corticobulbar tracts or spinal cord) [22]. Considering the amplitude of the response, these types of evoked potentials do not need to be averaged.

2.3.4.1. Transcranial electrical stimulation (TES)

This technique consists of the stimulation of the motor pathway by an electrical current delivered through electrodes placed outside the cranium, usually in the scalp [32]. The introduction of TES revolutionized the field of IONM [33].

It is commonly believed that TES excites the white matter of the inner capsule (IC) rather than cortical neurons. In fact, an increase in the magnitude of the current provides stimulation at the level of the brainstem [34]. This possibility must be recognized and kept in mind by the neurophysiologist, especially in the case of surgery at the supratentorial level.

Electrodes can be subdermal needles or cork-screws and are placed at different sites, depending on the region to be stimulated. The most common sites are as follows [35].

- C3/C4, positioned 6 cm from the vertex and in the same plane. These are adequate to elicit responses from the contralateral body, especially from the upper member.
- C1/C2, positioned in the same plane but separated 3 cm from the vertex. This configuration is suitable to elicit response from the lower limbs. However, it has the inconvenience of eliciting too much movement in the patient.
- Fz–Cz': this configuration is adequate to elicit responses from the lower limbs simultaneously. Unfortunately, the response is more variable than the above configurations.
- M1/M2: the electrodes are located 9 cm from the vertex and usually 1 cm in the rostral direction. This configuration is suitable to elicit responses from facial and cranial nerves starting from the brainstem.
- C3/C4–Cz: in this montage, a hemispheric stimulation is elicited with an anode located 6 cm lateral from the vertex and a cathode at Cz. We have modified this configuration with a cathode located 2 cm from the vertex in the contralateral hemisphere [36]. This modification allowed a response not only from the face and contralateral upper limb but also from the lower member.

The parameters used to elicit MEP through TES are variable, but we use trains of 4–6 pulses, with a 50–75 μ s pulse width, an inter-stimulus interval (ISI) of 2 ms (i.e., 500 Hz) and a voltage ranging from 120 to 450 V. It is extremely unusual to use a higher voltage. The recording should be performed with at least 50 μ V/div, although it is quite common to use up to 500 μ V/div for some muscles.

In some tumours located in the brainstem, cervical or upper thoracic cord, it can be useful to use a D wave recording rather than MEP. This wave reflects the travel wave of CNAP from the lateral cortico-spinal tract and must be recorded through electrodes placed in the immediacy of the spinal cord [32]. This technique is very useful because it can be performed under total neuromuscular relaxation and elicited by only one pulse. However, it cannot be used for vascular pathology of the spinal cord and must be cautiously considered when tumours are located near the anterior horns.

There is a false dispute, in our opinion, regarding the superiority of constant-current over constant-voltage stimulation. Of course, there are benefits and flaws of both techniques, but safe and reliable monitoring can be performed using voltage stimulation. Moreover, using a current of 61 mA with a pulse width of 500 μ s [35], the total charge applied is 30.5 μ C. However, a current of 340 mA over 50 μ s [36] supplies a charge of 17 μ C, which is approximately half of the total charge supplied with longer pulses.

2.3.4.2. *Direct cortical stimulation (DCS)*

For this technique, electrodes are applied directly to the cortical/subcortical surface. Direct cortical stimulation (DCS) to identify the primary motor cortex (PMC) is accomplished using paired electrodes. Stimulation is performed using 4–6 pulse trains at 500 Hz (the reason we denote this paradigm high frequency; this technique is also known as multipulse, which is misleading), with biphasic pulses of 150–200 μ s in the duration/phase. Motor evoked potentials are assessed using pairs of subdermal needles spaced approximately 2 cm apart that are inserted into the contralateral muscles, but surface electrodes attached to the skin can also be used. Depending on the location of the tumour, it is customary to use the following muscles: the orbicularis oculi, orbicularis oris, deltoid, brachial biceps, extensor digitorum carpal flexor, abductor pollicis brevis, abductor digiti minimi, quadriceps, tibialis anterior and abductor hallucis.

Stimulation is initiated at 4 mA and increased continuously in increments of 1–2 mA until a stable compound muscle action potential (CMAP) is recorded, at a minimum amplitude of 30 μ V or until an upper limit of 30 mA is achieved without eliciting a CMAP [5,6].

An alternative strategy entails the use of Ojemann's stimulation or low-frequency stimulation, which consists of a 50–60 Hz train that is 3–5 seconds in length and has a pulse width as high as 0.5 ms [37,38].

Although a systematic comparison between both strategies remains to be performed, it is important to be aware that neither electrical thresholds nor muscle response or electrical safety are equivalent.

In this sense, it is important at this point to consider some electrophysiological variables concerning patient safety. The effect of any type of electrical stimulation over the neural tissue is mediated by the total amount of charge applied to the system and the duration of application [39]. The electric current (i , in mA) is defined as follows:

$$i(t) = \frac{dq}{dt} \quad (8)$$

where q is the charge (in μC) and t is time (in ms). Thus, the total charge applied during time t_{pw} (time of pulse width) can be calculated from Eq. (8) as $q(t) = \int_0^{t_{pw}} i(t) dt$. For square pulses (which are the most common), the integral equals the amplitude \times duration, e.g.:

$$q(t) = i \times t_{pw} \quad (9)$$

However, this expression only provides information about the charge/pulse. Therefore, to elucidate the total charge administered to the tissue (q_{total}), we must multiply by the number of pulses (N) as follows:

$$q_{\text{total}} = i \times t_{pw} \times N \quad (10)$$

Another relevant feature concerning safety is the maximum charge density (ρ_{max}), which is defined as q_{max}/A ($\mu\text{C}/\text{cm}^2/\text{phase}$), where A is the area (usually in cm^2). This parameter directly depends on the size and shape of the stimulation electrode.

A comparison of these magnitudes is provided in **Table 1** for three different stimulation paradigms.

Technique	i_{max} (mA)	Pulse width (μs)	Number of pulses	Surface (cm^2)	$q_{\text{max}}/\text{pulse}$ (μC)	$q_{\text{total}}/\text{train}$ (μC)	ρ_{max} ($\mu\text{C}/\text{cm}^2$)
HF	25	300	6	0.0133*	7.5	45	563.9
Awake craniotomy	10	1000	1	0.0079**	10.0	10	1265.8
Ojemann	10	500	240	0.0079	5.0	120	632.9

HF, high frequency.

*The surface is calculated from a 1.3 mm diameter disk electrode.

**The surface is calculated from a 1 mm diameter spherical electrode, assuming that only 1/4th of the surface is in contact with the cortex.

Table 1. Comparison of magnitudes.

Although there are no well-defined limits for the above-mentioned magnitudes, from the table we can observe that Ojemann's technique is the paradigm with the highest $q_{\text{total}}/\text{train}$, and the stimulation for awake craniotomy has the highest ρ_{max} .

2.3.5. Stimulated electromyography (sEMG)

For this technique, EMG is induced by an electrical shock that is delivered consciously, in contrast to the application described for fEMG. The pulses are usually delivered through bipolar (either concentric or parallel) or monopolar probes. In the latter case, it is important to use a cathodal current to stimulate the nerve and place the anode at a non-stimulated tissue.

The parameters must include pulses of a short length to avoid diffusion of the current. Normally, 50–100 μs should be adequate. The current must be maintained as low as possible to avoid injury to the neural tissue and diffusion. The latter effect must be considered in particular when a functional block is apparent because a high current or a long pulse (or both) can stimulate a region of the nerve distal in the damaged or blocked area and result in misleading information.

It is common to use sEMG in the next situation: (i) to explore a region to identify the proximity of nerves that are not easily visible (e.g., when the CN runs inside a schwannoma); (ii) to determine the identity of a nerve; (iii) to evaluate the functionality of the nerve. We usually measure the threshold to elicit a muscular response at two different points (proximal and distal to the region at risk or more damaged by the surgery) and calculate the ratio of $i_{\text{distal}}/i_{\text{proximal}}$. The closer this ratio is to 1, the better the function of the nerve.

The settings used to record sEMG depend on the muscle being recorded, but it is quite common to use a 50–3000 Hz bandwidth, with the notch off, a gain consistently greater than 30 $\mu\text{V}/\text{div}$ (typically 50 $\mu\text{V}/\text{div}$), and a time base between 1.5 and 4.5 ms/div.

2.4. Cortical and subcortical surgery in awake patients

In recent years, there has been a renewed interest in surgery in awake patients [38,40,41]. This procedure uses the asleep–awake–sleep anaesthetic technique, which consists of induction with propofol + sevoflurane and topical blocking with svedocain + lidocaine around the skin incision. During exploration, the patient must be awakened slowly by removing the sedation. In recent years, a new anaesthetic, dexmedetomidine, has been introduced for this type of surgery and is considered the most effective [18].

Cortical stimulation is usually performed through a bipolar probe with ball-tips that are separated by 0.5 cm. It is common to use 60 Hz trains over 1–4 s. The pulse width is usually 1 ms, with a current intensity of 2.5–10 mA [42,43].

A low rate of intraoperative seizures has been reported (approximately 3–3.4%) [44], and some authors have concluded that control by ECoG is not mandatory [42]. However, this conclusion has been debated and remains to be validated.

In addition to this prevention, some authors have focussed on possible secondary effects derived from this technique. A normal human response to such an exceptional situation as awake craniotomy can, for instance, result in the delayed appearance of unintentional distressing recollections of the event or some type of post-traumatic stress disorder (as yet undescribed), despite the satisfaction of the patient concerning the procedure [45].

The limitations of awake surgery must be considered seriously. During such surgeries, the patient is awake with the head fixed and covered with cloth; and the patient may be kept awake for up to 2 h. Hence, patients must have both adequate cognitive function and the emotional maturity necessary to withstand such an environment. In fact, the Japan Society for Awake Surgery Guidelines limits the target patient population to those ranging from 15 to 65 years of age. Although with some limitations, awake craniotomy can be used in the paediatric population [50]. Nevertheless, use in mentally handicapped patients remains problematic or impossible.

However, no differences in the immediate postoperative motor status, extent of resection, or threshold intensity were found between IONM in anaesthetized patients and stimulation during awake craniotomy [46], although a detailed evaluation has not been performed for the different techniques or surgeries.

For selected patients, an awake craniotomy presents an option to reduce the risk of surgery-related neurological deficits, especially for language mapping. However, the benefits and risks of this type of procedure should be carefully considered, and the decision should serve the interests of the patient.

3. Different features of intraoperative neurophysiology

From a conceptual perspective, intraoperative clinical neurophysiology can be divided into two features: mapping and monitoring [47,48]. The characteristics of these features will be briefly described because neither their requirements nor the expectations associated with each are equivalent. The main differences between the features are the duration of study, the objectives and the modifications introduced to the surgery. However, in clinical practice, both features very often largely overlap or are used at different epochs of the same surgery.

3.1. Functional mapping

Functional mapping generally consists of the topographic assessment (although sometimes it is merely qualitative) of various structures to determine the functions that lead to or sit on the structures [9].

From the perspective of duration, it is usually short so that mapping ceases as soon as the function is positively identified. The objectives, as mentioned previously, are purely descriptive.

The changes during surgery are usually minor, especially because the surgery has a limited duration.

A typical example of mapping is the identification of eloquent areas in cortical surgery. In this case, the issue is to identify the eloquent regions. Thus, the surgeon knows the function of each region so he/she can decide where to position the incision or how far it can be moved prior to the detection of eloquent structures.

3.2. Intraoperative monitoring

Monitoring consists of the surveillance of the functional state(s)/structure(s) that is(are) being monitored for all or most of the surgical action, given the risk of iatrogenic injury [9].

Therefore, the duration of monitoring is considerably greater than in the case of mapping, and it usually lasts as long as the surgery itself. This condition naturally requires more dramatic changes than those used for mapping, beyond the modification of anaesthesia.

The objectives in this case are not just the functional identification but also the preservation of functional integrity, which can be compromised by many medical/surgical procedures, ranging from problems related to tissue perfusion (for example, by actively inducing hypotension or bleeding) to inadvertent surgical injuries such as the placement of spatulas.

In general, neurophysiological monitoring is widely employed in oncological or vascular neurosurgery.

4. Topographical approach to IONM

4.1. Cortical surgery

4.1.1. Anatomical and surgical considerations

IONM of cortical tumours is indicated when the lesion is in or near an eloquent area (areas responsible for carrying out basic neurological functions) such as the sensorimotor cortex or the language cortex. IONM enables clinicians to access the function of the motor and sensory systems of the patient during surgery to preserve neurological function, and it increases the success of radical tumour resection [6].

Functional mapping is initially performed to identify functional areas and their relationship with the tumour. This procedure might help the surgeon to determine the site at which to initiate resection of the tumour. Mapping is then followed by monitoring of the structures requiring continuous vigilance.

4.1.2. Particularities of IONM

As mentioned previously, ECoG is used to define functional areas. Moreover, electrical stimulation can elicit epileptiform discharges before, after and during mapping and IONM, considering that seizures in brain tumour patients are a common phenomenon accounting for 20–40 percent of cases [49].

Following the identification of functional areas via ECoG (**Figure 1B**), the location of the CS is determined by cSSEP phase reversal (**Figure 1C**). Accurate identification of the CS is extremely important because it permits identification of the PMC (**Figure 1C**) [5,6]. There is evidence that cSSEP phase reversal increases both the efficiency and the safety of PMC identification

[50]. Thereafter, DCS for the identification of PMC is performed. Of course, the motor map reference is always the Penfield homunculus [51]. However, when performing motor mapping, we must not forget that it does not conform strictly to reality [52]. It is a scheme upon which there are local movements in different directions [53].

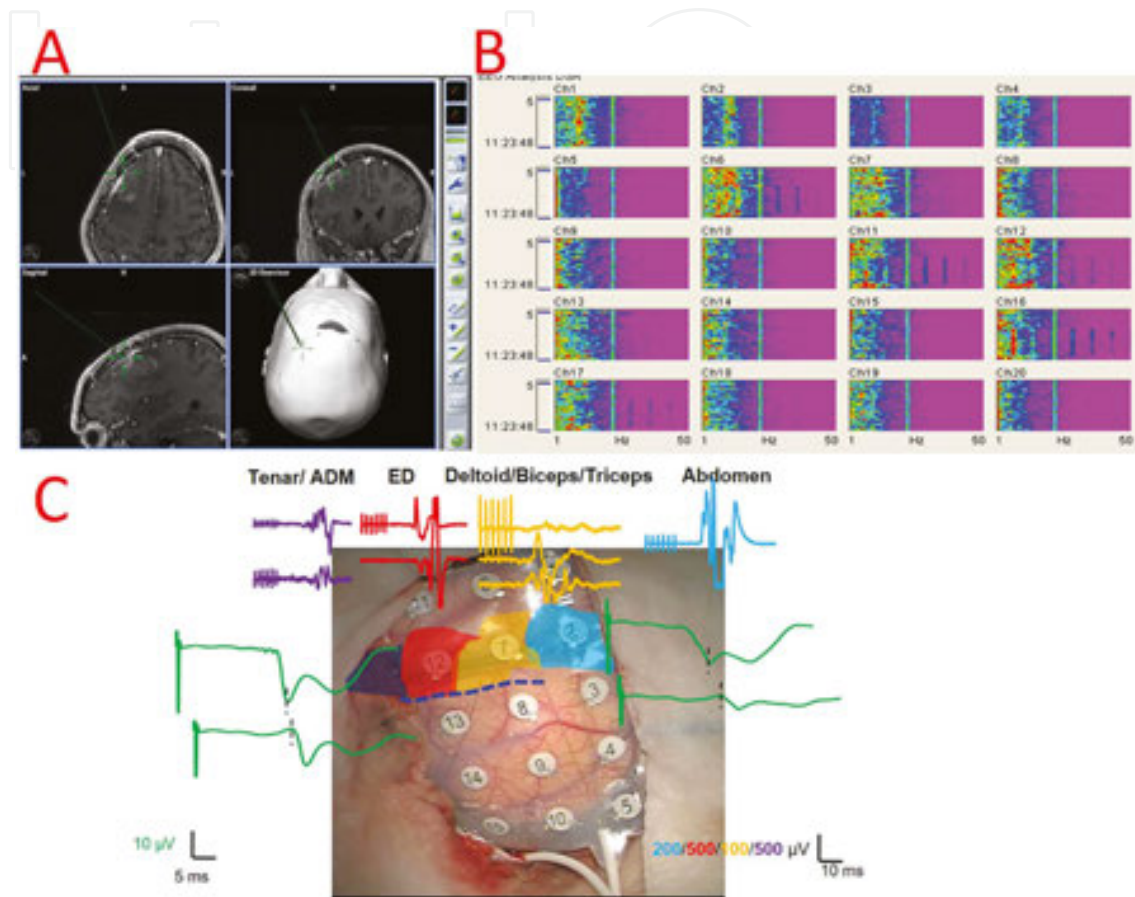


Figure 1. Cortical surgery in a patient with a left frontal glioma. (A) Neuronavigator showing coronal, frontal and sagittal views of left cortical tumour. (B) DSA of electrocorticography. For each electrode, there is a colour-coded plot showing the power spectral density for every frequency in the abscissa axis along the time shown in the ordinate axis. For electrodes 3–5, the power of all frequencies is lower than that for the rest of the grid. (C) Placement of the grid over the cortex with sensory and motor mapping. The coloured areas show the motor regions of the abdomen, arm, forearm and hand, and they correspond to the MEPs with the same colour. The dashed line in blue shows the area of the central sulcus, with the phase reversal illustrated in SSEPs in green.

4.1.3. Cortical language mapping

Locating the functional cortical regions related to language is the goal of intraoperative language mapping stimulation, which is performed during awake surgery. DCS is the technique of choice, as has been widely discussed in the previous section. Concerning this area of the cortex, we have provided additional information about the procedure employed for this type of surgery. The cortex is mapped every 5–10 mm, and positive stimulation sites responsible for language impairment are marked; the same technique is utilized during resection of

the tumour via subcortical stimulation. A series of language tasks is conducted by a trained neuropsychologist throughout the duration of the tumour resection.

Although the risk of intraoperative seizures related to DCS is low, it is a real possibility. Additionally, considering that the patients are awake, this complication seems to be a particularly undesirable effect, not only from the perspective of patient discomfort but also because it would interfere with mapping by post-ictal hyperpolarisation. Using ECoG in this type of surgery could prevent, by monitoring and identifying discharges, the occurrence of seizures (**Figure 2**).

The identification of language areas and their fibres is not as successful as the localization of the cortical white matter in the PMC. Sanai and Berger [54] successfully identified the language areas in 145 (58%) of 250 patients with gliomas. Regarding neurological outcome, temporary language deficits were observed in 22% of patients, whereas permanent language deficits were observed in only 1.6% of patients.

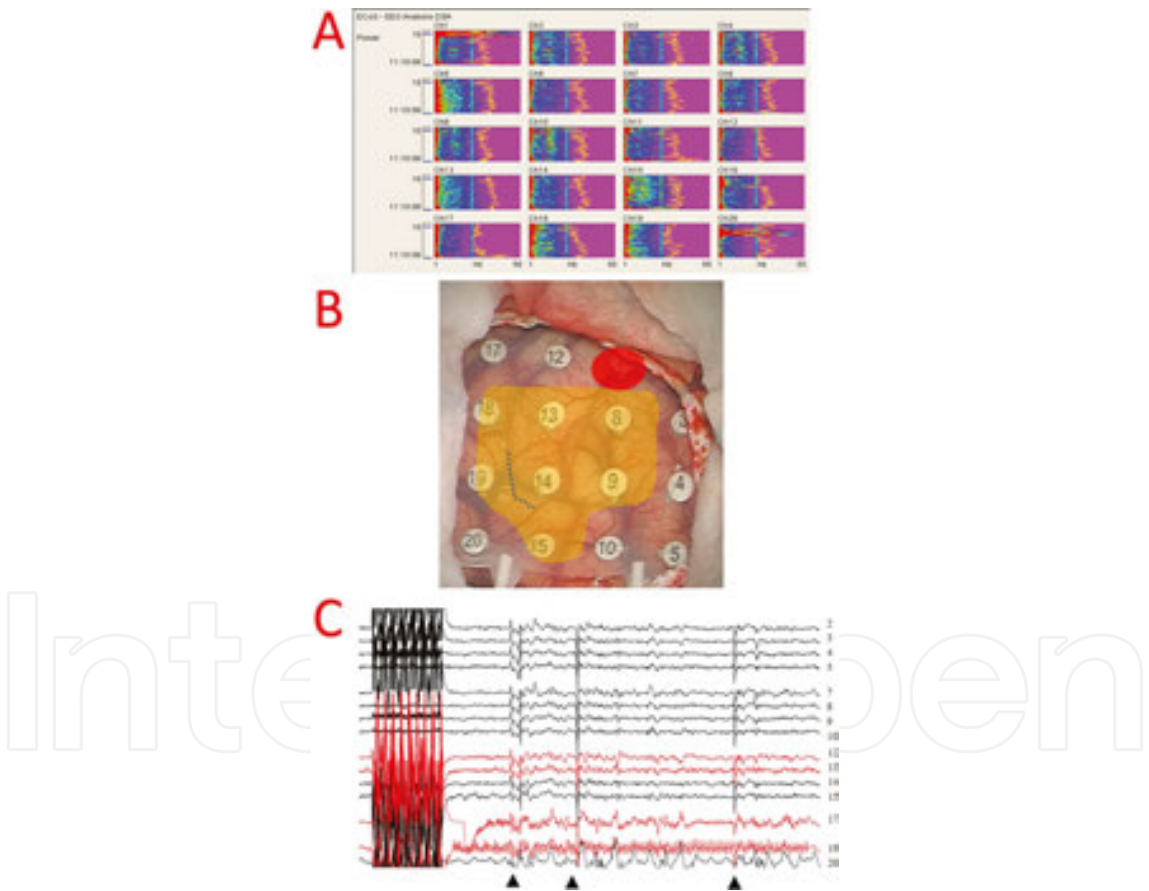


Figure 2. Mapping language in a patient with a cavernoma in Wernicke's area. (A) DSA showing a relative loss of cortical fast rhythms in electrodes 12 and 17. (B) Image showing the cortical mapping results. Red: Wernicke's area to 13 mA. Orange: region with negative results above 12 mA. The dotted line indicates the cortical incision for approaching. (C) Recording showing long-term after-discharges following stimulation by electrodes 18/1 -9 mA. The widespread artefact (arrowhead) corresponds to the moment at which cool serum was administered. The channels affected by after-discharges are shown in red.

4.1.4. Continuous IONM techniques

Following the determination of the relationship between the tumour and the PMC, continuous monitoring is performed via DCS using pairs of grid electrodes and employing high-frequency stimulation (**Figure 2B**).

It is accepted that the primary criterion for monitoring MEP in the setting of supratentorial surgery is an amplitude reduction of >50%. Temporary motor deficits have been linked to reversible declines in MEP amplitude of >50%, whereas irreversible declines and losses in MEP are predictors of permanent motor deficits [5]. Pastor et al. [5] described a study involving 34 patients who underwent surgical resection of glioma that was guided using 5-aminolevulinic acid (5-ALA) with no false-negative results. Nevertheless, postoperative neurological deficits without alterations in MEP are possible. This scenario, may be explained by secondary events such as postoperative oedema, haemorrhage and tumour resection from the supplementary motor area (SMA) [55].

An interesting issue for discussion is whether patients who harbour tumours in a region of the eloquent cortex other than the language area must be operated under general anaesthesia. As we have highlighted, there has recently been a renewed use of awake craniotomies [40,41]. In our experience, no new neurological deficits are observed in anaesthetized patients [5,20]. Accordingly, surgery near motor and somato-sensory cortical areas can be performed safely with the concomitant use of intensive neurophysiological mapping and monitoring [5]. Moreover, this combined approach is much more comfortable for both the patient and the surgical team.

When sensory function monitoring is also required, cSSEP are directly recorded from the grid. Monitoring the electrode entails the selection of higher amplitude responses for N1/P1/N2 potentials.

4.2. Semi-oval centre surgery

4.2.1. Anatomical and surgical considerations

The white matter in each hemisphere located between the cerebral cortex and deep nuclei together has a semi-oval shape. It consists of an association, a commissural and projecting cortical fibres. It contains, among others, the corticospinal, thalamo-cortical (containing somato-sensory and visual projections) or corticobulbar tracts.

In these patients, surgical removal of the tumour is performed far away from the motor cortex but near the subcortical structures such as the basal ganglia and the IC.

4.2.2. Particularities of IONM

As stated, DCS in these cases is usually precluded, and TES is the technique of choice. Because there is a risk of stimulation beneath the lesion, hemispheric TES must be performed. The

somato-sensory pathway should also be monitored through the SSEP and, in a number of cases, even the VEP.

An interesting point is that warning criteria for the motor response may occur segmentally in isolated muscles. As previously described, these segmented changes are the most commonly observed changes [5] (**Figure 3**).

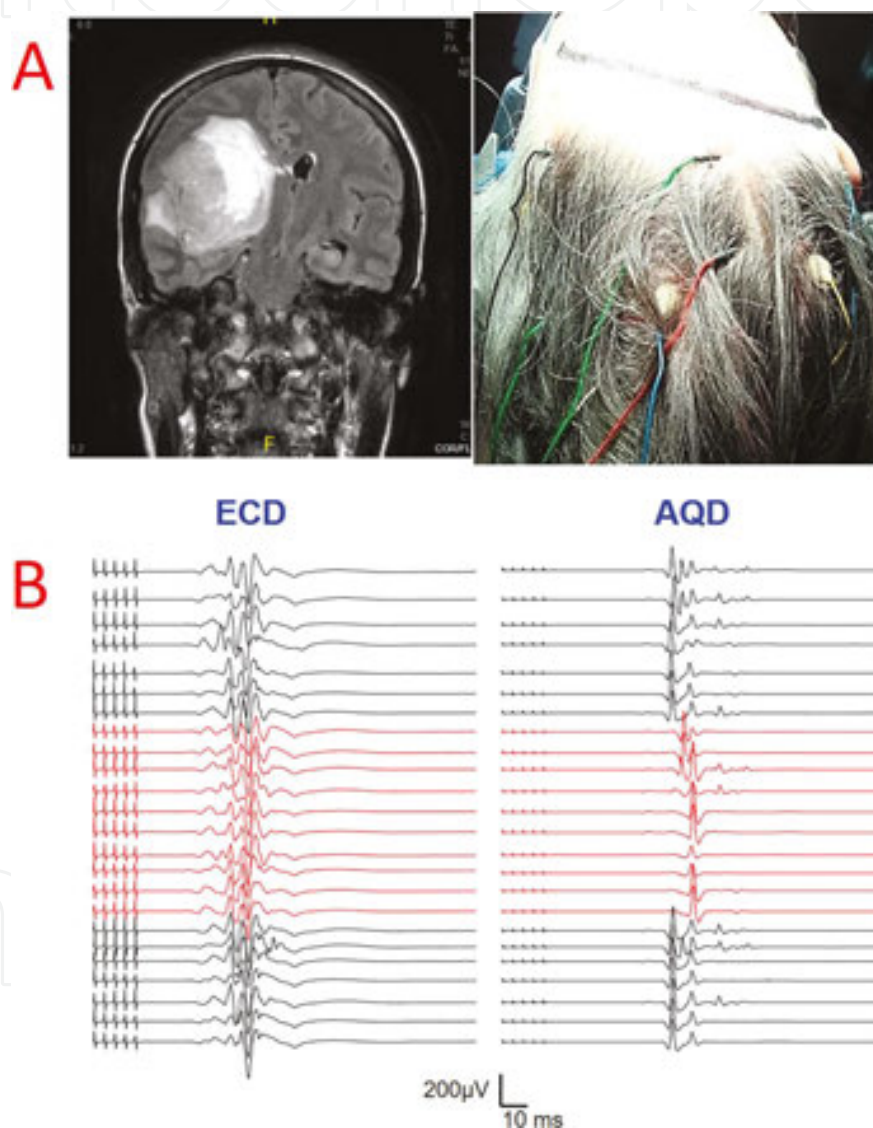


Figure 3. Monitoring of a patient with a tumour in the right semi-oval centre. (A) Frontal MRI before surgery, and an image indicating the placement of the electrodes for TES (B) MEPs monitoring of the upper limb at the moment a reversible segmental alteration occurred in the MEPs of the hand is shown in red.

Subcortical electrical stimulation is an important technique for the identification of the corticospinal tract [35]. The most accepted technique to date, in terms of effectiveness with

respect to subcortical activation with a lower motor threshold (MT), is monopolar cathodal stimulation [39].

In general, a linear relationship is considered to be present among the five monopolar 0.2–0.5 ms pulses and the 3–4 ms ISI, as well as a threshold of 1 mA of stimulation, which is equivalent to approximately 1 mm of distance from the CST [56]. Some studies have attempted to determine the lowest intensity of stimulation allowed before resection should be terminated to prevent injury to the CST. This safety margin has not been standardized and has been defined as 6 mA in some studies, whereas other studies have suggested that both significant signal changes in MEP and permanent motor deficits do not occur below a threshold of 1–3 mA [57]. Regardless, it seems reasonable to follow these motor threshold safety margins provided that no alterations in MEP are observed during continuous motor monitoring; otherwise, the resection must be stopped immediately.

VEP are needed when the tumour is located in the occipito-parietal region due to the risk of injury to the thalamo-cortical projections to the visual cortex. In fact, we noted that up to 50% of patients monitored by VEP during semi-oval centre surgery displayed warning criteria [5].

4.3. Cranial base and anterior fossa surgery

4.3.1. Anatomical and surgical considerations

In general terms, the skull base consists of five bones: ethmoid, sphenoid, occipital, paired frontal and paired temporal bones. The anterior limit of the anterior fossa is the posterior wall of the frontal sinus. The anterior clinoid processes and the planum sphenoidale, which forms the roof of the sphenoid sinus, mark the posterior limit. The frontal bone forms the lateral boundaries.

The posterior aspect includes the optic canal, the superior orbital fissure (SOF), and the inferior orbital fissure (IOF). The SOF conveys the oculomotor (CN III), trochlear (CN IV), abducens (CN VI), ophthalmic nerves and V1, as well as the ophthalmic veins. An understanding of the relationship of the tumour to vital structures is essential to preserve these structures and to minimize morbidity associated with treatment.

The greater wing of the sphenoid forms the anterior limit of the middle skull base. The posterior limit is the clivus. The SOF, foramen rotundum, foramen ovale, and foramen spinosum lie in an anteroposterior and medio-lateral plane [58].

A significant structure that can be found lateral to the sphenoid sinus is the cavernous sinus. Along its lateral wall runs the internal carotid artery (ICA), CNs III, IV, V, and VI and the maxillary nerve (CN V2). The facial nerve (CN VII) and vestibule cochlear nerve (CN VIII) originate from the caudal pons. They course through the subarachnoid space and enter the porus acusticus and IAC.

With a suitable understanding of skull base anatomy and surgical access, diverse IONM techniques have been steadily improving the outcome of surgery, both in terms of disease-free survival and morbidity associated with treatment.

4.3.2. Particularities of IONM

According to the anatomy of the anterior and middle fosses, the main structures to monitor are the CNs. Therefore, the standard technique is recording fEMG to identify different discharge patterns related to either irritative or injury activity. Several criteria have been advanced to identify patterns that predict transitory or permanent nerve injury, but these criteria lack uniformity, and the correlation with the postoperative outcome is often unsatisfactory [59]. sEMG is a functional technique that is also essential during these types of surgeries.

Various techniques have been used for the placement and recording of the superior rectus muscle for CN III and the lateral rectus muscle for CN VI. These include the manual placement of bipolar needles, or single-shafted bipolar needles using an orbital ultrasound [60] or image guidance [61].

Corticobulbar tract (CBT) MEP monitoring is a neurophysiological technique that has improved greatly over time and is increasingly used in brainstem tumour surgery. Although the correlation between the intraoperative corticobulbar response and the postoperative outcome may not be completely accurate due to the possibility of false-positive and false-negative responses [62], experience seems to indicate that the complete disappearance of a corticobulbar MEP usually correlates with a severe, mostly irreversible, postoperative deficit. Conversely, when the corticobulbar MEP remains unchanged at the end of surgery, a transient deficit may not be prevented, but the great majority of these patients have recovered their preoperative status at the time of follow-up [59].

The vestibulocochlear nerve (CN VIII) and, to a greater extent, the auditory pathways as they pass through the brainstem are especially at risk during cerebellopontine angle (CPA), posterior/middle fossa or brainstem surgery. CN VIII can be damaged by several mechanisms, from vascular compromise to mechanical injury by stretch, compression, dissection and heat injury. Additionally, the cochlea itself can be significantly damaged during temporal bone drilling, by noise, mechanical destruction, or infarction, and due to rupture, occlusion or vasospasm of the internal auditory artery. CN VIII monitoring can be successfully achieved by live recording of the function of one of its parts, the cochlear or auditory nerve (AN), using the BAEPs [63].

The necessity to protect the optic tract is not uncommon in this setting, and thus intraoperative monitoring of the VEP is mandatory. Although such monitoring techniques were previously not well-established, high rates of feasibility have recently been reported in a number of publications, and stable VEPs have been associated with good postoperative visual function [30].

From a neurophysiological perspective the ICA emits at the supraclinoid segment, an important collateral branch: the posterior communicating. This artery is of paramount importance because in addition to providing branches to the optic chiasm and oculomotor

nerve, it is also responsible for irrigating the thalamus. Therefore, in this type of surgery, the MEP and SSEP must be monitored.

4.4. Posterior fossa surgery

4.4.1. Anatomical and surgical considerations

The posterior cranial fossa is the deepest and most capacious fossa of the skull base. It contains the cerebellum, pons and medulla oblongata. Recent advances in diagnostic and surgical techniques have increased the accessibility of this region to surgery, providing new and neurologically safer treatments for these patients [64].

Tumours of the skull base show a tendency to be large in size, they are critical brain lesions because they extend inside and around the brainstem, placing not only the CNs and/or their motor nuclei at risk of injury but also the motor and somato-sensory pathways.

The particular approach is determined not simply by the location of the lesion but largely by the path that allows access to the lesion while minimally disturbing critical structures. The surgeon must select a cranial approach that provides line-of-sight access to the lesion while avoiding excessive manipulation; however, this achievement is not simple due to the high density of critical structures in the brainstem, and even a mild manoeuvre can result in the injury to the delicate nuclei, tracts, or nerves.

4.4.2. Particularities of IONM

There is a critically high potential risk of damage to neural structures during the resection of these tumours, and therefore IONM is an indispensable tool for posterior fossa surgery. The decision to monitor certain structures depends on both the anatomical location of the tumour and the surgical approach selected by the surgeon.

In general, IONM consists of three procedures (**Figure 4**): (i) brainstem mapping (BSM), (ii) CBT-MEP monitoring and (iii) monitoring of ascending and descending long pathways and transverse auditory radiations. BSM is a neurophysiological technique that is used to locate cranial nerves and their motor nuclei on the floor of the fourth ventricle [65] through sEMG. During resection of brainstem tumours involving incision of the fourth ventricle, the facial colliculus (intramedullary roots of the CN VII around the abducens nucleus) and motor nuclei of the lower CNs nucleus are especially prone to injury because the tumour often grossly distorts the brainstem anatomy, and the normal landmarks on the floor of the fourth ventricle are missing. If the neurosurgeon cannot identify these landmarks, he will not be able to make a safe incision. Hence, the mapping assists surgeons in locating these important structures.

The recording technique used for targeted muscles is the same as discussed previously, and the standard set of muscles used to record muscle activity are as follows: the orbicularis oris, orbicularis oculi, and mentalis for the VII cranial motor nucleus (CMN), the posterior

pharyngeal wall for CMN IX, the cricothyroid or vocalis muscle for X and the intrinsic tongue muscles for CMN XII. Electrical stimulation of the floor of the fourth ventricle is delivered through a monopolar hand-held probe using the same parameters described above for the stimulated EMG technique. It is important to stress that during this procedure, the threshold intensity is essential for proper localization of the CMN.

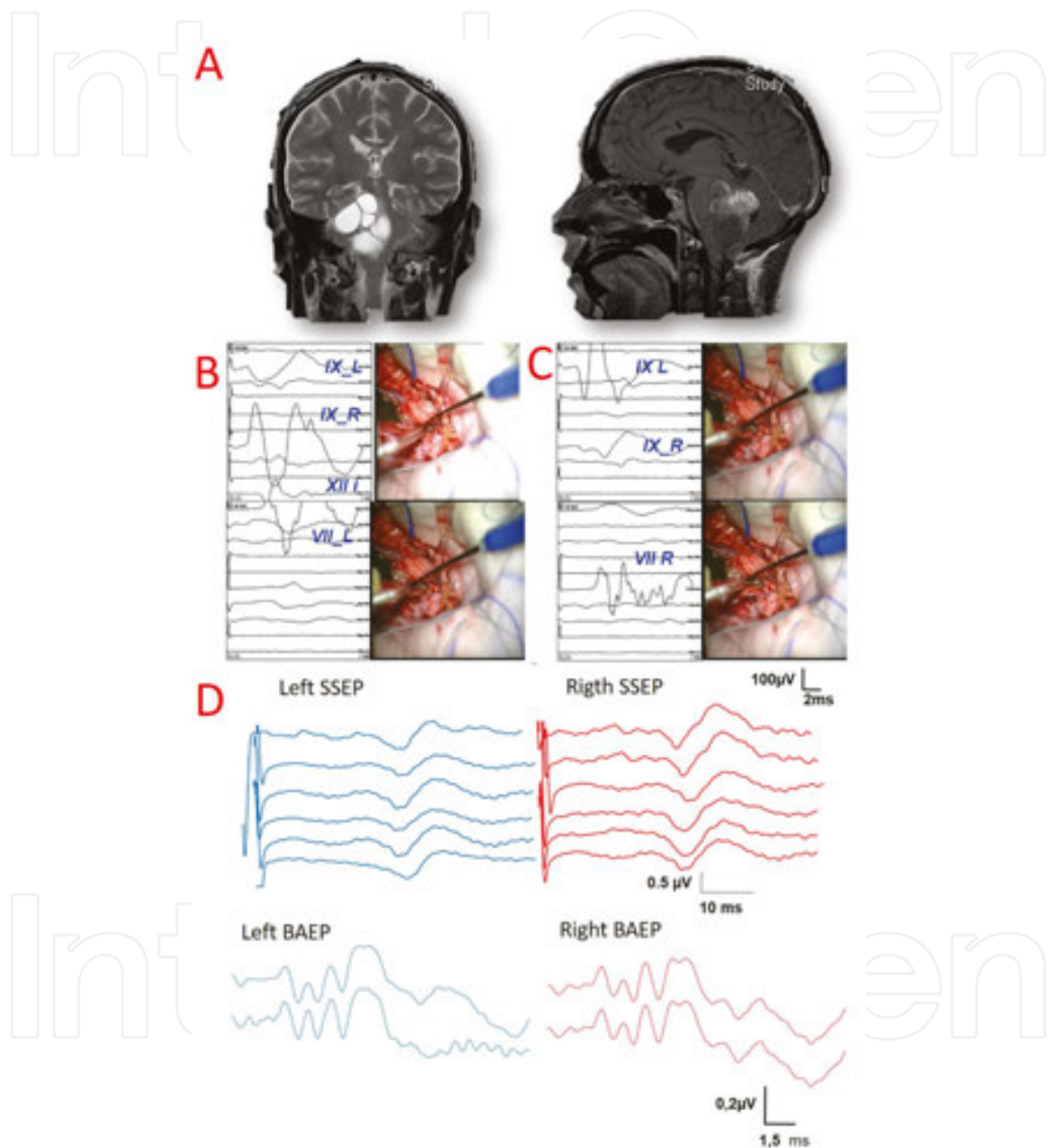


Figure 4. Brain stem mapping in a patient with a tumour locate on the floor of the fourth ventricle. (A) Frontal and sagittal MRI before surgery. (B) Stimulated EMG during identification of the right CN IX (above) and the left CN VII (below). (C) Identification of the left CN IX (above) and the right CN VII (below). (D) Brain stem monitoring comprising SSEPs (top) and BAEPs (bottom).

This technique is very valuable because although there has been a recent advancement of neuroimaging techniques, BSM remains the only way to reveal the surgical anatomy in the

operative field [65,66]. We must not forget that it is a functional localization technique and can be performed only intermittently. Moreover, discrepancies between the final intraoperative recordings and postoperative function may occur. This situation can be explained by an injury to the afferent fibres during resection, in which the lower motoneuron is still intact or a nuclear injury results from a stimulation-elicited response activating the intramedullary root. Both instances can produce false-negative results [59,65]. A similar situation may occur during monitoring of the IX and X cranial nerve, difficulties in coughing or swallowing can occur postoperatively despite positive and normal CMAP recordings at the end of surgery. This phenomenon may be explained by BSM responses reflecting only the functional preservation of the efferent arc of these reflexes, but no information has been provided regarding the integrity of the sensory afferents.

For lesions that compress the brainstem ventrally or laterally, BSM provides a minimal contribution. In these cases, CBT-MEP monitoring is the neurophysiological technique indicated to monitor the entire CMN motor pathway from the cerebral cortex to the targeted muscle [59]. Likewise, when motor CN monitoring is considered, as mentioned previously, recording of fEMG with the identification of different discharge patterns will allow the identification of injury activity.

Electrical stimulation must be performed with extreme care due to the presence of vital structures within a very small space. Therefore, the frequency should be approximately 2.45 Hz, and the pulse width should be maintained as low as possible to provide specific stimulation and avoid current spreading. However, a compromise between current intensity and pulse width is essential, and therefore 100 μ s and a current lower than 2 mA should be desirable.

Regarding the remaining critical neural structures, the ascending sensory pathways are monitored by BAEPs as well as SSEP, which together can be used to monitor approximately 20% of the brainstem [59]. Information concerning the descending motor pathways is provided by the use of MEP.

4.5. Spinal cord surgery

4.5.1. Anatomical and surgical considerations

Intramedullary spinal cord tumours (ISCTs) comprise 15% of intradural spinal tumours in adults [67]. Tumours of glial origin represent approximately 68% of ISCTs, most of which are ependymomas or astrocytomas [68].

Microsurgery plays a central role in the treatment of these tumours, and the main goal is the complete surgical removal. This aim is limited because preservation of spinal cord function with minimum neurological morbidity it is also desired, representing another challenge of these surgeries.

Microsurgical resection and the surgical strategy may vary, depending on the histological type of each tumour. However overall, there are well-defined steps during the surgical approach to ISCTs: opening of the posterior median sulcus, exposure and initial tumour debulking with separation between the sidewall of the tumour and spinal cord tissue and complete removal

of the tumour, which requires the dissection and coagulation of the vascular afferences from the anterior spinal artery.

4.5.2. Particularities of IONM

During the resection of ISCT, lesions in neural structures can inadvertently occur, potentially creating severe neurological deficits. IONM of the spinal cord plays an important role in facilitating the resection of these tumours [69].

As previously described, an effective strategy could be to adapt IONM to the steps of the surgery to protect the somato-sensory and motor pathways [70]. Therefore, monitoring with SSEP and MEP is indicated.

Additionally, for spinal cord surgery, D wave recording is widely used and recommended. In well-documented studies of more than 100 ISCT surgeries, a preserved D wave up to 50% of the original amplitude, with a complete loss of muscle MEPs, has been shown to result in only transient paraplegia [71].

Although it also has disadvantages, we generally consider that under those circumstances in which the mechanism of injury to the spinal cord is purely ischemic, D wave monitoring does not add a significantly value to muscle MEP monitoring. Grey matter is more sensitive than white matter to cord ischemia, and both clinical and experimental data suggest that both peripheral and myogenic MEP disappear earlier than the D wave when spinal cord vascularisation is acutely compromised [72]. Regarding this issue, it seems logical to postulate that the nerve structures most likely to be affected during an ischemic alteration in ISCT surgery are the anterior horns (AH).

It is important to note that previous observations of EMG may improve the reliability of IONM during spinal cord surgery [73, 74]. Skinner and Transfeldt [75] have reported experience with EMG for monitoring ISCT in 14 patients. They described segmental and suprasegmental elicitation of neurotonic discharges that could anticipate the loss of MEP and predict a postoperative motor deficit. Moreover, some studies have associated spinal cord mechanical and thermal injury with EMG activity and motor conduction block (MEP loss) in animals [75, 76].

In our experience, we can define three different phases of the surgical approach to ISCTs that must be followed by the neurophysiological techniques used (**Figure 5**). (i) Phase A: during posterior median sulcus opening, it is important to protect the dorsal columns by monitoring the somato-sensory evoked potentials (SSEPs). (ii) Phase B: working at the cleavage plane, monitoring of motor evoked potentials (MEPs) is mandatory, mainly to protect the cortico-spinal tract in the lateral cords during the separation between the sidewall of the tumour and the spinal cord tissue. (iii) Phase C: the final phase of complete tumour removal during which, as previously mentioned, the anterior vascular supply is threatened and consequently there is a certain risk of injuring the AH. Thus, fEMG is critical during this phase.

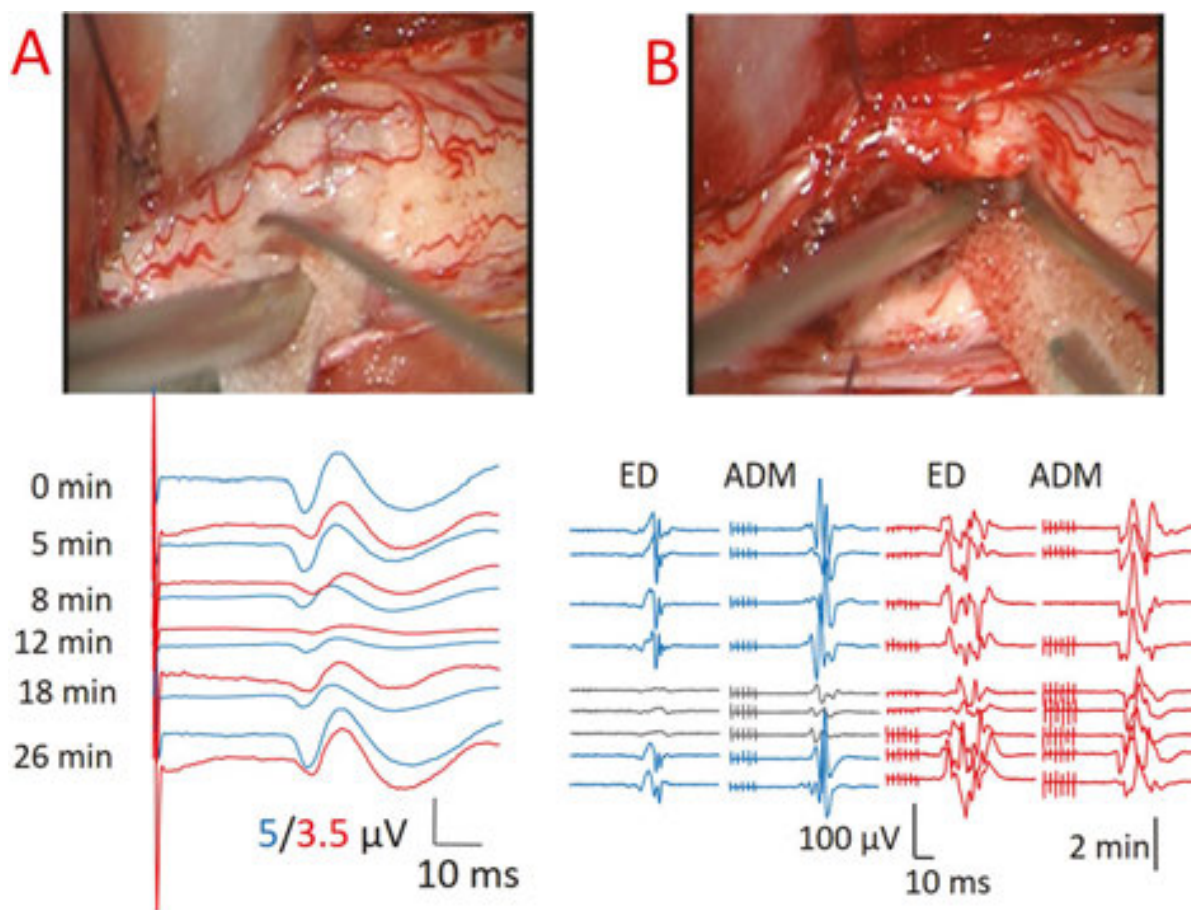


Figure 5. Two different times during monitoring of ISCT surgery. (A) (Top) Microphotograph during incision of the dorsal median raphe. (Bottom) SSEPs for the left (blue) and right (red) sides. Times are shown on the left. Zero min indicates opening of the dura. Between 8 and 18 min, both SSEPs, displayed a decrease in amplitude and an increase in latency (right SSEPs at 8 min). (B) (Top) Microphotograph during tumour removal from the lateral walls. (Bottom) MEPs for the left (blue) and right (red) sides. Grey lines indicate significant changes in MEPs. Times are shown on the left.

5. Conclusion

IONM is a cheap and effective method for reducing the risk of permanent postoperative deficits in many different operations in which NS is undergoing manipulation. It provides real-time monitoring of function to an extent that makes it superior to imaging methods that provide information about structures but not about the physiological state of the patient.

Intraoperative neurophysiology must be conducted by teams of experts that include a clinical neurophysiologist with a thorough understanding of neuroscience and the pathophysiology of the disorders that are to be treated.

Therefore, we can conclude without exaggerating that IONM and mapping are some of the techniques with more relevance during recent decades for oncological neurosurgery. The

widespread use and improvement of these techniques have allowed better functional post-surgical outcomes, increasing life expectancy together with better functionality.

However, different topics have been debated that must be clarified. Among these are parameters for stimulation, indications regarding awake versus anaesthetized craniotomy, different types of DCS, and a better definition of the warning criteria or the prognostic utility of some surgeries. Future investigations will clarify most of these features and will undoubtedly contribute to improve outcomes in neuro-oncology.

Acknowledgements

This work was supported by a grant from the Plan Nacional de Investigación Científica, Desarrollo e Innovación Tecnológica (I+D+I), Instituto de Salud Carlos III, Subdirección General de Evaluación y Fomento de la Investigación PI12/02839 and partially supported by F.E.D.E.R.

Author details

Lorena Vega-Zelaya^{1,3}, Rafael G. Sola² and Jesús Pastor^{1,3*}

*Address all correspondence to: jesus.pastor@salud.madrid.org

1 Clinical Neurophysiology, Hospital Universitario de la Princesa, Madrid, Spain

2 Neurosurgery, Hospital Universitario de la Princesa, Madrid, Spain

3 Biomedical Research Institute, Hospital Universitario de la Princesa, Madrid, Spain

References

- [1] Stummer W, Reulen HJ, Novotny A, Stepp H, Tonn JC. Fluorescence-guided resections of malignant gliomas—an overview. *Acta Neurochir Suppl.* 2003; 88: 9–12.
- [2] Stummer W, Pichlmeier U, Meinel T, Wiestler OD, Zanella F, Reulen HJ. Fluorescence-guided surgery with 5-aminolevulinic acid for resection of malignant glioma: a randomized controlled multicenter phase III trial. *Lancet Oncol.* 2006; 7: 392–401.
- [3] Thakkar JP, Dolecek TA, Horbinski C, Ostrom QT, Lightner DD, Barnholtz-Sloan JS, et al. Epidemiologic and molecular prognostic review of glioblastoma. *Cancer Epidemiol Biomarkers Prev.* 2014 Oct; 23(10): 1985–1996. doi: 10.1158/1055-9965.

- [4] Perry J, Okamoto M, Guiou M, Shirai K, Errett A, Chakravarti A. Novel therapies in glioblastoma. *Neurol Res Int*. 2012; 428565. <http://dx.doi.org/10.1155/2012/428565>.
- [5] Pastor J, Vega-Zelaya L, Pulido P, Garnés-Camarena O, Abreu A, Sola RG. Role of intraoperative neurophysiological monitoring during fluorescence-guided resection surgery. *Acta Neurochir (Wien)*. 2013; 155(12): 2201–2213.
- [6] Vega-Zelaya L, Pastor J. Intraoperative neurophysiological monitoring techniques for the resection of malignant brain tumors located in eloquent cortical areas. *Austin J Neurosurg*. 2015; 2(4): 1038.
- [7] Møller AR. Introduction. *Intraoperative Neurophysiological Monitoring*. 2nd edition. Humana Press, Totowa, 2006; pp: 1–8.
- [8] Krieg SM, Shiban E, Droese D, Gempt J, Buchmann N, Pape H, et al. Predictive value and safety of intraoperative neurophysiological monitoring with motor evoked potentials in glioma surgery. *Neurosurgery*. 2012; 70(5): 1060–1071.
- [9] Pastor J. Conceptos de Neurofisiología en Neurocirugía Funcional, in Navarrete EG y Sola RG (ed): *Neurocirugía Funcional y Estereotáctica*. Barcelona: Viguera Editores, 2011, pp. 17–27.
- [10] Pastor J. Quirófano: Neurofisiología intraoperatoria. En: *Cirugía raquimedular*. Eds. C Botella, RG Sola, A Isla. Viguera Editores, Barcelona, 2014; pp. 157–170 ISBN 978-84-92931-26-2
- [11] Koester J, Siegelbaum SA. Propagated signalling: the action potential. In: *Principles of Neural Sciences*, 5th edition, Eds: Kandel ER, Schwartz JH, Jessell TM, Siegelbaum SA, Hudspeth AJ. Elsevier, New York, 2013; pp. 148–176.
- [12] Pastor J. Biophysical foundations of neural activity. *Rev Neurol*. 2000; 30(8): 741–755.
- [13] Pastor J: Neurofisiología Intraoperatoria, in Navarrete EG y Sola RG (ed): *Neurocirugía Funcional y Estereotáctica*. Barcelona: Viguera Editores, 2011, pp. 589–604
- [14] Nunez P, Srinivasan R. The physics-EEG interface. In: *Electric Fields of the Brain*, 2nd Edition. Oxford University Press, New York, 2006; pp. 3–55.
- [15] Stevens JC. Somatosensory evoked potentials. In: *Clinical Neurophysiology*, 2nd ed., Ed: Daube JR. Oxford University Press; 2002. pp. 181–203.
- [16] Nuwer MR, Comi C, Emerson R, Fuglsang-Frederiksen A, Guérit J-M, Hinrichs H, et al. IFCN standards for digital recording of clinical EEG. *Electroencephalogr Clin Neurophysiol*. 1998; 106: 259–261.
- [17] Finnigan S, Wong A, Read S. Defining abnormal slow EEG activity in acute ischaemic stroke: delta/alpha ratio as an optimal QEEG index. *Clin Neurophysiol*. 2016; 127(2): 1452–1459. doi: 10.1016/j.clinph.2015.07.014. Epub 2015 Jul 22.

- [18] Smith DJ, Howie MB. General anesthesia: intravenous and inhalational agents. In: *Modern Pharmacology with Clinical Applications*, 6th ed. Eds: Craig Ch R, Stitzel RE. Lippincott, Williams, Wilkins; Philadelphia; 2003; pp. 291–309.
- [19] Vega-Zelaya L, Torres CV, Garnes-Camarena O, Ortega GJ, García-Navarrete E, Navas M, et al. Electrocorticographic evidence and surgical implications of different physiopathologic subtypes of temporal epilepsy. *Clin Neurophysiol*. 2014; 125: 2349–2357.
- [20] Pastor J, Pulido P, Sola RG. Neurophysiological assisted transsulcal approach to a high grade glioma without affect neither motor nor somatosensory function. *Rev Neurol*. 2013; 56(7): 370–374.
- [21] Van Drongelen W. Noise. In: *Signal Processing for Neuroscientists*. Amsterdam, Elsevier, 2004; pp. 34–53.
- [22] Pastor J. Diagnóstico funcional: Neurofisiología. En: *Cirugía raquimedular*. Eds. C Botella, RG Sola, A Isla. Viguera Editores, Barcelona; pp. 99–114. ISBN 978-84-92931-26-2, 2014.
- [23] Pastor J. Quirófano: Neurofisiología intraoperatoria. En: *Cirugía raquimedular*. Eds. C Botella, RG Sola, A Isla. Viguera Editores, Barcelona; pp. 157–170. ISBN 978-84-92931-26-2, 2014
- [24] Pastor J, Reina MA. Fisiología del nervio periférico normal y patológico. In Wikinski JA, Reina MA, Bollini C, De Andrés JA, Salas X, Salgueiro C, et al, eds. *Complicaciones neurológicas asociadas con la anestesia regional periférica y central*. Buenos Aires: Ed. Panamericana; 2011. p. 87–103.
- [25] Mauguière F. Somatosensory evoked potentials: normal responses, abnormal waveforms and clinical applications in neurological diseases. In: *EEG, basic principles, clinical applications and related fields*, Eds. Niedermeyer E, Lopes da Silva A.. Baltimore: Lippincott, Williams & Wilkins; 1993. pp. 1014–1058.
- [26] Sala F, Lanteri P. Brain surgery in motor areas: the invaluable assistance of intraoperative neurophysiological monitoring. *J Neurosurg Sci*. 2003; 47: 79–88.
- [27] Liégeois-Chauvel C, Trécuchon-Dafonseca A, Régis J, Marquis P, Chauvel P. Auditory evoked potentials in the definition of eloquent cortical areas. In: *Presurgical Assessment of the Epilepsies with Clinical Neurophysiology and Functional Imaging*. Eds: Rosenow F, Lüders HO. Elsevier, Amsterdam, 2004; 305–316.
- [28] Wiedemayer H, Fauser B, Armbruster W, Gasser T, Stolke D. Visual evoked potentials for intraoperative neurophysiologic monitoring using total intravenous anesthesia. *J Neurosurg Anesthesiol*. 2003; 15: 19–24.
- [29] Ota T, Kawai K, Kamada K, Kin T, Saito N. Intraoperative monitoring of cortically recorded visual response for posterior visual pathway. *J Neurosurg*. 2010; 112: 285–294.

- [30] Kodama K, Goto T, Sato A, Sakai K, Tanaka Y, Hongo K. Standard and limitation of intraoperative monitoring of the visual evoked potential. *Acta Neurochirurgica*. 2010; 152: 643–648. doi:10.1007/s00701010-0600-2.
- [31] Torres Díaz C, Pastor J, Rocio E, Sola RG. Continuous monitoring of cortical visual evoked potentials by means of subdural electrodes in surgery on the posterior optic pathway. A case report and review of the literature. *Rev Neurol*. 2012; 55(6): 343–348.
- [32] Deletis V. Intraoperative Neurophysiology and methodologies used to monitor the functional integrity of the motor system. In: *Neurophysiology in Neurosurgery*. Eds: Deletis V, Shils JL. Academic Press, London, 2002; pp: 25–54.
- [33] Taniguchi M, Cedzich C, Schramm J. Modification of cortical stimulation for motor evoked potentials under general anesthesia: technical description. *Neurosurgery*. 1993; 32: 219–226.
- [34] Rothwell J, Burke D, Hicks R, Stephen J, Woodforth I, Crawford M. Transcranial electrical stimulation of the motor cortex in man: further evidence for the site of activation. *J Physiol*. 1994; 481: 243–250.
- [35] Szelényi A, Kothbauer KF, Deletis V. Transcranial electric stimulation for intraoperative motor evoked potential monitoring: stimulation parameters and electrode montages. *Clin Neurophysiol*. 2007; 118: 1586–1595.
- [36] Pastor J, Perla-Perla P, Pulido-Rivas P, Sola RG. Hemispheric transcranial electrical stimulation: clinical results. *Rev Neurol*. 2010; 51: 65–71.
- [37] Chang EF, Clark A, Smith JS, Polley MY, Chang SM, Barbaro NM, et al. Functional mapping-guided resection of low-grade gliomas in eloquent areas of the brain: improvement of long-term survival. Clinical article. *J Neurosurg*. 2011; 114(3): 566–573.
- [38] De Witt Hamer PC, Robles SG, Zwinderman AH, Duffau H, Berger MS. Impact of intraoperative stimulation brain mapping on glioma surgery outcome: a meta-analysis. *J Clin Oncol*. 2012; 30: 2559–2565.
- [39] Merrill DR, Bikson M, Jefferys JGR. Electrical stimulation of excitable tissue: design of efficacious and safe protocols. *J Neurosci Methods*. 2005; 141: 171–198.
- [40] Peruzzi P, Puente E, Bergese S, Chiocca EA. Intraoperative MRI (ioMRI) in the setting of awake craniotomies for supratentorial glioma resection. *Acta Neurochir*. 2011; Suppl 109: 43–48.
- [41] Duffau H, Capelle L, Sichez J, Faillot T, Abdenmour L, Law Koune JD, et al. Intraoperative direct electrical stimulations of the central nervous system: the Salpêtrier experience with 60 patients. *Acta Neurochir (Wien)*. 1999; 141: 1157–1167.
- [42] Boetto J, Bertram L, Moulinié G, Herbet G, Moritz-Gasser S, Duffau H. low rate of intraoperative seizures during awake craniotomy in a prospective cohort with 374

- supratentorial brain lesions: electrocorticography is not mandatory. *World Neurosurg.* 2015 Dec; 84(6): 1838–1844. doi: 10.1016/j.wneu.2015.07.075.
- [43] Li T, Bai H, Wang G, Wang W, Lin J, Gao H, et al. Glioma localization and excision using direct electrical stimulation for language mapping during awake surgery. *Exp Ther Med.* 2015 May; 9(5): 1962–1966.
- [44] Hervey-Jumper SL, Li J, Lau D, Molinaro AM, Perry DW, Meng L, et al. Awake craniotomy to maximize glioma resection: methods and technical nuances over a 27-year period. *J Neurosurg.* 2015; 123(2): 325–339. doi: 10.3171/2014.10.JNS141520.
- [45] Milian ML, Tatagiba M, Feigl GC. Patient response to awake craniotomy — a summary overview. *Acta Neurochir (Wien).* 2014; 156(6): 1063–1070. doi: 10.1007/s00701-014-2038-4.
- [46] Delion M, Terminassian A, Lehouste T, Aubin G, Malka J, N'Guyen S, et al. specificities of awake craniotomy and brain mapping in children for resection of supratentorial tumors in the language area. *World Neurosurg.* 2015; 84(6): 1645–1652. doi: 10.1016/j.wneu.2015.06.073.
- [47] Bello L, Fava E, Cascaceli G, Bertani G, Carrabba G, Papagno C, et al. Intraoperative mapping for tumor resection. *Neuroimag Clin N Am.* 2009; 19: 597–614.
- [48] Bertani G, Fava E, Casaceli G, Carrabba G, Casarotti A, Papagno C, et al. Intraoperative mapping and monitoring of brain functions for the resection of low-grade gliomas: technical considerations. *Neurosurg Focus.* 2009; 27(4): E4.
- [49] Lwu S, Hamilton MG, Forsyth PA, Cairncross JG, Parney IF. Use of peri-operative anti-epileptic drugs in patients with newly diagnosed high grade malignant glioma: a single center experience. *J Neurooncol.* 2010 Feb; 96(3): 403–408.
- [50] Simon MV, Sheth SA, Eckhardt CA, Kilbride RD, Braver D, Williams Z, et al. Phase reversal technique decreases cortical stimulation time during motor mapping. *J Clin Neurosci.* 2014; 21: 1011–1017.
- [51] Porter R, Lemon R. Corticospinal function and voluntary movement. Oxford: Oxford University Press; 1993.
- [52] Cuadrado ML, Arias JA, Palomar MA, Linares R. The pyramidal tract: new pathways. *Rev Neurol.* 2001; 32(12): 1151–1158.
- [53] Schott GD. Penfield's homunculus: a note on cerebral cartography. *J Neurol Neurosurg Psychiatry.* 1993; 56: 329–333.
- [54] Sanai N, Berger MS. Intraoperative stimulation techniques for functional pathway preservation and glioma resection. *Neurosurg Focus.* 2010; 28: E1.
- [55] Krieg SM, Schäffner M, Shiban E, Droese D, Obermüller T, Gempt J, et al. Reliability of intraoperative neurophysiological monitoring using motor evoked potentials during

resection of metastases in motor-eloquent brain regions. *J Neurosurg.* 2013; 118: 1269–1278.

- [56] Kamada K, Todo T, Ota T, Ino K, Masutani Y, Aoki S, et al. The motor-evoked potential threshold evaluated by tractography and electrical stimulation. *J Neurosurg.* 2009; 111(4): 785–795.
- [57] Seidel K, Beck J, Stieglitz L, Schucht P, Raabe A. The warning-sign hierarchy between quantitative subcortical motor mapping and continuous motor evoked potential monitoring during resection of supratentorial brain tumors. *J Neurosurg.* 2013; 118(2): 287–296.
- [58] Lang DA. Surgery of the cranial base. In: *Surgery of Cranial Base Tumors*, Eds.: Sekhar LN, Janecka IP. New York, Raven Press, 1993; pp. 93–121.
- [59] Sala F, Manganotti P, Tramontano V, Bricolo A, Gerosa M. Monitoring of motor pathways during brain stem surgery: what we have achieved and what we still miss? *Neurophysiol Clin.* 2007; 37(6): 399–406.
- [60] Schlake HP, Goldbrunner R, Siebert M, Behr R, Roosen K. Intra-Operative electromyographic monitoring of extra-ocular motor nerves (Nn. III, VI) in skull base surgery. *Acta Neurochir (Wien).* 2001; 143(3): 251–261.
- [61] Alberti O, Sure U, Riegel T, Bertalanffy H. Image-guided placement of eye muscle electrodes for intraoperative cranial nerve monitoring. *Neurosurgery.* 2001; 49(3): 660–663; discussion 663–664.
- [62] Dong CC, Macdonald DB, Akagami R, Westerberg B, Alkhani A, Kanaan I, et al. Intraoperative facial motor evoked potential monitoring with transcranial electrical stimulation during skull base surgery. *Clin Neurophysiol.* 2005; 116(3): 588–596.
- [63] Simon MV. Neurophysiologic intraoperative monitoring of the vestibulocochlear nerve. *J Clin Neurophysiol.* 2011; 28(6): 566–581
- [64] Bricolo A, Turazzi S. Surgery for gliomas and other mass lesions of the brainstem. *Adv Tech Stand Neurosurg.* 1995; 22: 261–341.
- [65] Morota N, Deletis V, Epstein FJ, Kofler M, Abbott R, Lee M, et al. Brain stem mapping: neurophysiological localization of motor nuclei on the floor of the fourth ventricle. *Neurosurgery.* 1995; 37: 922–930.
- [66] Sola RG, Pulido P, Pastor J, Ochoa M, Castedo J. Surgical treatment of symptomatic cavernous malformations of the brainstem. *Acta Neurochir (Wien).* 2007; 149(5): 463–470
- [67] Wong AP, Dahdaleh NS, Fessler RG, Melkonian SC, Lin Y, Smith ZA, et al. Risk factors and long-term survival in adult patients with primary malignant spinal cord astrocytomas. *J Neurooncol.* 2003; 115(3): 493–503.

- [68] Chamberlain MC, Tredway TL. Adult primary intradural spinal cord tumors: a review. *Curr Neurol Neurosci Rep.* 2011; 11(3): 320–328.
- [69] Deletis V, Sala F. Intraoperative neurophysiological monitoring of the spinal cord during spinal cord and spine surgery: a review focus on the corticospinal tracts. *Clin Neurophysiol.* 2008; 119(2): 248–264.
- [70] Sala F, Bricolo A, Faccioli F, Lanteri P, Gerosa M. Surgery for intramedullary spinal cord tumors: the role of intraoperative (neurophysiological) monitoring. *Eur Spine J.* 2007; 16 Suppl 2: S130–9.
- [71] Kothbauer K, Deletis V, Epstein FJ. Intraoperative spinal cord monitoring for intramedullary surgery: an essential adjunct. *Pediatr Neurosurg.* 1997: 247–254.
- [72] de Haan P, Kalkman CJ, Ubags LH, Jacobs MJ, Drummond JC. A comparison of the sensitivity of epidural and myogenic transcranial motor-evoked responses in the detection of acute spinal cord ischemia in the rabbit. *Anesth Analg.* 1996; 83: 1022–1027.
- [73] Hyun SJ, Rhim SC. Combined motor and somatosensory evoked potential monitoring for intramedullary spinal cord tumor surgery: correlation of clinical and neurophysiological data in 17 consecutive procedures. *Br J Neurosurg.* 2009; 23(4): 393–400.
- [74] Skinner SA, Nagib M, Bergman TA, Maxwell RE, Msangi G. The initial use of free-running electromyography to detect early motor tract injury during resection of intramedullary spinal cord lesions. *Neurosurgery.* 2005; 56 (2 Suppl): 299–314.
- [75] Skinner SA, Transfeldt EE. Electromyography in the detection of mechanically induced spinal motor tract injury: observations in diverse porcine models. *J Neurosurg Spine.* 2009; 11(3): 369–374.
- [76] Skinner SA, Hsu B, Transfeldt EE, Mehbod AA, Rippe DM, Wu C, et al. Spinal cord injury from electrocautery: observations in a porcine model using electromyography and motor evoked potentials. *J Clin Monit Comput.* 2013; 27(2): 195–201.