

We are IntechOpen, the world's leading publisher of Open Access books Built by scientists, for scientists

6,900

Open access books available

186,000

International authors and editors

200M

Downloads

Our authors are among the

154

Countries delivered to

TOP 1%

most cited scientists

12.2%

Contributors from top 500 universities



WEB OF SCIENCE™

Selection of our books indexed in the Book Citation Index
in Web of Science™ Core Collection (BKCI)

Interested in publishing with us?
Contact book.department@intechopen.com

Numbers displayed above are based on latest data collected.
For more information visit www.intechopen.com



Computer-Aided Designed/Computer-Aided Manufactured and Conventional Techniques in Maxillofacial Reconstruction with Free Fibula Flaps

Jan Rustemeyer, Aynur Sari-Rieger,
Alexander Busch, Alex Melenberg and Lutz Günther

Additional information is available at the end of the chapter

<http://dx.doi.org/10.5772/63205>

Abstract

We treated 26 patients via vascularized osteocutaneous fibula flaps for maxillofacial osseous reconstruction between September 2012 and October 2015. The CAD/CAM technique was attempted for all patients needing bony maxillofacial reconstructions. The time interval from deciding to use the CAD/CAM technique and receiving the hardware depended on the capacity of the CAD/CAM providing companies. It usually takes between 3 and 4 weeks. Hence, the CAD/CAM technique was not used for patients with rapid tumor growth or pathologic fractures of the mandible. In these urgent cases, surgery could not be delayed and the conventional technique was used. In the abovementioned time period, 11 patients underwent osseous reconstruction using CAD/CAM and 15 patients using the conventional technique. Data were collected and evaluated according to demographics, medical history, number of bone segments, and complications. Time measurements of virtual planning sessions, flap harvesting, flap ischemia, tourniquet inflation, total reconstruction, and overall operating times were additionally recorded.

Keywords: CAD/CAM technique, maxillofacial reconstruction, free fibula flaps, flap ischemia time, virtual planning session

1. Introduction

Computer-aided designed/computer-aided manufactured (CAD/CAM) techniques have received increasing attention in maxillofacial reconstruction. Virtual simulation and three-

dimensional (3-D) hardware such as cutting guides and stereolithographic models to avoid error during intraoperative hand-setting can be used in CAD/CAM surgery [1].

There are three basic steps of surgical treatment in computer-aided osseous reconstruction, namely:

1. Virtual planning
2. CAD/CAM rapid prototyping of the customized surgical devices and
3. Surgery [2].

The clinical indications for virtual surgical planning include the following:

1. Need for multiple free tissue transfer
2. Reconstruction of multiple mandible or midface defects
3. Multiple osteotomies in reconstructive flaps [3–5].

The advantages of virtually planned surgery over conventional surgery include the following:

- a. Enhanced accuracy
- b. Less deviation of reconstructed areas
- c. Improved aesthetic contour and
- d. better functional outcomes [6–10].

Use of CAD/CAM techniques can eliminate the need for intraoperative measurement, provide bony segments with excellent apposition, accurately duplicate the preoperative plan, and minimize adjustments upon inset of the osseous transplant [11–13].

However, whether CAD/CAM techniques accelerate the time-consuming intraoperative steps or reduce overall operative times remains controversial [14, 15].

In this chapter, the description of bony maxillofacial defects followed international classification systems. The HLC applied classification of mandibular defects refers to the classification given by Boyd et al. [16]. The capital letter “H” stands for a defect involving a lateral mandibular segment with a condyle without crossing the midline; “L” represents the same defect but without a condyle; and “C” describes a defect of the anterior mandible between the incisor foramina. The classification of defects of the maxilla referred to the classification of Okay et al. [17]. Class Ia comprises defects with no involvement of the maxillary alveolus; Class Ib describes defects with preservation of both canines; Class II stands for the resection of one canine or less than 50% of the hard palate; and Class III cases comprises the resection of both canines or greater than 50% of the hard palate.

1.1. CAD/CAM technique

High-resolution, helical computed tomography (CT) scans (0.5 mm fine cuts) of the maxillofacial area and the respective fibula donor site were performed. Data including digital imaging

and communications in medicine (DICOM) formats were transmitted to one of two CAD/CAM device-providing companies (Xilloc, Maastricht, Netherlands; Materialise, Leuven, Belgium). Virtual planning starts with using web-based meetings or e-mail services between the company, the biomedical engineers, and the surgical team. The biomedical engineers use the geometry of the virtually resected mandible or maxilla, or mirror of the contralateral disease-free bone to create the ideal orthognathic relationship. In defects involving both sides of the mandible or maxilla, the mirroring technique was not possible. Therefore, in such cases, we have to have a database with segmented atraumatic mandibles and maxillae from other patients that can be imported as a reference (Figure 1).

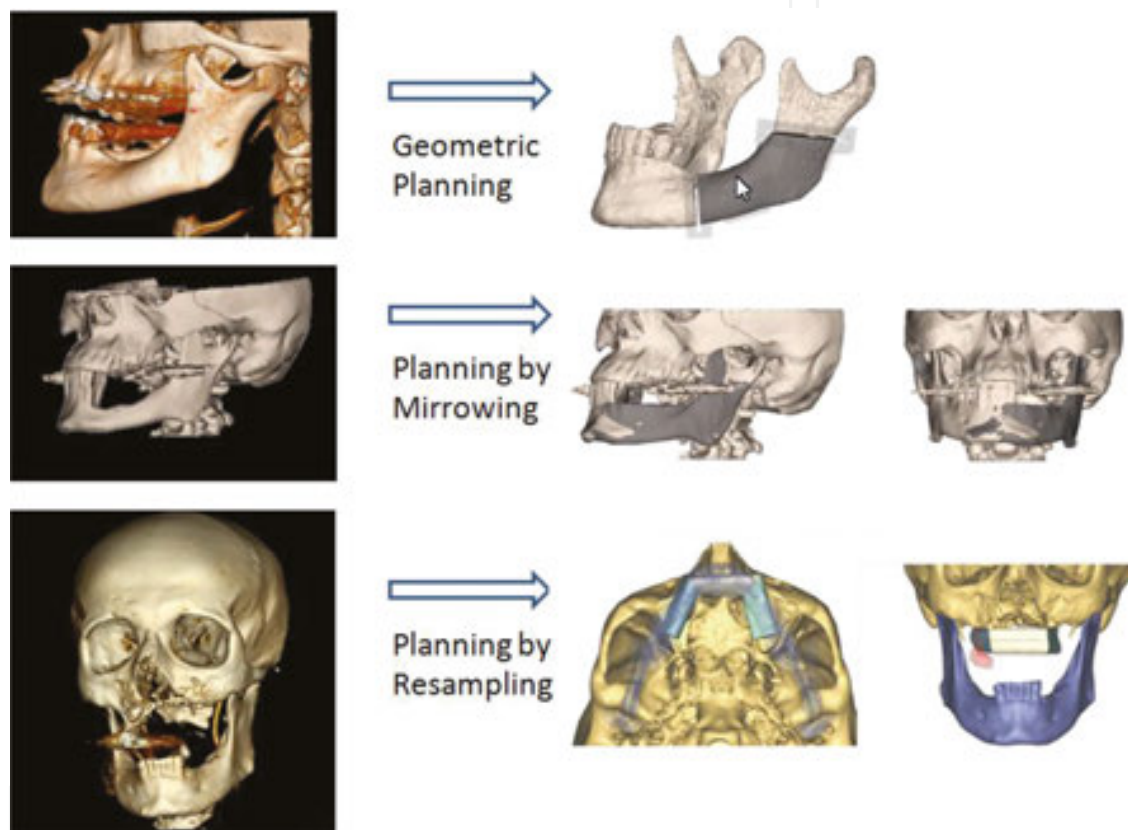


Figure 1. Virtual planning sessions.

The surgeon directs the virtual defect repair by superimposing the patient's own 3-D virtual fibula onto the mandibular or maxillary defect placing osteotomies to recreate the original mandibular or maxillary contour via a trial-and-error process until the number and cutting sites of the osteotomies, bone-to-bone contact, and segment lengths are optimized. A linearized patient-specific cutting guide designed from the cut segments of a virtual fibula with cutting slots or flanges located at appropriate lengths along the osseous transplant with proper angles is rendered to recreate the desired shape without any intraoperative measurements. Additional cutting guides for definite resection borders of the maxillary or mandibular region were created as well. Using a laser-sintering 3-D printer virtual cutting guides were converted to hardware. Stereolithographic models were manufactured similarly for the craniomaxillofacial

skeleton intended. A reconstruction plate or a 3-D bending template was manufactured. **Figure 2** displays the workflow of computer-assisted planning for reconstruction of the mandible.

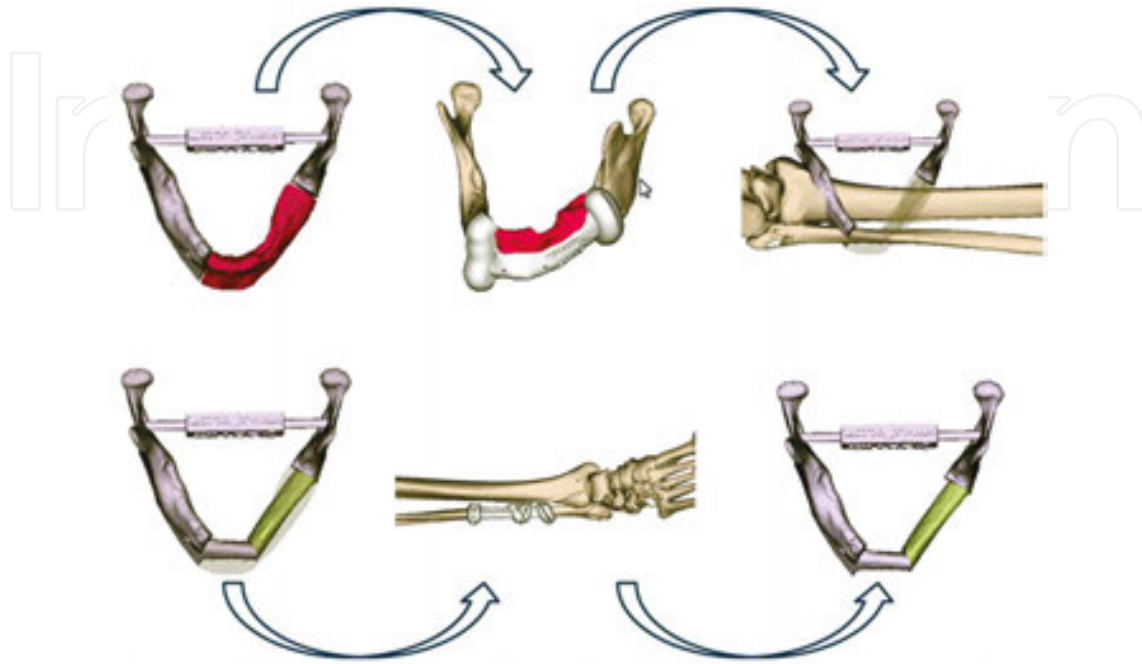


Figure 2. Workflow from virtual planning to 3-D cutting guides for intraoperative use.

1.2. Surgical technique

In order to reduce overall operation time, surgery was performed using two teams; a resection team to prepare the recipient site and a reconstruction team to harvest the fibula flap. The latter team harvested the flap according to the principles described by Hidalgo [18]. A senior surgeon did the planning, flap harvesting, modeling, inset, and microvascular anastomosis. The osteocutaneous fibula flap was dissected and isolated on the vascular pedicle under an inflated pneumatic tourniquet (350 mmHg). Strict adherence to scientifically based guidelines for tourniquet width, pressure, and duration of use is imperative [19]. After complete dissection, the tourniquet was released and meticulous hemostasis was done. In cases of using CAD/CAM technique, the cutting guides were fixed to the bone with lateral unicortical screws and osteotomies were performed with an oscillating saw placing in the cutting slots or along the flanges in order to effectively replicating the virtually planned osteotomies at the harvesting site. Fixation of the osseous segments was realized either via titanium miniplates or a pre-bent reconstruction plate. It was also possible to partially bend and fix the osteosynthesis plate to the transplant before transection of the pedicle using a sterilized defect model during surgery and also check the overall accuracy of osseous modeling (**Figure 3**). After the vascular pedicle was severed, the osseous reconstruction was transferred as a composite unit and secured to the mandibular or maxillary remnant at its optimal predetermined position.

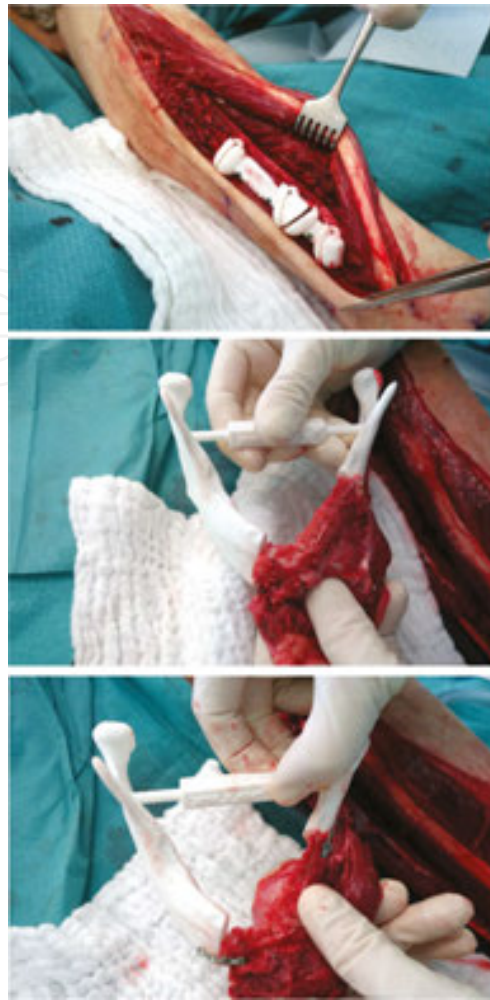


Figure 3. Sterilized defect model during surgery facilitates bending and fixing the osteosynthesis plate to the transplant to check the overall accuracy of osseous modeling before transection of the pedicle in the CAD/CAM technique group.

2. Conventional technique

When using the conventional technique, the lengths of the osseous defect and the desired fibula bone were measured with a metric ruler. Then, the fibula was harvested and the pedicle divided before segmental osteotomies and osteosynthesis were done. These procedures were performed on the back table. In contrast to the CAD/CAM technique, accuracy could only be achieved by repetitive inset and trimming of the transplant, making necessary earlier transection of the pedicle (**Figure 4**).

After inset at the recipient site and fixation of the transplant, two microvascular anastomoses between the recipient neck vessels and the peroneal artery and its accompanying dominant vein are carried out in both techniques (**Figure 5**). For the arterial and venous anastomoses, interrupted sutures were used.

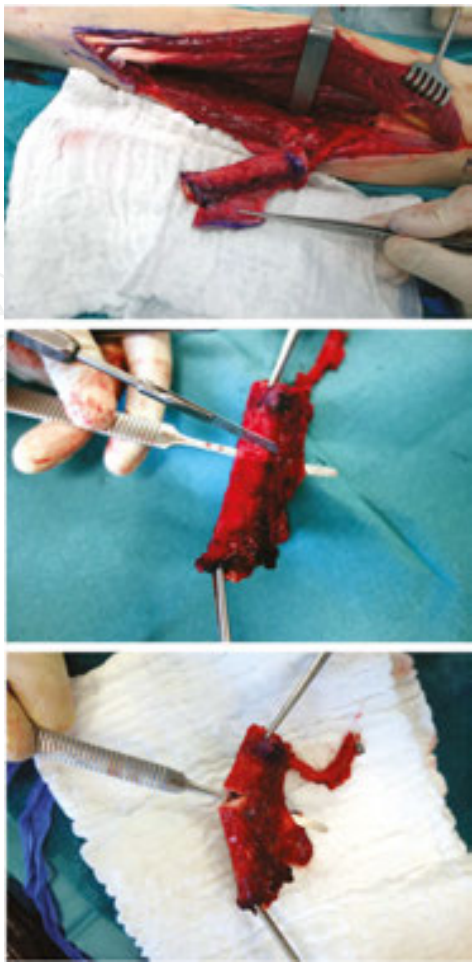

Figure 4. In the conventional technique group, accuracy could only be achieved by repetitive trimming of the transplant after transection of the pedicle on the back table.

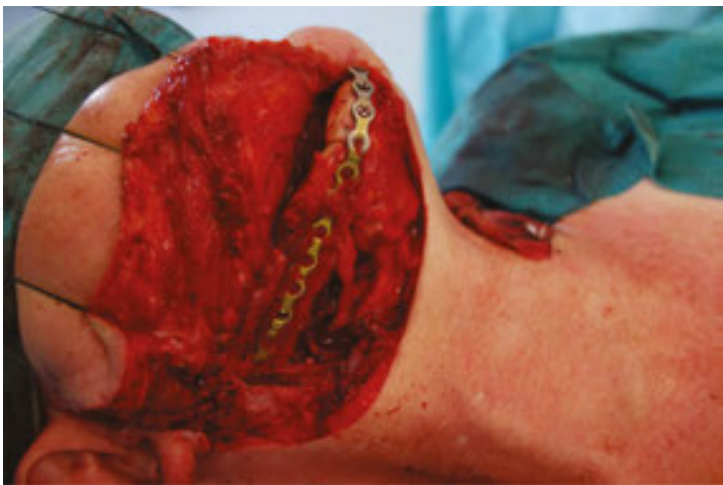





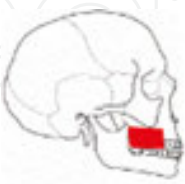
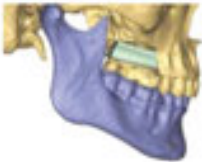

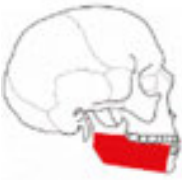
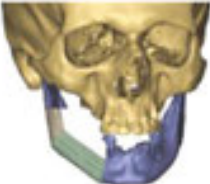



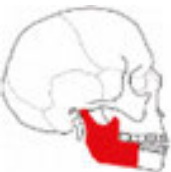






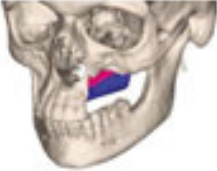










Figure 5. Inset and fixation of the transplant before microvascular anastomosis.




3. Outcomes

3.1. CAD/CAM group

Clinical data for all cases are shown in **Table 1** (CAD/CAM fibula flaps) and **Table 2** (conventional fibula flaps). The CAD/CAM group consisted of three patients suffering from osteoradionecrosis (ORN), two patients with squamous cell carcinoma (SCC), two patients with adenoid cystic carcinoma (ACC), and one patient with osteonecrosis of the jaw (ONJ), one patient with osteomyelitis (OM), one patient with melanotic neuroectodermal tumor of infancy (MNT), and one patient with posttraumatic defect (TRA). Immediate reconstruction was performed in only two patients undergoing the CAD/CAM technique.









Case	Age/ gender	History	Classification	Scheme	Virtual plan	Post-OP CT-scan	Osseous segments (n)
1	59/F	ORN RX SR	LCL				3
2	45/M	ONJ SR	III				3
3	38/F	ACC RX SR	Ib				1
4	64/M	ORN					2

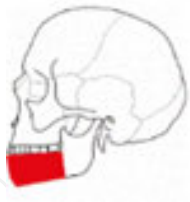











Case	Age/ gender	History	Classification	Scheme	Virtual plan	Post-OP CT-scan	Osseous segments (n)
5	43/M	SCC RX SR	H				2
6	72/F	ORN RX SR					
7	44/F	ACC RX SR	III				2
8	57/M	SCC PR	CL				2
9	56/F	OM PR	H				2
10	36/M	TRA SR	C				2




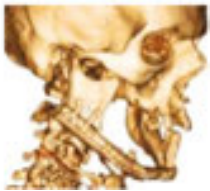
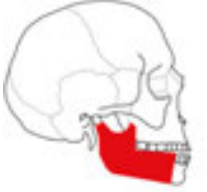





Case	Age/ gender	History	Classification	Scheme	Virtual plan	Post-OP CT-scan	Osseous segments (n)
11	17/M	MNT SR	II				1

ORN = osteoradionecrosis; ONJ = osteonecrosis of the jaw; ACC = adenoid cystic carcinoma; SCC = squamous cell carcinoma; OM = osteomyelitis; TRA = trauma; MNT = melanotic neuroectodermal tumor of infancy; RX = pre-operative radiation; PR = primary (immediate) reconstruction; SR = secondary reconstruction.

Table 1. CAD/CAM fibula flaps.

Case	Age/ gender	History	Classification	Scheme	Post-OP CT-scan	Osseous segments (n)
1	53/F	ONJ PR	LC			2
2	38/F	rACC RX PR	II			2
3	50/M	ONJ PR	CL			2
4	55/F	SCC PR	II			1

Case	Age/ gender	History	Classification	Scheme	Post-OP CT-scan	Osseous segments (n)
5	54/F	ONJ PR	CL			2
6	66/M	SCC PR	L			1
7	80/F	SCC PR	L			2
8	71/M	OM PR	L			1
9	27/M	rSCC RX PR	III			2
10	63/M	SCC PR	L			1

Case	Age/ gender	History	Classification	Scheme	Post-OP CT-scan	Osseous segments (n)
11	54/M	ORN RX PR	L			2
12	47/M	SCC PR	LC			3
13	63/M	SCC PR	L			2
14	58/M	OC PR	II			1
15	75/M	SCC RX PR	L			1

ONJ = osteonecrosis of the jaw; rACC = recurrent adenoid cystic carcinoma; SCC = squamous cell carcinoma; OM = osteomyelitis; rSCC = recurrent squamous cell carcinoma; ORN = osteoradionecrosis; OC = odontogenic cyst
RX = pre-operative radiation; PR = primary (immediate) reconstruction.

Table 2. Conventional fibula flaps.

3.2. Conventional group

The conventional technique was used in eight patients with SCC, in three patients with ONJ, in one patient with ACC, one patient with OM, one patient with ORN, and one patient with

odontogenic cyst (OC). In all patients who underwent the conventional technique, osseous reconstruction was performed immediately after resection.

4. Complications

In the CAD/CAM group, one fibular flap failed completely after 1 week and one skin paddle showed ischemic necrosis on postoperative day 6 and had to be excised. In the conventional technique group, one fibular flap was lost after 8 days and one patient required operative revision following an episode of severe bleeding on postoperative day 3, with consecutive skin paddle loss. In the CAD/CAM group, six patients underwent neoadjuvant radiation (54.5%), as opposed to only three patients undergoing conventional reconstructive surgery (26.7%).

	Technique		p-value
	CAD/CAM	Conventional	
	Mean ± SD	Mean ± SD	
Age (years)	48.3 ± 14.6	56.9 ± 13.3	0.152
Segments (n)	1.9 ± 0.7	1.7 ± 0.6	0.371
Time (min)			
Virtual planning	43.1 ± 5.1	N.A.	
Tourniquet inflation	102.9 ± 7.9	97.3 ± 8.9	0.121
Flap harvesting	141.4 ± 14.8	108.4 ± 7.7	<0.001*
Flap ischemia	72.9 ± 10.3	106.9 ± 23.7	<0.001*
Total ischemia	175.8 ± 7.5	204.2 ± 23.1	<0.001*
Total reconstruction ^a	214.1 ± 14.4	215.3 ± 24.1	0.893
Overall operating ^b	257.2 ± 17.5	215.3 ± 24.1	<0.001*

SD = standard deviation; N.A. = not applied.
^a Total amount of Flap harvesting and flap ischemia time.
^b Total amount of virtual planning time and total reconstruction time in the CAD/CAM group, similar to total reconstruction time in the conventional group.
* Highly significant at the level p < 0.01 (two-tailed).

Table 3. Comparison of demographics, intraoperative factors, and time measurements between the CAD/CAM and the conventional technique groups.

With regards to mean age, number of osseous segments, and tourniquet inflation times, there were no significant differences between groups (**Table 3**). However, flap harvesting time was significantly shorter in the conventional technique group; flap ischemia and total ischemia times were shorter in the CAD/CAM group. Total reconstruction time did not vary significantly among groups, although overall operating time (amount of virtual planning time plus total reconstruction time) in the CAD/CAM group was significantly higher, given the fact that overall operating time in the conventional group included only the reconstruction time.

5. Discussion

The primary issues in conventional osseous reconstruction are that the whole volume of resection at the recipient site can vary and the definite anatomic shape of the osseous transplant can only be determined at the moment of surgery. This results in prolonged intraoperative time and flap ischemia time, with the risk of suboptimal reconstruction of a region which requires a high degree of precision for optimal orthognathic functional and aesthetic outcomes [12]. To avoid these drawbacks, some authors promote as a suitable alternative, a silastic sheeting, which can be cut intraoperatively to shape relying on the mandible segment removed and can be used as a template for fibula harvesting and shaping. In the hands of an experienced surgeon, the final result should not be different from that of applying CAD/CAM technique [24].

5.1. Flap ischemia times

Recent studies have already investigated osteocutaneous fibula flap ischemia times. However, study designs vary, as do mean ischemia times for either the CAD/CAM or conventional technique with or without adding tourniquet inflation times; different time periods in a surgeon’s career also render differences in flap ischemia time between both techniques attributable to the surgeon’s learning curve [14, 25–27]. Mean flap ischemia times vary widely, between 75 and 216 min, with differences of up to 30 and 50 min between both techniques (Table 4).

	Technique		p-value
	CAD/CAM (min) ^a	Conventional (min) ^a	
Succo et al. [27]	75	N.A.	N.A.
Modabber et al. [26]	105	132	0.014
Chang et al. [25]	N.A.	216 ^b	N.A.
Seruya et al. [14]	120	170	0.004
Current study	73	107	<0.001
	176 ^b	204 ^b	<0.001

N.A. = not applied.
^a Rounded up to the next full minute.
^b Tourniquet inflatiogn time included, N.A. = not applied

Table 4. Mean flap ischemia times upon applying CAD/CAM and conventional techniques as provided by recent literature and this study.

In contrast to previous studies, this survey provides a more comparable setup. The CAD/CAM and the conventional techniques were used concurrently, not consecutively. Hence, the predicted bias was reduced to minimum with respect to a learning curve. Our results showed that flap ischemia time could be significantly reduced by 34 min in the CAD/CAM group

compared to the conventional group. The reduction in flap ischemia time was in accordance with the data given by Modabber et al. [26]. Nevertheless, flap ischemia times were definitively longer in the latter study.

However, in this study, it can be recognized that the decrease of ischemia time in the CAD/CAM group did not decrease the total reconstruction time as well. The reduced ischemia time in the CAD/CAM group was the result of shaping and modeling of the fibular parts prior to severing the vascular pedicle. Indeed, this procedure led to a longer flap harvesting time compared with that in the conventional group. But this time lost was regained, since in turn, ischemia time in the conventional group was significantly longer because shaping and trimming of the devascularized fibula flap was carried out on the back table and accuracy could only be achieved by repetitive and time-consuming in- and out-setting of the transplant.

There were no differences found between groups, however, with respect to partial or total flap loss and rate of soft tissue or bony tissue revisions, in this or in previous studies [14, 22]. Chang et al. [25] found that an ischemia time of up to 5 hours (comprising tourniquet inflation and flap ischemia time) did not detrimentally affect fibula flap success or increase complication rates. In most cases, an ischemia time greater than 5 hours was attributable to time-consuming flap inset procedures as mentioned earlier or compromised septocutaneous perforators. In accordance with these findings, in our survey, partial and complete flap losses were not associated with prolonged ischemia times, since total ischemia times in both groups did not approach by far the 5-hour limit. The total number of losses was equal between groups; flap failures were attributed to venous congestion, bleeding, and hematoma which compromised the anastomosed sites.

6. Conclusion

Results are comparable with findings in other studies evaluating the CAD/CAM technique. We showed again that CAD/CAM technology has several advantages compared with the conventional technique, comprising the potency to repair more accurately massive craniofacial defects, the possibilities to plan segmental osteotomies, to perform osteotomies by custom-made cutting guides with the flap pedicle still in continuity, to use a stereolithographic model to confirm proper configuration of osseous flaps, to effectively perform condylar positioning, and to operate with greater convenience and ease [1, 20–22]. In the same way, we experienced the disadvantages of increased preoperative time for planning and the considerable time delay between planning and receiving the hardware for the CAD/CAM technique not appropriate for urgent cases, and the costs incurred by applying this technique [23]. However, in addition to all the advantages of the CAD/CAM over the conventional technique given above, including reduced ischemia time of fibula free flaps, there was no clinically significant impact on total reconstruction time and flap survival at all, since ischemia times obtained with the conventional technique did not exceed critical time levels.

Author details

Jan Rustemeyer*, Aynur Sari-Rieger*, Alexander Busch*, Alex Melenberg* and Lutz Günther*

*Address all correspondence to: janrustem@gmx.de; Aynur.Sari-Rieger@Klinikum-Bremen-Mitte.de; A.Busch@gmx.de; Alex.Melenberg@klinikum-bremen-mitte.de and Lutz.Guenther@klinikum-bremen-mitte.de

Department of Oral and Maxillofacial Surgery, Plastic Operations, Klinikum Bremen-Mitte, School of Medicine of the University of Göttingen, Bremen, Germany

References

- [1] Roser SM, Ramachandra S, Blair H, Grist W, Carlson GW, Christensen AM, Weimer KA, Steed MB. The accuracy of virtual surgical planning in free fibula mandibular reconstruction: comparison of planned and final results. *Journal of Oral and Maxillofacial Surgery* 2010;68:2824–2832.
- [2] Mazzoni S, Marchetti C, Sgarzani R, Cipriani R, Scotti R, Ciocca L. Prosthetically guided maxillofacial surgery: evaluation of the accuracy of a surgical guide and custom-made bone plate in oncology patients after mandibular reconstruction. *Plastic Reconstructive Surgery* 2013;131:1376–1385.
- [3] Saad A, Winters R, Wise MW, Dupin CL, St Hilaire H. Virtual surgical planning in complex composite maxillofacial reconstruction. *Plastic Reconstructive Surgery* 2013;132:626–633.
- [4] Ghazali N, Collyer JC, Tighe JV. Hemimandibulectomy and vascularized fibula flap in bisphosphonate-induced mandibular osteonecrosis with polycythaemia rubra vera. *International Journal of Oral and Maxillofacial Surgery* 2013;42:120–123.
- [5] Tepper OM, Sorice S, Hershman GN, Saadeh P, Levine JP, Hirsch D. Use of virtual 3-dimensional surgery in post-traumatic craniomaxillofacial reconstruction. *Journal of Oral and Maxillofacial Surgery* 2011;69:733–741.
- [6] Hanasono MM, Skoracki RJ. Computer-assisted design and rapid prototype modeling in microvascular mandible reconstruction. *Laryngoscope* 2012;123:597–604.
- [7] Hou J, Chen M, Pan CB, Tao Q, Wang JG, Wang C, Zhang B, Huang HZ. Immediate reconstruction of bilateral mandible defects: management based on computeraided design/computer-aided manufacturing rapid prototyping technology in combination with vascularized fibular osteomyocutaneous flap. *Journal Oral and Maxillofacial Surgery* 2011;69:1792–1797.

- [8] Hayden R, Mullin D, Patel A. Reconstruction of the segmental mandibular defect: current state of the art. *Current Opinion in Otolaryngology & Head and Neck Surgery* 2012;20:231–236.
- [9] Levine JP, Patel A, Saadeh PB, Hirsch DL. Computer-aided design and manufacturing in craniomaxillofacial surgery: the new state of the art. *Journal of Craniofacial Surgery* 2012;23:288–293.
- [10] Foley BD, Thayer WP, Honeybrook A, McKenna S, Press S. Mandibular reconstruction using computer-aided design and computer-aided manufacturing: an analysis of surgical results. *Journal of Oral and Maxillofacial Surgery* 2013;71:e111–e119.
- [11] Marchetti C, Bianchi A, Manzoni S, Cipriani R, Campobassi A. Oromandibular reconstruction using a fibula osteocutaneous free flap: four different “preplating” techniques. *Plastic Reconstructive Surgery* 2006;118:643–651.
- [12] Hirsch DL, Garfein ES, Christensen AM, Weimer KA, Saddeh PB, Levine JP. Use of computer-aided design and computer-aided manufacturing to produce orthognathically ideal surgical outcomes: a paradigm shift in head and neck reconstruction. *Journal of Oral and Maxillofacial Surgery* 2009;67:2115–2122.
- [13] Antony AK, Chen WF, Kolokythas A, Weimer KA, Cohen MN. Use of virtual surgery and stereolithography-guided osteotomy for mandibular reconstruction with the free fibula. *Plastic Reconstructive Surgery* 2011;28:1080–1084.
- [14] Seruya M, Fisher M, Rodriguez ED. Computer-assisted versus conventional free fibula flap technique for craniofacial reconstruction: an outcomes comparison. *Plastic Reconstructive Surgery* 2013;132:1219–1228.
- [15] Matros E, Disa JJ. Discussion: computer-assisted versus conventional free fibula flap technique for craniofacial reconstruction: an outcomes comparison. *Plastic Reconstructive Surgery* 2013;132:1229–1230.
- [16] Boyd JB, Gullane PJ, Brown DH. Classification of mandibular defects. *Plastic Reconstructive Surgery* 1993;92:1266–1275.
- [17] Okay DJ, Genden E, Buchbinder D, Urken M. Prosthodontic guidelines for surgical reconstruction of the maxilla: a classification system of defects. *Journal of Prosthetic Dentistry* 2001;86:352–363.
- [18] Hidalgo DA. Fibula free flap: a new method of mandible reconstruction. *Plastic Reconstructive Surgery* 1989;84:71–79.
- [19] Hicks RW, Denholm B. Implementing AORN recommended practices for care of patients undergoing pneumatic tourniquet-assisted procedures. *Association of Operating Room Nurses Journal* 2013;98 383–393.
- [20] Sharaf B, Levine JP, Hirsch DL, Bastidas JA, Schiff BA, Garfein ES. Importance of computer-aided design and manufacturing technology in the multidisciplinary

approach to head and neck reconstruction. *Journal of Craniofacial Surgery* 2010;21:1277–1280.

- [21] Schepers RH, Raghoobar GM, Vissink A, Lahoda LU, Van der Meer WJ, Roodenburg JL, Reintsema H, Witjes MJ. Fully 3-dimensional digitally planned reconstruction of a mandible with a free vascularized fibula and immediate placement of an implant-supported prosthetic construction. *Head and Neck* 2013;35:e109–114.
- [22] Ayoub N, Ghassemi A, Rana M, Gerressen M, Riediger D, Hölzle F, Modabber A. Evaluation of computer-assisted mandibular reconstruction with vascularized iliac crest bone graft compared to conventional surgery: a randomized prospective clinical trial. *Trials* 2014;15:114.
- [23] Rustemeyer J, Melenberg A, Sari-Rieger A. Costs incurred by applying computer-aided design/computer-aided manufacturing technique for reconstructing maxillofacial defects. *Journal of Cranio-Maxillo-Facial Surgery* 2014;42:2049–2055.
- [24] Hayden RE (2014) Reconstruction of the composite oromandibular defect: fibular free flap. In: Genden EM (Ed.), *Reconstructive surgery*, 1st ed. Philadelphia: Wolters Kluwer Health; 2014. pp. 103–116.
- [25] Chang SY, Huang JJ, Tsao CK, Nguyen A, Mittakanti K, Lin CY, Cheng MH. Does ischemia time affect the outcome of free fibula flaps for head and neck reconstruction? A review of 116 cases. *Plastic Reconstructive Surgery* 2010;126:1988–1995.
- [26] Modabber A, Legros C, Rana M, Gerressen M, Riediger D, Ghassemi A. Evaluation of computer-assisted jaw reconstruction with free vascularized fibular flap compared to conventional surgery: a clinical pilot study. *The International Journal of Medical Robotics and Computer Assisted Surgery* 2012;8:215–220.
- [27] Succo G, Berrone M, Battiston B, Tos P, Goia F, Appendino P, Crosetti E Step-by-step surgical technique for mandibular reconstruction with fibular free flap: application of digital technology in virtual surgical planning. *European Archives of Oto-Rhino-Laryngology* 2015;272:1491–1501.

IntechOpen

