

We are IntechOpen, the world's leading publisher of Open Access books Built by scientists, for scientists

6,900

Open access books available

186,000

International authors and editors

200M

Downloads

Our authors are among the

154

Countries delivered to

TOP 1%

most cited scientists

12.2%

Contributors from top 500 universities



WEB OF SCIENCE™

Selection of our books indexed in the Book Citation Index
in Web of Science™ Core Collection (BKCI)

Interested in publishing with us?
Contact book.department@intechopen.com

Numbers displayed above are based on latest data collected.
For more information visit www.intechopen.com



Split Liver Transplantation

Ahmed Zidan and Wei-Chen Lee

Additional information is available at the end of the chapter

<http://dx.doi.org/10.5772/62450>

Abstract

Liver transplantation is the most effective treatment for the patients with acute liver failure or end-stage liver diseases. Liver transplantation is also indicated for patients with hepatocellular carcinoma to yield a best result if the tumor/tumors meet Milan criteria, University of California San Francisco(UCSF) criteria, or up-to-seven criteria. It is no doubt that more and more people need liver transplantation to save their lives. However, liver donation is always short to match the demand of liver transplantation. Therefore, how to expand the donor pool to increase the opportunities of liver transplantation is paramount. Splitting liver is one of the ways to expand the donor pool and offers an additional chance of liver transplantation. At the beginning of split liver transplantation (SLT), the liver was split and transplanted to an adult and a child. Now, the liver can be split into full right and left lobes and transplanted to two adults. When split liver transplantation is to be performed, there are many considerations that should be clarified. With the improvement of surgical skill, the outcomes of split liver transplantation are similar to that of deceased whole liver transplantation. It is worth to promote the policy of split liver transplantation.

Keywords: split liver transplantation, deceased liver transplantation, liver splitting, Lee's formula, donor pool increase

1. Introduction

Liver transplantation is considered to be the most effective treatment for acute and chronic liver failure patients as well as the only definitive treatment for hepatocellular carcinoma(HCC). With increased demand for liver transplantation, a big gap and discrepancy have been developed between the demand for liver transplantation and donation of liver. This increases the waiting time in the waiting list, which carries the hazards of progression of the disease to be out of curability spectrum. This encourages those who work in the transplantation field to find new

ways to increase the donor pool. Split liver transplant (SLT) is one of these methods for expanding the donor pool and giving another chance for transplant candidates, in which either one cadaver liver is split between one pediatric patient and an adult or between two adults.

SLT is considered to be a magic bullet, which gives the possibility to duplicate the numbers of transplanted patients using the same donor pool capacity.

2. Historical background

The concept of partial liver allograft was first advocated by Smith [1] in 1969 who proposed left lateral segments suitable for children. In 1988, Pichlmayr was the first surgeon who split the liver into two grafts, one for child (left lateral segment) and the other for adult (extended right trisegments) [2]. In 1989, Bismuth et al. [3] reported another case of split liver transplant for two patients with acute liver failure, and in 1990, Emond from the University of Chicago reported the first series of nine SLT procedures in 18 pediatric and adult recipients [4]. Although splitting of the liver between pediatric and adult patients has a good impact on the donor pool expansion for pediatric patients, it has little impact on the donor pool for adult patients, as only one adult patient will benefit from the splitting of the liver. Because most of the patients in the waiting list for liver transplantation are adults, this encouraged Bismuth and Paul Brousse hospital group in 1996 to publish a series of 26 adult patients receiving full left and right lobe split grafts [5]. In 1997, the first split liver transplant in Asia was performed in Taiwan, followed by the other Asian countries which need to augment the cadaveric donor pool, which is already low due to some cultural reasons [6].

Although the early experience of SLT was not encouraging as the results revealed higher rate of complications and graft loss, a European workshop held in 1993, analyzing data from different centers, published its findings in 1995, which reported 20% of the graft was lost due to complications including hepatic artery thrombosis (11%), portal vein thrombosis (4%), and biliary complications (19%). This report also revealed that the patient and graft survival were correlated to medical acuity at the time of transplantation. In transplantation due to acute emergency like fulminant liver failure, the 6-month pediatric graft and recipient survival were 61%, and adult recipient and graft survival were 67 and 55%, respectively. Contrarily, in elective liver transplantation, adult recipient and graft survival were 80 and 72%, respectively, and pediatric patient and graft survival were 89 and 80%, respectively [7].

So, it was clear that there was a learning curve to this technique, which contributed to higher incidence of complications and graft loss [8]. Another important factor was the recipient selection; high-risk recipient was unable to tolerate the technical complications, which contributed to the suboptimal results [9]. With the improvement in recipient selection and refinement of the surgical technique, significant improvement of the outcome was noticed. Azoulay et al. [5] described 27 split grafts with 1-year recipient and graft survival of 79 and 78%, respectively.

Our results from Chang Gung Memorial Hospital at Linkou were published in 2013 for 21 split liver transplants for 42 patients, which showed that 5-year recipient survival for right and left

hemiliver were 70.1 and 61.5%, respectively, with no reported vascular complications of either hepatic artery or portal vein thrombosis [10].

3. Donor criteria

Donor selection is one of the crucial determinants in the splitting liver transplant procedure. The key is to be able to predict the potential graft function and the graft weight. Regarding graft function and quality, donors less than 50 years are defined to be suitable for splitting. Minimal to mild fatty liver (10–20%) may be suitable, if the cold ischemia time is maintained as short as possible. Donors with slightly elevated liver enzymes (less than three times the normal range), with intensive care stay of less than 7 days, and without significant vasopressor use with absent or short arrest time could be considered as potential donors [10–14]. Short warm and cold ischemia time is a determinant factor, as early graft dysfunction is usually associated with prolonged warm and cold ischemia time (**Table 1**).

Determinant factors in graft function and quality in SLT
1. Donor age <50 years
2. Steatosis (minimal to mild)
3. ICU stay <7 days
4. Vasopressor support
5. Arrest and its duration
6. Warm and cold ischemia time
7. Liver enzymes less than three times the normal range

Table 1. Determinant factors in graft function and quality.

The gross picture and the intraoperative assessments play a major rule in splitting decision, although the liver biopsy and microscopic examination are the ideal determinants [11]. There is no big difference regarding the graft quality between right and left hemiliver splitting (two adult recipients) and extended right graft and left latter segment (one adult and one pediatric recipient), except that in the former it is safer to have a better graft quality in the form of less steatosis, shorter warm and cold ischemia time, and younger donor age.

3.1. Determination of graft weight

Regarding graft weight, some centers correlate the graft weight with the donor weight, as liver weight constitutes about 2–2.7% of body weight. Donor weight gives an idea about the whole graft weight, but cannot predict each hemiliver graft weight. Furthermore, application of donor weight in clinical practice is limited as obese donors are considered to be a risk factor for splitting liver transplantation as significant steatosis increases the possibility of primary graft dysfunction.

Some donors may have computed tomography or MRI scan of the abdomen, especially if the cause of death is trauma, and the graft volume of each split liver graft can be obtained easily from these scans. However, not every donor has computed tomography or MRI scan of the abdomen. For splitting the liver, transporting a potential organ donor from an intensive care unit to a CT facility to enable measurements of the sizes of hemilivers is controversial. In addition, the relevant technical expertise required to measure liver volumes by CT may not be readily available.

We introduced a simple formula and procedure to determine each split graft weight using only bedside ultrasound scans to measure right and left portal vein diameters. This formula, known as Lee's formula, consisted of standard liver volume (SLV) and portal vein diameters. The standard liver volume (SLV) is calculated by Urata's formula to determine the whole liver weight. The weight of each split liver graft is determined as follows: right hemiliver volume (RHLV) = $SLV \times [R^2/(R^2 + L^2)]$ and left hemiliver volume (LHLV) = $SLV \times [L^2/(R^2 + L^2)]$, where (R) is maximal right portal vein diameter and (L) is maximal left portal vein diameter [15]. Lee's formula can be used in two adult split liver transplants to determine the weight of each graft and subsequently the graft-to-recipient weight ratio (GRWR).

4. Recipient criteria

As we mentioned earlier, improper recipient selection was one of the causes of the unfavorable outcome of split liver transplant at the beginning of the procedure development. Two important determinants in the recipient may act as keys for favorable outcome: the first is the patient's general condition and acuity of the disease; the second is the correlation between the graft weight and recipient weight. Regarding patient's condition and acuity of the disease, the early experience of considering high-risk patient with high MELD score or acute liver failure for SLT was associated with low outcome with high incidence of graft dysfunction, graft loss, and re-transplantation [16]. Generally, critically ill patients with high MELD score, with severe portal hypertension, are not good candidates for split liver transplantation, which should be preserved for low-risk patients with low MELD score. Also, urgency is considered to be a determinant factor for outcome in SLT, as patient survival in urgent liver transplant is lower than that for elective causes [7, 17]. Nevertheless, in countries with low cadaveric liver donor pool, as most of Asian countries, SLT is the only treatment in such an acute fatal condition and must be offered to high urgent patients [10, 18].

The other important key for favorable outcome after SLT is the correlation between graft weight and recipient weight (GRWR). In extended right/left lateral split, the effect of this factor is not prominent, as left lateral segment is suitable for all children with acute or chronic liver disease with good patient and graft survival. In right/left hemiliver split, GRWR plays an important rule, especially in patients who will receive left hemiliver. As mentioned earlier, graft weight can be roughly estimated using Lee's formula; this helps in the determination of the ideal recipient weight.

Most of the results published using GRWR $< 0.8\%$ show inferior outcome than those with $\geq 0.8\%$, in spite of the results of living donor liver transplantation (LDLT) with GRWR $< 0.8\%$ being accepted. There are more risk factors and stresses on the SLT graft more than LDLT graft, as in the former, graft from deceased donor may suffer from hemodynamic instability of the donor and prolonged cold ischemia time, which have more injurious effect on the split graft [19]. Although most of the centers consider GRWR $> 0.8\%$ is the cutoff of safe SLT, our published data show that GRWR $> 1\%$ is the most optimal cutoff point to predict early graft and patient survival [10, 13].

5. Surgical techniques

5.1. Left lateral/extended right split

In the left lateral split, the liver is split into left lateral segment graft and extended right liver graft; left lateral segment is allocated to a child and the extended right graft is allocated to an adult recipient. The ex situ split technique was performed by Pichlmayr et al. [2]. Rogiers et al. introduced a technical modification in 1995, named in situ split technique in which split procedure is performed during procurement before aortic cross-clamp [20, 21].

5.1.1. Ex situ split

After retrieval and perfusion, the liver is split on back table while maintained in preservation solution at a temperature below 4°C . At first, the vascular inflow (portal vein and hepatic artery), outflow (hepatic veins), and biliary structures are assessed.

- Dissection of the left hepatic artery (LHA) from bifurcation of the hepatic artery proper is performed with the identification of segment IV artery, which may arise from right or left hepatic arteries; preservation of segment IV artery is important to maintain perfusion to segment IV and to avoid segment IV ischemia and necrosis. If segment IV artery arises from right hepatic artery, left hepatic artery could be cut at the bifurcation of hepatic artery proper (HAP) safely. If segment IV artery arises from left hepatic artery, some prefer to cut LHA distal to the origin of segment IV artery and others cut LHA at the bifurcation, with the reconstruction of segment IV artery later in the recipient. Actually, it depends on the experience of the transplant team and size matching with the child's recipient artery.
- Regarding biliary system, some prefer to do cholangiogram to identify segment IV duct and caudate ducts, but using a metallic probe only looks to be enough in left lateral split. Role of intraoperative cholangiogram may be more effective in right and left splits, which will be discussed later. Dissection of left hepatic duct should be avoided to maintain the periductal vascular plexus and avoid any injury to the caudate bile ducts. Then, the bile duct drain in the left lateral segment is cut at the level of hilar plate behind the junction of the transverse and longitudinal part of left portal vein, just proximal to segment IV duct, and its orifice in extended right graft is sutured.

- Then, left portal vein (LPV) is dissected from its bifurcation, and tributaries from the caudate and segment IV are isolated and ligated. Then, LPV is cut at the bifurcation, and its orifice in the main portal vein is sutured.
- After completing inflow and biliary duct division, liver parenchymal dissection is started 1 cm to the right of falciform ligament, using Kelly's clamp-crushing technique, with clipping or suturing any vascular structure.
- Left hepatic vein (LHV) is isolated during liver parenchymal transection, hanged with vascular loop, and then LHV is cut, and its orifice at the confluence of left and middle hepatic veins (LHV/MHV) is sutured.

Then, flushing of both grafts with preservation solution is done through portal veins; left lateral segment graft is prepared for implantation in a pediatric recipient, based on left hepatic vein, left portal vein, left hepatic artery, and left bile duct. Extended right graft is prepared for implantation in an adult recipient, based on IVC containing right and middle hepatic veins, main portal vein, main hepatic artery with aortic patch, and main bile duct. The main disadvantages of ex situ split is failure of assessment of segment IV perfusion and viability, prolonged cold ischemia time, and repeated rewarming during liver parenchymal transection, which may affect the graft survival (**Table 1**).

5.1.2. *In situ split*

Splitting is performed during organ retrieval before aortic cross-clamping.

- The liver parenchyma is divided at first 1 cm to the right of falciform ligament; transection of liver parenchyma is performed using clamp-crushing technique or cavitron ultrasonic surgical aspirator (CUSA), with the identification and ligation or clipping of vascular and biliary structures at the transection line.
- Segment IV perfusion is assessed, and hemostasis is performed on both cut surfaces of the liver. Once parenchymal transection is completed, retrieval procedure is continued as usual, and perfusion of the preservation solution is started.
- On back table, vascular and biliary structures are isolated as in ex situ technique.

In situ split has several advantages on ex situ split, as it decreases the total cold ischemia time by 1–2 h and reduces the possibility of rewarming in the back table split, which may have negative impact on the outcome. Also, the two liver grafts can be assessed for significant ischemia at the cut surface and margin, especially in segment IV. During parenchymal transection, hemostasis and vascular control may help in decreasing bleeding from cut surface after reperfusion.

On the other hand, there are some disadvantages of in situ split technique, as increased retrieval time may not only affect the liver itself but also the other retrieved organ, which makes this technique not a suitable option in hemodynamically unstable donors (**Table 2**).

Advantages	Disadvantages
1. Assessment of perfusion and viability of segment IV	1. Increase retrieval time
2. Better hemostasis on both liver cut surfaces	2. Not suitable in hemodynamic unstable donor
3. Decrease cold ischemia time	

Table 2. Advantages and disadvantages of in situ split over ex situ split technique.

5.2. Right/left split

There is no standard splitting technique in left/right split. Each center has its own technique with many modifications. We will try to present some of these modifications and techniques with our comments on each.

5.2.1. Ex situ split

- After retrieval of the whole liver with IVC, cholangiogram is performed on back table to detect any biliary anomaly.
- Then, transection line is identified in the midplane along Cantlie’s line. Liver parenchyma transection is performed as described earlier with clamp-crushing technique and identification of large tributaries of veins from segment V and VIII. Caudate lobe is preserved to left hemiliver, in spite of some centers excising it completely from the graft.
- Many centers, including our center, preserve the middle hepatic vein (MHV) in the left hemiliver to guarantee good drainage of segment IV. If there is sizable segment V or VIII veins, they should be reconstructed either using vascular allograft, portal vein of the explanted liver, or synthetic (Gortex) vascular graft (**Figure 1**). Some authors describe MHV split in which the transection line passes through MHV, which is reconstructed by vascular patch on each side.
- The stump of LHV/MHV is hanged and cut near IVC, and its opening is closed.
- IVC is better to be maintained in the right hemiliver to allow better outflow through retrohepatic veins. Some centers describe IVC split technique in which IVC is split into two halves longitudinally, one with each graft, and then reconstructed using vascular patch on each side. Both MHV split and IVC split carry the hazards of suture leakage and bleeding due to the long reconstruction line.
- Hepatic artery and portal vein are dissected, and it is better to preserve the main branches (main portal vein and main hepatic artery) with the left hemiliver graft, as the size of its vessels is relatively smaller.
- Segment IV artery is isolated, and if it arises from RHA, RHA is cut distal to the origin of segment IV artery.
- The main bile duct is preserved with the right hemiliver, as the left hepatic duct has longer extrahepatic course, and possibility to have more than one duct is more frequent at the right side.

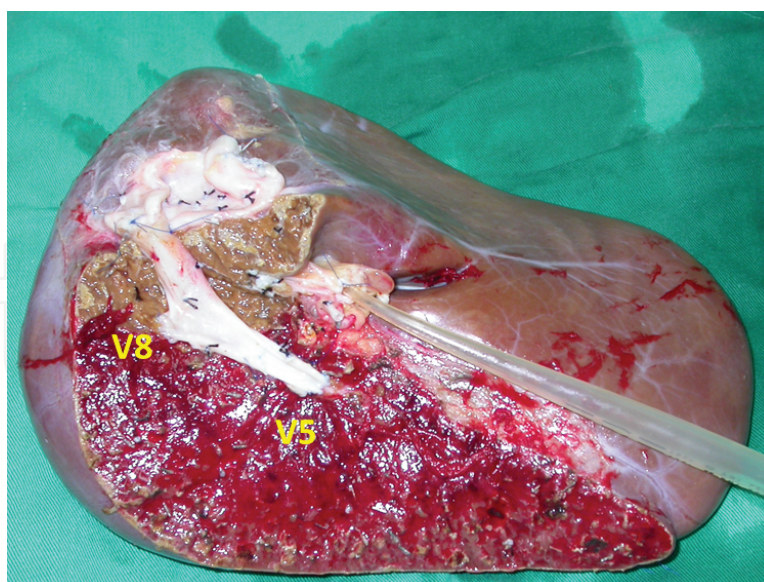


Figure 1. Reconstruction of the tributaries of segments V and VIII with a vein graft. Because the middle hepatic vein was preserved in left hemiliver graft, the tributaries of segments V and VIII were severed. When the diameters of tributaries were more than 5 mm, the tributaries were reconstructed with a vein graft into IVC.

Now we have two grafts: right hemiliver based on IVC, common bile duct, right hepatic artery (RHA), and right portal vein (RPV); and left hemiliver based on MHV/LHV confluence, main portal vein (MPV), hepatic artery proper (HAP), and left hepatic duct (LHD) (**Figure 2**).

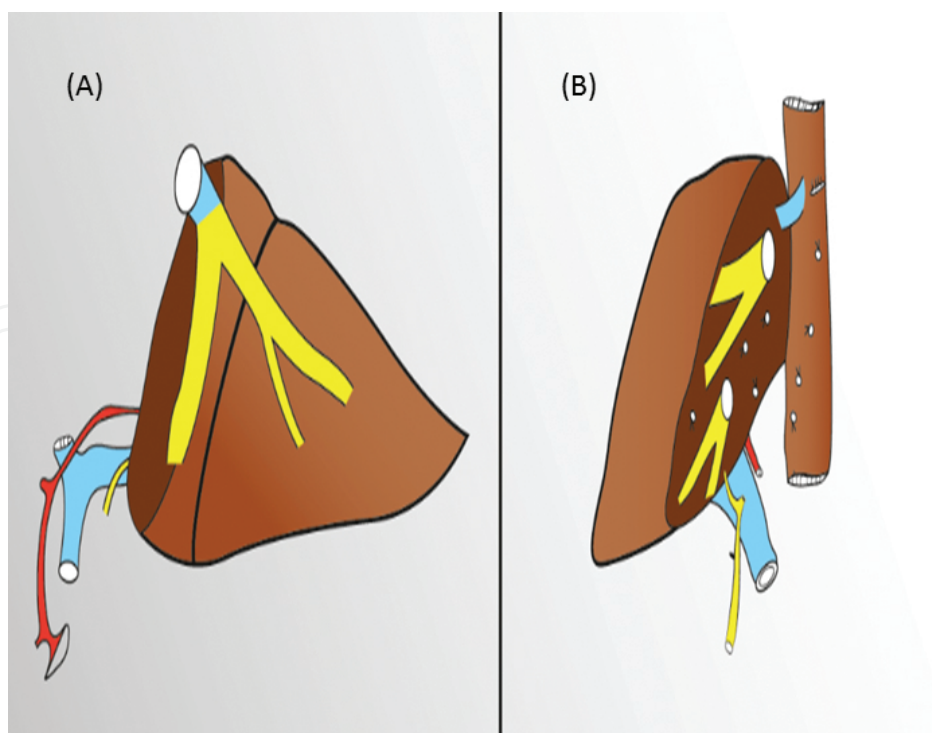


Figure 2. Diagram showing (A) left and (B) right split grafts with attached inflow and outflow structures.

5.2.1.1. Implantation of the right hemiliver

Vascular graft from reconstructed segments V and VIII branches can be anastomosed directly in donor IVC through a separate cavotomy. During implantation of the graft, IVC can be implanted by caval interposition technique, conventional piggyback (end-to-side) technique, or modified piggyback technique (side-to-side). RPV of the graft is anastomosed to RPV or MPV of the recipient; RHA of the graft is anastomosed to RHA of the recipient; and biliary reconstruction is achieved by duct-to-duct or Roux-en-Y technique (**Figure 3**).

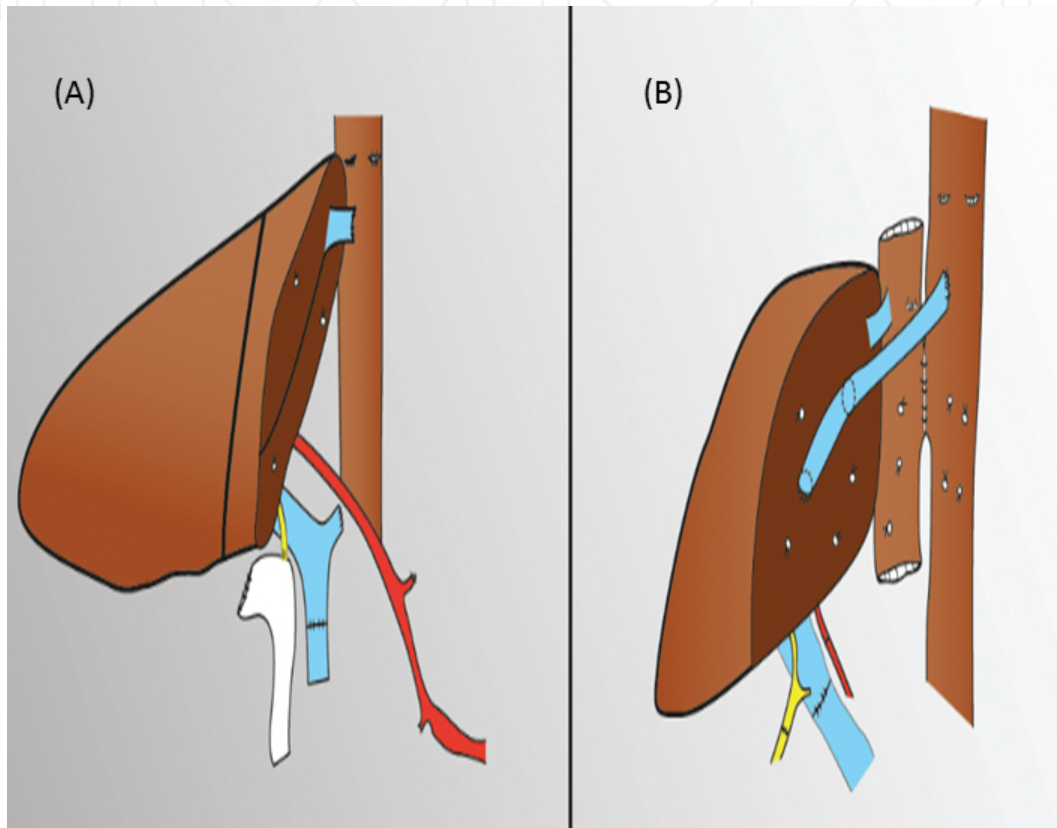


Figure 3. Diagram showing implantation of (A) left and (B) right hemiliver (left hemiliver was implanted by left at right technique).

5.2.1.2. Implantation of the left hemiliver

The left lobe could be implanted as usual in the left upper abdomen, but we have a new modification, published and innovated by Chang Gung Memorial hospital—Linkou, called left at right implantation [22], in which the left lobe is placed in the right upper quadrant to facilitate inflow and outflow reconstruction and avoid any compression of IVC or kinking of hepatic vein by the growing liver graft. Donor MHV/LHV confluence is anastomosed by separate cavotomy in recipient IVC; donor MPV is anastomosed to recipient RPV or MPV according to size-matching; donor HAP is anastomosed to recipient HAP; and biliary reconstruction is achieved by duct-to-duct or Roux-en-Y technique (**Figure 3**).

5.2.2. *In situ split*

In this technique, split is performed during retrieval procedure before aortic cross-clamping.

- First of all, careful examination of the liver with visual assessment of liver quality and size is performed.
- Then, intraoperative cholangiogram is performed to detect biliary anatomy and any anomaly in biliary system.
- The liver is mobilized from its attachment to diaphragm and retroperitoneum, but without interruption of the short hepatic veins which drain directly into IVC to keep reasonable outflow of the right lobe.
- Porta hepatis is examined. RHA and RPV are encircled.
- Then, transection of the liver parenchyma is started with CUSA or clamp-crushing technique, just to the right of MHV, which is detected either by intraoperative ultrasound or just through Cantlie's line.
- After complete transection of liver parenchyma, LHD is divided in the hilar plate just before the carina.
- Then, the infradiaphragmatic aorta is cross-clamped. The visceral organs are perfused with cooled preservation solution. All the donated organs are retrieved subsequently.
- Finally, two hemiliver grafts are separated completely by dividing RHA, RPV, and confluence of MHV and LHV at the back table. IVC is preserved with the right hemiliver graft most of the time. The large venous tributaries of segments V and VIII are reconstructed to IVC with venous grafts. The two liver grafts now are kept in cold preservative solution, with irrigation of the grafts through the portal vein.

We prefer to do the liver parenchymal transection only in the donor and keep porta hepatis division as described in ex situ splitting in the back table to decrease the retrieval time.

6. SLT outcomes

On reviewing graft and patient survival of SLT, it is apparent that there is prominent improvement across the time since 1988 till now; this improvement can be attributed to the learning curve and the improvement of patient selection as we mentioned before.

6.1. Pediatric recipient

Data from U.S. Scientific Registry of Transplant Recipient and Organ Procurement showed that recipient survival after year 2000 ranged between 76 and 100%, while Broering reported that recipient survival before 2000 was 50–92%. The graft survival is also improved after 2000 from 50–80% to 66–100%. The incidence of complications is 32%, which is comparable with

LDLT. This improvement in outcome is associated with better surgical technique and better recipient selection [11, 12].

6.2. Adult recipient

Similar to pediatric data, there is significant improvement regarding adult recipient, either in extended right liver graft or right and left liver grafts. Recipient survival ranges from 79 to 100%, and graft survival is 69–100% after year 2000, with 26% of complications [12, 23, 24]. Our published data showed that 3-month and 1-year survival rates were 76.2 and 71.4% for SLT and 89.3 and 79.9% for living donor recipients, respectively. This result shows no significant difference in patient outcomes between SLT and LDLT [9, 10].

7. Ethical considerations

Since the introduction of SLT, there are many ethical considerations, and debates have evolved. As SLT is introduced as one of the solutions of the gap between liver demands and liver donor pool, SLT helps in decreasing the waiting list time, as about 15–20% of the deceased livers are eligible to be split from medical point of view. This increases the number of recipients to receive liver transplantation. On the other hand, it is clear that the outcomes of SLT are relatively lower than whole liver transplant, with relative increase in morbidities and complications. So, the ethical debate is to increase the number of patients receiving LT, decrease the waiting time list, and decrease dropouts from waiting list by splitting the liver, or increase the patient survival, outcomes, and decrease the number of patients receiving LT without splitting the liver.

Although the importance of this question is fading down with time, with improvement in the splitting techniques and outcome, still there are different morbidities and complications between whole organ transplant and SLT. When the donated liver graft is suitable for splitting, the primary recipient who is on the top of waiting list should be asked for his consent and agreement to receive a liver splitting graft and sharing with another recipient. Transplant coordinator and team are obliged to supply the recipient with full data about the possible morbidities of split liver graft and the benefits regarding sharing this organ with another recipient. However, the patients have the full right to accept the splitting or receiving the whole organ depending on the medical data given by the transplant coordinator. If the primary recipient has not consented to split a liver which is ideally suited for splitting, the liver should be offered to the next person on the list who consents to splitting the liver. But, the primary recipient would maintain their position based on the MELD score and wait for the next opportunity of whole liver transplantation [25].

Another important ethical issue is that all parties involved in the transplantation process must understand a stewardship rather than an ownership of an organ by a potential recipient, transplant center/program, or transplant surgeon. To maximize the opportunities of liver transplantation, high-quality organs such as young deceased donors with low BMI and related stable hemodynamics are used for splitting, and the suboptimal organs are kept as whole liver grafts.

Again, this confliction between maximizing the number of transplanted recipients and maximizing the recipient survival could fade down with the improvement of the outcome of SLT, which is based primarily on choosing the right donor livers for splitting and improvement in split techniques.

Author details

Ahmed Zidan and Wei-Chen Lee*

*Address all correspondence to: weichen@cgmh.org.tw

Division of Liver and Transplantation Surgery, Departments of General Surgery, Chang Gung Memorial Hospital at Linkou, Chang Gung University College of Medicine, Taoyuan, Taiwan

References

- [1] Smith B. Segmental liver transplantation from a living donor. *J Pediatr Surg* 1969;4:126–132.
- [2] Pichlmayr R, Ringe B, Gubernatis G, Hauss J, Bunzendahl H. Transplantation of a donor liver to 2 recipients (splitting transplantation)--a new method in the further development of segmental liver transplantation. *Langenbecks Arch Chir* 1988;373:127–130.
- [3] Bismuth H, Morino M, Castaing D, Gillon MC, Descorps Declere A, Saliba F, et al. Emergency orthotopic liver transplantation in two patients using one donor liver. *Br J Surg* 1989;76:722–724.
- [4] Emond JC, Whittington PF, Thistlethwaite JR, Cherqui D, Alonso EA, Woodle IS, et al. Transplantation of two patients with one liver. Analysis of a preliminary experience with 'split-liver' grafting. *Ann Surg* 1990;212:14–22.
- [5] Azoulay D, Astarcioglu I, Bismuth H, Castaing D, Majno P, Adam R, et al. Split-liver transplantation. The Paul Brousse policy. *Ann Surg* 1996;224:737–746; discussion 746–738.
- [6] de Villa VH, Chen CL, Chen YS, Wang CC, Tan KC, Suh KS, et al. Split liver transplantation in Asia. *Transplant Proc* 2001;33:1502–1503.
- [7] de Ville de Goyet J. Split liver transplantation in Europe--1988 to 1993. *Transplantation* 1995;59:1371–1376.
- [8] Schrem H, Kleine M, Lankisch TO, Kaltenborn A, Kousoulas L, Zachau L, et al. Long-term results after adult ex situ split liver transplantation since its introduction in 1987. *World J Surg* 2014;38:1795–1806.

- [9] Lauterio A, Di Sandro S, Concone G, De Carlis R, Giacomoni A, De Carlis L. Current status and perspectives in split liver transplantation. *World J Gastroenterol* 2015;21:11003–11015.
- [10] Lee WC, Chan KM, Chou HS, Wu TJ, Lee CF, Soong RS, et al. Feasibility of split liver transplantation for 2 adults in the model of end-stage liver disease era. *Ann Surg* 2013;258:306–311.
- [11] Broering DC, Schulte am Esch J, Fischer L, Rogiers X. Split liver transplantation. *HPB (Oxford)* 2004;6:76–82.
- [12] Renz JF, Yersiz H, Reichert PR, Hisatake GM, Farmer DG, Emond JC, et al. Split-liver transplantation: a review. *Am J Transplant* 2003;3:1323–1335.
- [13] Ferla F, Lauterio A, Di Sandro S, Mangoni I, Poli C, Concone G, et al. Split-liver full-left full-right: proposal for an operative protocol. *Transplant Proc* 2014;46:2279–2282.
- [14] Abradelo M, Sanabria R, Caso O, Alvaro E, Moreno E, Jimenez C. Split liver transplantation: where? when? how? *Transplant Proc* 2012;44:1513–1516.
- [15] Wang F, Pan KT, Chu SY, Chan KM, Chou HS, Wu TJ, et al. Preoperative estimation of the liver graft weight in adult right lobe living donor liver transplantation using maximal portal vein diameters. *Liver Transpl* 2011;17:373–380.
- [16] Broelsch CE, Emond JC, Whittington PF, Thistlethwaite JR, Baker AL, Lichtor JL. Application of reduced-size liver transplants as split grafts, auxiliary orthotopic grafts, and living related segmental transplants. *Ann Surg* 1990;212:368–375; discussion 375–367.
- [17] Hashimoto K, Quintini C, Aucejo FN, Fujiki M, Diago T, Watson MJ, et al. Split liver transplantation using Hemiliver graft in the MELD era: a single center experience in the United States. *Am J Transplant* 2014;14:2072–2080.
- [18] Maggi U, De Feo TM, Andorno E, Cillo U, De Carlis L, Colledan M, et al. Fifteen years and 382 extended right grafts from in situ split livers in a multicenter study: are these still extended criteria liver grafts? *Liver Transpl* 2015;21:500–511.
- [19] Hill MJ, Hughes M, Jie T, Cohen M, Lake J, Payne WD, et al. Graft weight/recipient weight ratio: how well does it predict outcome after partial liver transplants? *Liver Transpl* 2009;15:1056–1062.
- [20] Kilic M, Seu P, Stribling RJ, Ghalib R, Goss JA. In situ splitting of the cadaveric liver for two adult recipients. *Transplantation* 2001;72:1853–1858.
- [21] Rogiers X, Malago M, Habib N, Knoefel WT, Pothmann W, Burdelski M, et al. In situ splitting of the liver in the heart-beating cadaveric organ donor for transplantation in two recipients. *Transplantation* 1995;59:1081–1083.

- [22] Chan KM, Eldeen FZ, Lee CF, Wu TJ, Chou HS, Wu TH, et al. "Left at right" adult liver transplantation: the feasibility of heterotopic implantation of left liver graft. *Am J Transplant* 2012;12:1511–1518.
- [23] Yersiz H, Renz JF, Farmer DG, Hisatake GM, McDiarmid SV, Busuttil RW. One hundred in situ split-liver transplantations: a single-center experience. *Ann Surg* 2003;238:496–505; discussion 506–497.
- [24] Renz JF, Emond JC, Yersiz H, Ascher NL, Busuttil RW. Split-liver transplantation in the United States: outcomes of a national survey. *Ann Surg* 2004;239:172–181.
- [25] Vulchev A, Roberts JP, Stock PG. Ethical issues in split versus whole liver transplantation. *Am J Transplant* 2004;4:1737–1740.