

We are IntechOpen, the world's leading publisher of Open Access books Built by scientists, for scientists

6,900

Open access books available

186,000

International authors and editors

200M

Downloads

Our authors are among the

154

Countries delivered to

TOP 1%

most cited scientists

12.2%

Contributors from top 500 universities



WEB OF SCIENCE™

Selection of our books indexed in the Book Citation Index
in Web of Science™ Core Collection (BKCI)

Interested in publishing with us?
Contact book.department@intechopen.com

Numbers displayed above are based on latest data collected.
For more information visit www.intechopen.com



Osteotomies in Orthognathic Surgery

Hossein Kashani and Lars Rasmusson

Additional information is available at the end of the chapter

<http://dx.doi.org/10.5772/63345>

Abstract

Orthognathic surgery is mostly performed to correct developmental or acquired oral and maxillofacial skeletal deformities (OMSDs). During the past three decades, significant advances in surgical osteotomy techniques and instrumentation have been developed and carried out in orthognathic surgery. However, the basic surgical principles have more or less remained unchanged. At the same time, numerous surgical techniques have been developed and refined and used by surgeons in the field of oral and maxillofacial surgery. These techniques have treatment of the most complex dentofacial deformities with confidence. Additionally, it has been possible to predict the results of the treatment. Although the initial surgical techniques for correction of anterior mandibular open bite were reported as early as the late 1800s, widespread use of currently acceptable techniques began in the middle of the last century. Detailed surgical planning is essential for a successful outcome. The treatment involves an accurate treatment plan, correct type of instruments for a specific procedure, a thorough surgical routine, and adherence to the guidelines for each routine. Although similar orthognathic surgical techniques are used, there are multiple important differences related to each osteotomy. It is essential for the surgeon to understand these differences in order to provide an effective and safe surgical care for the patient with facial anomalies. Choosing an optimal method of osteotomy depends on many factors, including the indication for treatment, the goal of therapy, patient profile, underlying medical conditions, and the magnitude of surgical movement. The major objective of this chapter is to provide practical guidelines and principles of osteotomies and commonly used techniques. These guidelines are based on a review of the current literature and the author's personal experience. The chapter focuses on the history of orthognathic surgery, anatomical considerations, indications for different osteotomies, and the surgical technique for each osteotomy. Techniques such as the Le Fort I, II, III osteotomies, segmental osteotomies of the maxilla, bilateral sagittal split osteotomy (BSSO), bilateral vertical osteotomy (BVO) genioplasty, segmental osteotomy of the mandible, and the chin wing osteotomy are described.

Keywords: osteotomy, maxilla, mandible, chin, segmentation

1. Introduction

During the last three decades, remarkable advances have been made in surgical techniques and instrumentation for dentofacial surgery. Our knowledge and understanding of all aspects of orthognathic surgery have also grown over time. However, the basic surgical principles have more or less remained unchanged, despite technical innovations. Oral and maxillofacial surgery plays a central role in many aesthetic and functional procedures affecting the face and oral cavity. Since the first reported osteotomy performed on the mandible in the USA in 1849 [1], a large number of improvements have been published in the fields of orthognathic surgery. A well-defined treatment plan is required to ensure a successful treatment outcome. The surgeon should develop and adopt a proper technique for each procedure; using the same surgical sequence enables assisting residents to anticipate each step, thus adopting skills and developing a routine. The leading surgeon should have explicit knowledge on each surgical step. The most common surgical techniques currently used for the correction of dentofacial deformities, with various modifications, are the bilateral sagittal split osteotomy (BSSO) of the mandible, the oblique ramus osteotomy of the mandible, genioplasty, and the Le Fort I osteotomy of the maxilla. Osteotomies of jaw must be performed in a safe way and preferably intraorally to avoid scars on the face and at the same time provide adequate exposure to the skeleton. Essential structures must be preserved, and provision for appropriate nutrition postoperatively should be considered.

2. History

The first reported operation to correct malocclusion was performed in the USA in 1849 by Simon P. Hullihen [1] (**Figure 1**), in a patient with an open-bite deformity secondary to scar contractures of the neck and chest.



Figure 1. Simon P. Hullihen [1] first reported an operation to correct the malocclusion.

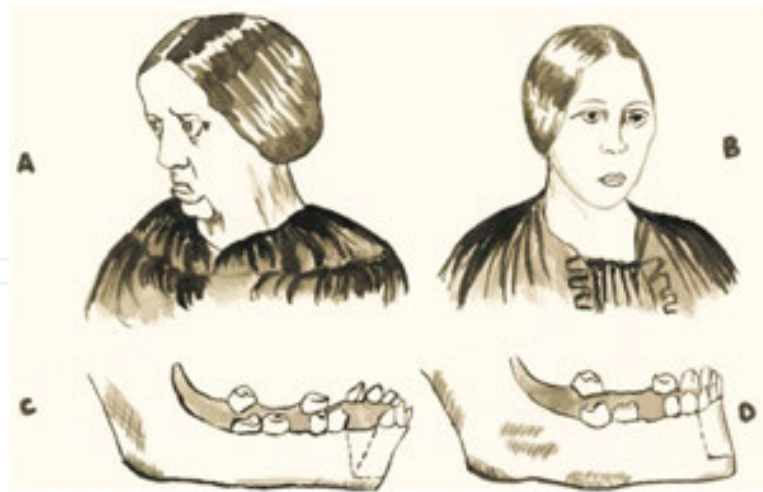

Figure 2. A 20-year-old woman severely burned on the neck at the age of 5 years operated by Hullihen [1] in 1849.

The cicatrix caused a deformity, and her head was drawn forward and downward with the chin frowsty close to the chest. Hullihen [1] performed an operation on the front section of the mandible and removed a wedge-shaped section from the anterior portion of the mandible, by sawing out a V-shaped segment, repositioned it, and fixed it with wire ligatures (**Figure 2**). Although the operation was performed primarily to correct the grotesque facial deformity, Hullihen [1], without formal dental training, had enough vision to reduce the class III malocclusion with bilateral subapical osteotomies. This was performed without having access to anaesthesia, antibiotics, or sophisticated instruments [2]. The development of orthognathic surgery continued in the USA when Steinhäuser and Berger 1897 described osteotomy of the condyle for the correction of prognathism.

Vilray Blair performed the first osteotomy of the mandibular body for the correction of horizontal mandibular excess, in 1907 [3]. He described three distinct problems: (1) cutting of the bone, (2) replacing the segment to a new position, and (3) fixation of the segments. This chapter was written more than 100 years ago but is still of great value.

In 1925, Limberg reported the first subcondylar osteotomy as an extraoral technique; later it was modified into the intraoral vertical subcondylar osteotomy. In the 1950s, mandibular osteotomies were routinely used with more or less predictable results, and publications came subsequently by Blair, Bruhn, Ascher, Obwegeser, Caldwell, and Letterman [4, 5]. Wassmund 1927 suggested a variation of the different subcondylar cuts similar to what is now known as the inverted L osteotomy. An anterior mandibular alveolar osteotomy was proposed by Hofer in 1963 to advance anterior teeth to correct mandibular dentoalveolar retrusion. Caldwell and Letterman developed a vertical ramus osteotomy technique that had the advantage of minimizing traumatic injury to the inferior alveolar neurovascular bundle [6].

A tremendous improvement in cutting the vertical ramus was the sagittal split osteotomy, described by Obwegeser in 1955 [7]. Trauner and Obwegeser published a modification of the same technique in 1957 [8]. Delpont made significant changes in osteotomy design in 1961 [9]. Later, Hunsuck 1968 [10] suggested a minor modification, which decreased trauma to

overlying soft tissues. In 1965, Obwegeser [11] performed complete mobilization of the maxilla for the first time. Relocating the maxilla could be done without tension. Until 1960, a pedicle of the soft tissue of buccal side was still preserved. Bell in 1970 published a paper and stressed that as long as the maxilla is attached to the palatal mucosa, the down fracture of the maxilla including the labial gingiva with complete mobilization can be done with adequate vascular supply [12].

Kent and Hinds, in 1971, presented the use of single tooth osteotomies of the mandible. Macintosh followed this technique with his description of total mandibular alveolar osteotomy in 1974 [13].

David Cheever reported the very first maxillary osteotomy in the USA in 1867 [14], for the treatment of complete nasal obstruction due to a sinus tumour for which a right hemimaxillary downfracture was used. The first time that an entire Le Fort I osteotomy was used for surgical correction of a facial deformity was by Wassmund in 1927. Wassmund introduced Le Fort I, or total maxillary osteotomy, for the treatment of an open bite. The early maxillary osteotomies that were performed in the 1950s were regarded with scepticism because of unpredictable results. After the successful mobilization and repositioning of the maxilla, presented by Wassmund, surgical correction of the maxilla appeared to be accepted from the early 1960s.

Schuchardt advocated the separation of pterygomaxillary junction in 1942. Bell 1975 stated that Le Fort I osteotomy has become a routine procedure in orthognathic surgery. Its simplicity, its broad application to resolve many functional and aesthetic problems, and the dependability of its results support this evolution. The applicability of the osteotomy makes it possible to reposition the maxilla in several directions; however, the setback of the maxilla is difficult because of the pterygoid plates. In the case where elongation of the maxilla is desired, a bone graft is often needed since bone contact will be lost. In modern protocols this can, however, be avoided if a pyramidal osteotomy is performed in the lateral walls of the maxillary complex, making the maxilla slide inferio-anteriorly. In 1949, Moore and Ward [15] recommended horizontal transection of the pterygoid plates for maxillary advancement. However, this technique was abandoned due to the incidence of severe bleeding in most cases. In 1959, Köle [16] suggested interproximal bone segmentation to expedite mobility between tooth bearing segments. He suggested that teeth could be segmented and moved as 'small boxes' through bone remodelling without involving the periodontal ligament. In the 1960s, Obwegeser suggested that the maxilla/maxillary segments should be fully mobilized so that they could be brought into the desired position without tissue resistance. This proved to be a significant advancement in stabilization, as documented by Hogemann and Willmar, De Haller, and Perko, respectively [17].

3. Anatomical considerations

3.1. Blood supply

Blood supply is essential for the healing of osteotomies. Bell and Levey 1969 [18] and 1970 have shown in a study that periosteum is necessary for maintaining the blood supply to the teeth

of a mobile jaw segment [12, 18]. Even when the labial periosteum is raised, care should be taken not to cause any tension or tears. A subapical osteotomy needs to be carefully planned to ensure as large a vascular pedicle as possible. In the lower jaw, the proximal segment of the vertical osteotomy is attached by the lateral pterygoid muscle and temporomandibular joint capsule. In some recent studies, stripping of the muscle attached to the medial segment has been suggested. However, in older literature, it was recommended to keep this muscle attachment intact. Apparently, either approach when used does not show any significant differences in clinical outcomes. However, it is important that the distance between the osteotomy and apices of the teeth is at least 5 mm. Keeping this distance minimizes tooth and pulpal injury, and a mobile segment will have greater vitality to survive by increased vascular supply.

It is advised to handle the soft tissues with care so that adequate collateral blood supply to the osteotomized segment is maintained and injury to other vital structures is avoided.

Prominent vessels to consider when planning orthognathic surgery are the posterior superior alveolar (PSA) artery, greater palatine artery, maxillary artery, pterygoid venous plexus, inferior alveolar artery, and buccal artery (**Figure 3**).

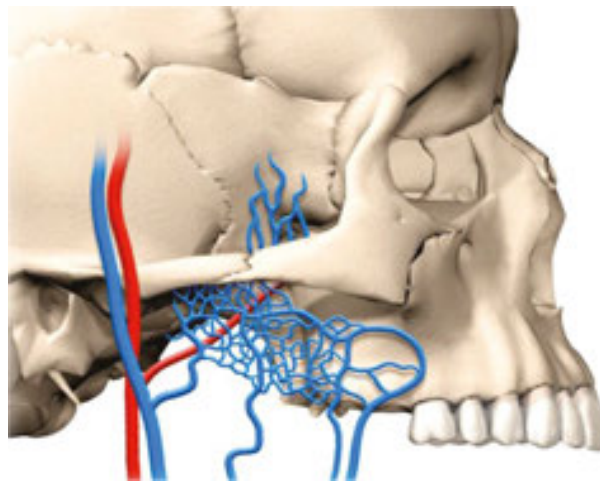


Figure 3. Prominent vessels to consider in orthognathic surgery are the posterior superior alveolar (PSA) artery, greater palatine artery, maxillary artery, pterygoid venous plexus, inferior alveolar artery, and buccal artery.

3.2. Nerves

Facial nerve branches are rarely damaged in orthognathic surgery, but great care should be taken when, for example, an extraoral vertical ramus osteotomy is performed. The course of the inferior alveolar nerve through the mandibular canal is at increased risk of injury when any osteotomy is carried out in the mandible. Bradycardia and asystole may occur during downfracture or mobilization of the maxilla due to the trigeminal-cardiac reflex. This can happen as a result of manipulation of the central or peripheral portions of the trigeminal nerve during mobilization of the maxilla [19]. All patients can experience varying degrees of dysesthesia some months postoperatively such as numbness, hypaesthesia, or tingling, most

commonly after BSSO [20]. Patients who undergo Le Fort II and III osteotomies may experience infraorbital nerve sensory dysfunction.

3.3. Muscles

Muscles are, as mentioned earlier, important in orthognathic surgery. On the one hand, they are essential for blood supply to the segments, and on the other, they have an impact on relapse. Surgery can affect muscles in two different ways; they can change the length and direction of function. The muscles that can be affected by orthognathic surgery are the suprahyoid group of muscles and the masticatory muscles.

4. Osteotomies in the maxilla

4.1. Le Fort I

Wassmund 1927 [21] described this osteotomy. In 1969, Obwegeser reviewed and modified the technique [22]. An intraoral incision, 3–4 mm above the attached gingiva at maxillary vestibular fornix, is made from the second premolar of one side to the opposite side. A mucoperiosteal flap is raised exposing maxillary walls. Modern protocols [23–26], however, advocate a less extended incision with an opening in the incisor region only. The infraorbital nerve must be identified, and the dissection will then extend to the level of infraorbital nerve to simplify the following osteotomies and to achieve direct control of periorbital tissues. During the exposure, great care should be taken not to expose the buccal fat pad. Before the bone osteotomy, a nasal mucosa mobilization is performed from the wall of the nasal cavity. The osteotomy is carried out with a burr, saw, or piezo machine, starting from the lateral aspect of the piriform aperture and extended to the posterior aspect of the maxilla towards the zygomatic buttress as backwards as possible and inferiorly (**Figures 4 and 5**).

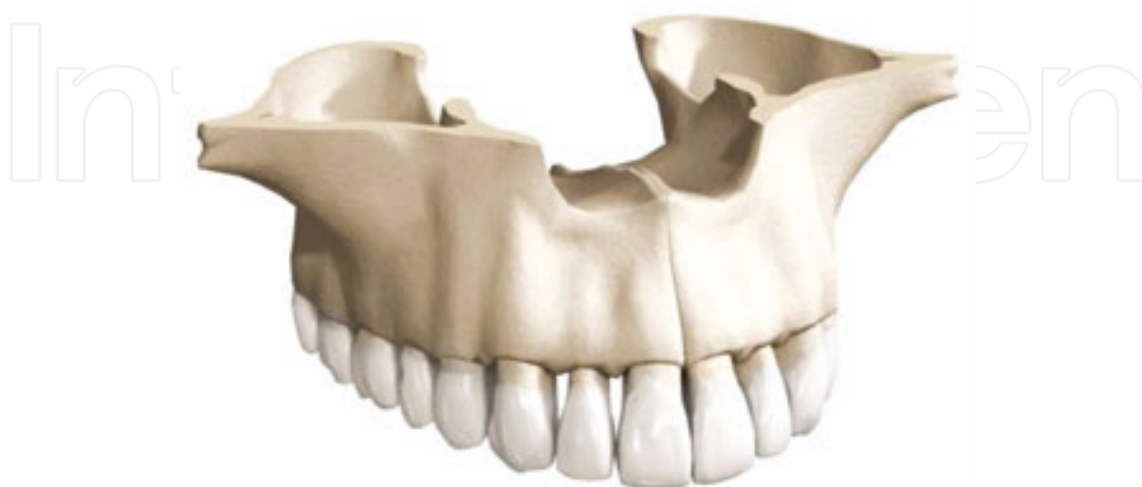

Figure 4. Schematic picture of a Le fort I Osteotomy

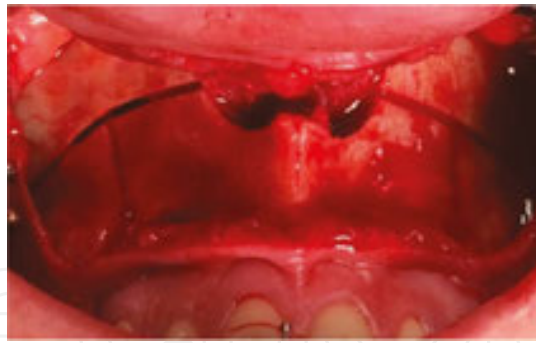


Figure 5. Frontal view of a Le Fort I osteotomy performed by a piezo saw with a nice cut.

The same is done on the opposite side. These osteotomies are completed with a chisel, to detach the nasal septum and lateral wall of the nasal cavity. The osteotomy of the nasal septum and separation of septal cartilage from the anterior nasal spine is usually made by chisel. Finally, it is important to separate the pterygomaxillary junction by using a curved chisel lateromedially to simplify the mobilization of the maxilla. After the last detachment of the maxilla is done, downfracture can be performed. The advantages of this osteotomy are full mobilization, speed, simplicity, direct vision, the safety of segmentation, and reduced risk for relapse. An alternative to the separation of the pterygomaxillary junction is a vertical osteotomy in the tuber region of the alveolar crest. This method will, however, not enable the same degree of mobility. It is fixated using miniplates.

Over many years, the precision of the operative technique and establishment of a scientific and biological basis for the procedure has been established. The Le Fort I osteotomy has become an essential procedure in the surgical armamentarium for correction of dentofacial deformities.

4.2. Segmented Le Fort I osteotomy

In cases of open bite or when a transversal expansion is required in the maxilla, a Le Fort I osteotomy approach can be combined with a multiple-piece osteotomy to correct an unfavourable curve of Spee or a transverse discrepancy. The maxilla can be sectioned into 2, 3, 4, 5, or 6 segments depending on the indications (**Figures 6–8**).

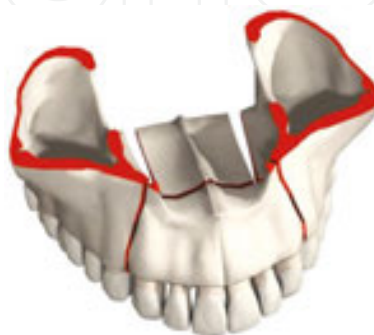

Figure 6. Segmentation of maxilla into 4 pieces.

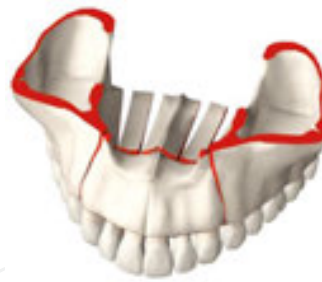

Figure 7. Segmentation of maxilla into 6 pieces.

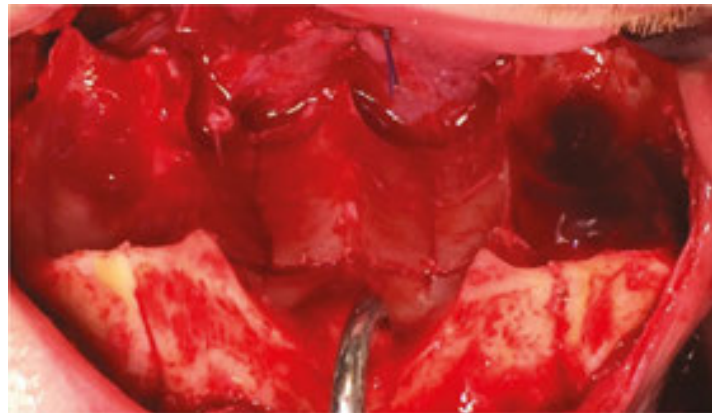


Figure 8. Clinical view of segmented maxilla.

A median osteotomy is made by a Lindeman burr or piezo at the lateral aspect of the median palatal suture. When a two-segment osteotomy is planned, one median cut is performed only on the side of the palatal suture. This cut will be connected consequently to a vertical interdental osteotomy that will be placed between the canine and first bicuspid teeth on the same side (**Figure 9**).

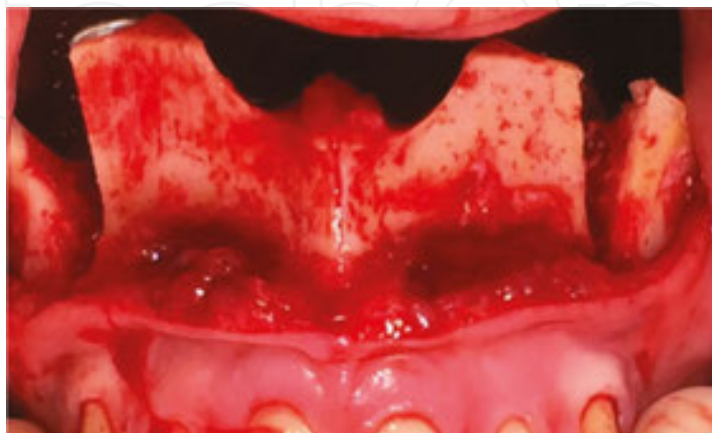


Figure 9. A vertical interdental osteotomy placed between the canine and first bicuspid teeth on the same side.

Another option of vertical osteotomy is to place the vertical interdental osteotomy between the lateral incisor and canine [23-30]. In both cases, the interdental osteotomies are combined with palatal osteotomies but from a superior angle without raising a palatal flap. When a four-piece segmentation is required, two parallel osteotomies are performed on each side (**Figure 6**). These osteotomies will consequently be connected to each other by an oblique osteotomy and subsequently to the vertical interdental osteotomy placed between the canine and first bicuspid or between the lateral incisor and canine. It is essential to keep the palatal mucosa intact. Careful sectioning when performing the interdental osteotomies is mandatory to avoid injury to the tooth roots and their blood supply. This approach allows placement of the maxillary segments in different directions since they are detached.

In some cases, a high Le Fort I osteotomy is required for advancement of the entire midface to improve the extraoral profile of the facial skeleton (**Figure 10**).

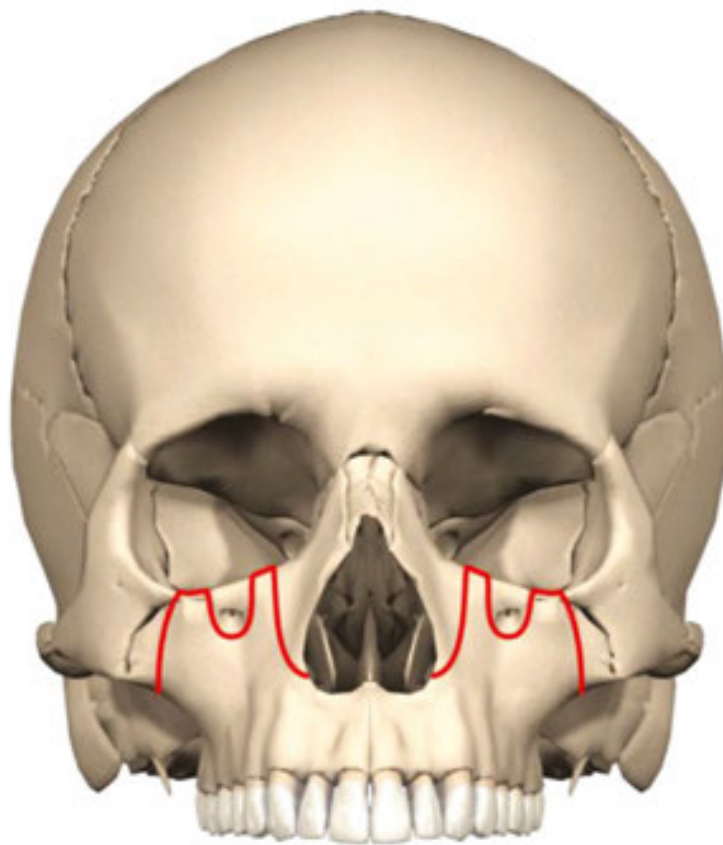


Figure 10. In some cases, a high Le Fort I osteotomy is required for advancement of the entire midface to improve the extraoral profile.

4.3. Le Fort II

The indication for this osteotomy is when a forward, downward movement of the nasal and maxillary complex is necessary for correction of the midface. This osteotomy is performed in the upper midface, between the frontal facial unit and above Le Fort I (**Figure 11**).

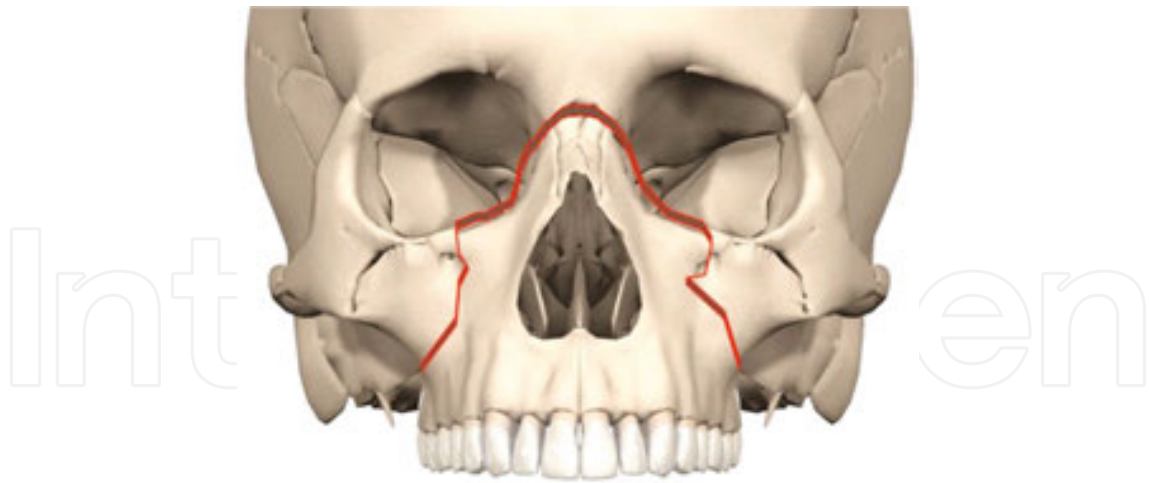


Figure 11. Le Fort II osteotomy is performed in the upper midface, between the frontal facial unit and above Le Fort I.

The approach has its place where there is a need for the correction of nasomaxillary hypoplasia [31, 32]. This osteotomy is also called a pyramidal naso-orbital maxillary osteotomy. The Le Fort II osteotomy includes the naso-orbital ethmoidal (NOE) fracture line, the zygoma laterally, and internal part of the orbit. This osteotomy was first presented by Henderson and Jackson in 1973. Surgically, an incision is performed obliquely to the paranasal region extending to the infraorbital rim to the medial canthus and over the nasal bone. The Le Fort II osteotomy is relatively rare because it is not required as often (only in 2% of dentofacial anomalies cases, such as in Apert, Crouzon Treacher Collins syndromes). Other indications are a skeletal class III malocclusion in combination with maxillary-zygomatic deficiency, maxillary-alveolar-palatal cleft deformity, and nasomaxillary deficiency [28]. The osteotomy allows lengthening of the nose along with the movement of the upper jaw in selected cases where this effect is desired.

Steinhauser, 1980, described three different surgical approaches namely anterior-, pyramidal, and quadrangular osteotomies [33].

To get surgical access for the Le Fort II osteotomy, a V-shaped incision with the apex at the glabella is made to extend bilaterally along both sides of the nose to reach just above the alar base. The columella of the nose is pulled down, and the cartilaginous and bony part is separated. Osteotomy starts at the bottom of the nasal bone towards the medial wall of orbit towards the floor of orbit posterior to the nasolacrimal apparatus. Then it continues to the infraorbital margin medial to the infraorbital nerve and extends to the alveolar bone posterior to the second premolar. A flap in the posterior buccal area is raised. The osteotomy is completed through the intra oral incision towards the pterygoid plates. In cases with deficiency in the infraorbital area, the cut can be continued to the zygomatic buttress before going down towards the pterygoid plates. Downfracture of the midface can be done. The segment can be advanced after mobilization. Fixation can be done either by an acrylic splint or by fixation plates. In this approach, bone grafts should be used to restore the bone deficiencies. It is crucial to have skin coverage, and nasal lining must be provided. The nasolacrimal apparatus must not be damaged.

4.4. Le Fort III

Sir Harold Gillies and colleagues presented the Le Fort III osteotomy for the first time in 1951. The technique was improved by Paul Tessier in 1967 making five different variations mainly regarding the osteotomy of the lateral wall of the orbit [34]. The Le Fort III procedure is designed to move the entire midface forward including the portions of the eye sockets to get a more balanced appearance in whom facial disharmony results from panfacial hypoplasia. This technique is used in various craniofacial syndromes such as Apert, Crouzon, Treacher Collins, etc.

Those patients who have a total retrusion of the midface often have a retrusion of the nose, cheeks, inferior orbital rims, and upper lip. Patients with Crouzon, Apert's, and Pfeiffer's syndrome often have a hypoplastic nose. In some cases, it will be necessary to complete a Le Fort III with a Le Fort I osteotomy to make the appropriate adjustment for optimal aesthetics and occlusion. One more detail to keep in mind is the intercanthal distance and level of attachment of the medial and lateral canthal tendons. Epker et al. 1980 [35] suggested that this method is more aesthetic, and function of the lacrimal sac is better when dystopia of the medial canthal tendons or telecantism does not exist.

The bicoronal approach is preferred and often utilized in Le Fort III osteotomies. The incision is a coronal flap to lift the full-face skin combined with subciliary, subtarsal or transconjunctival incision, and intraoral vestibular incisions. The dissection of the supraorbital rim includes decompression of the supraorbital nerve by an osteotomy on the supraorbital rim to release the nerve (Figure 12).

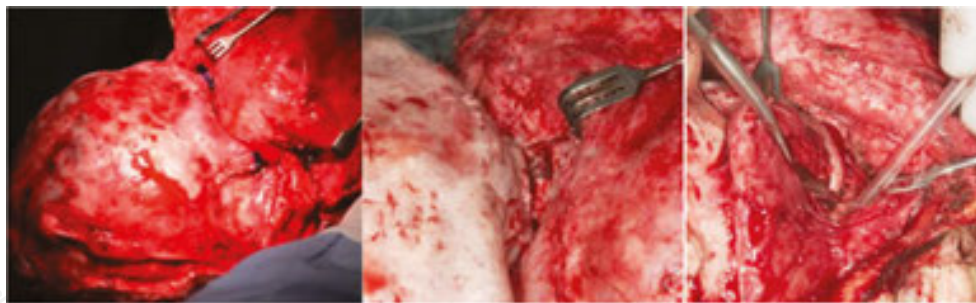


Figure 12. The dissection of the supraorbital rim includes decompression of the supraorbital nerve by an osteotomy on the supraorbital rim to release the nerve. The incision extended to the lateral orbital rim, nasion, and through the zygomatic arch via a coronal incision.

After releasing the nerve, nasal bone, medial canthal tendons, and superior part of the lacrimal sac, the lateral and inferior orbital rims are exposed.

The osteotomies start at the glabella using a horizontal cut (Figure 12). The medial canthal tendons should be either left intact or reflected off or reached with a suture. The lacrimal fossa is exposed below this area with the accompanying lacrimal sac. Care should be taken not to interfere with the ethmoidal artery that is located about 25 mm back in the orbit. Thus, the cut can be applied only 12–15 mm posteriorly avoiding the ethmoidal artery. If the medial canthal distance is average, the cut can be placed anterior to the medial canthal tendon, leaving the

tendon untouched. If any subciliary or subconjunctival incision is made, the cut of the medial wall can be done via a chisel. A horizontal cut is then performed across the orbital floor extending to the lateral orbital rim. At the lateral orbital rim, the cut of the lateral wall can be carried out in the middle, but depending on the deficiency of the lateral rim it can be more superior or inferiorly placed according to Tessier I, II, and III. By elevating the anterior part of the temporal muscle, direct access to the retro-orbital and infratemporal space is gained. To detach the pterygomaxillary junction, an intraoral gingivobuccal incision as described for Le Fort I is used. It is also possible to separate the junction via bicoronal approach.

In some cases, a glabella incision together with bilateral subciliary incisions and oral vestibular incisions is utilized. With that approach, the osteotomies start at the glabella section through a horizontal incision in the skin. This cut continues to the middle part of the orbital rim with the same care mentioned earlier at the medial section of the orbit, downwards to the inferior orbital rim through the subciliary incision. The incision is then extended to the lateral orbital rim and finally through the zygomatic arch through an intraoral incision back to the pterygoidomaxillary junction that is detached by a chisel (**Figure 13**).

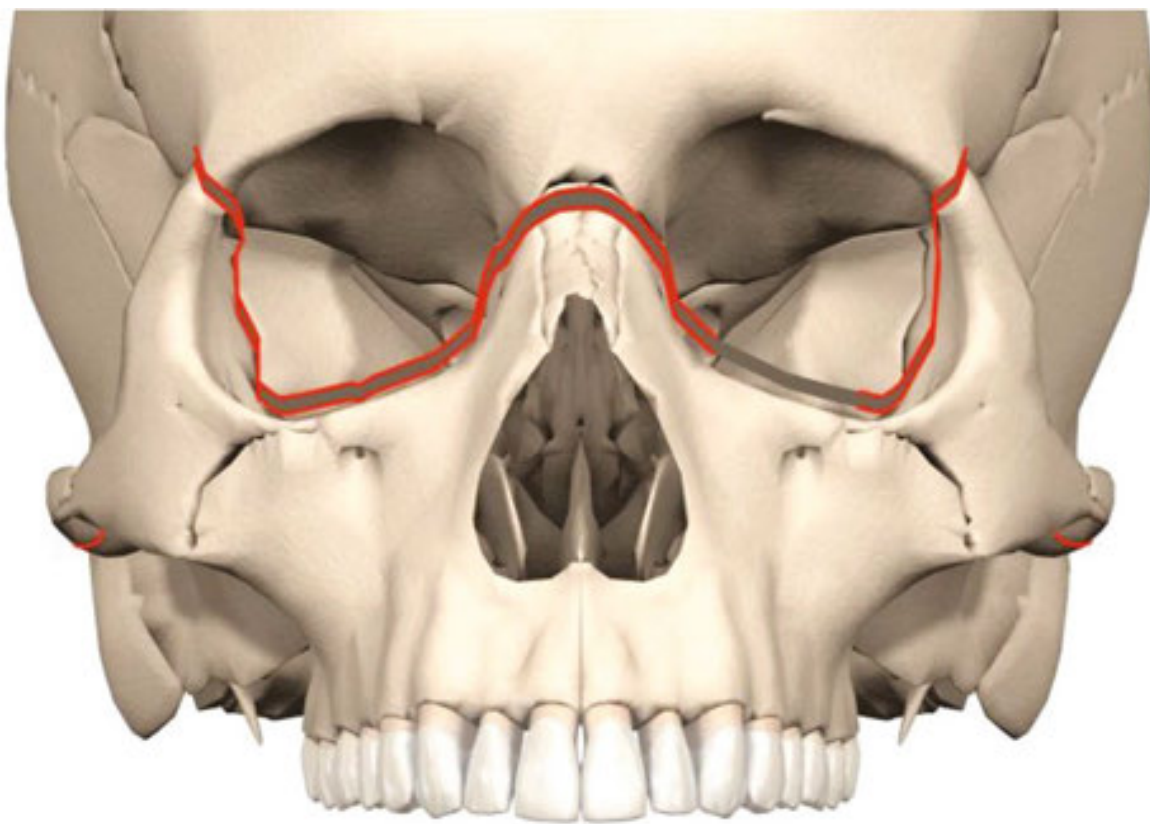

Figure 13. *Le Fort III* The incision extended to the lateral orbital rim, nasion, and through the zygomatic arch via a coronal incision, through an intraoral incision back to the pterygoidomaxillary junction that is detached using a chisel.

Rowe's forceps are then used to mobilize Le Fort III. Garcia and colleagues recently suggested some changes in this technique [36]. This method can be used in combination with distraction osteogenesis resulting in a very good outcome (**Figures 14–16**).

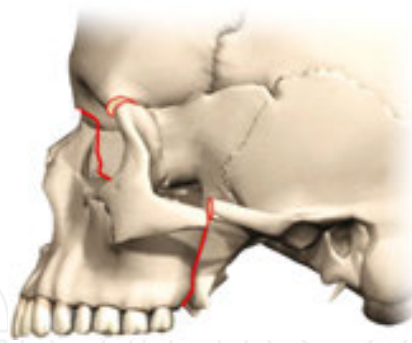


Figure 14. Le Fort I osteotomy can be used in combination with distraction osteogenesis resulting in a very good outcome. The mobilized midface is at the zygomatic region and paranasal bony anchored to the distractor. At the end of distraction, the midface is advanced. Note the increase of pharyngeal volume compared with the preoperative situation.

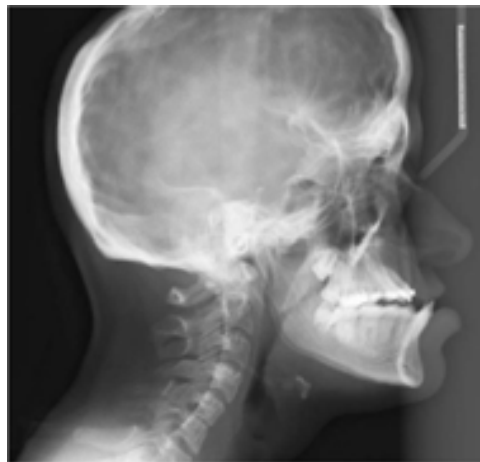

Figure 15. Lateral radiographic projection showing the preoperative view

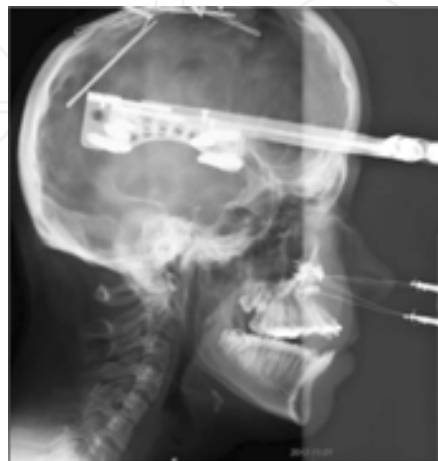

Figure 16. Lateral view after surgical correction with large anterior movement of the maxilla with distraction

4.5. Monobloc

The so-called monobloc craniofacial surgery is used for craniofacial advancement in combination with distraction osteogenesis and is used for children with complex craniosynostosis syndromes. A bicoronal incision will be used, following a standard fronto-orbital osteotomy. After separating the frontal bone flap, a forceful forward protrusion of the frontal lobe is noticed suggesting high intracranial pressure from the craniosynostosis. After that, the orbital bandeau is separated by the aid of a piezo saw. A Le Fort III osteotomy should then be performed. The osteotomy line should pass the arch of zygomatic, from the spheno-zygomatic suture across the floor of the orbit, continuing behind the nasolacrimal duct. After that, it should continue along the lacrimomaxillary suture to the nasal bone (**Figures 17 and 18**). The nasal septum must be separated from the perpendicular plate of the ethmoid bone with a chisel or straight osteotome. Next, the pterygoid plates must be separated with a chisel as described in Le Fort I osteotomy at pterygomaxillary fissure. The viscerocranium can then be mobilized. Rowe's forceps can be used for mobilization of the viscerocranium for rotation downwards.

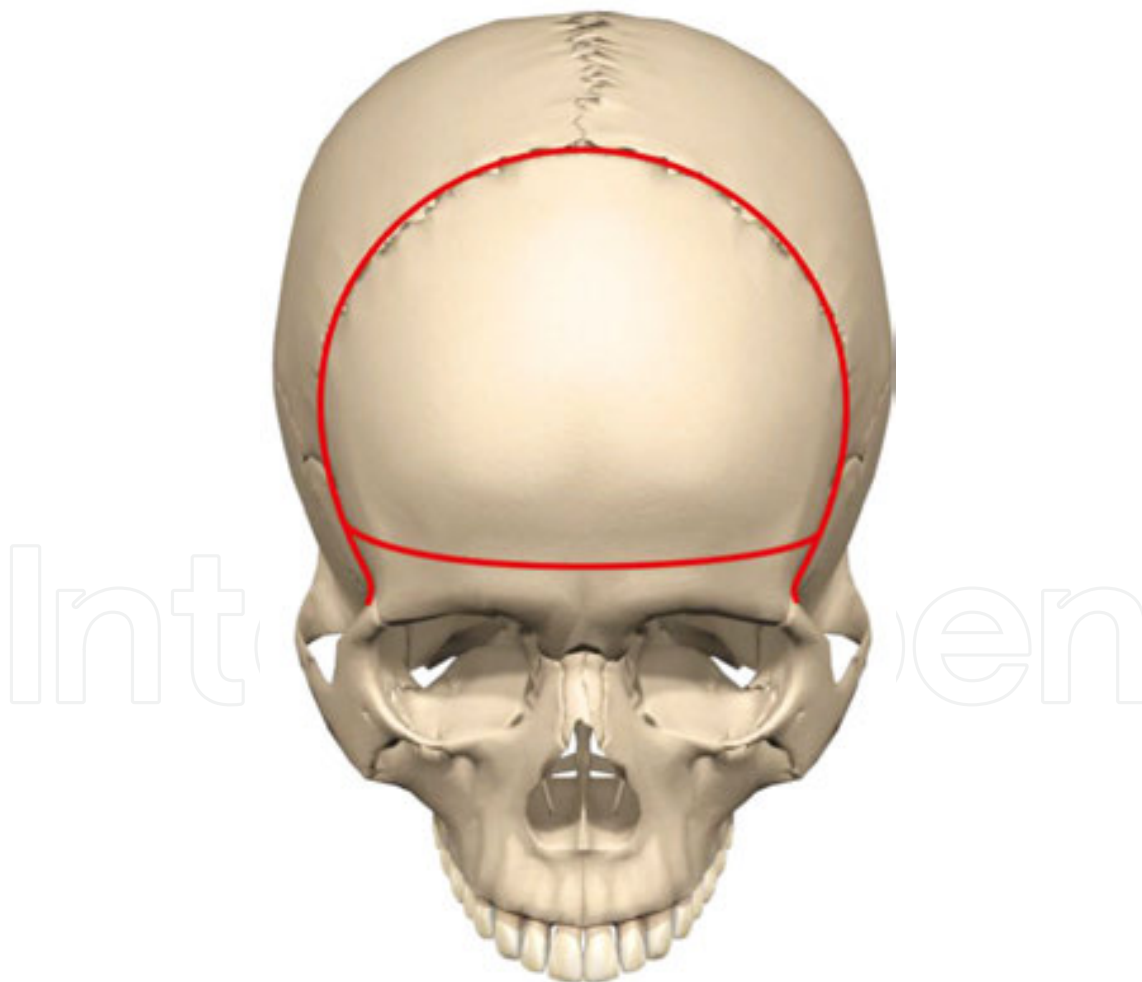


Figure 17. *Monobloc* The forehead, superior orbital rims when a monobloc approach is performed from a frontal point of view.

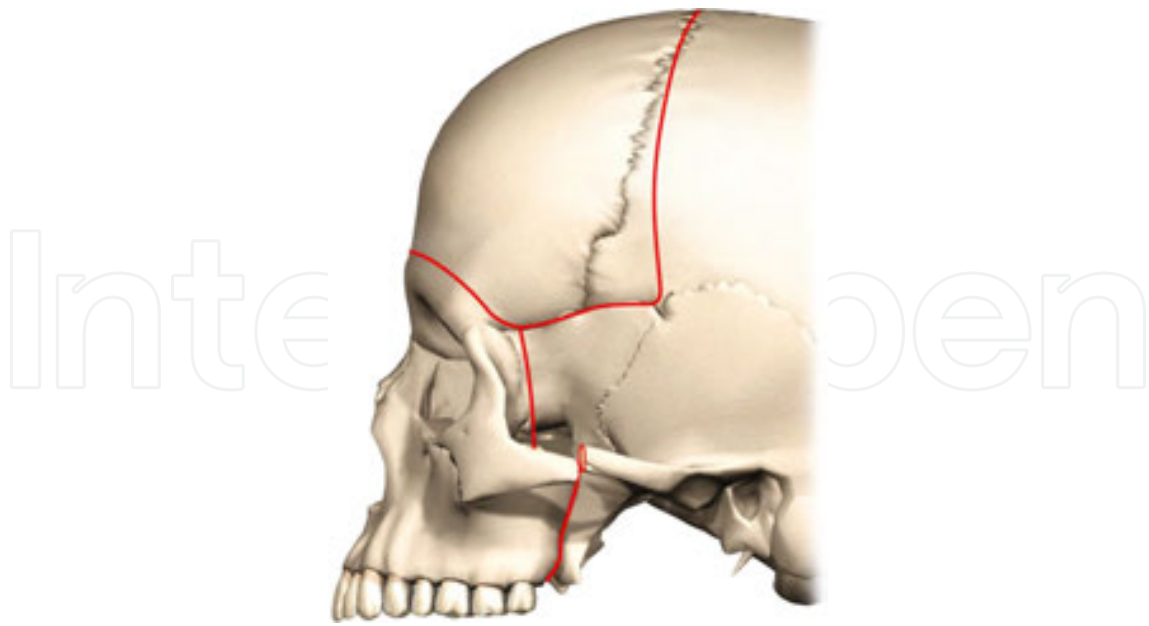


Figure 18. The monobloc approach seen from a sagittal point of view.

4.6. SARME

Surgical assisted rapid maxillary expansion osteotomy (SARME) or surgical assisted rapid palatal expansion osteotomy (SARPE) (SARME/SARPE expressions are used interchangeably) is one of the most commonly performed orthognathic techniques. The terminology is somehow confusing since this approach includes both maxillary and palatal expansions. The terminology includes only one part and is, therefore, inaccurate [37]. It was used and described first by

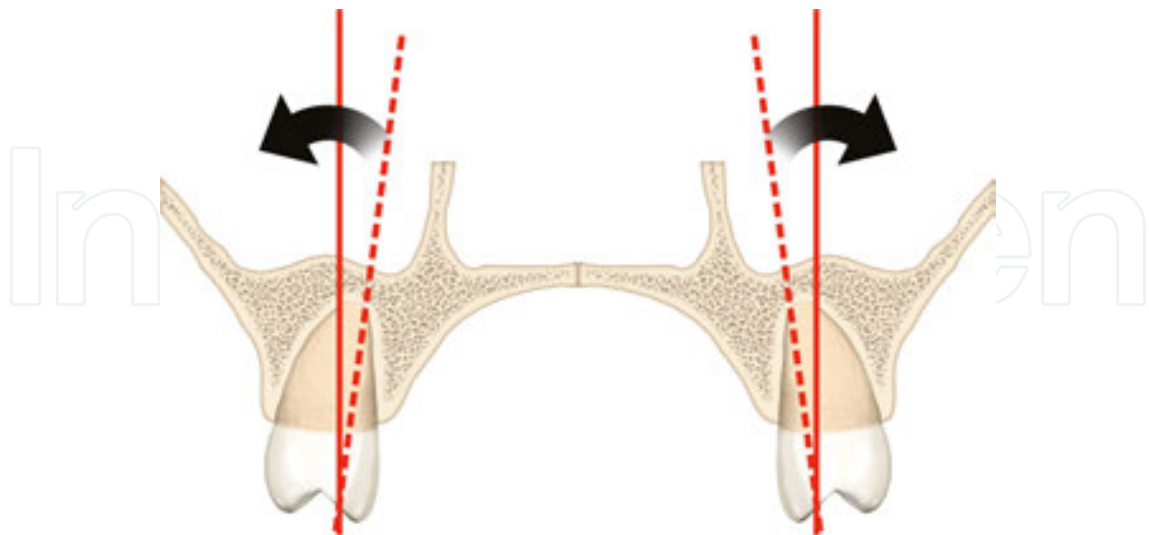


Figure 19. Important to avoid orthodontic tilting of molar teeth. When the median suture is fused, attempting to widen the palatal suture by orthodontic treatment only cause buccal displacement of teeth with a very high risk of relapse. A widening of the dental arch without tilting of the teeth is only possible by a surgery.

Brown in 1938. The most common indications for SARME are a transverse discrepancy in the maxilla, failed orthodontic expansion, significant nasal stenosis, and widening of the arch following collapse associated with the cleft palate deformity. This procedure is often used for patients between 16–20 years when the median sutures of the palate are fused. When the median suture is fused, attempting to widen the palatal suture by orthodontic treatment only causes buccal displacement of teeth with a very high risk of relapse (**Figure 19**). Therefore, in those patients, a widening of the dental arch without tilting of the teeth is only possible by a surgically assisted osteotomy together with orthodontic expansion.

The approach is similar to Le Fort I osteotomy as described above. A medial osteotomy is performed carefully with an osteotome following the suture. The activation of the expansion device is preferably done so the expansion can occur quickly. Proper care must be taken not to perforate the soft tissue in the gum with a chisel and not to damage the central incisor roots. Once the separation is done, the expansion device deactivates again. The activation of the device for expansion of the palatal can first be started one week post-operatively. In some cases, an anterior expansion is needed, only then the pterygoid-maxilla junction can be kept untouched. If posterior expansion is planned, a similar detachment between the posterior maxilla and pterygoid plate is done as described previously for a traditional Le Fort I osteotomy (**Figure 20**).

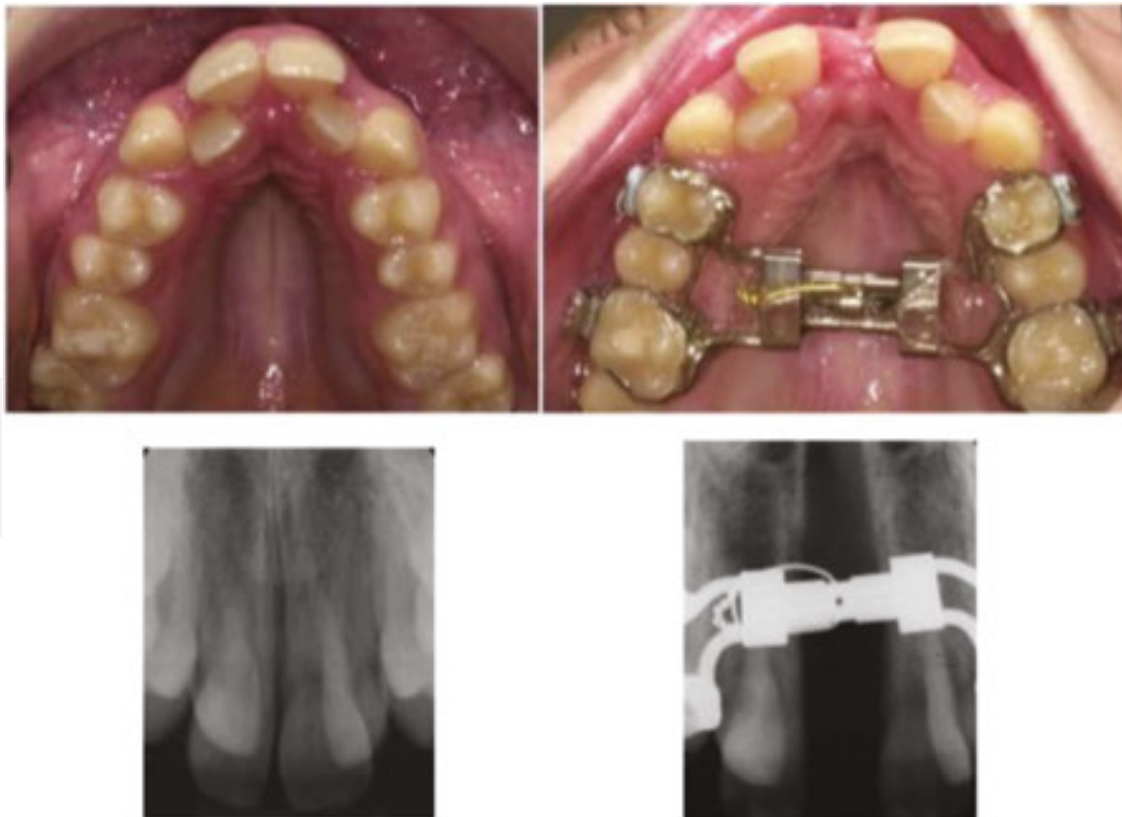

Figure 20. If the posterior expansion is planned, a similar detachment between the posterior maxilla and pterygoid plate is done as described previously for a traditional Le Fort I osteotomy.

The expansion device extends over the palate with an attachment, and by the use of a screw-driver it can spread the bony segments (**Figure 20**). The expansion of the maxilla may take some weeks depending on how far the plate needs to be expanded. The expansion is 1 mm per day. Transversal expansion of the mandible is possible in the same way but is a very unusual approach.

4.7. Anterior segmental maxillary osteotomy

This technique is applied when repositioning of the premaxilla in a vertical plan is required such as for frontal open bite, to retract the anterior teeth, when orthodontic treatment cannot accomplish the desired movement (e.g., when teeth are ankylotic or when a deep bite is present). Cohn-stock (1921) [38] was the first surgeon who reported this technique. A mucosal incision is applied in the buccal side of the maxilla above the roots of the incisors. This incision is extended to the distal section of the first bicuspid bilaterally. It is common to use a micro saw or piezoelectric device, followed by chisel since a high risk of injury to tooth roots exists. Consequently, osteotomies are performed after extraction of first bicuspids. After that, a transverse palatal incision is made following a wedge-shaped osteotomy to provide a green stick fracture. This osteotomy can be done either by performing a Le Fort I osteotomy or by a restricted buccal vestibular incision, allowing direct access to the anterior lateral maxillary walls, piriform aperture, nasal floor, and septum (**Figure 21**).

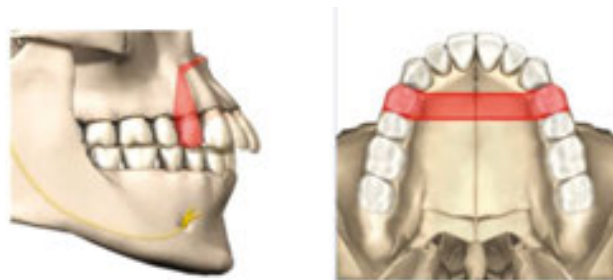


Figure 21. Anterior segmental maxillary osteotomy can be done either by performing a Le Fort I osteotomy or by a restricted buccal vestibular incision, allowing direct access to the anterior lateral maxillary walls, piriform aperture, nasal floor, and septum.

The anterior segmental maxillary osteotomy can cause some complications such as oronasal or oroantral fistula, damage to the teeth, loss of vitality of teeth, complication with the maxillary sinus and nasal cavity, unfavourable nasolabial aesthetics, and nasal septal deviation. The most common complication with anterior segmentation is a retraction of gingiva in the anterior segment and relapse during the early healing phase. This method has been revised and discussed widely in the literature by Epker 1977 [39], Epker and Wolford 1980 [35], and Wunderer 1985 [40].

4.8. Posterior maxillary segmental osteotomy

The technical difficulties concerning approaches to the posterior maxillary segmental osteotomy have been emphasized. The indications are mainly uni- or bilateral posterior open bite.

The cut is performed at the buccal vestibular section of the posterior maxilla 5 mm above the root apices (**Figure 22**).

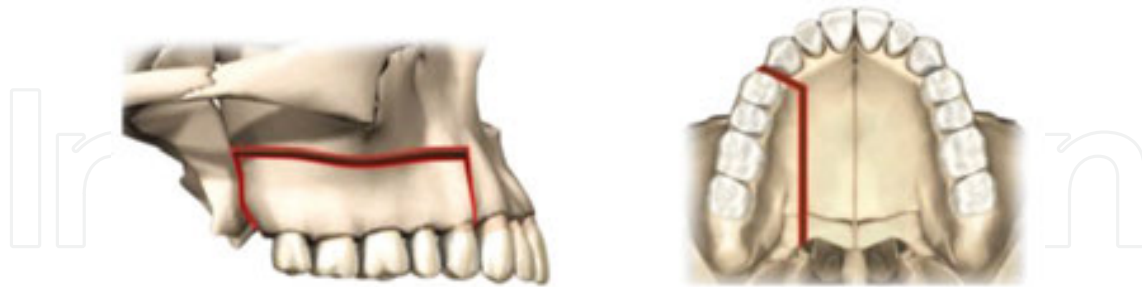


Figure 22. The cut is performed at the buccal vestibular section of the posterior maxilla 5 mm above the root apices.

The access to the bone is made through a horizontal cut in the buccal vestibule extending from the second molar to the distal aspect of the canine. The incision continues vertically to the papillae at the distal aspect of canine and distal aspect of the second molar. It is preferable to extract the molar in advance some months before this approach. After a horizontal cut, if an interdental vertical osteotomy through the extraction sites (in cases extraction is needed) and also a posterior vertical osteotomy at the pterygomaxillary junction is done, the palate will remain in original position, but the dentoalveolar complex will be separated and moved to the planned position. After a buccal vestibular incision, a parasagittal palatal incision is performed without any vertical interdental incisions (**Figure 22**).

The method is somewhat complicated since multiple areas of bony contacts may interfere. A Le Fort I osteotomy is more often used for correction of the posterior maxillary deficiency. There are, however, a number of indications for this approach namely maxillary hyperplasia, distal replacement of the posterior maxillary alveolar fragment to provide space for proper eruption of an impacted canine or bicuspid posterior open bite, posterior cross bite or scissors bite, and anterior open bite correction through bilateral impaction of the posterior parts.

Complications related to this approach are the loss of teeth vitality, relapse, necrosis of segment, and periodontal defects.

4.9. Combination of anterior and posterior maxillary osteotomy (Horseshoe osteotomy)

Paul Tessier in 1969 [34] reported this procedure for midface hypoplasia. It has also been described and further developed by West and Epker 1972, Hall and Roddy 1975, Wolford and Epker 1975, West and McNeil 1975, Hall and West 1976, and Maloney 1982. Palatal parasagittal osteotomies are performed with a piezoelectric device. The hard palate is untouched staying in position. The method creates a three-piece maxilla with the central nasal portion left undisturbed. This is a complicated technique since multiple areas of bone contacts exist. The indication is maxillary alveolar hyperplasia or transverse hypoplasia without a vertical component. The method has more or less been replaced by the traditional Le Fort I osteotomy (**Figure 23**).

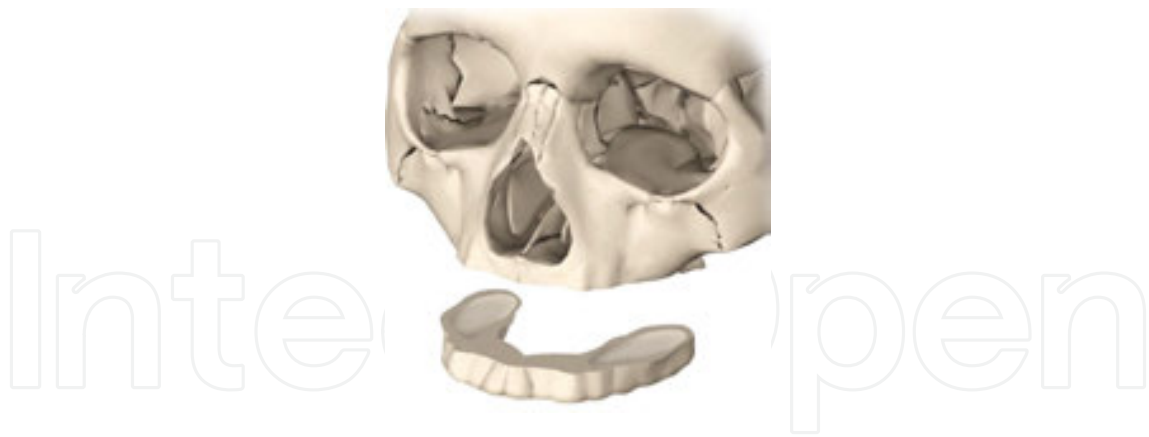

Figure 23. The horseshoe osteotomy; this method has more or less been replaced by the traditional Le Fort I osteotomy.

5. Osteotomies of mandible

5.1. Bilateral sagittal split osteotomy (BSSO)

The original bilateral ramus osteotomy by Trauner and Obwegeser [41] is performed in the ramus above the mandibular foramen. Dal Pont et al. [42] in 1961 modified this to the vertical osteotomy of the body of the mandible combined with lower horizontal osteotomy with an advantage of easy splitting. Hunsuck [10] in 1968 recommended the shorter horizontal cut that should only extend to the mandibular foramen at the medial ramus (**Figure 24**).

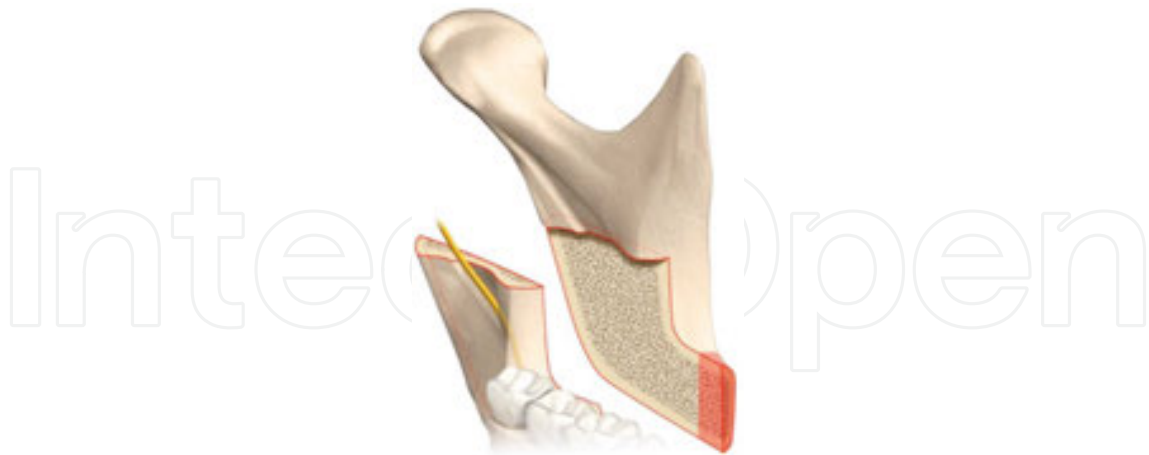

Figure 24. Hunsuck's shorter horizontal cut only extends to the mandibular foramen in the medial ramus.

This procedure is used to correct retrognathism and mandibular prognathism. Mandible advancement, setback, rotation, and in some cases closing of the an open bite is possible. The incision is made through the mucosa, muscle, and periosteum, down to the bone on the lateral aspect of the anterior border of the ramus midway up to the ascending ramus and downwards

into the depth of the vestibule ending mesial to the second molar. It is advisable to leave 7–8 mm of non-keratinized buccal epithelium for ease of suturing [10, 43].

Dissection of the periosteum starts subperiosteally along the anterior border of the ramus upwards the coronoid process. Dissection should be limited only to areas where the osteotomies will be performed and muscle attachments that need to be separated from the bone. No lateral dissection of the ascending ramus is needed. By using a coronoid notch retractor, soft tissue over the ascending ramus can be elevated. At medial section, the soft tissue is retracted gently to avoid damaging the inferior alveolar nerve. The inferior alveolar neurovascular bundle as it enters the mandibular foramen should be identified and supported by a medial retractor. The stylomandibular ligament and the medial pterygoid muscle can be stripped from the angle of the medial aspect.

The sagittal osteotomies can then be started by using a Lindeman fissure bur through only the medial cortex and extended just posterior and superior to the lingual about 2 mm above the inferior alveolar neurovascular bundle. It is advised that the horizontal cut at the medial section of the mandible is made through the whole length of the lingual cortex to avoid an unfortunate split (**Figure 24**). But it is still possible to extend the horizontal cut in the medial section of the mandible just some mm behind the inferior alveolar neurovascular bundle.

When the osteotomy is completed on the medial aspect of the mandible, the next cut is performed on the lateral aspect of the anterior ramus posterior to the second molar. This cut is made parallel and directly adjacent to the lateral cortex. Finally, the osteotomy is extended from approximately the first to second molar downwards vertically just inside the buccal cortex and ends at the base of the mandible [10, 43, 44]

The medial section of the mandible base should be included in the osteotomy. Chisels are then used to control the cut through all osteotomies. Usually, two osteotomes are used as levers to separate the segments: one of the osteotomes places in the vertical osteotomy and the other one in the horizontal osteotomy site behind the second molar. It is important to keep in mind that in cases where the separation does not proceed favourably, it is better to stop the procedure and identify the problem. The problem should be diagnosed and solved to avoid an unfortunate split. It is important that when the split is done, it will in effect separate the lateral proximal section from the cancellous bone, and the inferior alveolar nerve will remain in the distal segment, and the nerve should not be injured.

If the alveolar canal (including the nerve) is attached to the proximal segment during the splitting procedure, the canal should be carefully dissected from the proximal part, but this will increase the sensory morbidity of the inferior alveolar nerve. The separation of nerve from proximal section of the ramus is debated in the literature. In our experience, the nerve can be left in the proximal segment if the fixation material does not pinch it, and if the movement of the fragments is not too much. Thus, the nerve must be easily moveable in the mandibular canal. As soon as the separation of the layers is done, the surgeon should check that the osteotomy is done accurately, and the neurovascular bundle is intact and separate from the proximal segment (**Figure 25**).

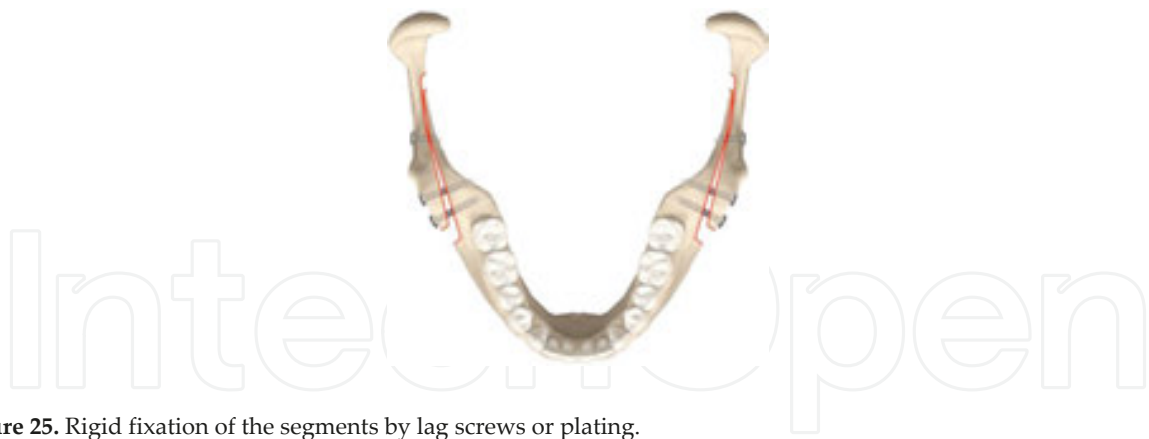


Figure 25. Rigid fixation of the segments by lag screws or plating.

5.2. Vertical ramus osteotomy

5.2.1. Extraoral

In the early 1950s, Caldwell and Letterman [6] popularized an osteotomy performed in the ramus of the mandible for the correction of mandibular excess. This technique is mainly used for the correction of asymmetry of the mandible [37, 45-47]. In this procedure, the lateral aspect of the ramus is exposed through a submandibular incision. The incision is marked about 2 cm below the inferior border of the mandible base, in the angle region. The length of the skin incision is about 4 cm long. Dissection is made through the skin and all the covering soft tissues over the platysma are carefully undermined. An incision is then performed on the platysma to the next layer as deep as to the superficial layer of the deep cervical fascia. The marginal mandibular branch of the facial nerve passes through this layer. Thus, extreme care should be taken. As soon as this layer is dissected, the masseter muscle will be exposed which can be cut

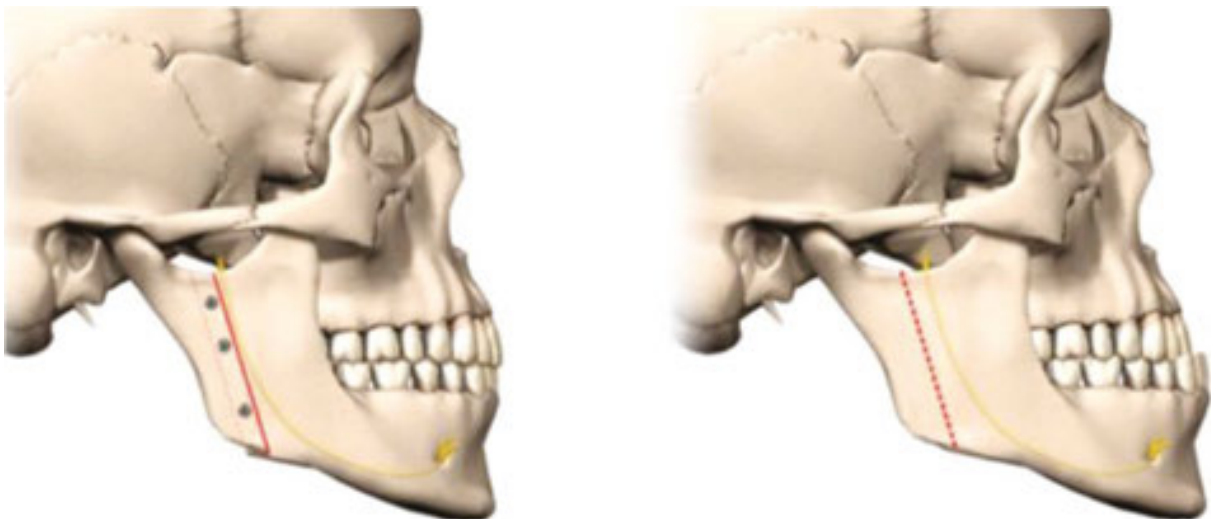


Figure 26. Vertical ramus osteotomy is suitable for posterior repositioning of the mandible.

with a knife. From here, dissection can be continued posteriorly to the gonial notch and superiorly subperiosteally to expose the ascending ramus laterally. Before starting the osteotomy, the medial pterygoid muscle should be released from the medial part of the angle. The ramus is osteotomized in a vertical direction, posterior to the foramen where the mandibular inferior nerve enters. The cut can be done superiorly from the sigmoid notch to the angle of the mandible. This osteotomy is suitable for posterior repositioning of the mandible (**Figure 26**).

It is also possible to perform an inverted L osteotomy, where a horizontal cut from the anterior section of the ascending ramus is made just below the coronoid process extending to the vertical osteotomy from the angle of the mandible. The entire body and anterior ramus section of the mandible are moved posteriorly, which places the teeth in proper occlusion. The proximal segment of the ramus that is attached to the condyle will overlap the anterior part of the jaw that includes the teeth and will be stabilized during the healing phase with wiring or plating of the bone segments combined with using elastic mandibulomaxillary fixation.

5.2.2. *Intraoral*

A similar technique can be done through an intraoral incision and an angulated oscillating saw or piezo saw. The design of the osteotomy is identical to that performed through an extraoral incision. The incision is performed via an intraoral entrance. This procedure has, at least, two advantages namely elimination of the risk of damage to the facial nerve and elimination of the risk of a visible scar postoperatively. The main disadvantage with the intraoral approach is that it is difficult to perform since visibility is limited (Hall et al. 1975) [48]. Additionally, fixation of the fragments is difficult.

Previously, it was common to use mandibulomaxillary fixation (MMF) for 5–7 weeks postoperatively when this approach was used. A rigid, internal fixation can be used but MMF must be considered for a short period.

5.3. **Genioplasty**

The chin is a critical part of the face. A disharmony in the chin is very noticeable and should be corrected in an artistic way [49]. Each of the different skeletal deficiencies (e.g., class II and III deep bite or open bite) can cause a morphology change of the chin that is very different between individuals even if the dentofacial deformities are similar.

Correction of a chin deficiency can be performed by reducing or augmenting in three different dimensions namely vertically, transversely, and sagittally. This correction can be combined with any operation in both maxilla and mandible. Augmentation genioplasty, reduction genioplasty, straightening genioplasty, and lengthening genioplasty are some procedures that can be used (**Figures 27–30**).

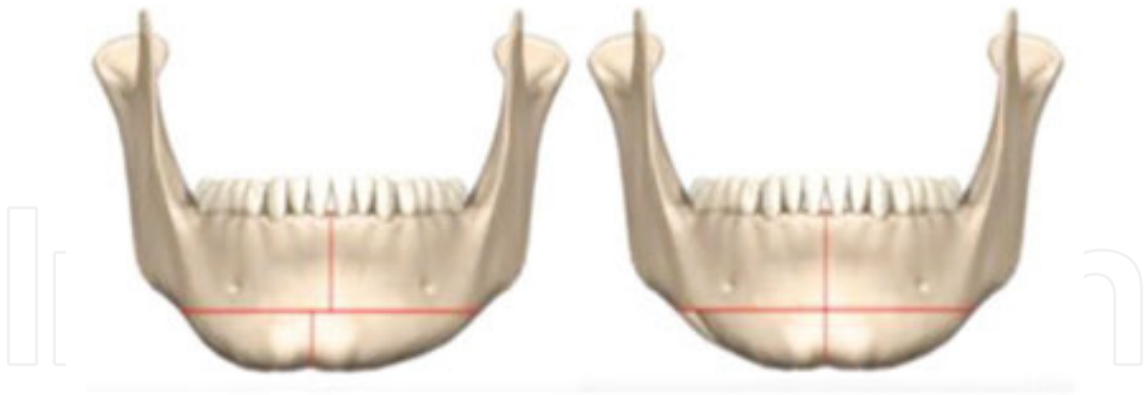

Figure 27. It is highly important to mark the midline of the chin before any osteotomy is performed.

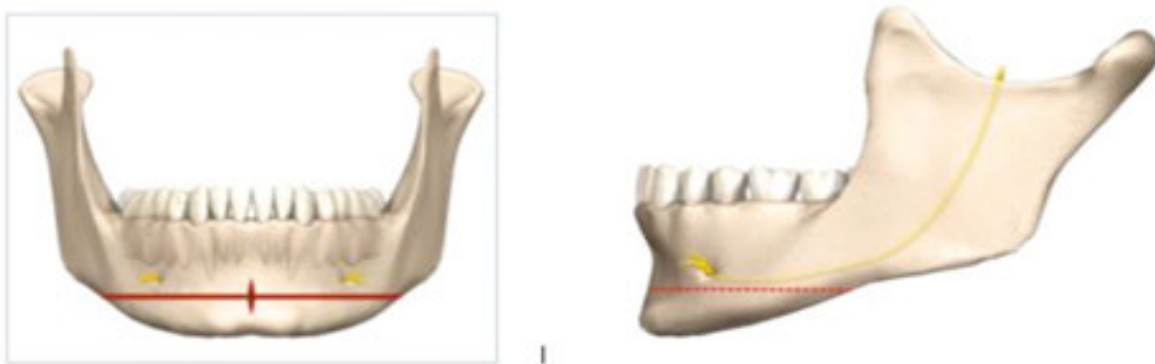


Figure 28. The midline can be marked as a reference point using a burr or saw. A plus (+) sign can be used to mark the bone in the centre of the buccal cortex.

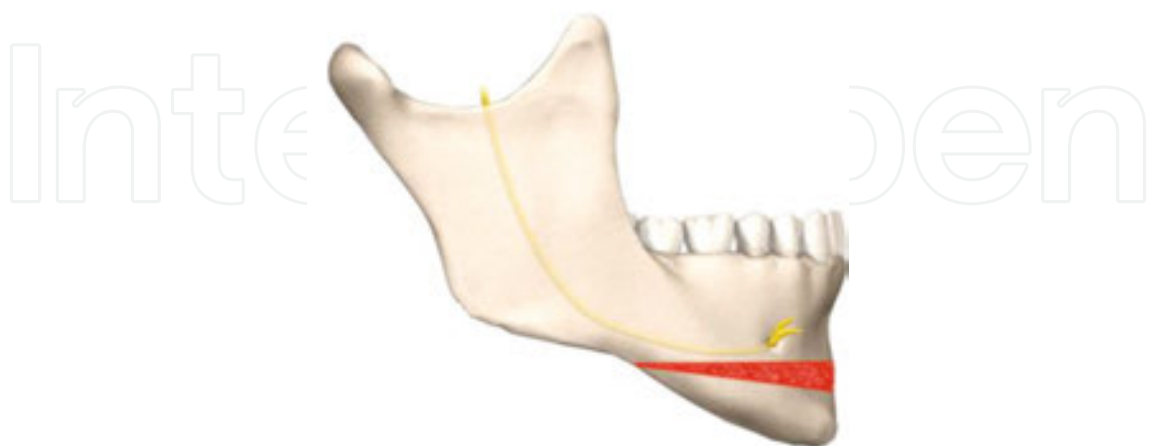


Figure 29. Lengthening or reduction of the chin by the so-called sliding osteotomy. In the case of reduction, a slice of the bone is removed and in the event of augmentation, the chin is pulled forward and sometimes downwards. Additional bonegraft material may be used to improve the augmentation.

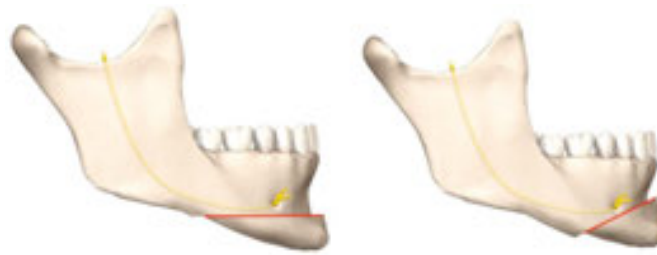


Figure 30. Augmentation genioplasty, reduction genioplasty, straightening genioplasty, and lengthening genioplasty are some procedures commonly used.

The most common osteotomy is sliding horizontal osteotomy [49, 50]. However, double horizontal osteotomy, hinge sliding osteotomy, oblique osteotomy for advancement, jumping genioplasty, wedge osteotomy, propeller genioplasty, triple osteotomy, quadruple osteotomy, and genioplasty using grafts or implants are also used.

A transoral incision is performed in the mucosa from the canine to canine with a good margin from the attached gingiva to make suturing easier. The mental muscles must be exposed and dissected to expose the bone. The second incision is made through the periosteum on to the bone. The periosteal attachment will be released, but the inferior anterior border should be untouched to keep the soft tissue contour unchanged and also keep the blood circulation intact. It is crucial to identify the mental foramen bilaterally. Then, the midline should be marked as a reference point, e.g., by using a burr or saw. A plus (+) sign can be used to mark the bone in the centre of the buccal cortex (**Figure 28**).

The osteotomy starts below the apical level of the roots (**Figure 28**), with a piezo ultrasonic or reciprocating saw. The osteotomy should be well planned with regard to chin shape and type of deficiency. Posteriorly, the angulation of the osteotomy can be altered depending on the treatment demands. This angulation results in the changes in vertical dimension of the anterior mandible. The posterior osteotomy must end at least 7–8 mm below the mental foramen (**Figure 30**) to avoid injury to the nerve bundle. The nerve canal is at about 5 mm below the mental foramen. When increasing the vertical dimension of the chin, bone can be applied to the gap. When reduction of the vertical dimension is planned, a parallel osteotomy to the first one can be performed and the segment in the middle can be pulled out (**Figure 29**).

The transverse dimension of the chin can be altered by segmentation of the symphysis area (**Figure 27**). If reducing the transverse dimension of the chin is planned, two parallel vertical osteotomies are performed laterally to the midline. The wound should be sutured in two layers. It is important to ensure the accurate position of the mental muscles before suturing the mucosa [49, 50].

5.4. Chin-wing osteotomy

In 2009, Albino Triaca described a different osteotomy, called chin wing osteotomy, for the correction of aesthetic dislocation of the lower face, either in the anterior part of the mandible

or for the entire border of the mandible base [51]. The name of the approach was coined due to the fact that the shape of the mandible base is like a wing (**Figure 31**).

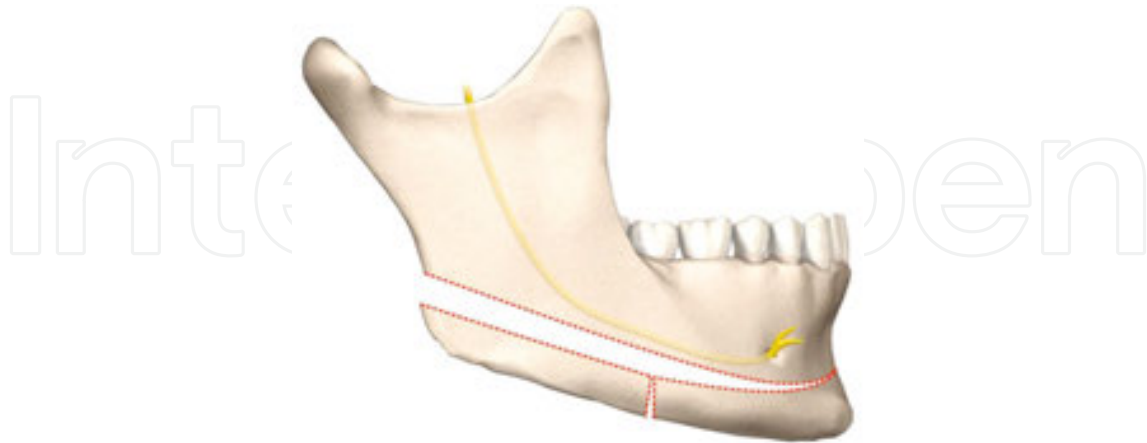


Figure 31 . Chin-wing osteotomy.

The incision is always intraoral and along the entire border of the mandible from the mandibular ramus to the opposite site below the dental arch. The mucoperiosteum will be raised to the same level of the cortex where the Chin-wing osteotomy is planned. It is important not to strip the periosteum caudally to allow a new blood circulation to the mandible. Particular care is taken near the mental foramen. Before performing this osteotomy, careful examination and identification of the location of the nerve bundle and canal is required by CBCT examination. The inferior mandibular nerve should not be placed buccally because the osteotomy is performed from the buccal cortex, and angulation of the osteotomy is in a somewhat sloping direction from superior to inferior below the nerve canal. A horizontal bicortical mandibular cut is then done with piezo-ultrasonic, reciprocating saw or a Mayfair bur (Maillefer Instruments, Ballaigues, Switzerland). The anterior region of the mandible can be cut in one or two segments. After osteotomy of the entire mandible, mobilization should be carried out very carefully not to fracture the mandible. The most dangerous place for fracture is around the mental foramen. Using this method, a change of the base of the mandible is possible, and the shape of the chin prominence can be adjusted sagittally and transversely without changing the tooth-bearing mandible and without influence on the Temporomandibular joint (TMJ). The method can also be combined with other osteotomies of the face [52, 53].

5.5. Lateral body osteotomy of the mandible

This osteotomy is widely used in selected cases of mandibular prognathism. This method is used especially when first or second premolars are missing or are planned to be extracted, and by using this method, a prosthetic reparation of intact teeth can be avoided. It is also desirable to use this method in the case of an anterior open bite, excess growth of the mandible with negative overjet located in the anterior dentoalveolar area of the mandible, to treat mandibular dental arch asymmetry.

This method can be used to reposition the anterior section of the mandible in every desirable direction, such as for posterior and superior repositioning. The method can be used for a block osteotomy or segmental or total alveolar osteotomy (**Figure 32**).

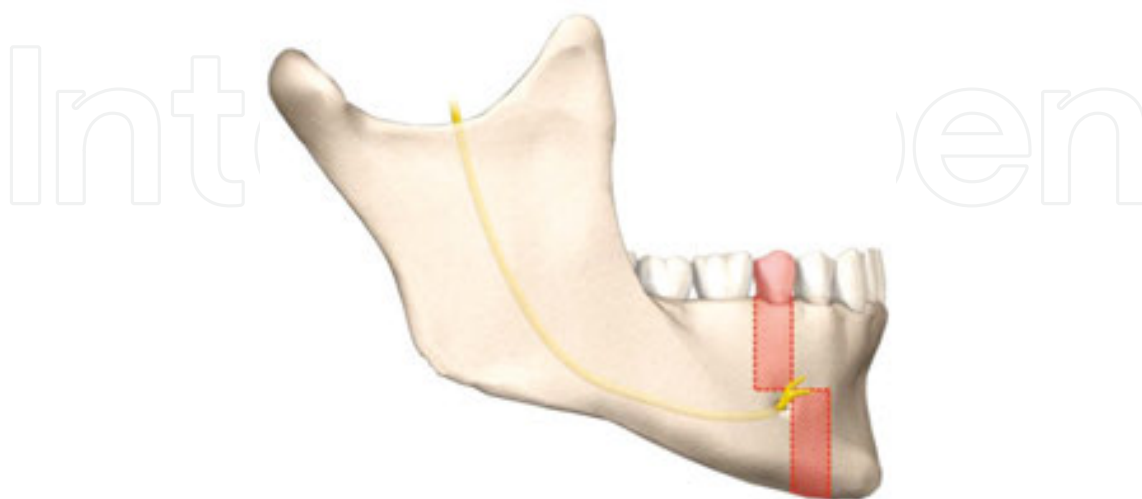


Figure 32. Lateral body osteotomy can be used for a block or segmental osteotomy or total alveolar osteotomy.

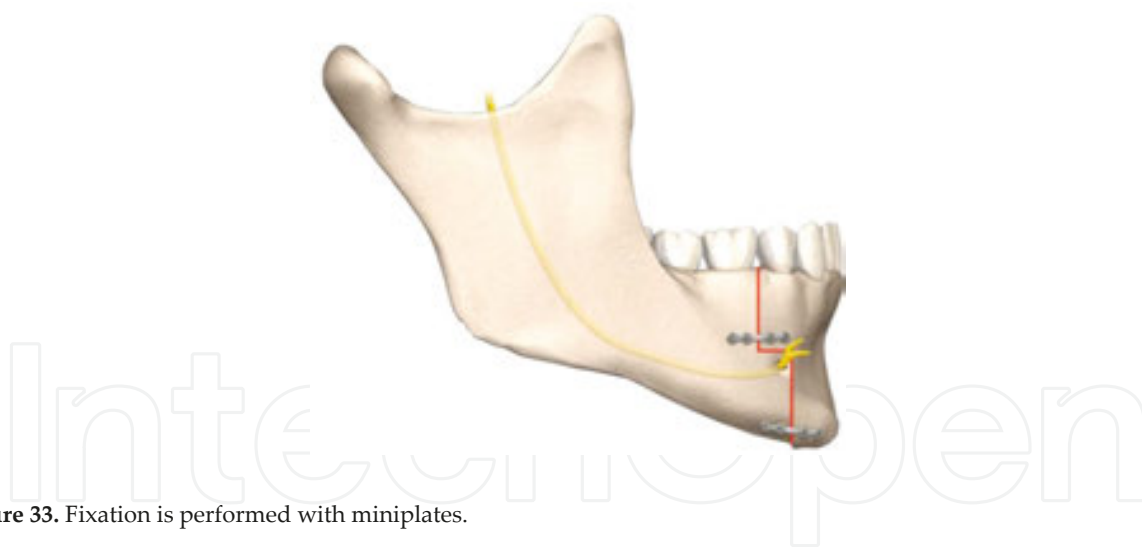


Figure 33. Fixation is performed with miniplates.

A transoral circumvestibular incision is performed following the extraction of the first premolars. The periosteal attachment will be released, but the inferior anterior border should be untouched to keep the soft tissue contour unchanged, and also keep the blood circulation undisturbed. An incision is made distally to the second premolar. The flap should be extended behind the second premolar to give sufficient access to the area. Care should be taken not to cause any unnecessary soft tissue stripping. The subapical area will then be exposed enough to achieve proper exposure for osteotomy. The osteotomy is horizontally placed subapical about 5 mm from the root apices and then will be connected with two vertical osteotomies at

the extracted first premolars. The horizontal osteotomy ends about 2–3 mm anteriorly to the mental foramen. The vertical osteotomies are preferably positioned at the extraction sites. Often, the vertical incision is performed with an anterior step osteotomy to avoid the inferior alveolar neurovascular bundle (**Figure 33**).

In this osteotomy, removal of premolar teeth and bone in the area of extraction sites is desired. After downfracture and separation, the anterior segment is repositioned posteriorly, at the same time extraction sites are closed. If no extraction is planned, the anterior section can be repositioned upwards to close an anterior open bite. The bone graft should be placed into the gap. It is important to remember to keep the excessive interdental bone to avoid periodontal problems.

5.6. Anterior subapical osteotomy

Anterior subapical osteotomy is suggested when the skeletal class I relation exists, and deformities in the front part of the mandible cannot be treated by orthodontic treatment. Some of the indications are as follows:

- Excess growth of the mandible with negative overjet located in the anterior dentoalveolar process of the mandible,
- The negative curve of Spee
- Some particular types of open bite
- Mandibular dental arch asymmetry
- When a lateral body osteotomy is planned, but the position of the chin is satisfactory

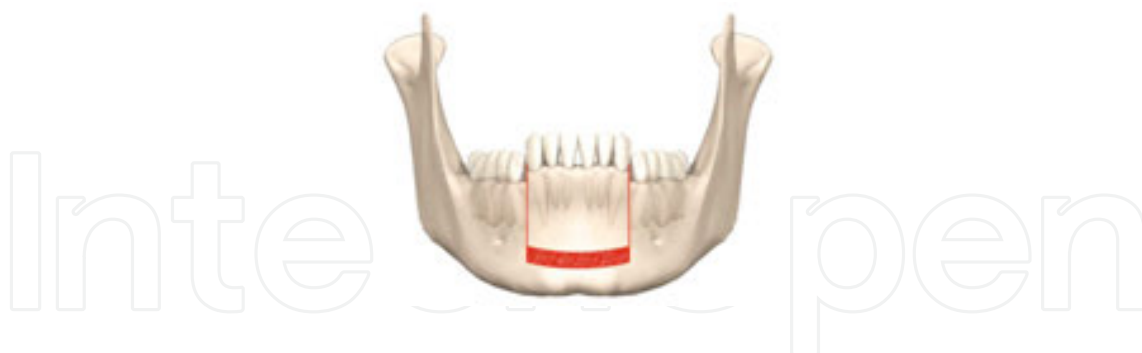


Figure 34. The subapical area is exposed far enough to provide sufficient access for the osteotomy.

Anterior subapical osteotomy method can be used to reposition the anterior section of the mandible in every desirable direction, such as posterior and superior repositioning.

A transoral circumvestibular incision is performed in the mucosa from canine to the canine with a good margin of attached gingiva. The periosteal attachment will be released, but the inferior anterior border should be untouched to keep the soft tissue contour unchanged, and also to keep the blood circulation undisturbed. After identifying the neurovascular bundle, the incision is extended carefully in the posterior direction to the premolar area. The flap should

be extended behind the first premolar to give sufficient access to the area. The mental muscles are identified and dissected to expose the bone. Care should be taken not to cause unnecessary soft tissue stripping. The subapical area will then be exposed far enough to provide sufficient access for the osteotomy (**Figure 34**).

The osteotomy is horizontally placed subapical, about 5 mm from the root apices and then connected with two vertical osteotomies between the canines and first premolars. Interdental osteotomy is performed with care to avoid injury to the roots. The anterior segment is subsequently repositioned superiorly to close the anterior open bite, and a bone graft is placed into the gap area. It should be kept in mind that interdental bone is essential to avoid periodontal problems.

5.7. Posterior subapical osteotomy

This method can be used for the correction of supereruption of mandibular posterior teeth or ankylosis of the posterior teeth.

A transoral incision is performed at the anterior border of the vertical ramus and is carried forward to the canine area. The incision is made around the margins of the teeth with starts one tooth behind the proposed osteotomy anteriorly and posteriorly. Two vertical, oblique incisions are connected to the horizontal. The periosteal attachment is released, but the inferior border is untouched to keep the soft tissue contour unchanged, and also to keep the blood circulation undisturbed. Again, the neurovascular bundle is identified and the incision is extended carefully in an anterior direction to the premolar area (**Figure 35**).

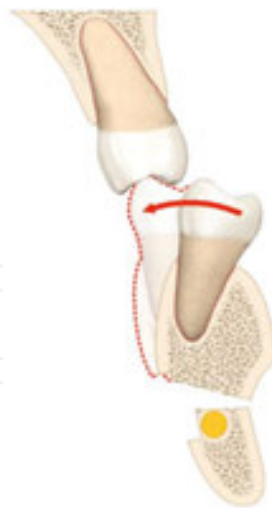

Figure 35. The neurovascular bundle is identified and preserved.

The osteotomy is horizontally placed subapical, about 5 mm from the root apices, and special care must be taken to preserve the mandibular canal. The horizontal osteotomy is connected with two vertical osteotomies between the first molar and second premolars. Interdental cuts should as always be done carefully with a chisel to avoid injury to the roots. The vertical

interdental cut is to be made from the buccal after downfracture and separation. The posterior segment can then be repositioned superiorly.

5.8. Inverted L and C ramus osteotomies

Trauner and Obwegeser presented inverted L and C ramus osteotomies in 1957 [35]. Indications for this osteotomy are horizontal mandibular deficiencies. This approach can be performed extraorally in the same way as vertical ramus osteotomy (**Figure 36**).

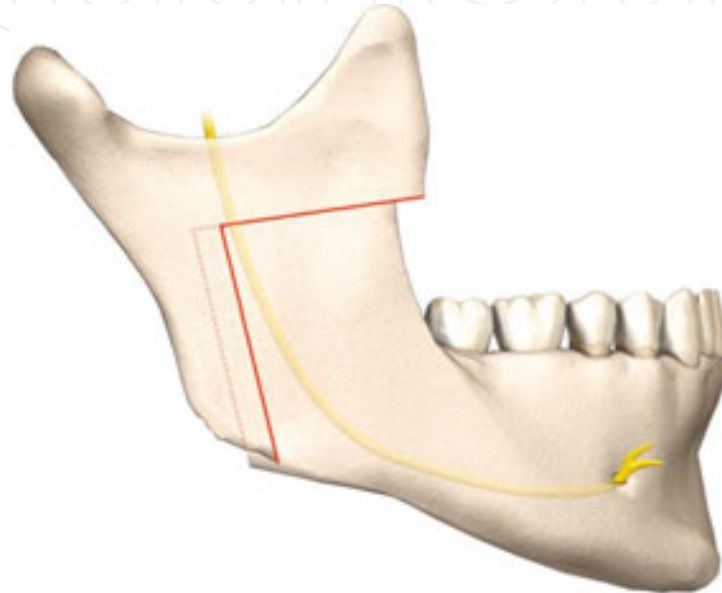


Figure 36. Extraoral inverted L ramus osteotomy.

The incision is very much like bilateral vertical ramus osteotomy. It starts with a 6 cm sub-mandibular cut 2 cm below the angle of the mandible in the inferior border. Exposure of the entire ramus is done very carefully by dissection through the different layers of soft tissues.

A vertical osteotomy is placed behind the mandibular foramen to avoid nerve damage. This vertical osteotomy starts at the base of the mandible and is connected to a horizontal osteotomy that is placed above the mandibular foramen and below the sigmoid notch. For setback of the mandible, the proximal segment is placed laterally. The segments can be fixed rigidly by plates, or left without fixation, but then maxillomandibular fixation (MMF) for 6 weeks will be needed.

If an increasing of the vertical height or horizontal direction is planned, a bone graft can be placed in the osteotomy.

Acknowledgements

Thanks to Mr. Farat Kanat for the contribution of hand-drawing figures in this chapter and Mr Fredrik Persson, Pixlar.se for all computerized drawings.

Author details

Hossein Kashani* and Lars Rasmusson

*Address all correspondence to: mail@drkashani.se

Department of Oral and Maxillofacial Surgery, The Sahlgrenska Academy, University of Gothenburg, Gothenburg, Sweden

References

- [1] Hullihen SP. Case of elongation of the under jaw and distortion of the face and neck, caused by burn, successfully treated. *Am. J. Dent. Sci.* 1849; 9:157.
- [2] Kruger G. Textbook of oral and maxillofacial surgery. The CV Mosby Company. St Louis, Toronto, London 1979
- [3] Blair VP. Operations on the jaw bone and face. *J. Oral Surg.* 1907; 4: 67–78.
- [4] Ascher F. Zum problem der chirurgis chen obilisierung des prognathen oberkiefer.mit.telstuckes in kieferoothopaedischer sincht. *Fortschritte der kiefer und Gesichts-Chirurgie*, vol–1. Stuttgart; 1955. *Chirurgie*, vol-1. Stuttgart; 1955. 16(1):81–8.
- [5] Bruhn C. The surgical-orthopedical removal of the deformations of the jaws. *Int. J. Orthod.* 1927; 13:65.
- [6] Caldwell JB, Letterman GS. Vertical osteotomy in the mandibular rami for correction of prognathism. *J. Oral. Surg.* 1954; 12:185.
- [7] Obwegeser H, Trauner R. Zur operationstechnik bei der progenie und anderen unterkieferanomalien. *Dtsch Zahn Mund Kiefer-heikd.* 1955; 23:H1–2.
- [8] Trauner R, Obwegeser H. The surgical correction of mandibular. *Oral Surgery, Oral medicine, Oral Pathology*, 1957 (Elsevier, Volume 10, issue 10, July 1957, p 677–689.
- [9] Dal Pont G. Retromolar osteotomy for the correction of prognathism. *J. Oral Surg. Anesth. Hosp. Dent. Serv.* 1961;19:42.
- [10] Hunshuck EE. A modified intra-oral sagittal splitting technique for the correction of mandibular prognathism. *J. Oral Surg.* 1968; 26:250–3.
- [11] Obwegeser H. Surgery of the Maxilla for the correction of prognathism.. *SSO Schweiz Monatsschr Zahnheilkd.* 1965 Apr;75:365–74.
- [12] Bell WH, Levy BN. Revascularization and bon regeneration after anterior mandibular osteotomy. *J. Oral Surg.* 1970; 28:196–203.

- [13] MacIntosh, RB. Total mandibular alveolar osteotomy. *J. Maxillofac. Surg.* 1974; 2:210–8.
- [14] Cheevers DV. Naso-pharyngeal polypus, attached to the basilar process of occipital and body of the sphenoid bone successfully removed by a section, displacement and subsequent replacement and reunion of the superior maxillary bone. *Med. Surg. J.* 1867; 8:162.
- [15] Moore FT, Ward TG. Complications and sequelae of untreated fractures of the facial bones and their treatment. *Br J Plast Surg.* 1949 Jan;1(4):257–67.
- [16] Köle H. Surgical operations on the alveolar ridge to correct occlusal abnormalities. *Oral Surg. Oral Med. Oral Pathol.* 1959; 12:277. 413, 515; 677–89.
- [17] Perko M. Retrognathia. *Trans Int Conf Oral Surg.* 1967:76–80
- [18] Bell WH. Revascularization and bone healing after anterior maxillary osteotomy: a study using adult rhesus monkeys. *J. Oral Surg.* Editor Reyneke J.P 1969; 27:249.
- [19] Lang S, Lanigan DT, van der wal M. Trigemino-cardiac reflexes, maxillary and mandibular variants of the oculocardiac reflex. *Can. J. Anaesth.* 1991; 38(6):757–60.
- [20] Teerijoki-oksä T, Jaaskelainen SK, Forssell H. Recovery of nerve injury after mandibular sagittal split osteotomy. Diagnostic value of clinical and electrophysiologic tests in the follow-up. *Int. J. Oral Maxillofac. Surg.* 2004; 33(2):134–40. *A Textbook of Advanced Oral and Maxillofacial Surgery Volume 3*
- [21] Wassmund M 1927. Die Le Fort I osteotomie zur korrektur Posttraumatischer Fehlstellungen. Leipzig, Meuser 1927.
- [22] Obwegeser HL. Surgical correction of small or retrodisplaced maxillae: the “dish-face” deformity. *Plast. Reconstr. Surg.* 1969; 43:351.
- [23] Reyneke JP. Surgical technique. In: *Essentials of orthognathic surgery*. Chicago, IL: Quintessence, 2003; p. 61.
- [24] *Orthognathic surgery: principles and practice*. Amsterdam: Elsevier; pp. 61–68. doi: 10.1016/B978-1-4557-2698-1.00003-4 ISBN978-145572698-1.
- [25] Lee JJ. Maxillary osteotomies: Le Fort I osteotomy. In: Fonseca RJ, Marciani RD, Turvey TA, (Ed.), *Oral and maxillofacial surgery*, vol. III, August 2010, Wiley-Blackwell 2nd ed. St Louis, MO: Elsevier, 2009; pp. 172–191.
- [26] Reyneke JP. *The Le Fort I maxillary osteotomy – surgical manual*, 2nd edn. Jacksonville, FL: Biomet Micro Fixation, 2008.
- [27] Reyneke JP, Masuriek CJ. Treatment of maxillary deficiency by a Le Fort I downsliding technique. *J. Oral Maxillofac. Surg.* 1985; 43:914–16.

- [28] Epker BN, Wolford LM. Middle third facial osteotomies: their use in correction of acquired and developmental dentofacial and craniofacial deformities. *J. Oral Surg.* 1975; 33:491.
- [29] Epker BN, Wolford LM. Middle third facial osteotomies: their use in correction of congenital dentofacial and craniofacial deformities. *J. Oral Surg.* 1976; 34:324.
- [30] Reyneke JP, Ferretti C. Oral diagnosis and treatment planning for orthognathic surgery textbook. In: Andersson L, Kahnberg K-E, Anthony (Tony) Pogrel M (Ed.), *Oral and maxillofacial surgery*. 2010, Chapter 46. Mosby 1980, ISBN 10:0801616069, ISBN 13: 9780801616068
- [31] Mathijssen IM. Guideline for care of patients with the diagnoses of craniosynostosis: working Group on Craniosynostosis. *J. Craniofac. Surg.* 2015; 26(6):1735–807.
- [32] Tahiri Y, Taylor J. An Update on midface advancement using Le Fort II and III distraction osteogenesis. *Semin. Plast. Surg. Clavadelstrasse 8, CH 7270, Davos Platz* 2014; 28(4):184–92.
- [33] Steinhäuser EW. Variations of Le Fort II osteotomies for correction of midfacial deformities. *J. Maxillofac. Surg.* 1980; 8(4):258–65.
- [34] Tessier P, Guiot G, Rougerie J, Delbet JP, Pastoriza J. Cranio-naso-orbito-facial osteotomies. Hypertelorism, *Ann Chir Plast.* 1967 Jun;12(2):103–18.
- [35] Epker BN, Wolford LM. Textbook. Dentofacial deformities, surgical- orthodontic correction. 1980.
- [36] García Y Sánchez JM, Gómez Rodríguez CL, Romero Flores J. Surgical guides for modified oblique Le Fort III osteotomy. *J. Maxillofac. J Oral Surg Anesth Hosp Dent Serv.* 1961;19:42–47
- [37] Ehrenfeld M, Manson PN, Prein J. Textbook. Principles of internal fixation of the craniomaxillofacial skeleton. Trauma and orthognathic surgery. Switzerland: Thieme, AO Foundation, 2012. Osteotomies of the Maxillofacial Skeleton 29.
- [38] Cohn-Stock G. Die chirurgische immedia-tregulier der kiefer, speziell die chirurgische behandlung der prognathie vjschr zabneik 37:320, 1921.
- [39] Epker BN. A modified anterior maxillary ostectomy. *J. Maxillofac. Surg.* 1977; 5(1):35–8.
- [40] Wunderer S, Watzke I. Complications in prognathism operations (following the method of labial pedicled anterior maxilla fragment and their prevention. *Fortschr Kiefer Gesichtschir.* 1985; 30:96–8. German. No abstract available.
- [41] Trauner R, Obwegeser H. The surgical correction of mandibular prognathism and retrognathia with consideration of genioplasty. *Oral Surg. Oral Med. Oral Pathol.* 1957; 10:677–89.

- [42] Dal Pont G. Retromolar osteotomy for the correction of prognathism. *J. Oral Surg.* 1961; 19: 42–7.
- [43] Reyneke JP. Surgical technique. In: *Essentials of orthognathic surgery*. Chicago, IL: Quintessence, 2003; pp. 247–307.
- [44] Epker BN. Modification of the sagittal split osteotomy of Epker BN, Wolford LM. Textbook. *Dentofacial deformities, surgical- orthodontic correction*, 1980.
- [45] Reyneke JP. *The bilateral sagittal split mandibular ramus osteotomy – surgical manual*, 2nd ed. Jacksonville, FL: Biomet Micro Fixation, 2008.
- [46] Watzke IM. Sagittal split osteotomy. In: Fonseca RJ, Marciani RD, Turvey TA (Ed.), *Oral and maxillofacial surgery*, vol. III, 2nd ed. St Louis, MO: Elsevier, 2009; pp. 87–118.
- [47] Caldwell JB. Surgical correction of development deformities of the mandible. *U. S. Armed Forces Med. J.* 1954; 3:362.
- [48] Hall HD, Chase DC, Pryor L. Evaluation and refinement of the intra-oral vertical subcondylar osteotomy. *J. Oral Surg.* 1975; 33:333.
- [49] Reyneke JP. *The sliding genioplasty – surgical manual*. Jacksonville, FL: Biomet Micro Fixation, 2008.
- [50] Precious D. Genioplasty. In: Fonseca RJ, Marciani RD, Turvey TA, (Ed.), *Oral and maxillofacial surgery*, vol. III, 2nd ed. St Louis, MO: Elsevier, 2009; pp. 137–54.
- [51] Triaca A, Minoretti R, Saulacic N. Mandibula wing osteotomy for correction of the mandibular plane: a case report. *Brit. J. Oral Maxillofac. Surg.* 2010; 48:182–4.
- [52] Triaca A, Brusco D. Ways of influencing the facial soft tissue by skeletal movements. *J. Aesthetic Surg.* 2011;4:137–41.
- [53] Triaca A. Chin wing osteotomy – a new facial concept. *Head Face Med.* 2014; 10 (Suppl 1):6.

