

We are IntechOpen, the world's leading publisher of Open Access books Built by scientists, for scientists

6,900

Open access books available

186,000

International authors and editors

200M

Downloads

Our authors are among the

154

Countries delivered to

TOP 1%

most cited scientists

12.2%

Contributors from top 500 universities



WEB OF SCIENCE™

Selection of our books indexed in the Book Citation Index
in Web of Science™ Core Collection (BKCI)

Interested in publishing with us?
Contact book.department@intechopen.com

Numbers displayed above are based on latest data collected.
For more information visit www.intechopen.com



Extracorporeal Membrane Oxygenation in Traumatic Injury: An Overview of Utility and Indications

Ronson Hughes, James Cipolla, Peter G. Thomas and
Stanislaw P. Stawicki

Additional information is available at the end of the chapter

<http://dx.doi.org/10.5772/63434>

Abstract

Severe respiratory failure may develop in the trauma patient as a consequence of direct lung injury, in response to trauma-associated systemic inflammatory response syndrome (SIRS), as a result of infection, or at times as an unintended consequence of the life-saving management of the acute traumatic injury. Approximately 0.5% of all adult trauma patients develop some form of pulmonary dysfunction along the acute lung injury (ALI) – acute respiratory distress (ARDS) spectrum, with the incidence of severe respiratory failure reaching 10–20% in multisystem trauma victims. Of concern, mortality in patients with acute respiratory failure who go on to develop severe pulmonary dysfunction can be as high as 37–50% with the use of conventional therapeutic modalities. Extracorporeal membrane oxygenation (ECMO) has been proposed as a rescue strategy when less invasive primary or adjunctive attempts fail. Numerous case reports and single-center studies demonstrate potential benefits of early implementation of veno-venous (VV)-ECMO for the treatment of severe respiratory failure associated with trauma or sequelae of trauma. In this clinical context, VV-ECMO can be employed to correct for both ventilatory and oxygenation failure while allowing the treating physician to provide much needed rest to the patient's lungs and permit healing to take place. The use of ECMO (mainly veno-venous, with limited use of veno-arterial circuits for cardiac indications) has been described in patients with severe chest injuries, traumatic pneumonectomy, bronchopleural fistulas, and various forms of respiratory failure refractory to conventional therapies.

Keywords: VV-ECMO, VA-ECMO, ALI, ARDS, acute respiratory failure, trauma, indications, contraindications

1. Introduction

Approximately 0.5% of all adult trauma patients develop some form of pulmonary dysfunction, with the incidence of severe respiratory failure reaching 10–20% in multisystem trauma victims [1]. Mortality may be as high as 50% in trauma patients with acute respiratory failure who go on to develop severe pulmonary dysfunction [2]. Novel approaches to mechanical ventilation and adjunctive strategies may help improve outcomes, but continue to fall short of the desired paradigm change [3–6]. Extracorporeal membrane oxygenation (ECMO) has been proposed as a rescue strategy when less invasive primary or adjunctive attempts fail [7–9]. Due to ample case-based literature on the topic of ECMO use in the trauma patient, the goal of this chapter is to provide the reader with a high-level overview of trauma-specific considerations, controversies, pitfalls, indications, and potential avenues for future development in the use of ECMO in the trauma patient.

2. ECMO: a synopsis

There are four major types of short-term mechanical circulatory assist devices used for cardiopulmonary support: (1) intra-aortic balloon pumps, (2) percutaneous ventricular assist devices, (3) extracorporeal membrane oxygenators (ECMO), and (4) non-percutaneous centrifugal pumps [10, 11]. The use of ECMO is limited largely to non-trauma applications, including respiratory (veno-venous or VV-ECMO) and mixed cardiac and respiratory support (veno-arterial or VA-ECMO) in pathophysiologic states considered refractory to maximal standard therapies [12–14]. Circuit characteristics, technical considerations, and other fundamentals of ECMO have been discussed elsewhere in this book. This chapter including the use of ECMO in trauma patients, including indications, contraindications, competing priorities, and practical clinical considerations.

Key considerations must first be addressed before continuing the discussion of ECMO in trauma. Cardiopulmonary support was initially introduced to facilitate and assist cardiac surgical interventions [12, 15]. Subsequent evolution of this technology included device miniaturization and clinical translation to environments outside of the operating room, such as the intensive care units (ICU) [12, 15, 16]. Consequently, it became much easier to deliver ECMO-based therapies, in the setting of acute, refractory respiratory failure, for extended periods of time [17]. Prolonged cardiopulmonary support based on ECMO is now considered a viable option in risk-appropriate, carefully selected non-cardiac surgery patients [18, 19]. At the same time, other non-interventional treatment options and adjuncts are being refined and potential new indications proposed which are actively and dynamically changing the landscape of clinical utilization of ECMO [20–25]. Finally, financial aspects of ECMO therapy must be recognized as well, with significant barriers to wider implementation due to healthcare institutions being increasingly focused on cost containment and value [26–28].

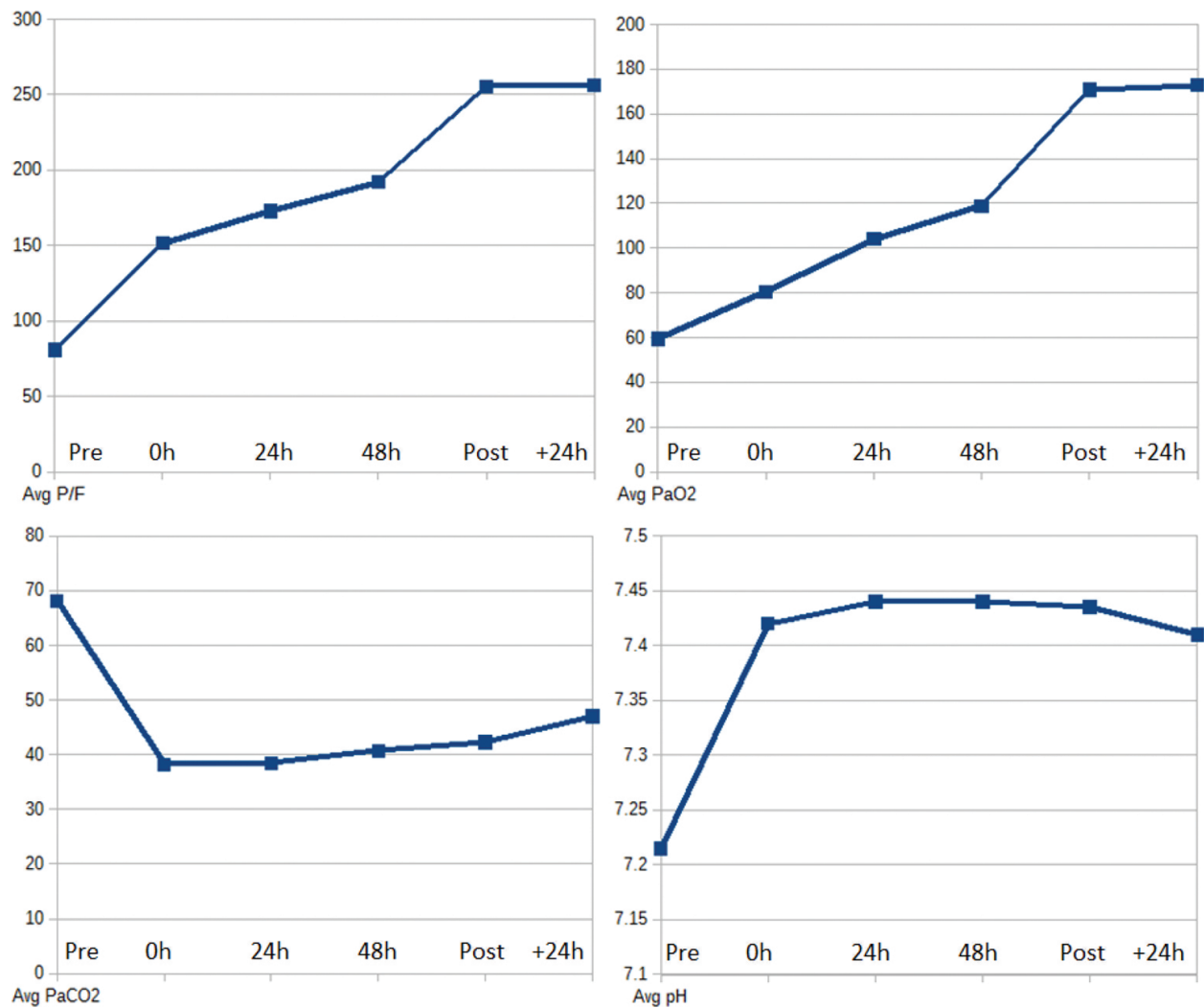


Figure 1. Simplified demonstration of the behavior of key physiologic parameters modifiable with the use of ECMO. Each graph above shows the baseline parameter value, followed by the initial post-ECMO, 24- and 48-h, and then immediate post-weaning measurements. The final value for each parameter represents average measurement for each corresponding variable at 24 h post-ECMO. (**Top left**) Average $\text{PaO}_2/\text{FiO}_2$ values; (**top right**) average PaO_2 values (mmHg); (**bottom left**) average PaCO_2 values (mmHg); (**bottom right**) average pH values. Data compiled from: Arlt et al. [33], Bonacchi et al. [110], Muellenbach et al. [89], Ried et al. [111], Wu et al. [45].

During ECMO, blood is drained from the patient's native vascular system, propagated by a mechanical pump device, and then re-introduced back into circulation [17, 29]. There are two major types of ECMO: (a) VV-ECMO and (b) VA-ECMO [30]. Both provide a support framework that is capable of essentially correcting systemic abnormalities related to catastrophic failure of pulmonary oxygenation and/or ventilation (**Figure 1**), with the main difference being the ability for VA-ECMO to actively augment systemic perfusion [30, 31]. As outlined above, systems capable of providing full pulmonary (but not cardiac) support in patients with severe hypoxemic respiratory failure are termed VV-ECMO devices [32]. Modern VV-ECMO systems take advantage of high flow rates in order to both maximize gas exchange capacity and decrease the risk of thrombotic complications, thus creating an additional potential benefit for patients with contraindications to heparin use [30, 33]. Because VV-ECMO accounts for the

majority of ECMO applications in trauma, we briefly discuss basic principles of venous cannulation required for the deployment of veno-venous ECMO circuits. Cannulation for VA-ECMO is beyond the scope of the current discussion and has been described in other parts of this text.

As outlined elsewhere in this book, the VV-ECMO “inflow catheter” is typically placed in the superior vena cava (SVC) by way of right internal jugular (IJ) central venous access [12, 34]. The “outflow catheter” is typically placed in the inferior vena cava (IVC) by way of femoral central venous access [35, 36]. At the bedside, the distinction between the two can be determined visually in most cases, as the “inflow catheter” blood is generally bright red and the “outflow catheter” blood is usually darker in appearance [37]. The care of the complex trauma patient is characterized by the presence of multiple competing clinical priorities [38, 39]. Thus, providers may need to be flexible in terms of vascular access options for ECMO. For example, cervical spine injury in the trauma patient may preclude internal jugular cannulation [40]. Moreover, significant pelvic or lower extremity fractures may preclude accessing the femoral vessels [41]. Finally, significant complications have been reported during and following ECMO catheter placement, highlighting the need for providers with appropriate level of expertise to be present throughout the entire ECMO delivery process [42, 43]. Image-guided approaches may provide an added degree of procedural safety during the cannula placement process [35, 44].

During its earliest applications, ECMO in trauma required the use of substantial amounts of heparin for anticoagulation due to the risk of clot formation and circuit occlusion [29]. This, in turn, limited ECMO's use due to the potential for hemorrhagic complications in patients with traumatic brain injury, solid organ injuries, or major vascular disruption related to trauma. ECMO circuits of the past were large, bulky, difficult to transport, and not as biocompatible as systems of today [29]. However, since then, ECMO circuits have evolved into essentially portable pump-driven devices that are compact, easy to transport, and carry a much lower risk of circuit clotting due to the synergies between device miniaturization, optimization of flow rates, and heparin-bonded circuits that are more biocompatible [29, 33]. Even when systemic heparinization is required during active ECMO therapy, mortality figures continue to be better than those for comparable non-ECMO trauma patients with equivalent injury severity [45]. In one study, 67.8% of trauma patients receiving ECMO with systemic heparinization survived [45]—a number comparable to non-heparinized trauma patients [46]. Later in the chapter, we discuss the application of ECMO *without* the use of anticoagulation, including important preconditions, indications, contraindications, and risks associated with such approaches.

When full cardiopulmonary support is required for patients in circulatory failure and/or cardiogenic shock, the VA-ECMO approach is utilized [12, 32]. Because the vast majority of trauma-related ECMO applications involve severe respiratory failure (e.g., VV-ECMO) and do not involve or require the need to augment systemic perfusion (e.g., VA-ECMO), we refer the reader to portions of this book that refer to VA-ECMO applications for specialized guidance regarding the patient with refractory cardiac failure. However, when applicable, VA-ECMO

use in trauma will be outlined in the context of general ECMO applicability and clinically relevant aspects central to the current discussion.

3. ECMO in trauma: general considerations, indications, and contraindications

Broadly speaking, ECMO provides the ICU team with an opportunity to ameliorate a broad range of cardiorespiratory maladies, from cardiogenic shock to refractory pulmonary failure [47–50]. In fact, ECMO may be the only clinical “bridge” for patients who otherwise would not be expected to survive the acute phase of their critical illness [47–50]. The degree to which ECMO is able to facilitate various clinical objectives depends on the principal patient diagnosis (e.g., the primary reason for extracorporeal circuit support) and the type of ECMO circuit used [12, 51–53]. In addition to improvement in key oxygenation and circulatory parameters, the vicious cycle of metabolic acidosis, coagulopathy, and hypothermia (e.g., “the lethal triad”) in the polytrauma patient can be limited and even reversed with early and aggressive use of ECMO [33, 54]. In the past, ECMO was utilized as a “last resort” or a salvage therapy when all other modes of intervention had failed. However, evidence is now emerging that early ECMO implementation can limit, or even reverse, the extent of multisystem organ failure resulting from trauma-related sequelae traditionally associated with high mortality, especially in the setting of severe chest injuries [29].

In terms of specific indications and contraindications, the literature pertaining to trauma in this evolving area of cardiopulmonary circulatory support remains scant. It has been proposed that indications for ECMO in the setting of trauma should generally mirror indications in non-trauma settings, as outlined in the Extracorporeal Life Support Organization (ELSO) guidelines (**Table 1**) [55, 56]. Typically, ECMO is indicated in the setting of severe hypoxemia and/or hypercarbia with anticipated mortality in excess of 80% using conventional ventilation strategies [56]. Consequently, patient eligibility should be determined utilizing a case-by-case, highly individualized selection process [57]. The overall risk–benefit equation must be taken into careful consideration, with general contraindications to ECMO being advanced age, the presence of significant comorbid conditions, and recent intracranial hemorrhage [56]. This selection process must also consider initiation of therapy prior to irreversible pulmonary damage and the emergence of non-preventable mortality. A delay in therapy due to stringent inclusion criteria may make any attempt at salvage moot [58]. Additional potential contraindications include the prospect of irreversible end-organ failure despite timely initiation of ECMO support, pre-ECMO ventilator support duration of >7 days, uncorrected coagulopathy, contraindication to anticoagulation, active systemic infection, recent stroke, severe peripheral arterial disease, inability to cannulate due to patient factors, and severe aortic regurgitation [57, 59, 60]. Because many of the above contraindications are viewed as being “relative” as opposed to “absolute,” each patient's case must be considered individually. Perhaps more importantly, outcomes appear to be better in centers that support dedicated, highly experienced ECMO and perfusion teams (optimally able to support at least six ECMO cases per year) [56].

| Inclusion criteria |
|--|
| Anderson et al. [46] <ul style="list-style-type: none">• Total static lung compliance <0.5 mL/cm H₂O/kg.• Transpulmonary shunt <30% on FiO₂ >60%• Reversible respiratory failure• Time on mechanical ventilation ≤5 days (10 day absolute maximum) |
| Biderman et al. [8] <ul style="list-style-type: none">• Injury severity score (ISS) >16• Conventional mechanical ventilation failed to control:<ul style="list-style-type: none">◦ Hypoxemia◦ Hypercapnia/respiratory acidosis |
| Cordell-Smith et al. [75] <ul style="list-style-type: none">• Severe, but potentially reversible, respiratory failure• Murray lung injury score >3.0 or uncompensated hypercapnia with pH <7.20 |
| Gothner et al. [40], p. 1–6 <ul style="list-style-type: none">• Hypoxemia, with PaO₂/FiO₂ of <200; FiO₂ between 0.8 and 1.0; and ventilation time >8 h• Tidal volume >4–6 mL/kg ideal body weight• Inspiratory pressure (<i>P</i>_{insp}) >32–34 mmHg• Respiratory acidosis (pH <7.25) and/or• Arterial oxygen saturation <90% |
| Michaels et al. [108] <ul style="list-style-type: none">• Potentially reversible respiratory failure• Mechanical ventilation <7–10 days• PaO₂/FiO₂ of <100• Shunt fraction >30%• Static lung compliance <0.5 mL/cm H₂O/kg or <30 mL/cm H₂O at tidal volume 10 mL/kg• Failure to resolve the above indicators despite aggressive conventional management |
| Muellenbach et al. [89] <ul style="list-style-type: none">• Optimization/maximization of lung-protective ventilation strategy (tidal volume 6 mL/kg and high PEEP prior to ECMO)• PaO₂/FiO₂ of <80, and FiO₂ >90% |
| Wu et al. [112] |

Inclusion criteria

Anderson et al. [46]

- Severe hypoxemia, with PaO₂/FiO₂ of <60, and PEEP >10 cm H₂O despite maximal ventilator support
- Initial PaO₂/FiO₂ of <60, with rapidly deteriorating pulmonary and hemodynamic status despite maximal ventilator support
- Irreversible CO₂ retention in the presence of hemodynamic instability

Exclusion criteria

Anderson et al. [46]

- Potential for severe bleeding
- Duration of mechanical ventilation >10 days (“11 days or greater”)
- Necrotizing pneumonia
- Poor quality of life (e.g., patients with metastatic malignancy, major central nervous system injury, or quadriplegia)
- Age >60 years

Biderman et al. [8]

- Age >60 years
- Prolonged mechanical ventilation (>7 days) with
 - Peak airway pressures >30 cm H₂O and/or
 - FiO₂ >80%
- Septic shock and multi-organ failure
- Non-commitment of staff/family to full treatment

Michaels et al. [108]

- Mechanical ventilation >7–10 days
 - Age >60 years
 - Excessive risk of central nervous system bleeding with heparinization
 - Septic shock
 - Advanced multi-organ failure
 - Severe pulmonary hypertension (mean pulmonary artery pressure >45 mmHg or >75% systemic pressure)
 - Pre-existing terminal disease
-

Table 1. Compilation of parameters used during the determination of ECMO suitability in various literature reports pertaining to trauma population.

After an indication for ECMO has been met, the decision regarding percutaneous cannulation versus open central cannulation has to be made [61, 62]. In addition, the provider team needs to determine whether to use anticoagulation or to proceed without anticoagulation [63–65]. This decision must consider issues not only related to initiation and maintenance but also weaning of ECMO support (e.g., ability to maintain clot-free circuit with lower flow rates) [65]. The choice of anticoagulation is also important, with alternative options available (e.g., argatroban, bivalirudin) for patients with a contraindication to heparin use (e.g., heparin-induced thrombocytopenia) [64, 66]. Some additional considerations include potential/relative contraindications to ECMO, such as severe aortic regurgitation, severe peripheral arterial disease, uncontrolled sepsis, bleeding diathesis, recent cerebrovascular accident (CVA), or an irreversible cause for the end-organ failure being treated [59]. Previous studies show short-term survival rates between 35% and 83% among patients who appropriately receive ECMO, depending on patient population and primary disease characteristics [67–71]. Additionally, the Conventional Ventilation or ECMO for Severe Acute Respiratory Failure (CESAR) trial showed that patients referred to an ECMO center had a significant increase in survival without disability at 6 months compared to conventional management (63% versus 47%, respectively) [72]. Of note, the CESAR study included a small subset of trauma patients [72]. From this point forward, this chapter focuses on the use of ECMO as a supportive therapy in critically ill trauma patients with respiratory failure.

4. ECMO for refractory respiratory failure in trauma

Approximately 0.5% of all adult trauma patients may be at risk of developing severe respiratory failure or ARDS, with the incidence increasing to 10–20% in multiply injured, high-risk patients [1]. The list of potential causes for trauma-related respiratory distress is heterogeneous and includes pulmonary contusions, fat emboli from long bone/pelvic fractures, thermal injuries, massive transfusion, traumatic brain injury, infection/sepsis, and severe pancreatic trauma, among other etiologies [73–77]. Veno-venous ECMO can be employed to improve systemic physiologic parameters while facilitating pulmonary rest and promoting healing of the lung in patients with the most severe chest injuries and worsening/refractory respiratory failure. Among some of the reported clinical scenarios where VV-ECMO has been successfully utilized are post-traumatic pneumonectomy, bronchopleural fistulas, tracheal injury, and severe/refractory respiratory failure associated with various primary causes [29, 54, 78–81]. For more cardiac-specific indications, including traumatic cardiac injury, VA-ECMO has been utilized [54, 82–84].

As suggested in previous sections of this chapter, early use of ECMO in trauma-related severe respiratory failure may improve outcomes and limit the extent of the post-injury “lethal triad” of acidosis, hypothermia, and coagulopathy that ultimately leads to multisystem organ failure and mortality [29, 46, 58, 85]. In order for VV-ECMO to produce optimal outcomes, a high degree of clinical vigilance, early diagnosis, and prompt management of refractory respiratory failure are required. Clinicians must be familiar with, and recognize the “vulnerable phase” of lung injury. The typical time frame during which pulmonary injury peaks in severity is

between 48 and 96 h [86]. Thus, it is logical that pre-ECMO mechanical ventilatory support of >7 days portends poor outcome [46, 57].

The majority of traumatic pulmonary contusions improve with conservative treatment alone; however, patients with involvement of >20% of the lung volume have been shown to progress to more severe respiratory failure in as many as 80% of cases [87]. Moreover, severe pulmonary contusions may be associated with findings of blood-filled pneumatoceles, lung lacerations, and multiple fractured ribs; the presence of which may further increase the already elevated mortality of the polytrauma patient [29, 88, 89].

Another special consideration is the clinical scenario of traumatic pneumonectomy, with the potential to cause severe acute right heart failure, potentially leading to refractory hypoxemia and very high mortality rates [29, 78]. In this setting, VV-ECMO may be considered as a life-saving therapy that helps minimize various post-trauma pneumonectomy physiologic derangements [29]. In other reports, ECMO was used to facilitate successful repair of ruptured mitral papillary muscle [90], resection of post-traumatic ruptured lung abscess with empyema [91], and postoperative cardiorespiratory support following repair of traumatic aorto-right atrial fistula and tricuspid valve rupture [92].

5. ECMO in the setting of neurologic (brain and spinal cord) injury

Ensuring adequate tissue oxygenation remains a basic tenet of neurologic injury management. The ability to maintain adequate arterial oxygen saturation can prevent secondary brain injury and mitigate against poor outcomes [93]. Due to the simultaneous presence of significant pulmonary injury and brain trauma, the risk of mortality and morbidity may be greater than that of each individual organ system failure in isolation. The need for systemic anticoagulation with ECMO has historically precluded the use of this modality in patients with traumatic brain injury. However, advances in the circuit flow characteristics and oxygenator technology now allow for heparin bonding of the circuit [94]. This in turn reduces the need for anticoagulation during VV-ECMO therapy, thus decreasing the odds of hemorrhagic complications such as cavitory or intracranial bleeding [89].

Firstenberg et al. [95] published a case report of a 27-year-old male involved in a motor vehicle collision. The patient was intubated at the scene and upon hospital arrival was hypothermic with severe mixed respiratory and metabolic acidosis. Due to refractory nature of the patient's respiratory failure, salvage VV-ECMO was utilized as a life-saving "bridge" to pulmonary recovery. Of note, the patient had massive pulmonary contusions, multifocal intraparenchymal brain hemorrhages, as well as intraventricular and subdural blood on computed tomography (CT) imaging [95]. Repeat head CT scans on post-trauma days 1 and 5 showed no significant intracranial changes following the initiation of VV-ECMO [95]. It should be pointed out that due to the concerns for intracranial hemorrhagic complications, the patient received only 10,000 units of heparin systemically before percutaneous femoral-femoral VV-ECMO cannulation and no heparin for 48 h thereafter. Because the lack of heparin anticoagulation posed concerns for clotting of the circuit, frequent evaluations of the VV-ECMO circuit (e.g.,

every 6–8 h) were instituted, with no evidence found of clot formation within the circuit. There were no apparent inefficiencies of gas exchange noted [95]. Following a 96-h course of VV-ECMO, the patient underwent decannulation. On post-trauma day 23, he was transferred to an inpatient rehabilitation facility [95]. Muelenbach et al. likewise reported successful application of VV-ECMO without continuous anticoagulation and only heparin-coated cannulas and circuits for up to 5 days in patients with ARDS and traumatic brain injuries [89].

In another report, a 31-year-old male suffered severe bilateral pulmonary contusions, a right pneumothorax, traumatic frontal brain contusions, subdural hemorrhage, and right main bronchus disruption [96]. Definitive repair of bronchial disruption was feasible utilizing ECMO as “bridge” therapy. Although VV-ECMO was the preferred “bridge” to bronchial repair, due to concerns for right heart failure, VA-ECMO was chosen in this particular case. Because the cannulation catheter used was not heparin coated, low-dose heparin was used during pre-cannulation and VA-ECMO, without worsening of the patient's traumatic brain injuries [96].

Veno-venous ECMO has also been used in a patient with spinal cord injury [44]. An 18-year-old victim of a vehicular crash sustained multiple traumatic injuries, including left hemothorax, intracerebral bleeding, and complete paraplegia. After developing severe respiratory failure, the patient was placed on VV-ECMO “rescue” therapy. Interestingly, the cannulation was performed using fluoroscopy, without anticoagulation, and involved a double-lumen catheter inserted via the right IJ vein. The patient subsequently improved, was successfully weaned from VV-ECMO after 1 week, and was eventually transferred to a rehabilitation facility [44]. In another report, a small subset of patients with spinal cord injury underwent VV-ECMO for post-traumatic ARDS, without reported neurologic sequelae [40].

6. ECMO in polytrauma: managing the risk of traumatic hemorrhage

The use of ECMO has been reported in trauma patients with a range of severe blunt and penetrating injuries [14, 97]. Polytrauma, in turn, presents the treating physician with a number of competing priorities [38, 39]. Wen et al. [98] reported on successful use of VV-ECMO in a 19-year-old motorcyclist with severe hypoxia on presentation. His subsequent trauma evaluation showed significant right-sided lung contusions, pulmonary aspiration, as well as a grade IV liver laceration (without evidence of active bleeding) [98]. A non-heparinized VV-ECMO circuit was used for 5 days without major complications [98].

Fortenberry et al. [97] described five children and three adults with median duration of pre-ECMO mechanical ventilation of 6 days. Reported injuries included four liver lacerations, three pulmonary contusions, as well as renal trauma. Four patients underwent pre-ECMO laparotomies, including three splenectomies. Of note, the majority of patients (seven of eight) in that series underwent VV-ECMO, and significant bleeding was reported in seven patients while on ECMO [97]. The authors classified hemorrhagic complications of ECMO as “manageable.” Survival in the pediatric subset of patients was 80% [97]. Similarly, Madershahian et al. [54] described successful ECMO use in patients with severe blunt injuries including pulmonary

contusions, bronchial rupture, multiple fractures, and abdominal trauma. The authors encourage prompt institution of ECMO for the temporary management of gas exchange in trauma patients with refractory respiratory failure [54].

In another report, a patient with grade III liver laceration and blunt chest trauma complicated by endobronchial hemorrhage was treated with VV-ECMO [99]. The patient was maintained on low-dose heparin to maintain the activated partial thromboplastin time (aPTT) around 1.5–2.0 times normal, with no complications noted. The reported duration of VV-ECMO therapy in this case was 10 days [99]. Diffuse pulmonary hemorrhage may result from massive pulmonary contusions. In such cases, hemostasis may be difficult to achieve, even with surgical resection. Employment of single lung ventilation may be used, coupled with VV-ECMO and frequent bronchoscopic lavage [95]. Skarda et al. [14] reported on ECMO use in children with severe traumatic injuries, including open reduction and internal fixation and endoscopic procedures while on active extracorporeal support.

7. ECMO as bridge to definitive surgical management

Across various scenarios outlined in previous sections of this chapter, ECMO was believed to be the main factor contributing to patient survival in potentially futile situations. At times, patient survival is possible without the use of ECMO; however, definitive surgical repair may not be possible without extracorporeal support. Finally, ECMO may be necessary for both survival and definitive repair of injuries.

Gatti et al [9] published a case of a 27-year-old man who sustained a 4-cm-wide stab wound to the fifth left intercostal space, resulting in cardiac injury evidenced by a massive left hemothorax and a pericardial effusion. The patient experienced acute clinical decompensation, developed pulseless electrical activity (PEA) arrest, and underwent an emergency department implementation of VA-ECMO (using left internal jugular vein inflow and right femoral artery outflow) at flow rates between 4.5 and 5.0 L/min [9]. A median sternotomy was then performed, with drainage of a pericardial effusion, repair of a right ventricular injury and repair of an injured branch of the right coronary artery. This was followed by return of adequate cardiac function [9]. Overall, the patient underwent >40 minutes of cardiopulmonary resuscitation and was cannulated on VA-ECMO for approximately 120 minutes, with 350 units/kg of heparin administered during the duration of extracorporeal support [9]. Other than a mild postpericardiotomy syndrome, the patient recovered from his injury without neurological sequelae [9]. Other scenarios where ECMO was instrumental to satisfactory clinical outcomes following major cardiac trauma include repair of ruptured mitral papillary muscle [90] and postoperative cardiorespiratory support following repair of traumatic aorto-right atrial fistula and tricuspid valve rupture [92].

Major airway trauma, including bronchopleural fistulae, has an associated mortality in excess of 30% [100]. In one case, VV-ECMO was used in the setting of severe hypoxemia as a bridge to surgical management of major bronchial injury [101]. A 31-year-old male sustained multiple injuries following an automobile collision, including a right-sided hemopneumothorax,

cerebral contusion, subarachnoid and subdural hemorrhages, bilateral pulmonary contusions, and a right main stem bronchial tear that was immediately repaired operatively. On postoperative day 5, the patient developed complete occlusion of the right main stem bronchus, with severe respiratory failure and hemodynamic instability. Consequently, the patient was placed on a VA-ECMO circuit utilizing low-dose heparin to help facilitate the definitive surgical airway repair. The authors reported that they would have considered VV-ECMO if the patient was hemodynamically stable [101].

Ballouhey et al. [102] utilized ECMO in a 32-month-old girl who sustained major tracheobronchial trauma after being struck by a vehicle. Initial diagnostic imaging showed the endotracheal tube to be outside of the trachea. Due to the presence of hemodynamic instability, VA-ECMO was selected for the surgical repair. Of note, the authors did point out that in the presence of hemodynamic stability, VV-ECMO can be used to support patients in need of surgical correction of major tracheobronchial disruptions [102]. In some cases of unilateral pulmonary or bronchial trauma, either single-lung (e.g., selective ventilation of only one lung) or differential-lung (e.g., each lung managed independently via separate ventilator-tracheal tube circuits) ventilation can be coupled with ECMO to ensure adequate oxygenation while the healing of contralateral traumatic injury is taking place [103]. Following surgical repair of the airway, postoperative continuation of ECMO may be deemed appropriate because (a) healing of operatively repaired tissue may be otherwise affected or compromised [29] or (b) the patient may not be able to immediately wean off the extracorporeal support [92].

8. ECMO: summary of single-center experiences

A number of valuable single-center experiences have been reported, demonstrating successful use of VV-ECMO in trauma. Key findings from these studies are presented in **Table 2** and **Figure 2**. The subsequent discussion focuses on the most important “take-home” messages from this cumulative body of literature. In addition to supporting the notion that in carefully selected trauma patients ECMO can improve survival, there is emerging evidence that the performance of surgical procedures on extracorporeal support is safe, including repeated damage control operations [104–106].

Back in mid-1990s, Anderson et al. [46] presented a single-institution experience with 24 multiply injured patients treated with ECMO for refractory respiratory failure. Both VV-ECMO and VA-ECMO was utilized, with all patients receiving systemic heparinization. Hemorrhagic complications were reported in 75% of patients. The overall survival to hospital discharge was 63%, with early initiation of ECMO (<5 days) being associated with better outcomes [46]. In another early experience, Senunas et al. [107] reported on 14 multiply injured patients who sustained severe skeletal trauma and progressed to refractory respiratory failure. Consistent with data provided by others [46, 108], this study also showed improved survival when ECMO was initiated early (87% survival for <6 pre-ECMO ventilator days versus 16.7% survival for >6 pre-ECMO ventilator days) [107]. Michaels et al. further quantify the importance of early ECMO initiation in a series of 30 trauma patients, with associated odds ratio of 7.2 for patient survival when the duration of pre-ECMO ventilator support was ≤5 days [108].

| Study | Patient data | ELS data | Complications | Mortality/survival | Comment |
|---------------------------|--|--|--|--|--|
| Anderson et al. [46] | N = 24 Mixed pediatric and adult population | Duration of ELS: 287 ± 43 h (12 ± 1.8 day) Heparinization: All patients Circuit-related complications: Oxygenator failure: 8.3% Raceway/tubing rupture: 8.3% Pump failure: 4.2% Circuit change: 25% | Hemorrhage: 75% Renal failure: 21% Cardiac: 12.5% Stroke or intracranial bleeding: 21% Pneumothorax: 8.3% | Survival to discharge from hospital: 63% Time to ELS: Survivors 3.8 ± 0.8 days Deceased 10 ± 1.4 days | Both VV-ECMO and VA-ECMO was utilized Early intervention (e.g., ≤5 days to ECMO) was associated with better outcomes Reduced anticoagulation levels were utilized in a patient with closed head injury and depressed skull fracture |
| Senunas et al. [107] | N = 14 (4 male; 10 female) Survivors: Mean ISS 19 (9–34) Mean GCS 14.5 (12–15) Non-survivors: Mean ISS 18 (11–29) Mean GCS 13.3 (6–15) | MV prior to ECMO: 6 days (1–19 days) Duration of ECMO: 240 h (50–624 h) | Hemorrhage: 57.1% | Overall survival: 57.1% Survival for patients with <6 pre-ECMO ventilator days: 87.5% Survival for patients with >6 pre-ECMO ventilator days: 16.7% | The study involved 14 multiply injured patients with major orthopedic trauma 5 of 14 patients underwent surgical procedures while on ECMO Consistent with experience reported by Anderson, et al., early initiation of ECMO was associated with better survival |
| Michaels et al. [108] | N = 30 (15 male; 15 female) Age 26.3 ± 2.1 years (15.59 years) Mean ISS 19.8 ± 2.2 Mean PaO ₂ /FiO ₂ 56.9 ± 5.4 | Duration of ECMO: 237.8 ± 36.9 Circuit-related problems: Oxygenator change: 24% Pump complication: 7% Tubing change: 21% | Acute renal failure: 55% Hemorrhage: 59% Infection: 28% (positive cultures) Pneumothorax: 31% Neurologic: 14% | Survival to discharge: 50% Early use of ECMO (≤5 vent days) was associated with odds ratio of 7.2 for survival | Fewer ventilator days and more normal SvO ₂ were associated with survival Numerous patients underwent surgical procedures while on ECMO, including tracheostomy (50%), laparotomy (13%), thoracotomy (3%), femoral artery repair (3%), and open reduction of lower extremity fracture (3%) |
| Cordell-Smith et al. [75] | N = 28 Age 27 years Mean ISS 18 Mean PaO ₂ /FiO ₂ 62 Lung injury score 3.1 (Murray) | Pre-ECMO MV: 69 h Duration of ECMO: 141 h Heparinization: All patients received systemic heparin, with activated clotting time targets between 180 and 220 s | Complication data not provided | Overall survival: 71.4% Of interest, survivors had higher mean ISS (19) than non-survivors (14) | Mean time to ECMO was 61 h for survivors versus 87 h for non-survivors |
| Huang et al. [109] | N = 9 Age 35.1 ± 9.7 years (18–47 years) Mean ISS 44.56 ± 4.93 (35–50) Mean SOFA 12.1 ± 3.67 (7–16) Mean PaO ₂ 49.04 ± 9.82 mmHg (31–64) Mean PaCO ₂ 66.4 ± 15.72 mmHg (45–86) | Time from injury to ECMO: 33 h (4–384 h) Duration of ECMO: 145 h (69–456 h) | Colonic rupture with sepsis: 1 patient (11%) Liver failure: 11% | Survival to discharge: 77.8% | VA-ECMO: 2 patients VV-ECMO: 7 patients 6 patients (66.7%) received additional surgeries while on ECMO |
| Arlt et al. [33] | N = 10 (8 male; 2 female) Age 34.8 years (21–62 years) Mean ISS 73 ± 4 PaCO ₂ 67 (36–89) Median norepinephrine demand 3 mg/h (1.0–13.5) | Duration of ECMO: 5 days (0.5–11 days) The authors report on the use of a new miniaturized ECMO device, with initial therapy performed without heparinization | Sepsis/ Multi-organ failure: 30% | Overall hospital survival: 60% | VV-ECMO: 7 patients VA-ECMO: 3 patients The study describes the use of ECMO in actively hemorrhaging patients |
| Biderman et al. [8] | N = 10 (6 male; 4 female) Age 29.8 ± 7.7 years (19–42) Mean ISS 50.3 ± 10.5 (29–57) PaO ₂ /FiO ₂ : ECMO 62 (35–82) iLA 92 (78–140) PaCO ₂ : ECMO 62 (48–95) iLA 85 (65–150) (+) Traumatic brain injury | Time to ECMO: 3 days (1–7 days) Time to iLA: 5 days (3–8 days) Duration of ECMO: 9.5 ± 4.5 days | Cannula related: Bleeding: 10% Accidental removal: 10% Pressure ulcer: 30% Sepsis: 20% Cardiogenic shock: 10% | ECMO survival: 60% iLA survival: 80% | iLA Circuit: 5 patients ECMO: 5 patients iLA is a pumpless extrapulmonary gas exchange system (http:// www.novalung. com/en/home) |

| Study | Patient data | ELS data | Complications | Mortality/survival | Comment |
|-----------------------|---|---|--|---|---|
| Bonacchi et al. [110] | N = 14 (10 male; 4 female) Age 47 ± 17.6 years Mean ISS 46.5 ± 16.3 (+) Damage control surgery | Time from trauma to ECMO: 351.8 ± 242 min (145–950 min) Duration of ECMO: 128.7 ± 113 h (24–384 h) Heparin-free time on ECMO: 20.7 ± 19.8 h Blood transfusion: 11.9 ± 5.3 units rfVIIa administration during ECMO: 50% Heparinization: ECMO circuit used was heparin-coated; systemic heparin was held in cases of bleeding (mean delay of 16.7 ± 19 h, range 2.5–72 h); Titration to mean aPTT of 40–50 s / activated clotting time of 160–180 s Initially, 18 patients were considered for ECMO; however, due to inability to maintain adequate circuit flow and perfusion on VA-ECMO, only 14 patients were successfully treated | Renal failure requiring VV hemofiltration: 50% cases Hepatic insufficiency: 14.2% Sepsis: 21.4% Leg ischemia: 7.1% Oxygenator failure: 7.1% | ECMO survival: 35.7% Organ donation: 42.9% Death (w/o organ donation): 21.4% All cases (<i>n</i> = 4) with inability to establish or maintain circuit flow/perfusion died | VV-ECMO: 4 patients VA-ECMO: 10 patients Cardiac index, mean arterial pressure, blood lactate, PaO ₂ , PaCO ₂ , and pH normalized within 3.5 ± 1.5 h of ECMO initiation Intra-aortic balloon pump was used in 2 patients |
| Ried et al. [111] | N = 52 (49 male; 3 female) Age 32 ± 14 years (16–72 years) Mean BMI 28.2 ± 6.1 Mean ISS 58.9 ± 10.5 Mean LIS 3.3 ± 0.60 Mean SOFA 10.5 ± 3.0 PaO ₂ /FiO ₂ 63 (49–101) PaCO ₂ 67 (50–87) Lactate 28 (14–49) mg/dL | Pre-ELS MV: 3.2 ± 4.1 day (0–21 days) Time to ELS: 5.2 ± 7.7 days (0–38 days) Duration of ELS: 6.9 ± 3.6 days (<1–19 days) ELS flow rate (L/min): 2.3 ± 0.9 (0.7–4.6) Duration of MV: 18.4 ± 10.6 days (1–51 days) ICU/ hospital stay: 22 days (14–32)/ 25 days (16–41) Surgical procedure: 86.5% Thoracic procedure: 15.4% Surgery with ELS: 30.8% | Cannula-related: PECLA 19% VV-ECMO 12% RRT: 30.8% | 8 (15.4%) during ELS support 3 (6%) after ELS weaning Hospital mortality: 21% Overall survival: 79% | VV-ECMO: 26 patients pECLA: 26 patients pECLA: Pumpless extracorporeal lung assist |
| Tseng et al. [104] | N = 9 (8 male; 1 female) Age 37 years (IQR 26.5–46 years) Median ISS 34 (IQR 15.5–41) (+) Damage control surgery | Median time to VA-ECMO: 6 h (IQR 4–47.5) Median duration of ECMO: 91 h (IQR 43–187) | Hemorrhage: 22% | Survival to discharge: 33% | VA-ECMO: 9 patients |
| Wu et al. [45] | N = 20 Age 38 years (22–61 years) Median ISS 35 (19–75) (+) Intracranial hemorrhage (+) Damage control surgery | Time from trauma to ECMO: 64 h (IQR 12–230) Median duration of pre-ECMO ventilation: 45 h (IQR 8–148) Median ECMO duration: Survivors: 144 h (74–196 h) Deceased: 232 h (36–575 h) Post- ECMO intubation: 231 h (61–476 h) Hospital days: Survivors: 69 days (27–81 days) Deceased: 32 days (4–46 days) | Hemorrhage: 35% CVVH: 35% Tracheostomy: 40% | Overall survival: 70% Age (survivors): 41 years (29–57) Age (non-survivors): 30 years (22–61 years) ISS (survivors): 29 (19–43) ISS (non-survivors): 63 (26–75) Mortality from sepsis: 15% | VV-ECMO: 20 patients “Heparin-minimized” strategy was utilized in 55% of patients |
| Wu et al. [112] | N = 19 (17 male; 2 female) Age 38 years (25–58 years) Median ISS 29 (25–34) Median APACHE II 25 (21–36) PaO ₂ / FiO ₂ 60 (48–65) (+) Brain hemorrhage | Median blood transfusion: 5500 mL (3,500–13,000) Heparinization: 16 patients (84.2%) ICU duration: 16.8 ± 9.37 days | Pneumonia: 15.8% Coagulopathy: 10.5% Need for CVVH: 37% | Overall survival: 68.4% Age (survivors): 30 years (21–39) Age (non-survivors): 53 years (48–63 years) | VV-ECMO: 9 patients VA-ECMO: 10 patients Five patients had pre-ECMO traumatic brain hemorrhage (3/5 or 60% survived) Mortality in heparin group was 5/16 (31.3%) Gothner et al. [40] |
| Gothner et al. [40] | N = 6 (all male) Age 45 years (31–54 years) Mean ISS 31 (20–48) (+) Spinal cord injury (+) Minor brain injury | Time to ELS: 3 ± 5 days (0–13 days) Duration of ELS: 7 ± 5 days (6–18 days) ICU stay: 21 ± 7 days (13–30 days) Hospital stay: 60 ± 34 days (21–105 days) Blood transfusion: 8 Units (2–20 U) PRBC | Cannula related: 17% (thrombosis) Urethral bleeding: 17% Acute renal failure: 17% VAP: 83% | Overall survival: 100% | VV-ECMO: 6 patients Authors describe the use of double lumen cannula placed via right IJ approach |

Table 2. Important characteristics of major clinical studies of ECMO in trauma (1994–2015).

Cordell et al. [75] treated 28 multiply injured patients suffering from severe respiratory failure with VV-ECMO. In that series, patients received “limited anticoagulation” using intravenous heparin, with activated clotting times between 180 and 220 s [75]. The overall survival was 71.4%, with shorter “time to ECMO” associated with better survival (e.g., 61 h for survivors versus 87 h for non-survivors) [75]. Huang et al. describe 78% survival in nine trauma patients undergoing ECMO [109]. In that series, two-thirds of patients underwent additional surgeries while on extracorporeal support [109]. Arlt et al. [33] treated 10 multiply injured patients with hemorrhagic shock using a miniaturized ECMO circuit, without initial systemic heparinization. The 60% reported survival is very impressive given the mean ISS of 73 for the study cohort [33]. Others have found that independent predictors of mortality in trauma patients undergoing ECMO include ISS >63, pH <7.01 (mean of last three evaluations), and blood lactate of >14.4 mmol/L (mean of last three evaluations) [110].

Gothner et al. [40] published clinical experience based on six patients with major trauma (mean injury severity score [ISS], 31) and post-traumatic severe respiratory failure who were supported with VV-ECMO using a double lumen cannula. The authors reported mean pre-ECMO hospitalization of 3 days, mean ECMO run times of 7 days, mean hospital stays of 60 days, and 100% survival for the 6 study patients [40]. It was noted that the double lumen cannula utilized was not heparin coated and thus heparin dosages had to be adjusted to maintain the prothrombin time (PTT) in the range of 50–60. As such, this approach in patients

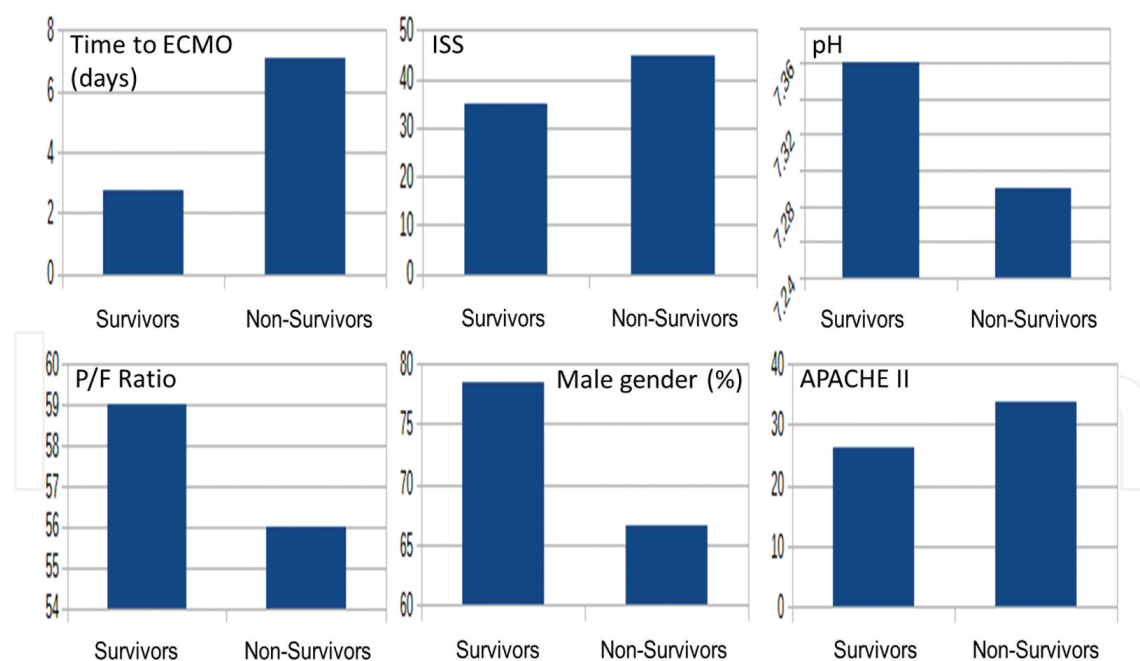


Figure 2. Comparison of important baseline parameters for trauma survivors and non-survivors, compiled from key single-center ECMO experiences. (**Top left**) Time from injury to ECMO (days); (**top middle**) injury severity score (ISS); (**top right**) pH values; (**bottom left**) $\text{PaO}_2/\text{FiO}_2$ ratio; (**bottom middle**) male gender (%); (**bottom right**) APACHE II score. Data compiled from: Anderson et al. [46], Arlt et al. [33], Biderman et al. [8], Cordell-Smith et al. [75], Michaels et al. [108], Senunas et al. [107], Wu et al. [45, 112].

who are at elevated risk of bleeding is controversial, despite the report finding no substantial elevation in the risk of bleeding among study patients [40].

Another study retrospectively looked at a single-center experience with VV-ECMO over a 10-year period. The authors focused on critically injured trauma patients with mean ISS of nearly 59 and the sequential organ failure assessment (SOFA) scores of 10.5 [111]. Within the sample of 52 patients, 26 received pumpless extracorporeal lung assist (PECLA) and the other 26 underwent VV-ECMO [111]. In this series, mean time to extracorporeal support was 5.2 days, average support duration of was 6.9 days, many patients underwent surgery while on extracorporeal support, and cannula-related complications occurred in 15% of patients (19% PECLA; 12% VV-ECMO) [111]. Overall survival was 79% compared to predicted survival of 59% (estimated from ISS data). The authors additionally noted that patients with elevated risk of hemorrhagic complications or evidence of intracranial bleeding were not started on heparin during the initial 48 h. After securing evidence that bleeding is controlled (e.g., repeat CT scan imaging), heparin was started slowly and target PTT set at approximately 40–50 s [111].

Wu et al. [112] studied 19 patients treated with ECMO for severe lung injury and respiratory failure. The most common mechanism of pulmonary injury was blunt trauma, with median patient age of 38 years, median ISS of 29, median Acute Physiology and Chronic Health Evaluation II (APACHE II) score of 25, and median blood transfusion volume of 5.5 L [112]. The overall survival within this cohort was 68% (13 of 19 patients), with survivors being younger (30 years) than non-survivors (53 years) [112]. There were five patients (26% of total) with traumatic brain hemorrhage, of whom three survived (60% of brain trauma group) [112]. Sixteen out of 19 patients (84%) received heparin during VV-ECMO therapy, with 5 mortalities noted in that group (31%). In addition to demonstrating potential benefits of VV-ECMO in multiply injured patients, the authors also emphasize the value of timely ECMO intervention [112].

Biderman et al. [8] published another important single-center experience using ECMO in trauma. A total of 10 patients (mean age 30 years; mean ISS of 50; 60% male) received ECMO therapy. Within this group, all patients suffered from blunt trauma and severe thoracic injuries, with vascular and abdominal solid organ injuries being the most common. Mean ECMO support time was 9.5 days [8]. Seven patients within the group had traumatic brain injury, with four exhibiting active intracranial hemorrhage. Coagulopathy was prevalent before institution of VV-ECMO in this group. Consistent with other reports outlined in this chapter, the authors point out that complications related to the extracorporeal support therapy were manageable and non-lethal [8]. Reported complications included bleeding from the cannulation site, dislodged cannula, and pressure ulcers. Mortalities were attributed to sepsis (two cases) and cardiogenic shock (one case) [8]. Of importance, the authors were able to demonstrate clinical success of high-flow ECMO technique without anticoagulation, especially in patients with coagulopathy or traumatic brain injury. This experience shows that even in patients with acute and active hemorrhage, meaningful benefits can be gained from utilizing ECMO [8].

9. ECMO: weaning and liberation

Because the increasing duration of ECMO support is associated with greater mortality, extracorporeal support weaning should be a constant consideration for patients undergoing this therapy [113]. Thus, as soon as a patient is identified as a candidate for ECMO wean, the process should begin promptly and follow a protocolized course toward the goal of liberation from dependence on extracorporeal oxygenation [113]. In general, weaning for patients on VV-ECMO for severe respiratory failure should be considered based on improvements in pulmonary compliance, chest radiography characteristics, and arterial oxygenation indices [12, 57]. This can be followed by a “weaning trial” where blood flow through the circuit is maintained, but gas transfer is temporarily (up to several hours) stopped [12, 57]. For patients on VA-ECMO for cardiac failure, important considerations prior to weaning therapy should include echocardiographic findings (preferably transesophageal), aortic pulsatility, and a successful “off-ECMO trial” that consists of temporary clamping of the drainage and infusion lines while maintaining a temporary bridge between the arterio-venous conduits [57, 114, 115].

10. The financial impact of ECMO

Due to resource utilization and the overall level of intensive care afforded to affected patients, ECMO is recognized as a labor intensive and costly intervention. In 1993, Schumacher et al. [116] demonstrated that early ECMO in infants was cost-effective when compared to late ECMO or “no ECMO” controls. In 2005, Mahle et al. [117] reported on the cost utility of salvage ECMO following surgery for congenital heart abnormalities. Based on their financial analysis, the authors concluded the calculated cost-utility for salvage extracorporeal membrane oxygenation in this population was \$24,386 per quality-adjusted life-year saved, which would be considered within the range of acceptable cost-efficacy. The CESAR trial evaluated cost based on in-hospital expense, as well as the economic burden of services required during follow-up for ECMO patients and their families [72]. The authors reported that mean costs per patient in the group who underwent ECMO were £73,979 (approximately \$116,502) over a period of 6 months. Based on cost-benefit analysis, the United Kingdom National Health Service declared ECMO treatment, at a referral center, to be cost-effective even though the mean costs of patients receiving ECMO were higher compared to the control arm. A caveat to this conclusion is that dollar-for-dollar cost in a non-single party payer system (e.g., the USA) may vary considerably [72].

11. Miscellaneous topics

11.1. Analgo-sedation

ECMO applications mandate the ability to control patient activity and ensure adequate analgesia and sedation [118, 119]. It has been noted that VA-ECMO is associated with signif-

icantly greater doses of sedation than VV-ECMO [119]. The current understanding of how different ECMO circuits affect pharmacokinetic characteristics of certain drugs (e.g., antibiotics, sedatives, analgesics) is incomplete [118, 120]. Over the past few years, evidence has emerged that periodic sedation and analgesia interruptions, and even allowing patients to remain awake may be beneficial to both short- and long-term ECMO outcomes [118, 121]. In fact, such daily interruptions help facilitate patient mobilization and even ambulation [17, 122, 123]. However, this is not without risks. The importance of adequate analgo-sedation optimization is highlighted by a case of major hemorrhage requiring cardiopulmonary resuscitation following ECMO cannula dislodgement in a conscious, spontaneously breathing patient [124]. The applicability of the “awake ECMO” concept in trauma is probably limited, mainly due to the generally transient requirement for extracorporeal support in this population, as well as the significant analgo-sedation requirement secondary to multiple injuries (e.g., not directly related to ECMO).

11.2. Organ donation

Trauma is one of the leading causes of death, with traumatic brain injury being a major contributor to the overall trauma mortality [39, 125]. Brain death following trauma is numerically one of the major sources of organs donated for transplantation [125]. Balsorano et al. [126] reported on successful use of VA-ECMO as a tool for organ preservation prior to organ procurement. The authors pointed out the myriad of complex physiologic disturbances that occur following brain death, emphasizing potential barriers to organ recovery such as cardiac arrest and refractory cardiopulmonary collapse [126, 127]. The use of ECMO to optimize organs from non-heart-beating donors (e.g., donation after cardiac death) is not a new concept [128]. Gravel et al. [129] describe the use of ECMO to facilitate renal transplantation from organ donors following cardiopulmonary death.

11.3. Multidisciplinary approach to ECMO

The authors of this chapter feel strongly that promotion of a multidisciplinary approach to trauma patients undergoing ECMO therapy is essential. In most of the published literature, patients enrolled in the ECMO arms of the trial were at tertiary referral centers that were replete with expertise in cardiac surgery, perfusion, advanced ventilator strategies, and specialized critical care. Trauma centers embarking on an ECMO program need to ensure that these specialties have reviewed pertinent treatment protocols and safety standards involved in the implementation of extracorporeal support. Also, we recommend involving the ELSO to help with credentialing and performance improvement initiatives for any center considering ECMO as a treatment option. As outlined earlier in this chapter, one of the most significant advantages of modern ECMO circuits is their portability. This facilitates ECMO implementation in a variety of settings, including the emergency department, the operating room, and the ICU [110]. Consequently, multidisciplinary participation in institutional ECMO programs should include representation from all key departments and stakeholders, from cardiovascular surgery to emergency medicine.

12. Conclusions

Improvements in biocompatibility, miniaturization, and portability of modern ECMO circuits have increased the safety profile and clinical utility of this extracorporeal support option. In turn, this has resulted in an expanding range of clinical applications of ECMO, including its increasing use in the trauma patient with refractory circulatory and respiratory failure. Clinical approaches once considered to be futile and controversial are now available as life-saving strategies for patients who otherwise would not be able to survive. Important challenges remain to greater ECMO implementation in the trauma population, including the use of anticoagulation and better optimization of patient selection. Trauma centers contemplating an ECMO program should seek buy-in from the services who will be intimately involved in the care of the patient as well as organizations dedicated to ensuring the quality and efficiency of extracorporeal support program.

Author details

Ronson Hughes, James Cipolla, Peter G. Thomas and Stanislaw P. Stawicki*

*Address all correspondence to: stanislaw.stawicki@sluhn.org

Regional Level I Trauma Center and Department of Surgery, Section of Cardiovascular Surgery, St. Luke's University Health Network, Bethlehem, Pennsylvania, USA

References

- [1] Cardona A JM, Valderrama CO, Gaviria UJ, Arboleda VC, Ramirez NG. Clinical and epidemiological characterization of acute respiratory distress syndrome in adult patients with femoral shaft fractures. *Rev Colomb Anesthesiol*. 2014; 42:176–183.
- [2] Navarrete-Navarro, P., et al., *Acute respiratory distress syndrome in trauma patients: ICU mortality and prediction factors*. *Intensive Care Medicine*, 2000. 26(11): p. 1624–1629.
- [3] Bone, R.C., et al., *Randomized double-blind, multicenter study of prostaglandin E1 in patients with the adult respiratory distress syndrome*. *Prostaglandin E1 Study Group*. *CHEST Journal*, 1989. 96(1): p. 114–119.
- [4] Zambon, M. and J.-L. Vincent, *Mortality rates for patients with acute lung injury/ARDS have decreased over time*. *CHEST Journal*, 2008. 133(5): p. 1120–1127.
- [5] Stawicki, S.P., M. Goyal, and B. Sarani, *High-frequency oscillatory ventilation (HFOV) and airway pressure release ventilation (APRV): a practical guide*. *Journal of Intensive Care Medicine*, 2009. 24(4): p. 215–229.

- [6] Dellinger, R.P., et al., *Effects of inhaled nitric oxide in patients with acute respiratory distress syndrome: results of a randomized phase II trial. Inhaled nitric oxide in ARDS study group.* Critical Care Medicine, 1998. 26(1): p. 15–23.
- [7] Bein, T., et al., *Transportable extracorporeal lung support for rescue of severe respiratory failure in combat casualties.* The Journal of Trauma and Acute Care Surgery, 2012. 73(6): p. 1450–1456.
- [8] Biderman, P., et al., *Extracorporeal life support in patients with multiple injuries and severe respiratory failure: a single-center experience?* The Journal of Trauma and Acute Care Surgery, 2013. 75(5): p. 907–912.
- [9] Gatti, G., et al., *Rescue extracorporeal membrane oxygenation in a young man with a stab wound in the chest.* Injury, 2014. 45(9): p. 1509–1511.
- [10] Saffarzadeh, A. and P. Bonde, *Options for temporary mechanical circulatory support.* Journal of Thoracic Disease, 2015. 7(12): p. 2102.
- [11] Suh, I.-W., et al., *Catastrophic catecholamine-induced cardiomyopathy mimicking acute myocardial infarction, rescued by extracorporeal membrane oxygenation (ECMO) in pheochromocytoma.* Journal of Korean Medical Science, 2008. 23(2): p. 350–354.
- [12] Marasco, S.F., et al., *Review of ECMO (extra corporeal membrane oxygenation) support in critically ill adult patients.* Heart, Lung and Circulation, 2008. 17: p. S41–S47.
- [13] Stub, D., et al., *Refractory cardiac arrest treated with mechanical CPR, hypothermia, ECMO and early reperfusion (the CHEER trial).* Resuscitation, 2015. 86: p. 88–94.
- [14] Skarda, D., J.W. Henricksen, and M. Rollins, *Extracorporeal membrane oxygenation promotes survival in children with trauma related respiratory failure.* Pediatric Surgery International, 2012. 28(7): p. 711–714.
- [15] Del Nido, P., et al., *Extracorporeal membrane oxygenator rescue in children during cardiac arrest after cardiac surgery.* Circulation, 1992. 86(5 Suppl): p. II300–II304.
- [16] Müller, T., et al., *A new miniaturized system for extracorporeal membrane oxygenation in adult respiratory failure.* Critical Care, 2009. 13(6): p. 1–10.
- [17] Tulman, D.B., et al., *Veno-venous ECMO: a synopsis of nine key potential challenges, considerations, and controversies.* BMC Anesthesiol, 2014. 14: p. 65.
- [18] Birnbaum, D.E., *Extracorporeal circulation in non-cardiac surgery.* European Journal of Cardio-Thoracic Surgery, 2004. 26(Suppl 1): p. S82–S85.
- [19] Midla, G.S., *Extracorporeal circulatory systems and their role in military medicine: a clinical review.* Military Medicine, 2007. 172(5): p. 523–526.
- [20] Hintz, S.R., et al., *Decreased use of neonatal extracorporeal membrane oxygenation (ECMO): how new treatment modalities have affected ECMO utilization.* Pediatrics, 2000. 106(6): p. 1339–1343.

- [21] Kawahito, K., et al., *Resuscitation and circulatory support using extracorporeal membrane oxygenation for fulminant pulmonary embolism*. Artificial Organs, 2000. 24(6): p. 427–430.
- [22] Diaz-Guzman, E., C.W. Hoopes, and J.B. Zwischenberger, *The evolution of extracorporeal life support as a bridge to lung transplantation*. ASAIO Journal, 2013. 59(1): p. 3–10.
- [23] Parhar, K. and A. Vuylsteke, *What's new in ECMO: scoring the bad indications*. Intensive care medicine, 2014. 40(11): p. 1734–1737.
- [24] Abrams, D. and D. Brodie, *Emerging indications for extracorporeal membrane oxygenation in adults with respiratory failure*. Annals of the American Thoracic Society, 2013. 10(4): p. 371–377.
- [25] Stawicki, S.P., et al., *What's new in critical illness and injury science? State of the art in management of ARDS*. International Journal of Critical Illness and Injury Science, 2014. 4(2): p. 95.
- [26] Peek, G.J., et al., *Efficacy and economic assessment of conventional ventilatory support versus extracorporeal membrane oxygenation for severe adult respiratory failure (CESAR): a multi-centre randomised controlled trial*. Lancet (London, England), 2009. 374(9698): p. 1351–1363.
- [27] Crow, S., A. Fischer, and R. Schears. *Extracorporeal life support: utilization, cost, controversy, and ethics of trying to save lives*. Semin Cardiothorac Vasc Anesth. 2009 Sep;13(3): 183–91.
- [28] Hsieh, F.T., G.S. Huang, W.J. Ko, and M.F. Lou *Health status and quality of life of survivors of extra corporeal membrane oxygenation: a cross-sectional study*. Journal of Advanced Nursing, 2016 [Epub ahead of print]. DOI: 10.1111/jan.12943.
- [29] Dreizin, D., J. Menaker, and T.M. Scalea, *Extracorporeal membranous oxygenation (ECMO) in polytrauma: what the radiologist needs to know*. Emergency Radiology, 2015. 22(5): p. 565–576.
- [30] Shaheen, A., et al., *Veno-Venous Extracorporeal Membrane Oxygenation (V V ECMO): indications, preprocedural considerations, and technique*. J Card Surg. 2016 Apr;31(4):248–52.
- [31] Makdisi, G. and I.-W. Wang, *Extra Corporeal Membrane Oxygenation (ECMO) review of a lifesaving technology*. Journal of Thoracic Disease, 2015. 7(7): p. E166.
- [32] Andrews, A., et al., *Total respiratory support with venovenous (VV) ECMO*. ASAIO Journal, 1982. 28(1): p. 350–353.
- [33] Arlt, M., et al., *Extracorporeal membrane oxygenation in severe trauma patients with bleeding shock*. Resuscitation, 2010. 81(7): p. 804–809.
- [34] Schmid, C., et al., *Venovenous extracorporeal membrane oxygenation for acute lung failure in adults*. The Journal of Heart and Lung Transplantation, 2012. 31(1): p. 9–15.

- [35] Javidfar, J., et al., *Insertion of bicaval dual lumen extracorporeal membrane oxygenation catheter with image guidance*. ASAIO Journal, 2011. 57(3): p. 203–205.
- [36] Kohler, K., et al., *ECMO cannula review*. Perfusion, 2013. 28(2): p. 114–124.
- [37] Williams, K.E., *Extracorporeal membrane oxygenation for acute respiratory distress syndrome in adults*. AACN Advanced Critical Care, 2013. 24(2): p. 149–168.
- [38] Jonathan R. Wisler, Paul R. Beery II, Steven M. Steinberg and Stanislaw P. A. Stawicki (2012). *Competing Priorities in the Brain Injured Patient: Dealing with the Unexpected, Brain Injury – Pathogenesis, Monitoring, Recovery and Management*, Prof. Amit Agrawal (Ed.), ISBN: 978-953-51-0265-6, InTech, Available from: <http://www.intechopen.com/books/brain-injury-pathogenesis-monitoring-recovery-and-management/competing-priorities-in-the-brain-injured-patient-dealing-with-the-unexpected>
- [39] Bach, J., et al., *Multidisciplinary approach to multi-trauma patient with orthopedic injuries: the right team at the right time*. OPUS 12 Scientist, 2012. 6(1): p. 6–10.
- [40] Gothner, M., et al., *The use of double lumen cannula for veno-venous ECMO in trauma patients with ARDS*. Scandinavian Journal of Trauma, Resuscitation and Emergency Medicine, 2015. 23: p. 30.
- [41] Boeckmann, D., et al., *ECMO in trauma patients—should we consider alternative cannulation sites?* Injury Extra, 2006. 37(8): p. 297–298.
- [42] Hirose, H., et al., *Right ventricular rupture and tamponade caused by malposition of the Avalon cannula for venovenous extracorporeal membrane oxygenation*. Journal of Cardiothoracic Surgery, 2012. 7(36): p. 1–4.
- [43] Riccabona, M., et al., *Venous thrombosis in and after extracorporeal membrane oxygenation: detection and follow-up by color Doppler sonography*. European Radiology, 1997. 7(9): p. 1383–1386.
- [44] Stoll, M.C., et al., *Veno-venous extracorporeal membrane oxygenation therapy of a severely injured patient after secondary survey*. The American Journal of Emergency Medicine, 2014. 32(10): p. 1300 e1–1300 e2.
- [45] Wu, M.Y., et al., *Venovenous extracorporeal life support for posttraumatic respiratory distress syndrome in adults: the risk of major hemorrhages*. Scandinavian Journal of Trauma, Resuscitation and Emergency Medicine, 2014. 22: p. 56.
- [46] Anderson, H.L., et al., *Extracorporeal life support for respiratory failure after multiple trauma*. Journal of Trauma and Acute Care Surgery, 1994. 37(2): p. 266–274.
- [47] Minicucci, M.F., et al., *Heart failure after myocardial infarction: clinical implications and treatment*. Clinical Cardiology, 2011. 34(7): p. 410–414.
- [48] Kar, B., et al., *Percutaneous circulatory support in cardiogenic shock interventional bridge to recovery*. Circulation, 2012. 125(14): p. 1809–1817.

- [49] Mydin, M., et al., *Extracorporeal membrane oxygenation as a bridge to pulmonary endarterectomy*. The Annals of Thoracic Surgery, 2011. 92(5): p. e101–e103.
- [50] Pagani, F.D., et al., *Extracorporeal life support to left ventricular assist device bridge to heart transplant a strategy to optimize survival and resource utilization*. Circulation, 1999. 100 (suppl 2): p. II-206–II-210.
- [51] Kulik, T.J., et al., *Outcome-associated factors in pediatric patients treated with extracorporeal membrane oxygenator after cardiac surgery*. Circulation, 1996. 94(9 Suppl): p. II63–II68.
- [52] Rastan, A.J., et al., *Early and late outcomes of 517 consecutive adult patients treated with extracorporeal membrane oxygenation for refractory postcardiotomy cardiogenic shock*. The Journal of Thoracic and Cardiovascular Surgery, 2010. 139(2): p. 302–311. e1.
- [53] Friesenecker, B., et al., *Craniotomy during ECMO in a severely traumatized patient*. Acta Neurochirurgica, 2005. 147(9): p. 993–996.
- [54] Madershahian, N., et al., *Application of ECMO in multitrauma patients with ARDS as rescue therapy*. Journal of Cardiac Surgery, 2007. 22(3): p. 180–184.
- [55] Paden, M.L., et al., *Extracorporeal life support organization registry report 2012*. ASAIO Journal, 2013. 59(3): p. 202–210.
- [56] Wydo, S. and R. George, *Extracorporeal membrane oxygenation: a trauma surgeon's perspective*. Mechanical Circulatory Support, 2013. 4:21599.
- [57] Haft, J., et al., *Extracorporeal membrane oxygenation (ECMO) in adults*. UpToDate Web site. <http://www.uptodate.com/contents/extracorporeal-membrane-oxygenation-ecmo-in-adults>, 2012. Accessed May 7, 2016.
- [58] Marasco, S.F., et al., *Institution of extracorporeal membrane oxygenation late after lung transplantation – a futile exercise?* Clinical Transplantation, 2012. 26(1): p. E71–E77.
- [59] Myat, A., et al., *Percutaneous circulatory assist devices for high-risk coronary intervention*. JACC Cardiovascular Interventions, 2015. 8(2): p. 229–244.
- [60] Rupperecht, L., et al., *Pitfalls in percutaneous ECMO cannulation*. Heart, Lung and Vessels, 2015. 7(4): p. 320–326.
- [61] Stulak, J.M., et al. *ECMO cannulation controversies and complications*. Semin Cardiothorac Vasc Anesth. 2009 Sep;13(3):176–82.
- [62] Field, M., et al., *Open and closed chest extrathoracic cannulation for cardiopulmonary bypass and extracorporeal life support: methods, indications, and outcomes*. Postgraduate Medical Journal, 2006. 82(967): p. 323–331.
- [63] Oliver, W.C. *Anticoagulation and coagulation management for ECMO*. Semin Cardiothorac Vasc Anesth. 2009 Sep;13(3):154–75.
- [64] Koster, A., et al., *Successful use of bivalirudin as anticoagulant for ECMO in a patient with acute HIT*. The Annals of Thoracic Surgery, 2007. 83(5): p. 1865–1867.

- [65] Lappa, A., et al., *Weaning from venovenous extracorporeal membrane oxygenation without anticoagulation: is it possible?* The Annals of Thoracic Surgery, 2012. 94(1): p. e1–e3.
- [66] Mejak, B., et al., *Argatroban usage for anticoagulation for ECMO on a post-cardiac patient with heparin-induced thrombocytopenia.* The Journal of Extra-Corporeal Technology, 2004. 36(2): p. 178–181.
- [67] Schumacher, R., et al., *Follow-up of infants treated with extracorporeal membrane oxygenation for newborn respiratory failure.* Pediatrics, 1991. 87(4): p. 451–457.
- [68] Heiss, K., et al., *Reversal of mortality for congenital diaphragmatic hernia with ECMO.* Annals of Surgery, 1989. 209(2): p. 225.
- [69] Ssemakula, N., et al., *Survival of patients with congenital diaphragmatic hernia during the ECMO era: an 11-year experience.* Journal of Pediatric Surgery, 1997. 32(12): p. 1683–1689.
- [70] Smedira, N.G., et al., *Clinical experience with 202 adults receiving extracorporeal membrane oxygenation for cardiac failure: survival at five years.* The Journal of Thoracic and Cardiovascular Surgery, 2001. 122(1): p. 92–102.
- [71] Nair, P., et al., *Extracorporeal membrane oxygenation for severe ARDS in pregnant and postpartum women during the 2009 H1N1 pandemic.* Intensive Care Medicine, 2011. 37(4): p. 648–654.
- [72] Peek, G.J., et al., *Efficacy and economic assessment of conventional ventilatory support versus extracorporeal membrane oxygenation for severe adult respiratory failure (CESAR): a multi-centre randomised controlled trial.* Lancet, 2009. 374(9698): p. 1351–1363.
- [73] Kao, L.S., et al., *Predictors of morbidity after traumatic pancreatic injury.* Journal of Trauma and Acute Care Surgery, 2003. 55(5): p. 898–905.
- [74] Mascia, L., *Acute lung injury in patients with severe brain injury: a double hit model.* Neurocritical Care, 2009. 11(3): p. 417–426.
- [75] Cordell-Smith, J., et al., *Traumatic lung injury treated by extracorporeal membrane oxygenation (ECMO).* Injury, 2006. 37(1): p. 29–32.
- [76] Hill, J.D., et al., *Clinical prolonged extracorporeal circulation for respiratory insufficiency: hematological effects.* Transactions – American Society for Artificial Internal Organs, 1972. 18(0): p. 546–552, 561.
- [77] Ombrellaro, M., et al., *Extracorporeal life support for the treatment of adult respiratory distress syndrome after burn injury.* Surgery, 1994. 115(4): p. 523–526.
- [78] Martucci, G., et al., *Veno-venous ECMO in ARDS after post-traumatic pneumonectomy.* Intensive Care Medicine, 2013. 39(12): p. 2235.
- [79] Khan, N.U., et al., *Extracorporeal membrane oxygenator as a bridge to successful surgical repair of bronchopleural fistula following bilateral sequential lung transplantation: a case report and review of literature.* Journal of Cardiothoracic Surgery, 2007. 2(1): p. 28.

- [80] Goldman, A.P., et al., *Extracorporeal membrane oxygenation as a bridge to definitive tracheal surgery in children*. The Journal of Pediatrics, 1996. 128(3): p. 386–388.
- [81] Jacobs, J.V., et al., *The use of extracorporeal membrane oxygenation in blunt thoracic trauma: a study of the Extracorporeal Life Support Organization database*. Journal of Trauma and Acute Care Surgery, 2015. 79(6): p. 1049–1054.
- [82] DeBerry, B.B., et al., *Successful management of pediatric cardiac contusion with extracorporeal membrane oxygenation*. Journal of Trauma and Acute Care Surgery, 2007. 63(6): p. 1380–1382.
- [83] Giraud, R., et al., *Massive pulmonary embolism leading to cardiac arrest: one pathology, two different ECMO modes to assist patients*. Journal of Clinical Monitoring and Computing, 2015: p. 1–5.
- [84] Barreda, E., et al., *Extracorporeal life support in right ventricular rupture secondary to blast injury*. Interactive Cardiovascular and Thoracic Surgery, 2007. 6(1): p. 87–88.
- [85] Tisherman, S.A., *Salvage techniques in traumatic cardiac arrest: thoracotomy, extracorporeal life support, and therapeutic hypothermia*. Current Opinion in Critical Care, 2013. 19(6): p. 594–598.
- [86] Cohn, S.M., *Pulmonary contusion: review of the clinical entity*. The Journal of Trauma, 1997. 42(5): p. 973–979.
- [87] Miller, P.R., et al., *ARDS after pulmonary contusion: accurate measurement of contusion volume identifies high-risk patients*. Journal of Trauma-Injury Infection and Critical Care, 2001. 51(2): p. 223–230.
- [88] Maung, A.A. and L.J. Kaplan, *Mechanical ventilation after injury*. Journal of Intensive Care Medicine, 2014. 29(3): p. 128–137.
- [89] Muellenbach, R.M., et al., *Prolonged heparin-free extracorporeal membrane oxygenation in multiple injured acute respiratory distress syndrome patients with traumatic brain injury*. The Journal of Trauma and Acute Care Surgery, 2012. 72(5): p. 1444–1447.
- [90] Kugai, T. and M. Chibana, *Rupture in a mitral papillary muscle following blunt chest trauma*. The Japanese Journal of Thoracic and Cardiovascular Surgery, 2000. 48(6): p. 394–397.
- [91] Brenner, M., J.V. O'Connor, and T.M. Scalea, *Use of ECMO for resection of post-traumatic ruptured lung abscess with empyema*. The Annals of Thoracic Surgery, 2010. 90(6): p. 2039–2041.
- [92] Rubin, S., et al., *Traumatic aorto-right atrial fistula and tricuspid valve rupture. Post-operative cardiac and respiratory support with extracorporeal membrane oxygenation*. Interactive Cardiovascular and Thoracic Surgery, 2006. 5(6): p. 735–737.
- [93] Brain Trauma, F., et al., *Guidelines for the management of severe traumatic brain injury. I. Blood pressure and oxygenation*. Journal of Neurotrauma, 2007. 24 (Suppl 1): p. S7–S13.

- [94] Bermudez, C.A., et al., *Initial experience with single cannulation for venovenous extracorporeal oxygenation in adults*. The Annals of Thoracic Surgery, 2010. 90(3): p. 991–995.
- [95] Firstenberg, M.S., et al., *Extracorporeal membrane oxygenation for complex multiorgan system trauma*. Case Reports in Surgery, 2012. 2012: p. 897184.
- [96] Zhou, R., et al., *ECMO support for right main bronchial disruption in multiple trauma patient with brain injury—a case report and literature review*. Perfusion, 2015. 30(5): p. 403–406.
- [97] Fortenberry, J.D., et al., *Extracorporeal life support for posttraumatic acute respiratory distress syndrome at a children's medical center*. Journal of Pediatric Surgery, 2003. 38(8): p. 1221–1226.
- [98] Wen, P.H., et al., *Non-heparinized ECMO serves a rescue method in a multitrauma patient combining pulmonary contusion and nonoperative internal bleeding: a case report and literature review*. World Journal of Emergency Surgery, 2015. 10: p. 15.
- [99] Yuan, K.-C., J.-F. Fang, and M.-F. Chen, *Treatment of endobronchial hemorrhage after blunt chest trauma with extracorporeal membrane oxygenation (ECMO)*. Journal of Trauma and Acute Care Surgery, 2008. 65(5): p. 1151–1154.
- [100] Guest, J. and J. Anderson, *Major airway injury in closed chest trauma*. CHEST Journal, 1977. 72(1): p. 63–66.
- [101] Liu, C., et al., *Extracorporeal membrane oxygenation as a support for emergency bronchial reconstruction in a traumatic patient with severe hypoxaemia*. Interactive Cardiovascular Thoracic Surgery, 2014. 19(4): p. 699–701.
- [102] Ballouhey, Q., et al., *Benefits of extracorporeal membrane oxygenation for major blunt tracheobronchial trauma in the paediatric age group*. European Journal of Cardiothoracic Surgery, 2013. 43(4): p. 864–865.
- [103] Garlick, J., et al., *Differential lung ventilation and venovenous extracorporeal membrane oxygenation for traumatic bronchopleural fistula*. The Annals of Thoracic Surgery, 2013. 96(5): p. 1859–1860.
- [104] Tseng, Y.H., et al., *Venoarterial extracorporeal life support in post-traumatic shock and cardiac arrest: lessons learned*. Scandinavian Journal of Trauma, Resuscitation and Emergency Medicine, 2014. 22: p. 12.
- [105] Smith, B.P., et al., *Review of abdominal damage control and open abdomens: focus on gastrointestinal complications*. Journal of Gastrointestinal and Liver Diseases, 2010. 19(4): p. 425–435.
- [106] Stawicki, S.P., J. Cipolla, and C. Bria, *Comparison of open abdomens in non-trauma and trauma patients: a retrospective study*. OPUS 12 Scientist, 2007. 1(1): p. 1–8.
- [107] Senunas, L.E., et al., *Extracorporeal life support for patients with significant orthopaedic trauma*. Clinical Orthopaedics and Related Research, 1997(339): p. 32–40.

- [108] Michaels, A.J., et al., *Extracorporeal life support in pulmonary failure after trauma*. The Journal of Trauma, 1999. 46(4): p. 638–645.
- [109] Huang, Y.-K., et al., *Extracorporeal life support in post-traumatic respiratory distress patients*. Resuscitation, 2009. 80(5): p. 535–539.
- [110] Bonacchi, M., et al., *Extracorporeal life support in patients with severe trauma: An advanced treatment strategy for refractory clinical settings*. The Journal of Thoracic and Cardiovascular Surgery, 2013. 145(6): p. 1617–1626.
- [111] Ried, M., et al., *Extracorporeal lung support in trauma patients with severe chest injury and acute lung failure: a 10-year institutional experience*. Critical Care, 2013. 17(3): p. R110.
- [112] Wu, S.C., et al., *Use of extracorporeal membrane oxygenation in severe traumatic lung injury with respiratory failure*. American Journal of Emergency Medicine, 2015. 33(5): p. 658–662.
- [113] Thiagarajan, R.R. and C.S. Barrett, *ECMO-indications and outcomes*. Available from: <http://www.sccm.org/Communications/Critical-Connections/Archives/Pages/ECMO—Indications-and-Outcomes.aspx>. 2011. Accessed on May 7, 2016.
- [114] Aissaoui, N., et al., *Predictors of successful extracorporeal membrane oxygenation (ECMO) weaning after assistance for refractory cardiogenic shock*. Intensive Care Medicine, 2011. 37(11): p. 1738–1745.
- [115] Cavarocchi, N.C., et al., *Weaning of extracorporeal membrane oxygenation using continuous hemodynamic transesophageal echocardiography*. The Journal of Thoracic and Cardiovascular Surgery, 2013. 146(6): p. 1474–1479.
- [116] Schumacher, R.E., et al., *Extracorporeal membrane oxygenation in term newborns. A prospective cost-benefit analysis*. ASAIO Journal, 1993. 39(4): p. 873–879.
- [117] Mahle, W.T., et al., *Cost-utility analysis of salvage cardiac extracorporeal membrane oxygenation in children*. The Journal of Thoracic and Cardiovascular Surgery, 2005. 129(5): p. 1084–1090.
- [118] Wildschut, E., et al., *Determinants of drug absorption in different ECMO circuits*. Intensive Care Medicine, 2010. 36(12): p. 2109–2116.
- [119] Shekar, K., et al., *Increased sedation requirements in patients receiving extracorporeal membrane oxygenation for respiratory and cardiorespiratory failure*. Anaesthesia and Intensive Care, 2012. 40(4): p. 648.
- [120] Shekar, K., et al., *ASAP ECMO: antibiotic, sedative and analgesic pharmacokinetics during extracorporeal membrane oxygenation: a multi-centre study to optimise drug therapy during ECMO*. BMC Anesthesiology, 2012. 12(1): p. 29.
- [121] Fuehner, T., et al., *Extracorporeal membrane oxygenation in awake patients as bridge to lung transplantation*. American Journal of Respiratory and Critical Care Medicine, 2012. 185(7):763–768.

- [122] Rehder, K.J., et al., *Active rehabilitation during ECMO as a bridge to lung transplantation*. Respir Care 2013;58(8):1291–1298.
- [123] Gulack, B.C., S.A. Hirji, and M.G. Hartwig, *Bridge to lung transplantation and rescue post-transplant: the expanding role of extracorporeal membrane oxygenation*. Journal of Thoracic Disease, 2014. 6(8): p. 1070–1079.
- [124] Haneke, F., et al., *Use of extracorporeal membrane oxygenation in an awake patient after a major trauma with an incidental finding of tuberculosis*. Perfusion. 2016 May;31(4):347–8.
- [125] Klein, A., et al., *Organ donation and utilization in the United States, 1999–2008*. American Journal of Transplantation, 2010. 10(4p2): p. 973–986.
- [126] Balsorano, P., et al., *Extracorporeal life support and multiorgan donation in a severe poly-trauma patient: a case report*. International Journal of Surgery Case Reports, 2015. 9: p. 109–111.
- [127] Cipolla, J., S. Stawicki, and D. Spatz, *Hemodynamic monitoring of organ donors: a novel use of the esophageal echo-Doppler probe*. The American Surgeon, 2006. 72(6): p. 500–504.
- [128] Ko, W.J., et al., *Extracorporeal membrane oxygenation support of donor abdominal organs in non-heart-beating donors*. Clinical Transplantation, 2000. 14(2): p. 152–156.
- [129] Gravel, M., et al., *Kidney transplantation from organ donors following cardiopulmonary death using extracorporeal membrane oxygenation support*. Annals of Transplantation: Quarterly of the Polish Transplantation Society, 2003. 9(1): p. 57–58.