

# We are IntechOpen, the world's leading publisher of Open Access books Built by scientists, for scientists

6,900

Open access books available

185,000

International authors and editors

200M

Downloads

Our authors are among the

154

Countries delivered to

TOP 1%

most cited scientists

12.2%

Contributors from top 500 universities



WEB OF SCIENCE™

Selection of our books indexed in the Book Citation Index  
in Web of Science™ Core Collection (BKCI)

Interested in publishing with us?  
Contact [book.department@intechopen.com](mailto:book.department@intechopen.com)

Numbers displayed above are based on latest data collected.  
For more information visit [www.intechopen.com](http://www.intechopen.com)



---

# Guided Bone Regeneration Technique Using Hyaluronic Acid in Oral Implantology

---

Fatih Özkan, Metin Şençimen, Aydın Gülses and Mustafa Ayna

Additional information is available at the end of the chapter

<http://dx.doi.org/10.5772/63101>

---

## Abstract

Guided bone regeneration is a term used to describe the use of the barrier membranes to enhance complete osteogenesis by preventing the rapid ingrowth of fibroblasts into a bony defect and promoting the migration of osteogenic cells from adjacent bony edges or bone marrow into the defect in an unimpeded fashion. Hyaluronic acid (HA) is a glycosaminoglycan of the general formula  $(C_{14}H_{22}NO_{11})_n$  and is an essential component of the extracellular matrix in connective tissue, which is found in abundance in the alveolar environment. The most important function of HA is its involvement in tissue healing and repair. It has been shown that HA stimulates cell proliferation, migration and angiogenesis, re-epithelialization and proliferation of basal keratinocytes and reduces collagen and scar tissue formation. This text presents our clinical experiences and outcomes following HA applications in various implant surgery procedures. According to our clinical outcomes, HA is a highly promising material for improving therapeutic outcomes for oral implantology.

**Keywords:** guided bone regeneration, hyaluronic acid, oral implantology, bone reconstruction, advanced oral surgery

---

## 1. Introduction

Loss of alveolar bone can result in secondary to periodontal diseases, periapical pathologies, maxillary sinus pneumatization or trauma to teeth and adjacent structures. Damage of the osseous structures during tooth extraction procedures may also result in bone loss of various types and severity. Sufficient alveolar bone volume and favorable architecture of the alveolar

ridge are essential to obtain ideal functional and esthetic prosthetic reconstruction following implant therapy [1]. In order to overcome the problems related to osseous defects adjacent to implants and/or implant recipient sites, Dahlin and colleagues spearheaded early research on guided bone regeneration (GBR) techniques [2–4]. Herein, we present the technique.

## 2. Guided bone regeneration

GBR is a term used to describe the use of barrier membranes to enhance complete osteogenesis by preventing the rapid ingrowth of fibroblasts into a bony defect and promoting the migration of osteogenic cells from the adjacent bony edges or bone marrow into the defect in an unimpeded fashion [5]. Nowadays, various types of dental GBR materials have been developed, which can be grouped together as either non-resorbable or resorbable membranes.

## 3. Non-resorbable membranes

The first and recently mostly used commercial membrane was produced from Teflon® (e-PTFE). According to the results of various studies focusing on the efficacy of e-PTFE, predictable outcomes were observed, especially in ridge augmentation using it either alone or in combination with osseous grafting. However, membrane exposure, which permits a communication between the oral environment and newly forming tissues, increasing the potential for infection and decreasing the likelihood of regeneration, has been a frequent post-surgical complication associated with the use of non-resorbable membranes [6]. Moreover, non-resorbable membranes must be retrieved by employing a second surgical procedure [7].

## 4. Resorbable membranes

There are mainly three types of biologically resorbable membranes: (1) polyglycoside synthetic copolymers, (2) collagen and (3) calcium sulfate.

Collagen is the principal component of connective tissue and provides structural support for them. Collagen membranes are the most widely used resorbable membranes in implant surgery. They have various advantages such as hemostasis, chemotaxis, biotolerability, bioresorption, slow absorption and ease of manipulation compared to e-PTFE.

Hyaluronic acid (HA) is a glycosaminoglycan with a chemical formula  $(C_{14}H_{22}NO_{11})_n$  **and also found in abundance in the connective tissues of maxillary and mandibular tooth bearing areas** [8]. HA is particularly dense in the superficial layers of the buccal mucosa where it contributes to the epithelial barrier effect, at the same time enhancing both the stability and the elasticity of the peripheral connective tissue.

The most important function of HA is its involvement in tissue healing and repair [9, 10]. In the literature, it has been shown that HA stimulates cell proliferation, migration and angio-

genesis, re-epithelialization and proliferation of basal keratinocytes and reduces collagen and scar tissue formation [11, 12].

In covalently cross-linked condition, HA forms a hydrophilic polymer network which may absorb its dry weight in water a multiple of times [13]. This lubricious property combined with its biocompatibility has led to different medical applications of HA in dermatology, ophthalmology, orthopedics, plastic surgery, and more recently, implantology, in order to benefit from its properties against inflammation and infection together with its capacity to promote wound healing.

Owing to that, HA is used as an effective medication for treatment of recurrent aphthous ulcers [14], as an adjuvant treatment for gingivitis [15], to enhance healing of tooth extraction socket [16] and interdental papillae reconstruction [17]. More recently, cross-linked HA products were used as gel barriers to cover the osseous defects around the implants and implant recipient sites and thereby promoting GBR. Claar performed a lateral coverage of the augmentation followed by use of cross-linked HA in gel form, which was developed especially for GBR [18].

The principles of GBR applications are as follows [19, 20]:

*Cell exclusion:* Crating a barrier to prevent forming fibrous connective tissue by epithelial cells.

*Tenting:* New wound space beneath the membrane must be regenerated solely from around soft tissues so that high quality of new tissue can be gained.

*Scaffolding:* At first, a fibrin clot is seen in this space which is a scaffold for progenitor cells. Adjacent hard tissues serve as a storage for stem cells.

*Stabilization:* To gain successful healing, the defective area must be protected from environmental effects such as flap movement, bacterial invasion, exposure of region, etc. by fixing the membrane into position.

It is well known that HA is a biodegradable, biocompatible, non-toxic, non-immunogenic and non-inflammatory linear polysaccharide. These properties demonstrate the superiority of HA by providing high biocompatibility and tissue integrity as a barrier membrane.

As mentioned above, the placement and stabilization of the membrane play a key role in the success of GBR. Therefore, the surgeon's skill and experience are of great importance. In addition, the need for removal of the mini bone screws placed for the stabilization of the membrane during implant insertion surgery necessitates a larger flap design and excessive exposure of the surgical field, especially in lateral sinus elevation procedures. Claar [18] has also proclaimed that, because of its high viscosity, HA is readily applicable and has high positional stability.

Marinucci *et al.* [21] evaluated the effects of bioabsorbable and non-resorbable membranes on human osteoblast activity *in vitro*. Human osteoblasts were cultured on bioabsorbable membranes made of collagen, HA, and poly DL-lactide, and e-PTFE. The results showed that collagen and HA increased secretion of TGF- $\beta$ 1, a growth factor involved in bone remodeling. It may be concluded that bioabsorbable membranes, particularly collagen and HA, can

promote bone regeneration through their effects on osteoblasts. Besides that, HA and bioabsorbable membranes significantly increased collagen synthesis and alkaline phosphatase activity.

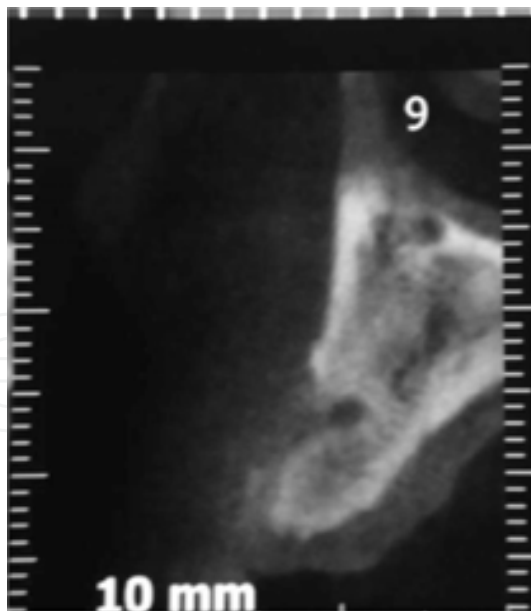
Membranes must remain in place until cells capable of regeneration are established at the wound site. Blumenthal [22] showed that collagen membranes cross-linked with formaldehyde can last 6 to 8 weeks before being absorbed, whereas non-cross-linked membranes lose their structural integrity in 7 days. HA gel in cross-linked form can last up to 3–4 weeks in the surgical field, which could be accepted as an appropriate term for enhancement of osteopromotion. HA is a highly promising material for improving therapeutic outcomes in dental implantology.

The aim of this section is to present clinical outcomes following HA applications in different implant surgery procedures.

## 5. Technique

### 5.1. Bone defects around dental implants

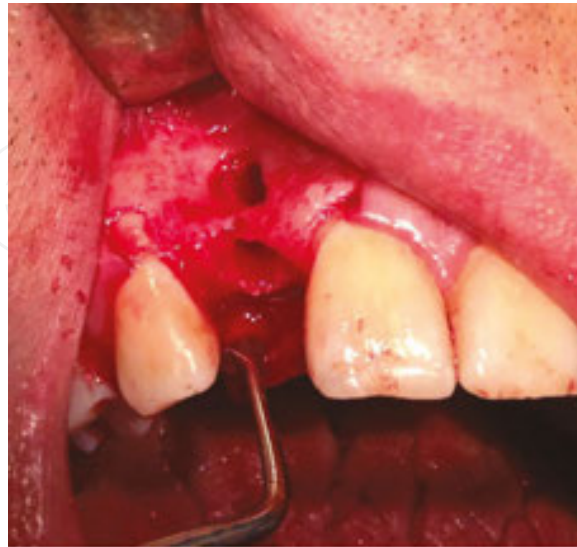A 43-year-old healthy male patient admitted to our department due to the loss of his upper left lateral incisor was assessed. According to his history, the tooth was extracted 4 months ago following an unsuccessful endodontic treatment. A computerized tomography revealed the presence of a bone defect located adjacent to the missing tooth (**Figure 1**).



**Figure 1.** A computerized tomography scan revealed the presence of a bone defect located adjacent to the missing tooth.

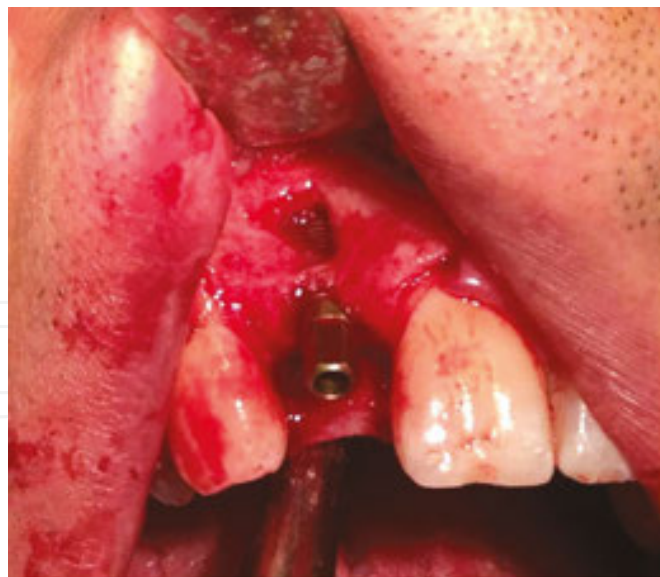After consultations with the prosthodontist, it was decided to insert an implant into the corresponding area. Under local anesthesia, a full thickness flap was raised and the bone defect

and the implant recipient site were exposed. The granulation tissue were thoroughly curetted and the defect became more apparent (**Figure 2**).



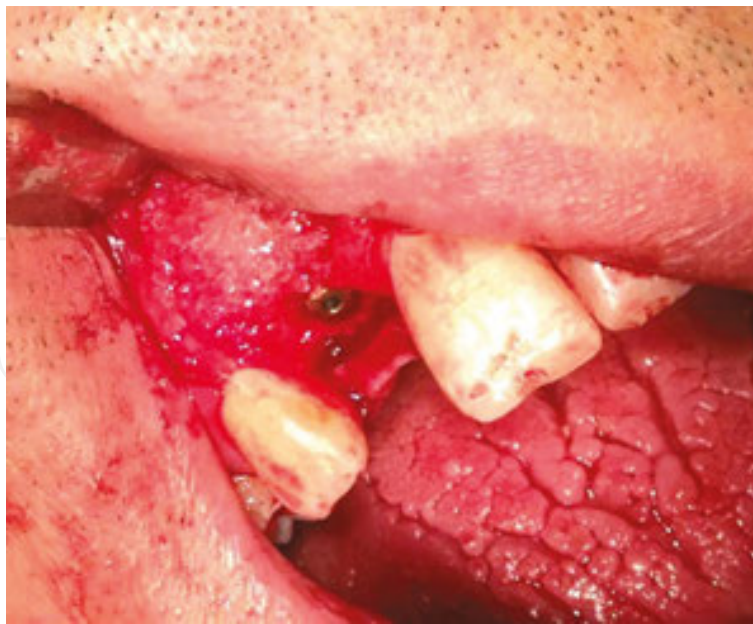**Figure 2.** The remaining granulation tissues were thoroughly curetted and the defect became more apparent.

The implant site was prepared. A 3.4 × 11 mm implant (Bone Trust, Medical Instinct Zahn Implantate, Bovenden, Germany) was placed (**Figure 3**).



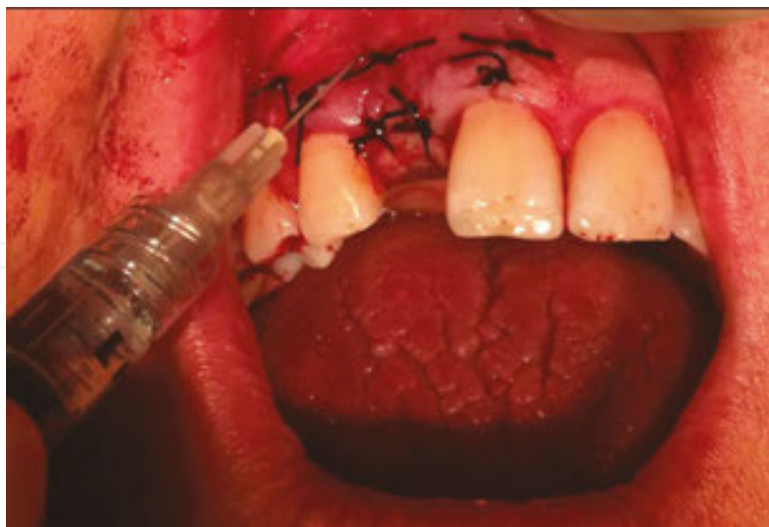**Figure 3.** Placement of the implant.

The defect was grafted by using bioactive glass material (Leonardo, Naturelize, Hirschberg, Germany) mixed with non-cross-linked HA (Tissue Support Hyaluronic Acid Liquid Gel, Hyadent Bioscience GmbH, Ransbach-Baumbach, Germany) (**Figure 4**).



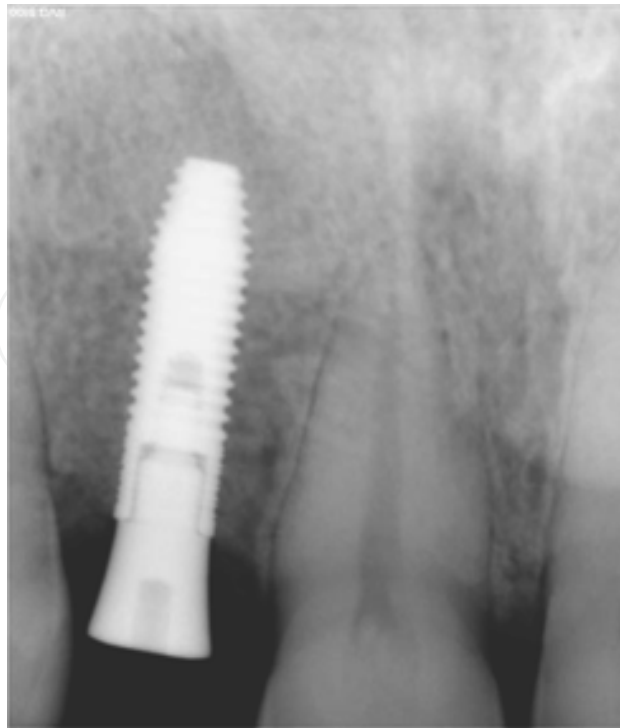**Figure 4.** The defect was grafted by using bioactive glass material mixed with non-cross-linked HA.

The surgical field was covered by using cross-linked HA gel to avoid epithelial ingrowth to the grafted area. After closure of the surgical field with 4/0 silk sutures, the remaining cross-linked HA gel (Flex Barrier Hyaluronic Acid Gel, Hyadent Bioscience GmbH, Ransbach-Baumbach, Germany) was injected into the surgical field in order to obtain a more predictable soft tissue profile and benefit from antibacterial properties of the material (**Figure 5**).



**Figure 5.** The injection of the remaining cross-linked HA into the surgical field.

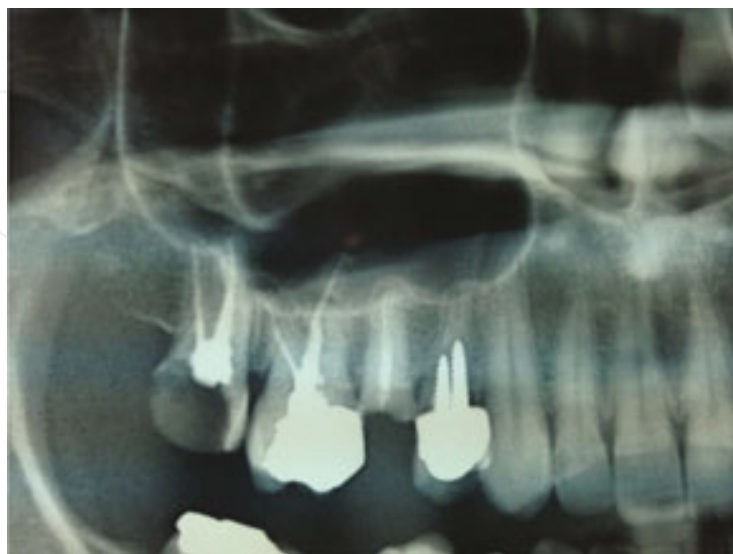
Four months after implant placement (**Figure 6**), an ideal implant-bone contact was observed and the implant was functionally loaded. The patient was functionally and esthetically satisfied.



**Figure 6.** Four months after implant placement, an ideal implant-bone contact was observed.

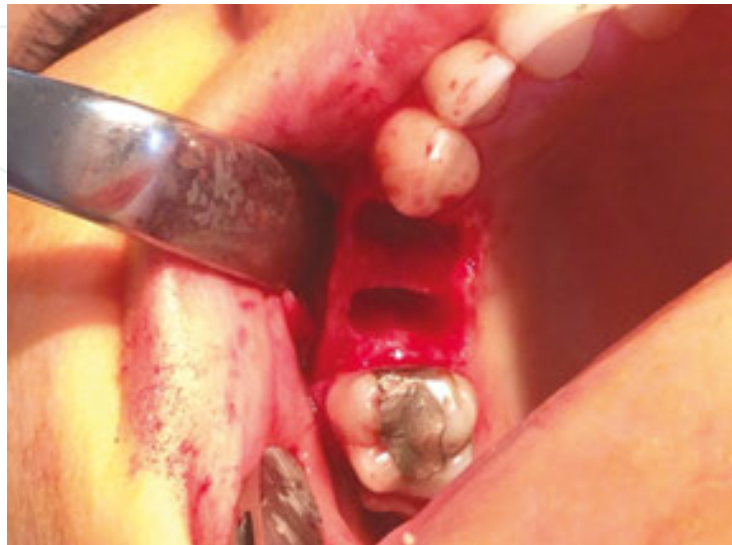## 5.2. Immediate post-extraction implant placement

A 34-year-old healthy female patient was admitted following the fracture of her upper left second premolar. On the clinical and radiographical examination, it was observed that upper left first and second premolars were unrestorable (**Figure 7**).

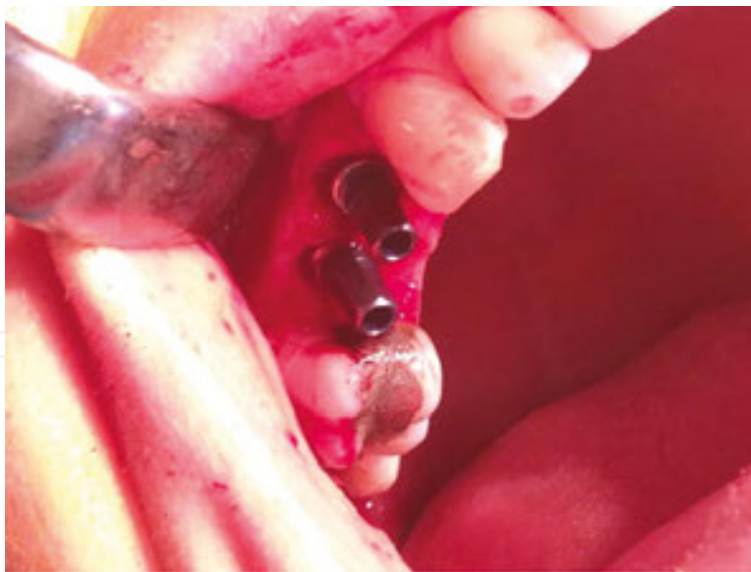

**Figure 7.** Radiological view of the upper right quadrant.

After consultation with the department of prosthodontics, it was decided to extract both teeth and to place implants simultaneously. Under local anesthesia, a full thickness flap was raised, both teeth were extracted (**Figure 8**) and two 5 × 11 mm Bone Trust implants (Bone Trust, Medical Instinct Zahn Implantate, Bovenden, Germany) were placed (**Figure 9**).

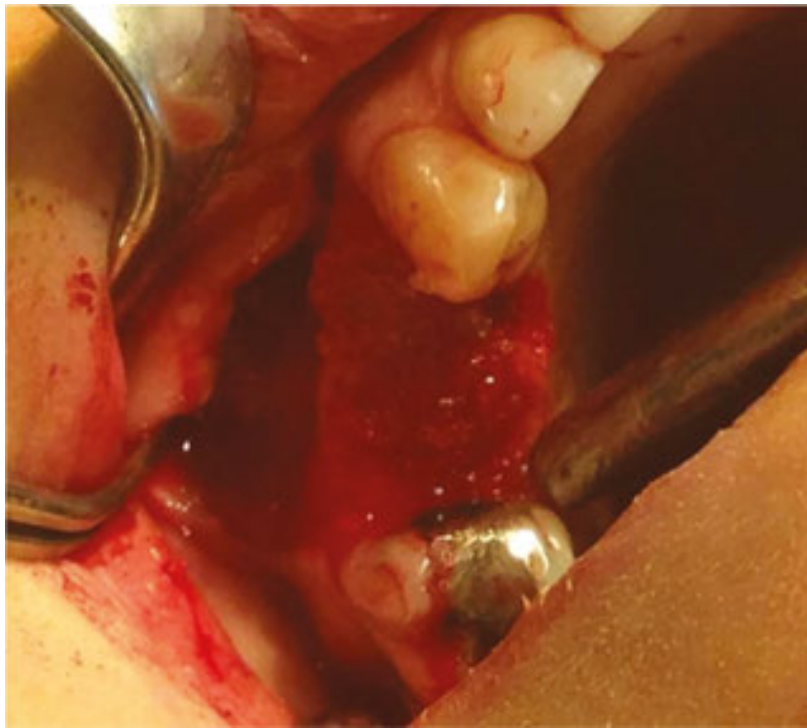


**Figure 8.** Intra-oral view after extraction of the upper first and second premolars.



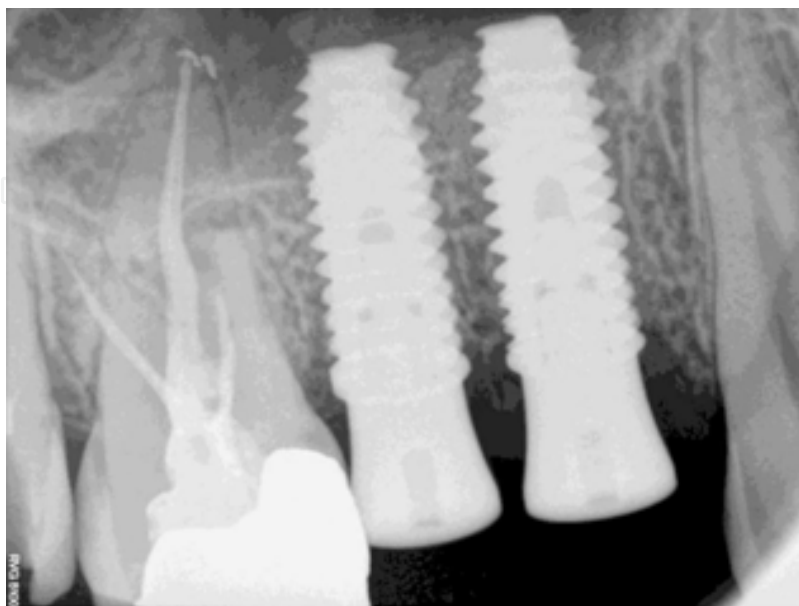
**Figure 9.** Placement of the implants. Please note the gap between the implants and the alveolus.

A gap was observed between the implant and the extraction socket, and these defects were grafted by using bioactive glass material (Leonardo, Naturelize, Hirschberg, Germany) mixed with non-cross-linked HA gel (Tissue Support Hyaluronic Acid Liqui Gel, Hyadent Bioscience GmbH, Ransbach-Baumbach, Germany) (**Figure 10**).

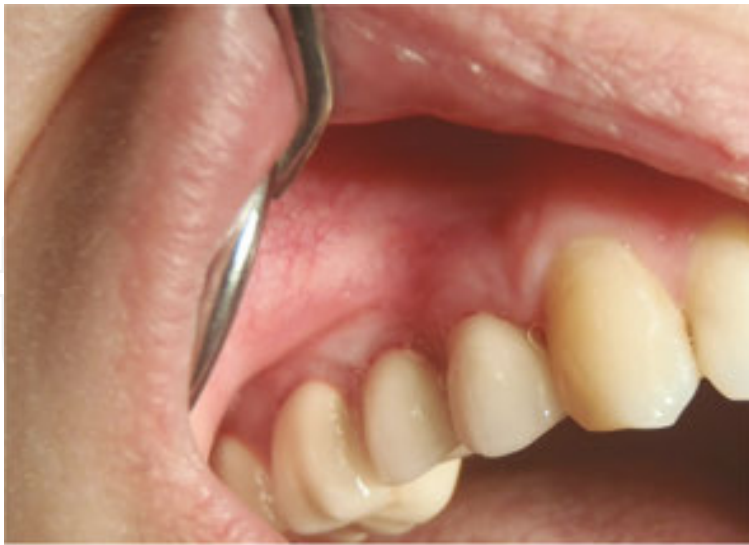

**Figure 10.** Grafting of the area with bioactive glass material mixed with non-cross-linked HA.

A cross-linked HA gel (Flex Barrier Hyaluronic Acid Gel, Hyadent Bioscience GmbH, Ransbach-Baumbach, Germany) was injected over the implants and the graft material. Three months after implant placement (**Figure 11**), the implant was functionally loaded. The patient was satisfied both esthetically and functionally (**Figure 12**).



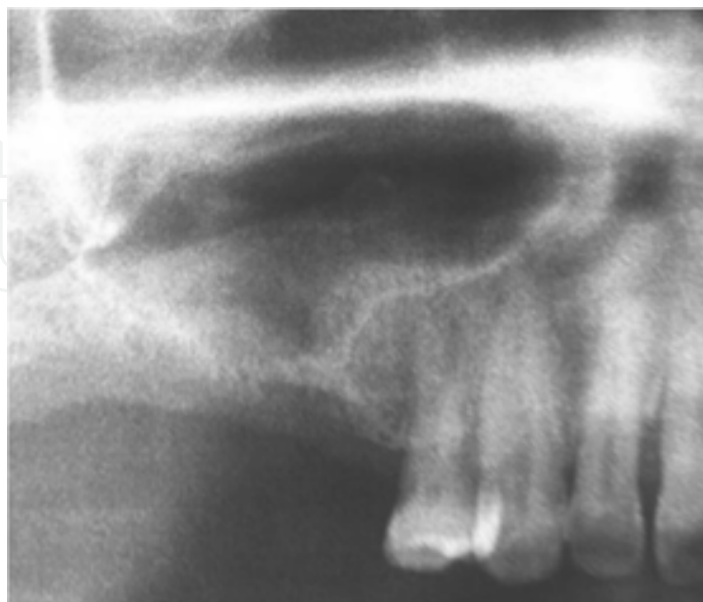**Figure 11.** Three months after implant placement, an ideal implant-bone contact was observed.



**Figure 12.** Clinical view after prosthetic procedure.

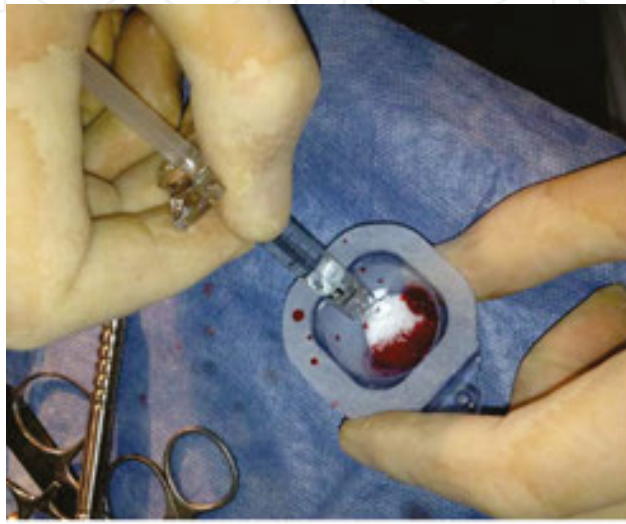
### 5.3. Sinus bone grafting

A 44-year-old healthy female patient presented to our department and requested a fixed prosthesis of the right maxillary posterior region. The teeth had to be removed at another clinic as a result of failed endodontic procedures. Clinical and radiological examinations showed the lack of an adequate vertical bone, but sufficient width of the alveolar ridge. Given that the residual vertical bone height was  $\leq 3$  mm (**Figure 13**), we planned to insert the implants following the sinus floor augmentation procedure.

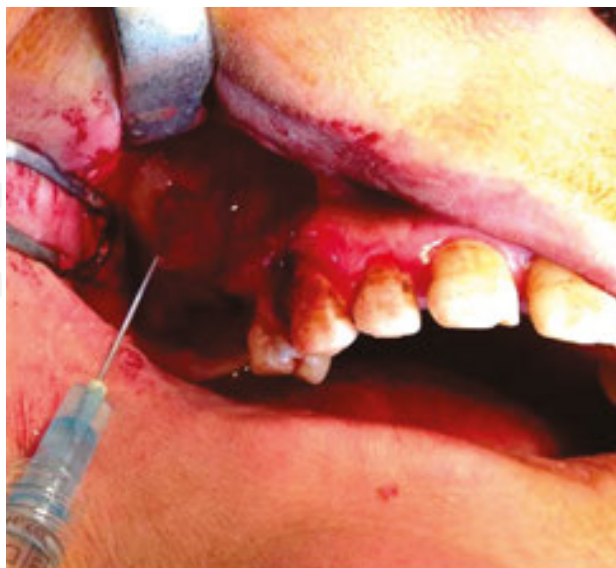

**Figure 13.** Preoperative radiological view.

A trapezoid incision was made under local anesthesia to reflect a mucoperiosteal flap. The vestibular portion of the maxillary sinus was exposed, a maxillary sinus window was prepared and the sinus membrane was elevated. The sinus cavity was augmented with a bioactive glass bone graft material (Leonardo, Naturelize, Hirschberg, Germany), which we had mixed with non-cross-linked HA (Tissue Support Hyaluronic Acid Liqui Gel, Hyadent Bioscience GmbH, Ransbach-Baumbach, Germany) extra-orally (**Figure 14**), and the lateral coverage of the augmentation site was made by using cross-linked HA gel (Flex Barrier Hyaluronic Acid Gel, Hyadent Bioscience GmbH, Ransbach-Baumbach, Germany) (**Figure 15**).

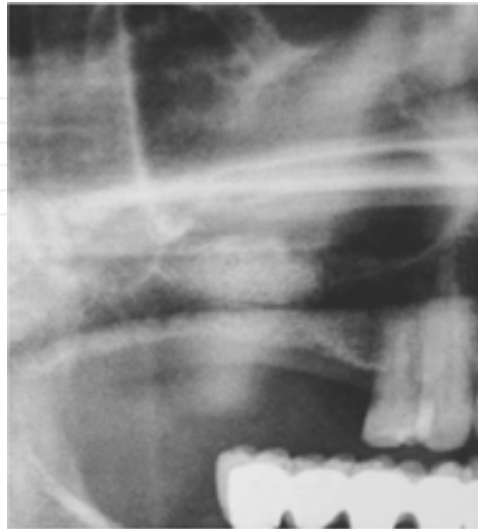


**Figure 14.** Mixing procedure of the bioactive glass bone graft material with non-cross-linked HA.



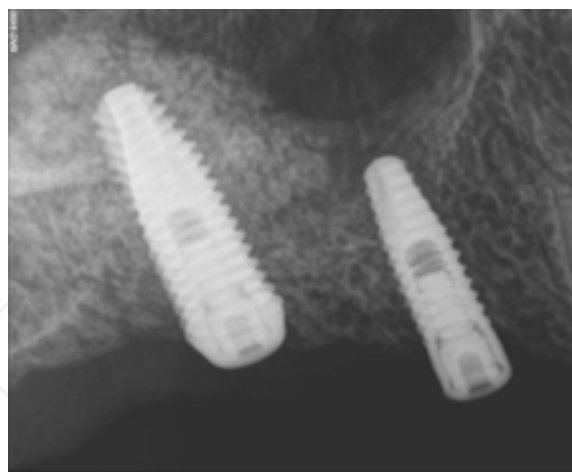
**Figure 15.** Augmentation of the sinus cavity with bioactive glass material mixed with non-cross-linked HA. Lateral coverage of the augmentation site was made by using cross-linked HA gel.

On radiographic examination 5 months postoperatively, particulated structure of the graft material was not seen and radio-opaque structure resembling the newly formed bone was observed (**Figure 16**).



**Figure 16.** On the radiographic examination 5 months postoperatively, radio-opaque structure resembling the newly formed bone was observed.

Two implants (Oxy Biomec SRL, Colico, Italy) of 4, 5 × 10 mm were placed (**Figure 17**).



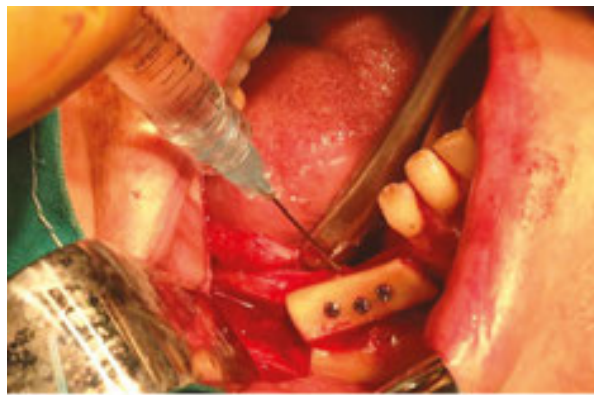**Figure 17.** Placement of the implants.

The implants were surgically exposed and the prosthetic procedures were performed.

#### 5.4. Covering of the autologous bone graft recipient sites (as a barrier membrane)

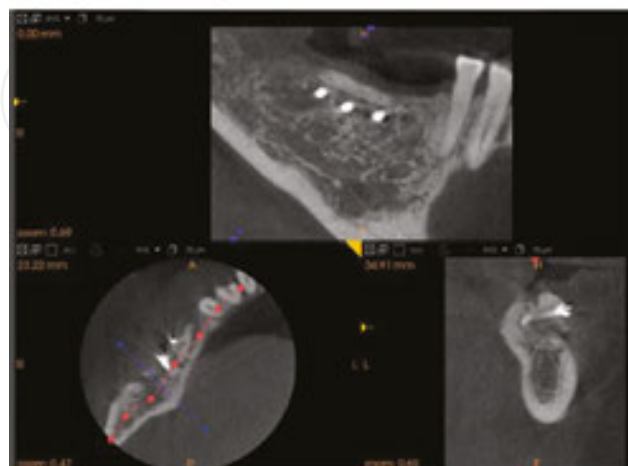
A 54-year-old female patient was admitted due to the difficulties in eating secondary to edentulousim of her lower left posterior mandible. According to her medical history, she

was under steroid therapy due to lupus erythematosus. Clinically and radiographically, the corresponding area was extremely thin and it was decided to perform a ramus grafting procedure prior to implant placement. Under local anesthesia, a full thickness flap was raised, the recipient site and the ramus area were exposed, a bone block of 10 × 15 mm was harvested by using piezotome (Variosurg, NSK, Japan). Decortication of the recipient site was made by using round burr and the bone block was adapted and secured via three titanium screws. In order to avoid soft tissue ingrowth into the existing minimal gap between the bone block and the alveolar bone, the entire surface of the bone block was covered with cross-linked HA gel (Flex Barrier Hyaluronic Acid Gel, Hyadent Bioscience GmbH, Ransbach-Baumbach, Germany) (**Figure 18**).

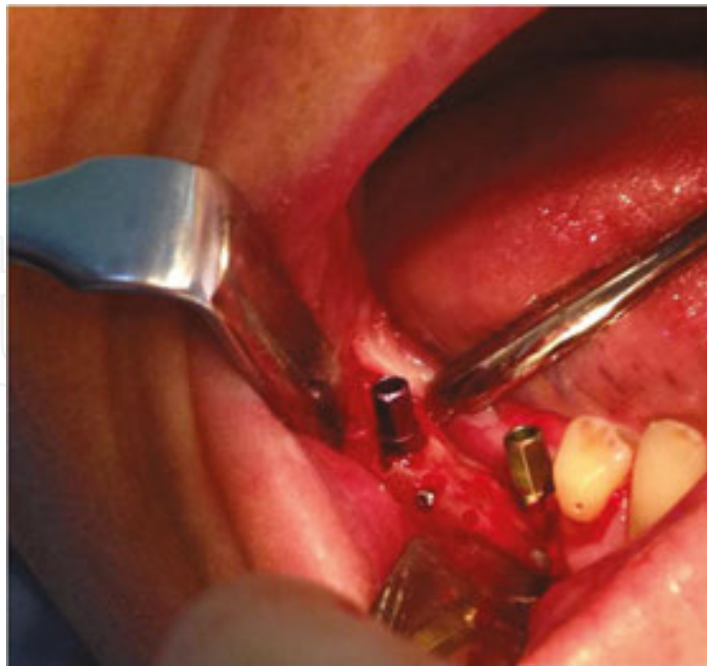

**Figure 18.** In order to avoid soft tissue ingrowth into the existing minimal gap between the bone block and the alveolar bone, the entire surface of the bone block was covered with cross-linked HA gel.

The postoperative period was uneventful. Three months postoperatively, radiological examination showed successful healing at the grafted site (**Figure 19**) and two implants were inserted into the grafted site (**Figure 20**).



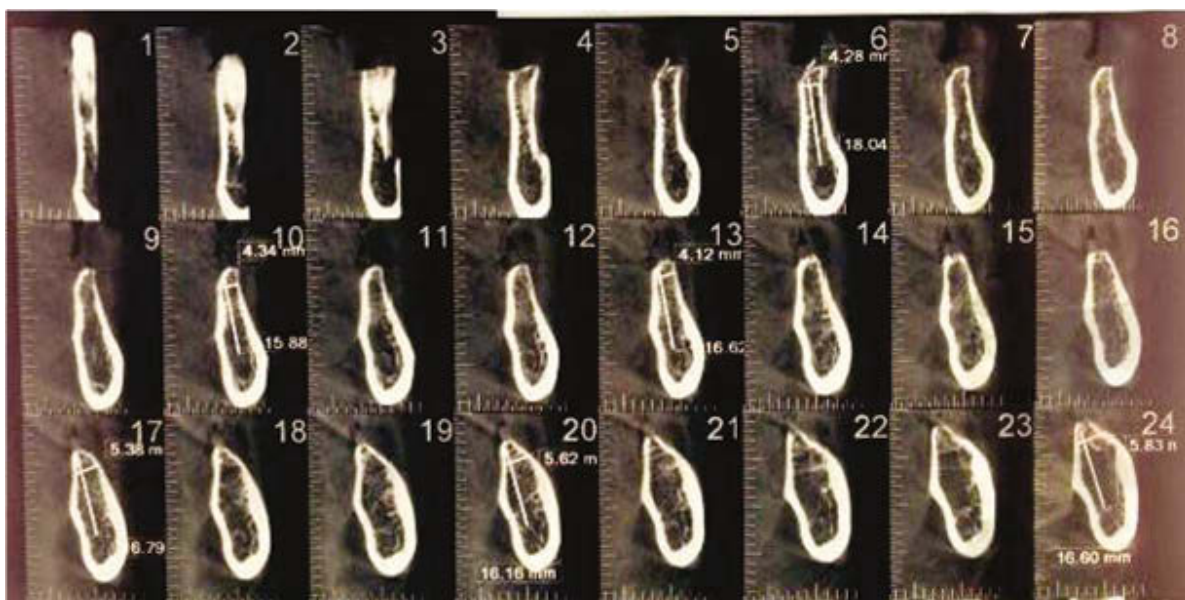
**Figure 19.** Three months postoperatively, radiological examination showed successful healing at the grafted site.



**Figure 20.** Two implants were placed into the grafted site.

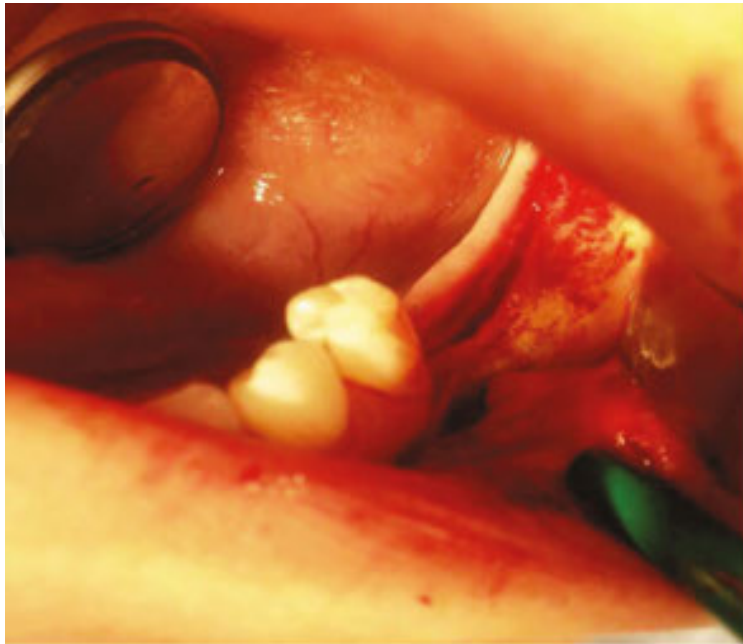### 5.5. Ridge splitting

A 44-year-old female patient was admitted due to the difficulties in eating. Clinically and radiographically, her left posterior mandible area was extremely thin and it was decided to perform a ridge splitting procedure prior to implant placement (**Figure 21**).



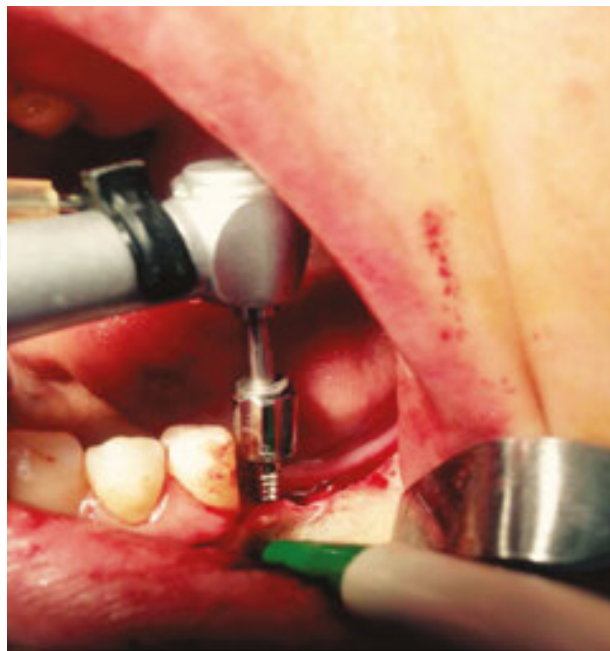
**Figure 21.** Radiographically, the corresponding area was extremely thin.

Under local anesthesia, a full thickness flap was raised, the recipient site and the ramus area were exposed, the alveolar ridge was decorticated and then splitted via osteotomes (**Figure 22**).



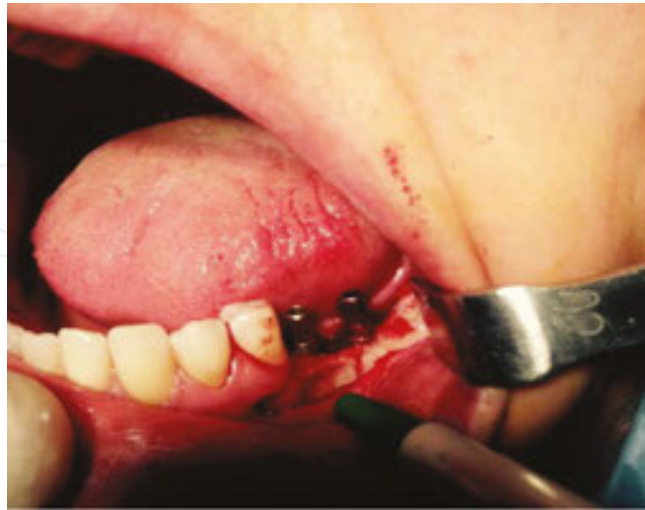**Figure 22.** The alveolar ridge was split via osteotomes.

A bone spreader was used to prepare the implant sockets (**Figure 23**).



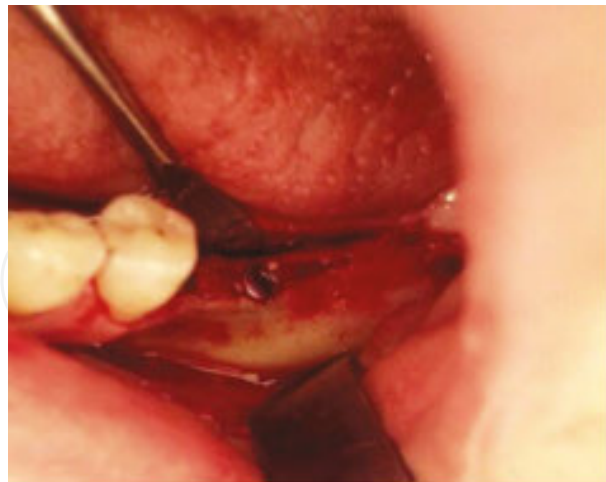**Figure 23.** Bone spreader was used to prepare the implant sockets.

Two implants (Bone Trust, Medical Instinct Zahn Implantate, Bovenden, Germany) were inserted into the grafted area (**Figure 24**).



**Figure 24.** Two implants (Bone Trust, Medical Instinct Zahn Implantate, Bovenden, Germany) were inserted into the grafted area.

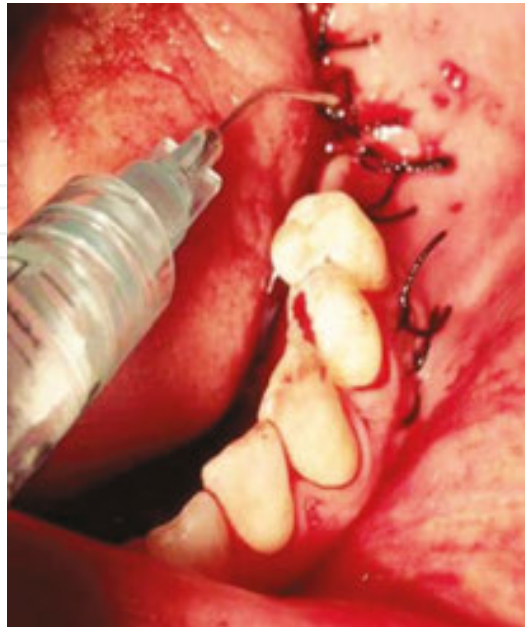The gap between the splitted fragments were grafted with bioactive glass bone graft material (Leonardo, Naturelize, Hirschberg, Germany), which we had mixed with non-cross-linked HA (Tissue Support Hyaluronic Acid Liqui Gel, Hyadent Bioscience Gmbh, Ransbach-Baumbach, Germany) (**Figure 25**).



**Figure 25.** The gap between the splitted fragments were grafted with bioactive glass bone graft material (Leonardo, Naturelize, Hirschberg, Germany), which we had mixed with non-cross-linked hyaluronic acid (Tissue Support Hyaluronic Acid Liqui Gel, Hyadent Bioscience Gmbh, Ransbach-Baumbach, Germany).

In order to avoid soft tissue ingrowth into the existing minimal gap between the bone block and the alveolar bone, the entire surface of the splitted area was covered with cross-linked HA

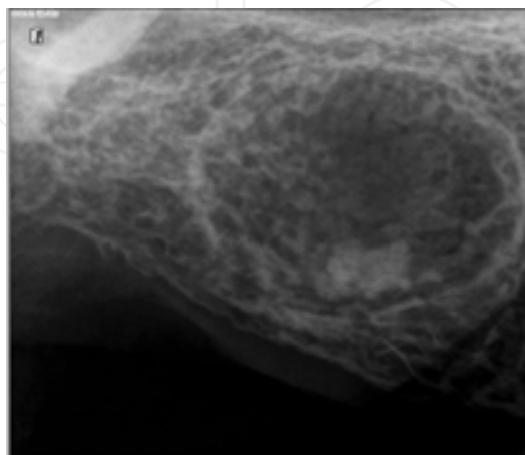
gel (Flex Barrier Hyaluronic Acid Gel, Hyadent Bioscience GmbH, Ransbach-Baumbach, Germany) (**Figure 26**). The postoperative period was uneventful.



**Figure 26.** In order to avoid soft tissue ingrowth into the existing minimal gap between the bone block and the alveolar bone, the entire surface of the splitted area was covered with cross-linked HA gel (Flex Barrier Hyaluronic Acid Gel, Hyadent Bioscience GmbH, Ransbach-Baumbach, Germany) before and after primary closure.

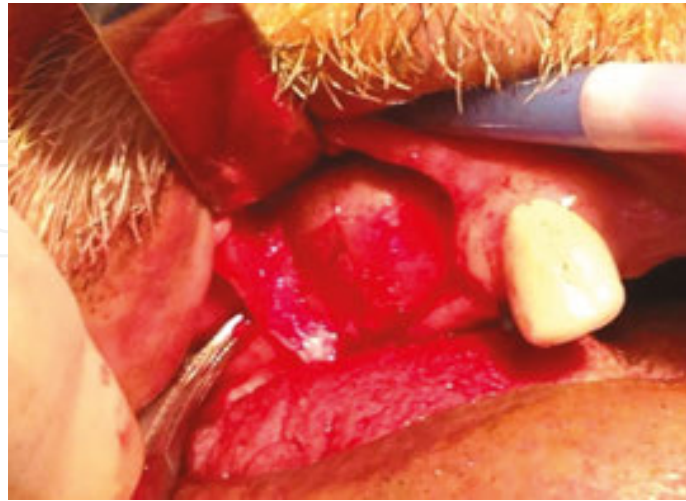
### 5.6. Filling of the bone defects following removal of oral lesions

A 64-year-old male patient was admitted due to swelling of his upper edentulous right maxilla. Radiographically, a radio-opacity resembling a residual root tip surrounded by a radiolucency was observed (**Figure 27**).



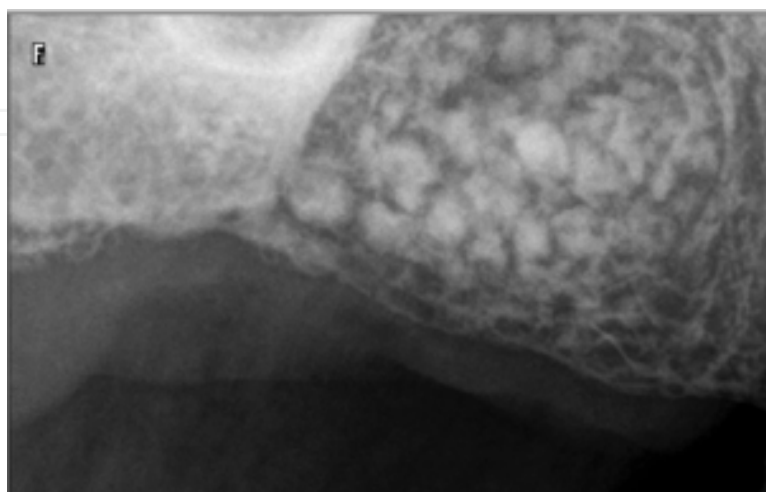
**Figure 27.** A radio-opacity resembling a residual root tip surrounded by a radiolucency.

Under local anesthesia, a full thickness flap was raised, the corresponding area was exposed (**Figure 28**) and the cyst was curetted.



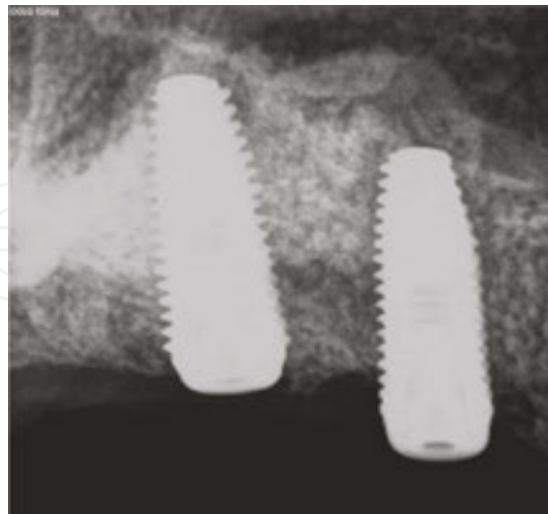
**Figure 28.** Surgical exposure of the cyst.

The cavity was filled with a bioactive glass bone graft material (Leonardo, Naturelize, Hirschberg, Germany), which we had mixed with non-cross-linked HA (Tissue Support Hyaluronic Acid Liqui Gel, Hyadent Bioscience GmbH, Ransbach-Baumbach, Germany) extra-orally and the lateral coverage of the augmentation site was made by using cross-linked HA gel (Flex Barrier Hyaluronic Acid Gel, Hyadent Bioscience GmbH, Ransbach-Baumbach, Germany). On the radiographic examination 2 months postoperatively, particulated structure of the graft material and radio-opaque structure resembling the newly formed bone were observed (**Figure 29**).



**Figure 29.** Two months postoperatively, radiological examination showed successful healing and particulated structure of the bone graft material.

The patient underwent implant surgery 3 months after cyst removal (**Figure 30**).



**Figure 30.** The patient underwent an implant surgery 3 months after cyst removal.

Two implants (Oxy Biomec SRL, Colico, Italy) were placed into the grafted site. As can be seen from our clinical outcomes, HA is a highly promising material for improving therapeutic outcomes for oral implantology.

## Author details

Fatih Özhan<sup>1\*</sup>, Metin Şençimen<sup>2</sup>, Aydın Gülses<sup>2</sup> and Mustafa Ayna<sup>3</sup>

\*Address all correspondence to: [dtfatihozan@gmail.com](mailto:dtfatihozan@gmail.com)

1 Faculty of Dentistry, Department of Oral and Maxillofacial Surgery, Abant İzzet Baysal University, Bolu, Turkey

2 Department of Dental Sciences, Department of Oral and Maxillofacial Surgery, Gülhane Military Medical Academy, Ankara, Turkey

3 Center for Implant Dentistry, Duisburg, Germany

## References

- [1] Schropp L, Wenzel A, Kostopoulos L, Karring T: Bone healing and soft tissue contour changes following single-tooth extraction: a clinical and radiographic 12-month prospective study. *Int J Periodontics Restorative Dent.* 2003; 23: 313-323.

- [2] Dahlin C, Gottlow J, Lindhe A, Nyman S: Healing of maxillary and mandibular bone defects using a membrane technique. An experimental study in monkeys. *Scand J Plast Reconstr Surg Hand Surg.* 1990; 24: 13-19.
- [3] Dahlin C, Linde A, Gottlow J, Nyman S: Healing of bone defects by guided tissue regeneration. *Plast Reconstr Surg.* 1988 ; 81: 672-676.
- [4] Dahlin C, Sennerby L, Lekholm U, Linde A, Nyman S: Generation of new bone around titanium implants using a membrane technique: an experimental study in rabbits. *Int J Oral Maxillofac Implants.* 1989; 4: 19-25.
- [5] Urist MR, McLean FC: Recent advances in physiology of bone: Part I. *J Bone Joint Surg Am.* 1963; 45: 1305-1313.
- [6] Murphy KG: Postoperative healing complications associated with Gore-Tex periodontal material. Part I. Incidence and characterization. *Int J Periodontics Restorative Dent.* 1995; 15: 363-375.
- [7] Wang HL, Carroll MJ: Guided bone regeneration using bone grafts and collagen membranes. *Quintessence Int.* 2001; 32: 504-515.
- [8] Baisse E, Piotrowski B, Piantoni P, Brunel G: Action of hyaluronic acid on the wound healing process following extraction. *Dent Inf.* 2004; 7: 1-9.
- [9] Huang L, Cheng YY, Koo PL, Lee KM, Qin L, Cheng JC, Kumpta SM: The effect of hyaluronan on osteoblast proliferation and differentiation in rat calvarial-derived cell cultures. *J Biomed Mater Res.* 2003; 15; 66A: 880-884.
- [10] Peattle RA, Nayate AP, Firpo MA, Shelby J, Fisher RJ, Prestwich GD: Stimulation of in vivo angiogenesis by cytokine-loaded hyaluronic acid hydrogel implants. *Biomaterials.* 2004; 25(14): 2789-2798.
- [11] Chen J, Abatangelo G: Functions of hyaluronan in wound repair. *Wound Repair Regen.* 1999; 7: 79-89.
- [12] Toole BP: Hyaluronan and its binding proteins, the hyaladherins. *Curr Opin Cell Biol.* 1990; 2: 839-844.
- [13] Petersen S, Kaule S, Teske M, Minrath I, Schmitz KP, Sternberg K: Development and in vitro characterization of hyaluronic acid-based coatings for implant-associated local drug delivery systems. *J Chem.* 2013; 2013(2013):11. Article ID 587875. doi: 10.1155/2013/587875.
- [14] Nolon A, Baillie C, Badminton J, Rudralinglam M, Seymour RA: The efficacy of topical hyaluronic acid in the management of recurrent aphthous ulceration. *J Oral Pathol Med.* 2006; 35: 461-465.
- [15] Jentsch H, Pomowski R, Kundt G, Göcke R: Treatment of gingivitis with hyaluronan. *J Clin Periodontol.* 2003; 30: 159-164.

- [16] Mendes RM, Silva GA, Lima MF, Calliari MV, Almeida AP, Alves JB, Ferreira AJ: Sodium hyaluronate accelerates the healing process in tooth sockets of rats. *Arch Oral Biol.* 2008; 53: 1155-1162.
- [17] Mansouri SS, Ghasemi M, Salmani Z, Shams N: Clinical application of hyaluronic acid gel for reconstruction of interdental papilla at the esthetic zone. *JIDA.* 2013; 25: 152-157.
- [18] Claar M: Hyaluronic acid in oral implantology. *EDI Case Studies.* 2013; 4: 64-68.
- [19] Wang HL, Carroll MJ: Guided bone regeneration using bone grafts and collagen membranes. *Quintessence Int.* 2001; 32: 504-515.
- [20] Hitti RA, Kerns DG: Guided bone regeneration in the oral cavity: a review. *Open Pathol J.* 2011; 5: 33-45.
- [21] Marinucci L, Lilli C, Baroni T: In vitro comparison of bioabsorbable and non-resorbable membranes in bone regeneration. *J Periodontol.* 2001; 72: 753-759.
- [22] Blumenthal NM: The use of collagen membranes to guide regeneration of new connective tissue attachment in dogs. *J Periodontol.* 1988; 59: 830-836.

