

# We are IntechOpen, the world's leading publisher of Open Access books Built by scientists, for scientists

6,900

Open access books available

186,000

International authors and editors

200M

Downloads

Our authors are among the

154

Countries delivered to

TOP 1%

most cited scientists

12.2%

Contributors from top 500 universities



WEB OF SCIENCE™

Selection of our books indexed in the Book Citation Index  
in Web of Science™ Core Collection (BKCI)

Interested in publishing with us?  
Contact [book.department@intechopen.com](mailto:book.department@intechopen.com)

Numbers displayed above are based on latest data collected.  
For more information visit [www.intechopen.com](http://www.intechopen.com)



---

## Treatment of Oral Fistulas

---

Erol Cansiz, Alper Gultekin, Melek Koltuk and  
Sirmahan Cakarar

Additional information is available at the end of the chapter

<http://dx.doi.org/10.5772/63015>

---

### Abstract

The term “fistula” can be defined as an improper connection between different body compartments. It can occur in different parts of the body. Although, fistulae mostly develop due to untreated chronic infections, traumatic injuries and congenital deformities, specific infections or diseases, and post-surgical healing abnormalities can also cause fistula formation. Although, there is a general classification system made by the World Health Organization to identify fistulae, specifically, in this chapter oral fistulae are divided into four different categories, namely dentoalveolar, oroantral, oronasal and orocutaneous fistulae. The diagnosis and the treatment protocols for oral fistulas are described using this specific classification and with additional new techniques introduced for the correction of the lesions. Conventional surgical methods also are summarized. The importance of the radiological examination is emphasized and the practitioners are informed of possible complications.

**Keywords:** fistula, dentoalveolar, oroantral, oronasal, orocutaneous

---

### 1. Introduction

The term “fistula” can be defined as an improper connection between different body compartments. They may be acquired or congenital and can occur in different parts of the body. Although, fistulae mostly develop due to untreated chronic infections, traumatic injuries, congenital deformities, specific infections or diseases, post-surgical healing abnormalities may also cause fistula formation.

The diagnosis and treatment of oral fistulas are well-described subjects in the literature. However, they are often misdiagnosed by dentists and physicians as cutaneous lesions or

non-odontogenic infections. The diagnosis of an oral fistula may be challenging because of the complex oral anatomy, and it requires the aid of radiological, microbiological, and/or pathological methods. In addition, detailed history taking and clinical examination are key factors for the diagnosis of oral fistulas.

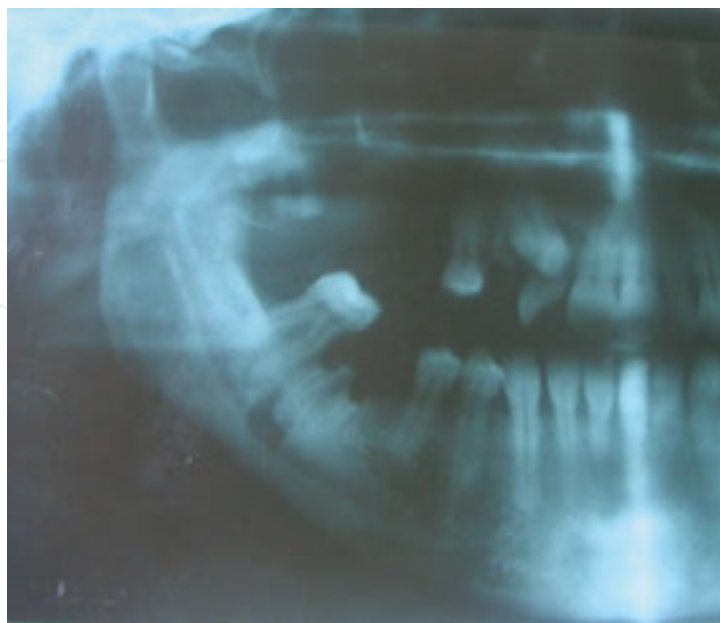
Although, dentoalveolar, oroantral, oronasal, and orocutaneous fistulae are the most frequent types related to the oral cavity, an oral fistula may vary depending on the origin. Consequently, determining the source of the fistula is the first step in treatment, which must be directed primarily to the underlying cause.

The present chapter reviews classification, etiological factors, diagnosis, and the treatment of the four major fistula types related to the oral cavity. The chapter also focuses on the different surgical techniques of treatment of fistulae according to the clinical causes of the lesions.

## 2. Types of oral fistulas

### 2.1. Dentoalveolar fistula

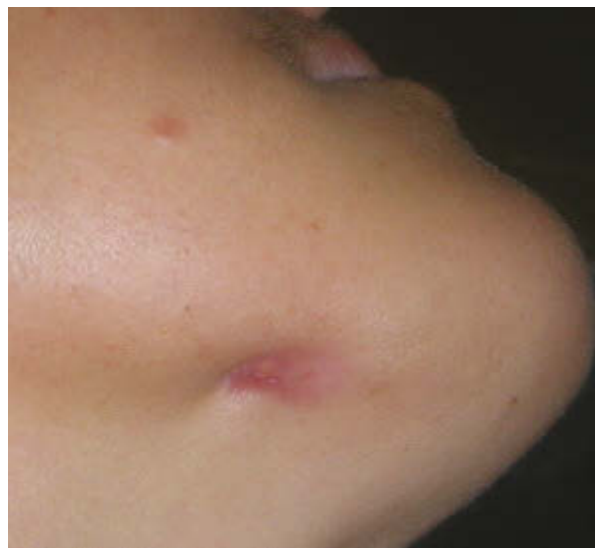Dentoalveolar fistula is a pathological pathway between the oral cavity and alveolar bone. They mostly occur as a result of infected cysts, mandibular or maxillary fractures, periodontal inflammation, necrotic teeth, and trauma. But the most common causes are pulpal necrosis and apical periodontitis [1–4]. On the other hand, differential diagnosis should include osteomyelitis, syphilis, tuberculosis, noma, actinomycosis, trauma, pyogenic granuloma, and neoplasia [2, 3].



**Figure 1.** Periradicular infection due to necrotic teeth.

Necrotic teeth usually have a history of trauma, tooth decay, periodontal disease, or orthodontic tooth movement. When the dental pulp becomes necrotic, the root canal becomes a potential site of bacterial colonization. At this stage if the treatment is not performed, infection spreads into the periradicular area, resulting in apical periodontitis and follows the path of least resistance in the bone and soft tissue (**Figure 1**).

The location of muscle attachments and the position of root tips determine the direction and the location of the fistula to the surface. Once the periradicular infection spreads and the cortical wall of the alveolar bone is perforated, the fistula follows the interstitial spaces. Although most of the periradicular infections end within the loose connective tissue compartments and cause abscess formation, they can reach to the skin or the oral mucosa and induce fistula formation (**Figure 2**).

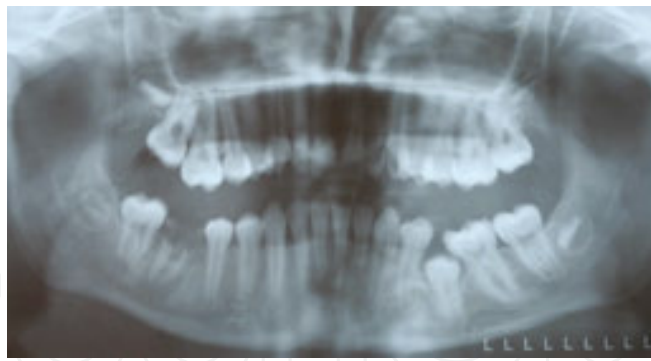


**Figure 2.** Extraoral view of the patient in **Figure 1**. Extraoral fistula formation.

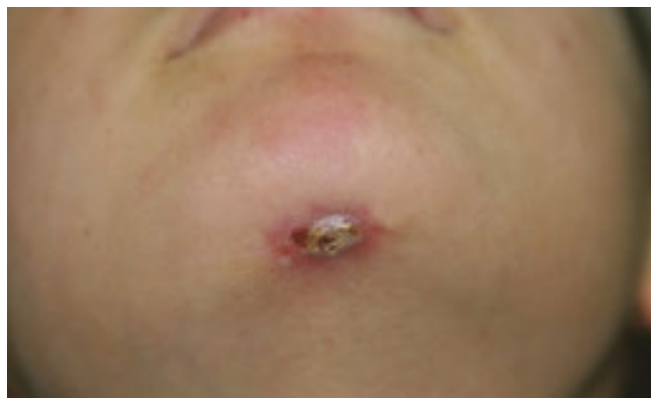The direction of a fistula differs for the maxilla and mandible due to the location of muscle attachments, root inclinations, and the localization of the root tips.

**In the maxilla**, generally, fistula tract formation from incisors exit on the labial vestibular mucosa, but lateral incisors may exit the palate due to distal inclination of the root. On the other hand, canines may lead to canine fossa abscess without fistula formation, if the root apex position is above the levator anguli oris attachments. For the molars and premolars, the fistula may occur in the buccal sulcus or spread to the buccal space. However, infected roots located palatally can lead to palatal abscess or fistula formation. In addition, they can easily spread to the maxillary sinuses that can lead to odontogenic maxillary sinusitis especially if there is a close relationship between the sinus floor and root apices [5–7].

**In the mandible**, periradicular infection of the incisors mostly leads to labial vestibular fistula formation. On the other hand, if the root tip of the canine is located under the mentalis muscle attachments, the fistula may spread to the subcutaneous area and can lead to an orocutaneous fistula formation on the chin (**Figures 3 and 4**) [8].

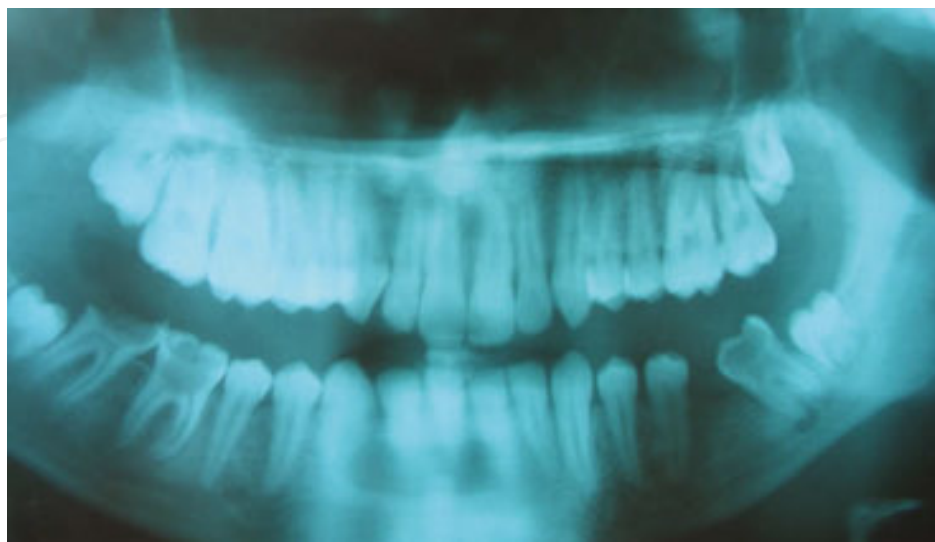


**Figure 3.** Necrotic mandibular incisors.



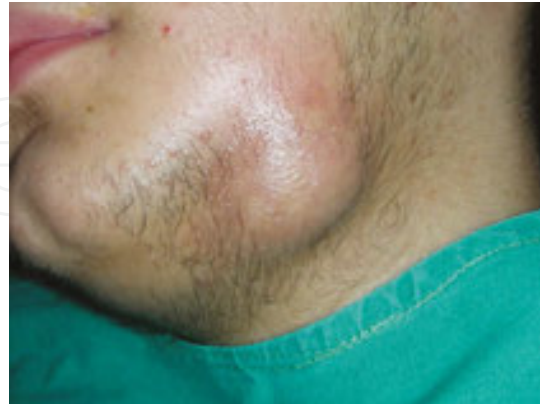**Figure 4.** Fistula formation on the chin due to necrotic mandibular incisors.

The location of the mylohyoid muscle is an important factor in submental and submandibular abscess formation. The root tips of mandibular premolar and molar teeth are mostly located



**Figure 5.** Submandibular abscess due to periradicular infection of the molar tooth.

below the mylohyoid muscle attachments, and the periradicular infection of these teeth spreads mostly under that muscle directly to the submental or submandibular spaces (**Figures 5 and 6**).



**Figure 6.** Radiograph of periradicular infection of the left mandible.

On the other hand, if the root tips are located at the buccal side of the mandibular alveolar bone, they may lead to fistula formation in the vestibular sulcus. However, if the buccally positioned root apices are located below the buccinator muscle, they may lead a buccal space abscess or orocutaneous fistula formation at the base or the mandibular [9].

Although the diagnosis of a dentoalveolar fistula is not challenging generally, they can be misdiagnosed by dentists and physicians. Furthermore, they may be mistaken for a neoplastic lesion because of their clinical appearance. For the determination of the origin, periapical and panoramic radiographs are helpful. On the other hand, Cone Beam Computed Tomography (CBCT) or MRI can be used when conventional radiography is insufficient. Placement of radiopaque material, such as gutta percha, during radiologic examinations is a useful method for the determination of the length, the localization of the fistula tract, and identifying the tooth causing it.

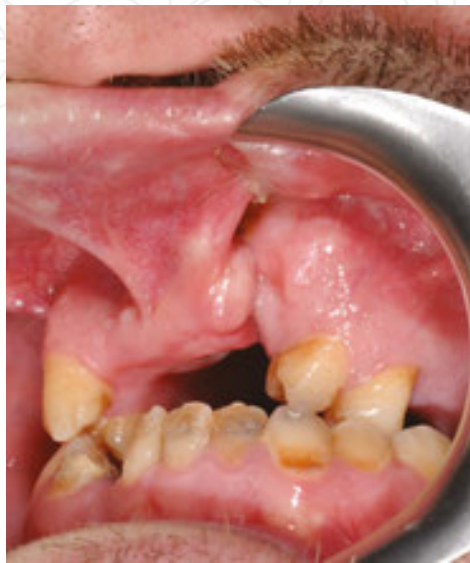The principle of managing such lesions is to remove the source of the infection. Prescribing an antibiotic drug for the treatment of a dentoalveolar fistula is a common mistake. The removal of the infected pulp tissue by appropriate endodontic treatment is a simple and effective treatment modality for eradicating periradicular infection in a very short time. On the other hand, if there is a periradicular granuloma formation, apical resection in addition to endodontic treatment may be required. However, if there is no indication for endodontic treatment or apical resection, extraction of the infected tooth and curettage of the periradicular region may be required.

## **2.2. Oronasal fistulas**

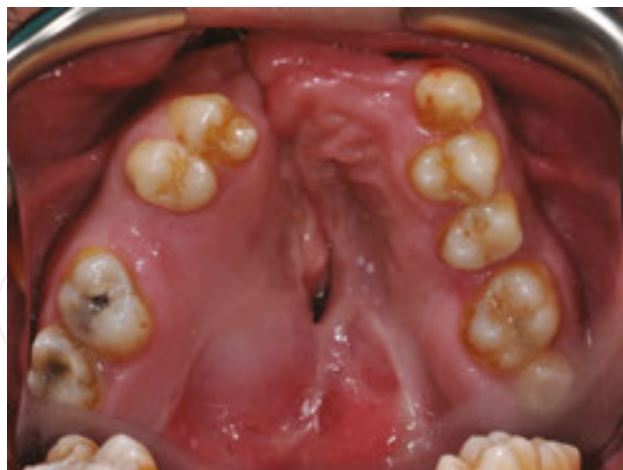A tract unnaturally leading from oral cavity to the nasal cavity is defined as oronasal fistula (ONF). Although tumor resections are the major reason of ONF formation, these openings are also seen frequently as a complication of cleft lip and palate reconstructive surgery. After the

velopharyngeal insufficiency, fistulae are the second most common complication of cleft palate operations.

Fistulae that occur after primary repair of cleft palate appear in specific locations, such as intersection between the hard and soft palate or junction of the primary and secondary palate. They can also take place anywhere along the line where the cleft was situated (**Figures 7 and 8**).



**Figure 7.** Nasopalatal and palatal fistula formation after cleft surgery.



**Figure 8.** Nasopalatal and oronasal fistula formation after cleft surgery.

Predisposing factors that may cause fistulae include cleft type, surgical technique, surgeon's inexperience, patient healing capability, and the age at the time of palatoplasty [10].

The more severe the cleft, the more likely a fistula may occur [11]. The incidence of formation of a fistula is higher in complete primary and secondary palate cleft reconstruction site rather

than isolated clefts. Similarly, a fistula is more likely in a patient who has bilateral cleft lip and palate (40.9%), in comparison to unilateral clefts (16.9%) [12]. The Veau classification is a classification that divides the cleft lip and palate into four groups according to cleft severity [13]. Patients with a Veau IV cleft (complete bilateral soft, hard, and/or lip and alveolar ridge cleft) are more prone to develop an ONF [14].

Numerous causes lead to fistulation in cleft patients after surgery, such as infection, hematoma formation, flap necrosis, inadequate occlusion, or excessive tension on the cleft repair site. Infection can be caused by the absence of oral hygiene or upper respiratory system infection. Hematoma formation between the nasal and oral layers that may generate excessive tension at the wound site also causes infection. Needless trauma during repositioning the flap, lacerations, or any movement that disrupts perfusion of the flap can lead to flap necrosis. Especially, later wide cleft closure operations, using inadequate material, absence of multilayer seal, or faulty suturing can cause openings in the surgery area. Trying to seal the gap with inadequate tissue produces excessive tension and leads to failure [15].

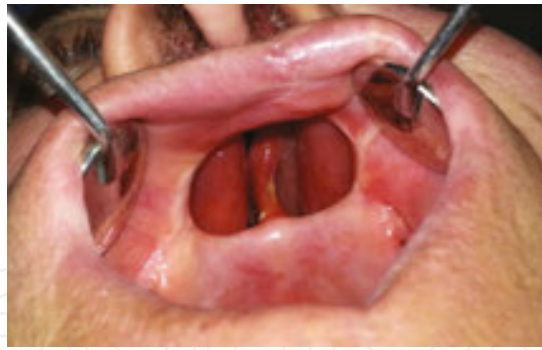ONFs cause problems due to their size. Food remnants pileup into the fistula track can cause bacterial accumulation, which leads to mucosal inflammation and bad breath. Fistulae also cause an excessive formation of thick phlegm or mucus, which can be seen in an airway or cavity and regurgitation of fluid into the nasal cavity during eating and drinking. Nasal secretions can seep into the oral cavity and create a bad taste, malodor, and cause poor oral hygiene. Even a fistula as small as 4.5 mm can cause speech problems such as hypernasal resonance, deficiency of pressure consonants, audible nasal air escape, and retracted tongue positioning while articulating speech sounds [16]. Air escapes create socially undesirable sounds that corrupt speech quality and intelligibility. Additionally, these functional problems add to social problems because of bad breath and the nasal fluid leakage. These issues can emerge after unsuccessful closure of the clefts, just like that in unoperated cleft patients.

ONFs are classified according to size such as small (1–2 mm), medium (3–5 mm), and large (>5mm) [14]. Smith et al. [17] created a classification system based on anatomic location of fistulae and named it the Pittsburgh classification. In this classification system, ONFs are divided into seven different subgroups such as; (1) bifid uvula, (2) soft palate, (3) soft and hard palate junction, (4) hard palate, (5) primary and secondary palates junction, (6) lingual alveolar, and (7) labial alveolar [17]. ONF is also described by shape as pinpoint, oval, slit, and total dehiscence [18]. The most common fistula type is the small size and slit-shaped ones. Small fistulas can remain asymptomatic, but it should be considered that after orthodontic treatment to expand the alveolar arch, fistulae can enlarge and become symptomatic.

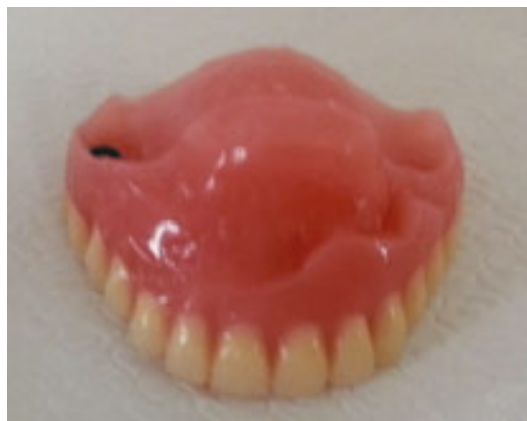### *2.2.1. Closure of ONFs*

#### *2.2.2.1. Non-invasive procedures*

Symptomatic fistulae that can cause speech problems or nasal regurgitation should be reconstructed as early as possible. The small ones with minimal problems can be delayed for a couple of years or even be left untreated.

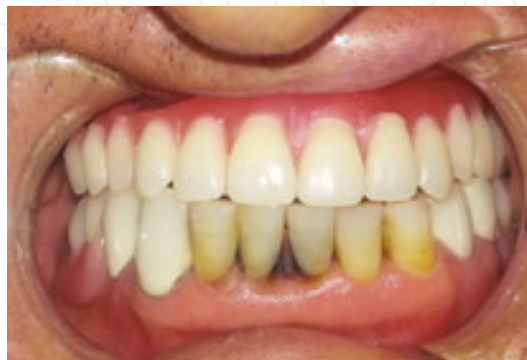

**Figure 9.** ONF after tumor resection surgery.



**Figure 10.** Obturator prosthesis.

There are plenty of surgical and prosthetic options for ONF closure. Openings can be managed using obturators/palatal prosthesis. Although use of this prosthesis significantly improves the aerodynamic characteristic of speech with temporary occlusion, obturators should not be considered as final treatment [19]. Some disadvantages of using these prosthesis are dramatic increase in oral bacteria count, rise in the incidence of carries, and chronic gingivitis at the areas where the denture fit is close to the neck of the teeth [20]. Obturator prosthesis should be



**Figure 11.** Application of an obturator prosthesis after tumor resection surgery.

considered as a practical alternative for patients who had resective tumor surgery and when surgical procedures are contraindicated (**Figures 9–11**) [21].

#### 2.2.2.2. *Surgical procedures*

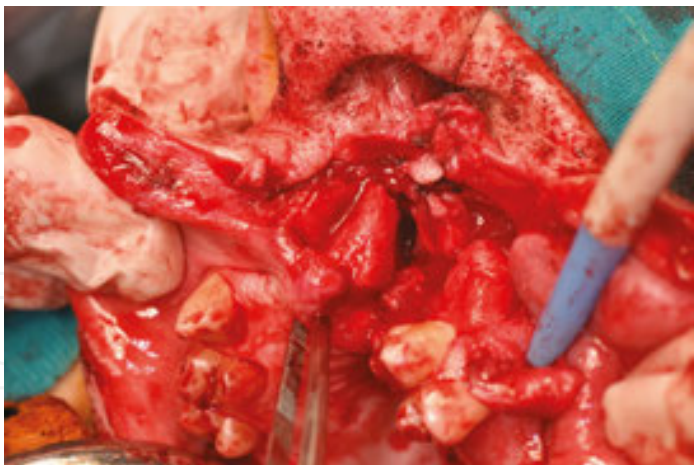
Timing of reconstruction should be at least 6 months after the previous surgery. During the assessment, the amount of scar tissue caused by earlier operation is more important than size and location of the ONF [22]. Sometimes a successful closure cannot be managed because of the presence of this scar tissue. Most of the fistulas can be closed with palatal local tissue transfer. When extra tissue is needed, variable options are available (i.e., free flaps, cartilage grafts, distraction osteogenesis, osmotic tissue expansion, allografts, and bone grafts) [23–27]. Small ONFs can be repaired easily with local tissue. For closure, an adjacent palatal mucoperiosteal flap is raised and slid to the fistula area. This procedure can be performed under local anesthesia.

For large fistulas a tongue flap is a useful option. Tongue flap is a type of myomucosal flap that has many advantages. Abundant tissue for closing defected site, low donor site morbidity, flap is possible in different directions (anterior, posterior, lateral, medial based, and central island flaps), ease of rotation, excellent blood supply, and high success rate are some of these benefits. Besides these advantages, it has some drawbacks such as need to stabilization of the flap, two stage procedure, and 3-week waiting period between flap surgery and division [28].

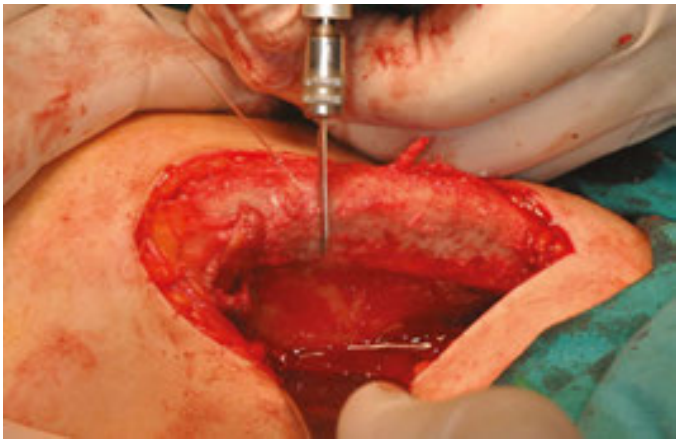Tongue flaps are indicated for large ONF repair where there is tissue deficit and when there is a persistent palatal fistula where earlier attempts have been unsuccessful. Thickness of the flap should be at least 6 mm, optimal references are 7–10 mm, and it should include a layer of underlying muscle tissue to ensure its vascularity. The width of the flap should fill the defect and allow movements of the tongue after turnover. The base must be two-thirds or at least the half of the ONF's width to ensure abundant blood supply [19–22].

To lower flap mobility, fixing the tip of tongue to the upper lip or anterior maxillary incisors may be done. Also prefabricated flap retainers or intermaxillary fixation can be used for this aim [29]. After 3 weeks, with a second operation, the pedicle should be divided and the contouring should be done.

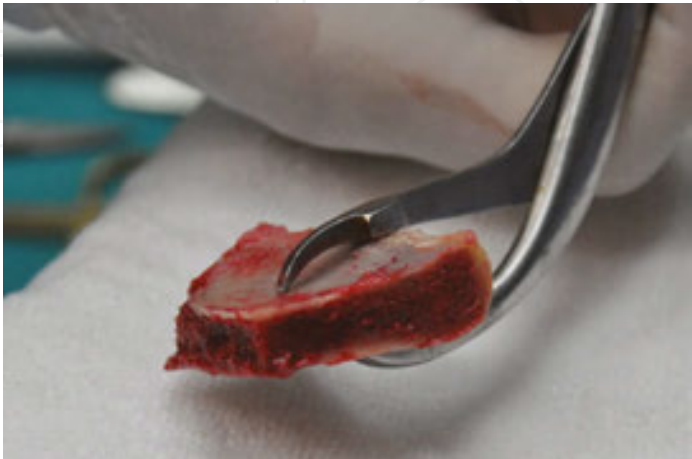
Repairing ONF with bone grafts has some significant advantages. Bone tissue helps form continuity and stability on the palate surface and attain its natural contour [30]. Hard tissue supports the oral mucosa above and the alar base beneath [31]. For this purpose, several autogenous donor sites are available, such as anterior iliac crest, scapula, radial forearm, tibia, calvarial bones, and ribs. Iliac crest graft is accepted as the gold standard because of its benefits, such as containing all the three of osteoinductive, osteoconductive, and osteogenic capacity with its corticocancellous structure. While the cortical part provides support, cancellous component contains viable precursor cells that help to form new bone tissue [32]. Based on its advantages, patient's ONF repaired with anterior iliac crest bone grafting. After palatal and buccal flaps are raised, harvested bone is fixed to the related site with mini screws. In control sessions, the patient's vestibular ONF is usually seen to be completely closed (**Figures 12–16**).



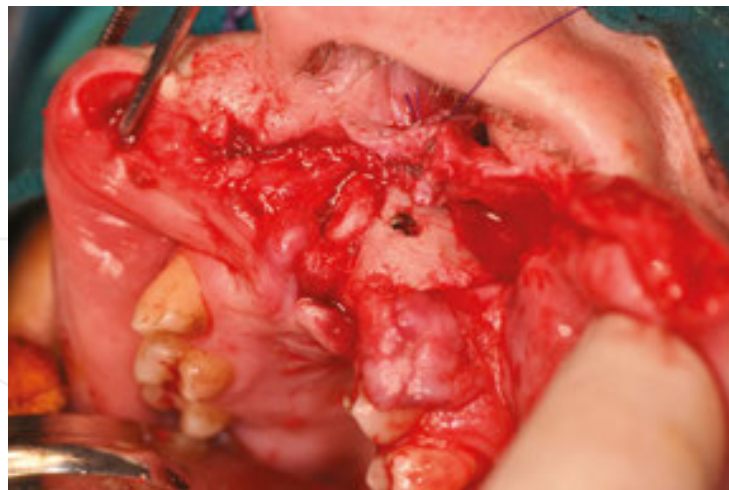
**Figure 12.** Recreating the defect for the closure of ONF.



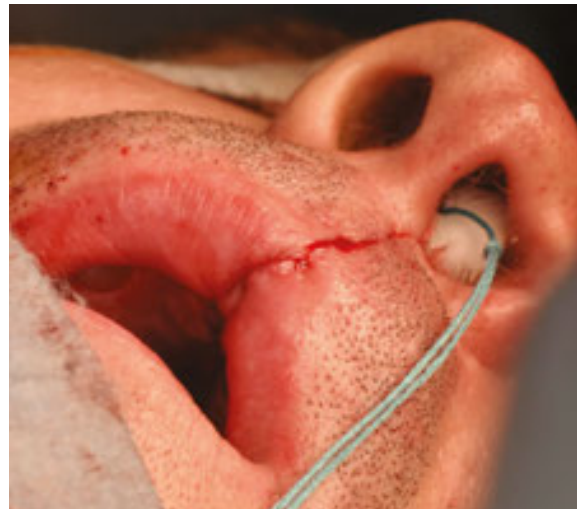**Figure 13.** Anterior iliac bone harvesting.



**Figure 14.** Anterior iliac bone.



**Figure 15.** Anterior iliac bone graft placed.



**Figure 16.** Anterior iliac bone graft for the closure of ONF.

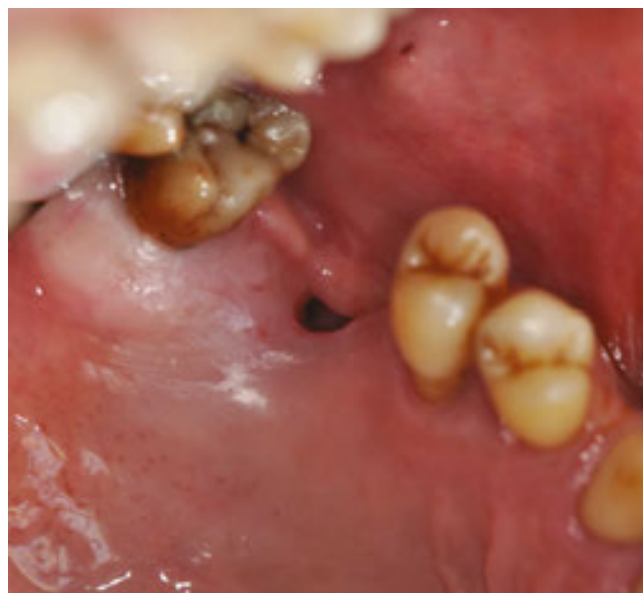### 2.3. Oroantral fistulas

Oroantral communications are not rare in dentoalveolar surgery due to close relationship between maxillary posterior region and sinuses. Surgical procedures involving maxillary posterior region, such as cyst or tumor surgeries, impacted third molar operations, removal of ectopic teeth located in the maxillary sinuses, or traumatic extraction of premolar and molar teeth are the main predisposing factors of surgery-related oroantral communications [33, 34]. Generally, there is a thin bone between maxillary sinus floor and posterior teeth, and also, root apices of the maxillary posterior teeth may be located in the maxillary sinuses. Consequently, oroantral communications are very frequent during the extraction of maxillary posterior teeth because of this anatomical proximity [35, 36]. In addition, maxillary sinus floor perforations due to apicoectomy of maxillary premolar and molar teeth are not rare [37, 38].

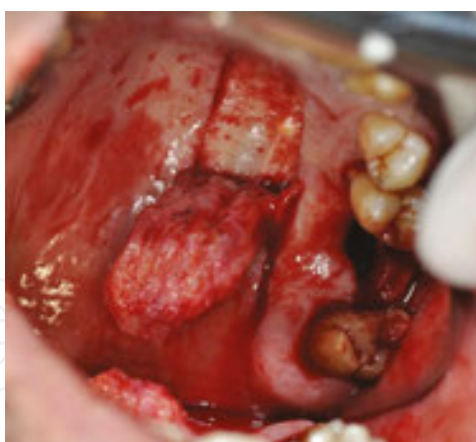Although rehabilitation of edentulous patients with dental implants has become popular, the incidence of complications has increased simultaneously with this popularity. Perforation of sinus floor during dental implant surgery or sinus floor augmentation procedures is quite often encountered, and this may induce complications [39, 40]. In addition, maxillofacial trauma is another predisposing factor causing maxillary sinus-related complications. Malunion of dentoalveolar or zygomatic fractures may lead to oroantral fistula formation [41]. Besides the mechanical and iatrogenic factors, chronic or specific infections may cause sinus perforation and oroantral fistula formation. Chronic infection of necrotic teeth or maxillary sinusitis may lead to bone resorption and communication between maxillary sinuses and the oral cavity. On the other hand, some specific infections such as syphilis may cause severe bone resorptions and oroantral communications [42].

If oroantral perforation occurs following surgical procedures or iatrogenic effects, perforation diameter, depth, and the presence of infection around the oral mucosa, alveolar bone and sinus membrane must be evaluated. Although small diameter, non-infected perforations are generally managed using simple surgical interventions such as buccal advancement flaps, more severe cases may require complicated surgical methods such as palatal rotational flaps or bone grafting procedures combined with soft tissue augmentations [43]. If the initial treatment of an oroantral perforation fails and fistula formation occurs, the treatment of the oroantral fistula may require the combination of medical and surgical interventions.

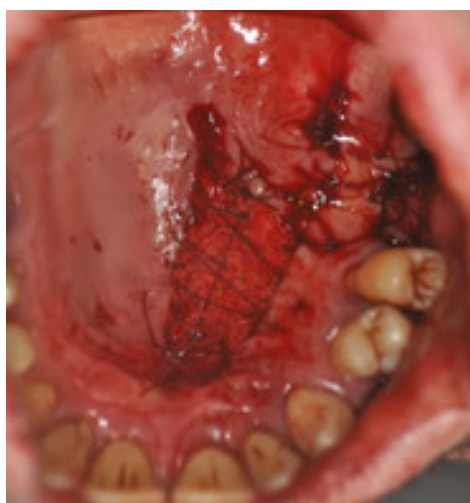Various surgical methods and approaches have been described in the literature for the treatment of oroantral fistulas and each of them has its specific pros and cons. Although most of the local rotational-advancement flaps are useful to treat small-sized oroantral fistulas, the palatal rotation flap is the most preferred technique in our practice especially if the patient has had a previous unsuccessful fistula closure operation (**Figures 17–20**).



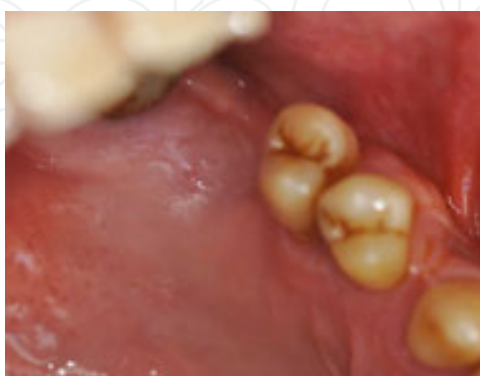**Figure 17.** Oroantral fistula.



**Figure 18.** Palatal rotational flap for the closure of oroantral fistula.



**Figure 19.** Post-operative appearance.

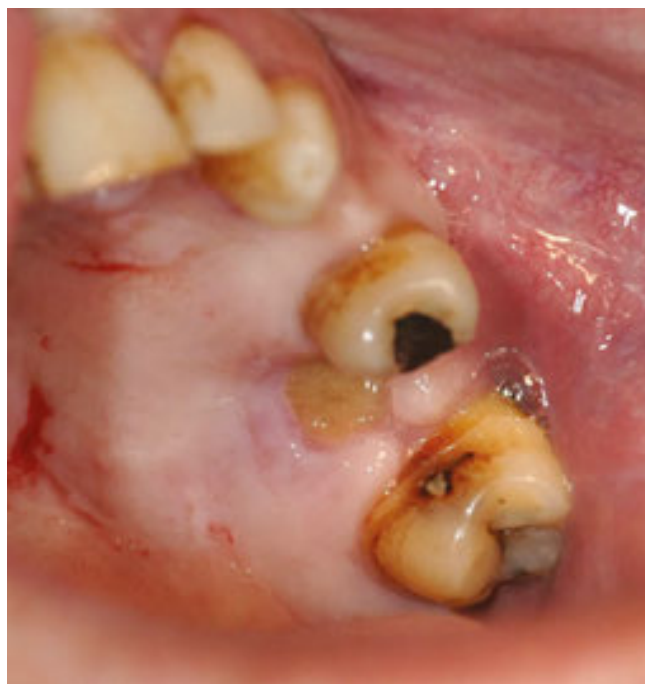

**Figure 20.** Post-operative appearance after 9 months.

In addition to conventional methods, there are some newly developed alternative approaches for the closure of oroantral fistulas and one of these newly described method is the closure of oroantral fistulae using auricular cartilage [44]. Cartilage is biocompatible, non-absorbable, easily manipulated, structurally durable, non-carcinogenic, readily accessible, resistant to infection, and cost-effective. Failure incidence is low due to the fact that it does not require vascularization to integrate to the recipient site. Additionally, cartilage graft acts as a separating barrier between the sinus membrane and the oral mucosa, which helps maintaining a successful healing.

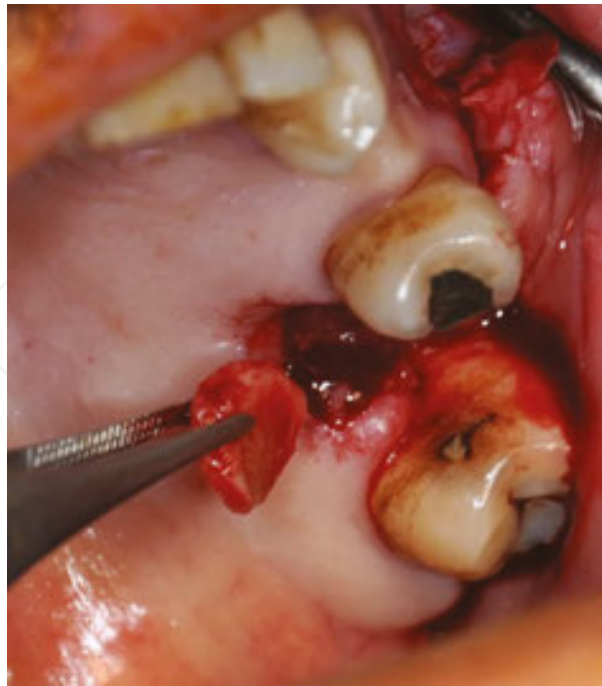The standard care for the closure of oroantral fistulae with an autogenous cartilage graft would be the utilization of nasal septal cartilage [45]. On the other hand, auricular cartilage is also a valuable alternative not only because of the lack of significant amount of defect formation at the donor site, but also because of the advantage of being able to harvest a larger graft in size using the auricle of the ear instead.

The operation technique for the closure of oroantral fistulae using auricular cartilage is recently described [44]. In this method, an anterior auricular approach is used and the incision line passes parallel to the semi-circular bulge in between the antitragus and the antihelix. Although scar formation is usually minimal, rarely some post-operative aesthetic complaints of the incision line were also observed due to scar formation. Taking this into account, the method was modified, using a posterior auricular approach. This operation is planned due to the failure of an autogenous bone graft for the closure of an oroantral fistula (**Figure 21**).

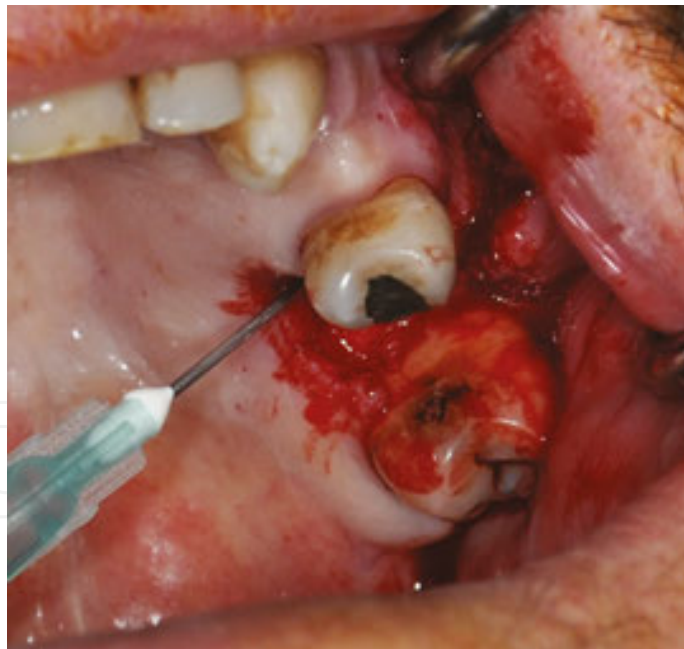


**Figure 21.** Failed autogenous bone graft for the closure of OAF.

Under local anesthesia, exposed necrotic block graft was removed and the site was cleaned from granulation tissue (**Figures 22 and 23**).

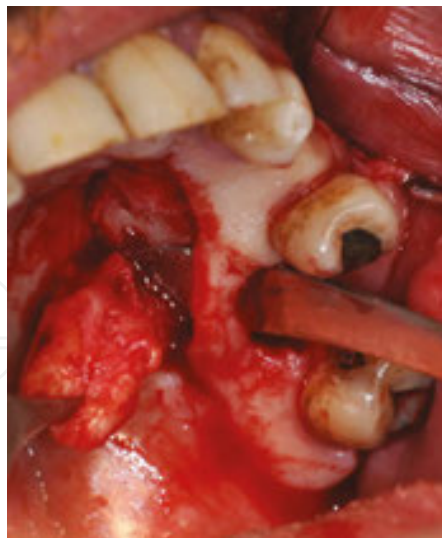

**Figure 22.** Removal of exposed bone graft.



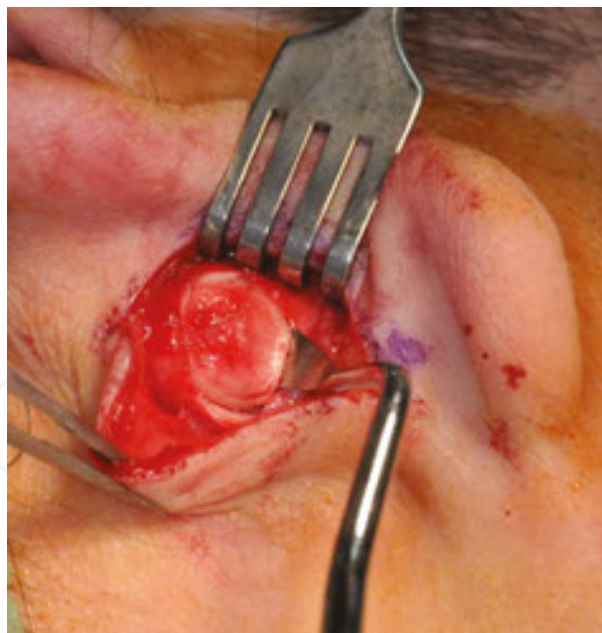
**Figure 23.** Identifying the OAF following removal of granulation tissue.

A buccal flap was elevated for the preparation of a recipient bed for the palatal rotational flap. Then, the palatal rotational flap was prepared and descending palatal artery was protected during the elevation of the flap. After, tension-free connection of the flaps was controlled by rotating palatinal flap to the buccal site (**Figure 24**).



**Figure 24.** Preparation of a palatal rotational flap.

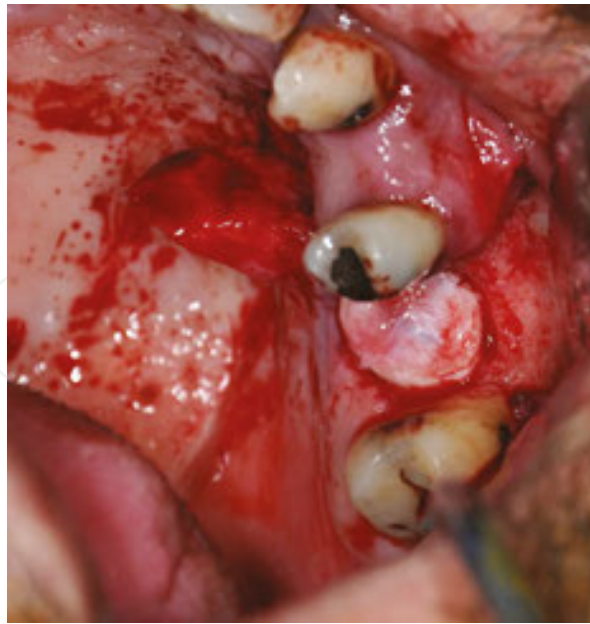Following the recipient site preparation, a curved, split-thickness incision following the curvature of the helix on the posterior side of the auricle was made, and the skin overlying the auricular cartilage was gently elevated. Circular incision was made on the auricular cartilage and the graft was extracted by preserving the perichondrium (**Figure 25**).



**Figure 25.** Auricular cartilage graft harvesting by posterior auricular approach.

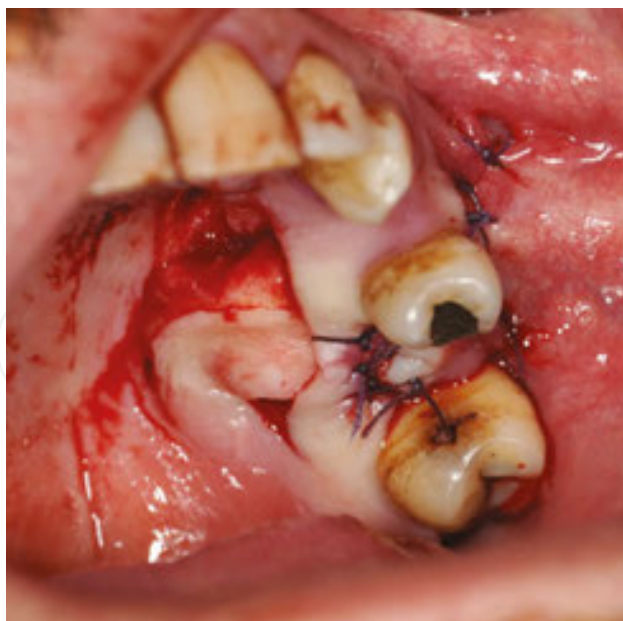Finally, posterior auricular skin flap was sutured using 5/0 polyglactin 910.

Auricular graft containing perichondrium was then adapted to the recipient bed (**Figure 26**) and sutured to the bone with 3/0 polyglactin 910 for stabilization.



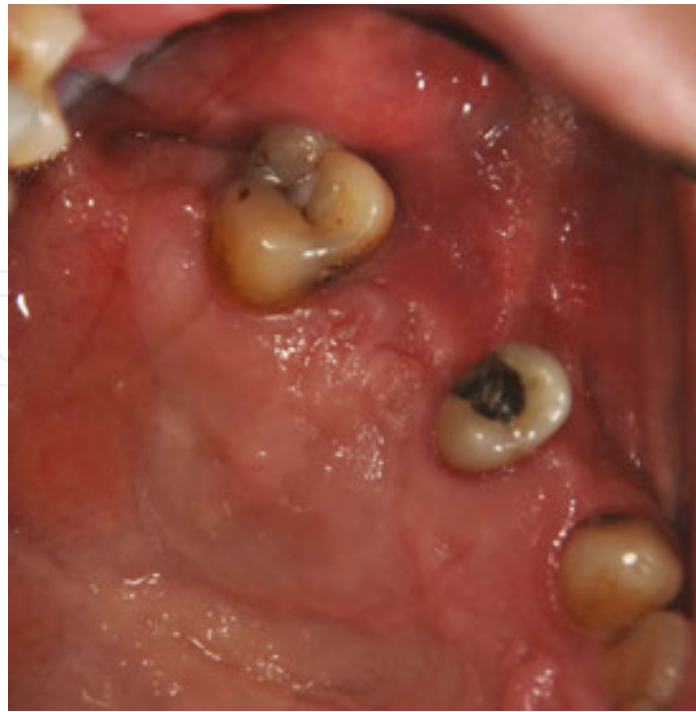**Figure 26.** Adaptation of cartilage graft to the recipient site.

De-epithelization was achieved on the keratinized layer of the palatal flap by a round diamond bur, and it was rotated under the previously prepared full-thickness palatal soft tissue tunnel. Finally, the buccal flap and the rotated palatal flap were joined using 3/0 polyglactin 910 sutures (**Figure 27**).



**Figure 27.** Connection of the palatal and the buccal flaps.

Any complication was not observed during the post-operative period and ideal healing was achieved after 4 months (**Figure 28**).



**Figure 28.** Post-operative appearance after 4 months.

We believe, using this modification in the surgical technique not only improves the aesthetic results but also decreases the resorption rate of the cartilage graft since the perichondrium is well-protected during the harvest of the graft.

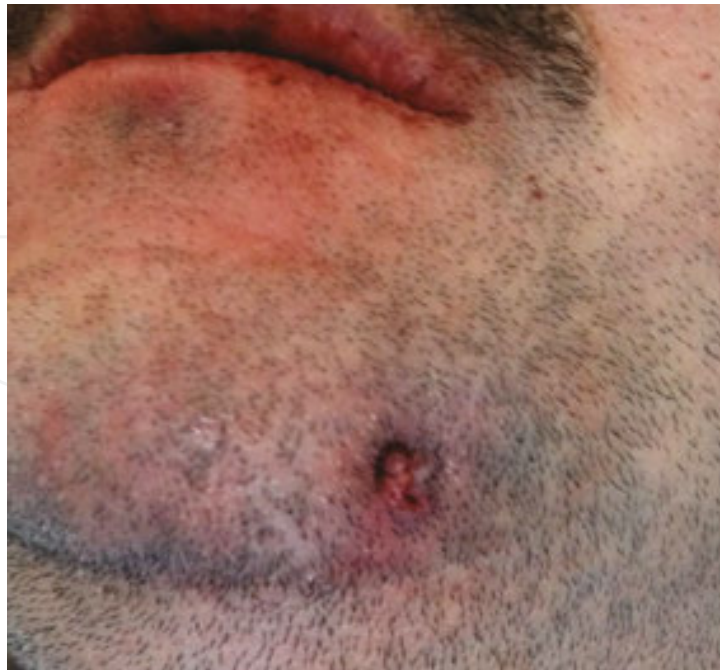#### **2.4. Orocutaneous fistulae**

An orofacial or orocutaneous fistula is a pathological communication between the cutaneous surface of the face and the oral cavity. An oral cutaneous fistula leads to esthetic problems due to the continual leakage of saliva from the oral cavity to the face. Malignancy, inflammation, and trauma are the most common causes [46].

The literature does not clearly demonstrate the incidence or treatment of the orocutaneous fistulas. This situation may be explained that the fistulas were not considered as a major complication in OMF practice. On the other hand, the fistulas that do not heal spontaneously may cause discomfort for the patients [46, 47].

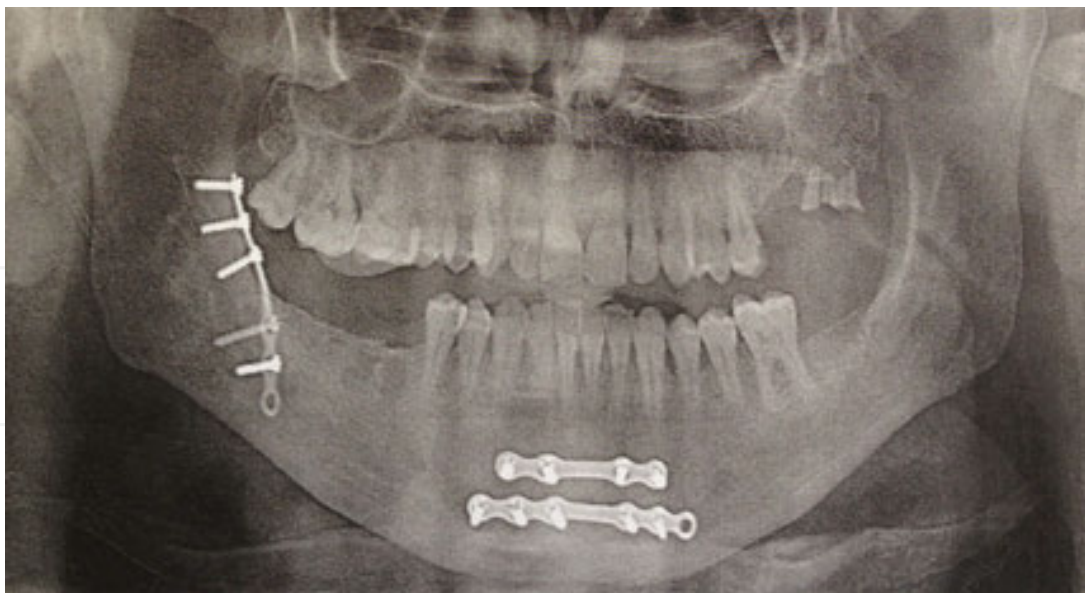
This part of the present chapter evaluated the common causes of the orocutaneous fistulas by demonstrating some of the cases which were managed in Istanbul University, Faculty of Dentistry at the Department of Oral and Maxillofacial Surgery. The surgical management is emphasized for practitioners.

Some of the orocutaneous fistulae may be presented due to the use of miniplates or reconstruction plates and screws. The removal of these materials is not a routine procedure, and there are conflicting ideas about removal. **Figure 29** demonstrates an orocutaneous fistula that occurred 5 years after the placement of miniplate and screws in the mandible.



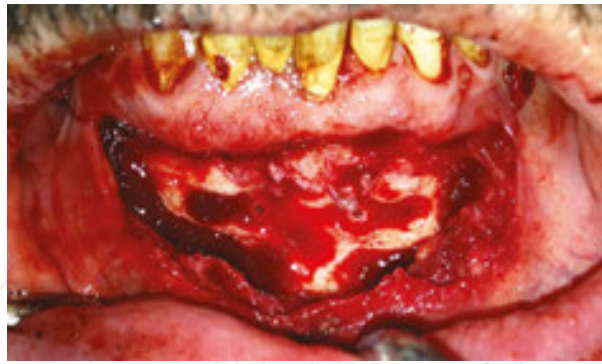**Figure 29.** Orocutaneous fistula.

The orthopantomograph demonstrated the plates which were placed 5 years ago for the management of the fractures of the mandible (**Figure 30**).




**Figure 30.** Preoperative orthopantomograph.

All the plates and screws placed at the symphysis were removed, and the infection site was curetted (**Figures 31 and 32**). The patient did not demonstrate any complaint after the operation and the fistula healed.

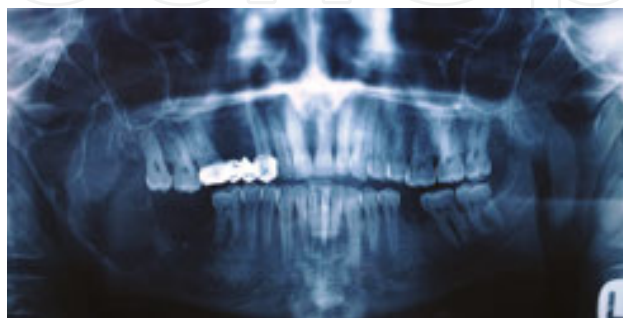


**Figure 31.** Intraoperative view of the operation site.



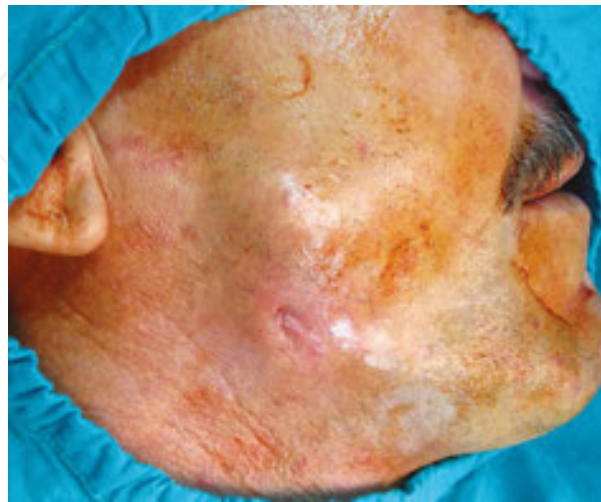**Figure 32.** Removed plates and screws and excised remnants of the infected site.

Residual lesions of the cysts and the tumors of the jaws may cause formation of orocutaneous fistulae also. The second case is a residual keratocystic odontogenic tumor at the condyle, which causes an orocutaneous fistula formation. A panoramic radiograph showed a multilocular radiolucency with sclerotic margins located in the ramus up to the processes coronioideus and condylaris (**Figure 33**).



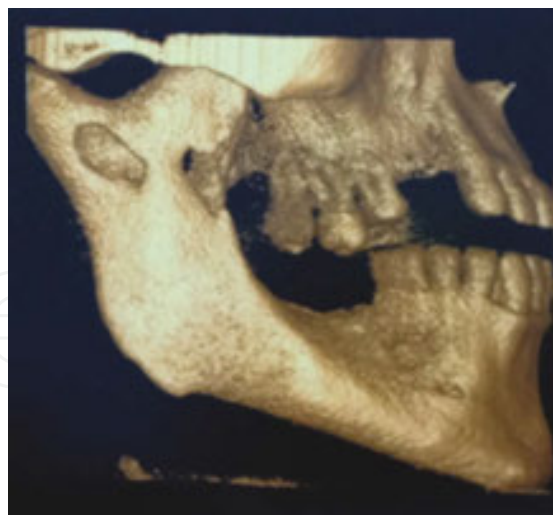
**Figure 33.** Pre-operative orthopantomograph which shows the affected right side of the ramus and condyle.

Four months later after marsupialization, the lesion was excised under general anesthesia. The definitive diagnosis was reported as keratocystic odontogenic tumor. Ten years after the operation he presented with an extraoral fistula at the right mandibular angle region (**Figure 34**).



**Figure 34.** Orocutaneous fistula.

Three-dimensional views demonstrated cortical perforation and the borders of the lesion (**Figure 35**).



**Figure 35.** 3D view shows the tumor in the right condyle.

The patient was operated under general anesthesia. Extraoral approach was performed to access to the coronoidal part of the ramus. The lesion was excised (**Figures 36–38**). The definitive diagnosis reported by the pathology department was keratocystic odontogenic tumor. The fistula healed subsequently.

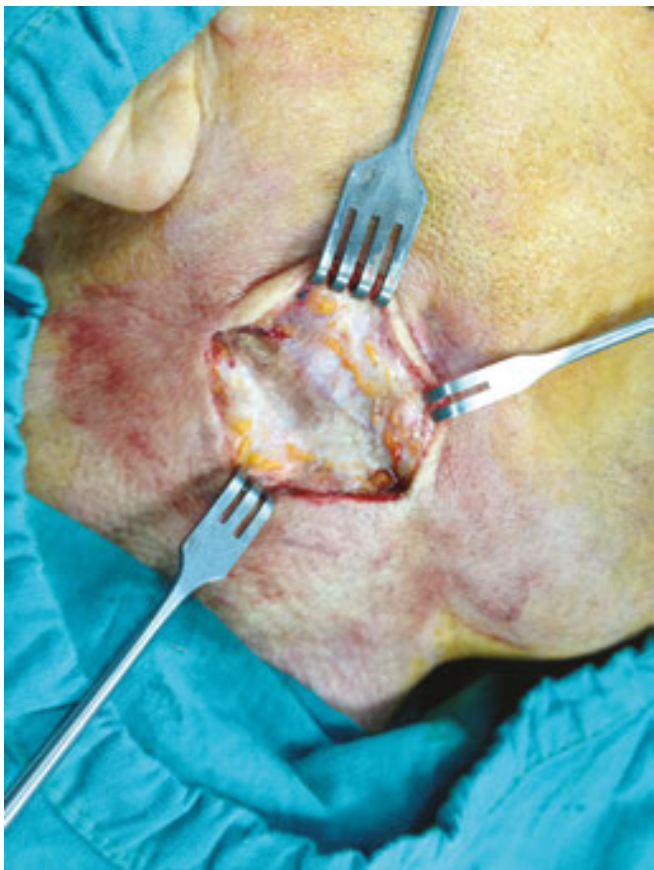

Figure 36. The view of the extraoral approach.

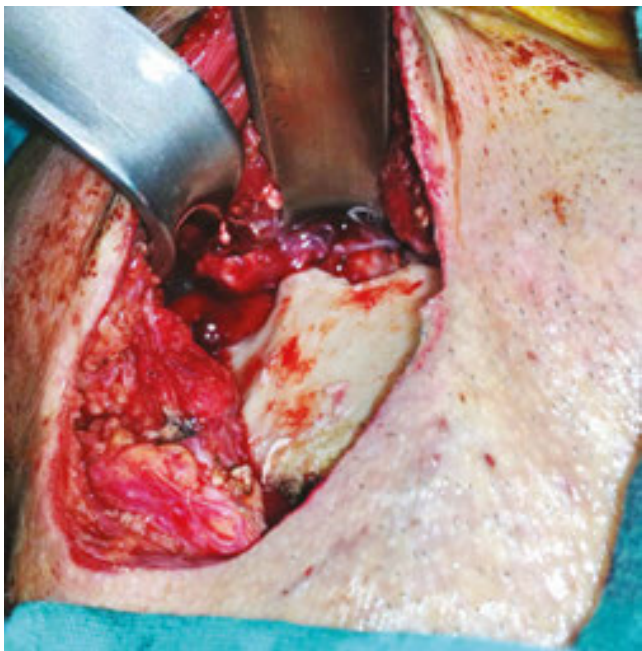
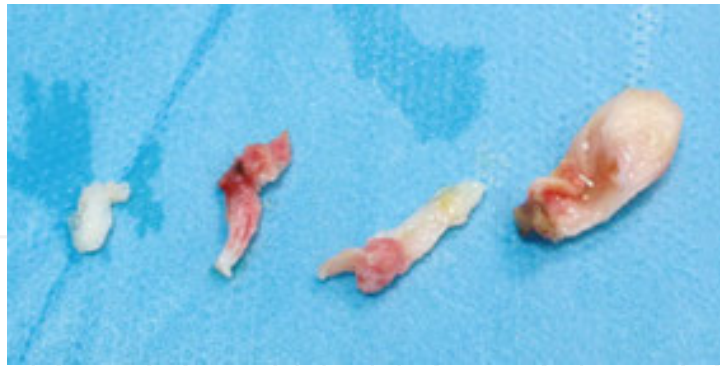


Figure 37. Intraoral view of the lesion.

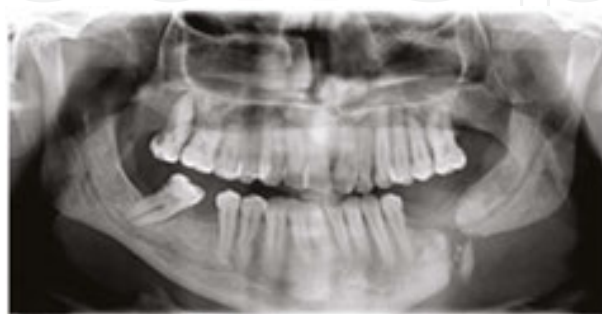

**Figure 38.** Excised tumor remnants.

**Osteoradionecrosis (ORN)** of the jaws is one of the most severe and debilitating complications following radiation therapy for head and neck cancer patients. It is a radiation-induced ischemic necrosis of bone with associated soft tissue necrosis, occurring in the absence of primary tumor, recurrence, or metastatic disease. The incidence of ORN ranges from 5 to 15% and is the most frequently noted (>70%) in the first 3 years after completion of treatment. Mandibular ORN is more prevalent when compared to the maxilla due to the relatively poor vascularization and the dense structure of mandibular bone.

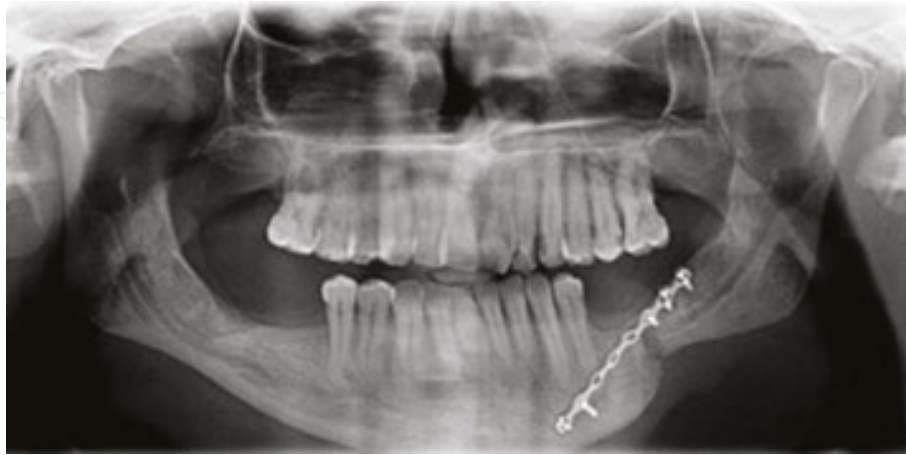Several risk factors have been implicated including tumor stage, tumor infiltration of adjacent bone, preradiation mandibular surgery, radiation modality, tooth extractions, and poor oral health. ORN can also develop spontaneously. Controversy exists over the management of ORN. Conservative measures include antiseptic mouthwashes, antibiotics, sequestrectomy, ultrasound therapy, and hyperbaric oxygen therapy. Surgical management includes more radical procedures with or without the use of conservative measures [48].

The third case demonstrates the formation of orocutaneous fistulas, which occurred after radiotherapy of head and neck cancer. The patient informed us that he had undergone head and neck radiotherapy due to nasopharyngeal carcinoma diagnosed 2 years ago. An extraction was performed also at the left side of the mandible. The OPG demonstrated a pathological fracture due to the osteoradionecrosis. It was noted that a sequestrum of bone from the fracture side was under the mandibular basal bone (**Figure 39**).



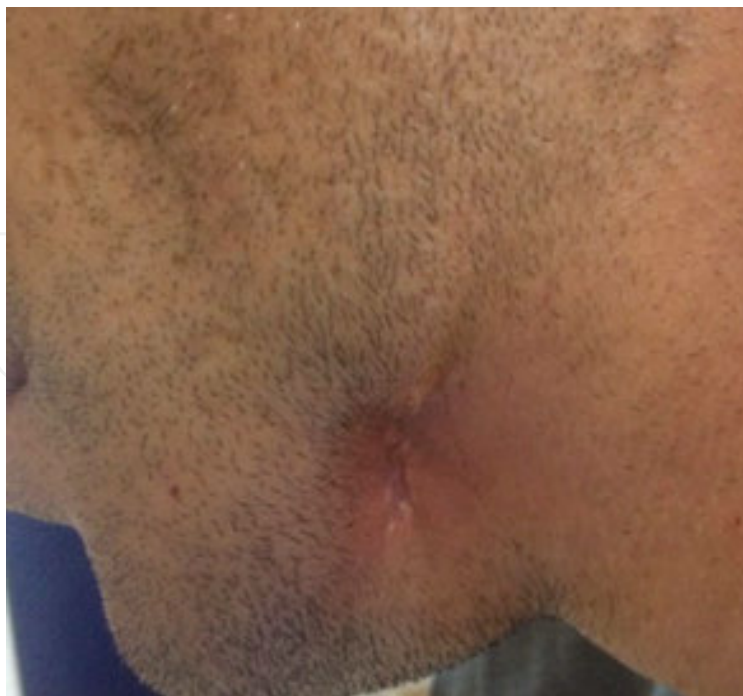**Figure 39.** The view of the pathological fracture.

The replaced bone was removed and the fracture site was debrided. The fracture segments were stabilized with a long plate and four screws temporarily. A slight bone regeneration was observed on the control radiograph (**Figure 40**).



**Figure 40.** Intraoral temporary stabilization of the fractured segments.

The patient was informed regarding the permanent operation which included an iliac crest augmentation for the treatment of the bone loss at the fracture site, but the patient refused another operation. The extraoral fistula healed and the patient did not have any complaints (**Figure 41**).



**Figure 41.** Healed fistula.

## 2.5. Odontogenic orocutaneous fistula

Chronic dental infections may cause odontogenic cutaneous fistulae which may occur intraorally or extraorally. When the treatment is delayed, the pulp becomes necrotic and apical periodontitis may occur. This situation results bone resorption which may lead to the formation of an odontogenic cutaneous fistula [49].

Cutaneous sinus tracts on the face from odontogenic infection are commonly misdiagnosed and subsequently incorrectly treated. The differential diagnosis includes local skin infection, pyogenic granuloma, osteomyelitis, and basal or squamous cell carcinoma. Therefore, many patients refer to numerous physicians to evaluate their sickness. They sustain several inappropriate surgeries and courses of antibiotics before conclusive therapy is established. Early correct diagnosis and treatment of these lesions can help preventing unnecessary and ineffective antibiotic therapy or surgical treatment [50].

Diagnosis is established by tracing the sinus tract with gutta-percha or similar radiopaque material, dental examination, and radiologic evaluation. Dental panoramic or periapical radiographic views reveal evidence of a radiolucent periapical disease process [51].

Patients should be evaluated with orthopantomograph and, if possible, with cone-beam computed tomography. The pulp vitality test should be used to determine whether the diseased tooth is restorable. Histologically, the cutaneous sinus usually consists of granulomatous tissue or epithelium. Diagnostic errors can result in multiple surgical excisions and biopsies, antibiotic therapy, and even radiation therapy [51].

When assessing these patients, intraoral examination may reveal a carious tooth or signs of previous dental trauma. Bimanual examination may identify a cord-like track between the oral cavity and the skin, probing the external opening or performing a fistulogram may help establish the diagnosis.

Patients often seek treatment from a physician and present with chronic suppurative lesions that resemble a cyst, furuncle, or ulcer. The most common sites for a cutaneous sinus of dental origin are the chin and the jaw. The sinus tract's exit is determined by the location of muscle attachments and fascial planes. Of the reported cases, 80% arise from mandibular teeth. Mandibular incisors and cuspids typically drain to the chin or submental region [51–53].

Mandibular premolar and molar infections drain to the posterior mandible or below the inferior border in the submandibular region. Dental fistulae may arise from infection of the maxillary teeth, resulting in sinus tracts erupting intranasally or the inner canthal areas. Tracts in the mandibular, submandibular, and neck regions are most often associated with disease of the mandibular molars [52, 53].

Extraoral fistulae typically present as erythematous, symmetrical, crusting, smooth, and non-tender nodules with periodic drainage. However, the dermal lesions are non-specific and can also present as abscesses, cysts, scars, and ulcers [54].

An understanding of the draining of cutaneous sinus tracts leads to more appropriate treatment. Most cases respond to conservative, non-surgical root canal therapy. Endodontic

treatment is recommended. Extraction may be required in non-restorable fractured or carious teeth, or in cases associated with extensive alveolar bone loss. The retention of natural teeth preserves function, arch integrity, and esthetics eliminates the need for a costly restorative procedure. After appropriate dental therapy, the sinus tract resolves spontaneously within a few weeks, but a retracted dimple or scar may develop. Because odontogenic sinus tract is a localized entity, systemic antibiotic administration is not indicated in healthy patients. The sinus tract will recur unless the source of infection has been eliminated. Early correct diagnosis, based on radiologic evidence of a periapical root infection, and treatment of these lesions can help prevent unnecessary and ineffective antibiotic therapy or surgical treatment, reducing the possibility of further complications such as sepsis and osteomyelitis [51].

Elimination of dental infection through endodontic treatments or tooth extraction is vital for the management of cutaneous sinus tracts. CBCT imaging facilitates successful endodontic treatment by aiding the diagnosis of odontogenic cutaneous sinus tract and enabling better understanding of unusual canal morphology [54].

Various types of intraoral infections may develop extraoral cutaneous fistulae, including odontogenic infections, osteomyelitis, osteonecrosis, midfacial fractures, cysts, and tumors of the jaws. The first attempt should be to reveal the cause of the fistula using clinical and radiological examinations. The treatment is to eliminate the causative factor. Early correct diagnosis and treatment of these lesions can help in preventing unnecessary and ineffective antibiotic therapy or surgical treatment.

## Author details

Erol Cansiz<sup>1\*</sup>, Alper Gultekin<sup>2</sup>, Melek Koltuk<sup>1</sup> and Sirmahan Cakarar<sup>1</sup>

\*Address all correspondence to: erolca@yahoo.com

1 Istanbul University, Faculty of Dentistry, Department of Oral and Maxillofacial Surgery, Istanbul, Turkey

2 Istanbul University, Faculty of Dentistry, Department of Oral Implantology, Istanbul, Turkey

## References

- [1] Samir N., Al-Mahrezi A., Al-Sudairy S.. Odontogenic cutaneous fistula: Report of two cases. Sultan Qaboos University Medical Journal, 2011, 11 (1): 115–118.
- [2] Johnson B.R., Remeikis N.A., Van Cura J.E., Diagnosis and treatment of cutaneous facial sinus tract of the dental origin. JADA, 1999, 130: 832–836.

- [3] Assery M., Al Shamrani S.. Cutaneous facial sinus tract of dental origin: A clinical case report. *Saudi Dental*, 2001, 13: 37–39.
- [4] Carl W., Helm A.F., Wood R.. Cutaneous lesion of dental origin, *Quintessence International*, 1975, 12: 75–78.
- [5] Simuntis R., Kubilius R., Vaitkus S.. Odontogenic maxillary sinusitis: A review. *Stomatologija*, 2014, 16 (2): 39–43.
- [6] Longhini A.B., Ferguson B.J.. Clinical aspects of odontogenic maxillary sinusitis: A case series. *International Forum of Allergy and Rhinology*, 2011, 1 (5): 409–415.
- [7] Sakamo E., Stratigos G.T.. Bilateral cutaneous sinus tracts of dental etiology: Report of case. *Journal of Oral Surgery*, 1973, 31: 701–704.
- [8] Heling I., Rotstein I., A persistent oronasal sinus tract of endodontic origin. *Journal of Endodontics*, 1989, 15: 132–134.
- [9] Foster K.H., Primack P.D., Kulild J.C., Odontogenic cutaneous sinus tract, *Journal of Endodontics*, 1992, 18: 304–306.
- [10] Rohrich R.J., Gosman A.A.. An update on the timing of hard palate closure: A critical long-term analysis. *Plastic and Reconstructive Surgery*, 2004, 113: 350–352.
- [11] Jeffery S.L.A., Boorman J.G., Dive D.C.. Use of cartilage grafts for closure of cleft palate fistulae. *British Journal of Plastic Surgery*, 2000, 53: 551–554.
- [12] H.H. Hosseinabad, et al., Incidence of velopharyngeal insufficiency and oronasal fistulae after cleft palate repair: A retrospective study of children referred to Isfahan Cleft Care Team between 2005 and 2009, *Int. J. Pediatr. Otorhinolaryngol.* (2015), <http://dx.doi.org/10.1016/j.ijporl.2015.07.035>
- [13] Ahmed M.K.. Risk of persistent palatal fistula in patients with cleft palate. *JAMA Facial Plastic Surgery*, 2015, 17 (2): 126–130.
- [14] Bykowski M.R., Naran S., Winger D.G., Losee J.E.. The rate of oronasal fistula following primary cleft palate surgery: A meta-analysis. *Cleft Palate-Craniofacial Journal*, 2015, 52 (4): e81–e87.
- [15] Reid D.A.C.. Fistula in the hard palate following cleft palate surgery. *British Journal of Plastic Surgery*. 1962, 15: 377–384.
- [16] Henningsson G., Isberg A.. Influence of palatal fistula on speech and resonance. *Folia Phoniatri*, 1987, 39: 183–191.
- [17] Smith D.M., Vecchione L., Jiang S., Ford M., Deleyiannis F.W., Haralam M.A., Naran S., Worrall C.I., Dudas J.R., Afifi A.M., Marazita M.L., Losee J.E.. The Pittsburgh Fistula Classification System: A standardized scheme for the description of palatal fistulas. *Cleft Palate-Craniofacial Journal*, 2007, 44: 590–594.

- [18] Schultz R.C.. Management and timing of cleft palate fistula repair. *Plastic and Reconstructive Surgery*, 1986, 78(6): 739–747.
- [19] Ogle O.E.. The management of oronasal fistulas in the cleft palate patient. *Oral and Maxillofacial Surgery Clinics of North America*, 2002, 14(4): 553–62.
- [20] Lehman J.A. Jr., Curtin P., Haas D.G.. Closure of anterior palate fistulae. *Cleft Palate-Craniofacial Journal*, 1978, 15(1): 33–8.
- [21] Law M.Y.T., Chung R.W.C., Lam O.L.T.. Prosthetic rehabilitation of an edentulous patient with an oronasal fistula. *Journal of Prosthetic Dentistry*, 2015, 113(4): 347–349.
- [22] Partha S.. Oronasal fistula in cleft palate surgery. *Indian Journal of Plastic Surgery*, 2009, 42: 123–128.
- [23] Jeffery S.L.A., Boorman J.G., Dive D.C.. Use of cartilage grafts for closure of cleft palate fistulae. *British Journal of Plastic Surgery*, 2000, 53: 551–554.
- [24] Taub P.J., Bradley J.P., KawamotoHenry K.. Closure of an oronasal fistula in an irradiated palate by tissue and bone distraction osteogenesis. *The Journal of Craniofacial Surgery*, 2001, 12 (5): 495–499.
- [25] Jenq T.F., Hilliard S.M., Kuang A.A.. Novel use of osmotic tissue expanders to treat difficult anterior palatal fistulas. *The Cleft Palate-Craniofacial Journal*, 2011, 48(2): 217–221.
- [26] El-Kassaby M.A., Khalifah M.A., Metwally S.A., Kader K.A.A.. Acellular dermal matrix allograft: An effective adjunct to oronasal fistula repair in patients with cleft palate. *Annals of Maxillofacial Surgery*, 2014, 4(2): 158–161.
- [27] Kirschner R.E., Cabiling D.S., Alison B.A., Slemp E., Siddiqi F.. Repair of oronasal fistulae with acellular dermal matrices. *Plastic and Reconstructive Surgery Journal*, 2006, 118 (6):1431–1440.
- [28] KimM-J., LeeJ-H., ChoiJ-Y.. Two-stage reconstruction of bilateral alveolar cleft using Y-shaped anterior-based tongue flap and iliac bone graft. *Cleft Palate Craniofacial Journal*, 2001, 38 (5): 432–437.
- [29] Sodhi S.P.S., Kapoor P., Kapoor D.. Closure of anterior palatal fistula by tongue flap: A prospective study. *Journal of Maxillofacial and Oral Surgery*, 2014, 13 (4): 546–549.
- [30] Chakranarayan A., Jeyaraj P., Sahoo N.K.. Mid versus late secondary alveolar cleft grafting using iliac. *Journal of Maxillofacial and Oral Surgery*, 2014, 13 (2): 195–207.
- [31] Murthy A.S., Lehman J.A.Jr. Secondary alveolar bone grafting: An outcome analysis. *Canadian Journal of Plastic Surgery*, 2006, 14 (3): 172–174.
- [32] Sen M.K., Micla T.. Autologous iliac crest bone graft: Should it still be the gold standard for treating nonunions? *Injury, International Journal*, 2007, 38(1): 75–80.
- [33] Rothamel D., Wahl G., D’Hoedt B., NentwigG-H., Schwarz F., Becker J.. Incidence and predictive factors for perforation of the maxillary antrum in operations to remove

upper wisdom teeth: Prospective multicentre study. *British Journal of Oral and Maxillofacial Surgery*, 2007, 45: 387–391.

- [34] Baykul T., Dogru H., Yasan H., Aksoy M.C.. Clinical impact of ectopic teeth in the maxillary sinus. *Auris Nasus Larynx*, 2006, 33: 277–281.
- [35] Nedbalski T.R., Laskin D.M.. Use of panoramic radiography to predict possible maxillary sinus membrane perforation during dental extraction. *Quintessence International*, 2008, 39: 661–664.
- [36] Lim A.A., Wong C.W., Allen J.C. Jr. Maxillary third molar: Patterns of impaction and their relation to oroantral perforation. *Journal of Oral and Maxillofacial Surgery*, 2012, 70 (5): 1035–1039.
- [37] Altonen M., Mattila K.. Follow-up study of apicoectomized molars. *International Journal of Oral Surgery*, 1976, 5: 33–40.
- [38] Freedman A., Horowitz I.. Complications after apicoectomy in maxillary premolar and molar teeth. *International Journal of Oral and Maxillofacial Surgery*, 1999, 28: 192–194.
- [39] Chiapasco M., Felisati G., Macari A.. The management of complications following displacement of oral implants in the paranasal sinuses: A multicenter clinical report and proposed treatment protocols. *International Journal of Oral and Maxillofacial Surgery*, 2009, 38: 1273–1278.
- [40] Ardekian L., Oved-Peleg E., Mactei E.E., Peled M.. The clinical significance of sinus membrane perforation during augmentation of the maxillary sinus. *Journal of Oral and Maxillofacial Surgery*, 2006, 64 (2): 277–282.
- [41] O'Hare T.H.. Blow-out fractures: A review. *Journal of Emergency Medicine*, 1991, 9 (4): 253–263.
- [42] Friedmann I.. Ulcerative/necrotizing diseases of the nose and paranasal sinuses. *Current Diagnostic Pathology*, 1995, 2 (4): 236–255.
- [43] Skoglund L.A., Pedersen S.S., Holst E.. Surgical management of 85 perforations to the maxillary sinus. *International Journal of Oral Surgery*, 1983, 12 (1): 1–5.
- [44] Isler S.C., Demircan S., Cansiz E.. Closure of oroantral fistula using auricular cartilage: A new method to repair an oroantral fistula. *British Journal of Oral and Maxillofacial Surgery*, 2011, 49 (8): e86–e87.
- [45] Kansu L., Akman H., Uckan S.. Closure of oroantral fistula with the septal cartilage graft. *European Annals of Otorhinolaryngology*, 2010, 267:1805–1806.
- [46] Balakrishnan C., Narasimhan K., Gursel T., Jackson O., Schaffner A.. Closure of orocutaneous fistula using a pedicled expanded deltopectoral flap. *Canadian Journal of Plastic Surgery*, 2008, 16: 178–180.

- [47] Föll D.A., Jokuszies A., Radtke C., Vogt P.M.. Successful closure of persistent oro-cutaneous fistulas by injection of autologous adipose-derived stem cells: A case report. *GMS German Plastic, Reconstructive and Aesthetic Surgery*, 2013, 3. ISSN: 2193–7052.
- [48] Rice N., Polyzois I., Ekanayake K., Omer O., Stassen L.F.. The management of osteoradionecrosis of the jaws—A review. *Surgeon*, 2015,13: 101–109.
- [49] Guevara-Gutierrez E., Riera-Leal L., Gomez-Martinez M., Amezcua-Rosas G., Carmen Lucia Chavez-Vaca G.L., Tlacuilo-Parra A.. Odontogenic cutaneous fistulas. *International Journal of Dermatology*, 2013. DOI: 10.1111/ijd.12262.
- [50] Zerener T., Rasit Bayar G., Gulses A., Simsek K., Sinan Aydintug Y.. Massive cutaneous fistula secondary to an odontogenic submandibular abscess in an immunocompromised patient: A case report. *Cumhuriyet Dental Journal*,2014, 17 (Supp 1): 11–15.
- [51] Gime'nez-GarcíaR., Martinez-Vera F., Fuentes-Vera L.. Cutaneous sinus tracts of odontogenic origin: Two case reports. *Journal of the American Board of Family Medicine*, 2015, 28: 838–840.
- [52] Gupta M., Das D., Kapur R., Sibal N.. A clinical predicament—Diagnosis and differential diagnosis of cutaneous facial sinus tracts of dental origin: A series of case reports. *Oral Surgery, Oral Medicine, Oral Pathology, Oral Radiology, and Endodontology*, 2011, 112: 132–136.
- [53] Tidwell E., Jenkins J.D., Ellis C.D., Hutson B., Cederberg R.A.. Cutaneous odontogenic sinus tract to the chin: A case report. *International Endodontic Journal*, 1997, 30: 352–355.
- [54] Tian J., Liang G., Qi W., Jiang H.. Odontogenic cutaneous sinus tract associated with a mandibular second molar having a rare distolingual root: A case report. *Head & Face Medicine*, 2015, 17 (11): 13.