

We are IntechOpen, the world's leading publisher of Open Access books Built by scientists, for scientists

6,900

Open access books available

185,000

International authors and editors

200M

Downloads

Our authors are among the

154

Countries delivered to

TOP 1%

most cited scientists

12.2%

Contributors from top 500 universities



WEB OF SCIENCE™

Selection of our books indexed in the Book Citation Index
in Web of Science™ Core Collection (BKCI)

Interested in publishing with us?
Contact book.department@intechopen.com

Numbers displayed above are based on latest data collected.
For more information visit www.intechopen.com



Ridge Augmentation Techniques in Preprosthetic Implant Surgery

Bahattin Alper Gultekin, Erol Cansiz and
Serdar Yalcin

Additional information is available at the end of the chapter

<http://dx.doi.org/10.5772/63003>

Abstract

Rehabilitation of missing teeth with dental implant-supported restorations has become a predictable treatment option in dentistry. The stability of hard and soft tissues around the implant is fundamental for long-term success. However, due to factors such as trauma, oncologic diseases, and missing teeth, vertical and horizontal bone loss is expected, and the available bone may not be suitable for optimum implant placement. Ridge augmentation procedures are applied to increase in the volume of the deficient sites for implant treatment. Autogenous block bone augmentation and guided bone regeneration (GBR) are two surgical approaches for implant placement. Autogenous bone is widely used for augmentations because of its osteogenic potential. A myriad of biomaterials, including xenografts, allografts, alloplasts, and composite grafts, are available for GBR. The aim of this chapter is to provide a brief summary of these methods and to discuss the advantages and pitfalls of ridge augmentation techniques.

Keywords: Alveolar ridge deficiency, guided bone regeneration, iliac block bone augmentation, biomaterials, autogenous bone

1. Introduction

Rehabilitation of edentulous sites with implant-supported restorations is a reliable technique with a predictable outcome. Alveolar ridge resorption after tooth loss is very common and may compromise the placement of implants. Trauma, oncologic diseases, oral infections, and congenitally missing teeth may also cause severe bone deficiency. A wide range of surgical procedures, such as guided bone regeneration (GBR) through the use of resorbable and non-

resorbable membranes, intra- and extra-oral block grafting, and distraction osteogenesis, can be applied for reconstruction of alveolar ridge deficiencies [1–3].

Defect morphology plays an important role in the success of alveolar ridge augmentation techniques. Defects can basically be classified as intrabony or extrabony defects [4]. It is easier to maintain space, stabilize the augmented site, achieve primary soft tissue closure, and protect the grafting site in intrabony defects than in extrabony defects. Therefore, intrabony defects are much easier to augment through techniques such as socket augmentation and sinus floor elevation. Extrabony defects can be more challenging in cases such as lateral and vertical augmentations (**Figure 1**) [5].

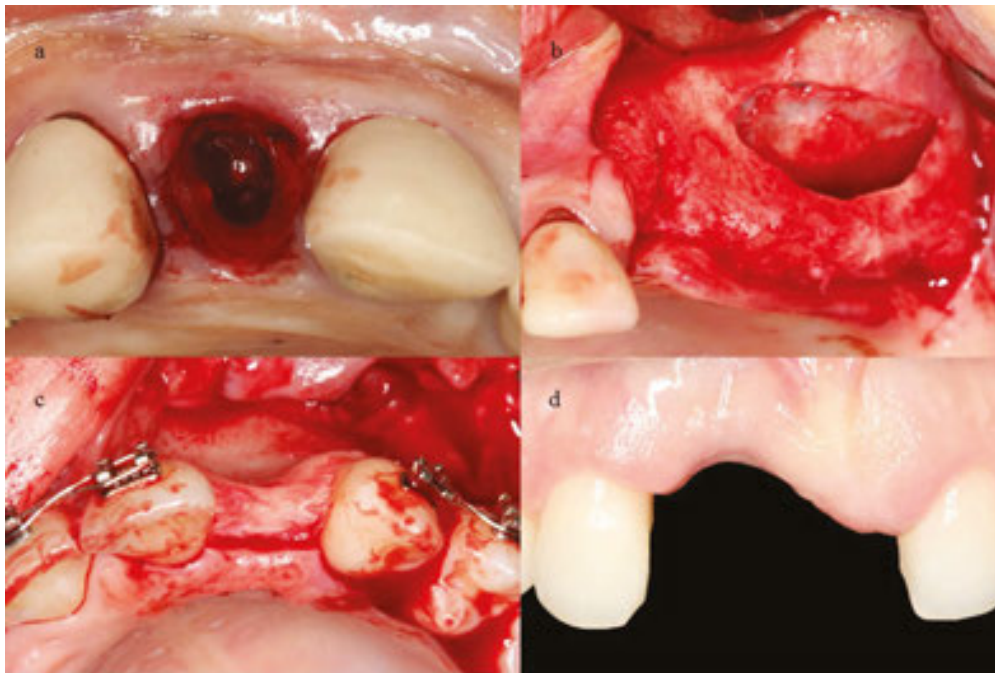


Figure 1. Intrabony (a, b) and extrabony (c, d) alveolar ridge defects.

The amount of augmentation may also influence the risk assessment of the operation. Particularly for vertical augmentation, complications are more likely if a large amount of height is needed outside the natural bone after bone regeneration.

This chapter is focused on GBR and extra-oral bone block techniques that are widely used for ridge augmentation.

2. Alveolar ridge augmentation techniques

2.1. Guided bone regeneration (GBR)

GBR is a surgical technique that increases the amount of alveolar ridge for implant placement using barrier membranes with or without bone substitutes [4]. Regeneration at the deficient

site depends on the exclusion of soft tissue (epithelial cells and fibroblasts) from osteogenic tissue (osteoblasts) during organization of the bone [6]. Osteoblasts are mainly responsible for increasing the amount of regenerated alveolar ridge. However, osteoblasts do not regenerate the alveolar ridge as quickly as epithelial and connective tissue cells grow. The success of the GBR approach mainly depends on the exclusion of soft tissue cells during bone remodeling by slowly working osteoblasts [6]. Aghaloo et al. evaluated the success of ridge augmentation techniques (GBR, onlay block grafting, distraction osteogenesis, ridge splitting, and mandibular interpositional grafting) based on implant survival in a systematic review [7]. They found that GBR may be the best way to augment the ridge according to implant survival.

The GBR technique can be applied in two stages (delayed approach) or in one stage (simultaneous approach with implant placement). If the bone deficiency is low and implant stability can be achieved, the one-stage approach can be applied (**Figure 2**).

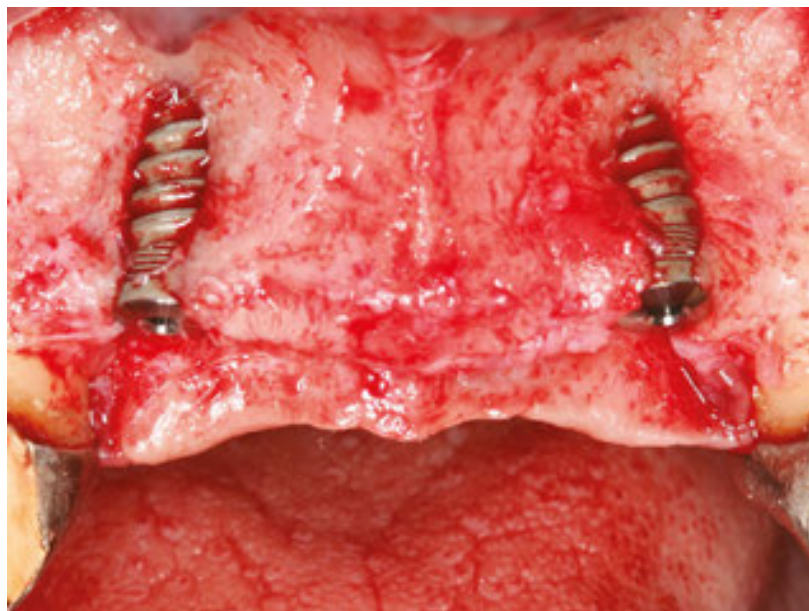


Figure 2. Labial bone deficiency.

However, if a greater amount of bone must be regenerated, then the two-stage approach is preferable and the complication risk will be reduced.

The predictability of GBR is based on several principles, such as space maintenance, stability, nutrition, and primary closure [5]. In this section, these principles are introduced in detail according to the morphology of the bone defects, the grafting material, and the chosen technique.

2.2. Space maintenance

Maintenance of space at the augmented site is one of the fundamental principles of the GBR technique. A protected space is needed for hard-tissue cells to regenerate bone that excludes soft-tissue cells during healing and maturation.

Bone substitutes, membranes, tenting screws, titanium, and bone plates are suggested for the maintenance of space. Jovanovic et al. evaluated the treatment groups in a pre-clinical study on GBR. They found that significant bone gain could be achieved when membrane and graft material were used than when no membrane was used [8]. Space maintenance can be challenging depending on the properties of the defect site. When significant bone augmentation is required in a severely resorbed alveolar ridge, creating space is more critical for the success of GBR.

2.3. Grafting biomaterials

Currently, the use of a bone substitute material in GBR applications is the standard of care. The primary types of bone substitutes are autogenous bone, xenografts, allografts, and alloplasts [4]. An ideal biomaterial for bone regeneration should have the ability to form new bone, and bone formation must be balanced with the speed of resorption [4, 6]. Autogenous bone is the gold standard for augmentation because of its osteogenic potential. It has the ability to regenerate bone through the mechanisms of osteogenesis, osteoinduction, and osteoconduction [4, 6]. Osteogenesis is the production and evolution of bone at every site, even in the absence of local undifferentiated mesenchymal stem cells. Osteoinduction is the transformation of undifferentiated mesenchymal cells into pre-osteoblasts and osteoblasts. Therefore, the graft material should be in contact with living bone. Osteoconduction provides a non-living scaffold for the regeneration of bone [9]. By using local bone harvesting techniques, morbidity can be lowered during autogenous bone collection. Scraping autogenous bone from a location near the recipient site may simplify bone harvesting, decrease morbidity, and reduce the treatment time (**Figure 3**).

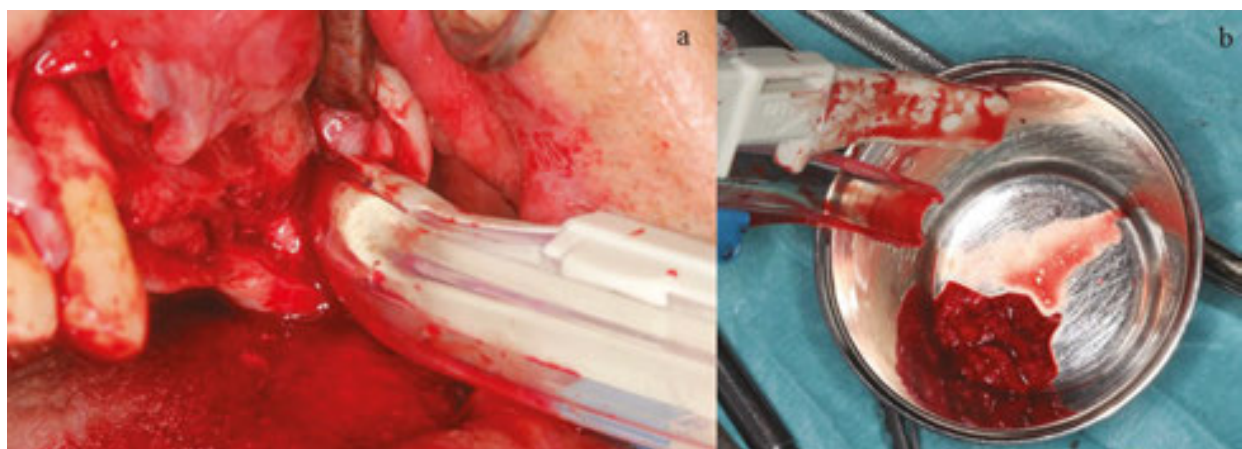


Figure 3. Bone harvesting from tuber site.

Peleg et al. found that the use of a bone scraper to harvest autogenous bone at the ramus resulted in no neurosensory injuries to the anatomical tissues and minimal morbidity in the patients [10]. There are also novel rotary tools to harvest bone easily from local sites (**Figure 4**).

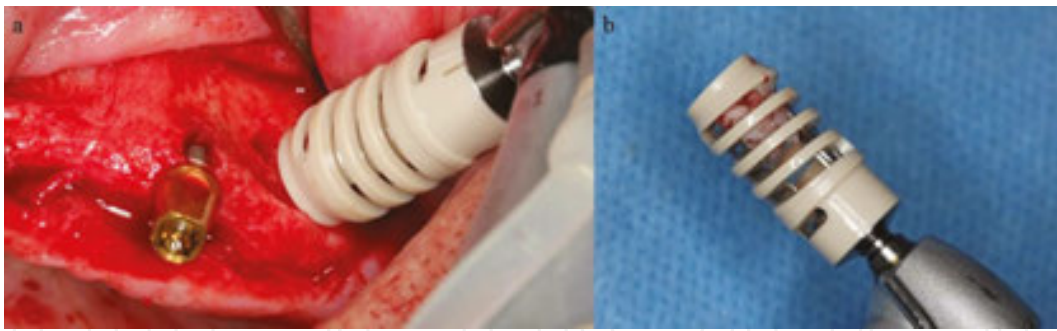


Figure 4. Bone harvesting rotary instrument.

These autogenous particulate grafts can be used alone or with biomaterials as a composite. Composite grafts greatly reduce the amount of autogenous bone required and therefore reduce morbidity.

Bone graft substitutes have osteoconductive properties. However, the use of bone grafting material is very popular among clinicians because of benefits such as the unlimited availability, lack of a need to harvest bone (hence, reduced donor-site morbidity), reduced operation time, and reduced risk of postoperative complications [4, 6].

Xenografts are bone grafts obtained from animals such as cows, horses, or species other than human [4, 6]. Deproteinized bovine bone (DBB) is a xenograft material that is frequently used in GBR applications. DBB is osteoconductive and has an interconnecting pore system that serves as a scaffold for the migration of osteogenic cells; the inorganic bone substance has a microscopic structure similar to that of natural cancellous bone [11, 12]. DBB particles are incorporated over time within the living bone, and DBB resorbs very slowly and has low-substitution rates. Therefore, it can provide space maintenance over a very long term [4, 6]. It was shown that DBB graft particles remain present even after 10 years postoperatively [13]. Chackartchi et al. reported that the mean percentage of new bone was $28 \pm 6\%$ using DBB alone 6–9 months after sinus augmentation [14]. Materials with low-substitution rates are good scaffolds for host bone growth during healing, and they inhibit resorption of the augmented site [4, 6]. However, increased amounts of residual graft particles may negatively impact the healing of the augmented site and decrease the rate at which the implant surface area is integrated with the newly formed bone [15]. In challenging cases that require a greater amount of bone augmentation, such as vertical, horizontal, or both, DBB can be mixed with autogenous particulate bone and applied as a composite [2]. The authors recommend allowing 6–9 months for healing of lateral/vertical augmentations before implant placement. During long-term healing, DBB particles prevent the shrinkage of the augmented site, and autogenous particles facilitate the incorporation of this scaffold with the living natural bone. The authors do not recommend implant placement during the early stages of bone healing (less than 4–5 months) for two-stage augmentations because implant stability may be compromised or severe marginal bone loss may occur before loading [4, 6].

Allografts are bone grafts obtained from the same species but are genetically dissimilar from the recipient [4, 6]. Allograft donors are meticulously screened, and specimens are carefully

processed to reduce the possibility of disease transmission. Freeze drying is a commonly used process. Mineralized allografts (MAs) provide stability and space by maintaining their physical properties during the bone remodeling phase [4, 6]. Osteoconductive scaffolds provide volume enhancement and effective site management for successful dental implant placement after augmentation [16]. MAs can be composed of cortical and cancellous particles. Mineralized cortical particles with slow resorption rates offer a scaffold, whereas cancellous particles that have faster resorption rates and are prone to resorption may provide a space for the ingrowth of bone cells and angiogenesis. Therefore, if the amount of cortical graft particles is increased in the composite, less resorption can be expected [17]. Demineralized allograft (DA) contains bone morphogenic proteins and stimulates osteoinduction. However, DA is highly biodegradable and has less compressive strength than DBB and MA. Therefore, it is often mixed with other slowly resorbed graft materials to maintain space [18]. The authors recommend using MAs in challenging cases, and demineralized grafts are recommended in well-protected defects such as socket augmentation. Implants can be placed safely after 4 months of healing in well-protected defects [17, 18]. The authors do not recommend using DA in challenging cases, such as vertical and lateral augmentation, because a great amount of bone loss can be expected after long-term healing [17, 18].

The possibility of disease transmission from xenografts and allografts to humans has drawn attention to synthetic bone graft substitutes [19]. Alloplasts are synthetic and also have osteoconductive properties that provide a scaffold for bone regeneration [20]. Various synthetic graft materials have been developed for crestal ridge augmentations, such as synthetic hydroxyapatite (HA), beta-tricalcium phosphate (β -TCP), and calcium sulfate (CS) [4]. HA has a low or very limited resorption rate [4]. β -TCP and CS are highly biodegradable and have less compressive strength than synthetic HA and DBB [21, 22]. CS can be completely resorbed within 1 month [23]. Therefore, according to the defect properties, these materials can be mixed with slow resorbable materials in different ratios to maintain space during healing [21, 22]. By increasing the amount of resorbable material in the composite, the rate of new bone formation can also be increased. However, the space maintenance capacity will be reduced, even in sinus augmentation applications [24].

The particle size in the graft may also affect the resorption time and the success of the procedure. There are conflicting articles in the literature regarding graft particle usage [14, 25]. Particles that are too small may be resorbed too rapidly, and advanced shrinkage of the augmented site can be observed. Particles that are too large may prevent angiogenesis and delay and/or reduce new bone formation [25]. Chackartchi et al. compared the use of small and large particles in grafts during two-stage sinus floor augmentation with regard to new bone formation and vertical bone height stability. The authors could not detect any statistically significant differences between the small and large graft particles [14].

Several factors, such as the graft properties, membrane choice, surgical technique, use of compression during packing of the graft material, availability of natural bone, composition of the graft, and activity of the host bone, may influence the resorption rate at the augmented site and may therefore affect space maintenance [26].

2.4. Barrier membranes

Barrier membranes are routinely used to maintain space. There are two kinds of barrier membranes: resorbable and non-resorbable [4, 6].

2.5. Resorbable membranes

The most important advantages of resorbable membranes are the elimination of membrane removal after healing, resulting in decreased morbidity, easy manipulation, and lower rate of complications. However, resorbable membranes are not very successful in comparison with non-resorbable membranes with regard to space maintenance. These membranes must be used with bone graft substitutes and additional tools, such as tenting screws or plates for space maintenance.

Resorbable membranes that are made of native collagen (non-cross-linking) show high biocompatibility resulting in good tissue integration and rapid vascularization (**Figure 5**) [27].

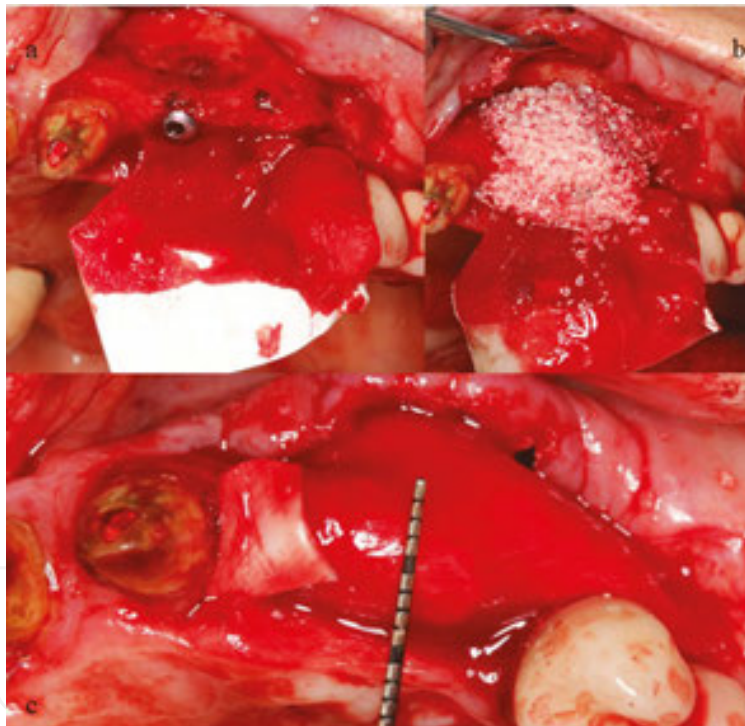


Figure 5. Native collagen resorbable membrane.

However, these membranes may lose their barrier function early due to rapid biodegradation [28]. The resorption time depends on the membrane's properties, the cellular activity of the native bone, and exposure [29]. One of the most important benefits of non-cross-linked collagen membranes is the spontaneous closure of membrane exposure during the healing period [30]. Epithelization of the exposed membrane occurs within weeks after mucosal dehiscence. Although spontaneous healing of the exposure occurs, the grafting volume may be negatively affected during healing, and some bone loss may be expected

[4, 6]. Simion et al. compared the effects of exposed and non-exposed membranes on bone regeneration at the site of implant insertion [31]. Bone regeneration was 99.6% with non-exposed membranes and 48.6% with exposed membranes [31]. There are also studies showing predictable results with late membrane exposures up to 6 months [5]. Therefore, every effort should be made to ensure primary closure of the grafted site during healing. Some clinicians recommend using double non-cross-linked membrane over the grafted site to extend the resorption time for better barrier function [6].

Cross-linking resorbable collagen membranes were produced to extend the degradation time in GBR applications. In a preclinical study, different collagen membranes were compared to evaluate the resorption time [32]. It was found that if the amount of cross-linking collagen fibrils was increased, the resorption time was also extended. However, tissue biocompatibility was decreased. There are also studies showing good results regarding tissue integration and bone regeneration using these membranes [33, 34]. Various types of cross-linked membranes may affect biocompatibility and tissue integration differently [6].

Membranes made of polylactic acid/polyglycolic acid copolymer (PGLA) are also available. These synthetic membranes simplify the clinical manipulation and reduce the application time [6]. Although studies have shown that this material is highly biocompatible and degrades without acidic products, concerns about the healing mechanism remain (**Figure 6**) [35, 36].

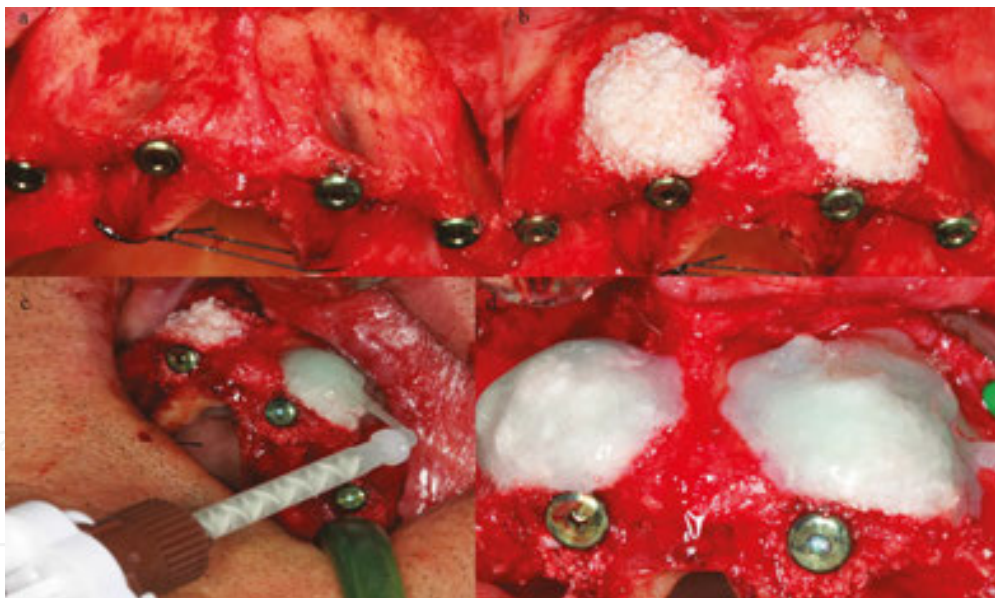


Figure 6. PGLA resorbable membrane.

2.5.1. Non-resorbable membranes

When a higher amount of bone augmentation is required, reinforced non-resorbable membranes are used. Reinforced membranes withstand the pressure from the surrounding tissues, resulting in the prevention of membrane collapse and allowing the bone to be regenerated during healing. Titanium mesh, titanium-reinforced expanded polytetrafluoro-

ethylene (e-PTFE), and dense polytetrafluoroethylene (d-PTFE) membranes are most commonly used, and their benefits have been demonstrated in published studies [2, 4, 6]. Urban et al. augmented alveolar ridges vertically using e-PTFE membranes [37]. The mean vertical augmentation was 5.5 mm after 6–9 months of healing. They concluded that vertical augmentation with e-PTFE membranes and particulate autografts are a reliable method for the reconstruction of deficient alveolar ridges.

Currently, e-PTFE membranes are not used in oral surgery due to high rates of complications related to membrane exposure. d-PTFE membranes are novel titanium-reinforced non-resorbable membranes that have replaced e-PTFE membranes and are used for the reconstruction of critical-sized defects, such as sites requiring vertical augmentation. The highly porous structure of e-PTFE membranes allows ingrowth of the oral microflora when the membrane is exposed. Exposure results in high rates of infection, regardless of whether it occurs early or late during healing. Due to the high porosity of the membrane, it is almost impossible to mechanically or chemically clean the exposed site of the membrane; therefore, early removal of the membrane is required. After removal, it is generally discovered that GBR has failed due to infection, and re-augmentation is needed. e-PTFE membranes must be completely healed in primary closure, and they have no tolerance for exposure [4, 6].

Novel d-PTFE membranes are manufactured in a dense micro-porous form that prevents oral bacteria from entering the grafted site when exposed. These membranes are also easy to mechanically and chemically clean. The removal of a d-PTFE membrane after healing is also easy to perform and takes less time than the removal of titanium-mesh membranes (**Figure 7**).

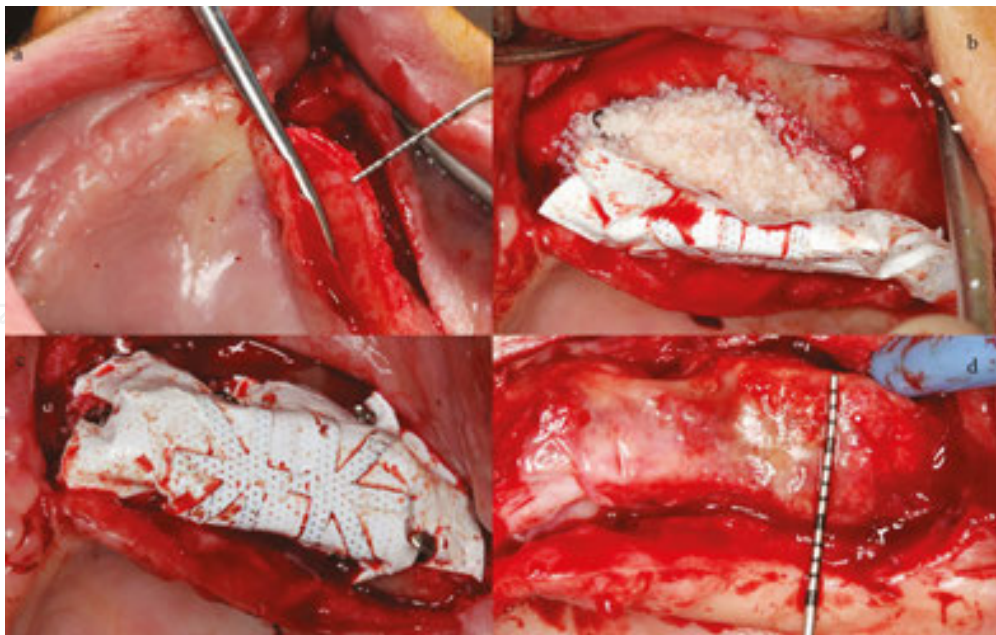


Figure 7. Titanium reinforced non-resorbable membrane.

Ronda et al. reported a mean defect fill of 5.49 mm after 6 months of healing at vertically augmented sites using d-PTFE membranes [38]. Urban et al. observed an average bone gain

of 5.45 mm using d-PTFE membrane with a mixture of bovine bone and autogenous particulate bone [2]. They also found a high rate of new bone formation (36.6%) on core biopsies that were taken at the time of implant placement. They concluded that treatment of vertically deficient alveolar ridges with GBR using a mixture of particulate autogenous bone and bovine grafts with d-PTFE membrane is a reliable method.

Although a high level of success with non-resorbable titanium-reinforced d-PTFE membranes has been reported in the literature, these membranes must be applied cautiously in selected patients. Non-resorbable membranes have higher complication rates than resorbable membranes [39]. If a d-PTFE membrane begins to be exposed, the amount of exposure can increase incrementally during healing [5]. Therefore, if early exposure of this membrane occurs, the prognosis may not be predictable. However, late exposures may be better tolerated with meticulous mechanical cleaning. If an infection does not occur 3–4 months after grafting, removal of the membrane may preserve the regenerated bone [5]. Complications regarding membrane exposure are less likely with resorbable membranes. The cost of GBR with titanium-reinforced membranes may also be higher than with resorbable membranes. Jensen et al. reported comparable amounts of bone gain between resorbable and non-resorbable membranes used for horizontal augmentation [40]. If minor augmentation is planned at a deficient site, resorbable collagen membranes should be considered first due to their low risk of complications. If the natural bone is not too thin, lateral augmentation can be successfully performed using collagen membranes with mixed autogenous particulate grafts and low-substitute graft materials such as DBB.

Titanium mesh is another alternative to non-resorbable membranes, and this type of mesh has a good space maintenance advantage [41]. It can be easily trimmed and bent according to the defect site. Another advantage, and also a disadvantage, of mesh over a PTFE membrane is that the holes within the membrane allow vascularization and nutrition from the periosteum to the grafting site [4–6]. However, bone can also grow from inside these holes over the mesh. After healing, the mesh can integrate with newly formed bone and complicate removal during surgery at the second stage [42, 43].

2.6. Stability

The stability of the augmented site in GBR applications during healing is an important factor for achieving success. The initial blood clot formation and stabilization of graft particles will result in predictable bone formation [5]. Although barrier membranes will cover the augmented site and exclude epithelial and connective tissue cells from the regenerating bone, additional tools are needed to provide stability and also to increase the resistance of the augmented site from the flap, lip, and mastication force pressure [5].

Membrane fixation systems can be used to secure resorbable membranes effectively. By using manual or automatic handles, tacks stabilize the membrane to the natural bone and prevent migration of the graft and soft tissue invasion (**Figure 8**).

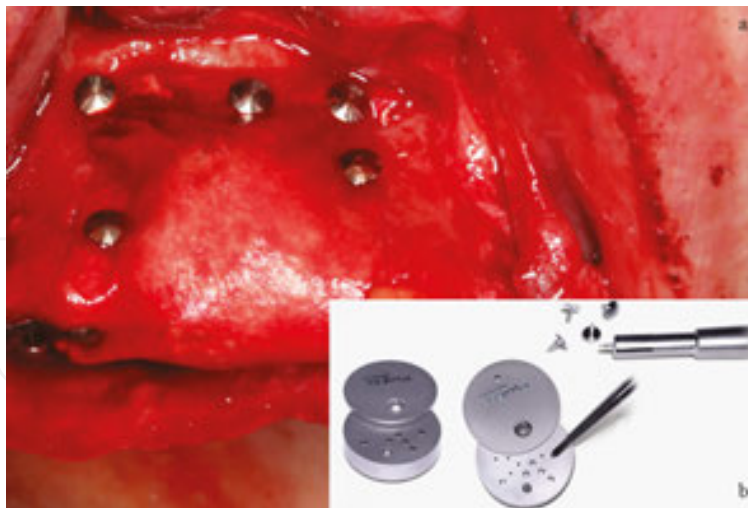

Figure 8. Bone tacks.

Another advantage is that tacking membranes simplify suturing because the membrane does not move during suturing. If lingual or palatal tacking is needed, the angled neck of the handle can be used to simplify the application. Generally, the tacks are made of titanium, and they do not need to be removed at the second-stage surgery. The authors recommend removing tacks that are placed coronally and leaving apically positioned ones to reduce morbidity from excessive flap elevation at the time of implant placement. If tacks are left, they may disturb the patient in the future, and they can be easily removed using a small circular incision around the tack.

Tacks may not be strong enough to secure non-resorbable membranes. Generally, membrane fixation screws are used for stabilization. The aggressive tip and thread design engage the membrane and bone and allow for precise placement in soft and dense bone (**Figure 9**).

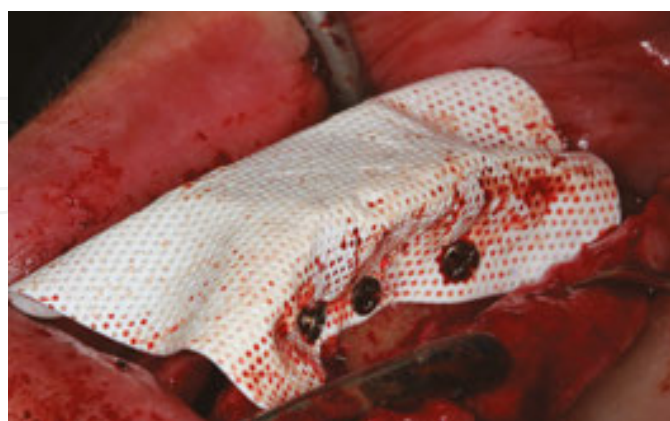

Figure 9. Bone screws.

The authors recommend using short screws in the mandible and longer screws in the maxilla due to its low density; it is easier to engage longer screws in soft bone. If lingual or palatal

screwing is needed, surgical hand pieces can be used to simplify the application. At the second surgery, the non-resorbable membrane and all screws must be removed. If any screw is left, the membrane may not be removed easily.

Tenting screws can also be used under resorbable or non-resorbable membrane to prevent pressure from the environment and also to stabilize the augmented site. The treaded part of these screws engages the natural bone, and the smooth part remains at the augmented site (**Figure 10**).

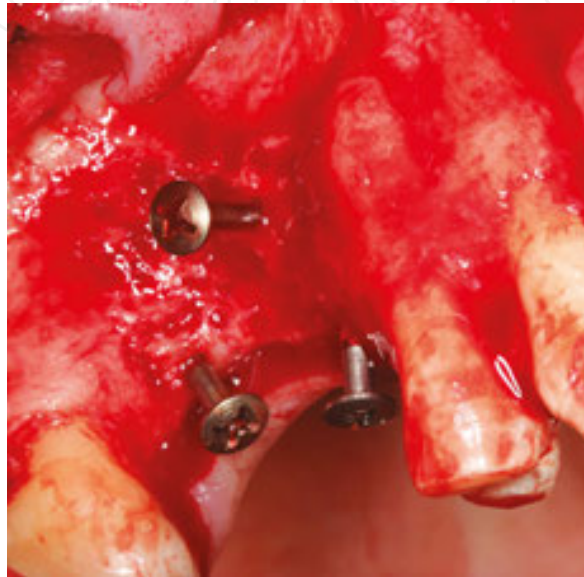

Figure 10. Tenting screws.

Another advantage of using tenting screw is that the clinician may estimate the amount of future bone gain at the time of the operation based on the length of the smooth part. For example, if 5 mm of bone gain is needed, an 8-mm tenting screw can be used and 3 mm of bone will stabilize the screw.

Metal plates that are generally used for orthognathic or trauma surgery can be used for space maintenance [4, 6]. The plate is fixed to the natural bone with screws, and the space between the bone and plate is filled with graft material. A resorbable membrane covers the augmented site. The authors recommend avoiding the use of overly thick plates to prevent soft tissue exposure during healing. Thin cortical strut allografts can also be used for space maintenance in a method known as the Shell technique. Space is created between the cortical strut and the host bone as with metal plates, but there is no need to remove the cortical struts during the second-stage surgery. However, these bone struts are very vulnerable during screwing, and they can be easily broken into pieces [4, 6].

2.6.1. Nutrition

The osteogenic potential of the defect site is also very important for the success of GBR. At the augmented site, the formation of a blood clot begins and granulation tissue invades over the

following days and weeks [44]. Blood vessels that are in the granulation tissue serve in osteoid formation and subsequently bone formation. Therefore, the remaining bone walls are an important source of vessels and native cell transformation. When there are fewer walls around the defect, the regenerative capacity is reduced and the total treatment time is increased [5]. Hammerle et al. observed that grafted sites were regenerated with new bone at least 6–9 months after surgery [45].

Buser et al. recommend perforating the cortical bone before bone grafting for better migration of vessels to the augmented site [46]. There are also conflicting studies suggesting that decortication is not needed for better augmentation [47, 48]. Decortication of both the buccal and lingual aspects of the recipient site has been shown to increase the bone healing capacity by 2–10 times when compared to non-decorticated sites [49]. Several benefits of decortication of recipient site have been demonstrated [50]. First, revascularization is increased after decortication, particularly in the mandible. Second, the release of growth factors can improve healing. Finally, the roughened surface of the recipient site may integrate with the graft materials and increase the stability [50]. If the osseous defect is in the mandible, the authors recommend decortication of the recipient site with a drill under copious cold sterile irrigation (**Figure 11**).

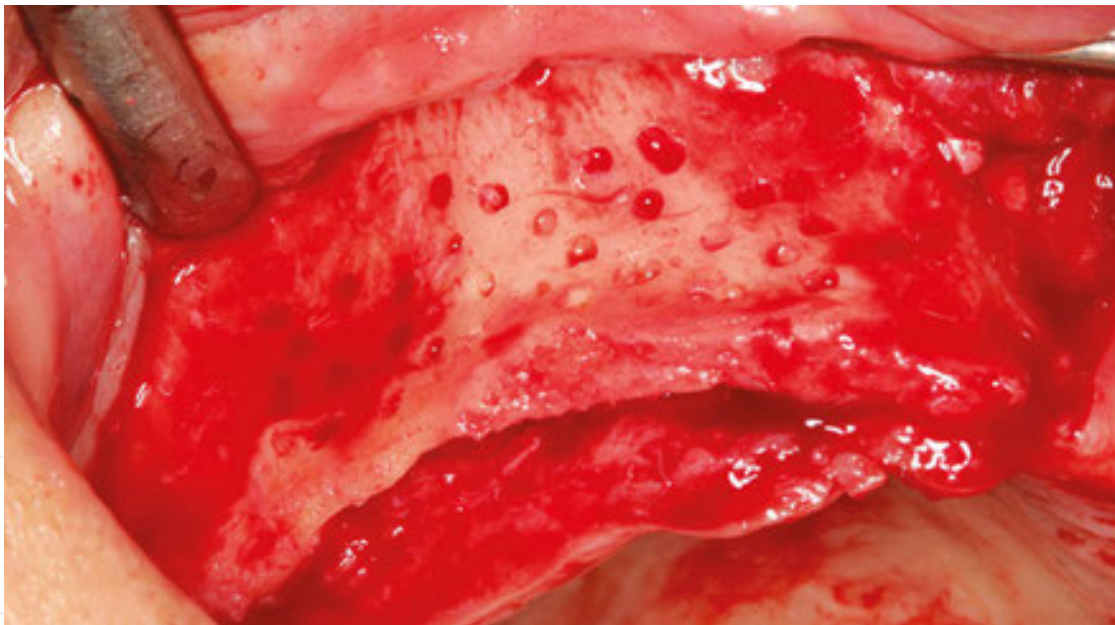


Figure 11. Decorticated bone.

Generally, decortication does not take a considerable amount of time or prolong the operation.

2.6.2. Primary closure

Protection of the grafted site during is an important factor. Wound healing in soft tissue can be achieved by primary or secondary intention. In primary intention, the edges of the flap are brought close and are in the same position as before the incision (**Figure 12**).

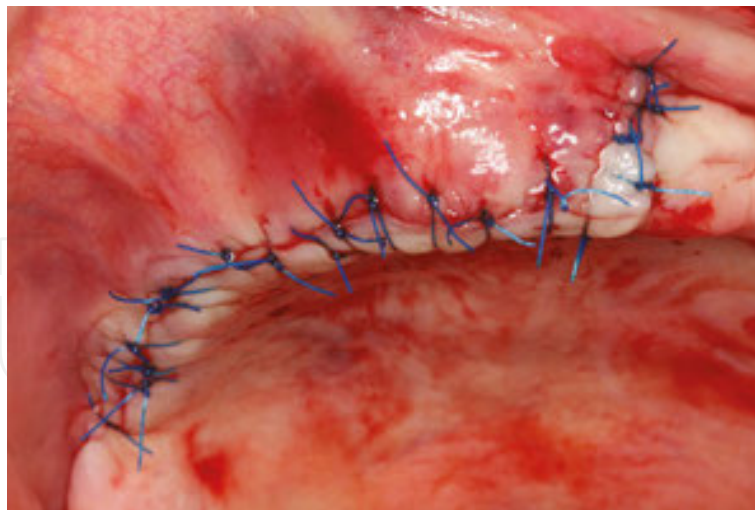


Figure 12. Primary closure.

In secondary intention, the edges of the flap are not closely approximated, and the membrane or grafting material can be seen visually [5]. Secondary intention prolongs the healing and increases the risk of infection at the grafted site [4–6]. Protection of the augmented site begins from a primary tension-free flap closure. If secondary intention healing occurs inadvertently, a series of complications may be encountered, and re-augmentation may be required [5].

Many factors may affect the predictability of GBR outcomes upon primary closure, including the grafting volume of the deficient site. The rate of soft tissue complications may increase in direct proportion with the grafting volume [4, 6]. Therefore, in challenging cases such as vertical augmentation, failures due to soft tissue dehiscence are more frequently seen [6]. Another factor that may affect the clinical outcome is the usage of the appropriate materials and technique. Multifilament sutures, such as silk sutures, are not recommended to use in augmented sites due to the high incidence of infection. Monofilament sutures may help to reduce the infection rate [4–6]. Most importantly, the clinician should be familiar with different suturing techniques to reduce the pressure on the edges of the flap. The authors recommend removing sutures 2–3 weeks after the operation. For vertical augmentations, sutures are generally removed after 3 weeks.

Incision design is also a key factor for tension-free flap closure. In particular, if large deficient sites are planned to be grafted, a greater number of releasing incisions will be needed for tension-free flap closure. Therefore, soft tissue surgical interventions may be needed before or after the operation to increase the vestibular depth and keratinized mucosa [6]. Clinicians should not only focus on hard tissue grafting. For the achievement and maintenance of success, soft tissue conditions such as the gingival biotype, the amount of keratinized mucosa, the vestibular depth, and previous surgical interventions due to failures should be evaluated meticulously during treatment planning [6].

Postoperative care during the initial weeks of healing may affect the outcome of GBR [51]. Chlorhexidine and hyaluronic acid mouthwash after the operation are recommended to reduce infection and improve soft tissue healing [5].

Postsurgical medications should also be prescribed, including antibiotics starting on the day of surgery and lasting for 7 days (1000 mg amoxicillin and clavulanic acid, twice daily), analgesics (to be taken as needed every 6 h), and corticosteroid (e.g., dexamethasone 4 mg daily) for 2–3 days to minimize edema [4, 6, 52]. Patients should be informed in detail with written postoperative instructions after the operation. Solely verbal instructions are not recommended because patients are generally tired after the operation and may forget these instructions.

2.6.3. Iliac crest block bone grafting

Iliac crest block bone grafting is widely used in oral and maxillofacial surgery for the reconstruction of major deficient alveolar ridges. Although both the anterior and posterior ilium can be a source of extra-oral bone grafts, clinicians generally choose the anterior ilium as a donor site because it allows convenient access to the recipient site. Patients remain in a supine position during the operation, and this approach reduces the operation time. Generally, the patient remains in a prone jackknife position during harvesting of the posterior iliac bone, and the patient must be switched to a supine position during the procedure. This may increase the operation time by at least 1–2 h. The anterior ilium can provide both cortical and cancellous bone blocks. Uni-, bi-, or tri-corticocancellous blocks can be harvested under general anesthesia. A bone volume of 50 cc or less can be harvested from a single anterior ilium [53]. If large corticocancellous blocks are needed, harvesting from the posterior iliac bone is appropriate.

The block is harvested according to the dimensions of the bone graft required for the reconstruction of the alveolar ridge. Under general or neuroaxial blockade anesthesia, a skin incision is made approximately 2 cm above the anterosuperior iliac spine, along the anterosuperior margin of the anterior iliac crest. The medial and lateral cortical surfaces of the iliac crest are exposed directly after the subperiosteal dissection. A micro-saw and chisel are used to harvest an autogenous bone block from the anterior iliac crest (**Figure 13**).

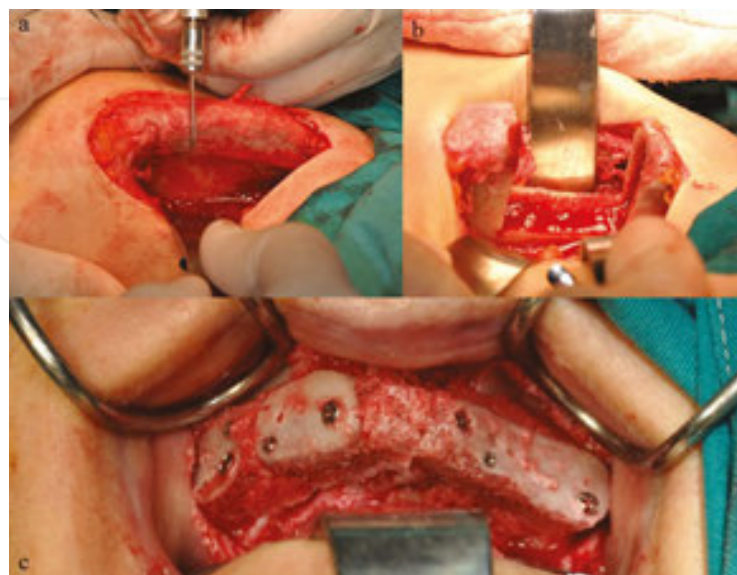


Figure 13. Iliac bone block application.

The block bone grafts are recontoured with diamond burs for optimum adaptation to the recipient site as an onlay technique, and they are fixed to the residual ridge with multiple screws to inhibit micro-movement during the healing process. The corners of the graft are smoothed out to avoid any undesirable exposure during the healing process. Suction drains can be used after harvesting before closure. The periosteum, fascia, and subcutaneous tissues are closed with sutures.

Numerous studies report low-to-moderate morbidity at the time of grafting. Major and minor complications, such as seroma, hematoma, fracture, paresthesia, pain, and gait disturbances, may occur after the operation [54]. Patients should remain in the hospital for at least 1 day; therefore, the total treatment cost is higher than the cost for intra-oral harvesting applications. Iliac bone block grafting morbidity is higher than that of local bone harvesting techniques, such as ramus or chin intra-oral autogenous block harvesting [54]. The experience of the surgeon and technique used plays important roles in reducing morbidity.

Sbordone et al. evaluated the resorption rate in alveolar ridge augmentation after iliac bone block grafting using computerized tomographic scans [53]. The authors reported an average resorption rate of 87% for maxillary grafts after 6 years follow-up [53]. Vermeeren et al. observed a resorption rate ranging from 44% to 50% after 5 years using two-dimensional images [55]. Other studies found a resorption rate ranging from 42% to 87% for onlay grafted bone [56, 57]. The use of a bone block for the reconstruction of a deficient alveolar ridge may be easier than GBR with regard to space maintenance. However, the use of a collagen membrane is still recommended, even in block grafting, to reduce bone resorption [4, 6]. The use of a collagen membrane with block grafting may reduce resorption by almost 25% [4, 6].

Jensen et al. compared GBR and block grafting techniques and found that in 11.1% of cases using GBR and in 2.8% of cases using block grafting, re-augmentation was needed [40]. Contour augmentation can be applied during the second-stage surgery, particularly during implant placement at an esthetically appropriate site. This second augmentation may not only limit bone resorption around implants in the future, but it may also support soft tissue and improve the esthetic appearance [4, 6]. The authors recommend using only slowly resorbable grafting materials such as DBB at the buccal site for re-augmentation with a collagen membrane. Tacked collagen membrane with grafting material will increase the bone thickness horizontally and facilitate anterior esthetic success.

More bone can be regenerated using iliac blocks than GBR [40]. However, iliac bone blocks may be more prone to resorption during healing [53]. Therefore, clinicians should estimate the rate of resorption and increase the amount of harvested bone block. Caution should be taken during treatment planning, and it is preferable to increase the number of implants used in iliac block-augmented patients to decrease the detrimental effects of loading forces [58]. Implant designs that include platform switching may also help to reduce marginal bone loss [52]. One important advantage of block grafting over GBR is the healing time. Four to five months are sufficient for a bone block integrates with the host bone and allow for implant placement [53, 54, 56]. However, particularly for vertical augmentations, 7–9 months are needed for the GBR technique to achieve implant stability [2, 37]. Therefore, it is easier for patients to accept a two-stage GBR treatment if temporary prostheses are provided during long-term healing. A

temporary prosthesis can be manufactured using a provisional implant with a fixed or removable prosthesis. If the available bone is appropriate for the stabilization of four provisional implants, fixed temporary restorations can be provided during long-term healing. Soft tissue-supported removable prostheses are not recommended because they may adversely influence the stability of the augmented site.

According to the literature, the survival rates of dental implants inserted at augmented sites are similar to the survival rates of implants placed in natural bone [59, 60]. Marginal bone loss was also similar between implants placed in augmented and pristine bone [61, 62].

2.6.4. The future of tissue engineering

The field of biomaterials and tissue engineering is rapidly growing, and growth factors have great potential for promoting bone regeneration at the resorbed alveolar ridge. Among the various growth factors, recombinant human bone morphogenic protein-2 (rhBMP-2) and recombinant human platelet-derived growth factor (rhPDGF) have received a great deal of attention [63]. Although there are numerous graft materials available, such as xenograft, allograft, and alloplast, most have only osteoconductive properties and provide only a scaffold for bone regeneration during healing. Researchers are attempting to completely eliminate the use of autogenous bone at severe augmentation sites to decrease patient morbidity. Therefore, studies regarding growth factor use with graft materials are increasing [63, 64].

The bone morphogenetic proteins (BMPs) are members of the transforming growth factor- β superfamily. BMPs regulate differentiation, chemotaxis, growth, and apoptosis of osteogenic cells and induce significant bone regeneration [65, 66].

Platelet-derived growth factor (PDGF) is released from aggregated platelets during the early healing phase at the wound site and exerts chemotactic and mitogenic effects on inflammatory cells and undifferentiated mesenchymal cells [67]. PDGF-BB shows potential effects on cells that influence bone regeneration, and it stimulates type I collagen synthesis in osteoblasts, directs cell migration or chemotaxis of progenitor cells, and participates in the initiation angiogenesis [68, 69]. Of the five PDGF isoforms, PDGF-BB is the most biologically potent and has the greatest binding affinity for osteoblasts [69].

In a preclinical study, Simion et al. found that a significant amount of new bone formation was achieved using DBB blocks and rhPDGF-BB in the rehabilitation of severe mandibular ridge defects [70]. Wallace et al. applied rhBMP-2-wetted absorbable collagen sponges in extraction sockets [71], and they found 49.6% vital bone in core biopsies taken after 4 months of healing. These authors suggested that rhBMP-2 and collagen sponges may replace the use of barrier membranes and graft materials to rehabilitate extraction sockets for future implant placement. In another study, Misch et al. used rhBMP-2/collagen sponges and a titanium mesh for augmentation of the atrophic mandible prior to implant placement [72]. All dental implants were placed after 6 months of healing, and healing of the augmented sites was uneventful.

The Food and Drug Administration has approved the usage of rhBMP-2/collagen sponges (INFUSE Bone Graft kits; Medtronic, Minneapolis, MN, USA) in extraction socket and sinus floor augmentation (well-protected defects). The number of published pre-clinical and clinical

articles regarding the use of growth factors in reconstruction of hard tissue defects is growing. The use of growth factor instead of autogenous bone offers several advantages, such as decreased patient morbidity, reduced operation time, increased amounts of vital bone at the augmented site in comparison with scaffold biomaterials, and simplification of the surgical technique [70–72]. Clinicians need to be familiar with properties, limitations, and techniques associated with these materials before application. In the future, there can be no doubt that growth factors will play an important role in hard and soft tissue engineering.

3. Conclusion

Many novel techniques, biomaterials, and tools have been described in the literature that clinicians may use to reconstruct bone deficiencies. However, most importantly, the success of alveolar ridge augmentation procedures mainly depends on clinician experience and skill. The surgical risks may be increased for challenging reconstructions. Therefore, the clinician and patient should carefully evaluate the benefits and risks of the operation and decide on the most ideal treatment option. Prosthetic-driven augmentation is recommended for a better outcome. If the clinician focuses only on ridge augmentation techniques to solve bone deficiency problems, he or she may overlook other treatment options that may have lower risks and less morbidity, such as using short, narrow, or tilted implants. After all, ridge augmentation is being performed for the ideal placement of dental implants.

Author details

Bahattin Alper Gultekin^{1*}, Erol Cansiz² and Serdar Yalcin¹

*Address all correspondence to: alpergultekin@hotmail.com

1 Istanbul University, Faculty of Dentistry, Department of Oral Implantology, Istanbul, Turkey

2 Istanbul University, Faculty of Dentistry, Department of Oral and Maxillofacial Surgery, Istanbul, Turkey

References

- [1] Chiapasco M, Consolo U, Bianchi A, Ronchi P. Alveolar distraction osteogenesis for the correction of vertically deficient edentulous ridges: a multicenter prospective study on humans. *Int J Oral Maxillofac Implants*. 2004;19:399–407.

- [2] Urban IA, Lozada JL, Jovanovic SA, Nagursky H, Nagy K. Vertical ridge augmentation with titanium-reinforced, dense-PTFE membranes and a combination of particulate autogenous bone and anorganic bovine bone-derived mineral: a prospective case series in 19 patients. *Int J Oral Maxillofac Implants*. 2014;29:185–193. doi: 10.11607/jomi.3346.
- [3] Urban IA, Nagursky H, Lozada JL, Nagy K. Horizontal ridge augmentation with a collagen membrane and a combination of particulate autogenous bone and anorganic bovine bone-derived mineral: a prospective case series in 25 patients. *Int J Periodontics Restorative Dent*. 2013;33:299–307. doi: 10.11607/prd.1407.
- [4] Liu J, Kerns DG. Mechanisms of guided bone regeneration: a review. *Open Dent J*. 2014;16:56–65. doi: 10.2174/1874210601408010056.
- [5] Wang HL, Boyapati L. “PASS” principles for predictable bone regeneration. *Implant Dent*. 2006;15:8–17.
- [6] Benic GI, Hämmerle CH. Horizontal bone augmentation by means of guided bone regeneration. *Periodontol 2000*. 2014;66:13–40. doi: 10.1111/prd.12039.
- [7] Aghaloo TL, Moy PK. Which hard tissue augmentation techniques are the most successful in furnishing bony support for implant placement? *Int J Oral Maxillofac Implants*. 2007;22:49–70.
- [8] Jovanovic SA, Schenk RK, Orsini M, Kenney EB. Supracrestal bone formation around dental implants: an experimental dog study. *Int J Oral Maxillofac Implants*. 1995;10:23–31.
- [9] Schenk RK, Buser D, Hardwick WR, Dahlin C. Healing pattern of bone regeneration in membrane-protected defects: a histologic study in the canine mandible. *Int J Oral Maxillofac Implants*. 1994;9:13–29.
- [10] Peleg M, Garg AK, Misch CM, Mazor Z. Maxillary sinus and ridge augmentations using a surface-derived autogenous bone graft. *J Oral Maxillofac Surg*. 2004;62:1535–1544.
- [11] Wallace SS, Froum SJ. Effect of maxillary sinus augmentation on the survival of endosseous dental implants. A systematic review. *Ann Periodontol*. 2003;8:328–343.
- [12] Chiapasco M, Casentini P, Zaniboni M. Bone augmentation procedures in implant dentistry. *Int J Oral Maxillofac Implants*. 2009;24:237–259.
- [13] Piattelli M, Favero GA, Scarano A, Orsini G, Piattelli A. Bone reactions to anorganic bovine bone (Bio-Oss) used in sinus augmentation procedures: a histologic long-term report of 20 cases in humans. *Int J Oral Maxillofac Implants*. 1999;14:835–840.
- [14] Chackartchi T, Iezzi G, Goldstein M, Klinger A, Soskolne A, Piattelli A, Shapira L. Sinus floor augmentation using large (1–2 mm) or small (0.25–1 mm) bovine bone mineral particles: a prospective, intra-individual controlled clinical, micro-computerized tomography and histomorphometric study. *Clin Oral Implants Res*. 2011;22:473–480. doi: 10.1111/j.1600-0501.2010.02032.

- [15] Jensen T, Schou S, Gundersen HJ, Forman JL, Terheyden H, Holmstrup P. Bone-to-implant contact after maxillary sinus floor augmentation with Bio-Oss and autogenous bone in different ratios in mini pigs. *Clin Oral Implants Res.* 2013;24:635–644. doi: 10.1111/j.1600-0501.2012.02438.
- [16] Blomqvist JE, Alberius P, Isaksson S, Linde A, Obrant K. Importance of bone graft quality for implant integration after maxillary sinus reconstruction. *Oral Surg Oral Med Oral Pathol Oral Radiol Endod.* 1998;86:268–274.
- [17] Avila G, Neiva R, Misch CE, Galindo-Moreno P, Benavides E, Rudek I, Wang HL. Clinical and histologic outcomes after the use of a novel allograft for maxillary sinus augmentation: a case series. *Implant Dent.* 2010;19:330–341. doi: 10.1097/ID.0b013e3181e59b32.
- [18] Won YH, Kim SG, Oh JS, Lim SC. Clinical evaluation of demineralized bone allograft for sinus lifts in humans: a clinical and histologic study. *Implant Dent.* 2011;20:460–464. doi: 10.1097/ID.0b013e31823541e7.
- [19] Sogal A, Tofe AJ. Risk assessment of bovine spongiform encephalopathy transmission through bone graft material derived from bovine bone used for dental applications. *J Periodontol.* 1999;70:1053–1063.
- [20] Barrack RL. Bone graft extenders, substitutes and osteogenic proteins. *J Arthroplasty.* 2005;20:94–97.
- [21] Degidi M, Dapriale G, Piattelli A. Primary stability determination of implants inserted in sinus augmented sites: 1-step versus 2-step procedure. *Implant Dent.* 2013;22:530–533.
- [22] Giannoudis PV, Dinopoulos H, Tsiridis E. Bone substitutes: an update. *Injury* 2005;36:20–27.
- [23] Guarnieri R, Grassi R, Ripari M, Pecora G. Maxillary sinus augmentation using granular calcium sulfate (surgiplaster sinus): radiographic and histologic study at 2 years. *Int J Periodontics Restorative Dent.* 2006;26:79–85.
- [24] Mazzocco F, Lops D, Gobbato L, Lolato A, Romeo E, del Fabbro M. Three-dimensional volume change of grafted bone in the maxillary sinus. *Int J Oral Maxillofac Implants.* 2014;29:178–184. doi: 10.11607/jomi.3236.
- [25] Committee on Research, Science and Therapy of the American Academy of Periodontology. Tissue banking of bone allografts used in periodontal regeneration. *J Periodontol.* 2001;72:834–838.
- [26] Kirmeier R, Payer M, Wehrschoetz M, Jakse N, Platzer S, Lorenzoni M. Evaluation of three-dimensional changes after sinus floor augmentation with different grafting materials. *Clin Oral Implants Res.* 2008;19:366–372. doi: 10.1111/j.1600-0501.2007.01487.

- [27] Owens KW, Yukna RA. Collagen membrane resorption in dogs: a comparative study. *Implant Dent.* 2001;10:49–58.
- [28] Miller N, Penaud J, Foliguet B, Membre H, Ambrosini P, Plombas M. Resorption rates of 2 commercially available bioresorbable membranes. A histomorphometric study in a rabbit model. *J Clin Periodontol.* 1996;23:1051–1059.
- [29] Rothamel D, Schwarz F, Fienitz T, Smeets R, Dreiseidler T, Ritter L, Happe A, Zöller J. Biocompatibility and biodegradation of a native porcine pericardium membrane: results of in vitro and in vivo examinations. *Int J Oral Maxillofac Implants.* 2012;27:146–154.
- [30] Riedmann A, Strietzel FP, Maretzki B, Pitaru S, Bernimoulin JP. Observations on a new collagen barrier membrane in 16 consecutively treated patients. Clinical and histological findings. *J Periodontol.* 2001;72:1616–1623.
- [31] Simion M, Baldoni M, Rossi P, Zaffe D. A comparative study of the effectiveness of e-PTFE membranes with and without early exposure during the healing period. *Int J Periodontics Restorative Dent.* 1994;14:166–180.
- [32] Rothamel D, Schwarz F, Sager M, Herten M, Sculean A, Becker J. Biodegradation of differently cross-linked collagen membranes: an experimental study in the rat. *Clin Oral Implants Res.* 2005;16:369–378.
- [33] Friedmann A, Gissel K, Soudan M, Kleber BM, Pitaru S, Dietrich T. Randomized controlled trial on lateral augmentation using two collagen membranes: morphometric results on mineralized tissue compound. *J Clin Periodontol.* 2011;38:677–685.
- [34] Moses O, Pitaru S, Artzi Z, Nemcovsky CE. Healing of dehiscence-type defects in implants placed together with different barrier membranes: a comparative clinical study. *Clin Oral Implants Res.* 2005;16:210–219.
- [35] Herten M, Jung RE, Ferrari D, Rothamel D, Golubovic V, Molenberg A, Hammerle CH, Becker J, Schwarz F. Biodegradation of different synthetic hydrogels made of polyethylene glycol hydrogel/RGD-peptide modifications: an immunohistochemical study in rats. *Clin Oral Implants Res.* 2009;20:116–125.
- [36] Wechsler S, Fehr D, Molenberg A, Raeber G, Schense JC, Weber FE. A novel, tissue occlusive poly(ethylene glycol) hydrogel material. *J Biomed Mater Res A* 2008;85:285–292.
- [37] Urban IA, Jovanovic SA, Lozada JL. Vertical ridge augmentation using guided bone regeneration (GBR) in three clinical scenarios prior to implant placement: a retrospective study of 35 patients 12 to 72 months after loading. *Int J Oral Maxillofac Implants.* 2009;24:502–510.
- [38] Ronda M, Rebaudi A, Torelli L, Stacchi C. Expanded vs. dense polytetrafluoroethylene membranes in vertical ridge augmentation around dental implants: a prospective

- randomized controlled clinical trial. *Clin Oral Implants Res.* 2014;25:859–866. doi: 10.1111/clr.12157.
- [39] Zitzmann NU, Naef R, Schärer P. Resorbable versus nonresorbable membranes in combination with Bio-Oss for guided bone regeneration. *Int J Oral Maxillofac Implants.* 1997;12:844–852.
- [40] Jensen SS, Terheyden H. Bone augmentation procedures in localized defects in the alveolar ridge: clinical results with different bone grafts and bone-substitute materials. *Int J Oral Maxillofac Implants.* 2009;24:218–236.
- [41] Sumi Y, Miyaishi O, Tohnai I, Ueda M. Alveolar ridge augmentation with titanium mesh and autogenous bone. *Oral Surg Oral Med Oral Pathol Oral Radiol Endod.* 2000;89:268–270.
- [42] Jovanovic SA, Nevins M. Bone formation utilizing titanium-reinforced barrier membranes. *Int J Periodont Restorat Dent.* 1995;15:56–69.
- [43] Malchiodi L, Scarano A, Quaranta M, Piattelli A. Rigid fixation by means of titanium mesh in edentulous ridge expansion for horizontal ridge augmentation in the maxilla. *Int J Oral Maxillofac Implants.* 1998;13:701–705.
- [44] Schmid J, Wallkamm B, Hämmerle CH, Gogolewski S, Lang NP. The significance of angiogenesis in guided bone regeneration. A case report of a rabbit experiment. *Clin Oral Implants Res.* 1997;8:244–248.
- [45] Hämmerle CH, Schmid J, Olah AJ, Lang NP. A novel model system for the study of experimental guided bone formation in humans. *Clin Oral Implants Res.* 1996;7:38–47.
- [46] Buser D, Dula K, Belser UC, Hirt HP, Berthold H. Localized ridge augmentation using guided bone regeneration. II. Surgical procedure in the mandible. *Int J Periodontics Restorative Dent.* 1995;15:10–29.
- [47] Kostopoulos L, Karring T, Uraguchi R. Formation of jawbone tuberosities by guided tissue regeneration. An experimental study in the rat. *Clin Oral Implants Res.* 1994;5:245–253.
- [48] Kostopoulos L, Karring T. Augmentation of the rat mandible using guided tissue regeneration. *Clin Oral Implants Res.* 1994;5:75–82.
- [49] Nishimura I, Shimizu Y, Ooya K. Effects of cortical bone perforation on experimental guided bone regeneration. *Clin Oral Implants Res.* 2004;15:293–300.
- [50] Lundgren AK, Lundgren D, Hämmerle CH, Nyman S, Sennerby L. Influence of decortication of the donor bone on guided bone augmentation. An experimental study in the rabbit skull bone. *Clin Oral Implants Res.* 2000;11:99–106.
- [51] Bunyaratavej P, Wang HL. Collagen membranes: a review. *J Periodontol.* 2001;72:215–229.

- [52] Gultekin BA, Gultekin P, Leblebicioglu B, Basegmez C, Yalcin S. Clinical evaluation of marginal bone loss and stability in two types of submerged dental implants. *Int J Oral Maxillofac Implants*. 2013;28:815–823. doi: 10.11607/jomi.3087.
- [53] Sbordone C, Toti P, Guidetti F, Califano L, Santoro A, Sbordone L. Volume changes of iliac crest autogenous bone grafts after vertical and horizontal alveolar ridge augmentation of atrophic maxillas and mandibles: a 6-year computerized tomographic follow-up. *J Oral Maxillofac Surg*. 2012;70:2559–2565. doi: 10.1016/j.joms.2012.07.040.
- [54] Barone A, Ricci M, Mangano F, Covani U. Morbidity associated with iliac crest harvesting in the treatment of maxillary and mandibular atrophies: a 10-year analysis. *J Oral Maxillofac Surg*. 2011;69:2298–2304. doi: 10.1016/j.joms.2011.01.014.
- [55] Vermeeren JI, Wismeijer D, van Waas MA. One-step reconstruction of the severely resorbed mandible with onlay bone grafts and endosteal implants. A 5-year follow-up. *Int J Oral Maxillofac Surg*. 1996;25:112–115.
- [56] Johansson B, Grepe A, Wannfors K, Hirsch JM. A clinical study of changes in the volume of bone grafts in the atrophic maxilla. *Dentomaxillofac Radiol*. 2001;30:157–161.
- [57] Sbordone L, Toti P, Menchini-Fabris GB, Sbordone C, Piombino P, Guidetti F. Volume changes of autogenous bone grafts after alveolar ridge augmentation of atrophic maxillae and mandibles. *Int J Oral Maxillofac Surg*. 2009;38:1059–1065. doi: 10.1016/j.ijom.2009.06.024.
- [58] Bayraktar M, Gultekin BA, Yalcin S, Mijiritsky E. Effect of crown to implant ratio and implant dimensions on periimplant stress of splinted implant-supported crowns: a finite element analysis. *Implant Dent*. 2013;22:406–413. doi: 10.1097/ID.0b013e31829c224d.
- [59] Donos N, Mardas N, Chadha V. Clinical outcomes of implants following lateral bone augmentation: systematic assessment of available options (barrier membranes, bone grafts, split osteotomy). *J Clin Periodontol*. 2008;35:173–202.
- [60] Hammerle CH, Jung RE, Feloutzis A. A systematic review of the survival of implants in bone sites augmented with barrier membranes (guided bone regeneration) in partially edentulous patients. *J Clin Periodontol*. 2002;29:226–231.
- [61] Gbureck U, Holzel T, Biermann I, Barralet JE, Grover LM. Preparation of tricalcium phosphate/calcium pyrophosphate structures via rapid prototyping. *J Mater Sci Mater Med*. 2008;19:1559–1563.
- [62] Jung RE, Fenner N, Zitzmann NU, Hammerle C. Long-term outcome of implants placed with guided bone regeneration (GBR) using resorbable and non-resorbable membranes after 12 to 14 years. *Clin Oral Implants Res*. 2013;24:1065–1073.
- [63] Park SY, Kim KH, Shin SY, Koo KT, Lee YM, Seol YJ. Dual delivery of rh PDGF-BB and bone marrow mesenchymal stromal cells expressing the BMP2 gene enhance bone formation in a critical-sized defect model. *Tissue Eng Part A* 2013;19:2495–2505.

- [64] Rocchietta I, Dellavia C, Nevins M, Simion M. Bone regenerated via rhPDGF-bB and a deproteinized bovine bone matrix: backscattered electron microscopic element analysis. *Int J Periodontics Restorative Dent*. 2007;27:539–545.
- [65] Reddi AH. Bone morphogenetic proteins: from basic science to clinical applications. *J Bone Joint Surg Am*. 2001;83:1–6.
- [66] Groeneveld EH, Burger EH. Bone morphogenetic proteins in human bone regeneration. *Eur J Endocrinol*. 2000;142:9–21.
- [67] Canalis E, Varghese S, Mc Carthy TL, Centrella M. Role of platelet derived growth factor in bone cell function. *Growth Regul*. 1992;2:151–155.
- [68] Andrew JG, Hoyland JA, Freemont AJ, Marsh DR. Platelet-derived growth factor expression in normally healing human fractures. *Bone* 1995;16:455–460.
- [69] Centrella M, Mc Carthy TL, Kusmik WF, Canalis E. Relative binding and biochemical effects of heterodimeric and homodimeric isoforms of platelet-derived growth factor in osteoblast-enriched cultures from fetal rat bone. *J Cell Physiol*. 1991;147:420–426.
- [70] Simion M, Rocchietta I, Kim D, Nevins M, Fiorellini J. Vertical ridge augmentation by means of deproteinized bovine bone block and recombinant human platelet-derived growth factor-BB: a histologic study in a dog model. *Int J Periodontics Restorative Dent*. 2006;26:415–423.
- [71] Wallace SC, Pikos MA, Prasad H. De novo bone regeneration in human extraction sites using recombinant human bone morphogenetic protein-2/ACS: a clinical, histomorphometric, densitometric, and 3-dimensional cone-beam computerized tomographic scan evaluation. *Implant Dent*. 2014;23:132–137. doi: 10.1097/ID.0000000000000035.
- [72] Misch CM, Jensen OT, Pikos MA, Malmquist JP. Vertical bone augmentation using recombinant bone morphogenetic protein, mineralized bone allograft, and titanium mesh: a retrospective cone beam computed tomography study. *Int J Oral Maxillofac Implants*. 2015;30:202–207. doi: 10.11607/jomi.3977.