

We are IntechOpen, the world's leading publisher of Open Access books Built by scientists, for scientists

6,900

Open access books available

186,000

International authors and editors

200M

Downloads

Our authors are among the

154

Countries delivered to

TOP 1%

most cited scientists

12.2%

Contributors from top 500 universities



WEB OF SCIENCE™

Selection of our books indexed in the Book Citation Index
in Web of Science™ Core Collection (BKCI)

Interested in publishing with us?
Contact book.department@intechopen.com

Numbers displayed above are based on latest data collected.
For more information visit www.intechopen.com



Modern Technologies for Timely Detection and Differential Diagnosis of Gastric Cancer

Vladimir Levkin, Nina Gagarina, Sergey Kharnas, Gaziyav Musaev, Artem Shiryaev and Dmitry Bulgin

Additional information is available at the end of the chapter

<http://dx.doi.org/10.5772/62540>

Abstract

The diagnostic potentialities of laser spectro- and videofluorescence endoscopy, complex transabdominal US examination, dynamic multihelical computed tomography (MHCT) with the possibility of constructing multiplanar reformations, and virtual gastroscopy were studied with a view to diagnosing gastric cancer (GC). It was established that laser spectral fluorescence with the drug Alasens (5-aminolevulinic acid) is a highly revealing method for diagnosis and differential diagnosis of GC. The sensitivity of the method is 96%, and its specificity is 78%. Well-defined videofluorescence was noted in 91.3% of patients with GC. The possibility of detecting cancer with complex trans-ultrasonography in the pyloroantral division and in the lower third of the body of the stomach constitutes 95.6% attaining absolute values in T3 and T4. Dynamic MHCT allows 97% detection of GC attaining absolute values, beginning with T2 invasion depth; tumor localization is irrelevant. Comparative visual assessment of the quality of a virtual image and conventional video esophagogastroduodenoscopy (EGDS) was made. The study demonstrated a sufficiently high level of virtual images whose quality was not inferior to that of conventional images in intraluminal tumor growth. The indications for the application of this technique require further specification.

Keywords: Gastric cancer, 5-aminolevulinic acid (Alasens), laser spectro- and videofluorescence, complex transabdominal US examination, dynamic multihelical-computed tomography, virtual endoscopy

1. Introduction

Despite the fact that during the previous decades the incidence of gastric cancer (GC) has been tending to decrease in many countries of the world, this disease continues to occupy a leading

place in the structure of oncological diseases and is one of the commonest causes of death from malignant neoplasms [1]. It is common knowledge that the success of treatment of patients with GC primarily depends on the timely diagnosis (tumor detection or primary diagnosis).

The main methods that enable us to detect gastric tumor and to verify the diagnosis are esophagogastroduodenoscopy with biopsy and roentgenologic examination of the upper gastrointestinal tract using the double contrast technique. The advantages of these methods are known and indisputable. At the same time, their shortcomings are also well known, namely the difficulty in detecting early forms of cancer as well as tumors with the endophytic submucosal character of growth. A relatively high number of both false-negative and false-positive results necessitates repeat endoscopic examinations and biopsies [2].

At present, laser fluorescence spectroscopy is one of the promising methods for the early diagnosis of malignant tumors, including GC [3, 4]. This method allows us to enhance the efficacy of the standard endoscopic examination in cancer and proved so informative that it is referred to as 'optic biopsy.' We distinguish autofluorescence, i.e., fluorescence of endogenic porphyrins whose concentration in the tumor cells is higher than in normal cells, and secondary fluorescence, i.e., the fluorescence of special exogenous photosensitizers, which are tropic to tumor cells. Neither method is free from typical disadvantages: photosensitizers are accumulated not only in the tumor but also in the skin and visible mucous membranes where they are retained for a long time and cause photodermatitis if the light regimen is compromised. The main disadvantages of autofluorescence monitoring are a low contrast ratio and the necessity of high-precision costly equipment.

Laser fluorescence spectroscopy has offered new possibilities with the development of 5-aminolevulinic acid (5-ALA), which induces the synthesis and accumulation of photoactive protoporphyrin IX in tumor cells. This results in intense fluorescence, which can be registered not only with spectroanalyzers but also with special highly sensitive fluorescent endoscopes, which opens up new horizons for clinical practice.

With the appearance of new radiodiagnostic technologies and the perfection of the already available [such as ultrasonography, endo-ultrasonography, computed tomography (CT), magnetic resonance imaging, and positron emission tomography] techniques, their possibilities in modern diagnostics of GC are actively being assessed [5–7]. In particular, numerous investigations demonstrated the potentialities of a complex transabdominal US examination with water loading as a method for primary diagnosis of GC [5].

Computed tomography is conventionally considered to be a method for secondary diagnosis of GC and, above all, detection of remote metastases. However, the studies conducted recently give evidence of the fact that the results of multihelical computed tomography (MHCT) are on a par with those of the X-ray and endoscopic methods in detecting GC [8]. Moreover, this method allows, after preliminarily insufflating the stomach, the performance of the so-called virtual gastroscopy. Thus, dynamic MHCT additionally allows a wider field of view of the organ in the modes of constructing multiplanar reformations and virtual endoscopy and, in contrast to conventional videoendoscopy, is characterized by the absence of blind zones [7, 9]. The drawbacks of the method are as follows: the construction of multiplanar and virtual images

is time-consuming; the absence of delicate shades of color at the boundary of lesion; the impossibility to perform biopsy; and radiation exposure [7, 9]. Most of the works devoted to primary diagnostics of GC with MHCT are mainly of pilot character.

The aim of this study is to look into the diagnostic possibilities of laser spectro- and video-fluorescent endoscopy, complex trans-US examination, MHCT with the possibility of constructing multiplanar reformations, and virtual gastroscopy in the primary diagnosis of GC.

2. Materials and methods

The studies were conducted in the Burdenko Surgical Clinic of the Sechenov First Moscow State Medical University from 2003 to 2010.

The results of laser spectral fluorescence diagnostics (FD) were analyzed in 62 patients with malignant (37, 59.7%) and benign (35, 40.3%) diseases. Videofluorescence was observed in 25 patients (23 with GC and 2 with benign diseases). The study was conducted using 5-ALA-based Alasens (GNTs NIOPIK, Research Institute of Organic Semi-Products and Dyes), which was preliminarily dissolved in 200 mL of water (10–20 mg/kg of body mass) and ingested per os 1.5–2 h before the study. A LESA-01 spectroanalyzer (Biospek and the Institute of Optic Physics, Russian Academy of Sciences, Russia) was used for monitoring fluorescence. To pinpoint videofluorescence (Figure 2), a special attachment for the standard endoscope consisting of a high-sensitivity camera (0.003 lx) and a system of light filters and a photodiode laser with a wavelength of 630 nm and a power of 1.5 W were used.

Eighty-seven patients with GC underwent complex trans-US examination. The study was conducted using SIQUOIA apparatuses (ACUSON, the United States) operating in the real-time mode and furnished with a convex transducer with a frequency of 2.5–3.5 MHz and a linear probe with a frequency of 7.0–11.0 MHz. A two-stage method with the water test proposed by Worlicek et al. (1989) was used when ultrasonography was performed [9].

Ninety patients with verified GC and 10 patients with suspected GC were subjected to dynamic MHCT. The study was conducted using a Toshiba 320-slice tomograph with 16-cm detector that allowed three-dimensional (3D) dynamic scanning with visualization of the whole stomach in the dynamic mode without table feed. The native sequence was then performed, a 16-cm examination zone along the Z-axis (embracing the whole stomach) was chosen, and the abdominal cavity and the small pelvis were scanned. The subsequent procedure included the construction of multiplanar reformations and dynamic video files. When virtual gastroscopy was constructed (16 patients), the stomachs were preliminarily insufflated through a probe or by using a special effervescent mixture consisting of citric acid and sodium bicarbonate (4.0–6.0 g).

To objectively evaluate the information content of the methods used for diagnosing GC and assessing its extent of spread, the diagnostic results were compared with the intraoperative and histological findings. The international TNM classification (UICC 2002) was used for staging GC.

The clinical data were analyzed with the standard methods for statistical processing using Microsoft Excel, SPSS 14.0, and MedCalc 5.0.

3. Results

3.1. Laser spectral and videofluorescent diagnostics of gastric cancer

Only 18 patients were diagnosed as having GC prior to the performance of FD. Later, this diagnosis was verified by both the fluorescence intensity data (PRIX, the contrast ratio 2.1–18.6) and histological findings.

Of 31 patients with the preliminary diagnosis of gastric ulcer, FD performance revealed a high-fluorescence intensity (the contrast ratio 2.1–9.6) at the edges of ulceration in 12 patients (Figure 1).

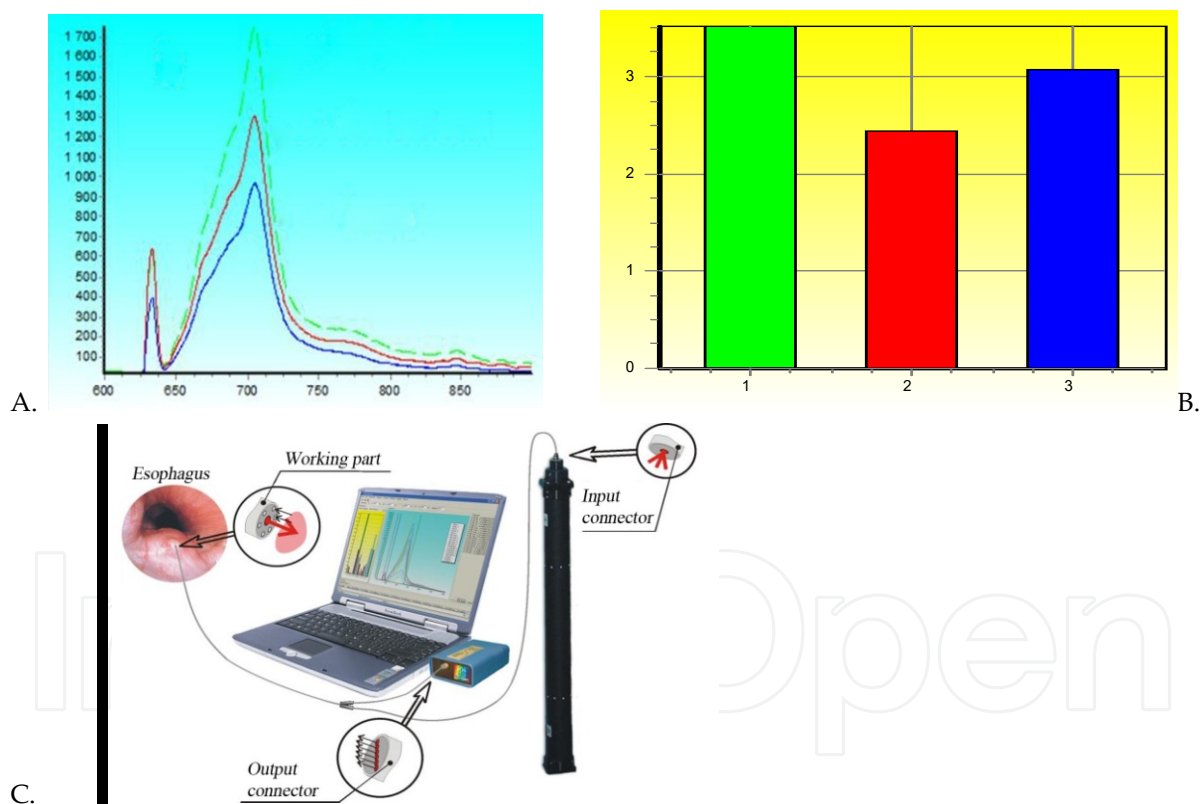


Figure 1. (A) Spectrogram and (B) histogram in gastric cancer and (C) the scheme and the principle of operation of LESA-01.

Target biopsy of the mucous membrane was performed at these points; histological examination of the biopsy material confirmed the diagnosis of GC. In the remaining 14 patients, the FD data (the contrast ratio 0.7–0.8) coincided with the histological findings; the diagnosis of gastric ulcer was verified.

Esophagogastroduodenoscopy revealed atypical regions of the mucosa suggestive of cancer in five patients. High-intensity fluorescence of ALA-induced PRIX (the contrast ratio 2.1–8.0) was observed in four patients when FD was carried out. Target biopsy of the mucous membrane of the stomach was performed, and the diagnosis of GC was made. Likewise, a patient with a gastric polyp (the contrast ratio 3.3) was diagnosed as having carcinoma in situ based on the results of histological examination.

In four patients, the preliminary diagnosis of GC was rejected after spectroscopy, which was verified by the data of the subsequent morphological examination.

High-intensity fluorescence of ALA-induced PRIX was detected at 1–2 points of the region studied in five observations. As evidenced by the results of histological examination, a markedly pronounced inflammatory reaction was revealed in four of five of these patients. Numerous authors [3] report that inflammation may be associated with increased generation of ALA-induced PPIX.

Taking into account the foregoing, these patients can be included in the risk group but not assigned to those with false-positive results. These patients require preventive endoscopic examinations at least once a year.

In one observation, during FD the contrast ratio constituted 1.1; however, morphological examination revealed highly differentiated adenocarcinoma. This result can be attributed to false-negative ones.

On the whole, the contrast ratio constituted 4.55 ± 0.2 across the GC group (from 3.83 ± 0.6 in carcinoma in situ to 6.13 ± 0.2 in stage IV). In patients with gastric ulcer, the contrast ratio was 1.08 ± 0.7 . The difference between the contrast ratio values in malignant and benign diseases is statistically significant ($p \leq 0.05$). The sensitivity of the diagnostic method with the study of Alasens-induced fluorescence was 96%, and its specificity was 78%.

3.2. Videofluorescence study

When performing endoscopic examination of the fluorescent images of the stomach, distinct fluorescence of the tumor in 21 (91.3%) of 23 patients with GC was noted (Figure 2).

In two patients, the diagnosis of GC was excluded during complex examination and, accordingly, videofluorescence was absent (no false-negative results were noted). In addition, the foci of severe dysplasia and malignancy were seen to be fluorescing, which was later confirmed by the results of analysis of both the fluorescence spectra and the biopsy findings.

3.3. Complex trans-ultrasonography in the primary diagnosis of GC

To assess the possibilities of complex transabdominal US examination as a potential screening method in detecting GC, we examined patients with different stages and different localization of the neoplastic process.

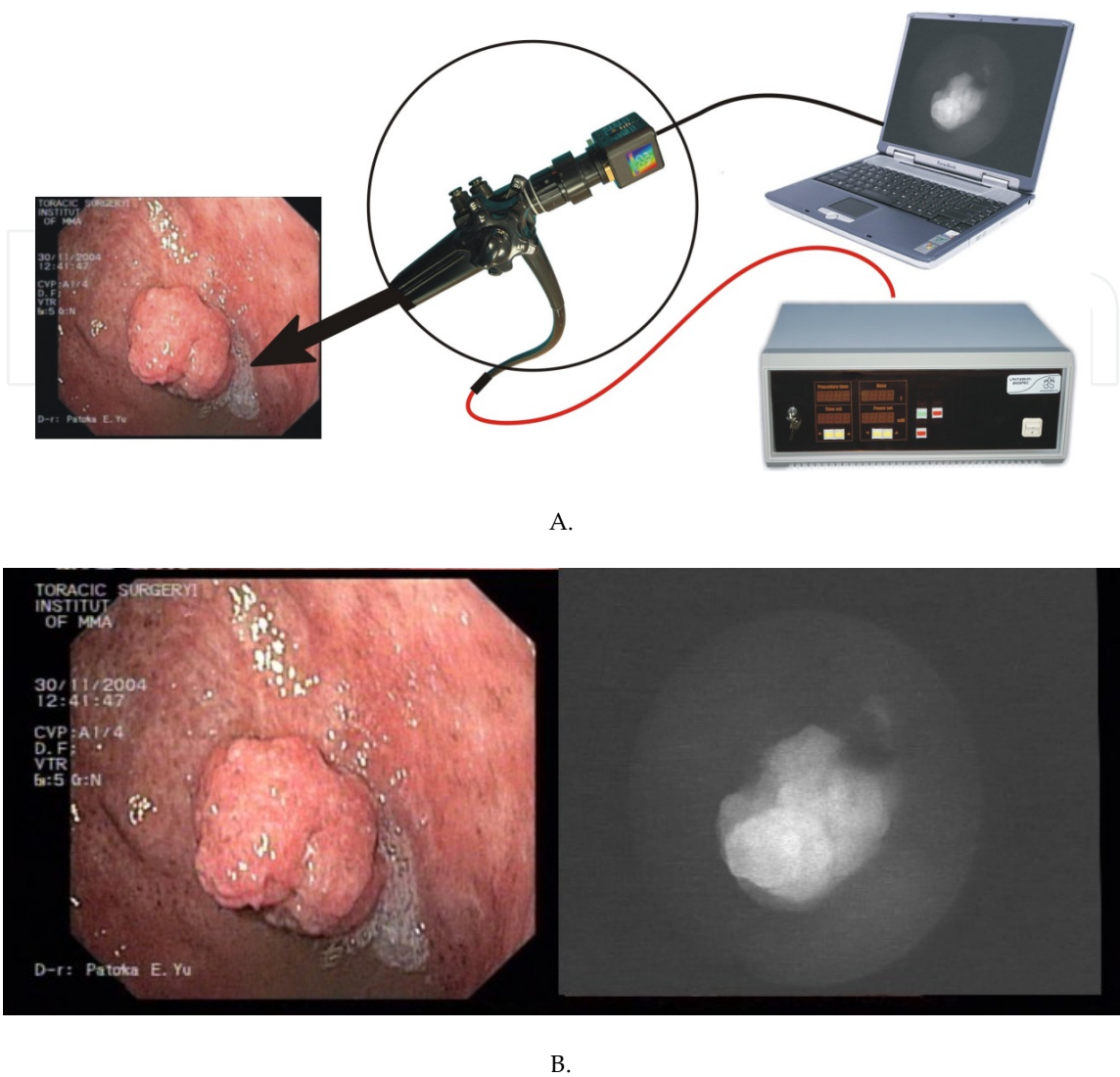


Figure 2. (A) Prototype of the videofluorescence unit and (B) Malignant gastric polyp (videoendoscopy and video-fluorescence).

3.3.1. T1 invasion depth

To reveal disease at this stage of development of the pathological process is a difficult task due to a small short local extension and a low depth of the tumor lesion (Figure 3).

According to the postoperative histological findings, 28 patients had T2 invasion depth; the performance of ultrasonography was successful in detecting the tumor in 20 patients (in 8 patients using the standard technique; in 12 patients, US + ingestion of water). In six observations, the tumor was localized in the regions inaccessible to US examination: the cardia and the upper third of the stomach body; in two observations, in the pyloroantral zone and the lower third of the body at the lesser curvature.

In two observations, ultrasonography was the first diagnostic procedure that enabled us to suspect early antral cancer in the form of local thickening of the gastric wall with 1.5-cm

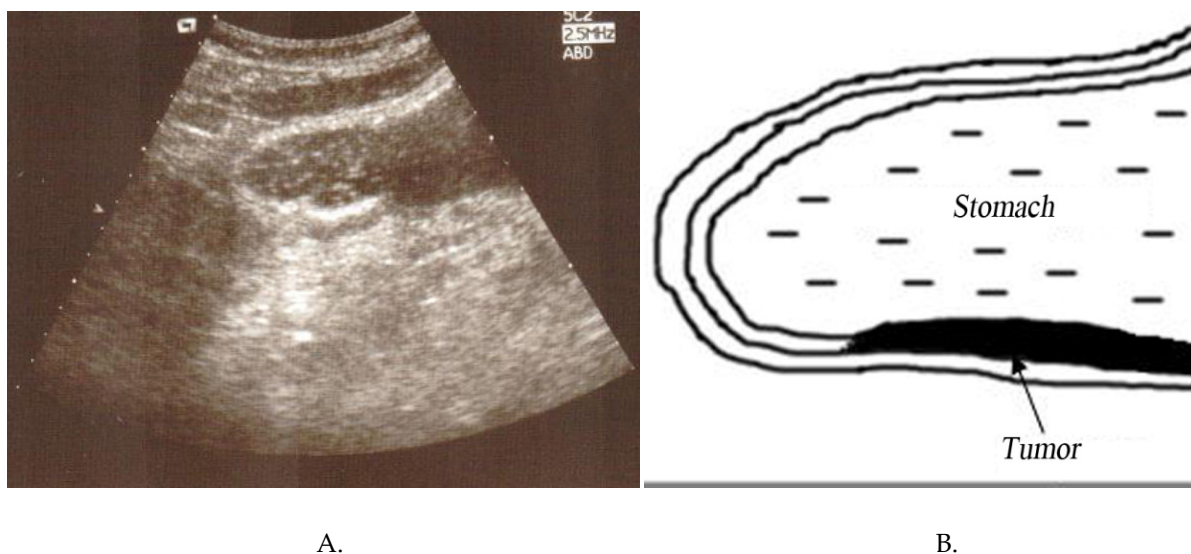


Figure 3. (A) Echogram and (B) the scheme of the infiltrative lesion of the gastric wall. T1 invasion depth.

extension, which was subsequently verified by the esophagogastroduodenoscopy (EGDS) + biopsy and X-ray findings.

Thus, complex US examination was instrumental in detecting a tumor at T1 invasion depth in 72% of observations, and when the tumor was localized in the pyloroantral division of the stomach and in the lower third of the organ, this level increased to 90%. The sensitivity and specificity of this technique in measuring the T1 invasion depth constituted 42.9% and 91.8%, respectively.

3.3.2. T2 invasion depth

According to the histological findings, T2 invasion depth was noted in 19 patients; complex ultrasonography revealed a tumor in 18 patients. In one patient, the tumor was localized in the cardiac region and in the upper third of the stomach body, i.e., the regions inaccessible to US examination. At the first stage of complex US examination, a tumor was detected in 16 patients and in two more patients at the second stage with the water test. However, in numerous cases, it was not simple to reveal a tumor with category T2 invasion depth. This was only possible when the organ was thoroughly and meticulously examined.

Thus, the detection rate for T2 invasion depth lesions was 95% if the tumor was localized in the pyloric and antral divisions of the stomach or involved in its body. The sensitivity and specificity in determining T2 invasion depth constituted 63.2% and 81%, respectively.

3.3.3. T3 invasion depth

According to the histological findings, T3 invasion depth was noted in 16 patients. In all observations, except one (a tumor invading the upper third and the cardiac division of the stomach with a low degree of extension), we succeeded in detecting the tumor easily enough resorting to both techniques: the standard ultrasonography and US supplemented with water

loading. At this depth of lesion, it was the classical 'hollow organ' symptom that was most commonly observed in the US image. At this pathological stage, we visualized not only considerable thickening of the stomach wall but also a large extent of spread of the tumor along the longitudinal axis of the organ involving several anatomical regions. All this facilitated the task of tumor detection.

Thus, ultrasound examination supplemented with the water test did not increase the information content in terms of tumor detection at this stage of the disease but allowed us to evaluate more thoroughly the extent of infiltration, to determine the depth of involvement by the tumor, and to improve visualization of the organs of the retroperitoneal space.

Complex transabdominal US examination enabled us to reveal the tumor in 94% of cases in T3 invasion depth. If the localization site was the pylorus, antrum, and body of the stomach, the detection rate was 100%. The sensitivity and specificity in relation to measuring the invasion depth were 75% and 83.6%, respectively.

3.3.4. T4 invasion depth

As judged by the results of the histological examination of biopsy material, T4 invasion depth was noted in 14 patients. In all the observations of patients with category T4 malignant lesions, the tumor was revealed easily as the 'hollow organ' symptom due to a large extent of spread using both techniques: the standard ultrasonography and US with water loading.

In our study, invasion of the adjacent organs, the great vessels, and fatty tissue by the tumor was suspected during ultrasonic examination in four patients, which was later confirmed intraoperatively using the same procedure and by revision of the organs of the abdominal cavity.

Thus, the possibility of detecting tumor lesions of the stomach with T4 invasion depth was absolute. As far as the sensitivity and specificity of the method are concerned, they are 85.7% and 93.7%, respectively.

3.4. Dynamic MHCT in the diagnostics of gastric cancer

Until recently, CT was regarded as a technique for secondary diagnosis of GC. As dynamic MHCT is a more informative diagnostic method, we studied the possibilities of primary diagnostics of GC, including the so-called virtual endoscopy.

3.4.1. T1 invasion depth

Based on the data of postoperative histological examination, T1 invasion depth was diagnosed in nine patients. We succeeded in detecting the tumor in seven of nine observations (78%). In all the cases, T1 invasion depth was characterized by the non-uniform contrast of the mucous-submucous layer and peristaltic disorder, even if the wall thickening was insignificant. In two observations of early GC (carcinoma in situ), we failed to reveal the tumor.

Thus, the sensitivity of MHCT in revealing T1 invasion depth constituted 22%; its specificity is 100%; the positive predictive value (PPV) is 100%; and the negative predictive value (NPV) is 93%.

3.4.2. T2 invasion depth

According to the histological findings, T2 invasion depth was determined in 13 patients. We succeeded in detecting the tumor in all the cases, irrespective of the localization of the neoplastic process in the stomach.

The most characteristic CT symptom at T2 invasion depth, as at T1 invasion depth, is limited thickening of the gastric wall (13.6 ± 5.4 mm) with increased accumulation of the contrast medium and with impaired peristalsis in this division without the involvement of perigastric fatty tissue.

The sensitivity of MHCT in measuring T2 invasion depth constituted 69%; its specificity is 92%; PPV is 57%; and NPV is 95%.

3.4.3. T3 invasion depth

According to the results of histological examination, the T3 invasion depth group included 24 patients. With T3 invasion depth, marked (19.0 ± 8.4 mm) thickening of the stomach wall, irregularity of the external outline with reticular, and linear thickening of the surrounding fatty tissue are noted.

The accumulation of contrast medium by the tumor was of different character and depended, to a larger degree, on its histological variant. It was not difficult to reveal the tumor lesion at this stage of the process due to the extent of spread when compared to stage T2, not to mention T1. Moreover, at this stage of the disease, not only the stomach wall is significantly thickened, but also the tumor is more extended involving several anatomical regions of the stomach, which was especially well seen when multiplanar images were constructed.

The sensitivity of MHCT in revealing T3 invasion depth constituted 80%; its specificity is 85%; PPV is 71%; and NPV is 91%.

3.4.4. T4 invasion depth

It should be noted that the T4 invasion depth is associated with the most significant lesion of the organ in terms of depth and the extent of spread. In all our observations (36 patients), it was not difficult to reveal the tumor as with T3 malignant lesions. The CT picture of T4 invasion depth, as visualized with dynamic MHCT, was characterized by marked thickening of the stomach walls (21.3 ± 7.1 mm) with their indistinct outline, infiltration of the adjacent fatty tissue, the absence of the boundary between the gastric wall and the adjacent organs, and invasion of the surrounding organs by the tumor (Figure 4).

The detection of the tumor involving the adjacent organs and tissues was a significant criterion confirming the presence of this stage of disease. Thus, according to the data of our study, when

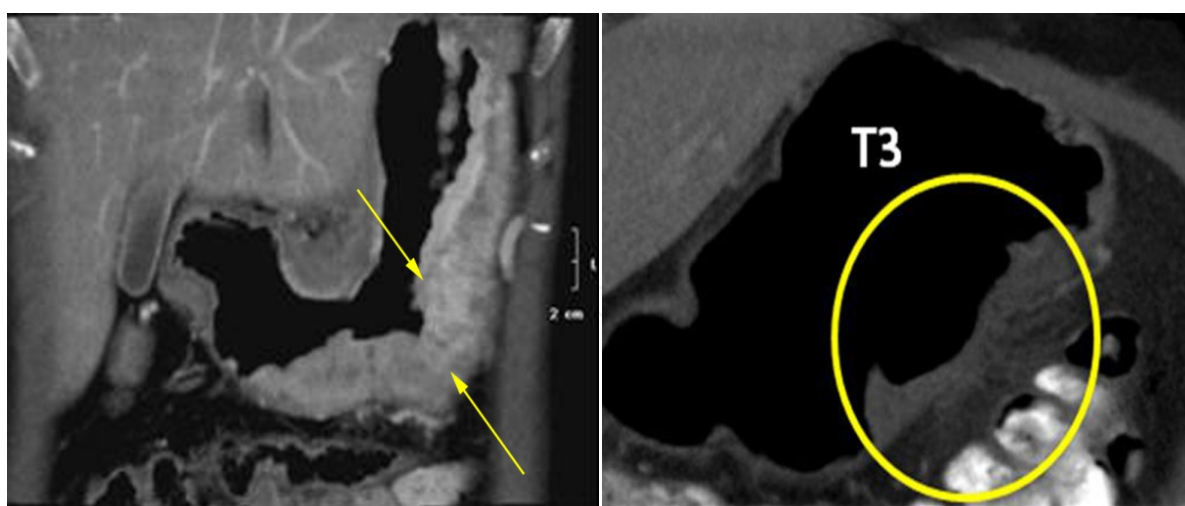


Figure 4. Dynamic MHCT, gastric cancer, subtotal lesion, T3–T4 invasion depth, multiplanar reformations.

MHCT was performed, we suspected invasion of the adjacent organs and the great vessels by the tumor in 18 patients, which was subsequently verified with intraoperative ultrasonographic examination and by revision of the organs of the abdominal cavity.

The sensitivity of MHCT in detecting T4 invasion depth was 83%; its specificity is 95%; PPV is 91%; and NPV is 91%.

On the whole, the sensitivity of MHCT in detecting GC constituted 97%; its specificity is 100%; PPV is 100%; and NPV is 77%.

3.5. Virtual endoscopy

Some authors consider virtual endoscopy as a potentially screening method of diagnostics and differential diagnostics of GC. In this connection, we evaluated the diagnostic possibilities of the method and the quality of the image obtained in the process of simulation.

3.5.1. Gastric leiomyoma

Based on the EGDS and X-ray data, two patients had intraluminal tumor growth; in one female patient, the tumor was localized outside the stomach only insignificantly bulging into the lumen of the organ. In all the cases, a virtual image obtained as a result of CT simulation was characterized by a high quality maximally approximating to the image obtained during videoendoscopy. The study enabled us to specify the localization of the tumor, and the planar slices demonstrated the tumor site relative to the stomach wall (intraparietal localization with prolapse into the lumen or extragastral). These data allowed us to preliminarily choose and plan the optimal treatment modality (wedge resection of the stomach was performed in all patients).

When a virtual image is constructed in patients with GC, it is worth pointing out the following. In the cases when exophytic tumor growth (Type 1, according to Bormann's classification) was

noted (three observations; Figure 5), the greatest similarity between a virtual and video image was obtained (irrespective of localization of the tumor in the stomach).

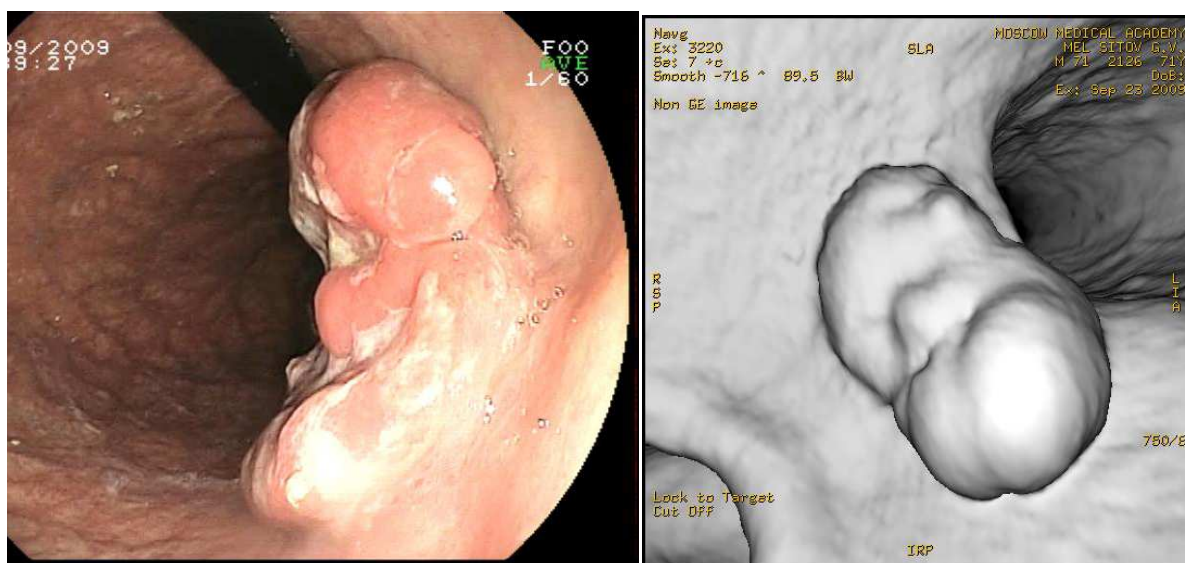


Figure 5. Video EGDS. The virtual endoscopy.

The high quality of virtual images was also noted in the infiltrative and mixed character of growth, when the tumor was localized in the body of the stomach (five patients). In infiltrative tumor growth with the phenomena of antral stenosis, the presence of fluid (primarily, its amount) in the organ lumen affected the quality of the image, which resulted in the appearance of artifacts in the simulation process (in two of five patients). Note that the mucous membrane in the region of lesion and nearby was characterized by excessive serration, although the circular narrowing of the antral division of the stomach characteristic of such a lesion was also well visualized as in videoendoscopy. The planar slices specified the depth of tumor invasion and the status of regional lymphatic vessels and allowed the detection of remote metastases. Unfortunately, the video sequences obtained during the study were characterized by the monotonousness of color images and did not allow us to pinpoint the areas of necrosis and disintegration, hemorrhage of the tumor surface, as well as perineoplastic and inflammatory mucosal changes. The high level (100%) of detection of a tumor lesion of the organ during virtual simulation in our study is determined by the vast extent of the lesion (large-sized leiomyomas and extended stage II–IV GC) and a good level of inflation of the organ.

4. Discussion

Despite rapid development of medical technologies, it is difficult to differentiate between benign and malignant tumors of the stomach. In this connection, the development of new and the perfection of available technologies is an important task. One of the most promising methods for increasing the resolving capacity of endoscopic examination is laser spectro- and

videofluorescence. The procedure of endoscopic fluorescent diagnostics only insignificantly lengthens the EGDS performance time (in contrast to chromoendoscopy), and the conclusion as to the character of a pathological process can be formulated immediately in the process of gastroscopy performance. The equipment complex used now for FD is compact (portable) and mobile enough, which allows it to be delivered to the endoscopy room. No additional time for assembling the complex and preparing it for operation under the endoscopy room conditions is required. The rapid elimination of Alasens from the body decreases the likelihood of the development of toxic and photic reactions and makes it a drug of choice for fluorescent diagnostics. All the above mentioned allows us to recommend laser spectral FD combined with the study of Alasens-induced PPIX, and videofluorescence in the future, to use in the clinical setting as an express method of diagnosis, including the early diagnosis, of malignant gastric tumors.

This study showed that complex transabdominal ultrasonography is a highly informative method of diagnosis of GC. The possibility of detecting GC localized in the pyloroantral division and in the lower third of the stomach body during trans-US performance approaches the absolute values (97.4%). At the same time, in isolated lesions of the cardia and the upper third of the stomach body, we failed to reveal the tumor in any of the 10 patients studied. On the whole, the success rate of revealing GC at all tumor sites using complex trans-US examination constituted 87.0%. The high level of detection of the neoplastic process in the stomach in our study can be explained by the fact that we knew exactly where the process was localized in most patients (based on the EGDS and X-ray findings) and targeted at the zone concerned. However, this does not decrease the possibilities of the method but, on the contrary, testifies to its high diagnostic potential. In addition to the changes revealed for the first time in the stomach (in two patients with early cancer), the 'hollow organ' symptom was detected in numerous patients at the outpatient step followed by purpose-oriented examination and verification of the diagnosis with the subsequent referral to the clinic for operative treatment. Our experience shows that routine ultrasonography of the organs of the abdominal cavity should not be confined to the examination of the parenchymatous organs only. What is necessary is target visualization in the region of hollow organs (in particular, the stomach), especially in patients with the phenomena of abdominal discomfort. True, ultrasonography is actually the first and sometimes the only diagnostic procedure for most of such patients.

The studies conducted recently emphasized low diagnostic possibilities of conventional CT investigation in detecting GC, especially at stage T1 when the attempts to reveal any changes in the stomach wall were unsuccessful. On the whole, the accuracy of detecting the depth of invasion in more prevalent forms was not satisfactory either (no more than 65%) [10]. The main limiting factors were artifacts from peristaltic movements of the stomach wall, which did not allow us to assess its condition on standard examination. However, at present, the appearance of dynamic 3D MHCT capable of assessing the stomach wall in all the divisions in the four-dimensional mode has significantly increased the diagnostic possibilities of this technique.

In our study, dynamic 3D CT proved to be a highly revealing technique for GC (sensitivity 97%). Such high values were primarily achieved by virtue of the possibility of evaluating peristaltic disorders of the stomach, which was afforded by this CT technique, in contrast to

the standard method relying on measuring only the thickness of the stomach wall. Dynamic MHCT enabled us to reveal seven of nine (85%) cases of early GC owing to the characteristic contrast between the mucous and submucous layers and peristaltic disorders without the stomach wall thickening. But it is fair to say that, at present, MHCT is inferior to the conventional endoscopic examination in revealing early GC.

The progress in computer technology led to the fact that virtual simulation is finding an ever wider application in different fields of surgery and oncology [6]. Our study demonstrated the possibilities of such simulation as applied to the construction of virtual gastroscopy. A high-quality virtual image not inferior to that acquired with conventional videoendoscopy was obtained in the case of intraluminal character of neoplastic growth [7, 9]. As it follows from the literature data, virtual endoscopy is not surpassed by conventional endoscopy in terms of its diagnostic possibilities of tumor detection and is more informative than planar slices, especially when the invasion depth is small (T2 and especially T1). Nevertheless, it is fair to say that now virtual endoscopy cannot be considered a real alternative to conventional videoendoscopy as a method of primary diagnostics of GC. At present, the possibilities of the wide application of the complex of CT techniques for differential diagnosis of benign and malignant ulcers with negative results of biopsy are also doubtful, although the first reports are highly encouraging [11]. In our opinion, the use of endo-ultrasonography and laser fluorescence spectroscopy (the so-called optic biopsy) is more justified for these purposes. Virtual simulation extends the possibilities of the method and allows for a more accurate choice of the target zone for a thorough study of the stomach wall with a view to specifying the depth of malignant invasion. However, the rapid progress of computer technology and software will possibly allow us to consider the complex of CT studies, including those in the virtual endoscopy mode, a screening technique in the countries with a high morbidity rate [7, 9]. At present, MHCT has found wide application in various diseases of the organs of the abdominal cavity, retroperitoneal space, and vertebral column. Therefore, we think that the use of such a method for an additional examination of the stomach in the group at higher risk not only for cancer but also for CT study of the organs of the abdominal cavity for other diseases with a view to detecting changes seems to be interesting and promising.

5. Conclusion

Fluorescent diagnostics with the study of Alasens-induced protoporphyrin IX is a highly efficacious, simple, and safe method for diagnosing GC. It can be used as a standard step of endoscopic examination in diagnostically complicated cases. The sensitivity of the method is 96%; its specificity is 98%.

The method for detecting videofluorescence with Alasens is a promising screening technique in patients with GC and in precancerous states.

Trans-ultrasonography is a potentially screening method in distal localization of GC. The possibility of detecting GC localized in the pyloroantral division and in the lower third of the

body of the stomach using complex trans-ultrasonography was 95.6% attaining the absolute values in the T3 and T4 groups.

Dynamic MHCT is a highly informative method for cancer detection. The possibility of revealing cancer did not depend on the tumor localization and constituted 97% in the group of patients attaining absolute values, beginning with T2 invasion depth.

Indications for use of virtual endoscopy, one of the MHCT modes, as a method for the primary diagnosis of GC and for screening the disease require further study and specification.

Modern ultrasound and CT technologies allow us not only to stage GC but also to carry out primary diagnostics. However, the technical complexity and the high cost of CT, and the impossibility that cancer of the proximal division of the stomach will be detected ultrasonographically do not allow us to regard them as full-fledged screening techniques. Laser spectroscopy is indicated only in diagnostically difficult cases, and videofluorescent diagnostics requires higher performance, after which it may rightly be considered a recognized screening method.

Author details

Vladimir Levkin^{1*}, Nina Gagarina¹, Sergey Kharnas¹, Gaziya Musaev¹, Artem Shiryaev¹ and Dmitry Bulgin²

*Address all correspondence to: doctor-levkin@mail.ru

1 Sechenov First Moscow State Medical University, Moscow, Russia

2 Center for Regenerative Medicine "ME-DENT", Rovinj, Croatia

References

- [1] Davydov MI & Aksel EM. The incidence of malignant tumors and mortality caused by them in Commonwealth of Independent States in 2005. *Vestn Ross Akad Med Nauk*, 2007,11:45–49.
- [2] Portnoi LM. Modern X-ray diagnostics in gastroenterology and gastroenterooncology. Moscow, Vidar-M, 2003.
- [3] Polsachev VI. Preoperative fluorescent diagnostics of the prevalence of gastric cancer. *Vestn Khirurg*, 1989,12:17–19.
- [4] Polsachev VI. Fluorescent method in the differential diagnosis of benign and malignant diseases of the stomach. *Vestn Khirurg*, 1992,1:95–97.

- [5] Gorovaya NS. Role of complex US examination in the surgical treatment of gastric cancer patients. Cand. Sci. Dissertation (Med.), Moscow, 2009.
- [6] Fedorov VD, Karamazovskii GG, Guzeeva EB & Tsvirkun VV. CT-based virtual surgical simulation. Moscow, Vidar-M, 2003.
- [7] Kim JH, Eun HW, Choi JH, Hong SS, Kang W & Auh YH. Diagnostic performance of virtual gastroscopy using MDCT in early gastric cancer compared with 2D axial CT: focusing on interobserver variation. *AJR Am J Roentgenol*, 2007,189(2):299–305.
- [8] Chen F, Ni YC, Zheng KE, Ju SH, Sun J, Ou XL, Zhang H & Marchal G. Spiral CT in gastric carcinoma: comparison with barium study, fiberoptic gastroscopy and histopathology. *World J Gastroenterol*, 2003,9(7):1404–1408.
- [9] Kim JH, Eun HW, Hong SS & Auh YH. Early gastric cancer: virtual gastroscopy. *Abdom Imaging*, 2006,31(5):507–513.
- [10] Cidon E & Cuenca I. Gastric adenocarcinoma: is computed tomography useful in preoperative staging? *Clin Med Oncol*, 2009,3:91–97.
- [11] Chen CY, Wu DC, Kuo YT, Lee CH, Jaw TS, Kang WY & Hsu JS. MDCT for differentiation of category T1 and T2 malignant lesions from benign gastric ulcers. *AJR Am J Roentgenol*, 2008,190(6):1505–1511.

