

We are IntechOpen, the world's leading publisher of Open Access books Built by scientists, for scientists

6,900

Open access books available

185,000

International authors and editors

200M

Downloads

Our authors are among the

154

Countries delivered to

TOP 1%

most cited scientists

12.2%

Contributors from top 500 universities



WEB OF SCIENCE™

Selection of our books indexed in the Book Citation Index
in Web of Science™ Core Collection (BKCI)

Interested in publishing with us?
Contact book.department@intechopen.com

Numbers displayed above are based on latest data collected.
For more information visit www.intechopen.com



Auxiliary Procedures in the Nasal Skin

Guillermo Blugerman, Diego Schavelzon, Gabriel Wexler and Roberto Schale

Additional information is available at the end of the chapter

<http://dx.doi.org/10.5772/62067>

Abstract

Dermabrasion: This is a procedure that removes epidermis and superficial dermis in order to stimulate neo formation of collagen, elastic fibers, and vessels. **Radiofrequency:** The equipment can be regulated in ablative or nonablative (heat in dermis results in collagen fibers contraction) mode. The main effect is contraction and remodeling of collagen fibers. **Chemical peels:** Most used products are: retinoic acid, alpha hydroxy acids, trichloroacetic acid, phenol, and resorcinol. Superficial and mid peels are indicated in pigmented lesions and fine wrinkles. Deep wrinkles need a deep peel. **External nasal lifting:** As we age, flaccidity and solar damage in nasal skin turns the tip downward, and its classical correction (rhinoplasty) deepens the nasal dorsum wrinkles. Incisions and skin resection is planned in the nasolabellar area. **Subnasal lifting:** An open nasolabial angle creates disequilibrium between the lip and nose in the central face. A buffalo horn like resection in the implantation of the nasal ala in the lip solves this angle, restoring the loss balance. **Treatment of vascular lesion with luminic energy:** Here we present our experience with nasal vascular lesions in the last 15 years. **Treatment of nasal vascular lesions through thermocoagulation with radiofrequency:** This technique is indicated in vascular lesions smaller than 3 mm of diameter, and punctiform lesions as rubi nevus and telangiectasias. **Hair removal with LASER or IPL:** The hairs anagen period of the nasal tip and vestibule gets longer as people age, turning hair to be unaesthetic.

Keywords: Chemical peels, dermabrasion, external nasal lifting, gravitational wrinkles, IPL in nasal area, LASER in nasal area, minimal invasive nasal procedure, nasal aesthetics, nasal aging, nasal dressings, nasal hair removal, nasal tip ptosis, nasal vascular lesions, nasal wrinkles, nasolabial proportions, nonablative radiofrequency, phenol peel, radiofrequency in nasal area, selective photothermolysis, subnasal lifting

1. Introduction

With aging, the nasal skin suffers the same changes as the rest of the face skin. The fact that it is medial and projected over the frontal plane makes it more vulnerable to sun radiation, having a greater risk of photoaging, preneoplastic and neoplastic lesions. As years go by, skin loses collagen fibers, elastic fibers, and subcutaneous tissue, losing volume and support. In this chapter, minimal invasive procedures for the solution of nasal skin aesthetic issues will be presented.

Caucasian thin skin tends to develop wrinkles earlier, while thicker skins develop them later. Women's skin is thinner and that is why it looks older than in a man of the same age. Smoking and sun exposure are main factors that contribute to the early development of wrinkles and sulcus. The use of heavy glasses over a long period of time can lead to skin sliding off the nasal bridge, creating wrinkles over the lateral wall of the nasal pyramid. In some cases, the material of glasses has generated chronic dermatitis.

Basically there are two types of wrinkles:

1. Expression wrinkles
2. Gravitational wrinkles

Expression wrinkles originate in mimic muscles activity, especially those superficial ones with insertions in skin around lip and eyes. The sphincter muscles such as the orbicularis oculi and orbicularis oris have mainly skin insertions and have a major function in expressing anger, worry, concentration, and other moods.

Gravity forces in any part of the face form the gravitational lines. As time passes, skin gets loose, falling over the forehead, brows, lids, nose, cheek, and neck. There is an important individual variation during this process. In the presence of atrophied skin, the aging process is faster.

As a general rule, expression wrinkles can be treated through external softening procedures or BOTOX®, and gravitational wrinkles with suspension procedures, fillers, or external lifting. There is a great amount of fillers: autologous or heterologous, absorbable or permanent. To stimulate the production of collagen, elastic fibers, and vessels, the superficial excision of epidermis and dermis can be used, creating a controlled lesion, that when healed leaves a more juvenile skin. This can be done through mechanical, chemical, physical, or electrical methods.

2. Mechanical methods: Dermabrasion

Dermabrasion is a very well-known technique [1] that was initially used for the treatment of unaesthetic scars (accidents, surgery, acne) and dysplastic lesions [2]. This procedure can be done with electrical instruments with abrasive tips of diamond or steel that spin at high speeds (Fig. 2) or water sandpaper previously sterilized (Fig. 1).



Figure 1. Materials employed in manual dermabrasion (left).




Figure 2. Equipment for high-speed dermabrasion (right).

The results of dermabrasion are very gratifying and comparable to chemical or LASER abrasion (Fig. 3). It is important not be aggressive if inexperienced because deep abrasion leave unaesthetic scars. Most frequent complication is wound infection with bacteria or herpes, with which the wound deepens and permanent scars appear.

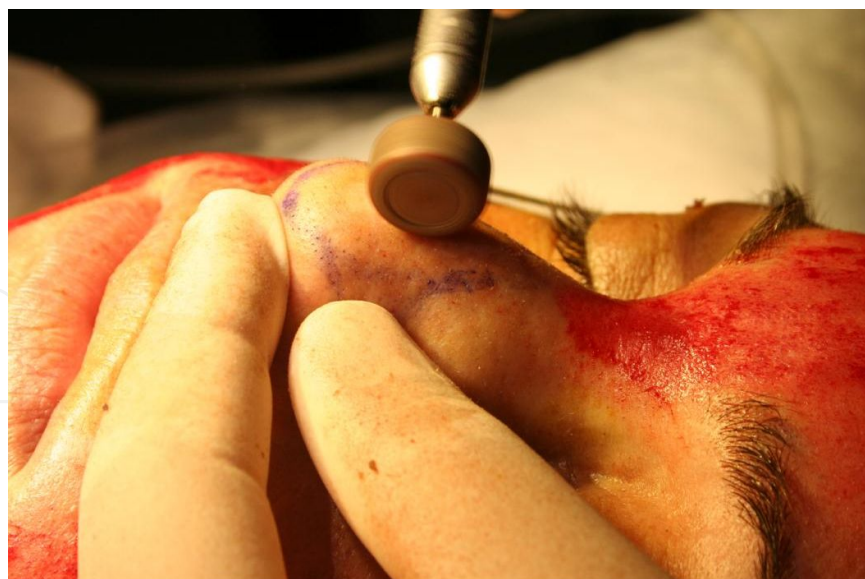

Figure 3. Dermabrasion with diamond tip.

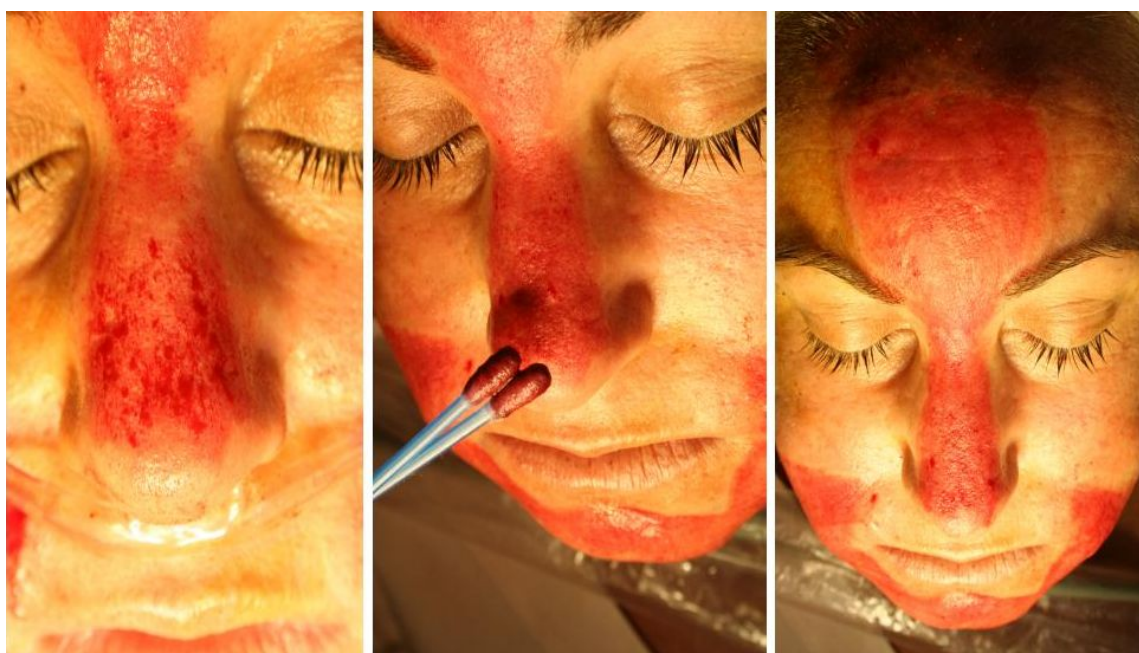

Figure 4. Blood bed and hemostasis after silver nitrate action.

In most patients, after dermabrasion we apply silver nitrate 10% over the blood bed. As a complement to the treatment, biologic dressings can be used as plasma rich in platelets (PRP), to avoid fluid loss and accelerate the healing process[3] (Figs. 4 and 5).

The procedure can be repeated after four to six months. This is the elective treatment in initial rhinophyma.

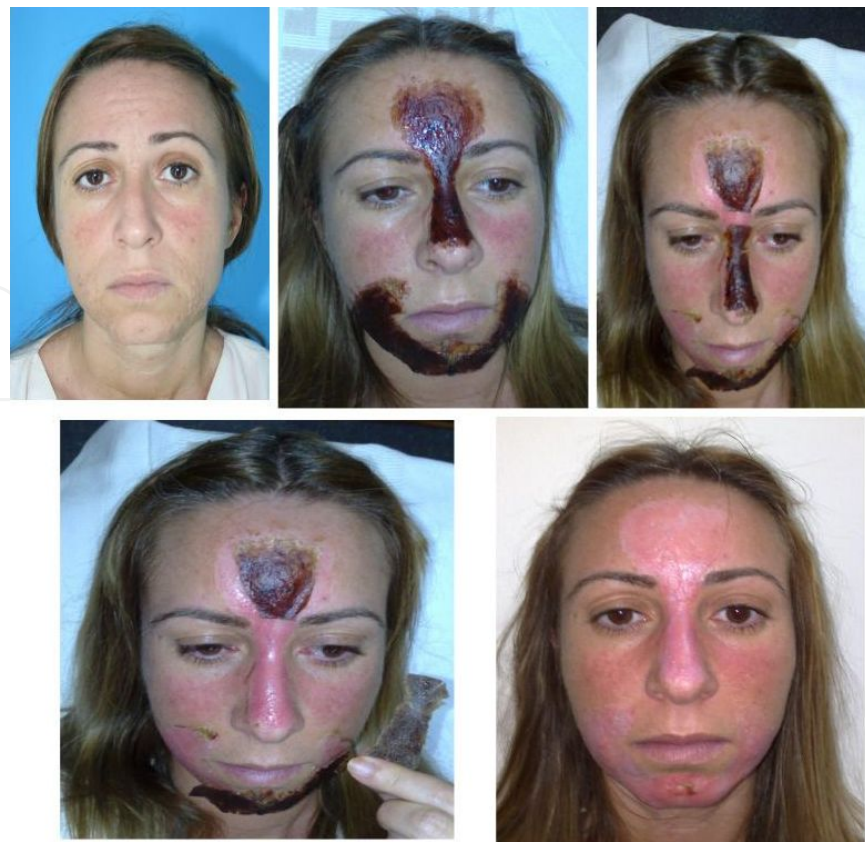

Figure 5. Preoperative, and process until the elimination of crusts left by silver nitrate.

3. Electric methods: Radiofrequency

For treatment with radiosurgery, an electronic transistorized device that produces radiofrequency waves is used [4]. This can be regulated to produce an ablative or nonablative treatment (a selective heating of the deep dermis promoting collagen fibers contraction). For the ablative treatment, we use a Surgitron 4.0 MHz of Ellman equipment with special needles and hand piece that adapt to the defect we need to correct. For the nonablative treatment, we use a Radiage hand piece, allowing us to stretch the skin without surgery (Fig. 6).

The most used radiofrequency nonablative treatment is done with Thermage equipment that produces monopolar capacitive radiofrequency. This system produces:

- Collagen fibers' immediate contraction
- Long-term collagen remodeling
- Controlled volumetric heating of tissue
- Simultaneous hand piece cooling, which protects epidermis
- Control of the heating deepness in dermis
- Possibility of normal life after the procedure



Figure 6. Ellman radiofrequency equipment.

The size and characteristics of the hand piece make its use in the nasal area difficult but using in the neighboring skin, a tightening effect is obtained in the nose.

Another equipment with which we have a positive experience is Accent of Alma Lasers that allows monopolar and bipolar modes, and has hand piece more adequate for the nose.

4. Chemical methods: Chemical peel

There are many ways to stimulate skin regeneration with acids. Taking into account the deepness of the lesions we need to treat, we choose different products to obtain a superficial, mid, or deep peel. Most used products are:

- Retinoic Acid, synthetic derived of vitamin A
- Alpha hydroxy acids, found in milk, fruits, and sugar (glycolic acid)
- Trichloroacetic acid (TCA)
- Phenol, in different concentrations

- Resorcinol

Superficial and mid peels are useful for treating pigmented lesions and fine wrinkles of the nasal dorsum and tip, but in the presence of deep wrinkles a deep peel is needed.

Baker-Gordon [5] formula with phenol has been the most popular deep peel in the world, but the solution instability has the risk of provoking vicious scars. That is why we prefer a commercial formula known as Exoderm [6]. This formula, created by Yoram Fintsi [7] is a modification of the Baker formula with a neutralization system. In this way, it does not transgress the basal membrane of the skin, having lesser chances of heart or kidney toxicity (Fig. 7). The formula is composed of:

- 1 ml. of liquid phenol 91%
- 1 ml. of crystal phenol 99.5%
- 2 qt. of croton oil
- 10 qt. of hexachlorophene
- 0.3 ml. of resorcinol
- 0.3 ml. of salicylic acid
- 0.5 ml. of stiller water
- 0.5 ml. of a mixture of olive oil, glycerin, ethanol, and sesame oil
- 10 ml. of hydroxymethyl aminomethane as buffer




Figure 7. Commercial presentation of exoderm.

The principal indications are:

- Photoaging wrinkles
- Frown lines
- Acne scars
- Scars

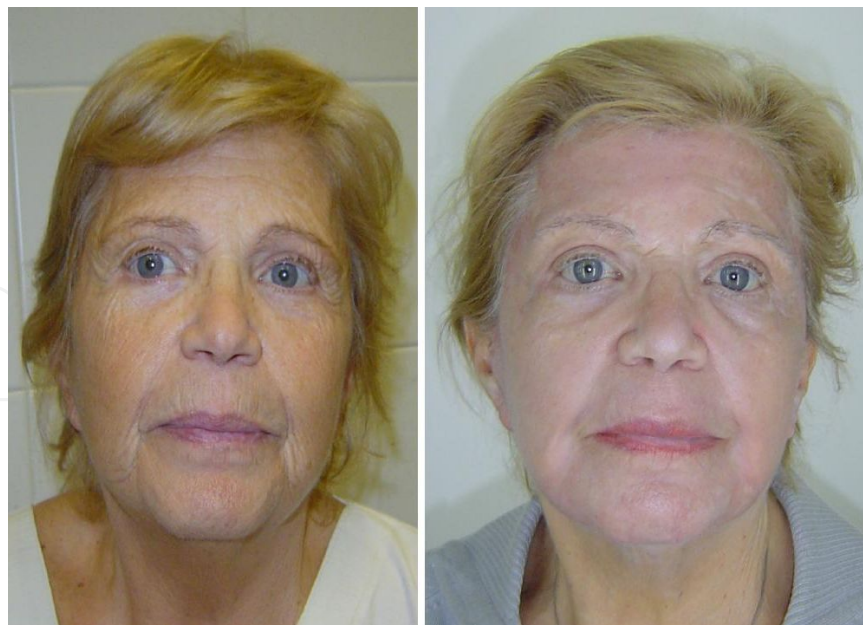

Figure 8. Pre- and postexoderm treatment.

- Pigmented lesions and keratoacanthoma
- Rhinophyma

It is fundamental to clean the skin with acetone before applying phenol to remove the skin's sebaceous content. Sedation is recommended to avoid the burning sensation. When treating the frown, nasal dorsum or tip, we must include the entire aesthetic unit. Usually, we apply the product and wait for the frosting effect, which indicates epidermal proteins denaturing. Then we evaluate if more product is needed in the entire area or just deeper lesions. The treated area can be left open in contact with air or with an occlusive bandage. If the last is done, it has to be removed the next day. After this, we use a bismuth-based healing powder, which forms a green crust that adheres to the area for approximately seven days. On day six, the patient must start using liquid vaseline to remove the crusts.

If the indication was appropriate and the procedure correctly done, positive results are expected (Fig 8). Erythema can last for eight weeks and in white skins or atrophied skins even longer. Labial herpes, heart arrhythmia, and kidney failure are absolute contraindications for this procedure. The most frequent complications are milia (a very marked line between treated and untreated skin), hyperpigmentation, hypopigmentation, and labial herpes.

5. External nasal lifting

When the skin quality, laxity, or nasal deformity cannot be corrected with the exposed methods, a surgical external nasal lifting is needed. Aging in the face affects each and every aesthetic area [8]. The central situation of the nose in the facial frame and its importance in the facial profile make it a subject of frequent consultation in patients seeking rejuvenation.

In the nose, skin alterations caused by the lack of elasticity, excessive looseness, and solar damage, causes an increase in the length of the cutaneous coverage resulting in tip ptosis. These patients, generally over their seventies, have an inelastic skin with horizontal wrinkles in the nasal bridge and lateral walls. By placing with our fingers the tip in the right position wrinkles deepen and increase significantly. In these cases, suspension techniques or fillers are useless to solve the problem. For this reduced amount of patients, in which the noninvasive procedures have poor results, we recommend the external nasal lifting, using techniques previously described for reconstructive procedures [9].

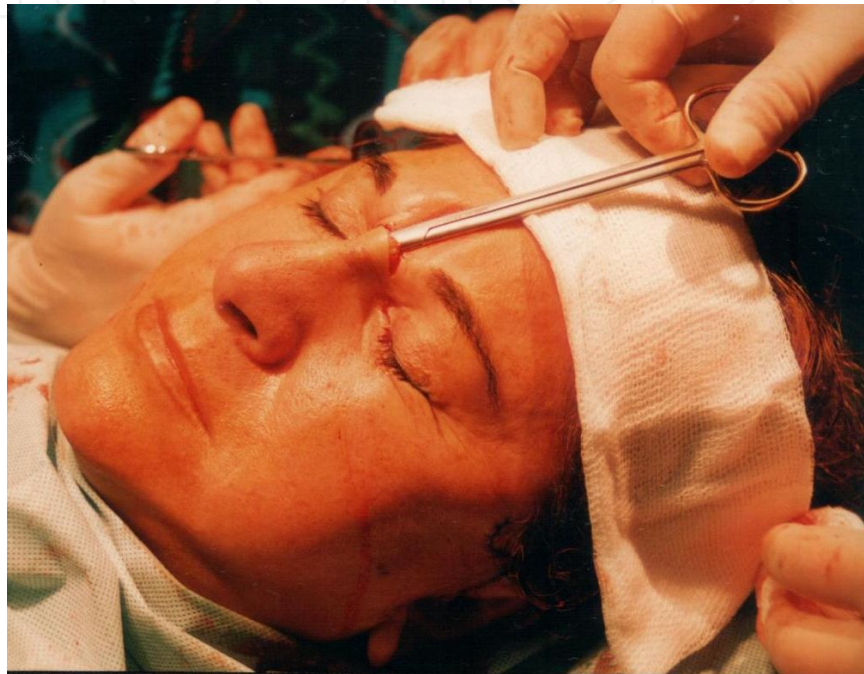

Figure 9. Picture of external nasal lifting surgical procedure.

5.1. Patient selection

The ideal candidates for this procedure are those with nasal tip ptosis caused by excessive skin looseness. These patients have usually important photoaging and are in their sixties or seventies.

5.2. Procedure

The main objective is to produce a shortening of the nasal length by resecting a block of skin over the nasal SMAS [10]. First, the skin to be removed is marked in ellipsoidal or inverted U form in the nasal bridge dorsum at the level of the medial canthus. Local infiltration is done with 1% Lidocaine with 1:100000 adrenalin in the nasal dorsum and the depressor septi nasi. The marked skin is resected respecting the SMAS plane [11]. After that we elevate a SMAS flap with inferior pedicle and we dissect below it until reaching the supratip area (Fig. 9). The SMAS flap is fixed to the periosteum of the nasofrontal joint with Nylon 5-0. Hemostasis is done.

Closure is done deep with separated stitches of Monocryl 4-0 and superficial with a continuous intracuticular suture with Monocryl 4-0. Finally, to reduce the risk of relapse, a myotomy of the depressor septi nasi is done through a small incision in the nasal vestibule or through an intraoral approach [12, 13].

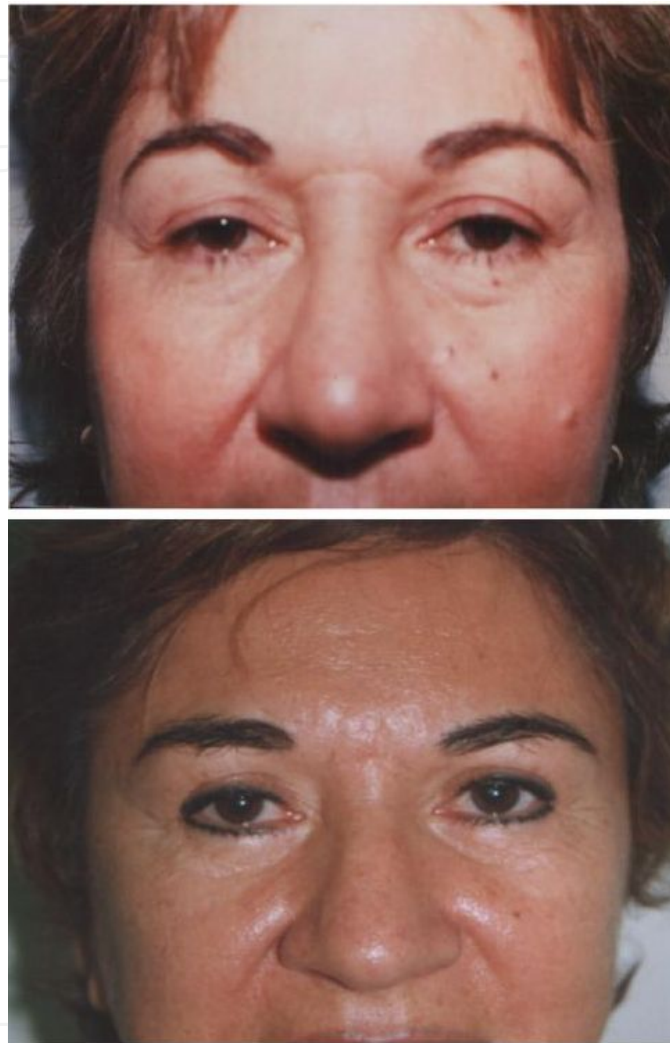

Figure 10. Before and after (8 years) external nasal lifting through previous scar. Frontal view.

We use occlusive bandage with micropore tape and thermomoldable plastic.

In general, the scar is acceptable from the aesthetic point of view and patients have a high degree of satisfaction with the procedure.

5.3. Conclusions

Nasal external lifting is a minimal invasive procedure, easy and fast to execute, without major complications. The combination with other facial rejuvenation surgical procedures does not increase significantly the surgical times (Figs. 10 and 11).

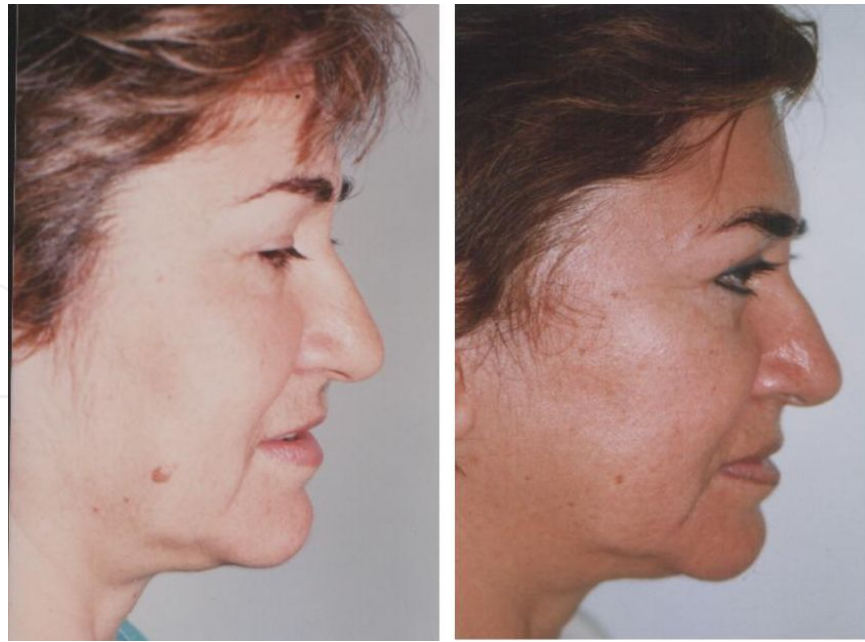

Figure 11. Before and after (8 years) external nasal lifting through previous scar. Lateral view.

6. Subnasal lifting

A over-open nasolabial angle creates disharmony between the nose and the lip, generating an unaesthetic appearance of facial features. For patients with this problem we use the subnasal lifting technique, a simple, minimal invasive procedure and one of rapid recovery. It can be done under local anesthesia, reducing the nasolabial angle (treating the depressor septi nasi), shortening the upper lip, and the vermillion is everted. A great number of men request for this surgery.

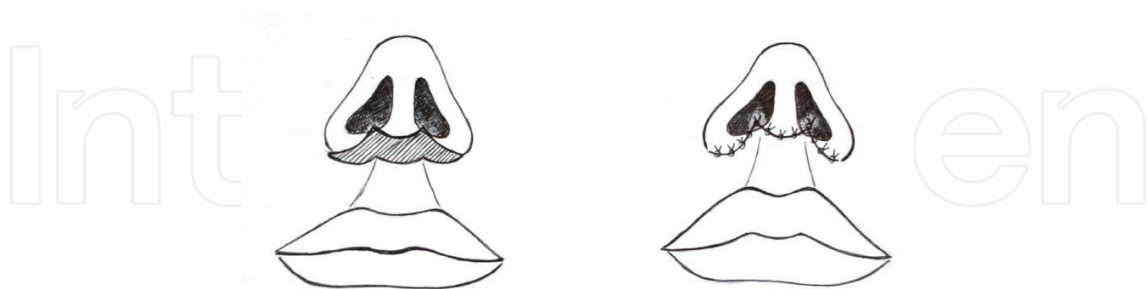


Figure 12. Buffalo horn design for skin resection.

Marking is in the form of a buffalo horn and it must be kept inside the external limit of implantation of the nasal ala to avoid visible scars (Fig. 12). Local anesthesia is done through infiltration with 1% lidocaine with adrenalin 1:100000. The resection is done following the markings, as in Fig. 13. Skin and subcutaneous tissue are resected, taking care, mainly in men, not to leave follicular units of the mustache to avoid future cystic lesions. The depressor septi

nasi is treated under direct vision according to their strength, by complete or partial resection. Hemostasis is done. Skin is closed with deep and superficial stitches of Monocryl 5/0. Micro-pore tape is applied. Even when this technique acts mostly in the upper lip, the effect is also seen in the nose, creating a new nasolabial balance (Figs. 13 and 14).

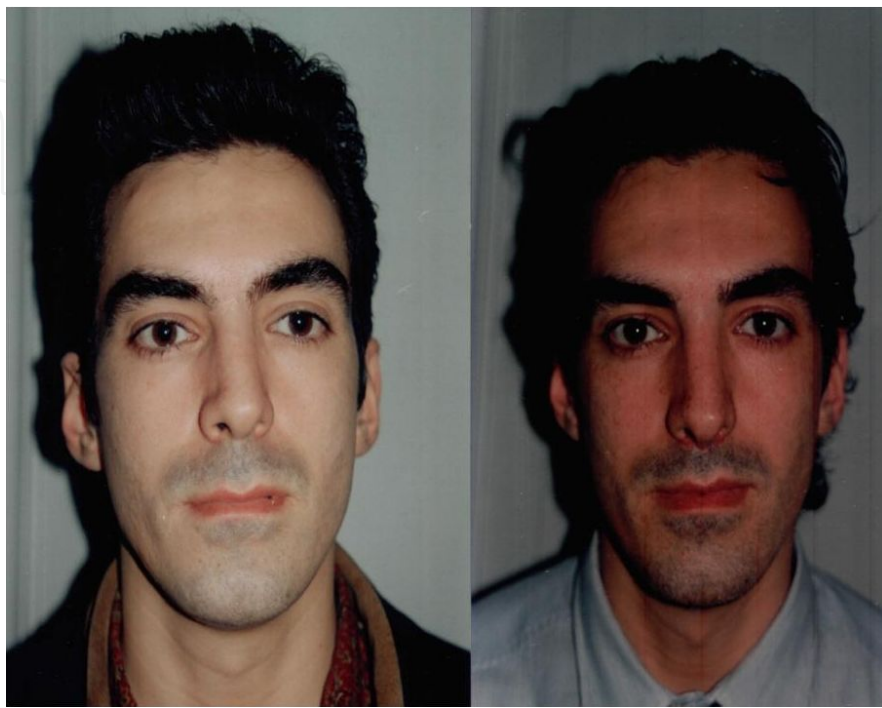

Figure 13. Before and after subnasal lifting. Frontal view.

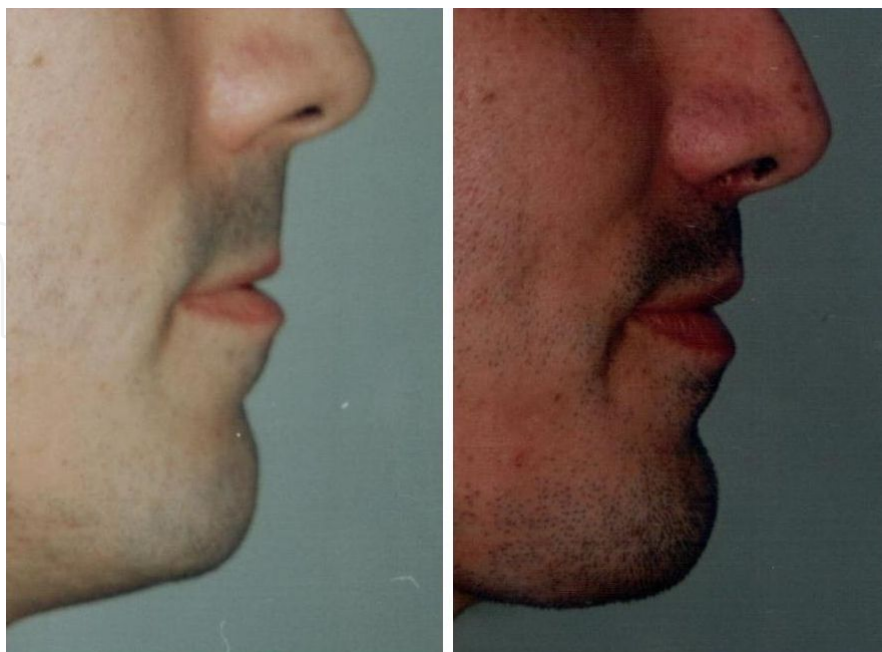

Figure 14. Before and after subnasal lifting. Observe the nasolabial angle.

7. Treatment of nasal vascular lesions with luminous energy

7.1. Introduction

Nasal vascular lesions are a common cause of consultation in a plastic surgery clinic. For their study, a complete clinical history is important to make the correct diagnosis and, subsequently, the correct treatment. The population that requests the removal of these lesions is growing, so we must select the best method available to minimize side effects. Nowadays, the most used methods for the treatment of these lesions are radiofrequency and luminous energy.

Vascular lesions are classified into:

- Congenital:
 - Hemangioma
 - Venous malformations
 - Port wine stains or nevus flammeus
 - Lymphangiomas
- Acquired:
 - Telangiectasias
 - Venous lakes
 - Poikiloderma
 - Cherry angiomas
 - Pyogenic granuloma
 - Rubi nevus
 - Kaposi sarcoma
 - Unspecified erythema
 - Rosacea

In general, congenital lesions have origin in vascular endothelium, arterial, venous, capillary, or lymphatic. Most frequent locations are face, neck, and extremities, but it can be located in any part of the body. They are noticed at birth or in the first weeks of life and suffer involution during childhood.

Acquired lesions are vascular dilatations, usually venous, frequently localized in face and lower extremities. There are important factors that predispose to nasal vascular lesions:

- Genetically predisposed
- Solar chronic damage
- Trauma

- Chronic treatments with steroids
- Pregnancy
- Infections
- Alcohol
- Estrogen supplements
- Rosacea

Different equipments are used according to the origin, nature, location, size, and depth of the lesion. It is important to know the working principles of these equipments in order to take the best advantage possible of them.

7.2. Luminous emission physical principles: History

Two centuries ago, only luminous emission was known. Physicists such as Newton were the first to recognize the wavy characteristic of light. Years later, they discovered that different colors corresponded to different wavelengths. In 1903, N.R. Finsen was awarded the Nobel Prize for the treatment of vulgar lupus with ultraviolet light, initiating a new field in medicine: Photomedicine. The work published by Einstein in 1917 about the controlled management of light waves was the fundamental knowledge for working with LASERS. It was not until 1933 with the discovery of optical fiber that scientists started working in microwave amplification. In 1951, this technique was patented by Fabrikant, a Russian physicist, and the year after the first equipment was built called MASER (microwave amplification by stimulated emission of radiation). In 1958, Schawlow and Townes [14] published their work in microwave amplification by stimulated emission of radiation bringing two new concepts: monochromatic light and coherent light. In 1960 [15], the first Ruby LASER was installed in the Cincinnati University. The first medical use of LASER was in ophthalmology. From there it had an exponential growth, reaching almost every field in medicine, with a great variety of equipments with different wavelength, frequency, and energy.

7.3. Physical aspects of light and LASER radiation

The transportation of energy in the form of particles generates waves with an electrical component and a magnetic one, resulting in electromagnetic radiation [16]. As these particles vary in their energy load, they have different wave length and frequency, thus completing the electromagnetic spectrum. Light is not more than electromagnetic radiation, transmitted by particles called photons, in the visible emission spectrum that has a wavelength between 300 and 700 nm.

The luminous system includes radiation with a wavelength between 200 and 1000000 nm, from ultraviolet to infrared. Most part of the radiation comes from the sun. So, radiation can be either natural (solar radiation) or artificial (LASERS and lamps). Both have emission in ultraviolet, visible, and infrared spectrum. The emission process can be coherent (LASER) or not coherent (solar light, lamps, LED).

7.4. LASER radiation

The word LASER [17] is an acronym of light amplification by stimulated emission of radiation. The characteristics of this light emission are: coherence, monochrome, directionality, intensity, and polarization. Basically, a LASER is composed by an energy source, an active medium whose molecules are excited (solid, liquid, or gas), and an amplifying system. The LASER is named after its active medium:

- Gas: CO₂, argon, He-Ne
- Solid: Er:YAG, Nd: YAG
- Liquid: colorants
- Semiconductors: diode

Reflecting surfaces, as mirrors, which have a multiplicative effect and direct photons, compose the amplifying system.

7.5. Effects of light emission in tissue

According to Grothus-Drayer law, the tissues are affected when they absorb the light, transforming it into thermal and biochemical energy. There is a long list of published investigations about the interaction between light and tissues. From the optical point of view, tissues are heterogeneous, so five effects can occur when an electromagnetic light hits them:

- Reflection
- Refraction
- Transmission
- Dispersion
- Absorption

There is a great variation in medical application of LASERs because many different structures can be aimed with different equipments. There are some mathematical models that try to predict the light distribution among tissues. One of these is the Kubelka-Munk model, which provides information regarding the percentage of absorbed energy in different depth of tissue, according to tissue composition, attenuation coefficient, and absorption and dispersion phenomenon. These measurements and parameters are the fundamentals of selective photothermolysis and absorption of cellular photoreceptors.

7.6. Selective photothermolysis

In 1983, Anderson and Parish [18] discovered the light selective destruction of a structure known as chromophore or target, with minimal effects in neighboring tissue. This is based on the Thermal Relaxation Time, that is, the time necessary to reduce by 50% the maximum temperature obtained in the destruction of the structure. The effects will depend on the interaction of the following factors:

- Wavelength
- Exposition time
- Fluency (or energy density)

This mechanism is the foundation for the treatment of different lesions: pigmented, vascular, tattoos, tissue renovation, cutaneous remodeling, and hair removal. Through specific chromophores, as melanin and oxihemoglobin, light is absorbed provoking radical changes in tissue. The luminous effects can be classified in four groups:

- Electromechanic or photoacoustic: photodisruption
- Photoablation, mainly used in ophthalmology
- Thermal, vaporization, and coagulation, most known and used
- Not thermal

Not all LASERs can produce these effects, and some noncoherent light sources, such as intense pulsed light (IPL), can produce some. Up to here, we have resumed the common characteristics of light emission equipments, coherent and noncoherent. Also the physics behind the LASER has been exposed in order to know which equipment to use according to the lesion structure that is being treated. In our practice, we have these equipments since 1998; in this chapter, we will share our experience in the treatment of nasal vascular lesions with:

- Deka Smartepil Nd YAG 1064nm
- Polaris Syneron Diodo 780–980 nm combined with radiofrequency
- Fotona XP Max Nd YAG 1064nm

The nasal vascular lesions that we have treated in the last 15 years include: plane angioma (cavernous, lobular, senile, serpiginous), facial telangiectasias, erythema, rosacea, and rubi nevus. A detailed clinical history is done taking into account the following:

- Type of lesions
- Phototype
- Localization
- History of the lesions
- Personal history
- Family history
- Medication
- Previous treatments
- Type of skin
- Pictures of the lesions

- Extended explanation of possible complications of the treatment
- Informed Consent

7.7. Technique

The preparation for the treatment is common for any equipment. Pictures of the area are taken. The equipment is programmed with the correct parameters to treat a specific lesion. Both, the patient and the doctor, must wear protective glasses.

For the treatment of nasal telangiectasia small spot LASERs are preferred; with IPL it is harder to adapt the hand piece to the treatment. It is important to check after the first shot the response in the vascular walls and skin covering the vessel. According to that response, parameters are adjusted in order to obtain the best result with least collateral damage. Cooling the skin is not recommended because it causes vasoconstriction, removing oxihemoglobin (the aimed chromophore) from vessels (Fig. 15). This is a very extensive mistake, and we think it is because doctors or technicians use the same methodology as for other applications (hair removal, facial rejuvenation, tattoo removal) with fixed chromophores (melanin, ink) in which cooling is very effective in reducing pain and side effects. Once finished with the treatment, an immediate effect is observed; this percentage of improvement is written down in the clinical history, together with the equipment used and the parameters.

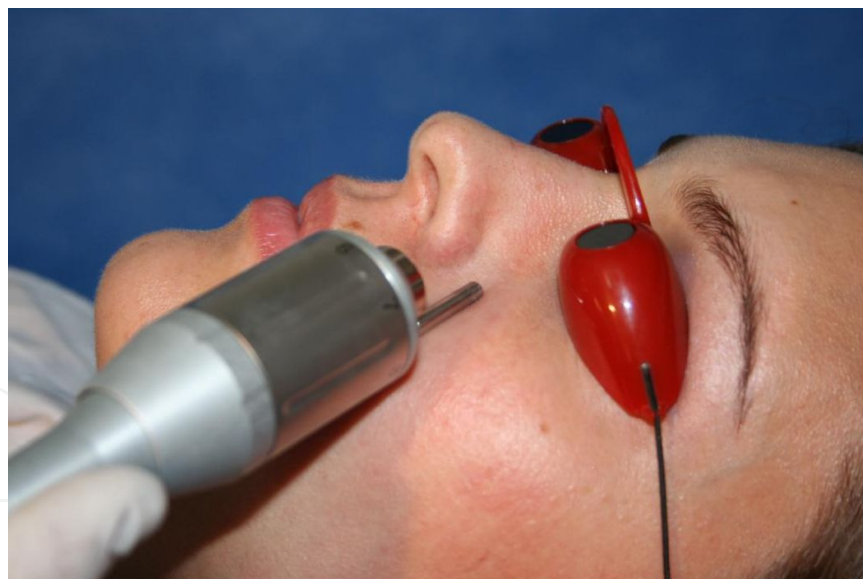


Figure 15. Nd:YAG LASER in nasal telangiectasia.

7.8. Parameters

According to the device equipments characteristics and the treatment to perform, they are used with different forms of energy, fluency, and pulse duration. The equipments we will discuss are the ones we have been using in the last 15 years, and the parameters are useful just for

reference since each patient has a different requirement. The following data are for nasal telangiectasias. It is important to know, as treatment background, that limits of oxyhemoglobin absorption are between 418 and 577 nm, with a pulse duration of 10–20 ms.

7.8.1. Deka Smartepil II

With this equipment, there is a great variety of spots, we generally use a 2 mm one, wavelength of 1064 nm, maximum energy of 150 J/cm², pulse duration of 16 msec, with time between pulses up to 300 msec. Up to 7 mm spots can be used that allow higher fluency up to 200 J/cm², but in this area of the face we do not recommend it.

7.8.2. Polaris Syneron ELOS

This is the only equipment, in our practice, that allows luminous energy treatment simultaneously with radiofrequency. Its power source is a diode, which produces a wavelength between 780 and 980 nm. Luminous energy can be used between 10 and 140 J/cm², and radiofrequency between 10 and 100 J/cm² with a spot of 5 x 5 mm.

7.8.3. Fotona XP II

This is an Nd-Yag LASER, with a wavelength of 1064 nm, maximum energy of 120 J/cm², pulse duration between 5 and 200 msec, and a 20 mm spot. This is the same equipment as for endolaser treatment of varicose veins (Fig. 16).

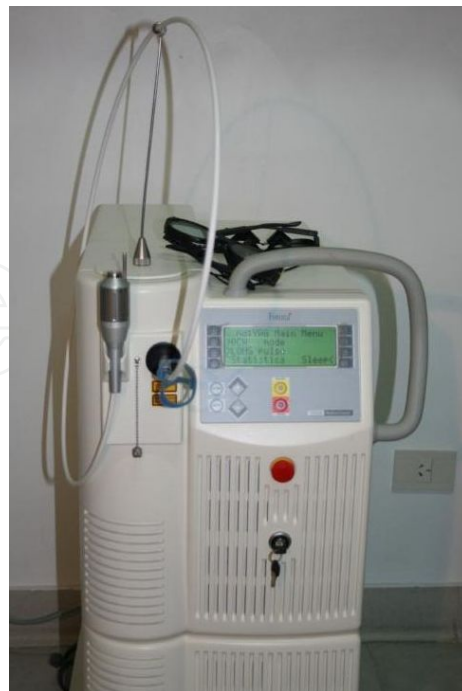

Figure 16. LASER FOTONA XP.

After the treatment is finished, cooling of the skin is done with ice or gel packs for a few minutes.

Apart from the mentioned equipments, there are others with the ability to produce selective photothermolysis:

LASER type	Wavelength in nm
Argon	488–514
Copper vapor	578
Krypton	568
KTP	532

7.9. Posttreatment indications

Indications and precautions are common for most equipments. Erythema can be experienced in the first hours and cooling devices usually solve it. The treated area should not be exposed to sun light, and tanning beds are forbidden for ten days after the treatment. Solar protection factor (SPF) over 40 should be used. If the patient has not experienced any complications, the treatment is repeated after day 21 until erasing of the lesion.

7.10. Side effects and complications

Complications of this treatment almost never end in permanent sequel. The most frequent side effect is erythema, which usually lasts between 6 and 48 hours after the treatment, disappearing spontaneously.

Vesicles of 1–3 mm can appear in the treated area; this is because vessels are very superficial, thus transmitting heat to the skin, or responding to an excess in the energy used. They usually heal spontaneously in few days. Steroid healing creams are recommended and sun exposure is forbidden.

The most serious complications are hypertrophic scars and keloids, but in the nasal area atrophic and hypopigmented scars are more frequent.

In the last years, there has been an important reduction of complications rate due to a better knowledge of this technology and of the biological response to it.

Prevention is essential: correct patient choice, avoiding tanned skins, complete knowledge of the equipment, and periodical equipment technical services. Constant training is necessary for personnel using the equipments. Following these principles, complications are reduced to a minimum, and the treatment turns safe and efficient.

Absolute contraindications for this treatment are:

- Photosensitivity
- Anticoagulation

- Low platelets level
- Convulsive syndrome triggered by light
- Treatment with photosensitive drugs
- Phototype VI of Fitzpatrick

7.11. Conclusions

The technical advances in LASER technology have made possible the treating of most skin vascular lesions. With the increase in energy density, wavelength, exposition time, the association of these parameters, and the added effect of radiofrequency, these equipments are entering every field of medicine. Constant training is needed in order to apply new technologies with a safety margin for patients.

8. Definitive hair removal with laser or IPL

The follicular units of the nasal tip have an anagen period that enlarges with age, thus growing a thicker hair as the years go by. The same occurs with hair in the nasal vestibule, which is highly unaesthetic. Changing some parameters in the mentioned equipments, melanin can be aimed as chromophore. So, based on the selective photothermolysis principle, follicular units from the nasal tip, ala, and vestibule can be eliminated. Five to six sessions with a 45–60 days interval are needed in order to obtain a permanent reduction in the number of active follicles using LASER or IPL. The patient should not be tanned during the treatment in order to avoid burns and hypopigmentation.

9. Radiofrequency thermocoagulation of nasal vascular lesions

Radiofrequency (RF) is another type of energy that has been used to alter skin connective tissue. Its use in medicine has a history of more than 70 years, but recent equipments can deliver the energy selectively to the deep dermis and subdermis. In the late 1990s, equipments were adapted for skin ablation, generating plasma at different deepness of skin. Recently, this technology was reconfigured for nonablative use in aesthetic medicine. The impact of RF on skin depends on the tissue impedance (Ohms), the RF power (Watts), the exposition time (seg), and the electrode configuration.

The radiofrequency thermocoagulation technique allows erasing vascular punctate lesions smaller than 3 mm such as Ruby nevus, cuperosis, small varicose lesions, and telangiectasia. The treatment is based on the thermal effect of a high-frequency wave that is focused in a fine needle. The varicose lesion disappears instantly, leaving a wheal that is replaced later by crusts. A disposable Teflon-coated nickel or gold needle of 0.075 mm diameter is used (Fig. 17). This reduces chances of allergic reactions, and thermal diffusion.

The treatment can be performed in a private office; it usually lasts for 15–10 min, and the posttreatment indications are similar to the ones mentioned for LASER. Topical anesthesia creams or cooling devices can be used in order to reduce pain during the procedure.



Figure 17. Needles used for radiofrequency cauterization of nasal telangiectasia.

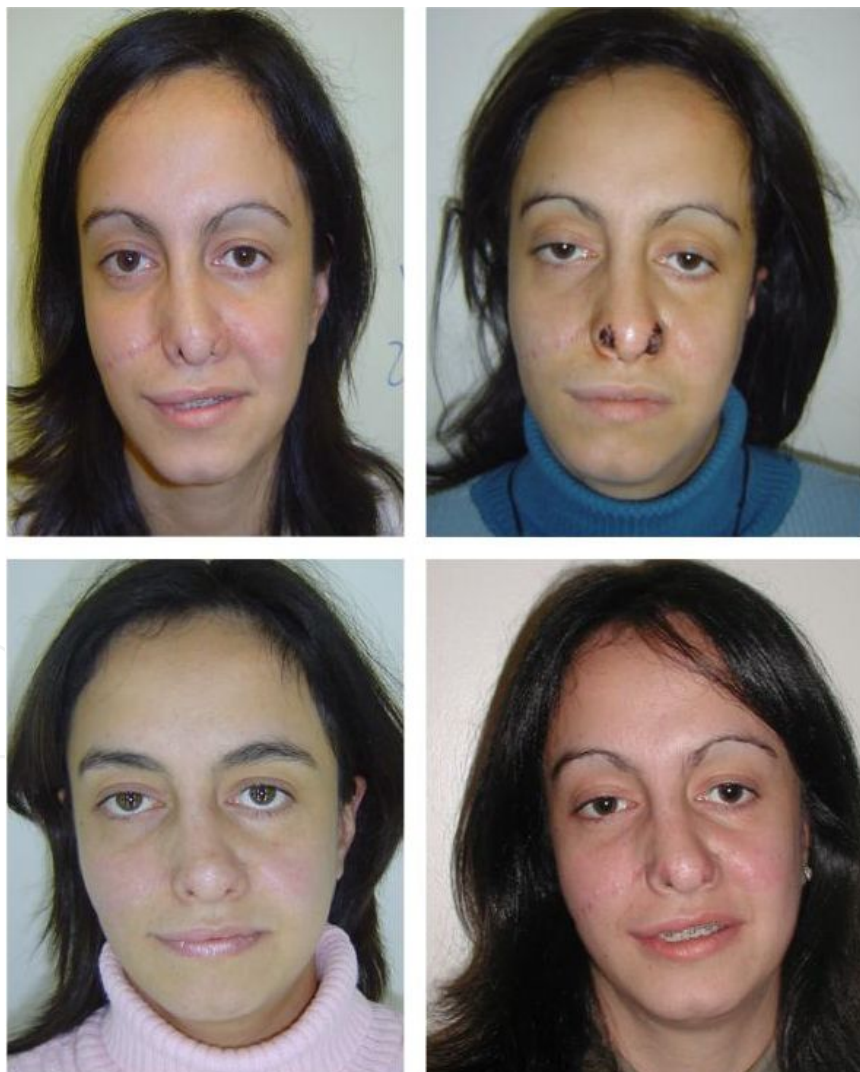

Figure 18. Before and after various auxiliary procedures for treatment of accident sequels.

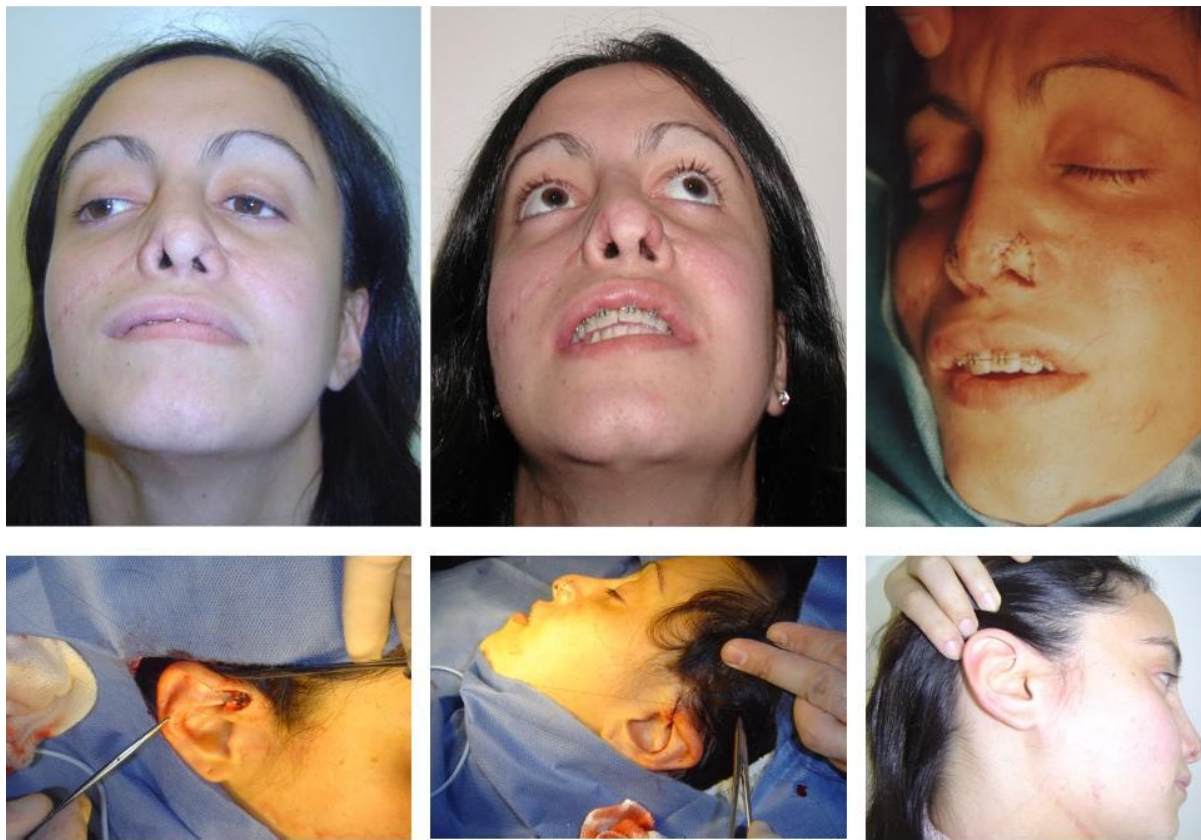

Figure 19. Nasal ala reconstruction with auricular compound graft, complemented with dermabrasion and PMMA.

Thermocoagulation is a safe technique that selectively delivers energy to the vascular lesion, preserving the epidermis. This procedure can be done in every season, in any kind of skin, is not painful, and does not require posttreatment bandages. The only drawback is that in every site treated the patient will have for some days a crust, and for some patients this is socially unacceptable. Effectiveness is seen in the first session (Figs. 18 and 19).

Author details

Guillermo Blugerman^{1*}, Diego Schavelzon¹, Gabriel Wexler² and Roberto Schale¹

*Address all correspondence to: blugerman@centrosbys.com

1 Plastic Surgery Department of Centros ByS, Centros B&S de Excelencia en Cirugía Plástica, Argentina

2 Universidad Nacional del Nordeste, Argentina

Conflict of interest: none. Authorized consent was obtained from the patients included in the chapter.

References

- [1] Petres, J., Rompel R., Robins P. *Dermabrasion. Dermatologic Textbook and Atlas Surgery*. Berlin, 1996. Springer. pp. 39-41.
- [2] Horibe E.K. *Estética Clínica y Quirúrgica*. Rio de Janeiro, 2000. Revinter: pp. 77-83.
- [3] Blugerman G. Utilización de Plasma Rico en Plaquetas como curativo de la Dermabrasión Quirúrgica, In: *Procedimientos Estéticos Mínimamente Invasivos* Coor. Charles Yamaguchi, Sao Pablo, 2006 Editorial Santos. pp.173-182
- [4] Filippo Alexandre. Radiofrecuencia, In: *Procedimientos Estéticos Mínimamente Invasivos* Coor. Charles Yamaguchi. Sao Pablo, 2006 Editorial Santos. pp. 273-274.
- [5] Baker T.J. Chemical face peeling and rhyectomy. *Plast Reconstr Surg Transplant Bull*. 1962;29:199-207.
- [6] Schavelzon D. Nuestra Experiencia con Exoderm en Rejuvenecimiento Facial. *Procedimientos Estéticos Mínimamente Invasivos* Coor. Charles Yamaguchi. Sao Pablo, 2006, Editorial Santos. pp. 165-172.
- [7] Fintsi Y., Landau M. Exoderm: Fenol based peeling in olive and dark skinned patients. *Int J Cosm Surg Aesthet Dermatol*. 2001;3:173-178.
- [8] Gonzalez-Ulloa, M. Restoration of the FACE covering by jeans of selected skin in regional aesthetic units. *Br J Plast Surg*. 1956;9(3):212-221.
- [9] Jackson Ian T. *Colgajos Locales en la Reconstrucción de Cabeza y Cuello*. Barcelona, 1990, Salvat Editores. pp. 136-137.
- [10] Letourneau A., Daniel R.K. The superficial musculoaponeurotic system of the nose. *Plast Reconstr Surg*. 1988;82(1):48-57.
- [11] Cheffe, Luis Oscar. Metodização eclética para tratamento do lábio senil com modificações tácticas Anais do Simpósio Brasileiro do Contorno Facial, Sociedade Brasileira de Cirurgia Plástica. 1983. pp. 244-247.
- [12] Perenack J. Lip modification procedures as an adjunct to improving smile and dental esthetics. *Atlas Oral Maxillofac Surg Clin N. Am*. 2006;14(1):51-74.
- [13] Randolph Waldman S. The subnasal lift. *Facial Plast Surg Clin N Am*. 2007;15(4): 513-516.
- [14] Schalow Al., Townes C.H. Infrared and optical Masers. *Phys Rev*. 1958;112:1940-1949.
- [15] Maimann Th. Stimulated optical radiation in ruby. *Nature* 1960;187:493-494.
- [16] Colls J. *Enfoque Conceptual de las Radiaciones Electromagnéticas*. La Paz. 1987 CDL; pp 1-5.

- [17] Kubelka P. New contributions to the optics of intensity light scattering materials. Part II: Nonhomogeneous layers. *J Opt Soc Am.* 1954;44:330-335.
- [18] Anderson R.R., Parish J.A. Selective photothermolysis precise microsurgery by selective absorption of pulsed radiation. *Science* 1983;220:524-527.

IntechOpen

IntechOpen